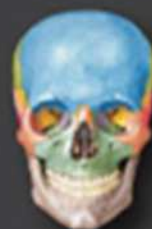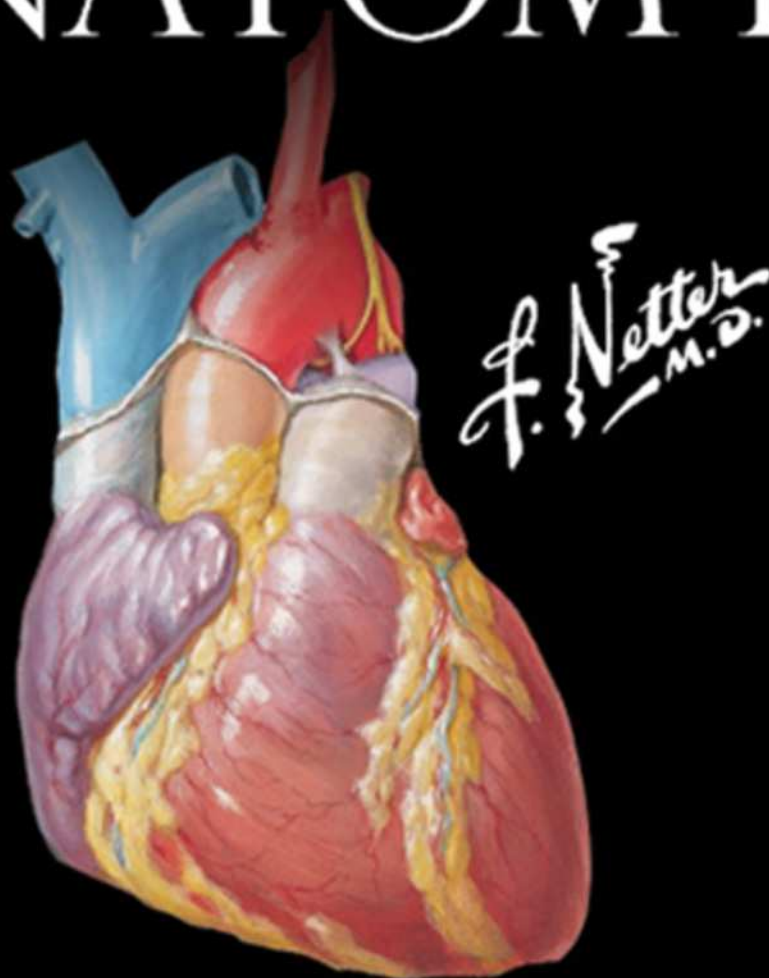


FRANK H. NETTER, MD

O'ZBEK TILIDA

ATLAS OF HUMAN ANATOMY



NETTER

7

SEVENTH
EDITION

ELSEVIER



MUNDARIJA

I-BO'LIM. Bosh va bo'yin

SUYAK VA BOYLAMLAR	1 – 16 rasm
YUZ SOHASI	17 – 21 rasm
BO'YIN	22 – 30 rasm
BURUN SOHASI	31 – 44 rasm
OG'IZ BO'SHLIG'I	45 – 56 rasm
HALQUM	57 – 67 rasm
QALQONSIMON BEZ VA HIQILDOQ	68 – 75 rasm
KO'Z SOQQASI TUZILISHI	76 – 86 rasm
QULOQ	87 – 93 rasm
MIYA VA UNING PARDALARI	94 -109 rasm
BOSH VA BO'YIN NERVLARI	110-129 rasm
MIYANING TOMIRLARI	130-141 rasm

II-BO'LIM. Umutrqa pog'onasi, orqa soha

Suyak va boylamlar	142 – 147 rasm
Orqa miya	148 – 159 rasm
Muskullar va nervlar	160 – 166 rasm

III-BO'LIM. Ko'krak qafasi

KO'KRAK BEZI	167-169 rasm
TANA DEVORLARI	170-183 rasm
O'PKALAR	184-199 rasm
YURAK	200-217 rasm
KO'KS ORALIG'I	218-230 rasm

IV-BO'LIM. Qorin

TANA DEVORLARI	231 - 250
QORIN BO'SHLIG'I	251 – 257 rasm
ICHKI A'ZOLAR	258 – 268 rasm
QORIN BO'SHLIG'I A'ZOLARI	269-281
ICHKI A'ZOLARNING QON BILAN TA'MINLANISHI	282 – 299 rasm
ICHKI A'ZOLAR INNERVATSIYASI	300-310 rasm
BUYRAK VA BUYRAK USTI BEZLARI	311-329 rasm

V-BO'LIM. Chanoq va oraliq

Suyak va boylamlar	330 -332 rasm.
Chanoq bo'shlig'i tubi	333 - 343 rasm.
Ayollar chanoq bo'shlig'i	344 – 353rasm.
erkaklar chanoq bo'shlig'i	354 – 362 rasm
TO'G'RI ICHAK	363 - 368 rasm
QON BILAN TA'MINLANISHI	369 - 379 rasm
INNERVATSIYASI	380 – 390 rasm

VI-BO'LIM. Qo'l sohasi

YELKA KAMARI SUYAKLARI	391 -401 rasm
YELKA	402 - 406 rasm
BILAK SOHASI VA TIRSAK BO'G'IMI	407 - 421 rasm
KAFT	422 - 440 rasm
QON BILAN TA'MINLANISHI VA	441 - 452 rasm
INNERVATSIYASI	

VII-BO'LIM. Oyoq sohasi

CHANOQ VA SON	453 - 471 rasm
TIZZA	472 - 477 rasm
BOLDIR	478 - 487 rasm
PANJA VA BOLDIR-PANJA BO'G'IMI	488 - 501 rasm
QON BILAN TA'MINLANISHI VA	502 – 510 rasm
INNERVATSIYASI	

I bo'lim.

BOSH

VA

BO'YIN

SUYAKLAR VA BOYLAMLAR

1-16rasm

1. Kalla suyagi (cranium): old tomoni (norma facialis)
2. Kalla suyagi: yon tomoni (norma lateralis)
3. Kalla suyagi: o'rta sagittal kesim
4. Kalla suyagi asosi (calvaria)
5. Kalla suyagi tashqi asosi (basis cranii externa)
6. Kalla suyagi ichki asosi (basis cranii interna)
7. Kalla suyagi ichki asosining teshiklari
8. Yangi tug'ilgan chaqaloqlarning kalla suyagi
9. Bosh va bo'yin skeleti
10. Pastki jag' suyagi (mandibula)
11. Chakka-pastki jag' bo'g'imi (articulatio temporomandibularis)
12. Bo'yin umurtqalari (vertebrae cervicales): atlant (atlas) va aksis (axis).
13. Bo'yin umurtqalari (vertebrae cervicales), davomi

14. Atlant-ensa va bo'yinning tashqi boylamlari

15. Atlant-ensa va bo'yinning tashqi boylamlari

16. Atlant-ensa bo'g'imi

YUZ SOHASI

17-21rasm

17. Boshning yuza arteriya va venalari

18. Bosh va bo'yinning teri nervlari

19. Yuz nervi (n. facialis) va quloq oldi so'lak bezi (glandula parotidea [parotis])

20. Mimik muskullar: (musculi faciei) oldidan ko'rinishi

21. Mimik muskullar: (musculi faciei), yon tomondan ko'rinishi

BO'YIN

22-30rasm

22. Boshning yuza arteriya va venalari

23. Bo'yin muskullari (musculi colli), yon tomoni

24. Tilosti suyagidan pastda va yuqorida turuvchi muskullar
25. Narvonsimon va umurtqaoldi muskullari
26. Bo'yinning yuza venalari va teri nervlari
27. Bo'yin chigali
28. O'mrov osti arteriyasi (a. subclavia)
29. Tashqi uyqu arteriyasi (a. carotis externa)
30. Bo'yin fassiyalari

BURUN SOHASI

31-44rasm

31. Tashqi burun (nusus externus)
32. Burun bo'shlig'i lateral devori (cavi- tas [cavum] nasi)
33. Burun bo'shlig'i lateral devori (davomi)
34. Burun bo'shlig'i medial devori (septum nasi)
35. Yuqori jag' arteriyasi (a. maxillaris)
36. Burun bo'shlig'i arteriyalari: burun to'sig'i yuqoriga ko'tarilgan
37. Burun bo'shlig'i nervlari: burun to'sig'i yuqoriga ko'tarilgan
38. Burun bo'shlig'i nervlari (davomi)
39. Burun bo'shlig'ining vegetativ innervatsiyasi
40. Ko'z (n. ophthalmicus) va yuqori jag' (n. maxillaris) nervlari
41. Pastki jag' nervi (n. mandibularis)
42. Burun yondosh bo'shliqlari (sinus paranasales)
43. Burun yondosh bo'shliqlari (sinus paranasales)
44. Burun yondosh bo'shliqlari, sinus paranasales: yoshga qarab o'zgarishi.

OG'IZ

BO'SHLIG'I

45-56rasm

45. Og'iz bo'shlig'ini tekshirish
46. Og'iz bo'shlig'ini yuqori devori
47. Og'iz bo'shlig'ini tubi
48. Chaynov (mm. masticatorii) va mimik muskullar (mm. faciei)
49. Chaynov muskullari, mm. masticatorii (davomi)
50. Tishlar (dentes)

51. Tishlar, dentes (davomi)
52. Til (lingua)
53. Til (lingua), davomi
54. Til va so'lak bezlari (kesimlar)
55. Solak bezlari (glandulae salivariae)
56. Sezuvchi (afferent) og'iz bo'shlig'i innervatsiyasi

HALQUM

57-67rasm

57. Halqum (pharynx): o'rta sagittal kesim
58. Tomoq (faucis)
59. Halqum muskullari: o'rta sagittal kesim
60. Halqum (ochilgan), orqa tomoni
61. Halqum muskullari: orqa devori qisman ochilgan
62. Halqum muskullari: yon tomoni
63. Halqum va og'iz sohasi arteriyalari
64. Halqum va og'iz sohasi venalari
65. Halqum va og'iz sohasi nervlari
66. Bosh va bo'yin limfatik tomirlari va tugunlari
67. Til va halqumning limfatik tomirlari hamda tugunlari

QALQONSIMON BEZ VA HIQILDOQ

68-75rasm

68. Qalqonsimon bez (glandula thyroidea), old tomoni
69. Qalqonsimon bez va halqum: orqa tomoni
70. Qalaonoldi bezlari (glandulae parathyroideae)
71. Hiqildoq tog'aylari
72. Hiqildoq muskullari (musculi larynges)
73. Hiqildoq muskullarining ta'sir qilish mexanizmi
74. Hiqildoq nervlari
75. Hiqildoqni tekshirish

KO'ZNING TARKIBI

76-86rasm

76. Qovoqlar (palpebrae)
77. Ko'z yoshi apparati (apparatus lacrimalis)
78. Ko'z (orbita): uning tarkibi
79. Ko'z olmasining muskullari (musculi bulbi)

80. Ko'z kosasi va ko'z olmasining arteriya va venalari
81. Ko'z kosasi nervlari
82. Ko'z olmasi (bulbus oculi)
83. Ko'zning oldingi va orqa kameralari
84. Shox-to'r parda burchagi va ko'zning oldingi kamerasi
85. Gavhar (lens) va uni ushlab turuvchi tuzilmalar
86. Ko'z olmasining arteriya va venalari

QULOQ

87-93rasm

87. Eshitish analizatorining yo'llari
88. Tashqi va o'rta quloq (auris externa et auris media)
89. Nog'ora bo'shlig'i (cavitas tympani)
90. Pardali va suyak labirinti (labyrinthus osseus et labyrinthus membranaceus)
91. Pardali va suyak labirinti (davomi)
92. Kalla suyagida labirintning joylashuvi
93. Eshituv nayi (tuba auditiva)

MIYA VA UNING PARDALARI

94-109rasm

94. Miya pardalari (meninges) va diploik venalar (venae diploicae)
95. Meningeal arteriyalar (arteriae meningeae)
96. Miya pardalari va yuza venalari
97. Miya qattiq pardasining sinuslari (sinus durae matris)
98. Miya qattiq pardasining sinuslari (sinus durae matris) (davomi)
99. Bosh miya(cerebrum): lateral tomoni
100. Bosh miya (cerebrum): medial tomoni
101. Bosh miya (cerebrum): pastdan ko'rinishi
102. Miya qorinchalari
103. Orqa miya suyuqligining sirkulyatsiyasi
104. Bazal yadrolar (nuclei basales)
105. Talamus

106. Gippokamp va gumbaz (hippocampus et fornix)
107. Miyacha (cerebellum)
108. Miya sopi (truncus encephali)
109. Miyacha va 4-qorincha (ventriculus quartus et cerebellum)

BOSH VA BO'YIN

NERVLARI

110-129rasm

110. Miya sopidagi bosh miya nervlarining yadrolari: sxemasi
111. Miya sopidagi bosh miya nervlarining yadrolari: sxemasi (davomi)
112. Bosh miya nervlarining sezuvchi va harakatlantiruvchi tolalari
113. Hid bilish nervi (nervus olfactorius [fila olfactoria])
114. Ko'ruv nervi (nervus opticus)
115. Ko'zni harakatlantiruvchi (n. oculomotorius), g'altak (n. trochlearis) va uzoqlashtiruvchi (n. abducens) nervlar
116. Uch shoxli nerv (n. trigeminus)
117. Yuz nervi (n. facialis)
118. Dahliz-chig'anoq nervi (n. vestibulocochlearis)
119. Til-yutqin nervi (n. glossopharyngeus)
120. Adashgan nerv (n. vagus)
121. Qo'shimcha nerv (n. accessorius)
122. Tilosti nervi (n. hypoglossus)
123. Bo'yin chigali (plexus cervicalis)
124. Bo'yinnig avtonom (vegetativ) nervlari
125. Boshning avtonom(vegetativ) nervlari
126. Kipriksimon tugun (ganglion ciliare)
127. Qanot-tanglay va jag'osti tugunlari (ganglion pterygopalatinum et ganglion submandibulare)
128. Quloq tuguni (ganglion oticum)
129. Ta'm bilish sezgisi

MIYA TOMIRLARI

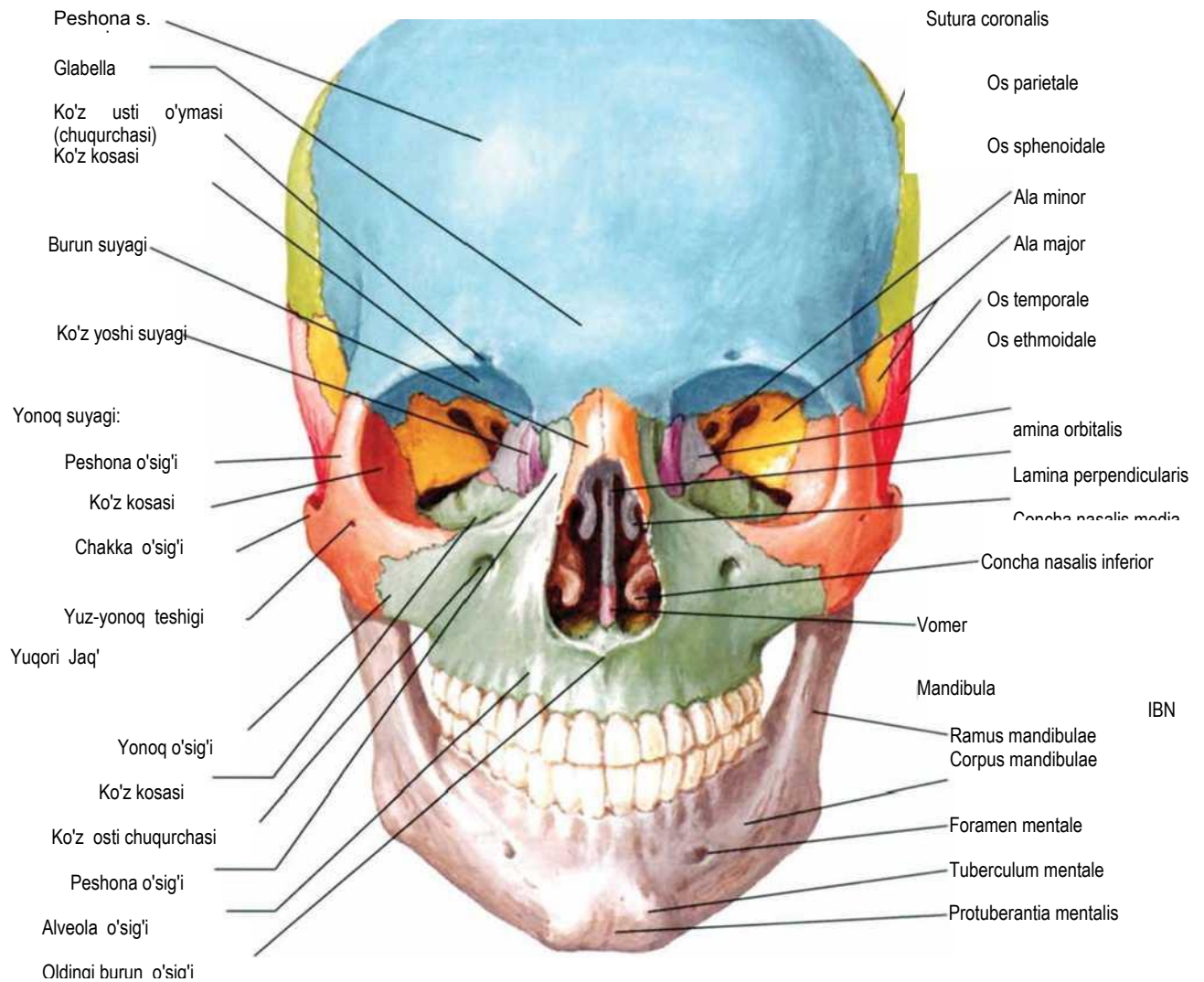
130-141rasm

130. Miya va uning pardasi arteriyalari
131. Miya arteriyalari: sxemasi

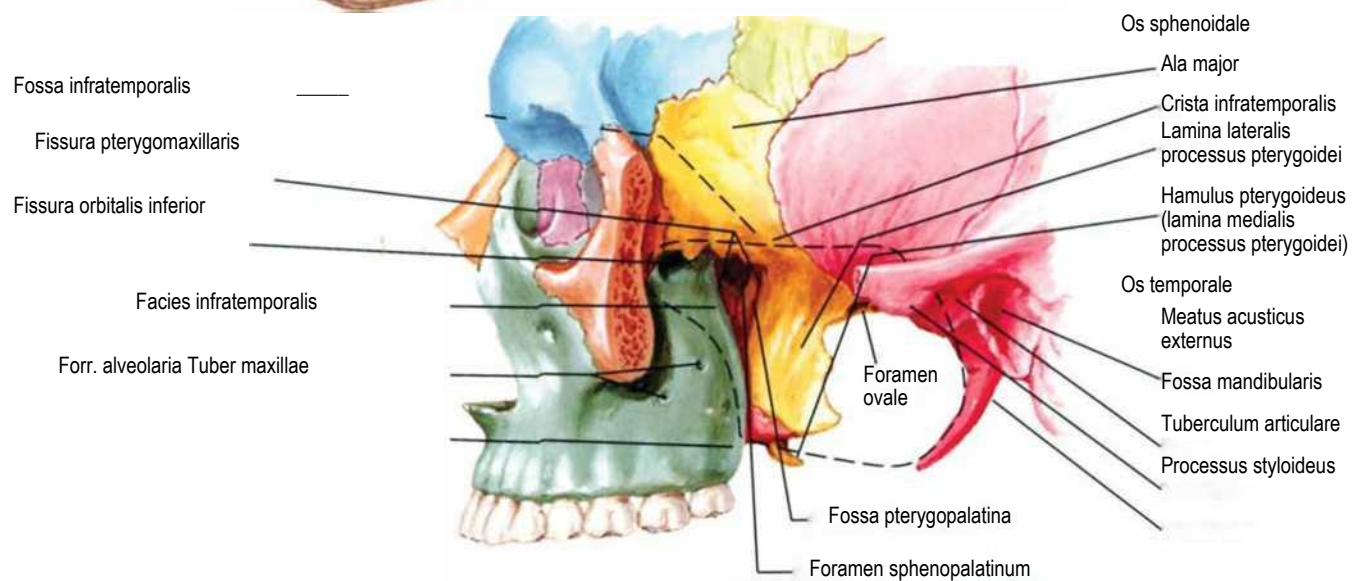
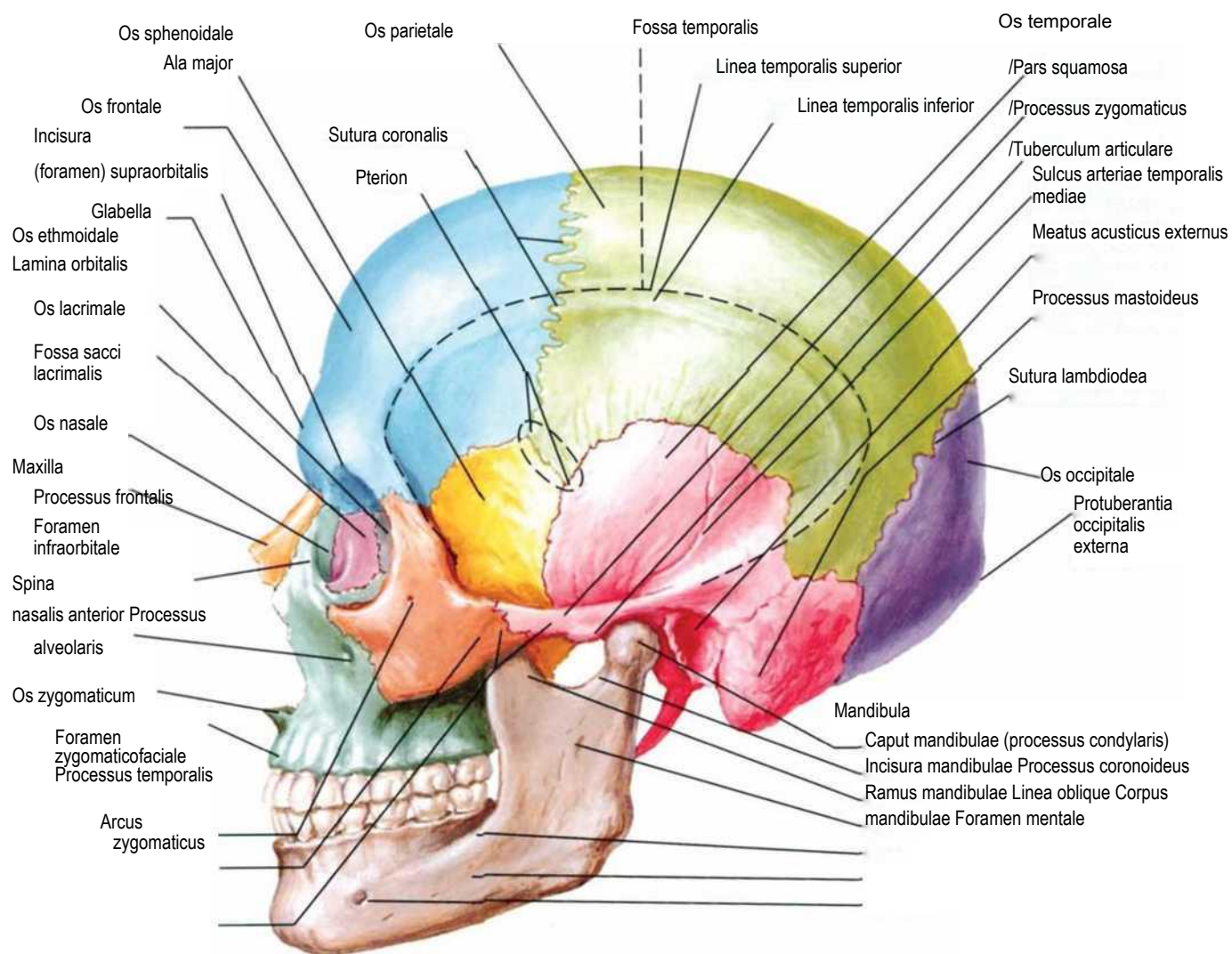
- 132. Miya arteriyalari: pastdan ko'rinishi
- 133. Bosh miya arterial doirasi (circulus arteriosus cerebri), Villiziy halqasi
- 134. Miya arteriyalari: frontal kesim va oldidan ko'rinishi
- 135. Miya arteriyalari: yarimsharlarning medial va lateral tomonlaridan ko'rinishi

- 136. Kalla suyagi orqa chuqurchasining arteriyalari
- 137. Kalla suyagi orqa chuqurchasining venalari
- 138. Miyaning chuqur venalari
- 139. Miyaning chuqur venalari:sxemasi
- 140. Gipotalamus va gipofiz

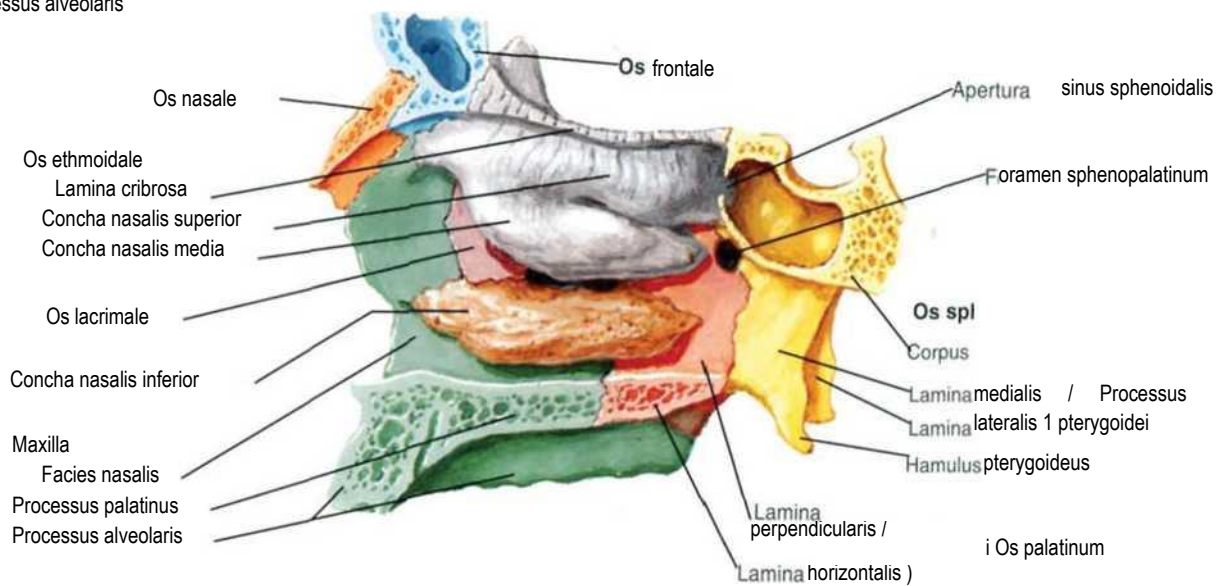
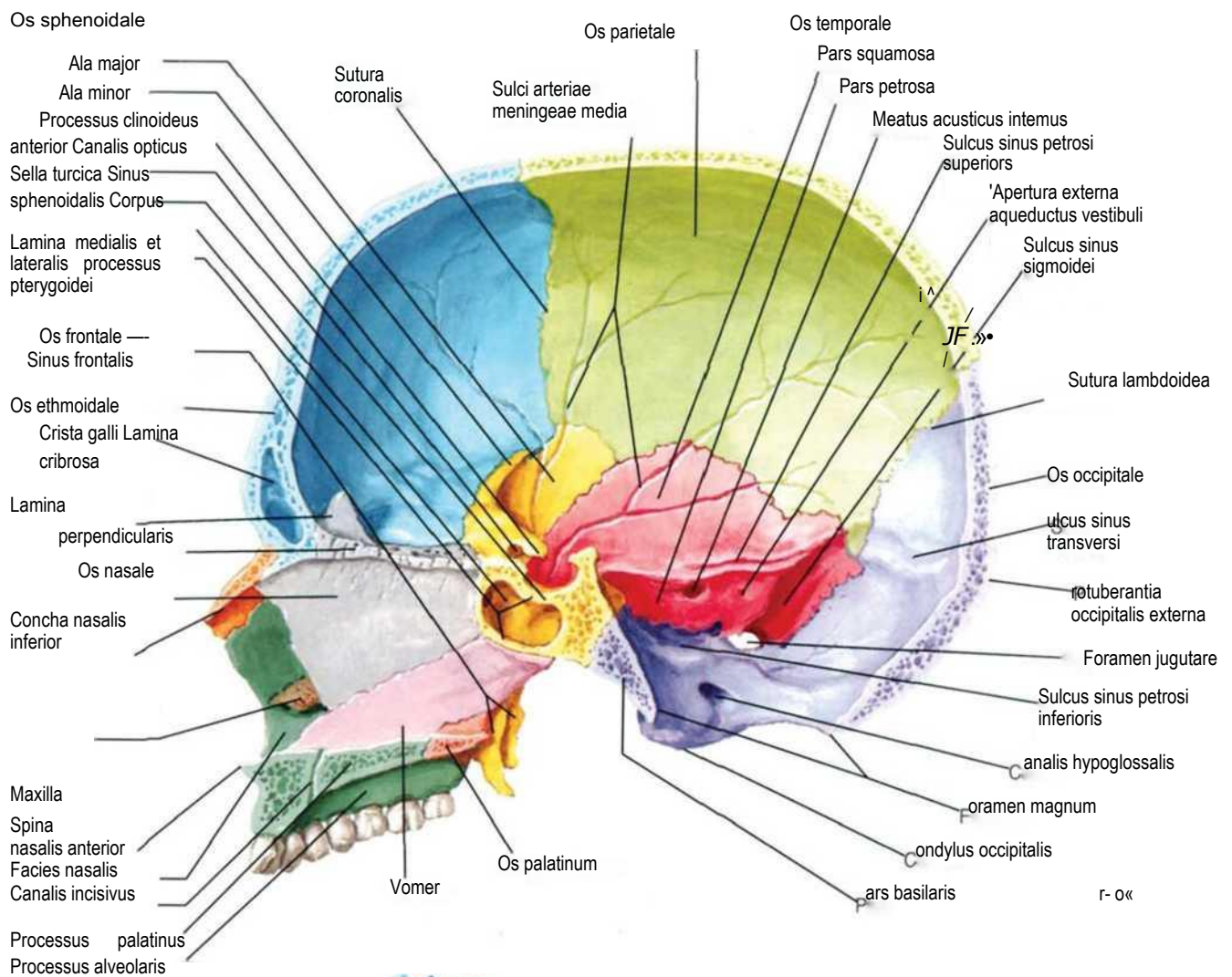
Kalla suyagi



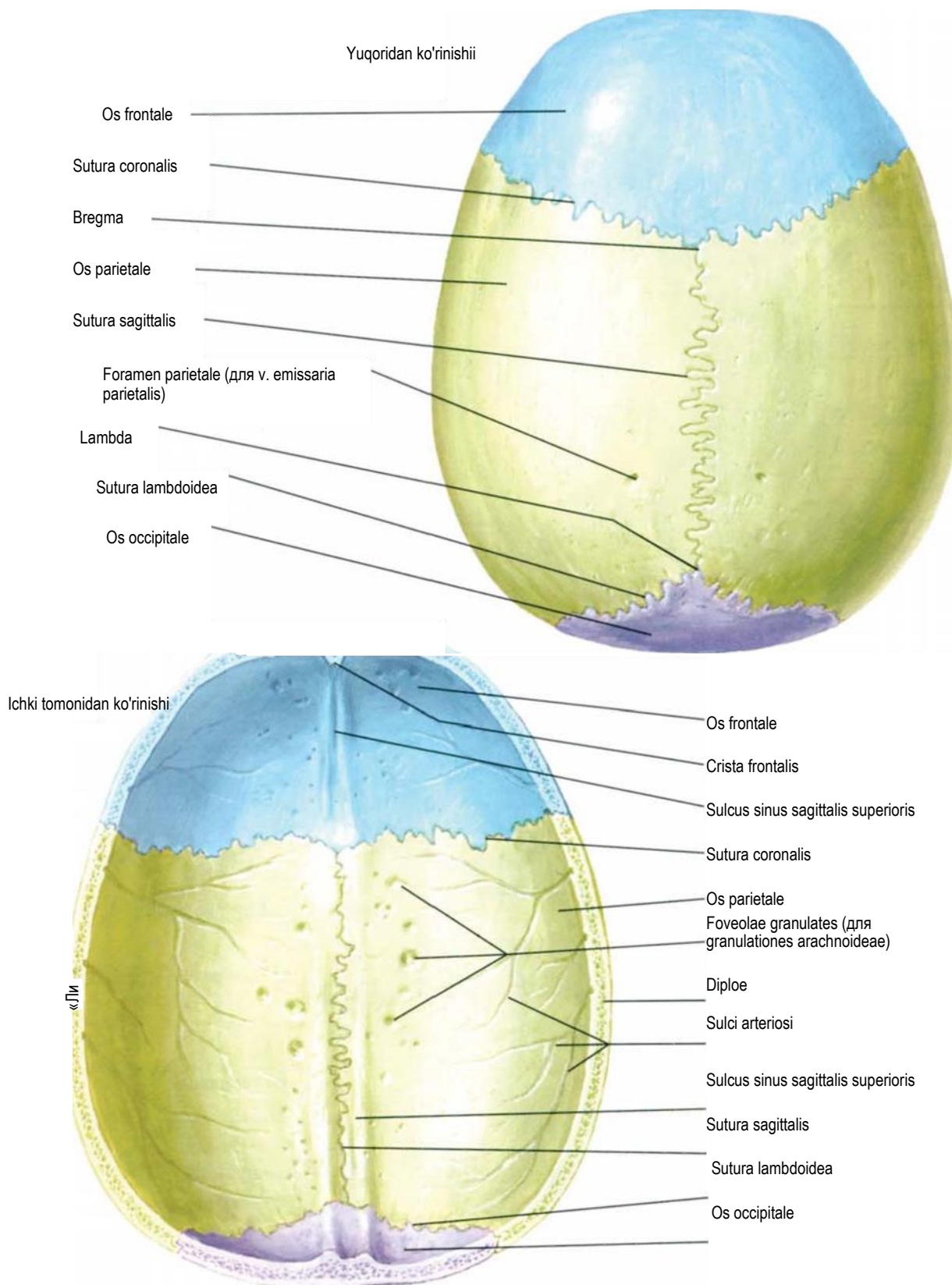
Kalla suyagi:yon tomondan ko'rinishi



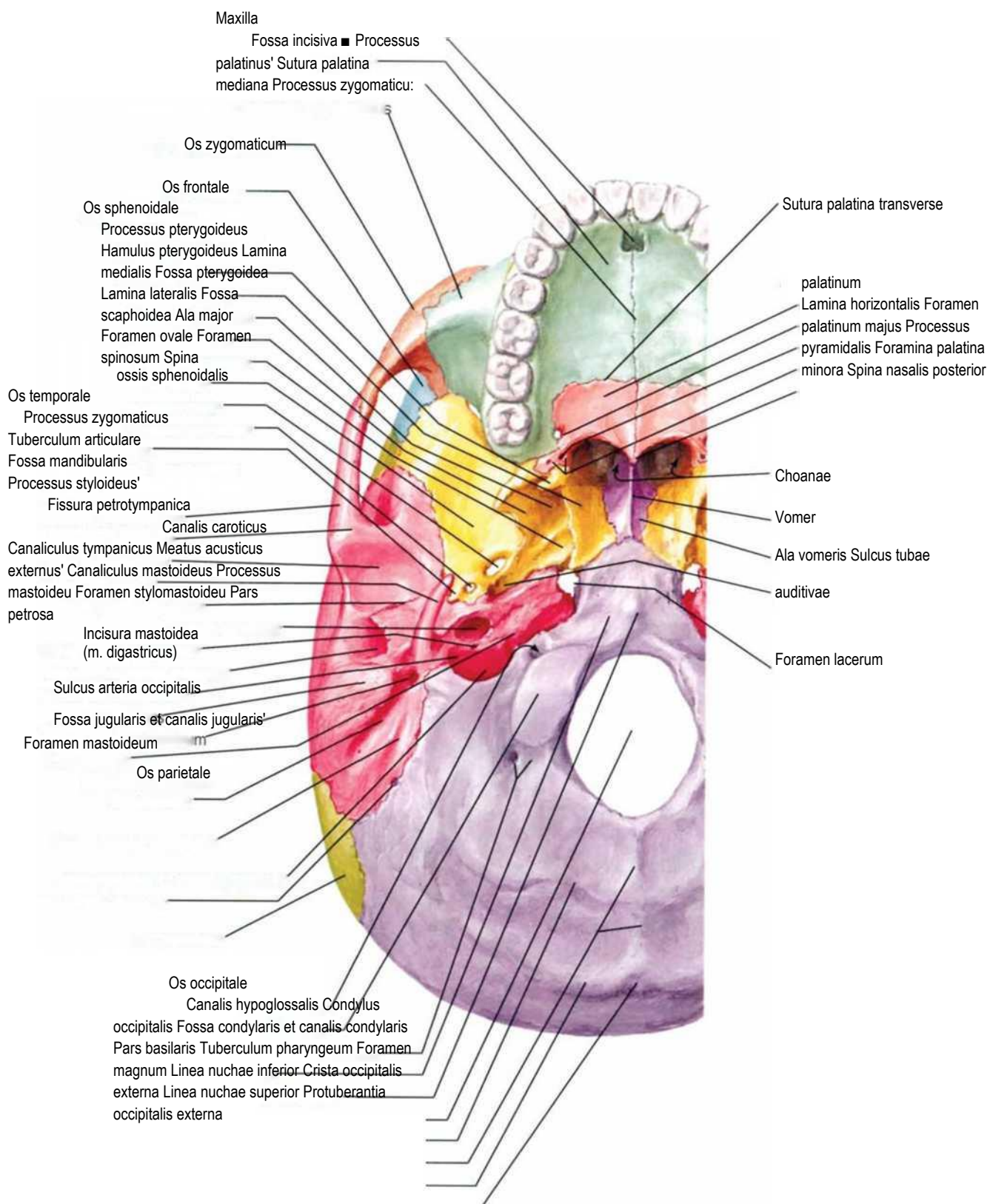
Kalla suyagi: o'rta sagittal kesmasi



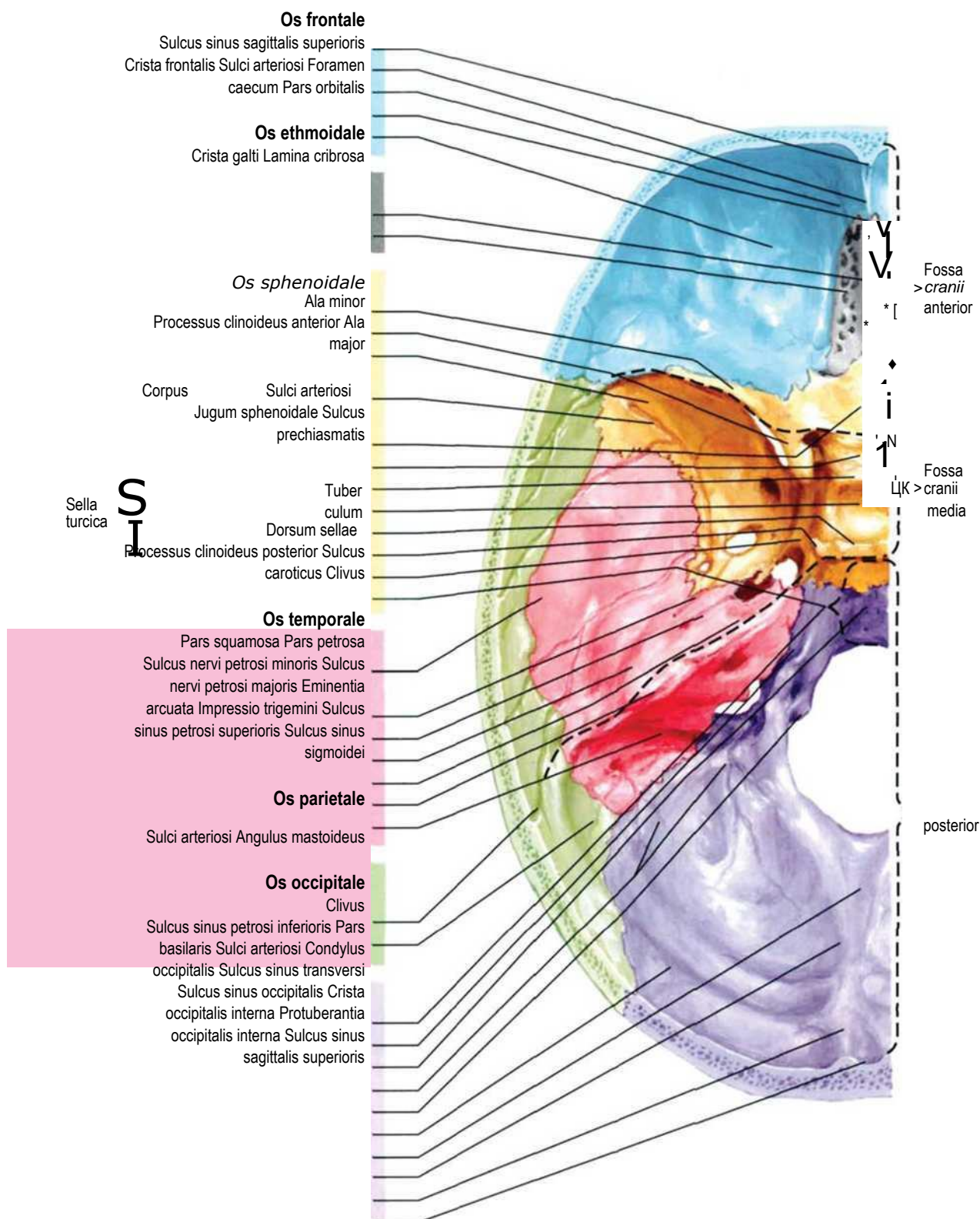
Kalla suyagidagi choklar(calvaria)



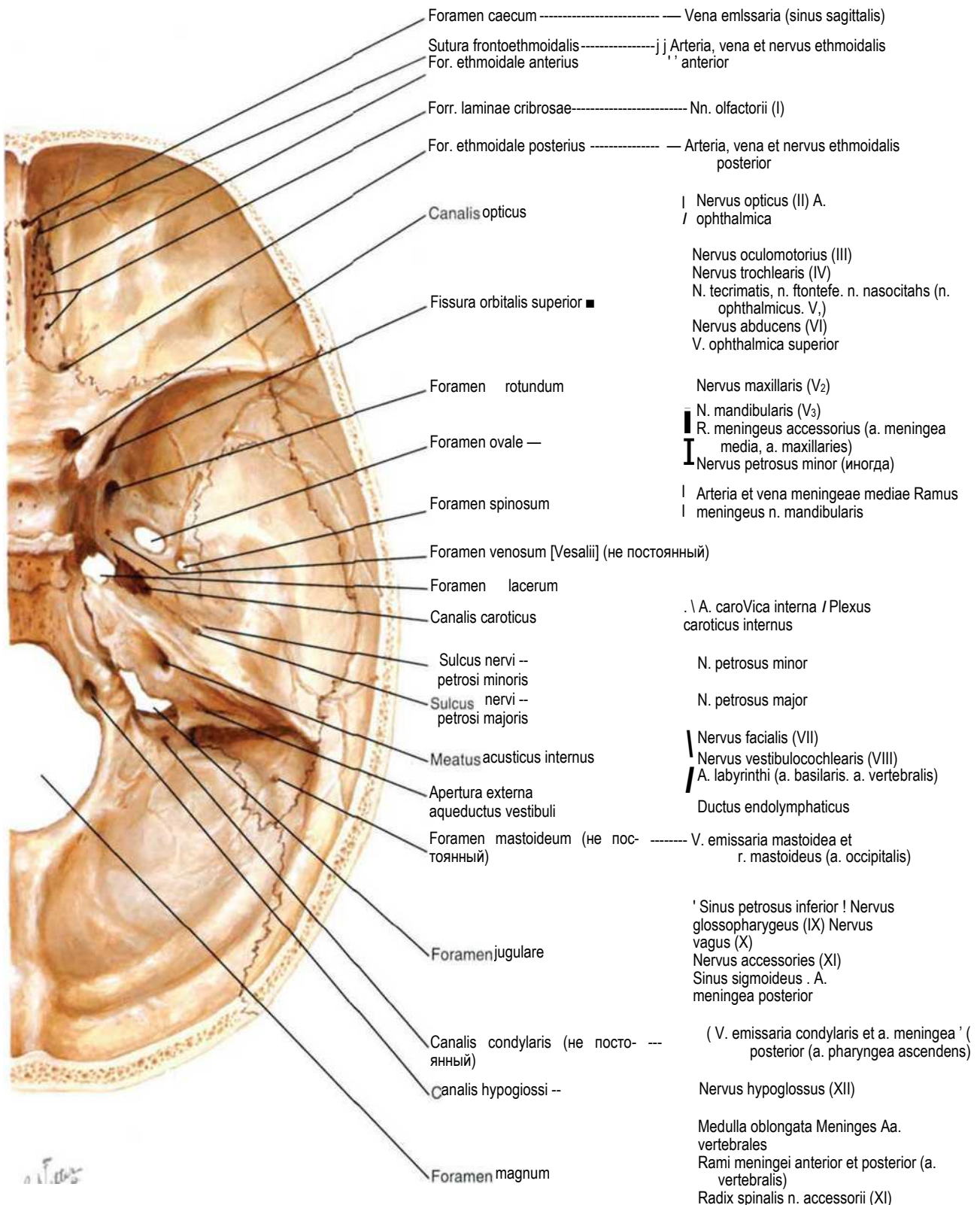
Kalla suyagining tashqi asos qismi (basis cranii externa)



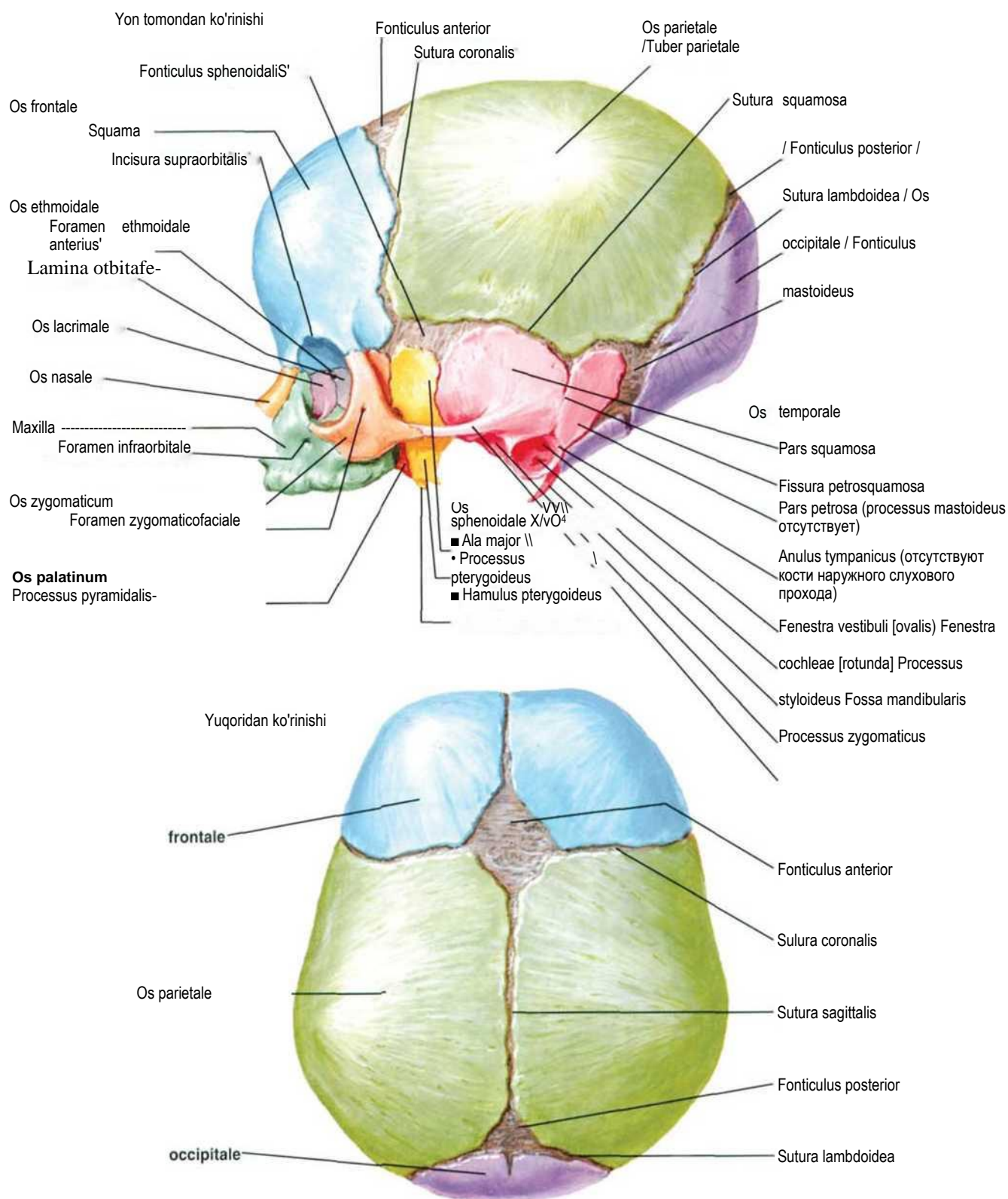
Kalla suyagining ichki asos qismi (basis cranii interna)

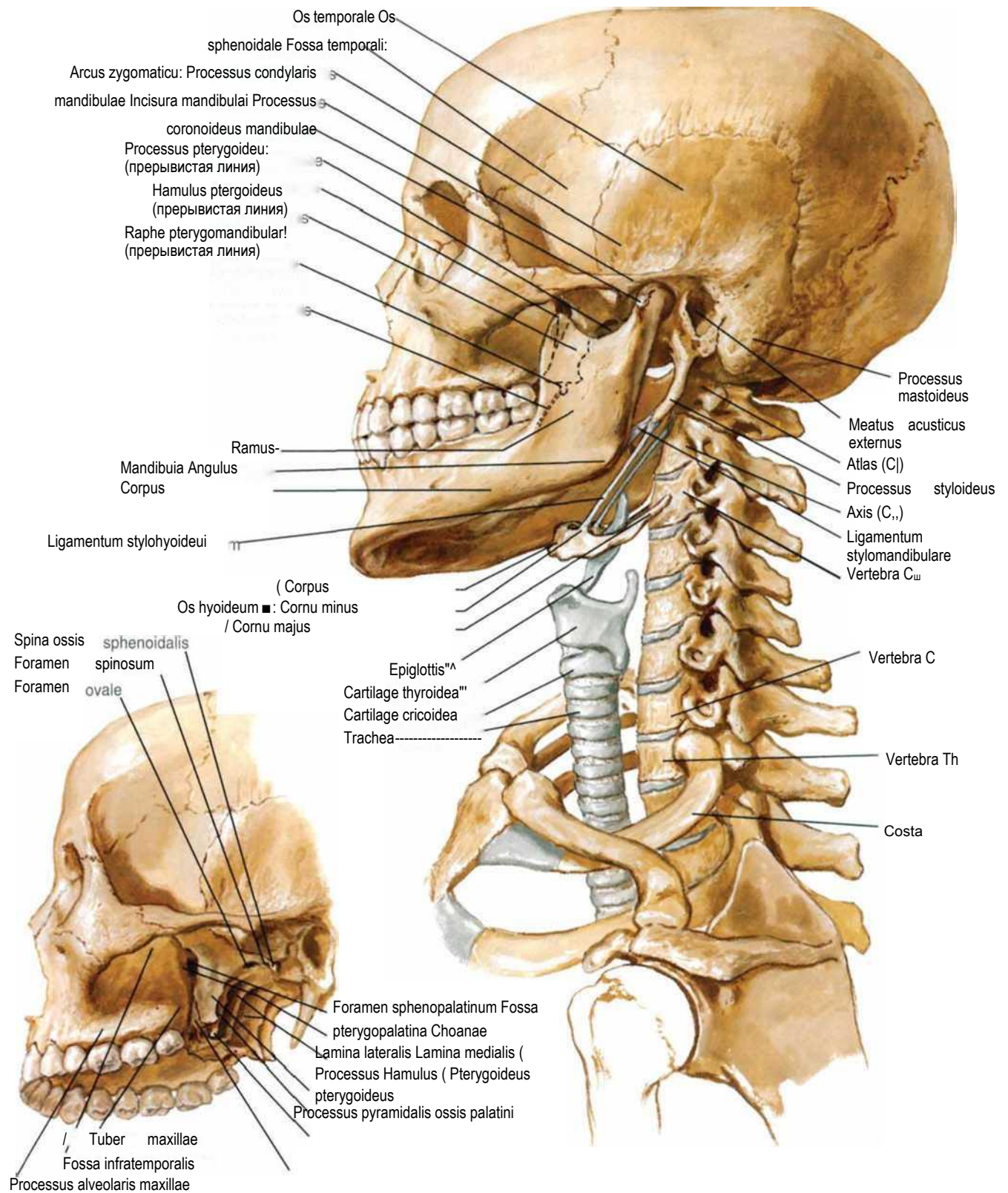


Kalla suyagi ichki asosidagi teshiklar

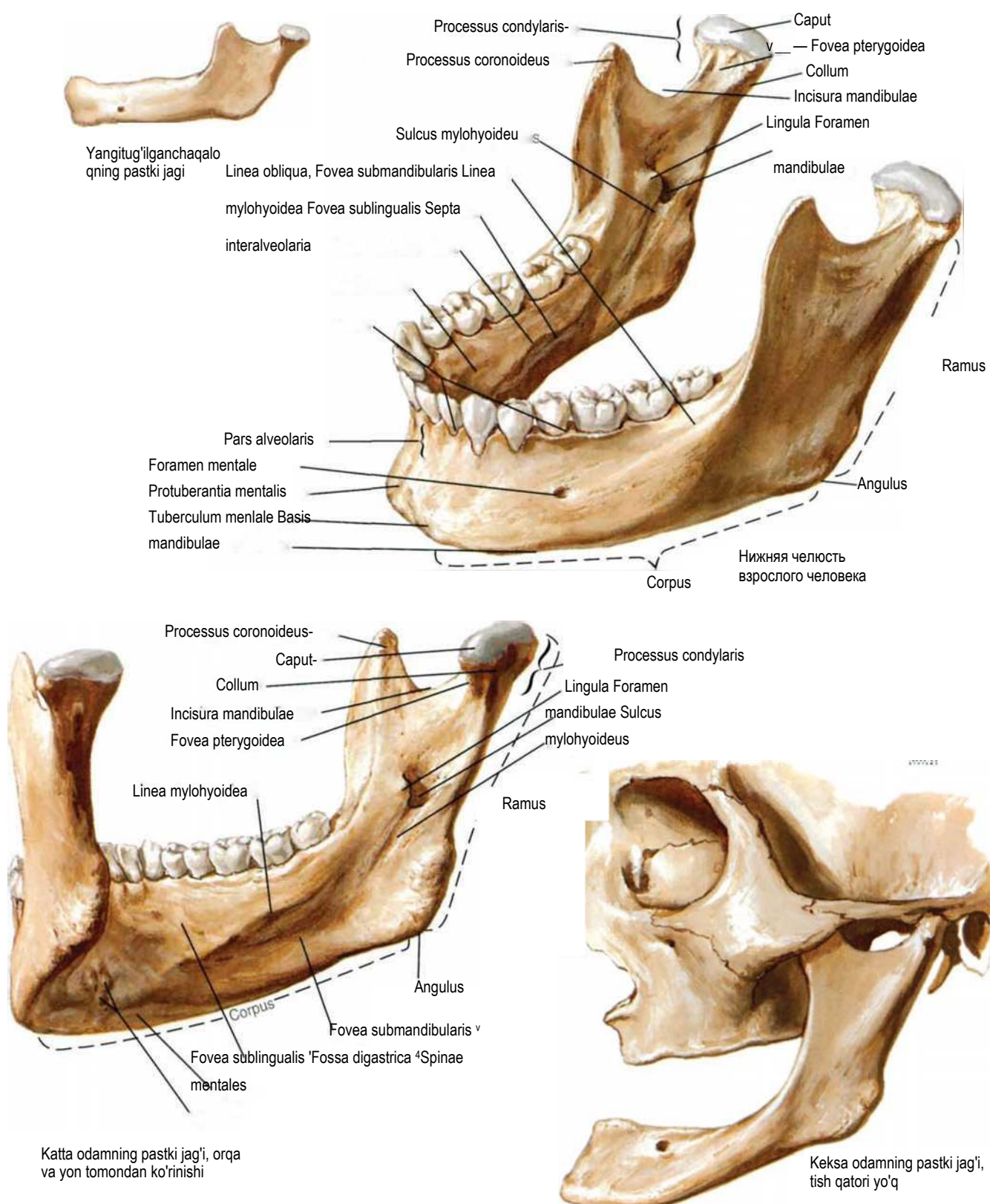


Yangi tug'ilgan chaqaloqlarning kalla suyagi

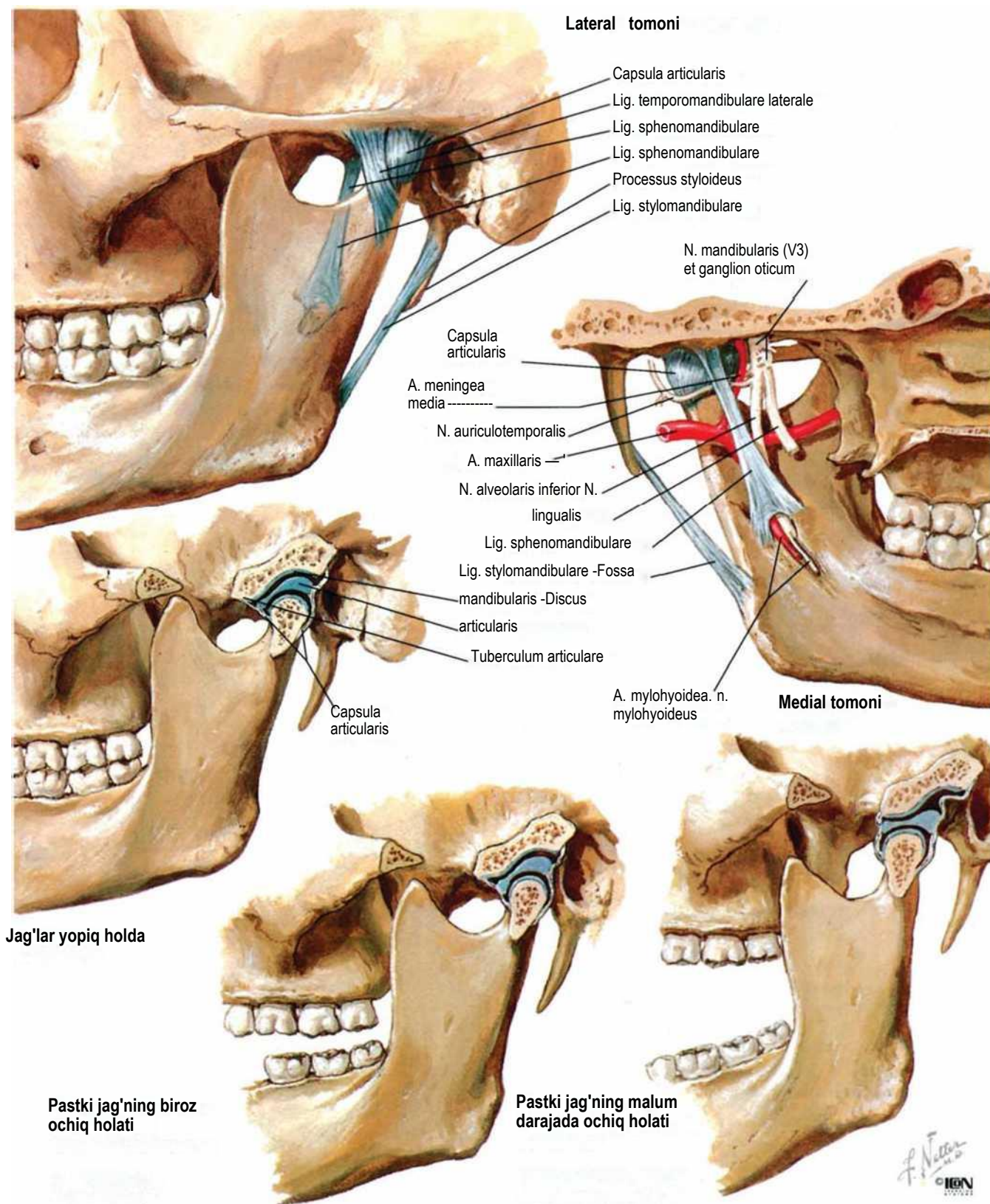




Pastki jag' (mandibula)

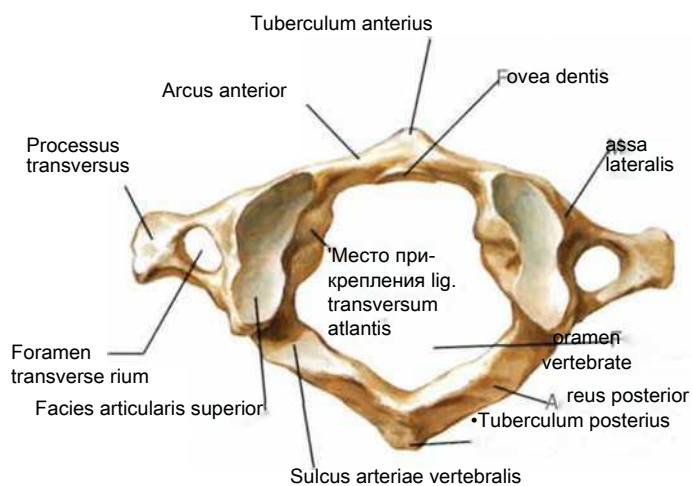


Chakka-pastki jag' bo'g'imi (articulatio temporomandibularis)

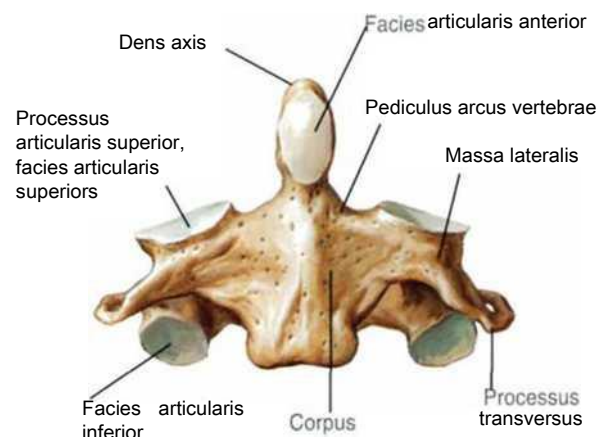


Bo'yin umurtqalari: atlant (atlas) va II-bo'yin umurtqasi (axis)

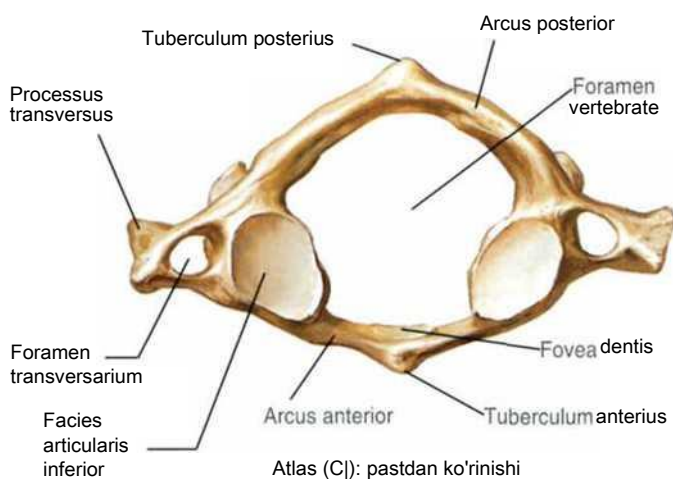
Rasmga qarang 9. 142



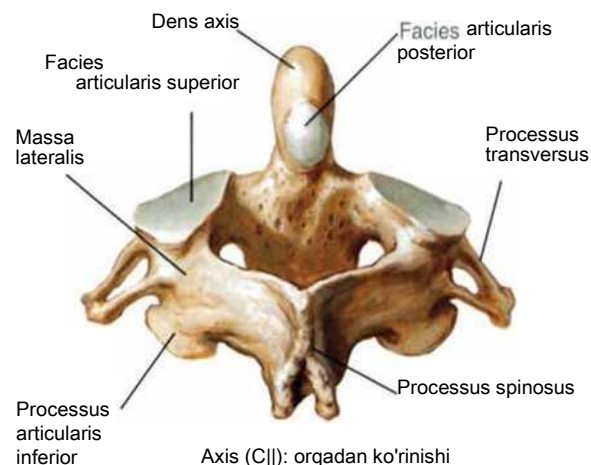
Atlas (C1): yuqoridan ko'rinishi



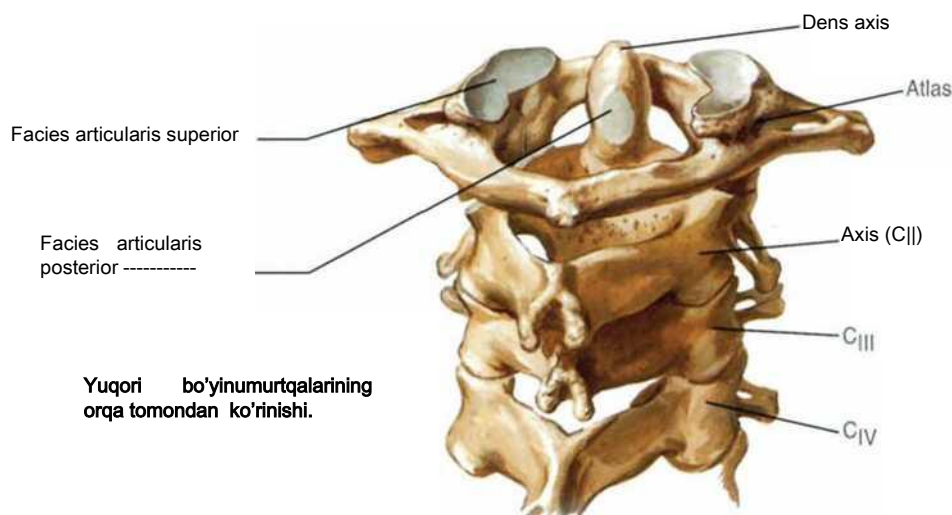
Axis (C2): oldidan ko'rinishi



Atlas (C1): pastdan ko'rinishi



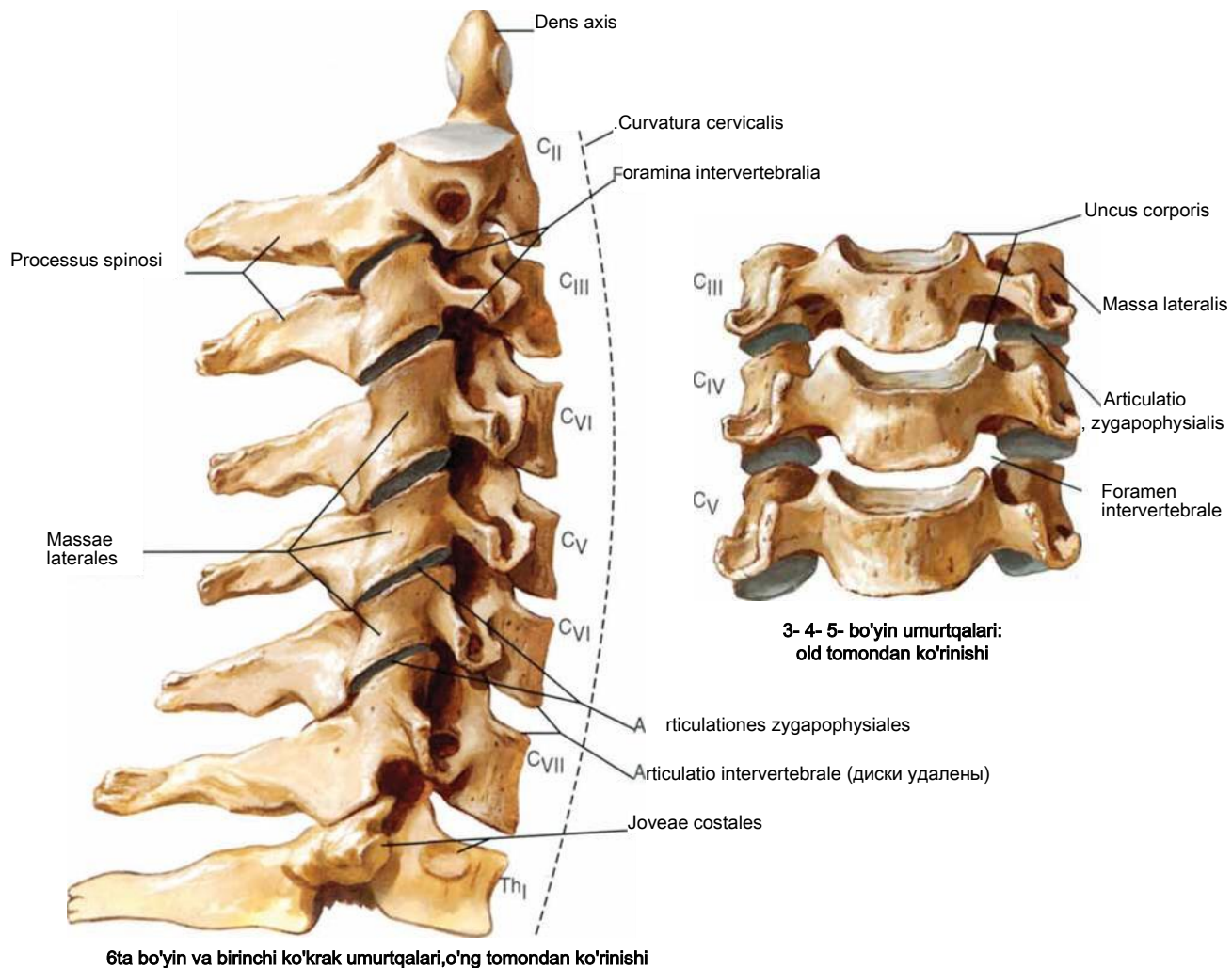
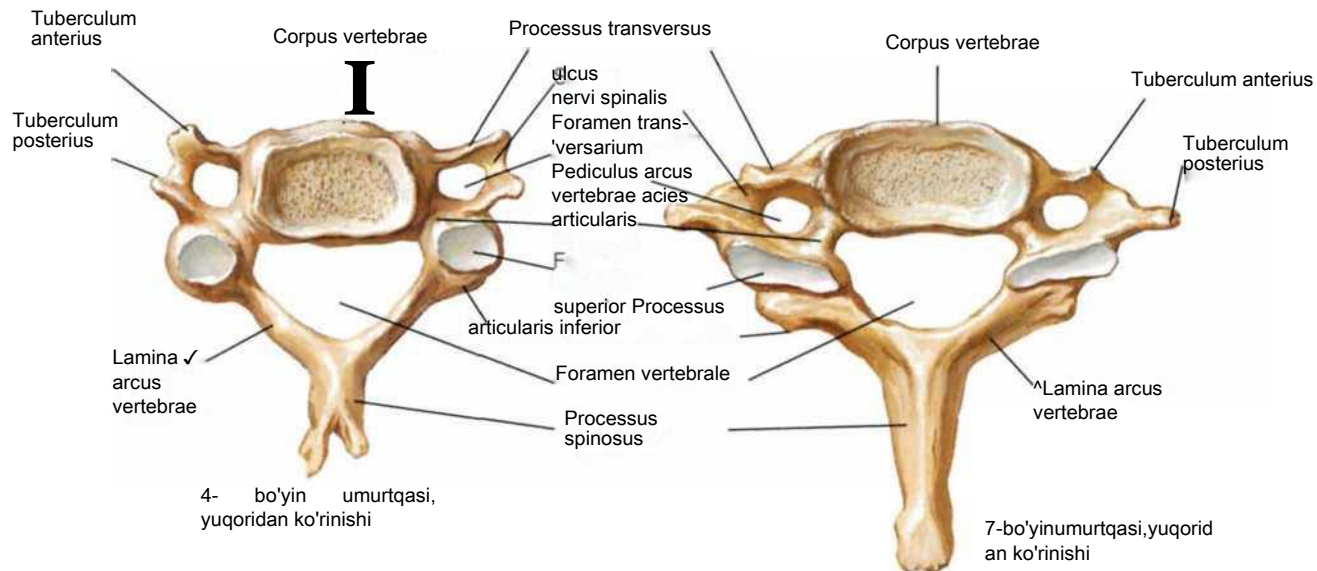
Axis (C2): orqadan ko'rinishi



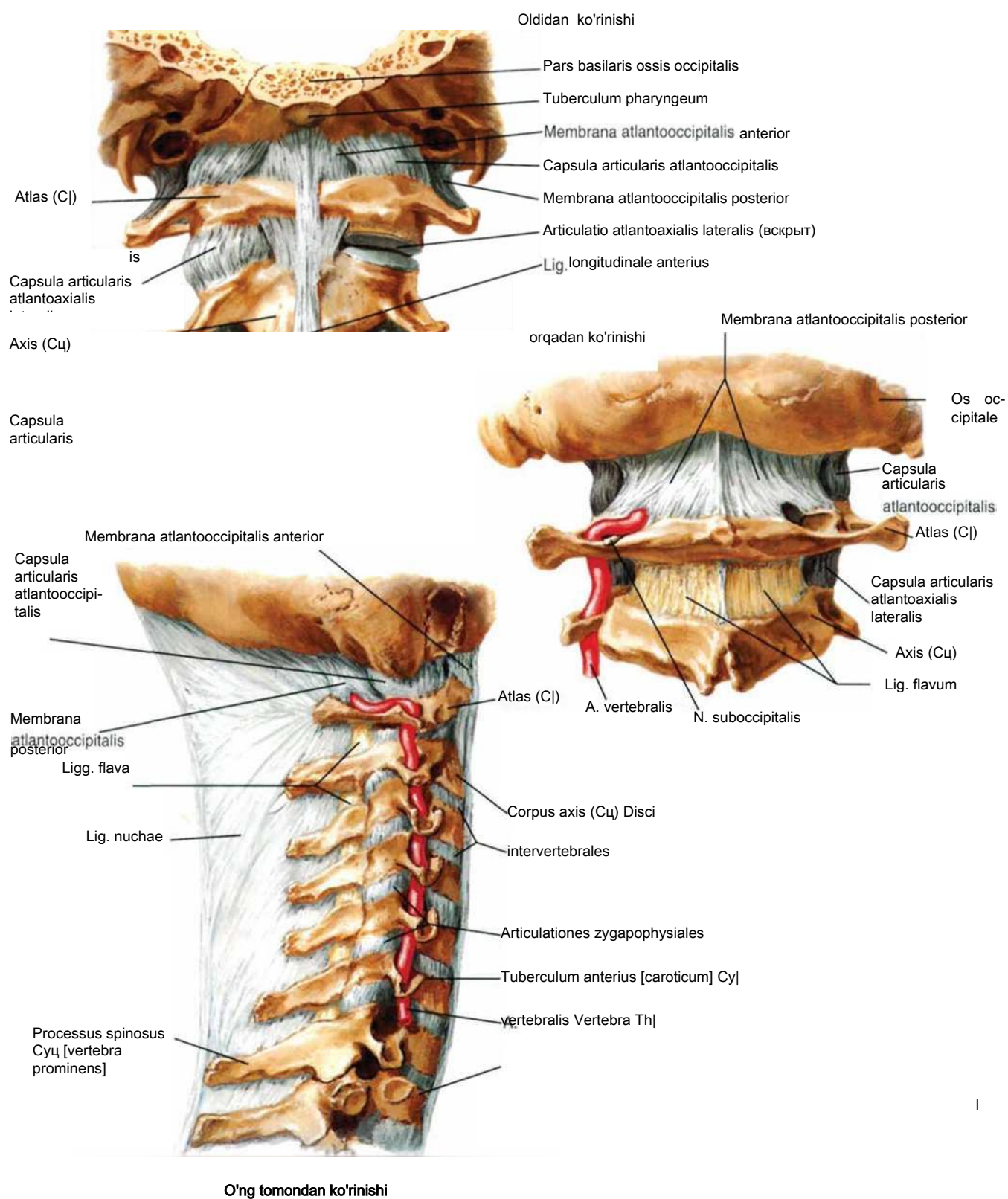
Yuqori bo'yinumurtqalarining orqa tomondan ko'rinishi.

Bo'yin umurtqalari (vertebrae cervicales), davomi

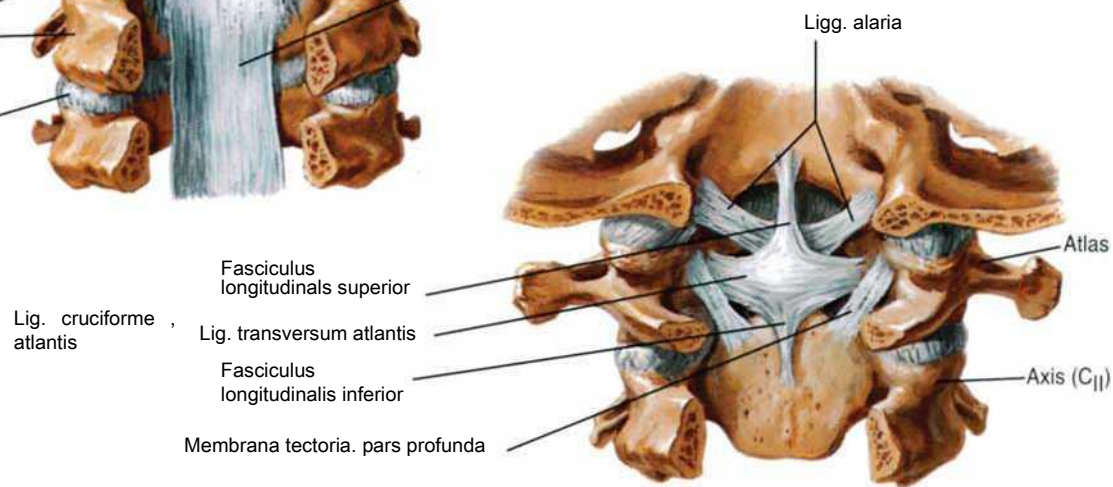
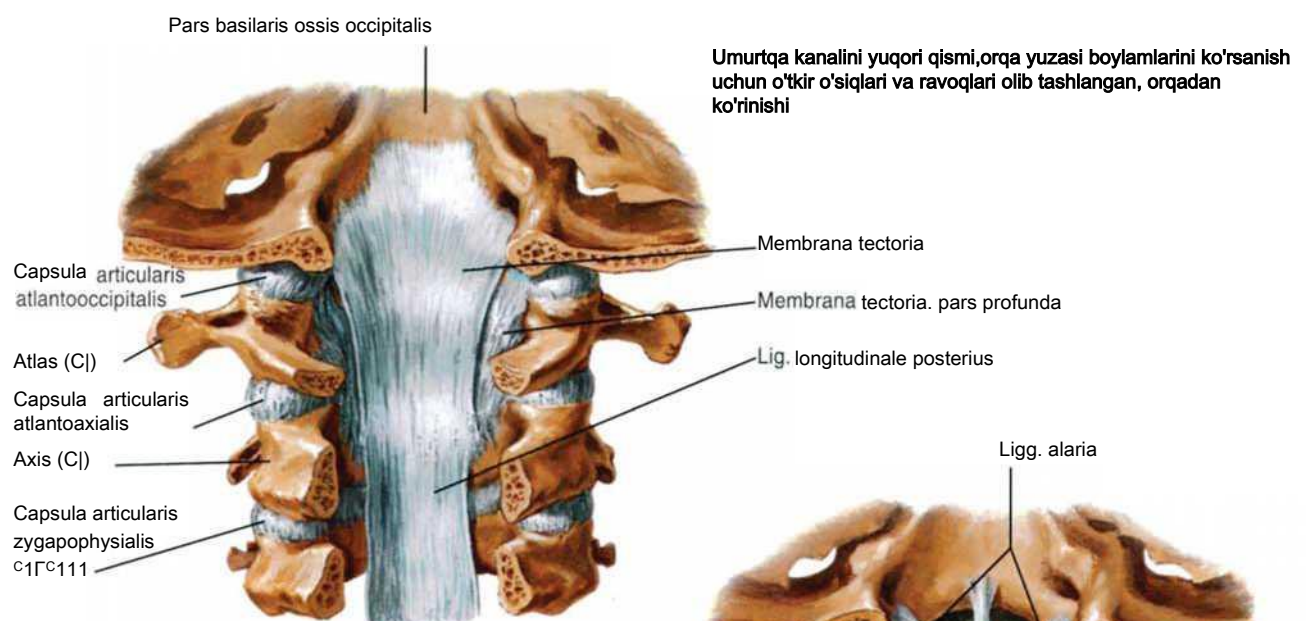
9. 142-rasmlarga qarang



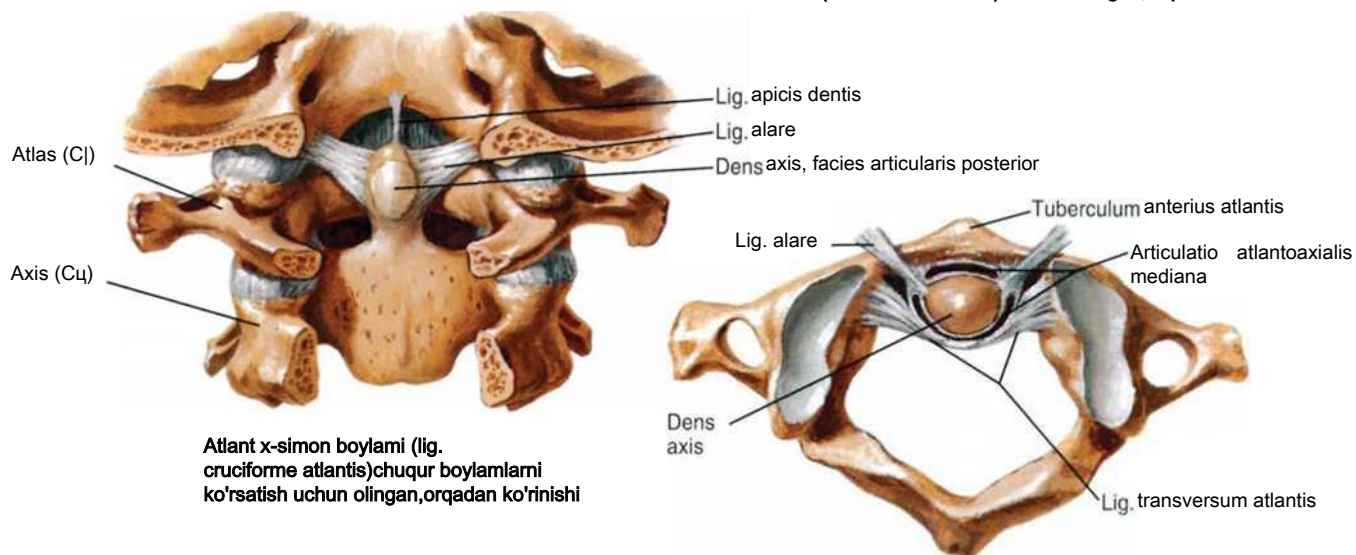
Ensa-atlant bo'g'imining va bo'yinning tashqi boylamlari



Ensa-atlant bo'g'imining va bo'yinning tashqi boylamlari



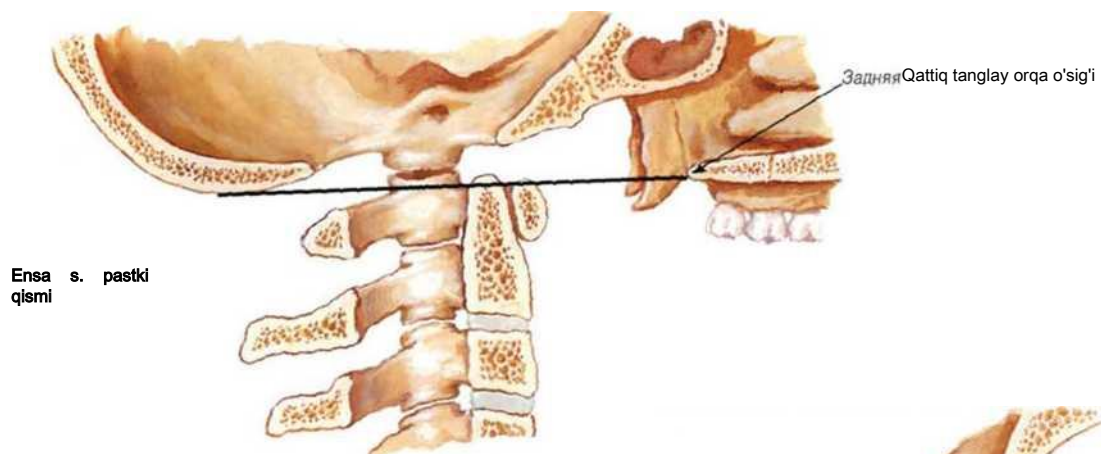
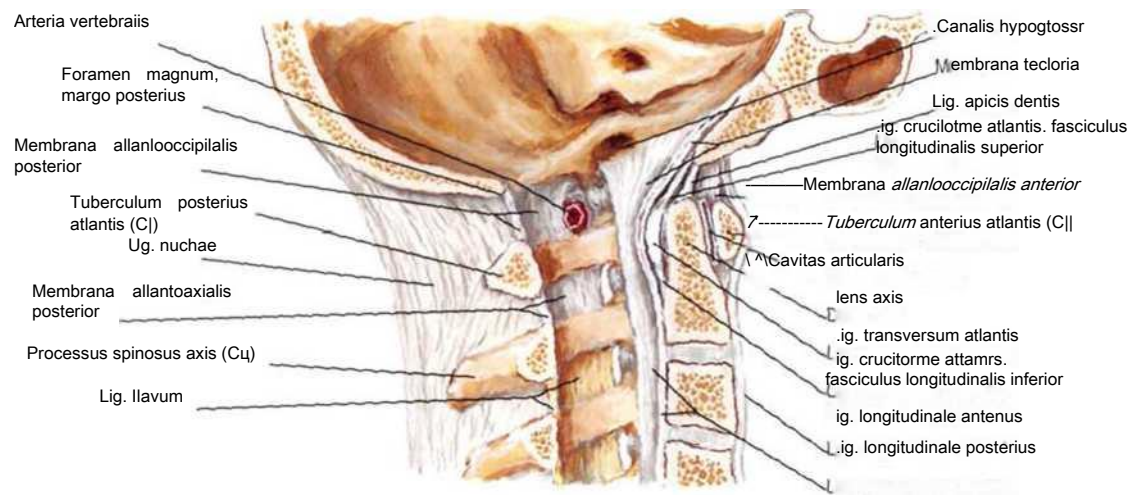
Chuqur joylashgan boylamlarni ko'rsatish uchun qoplovchi membrana (membrana tectoria) olib tashlangan, orqa ko'rinishi



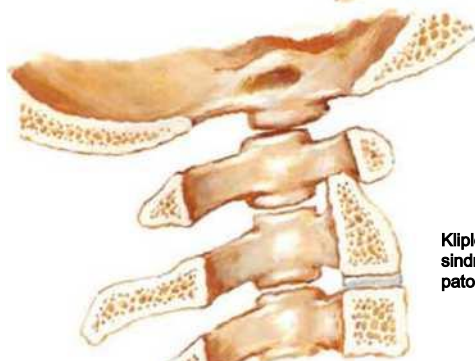Atlant x-simon boylami (lig. cruciforme atlantis) chuqur boylamlarni ko'rsatish uchun olingan, orqadan ko'rinishi

Atlant-aksis bo'g'imi (art. atlantoaxialis mediana), yuqoridan ko'rinishi

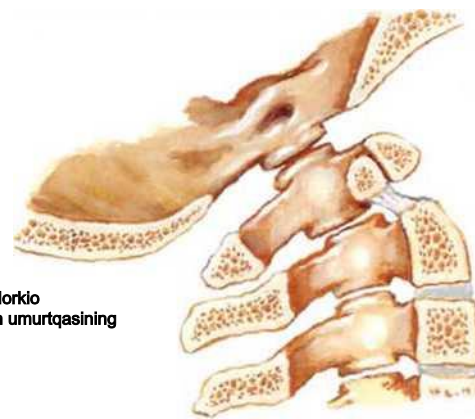
Atlant-ensa bo'g'imi (articulatio atlantooccipitalis)



Ensa s. pastki qismi



Axis tish o'sig'ining gipoplasiyasi

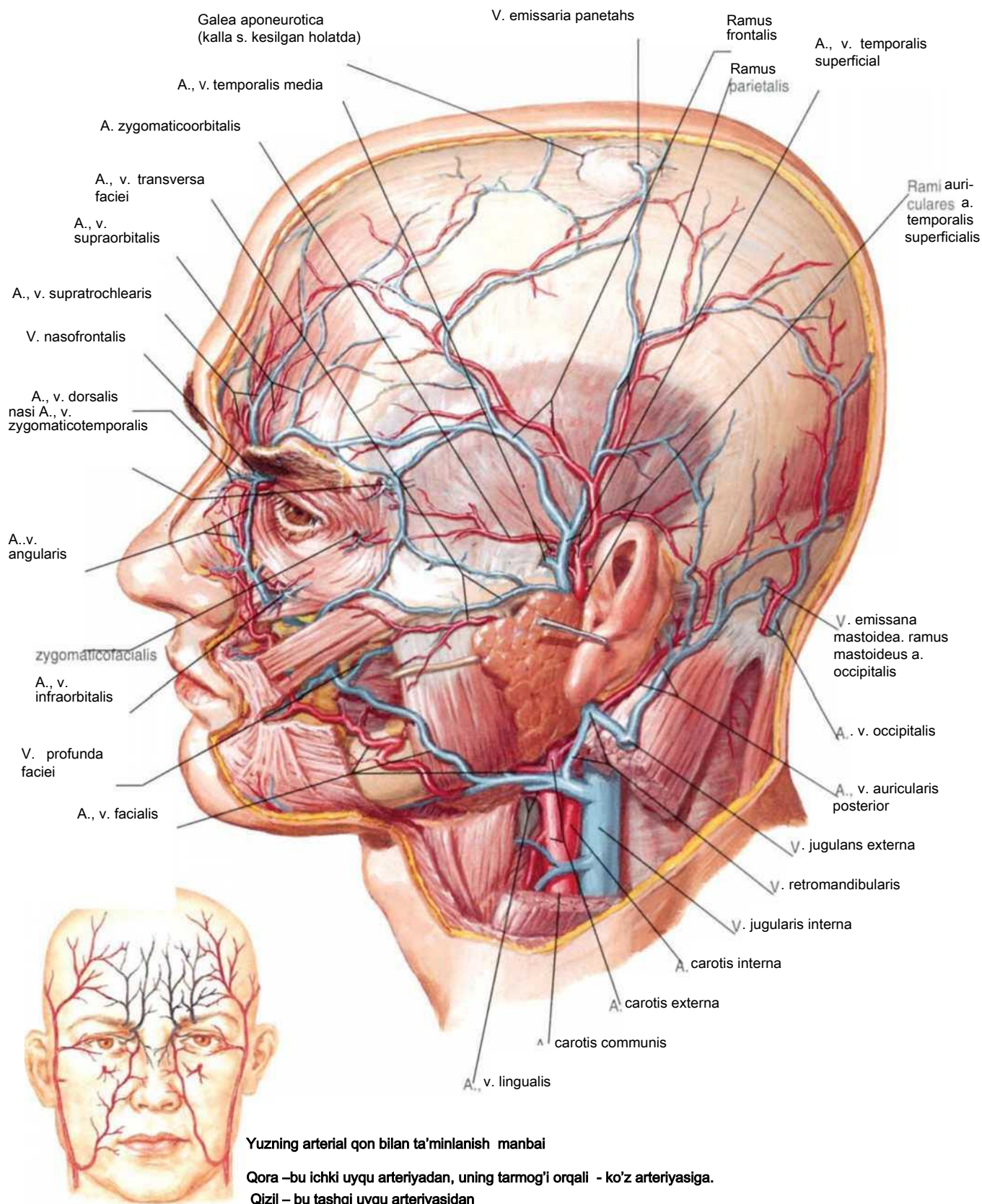


Bunda axisni tish o'sig'i alohida bo'lib boylam orqali birikadi. Boshni orqaga tashlaganda umurtqa kanali torayadi

Klippel-Feyl, Daunva Morkio sindromlarida 2-bo'yin umurtqasining patologiyasi uchraydi

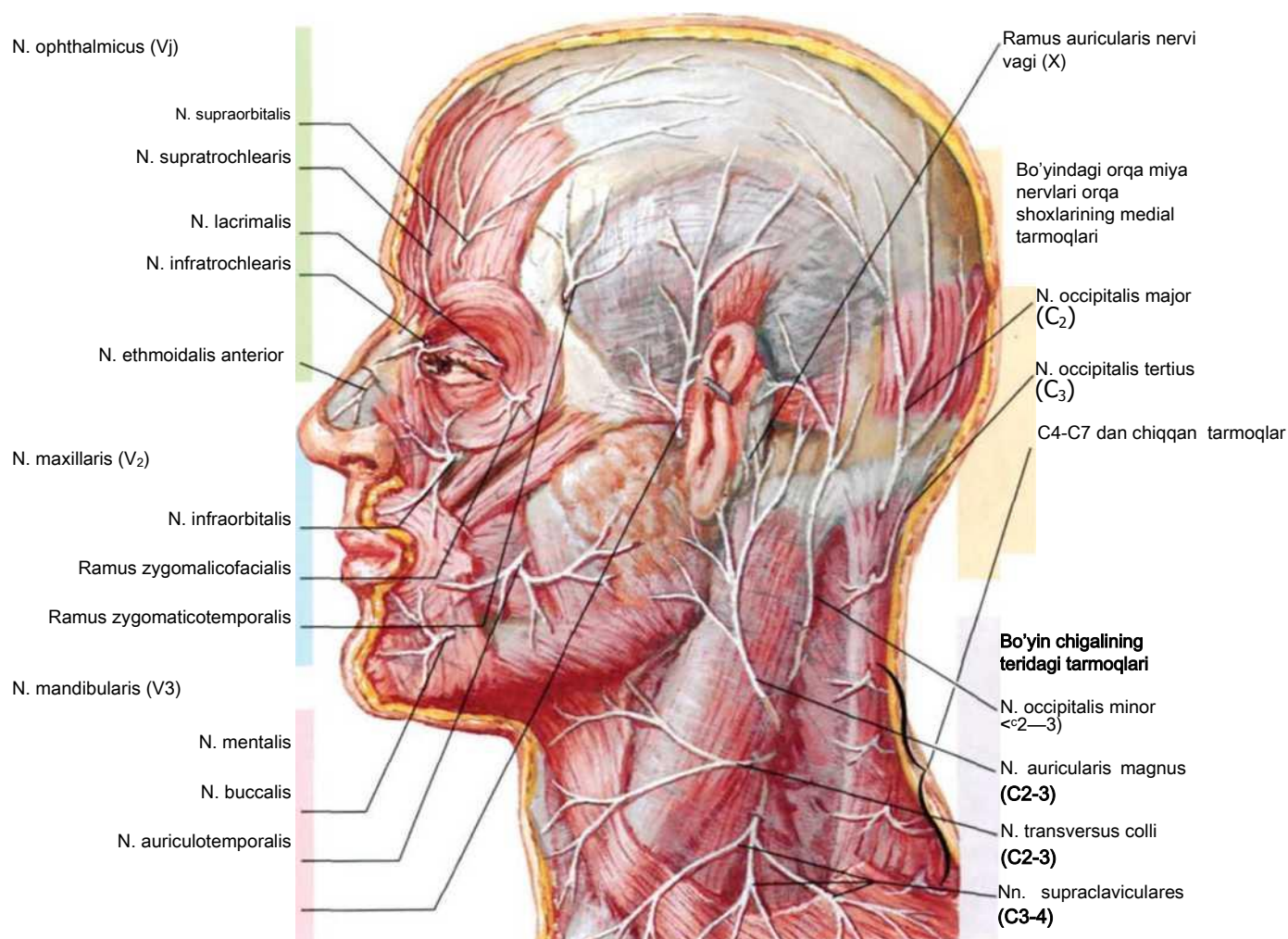
Boshning yuzada joylashgan arteriya va venalari

29. 35. 63. 64. 80. 98-rasmlarga qarang.



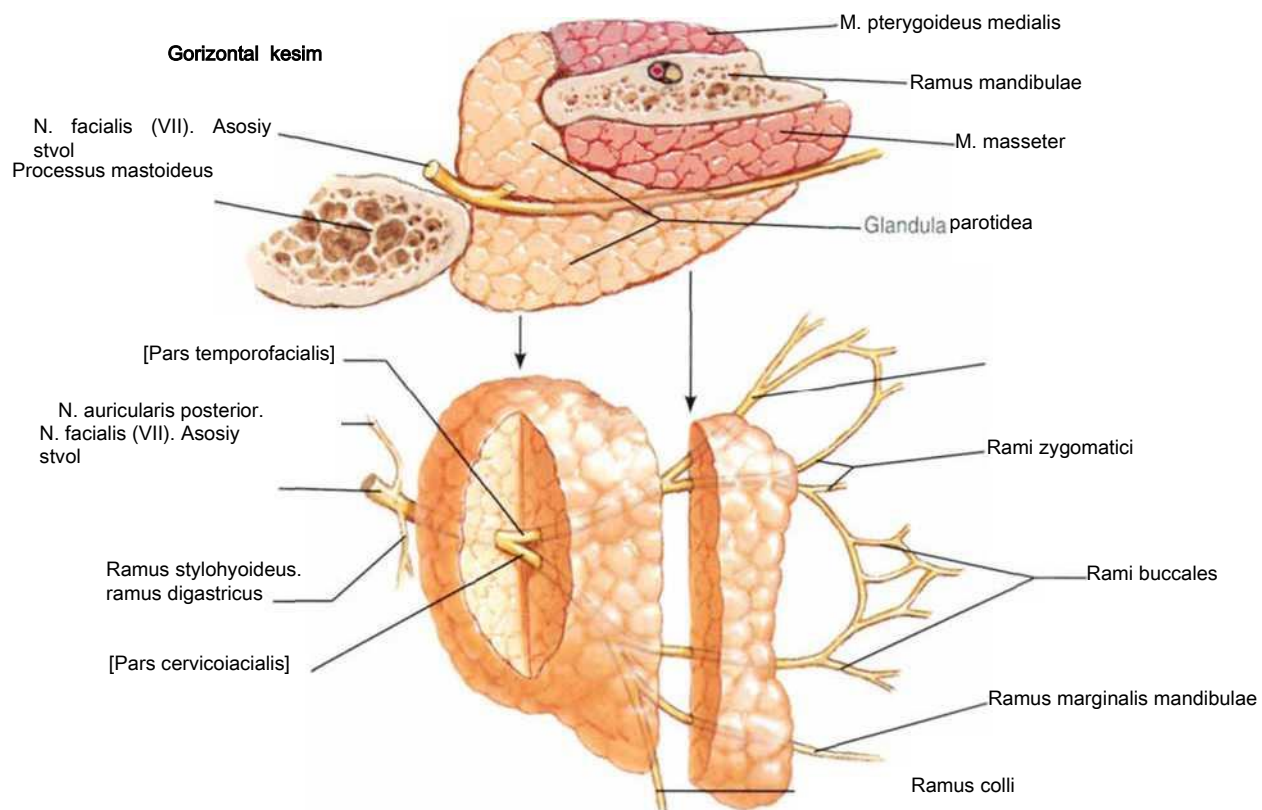
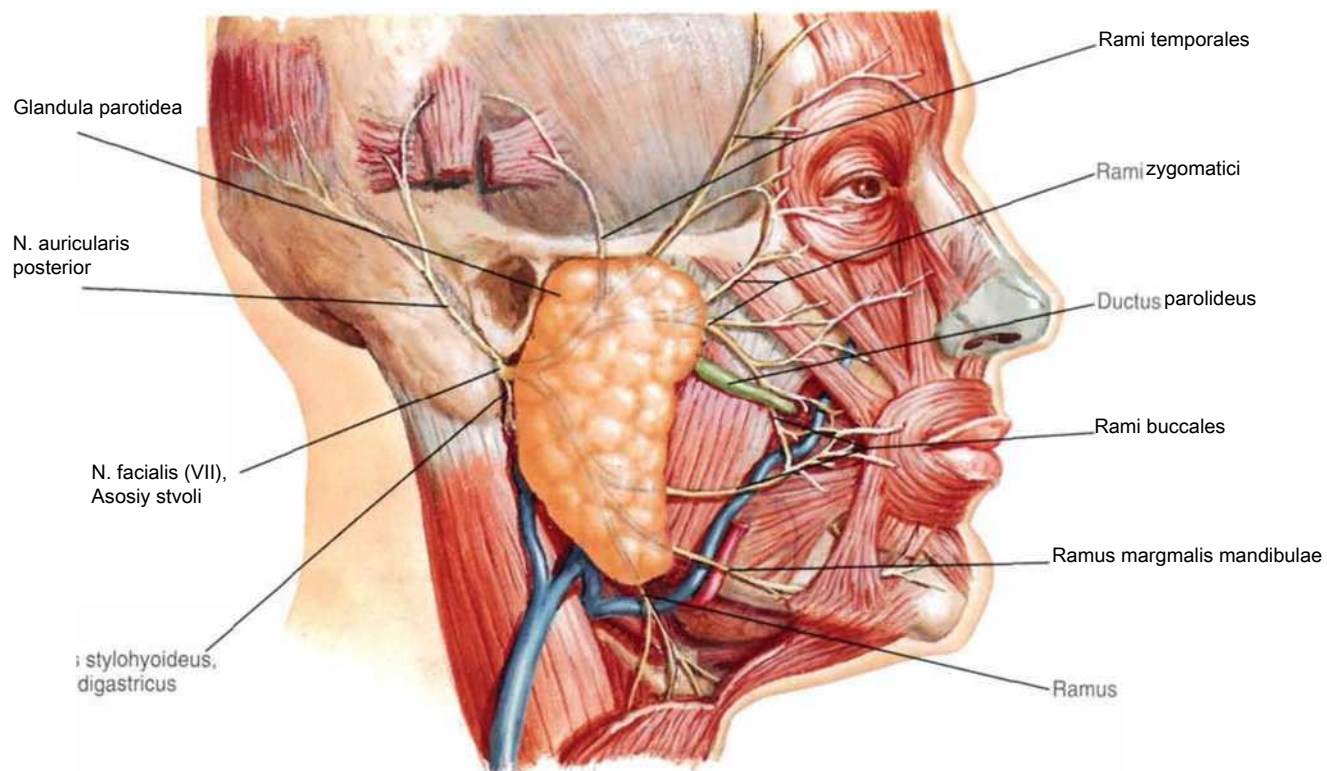
Bosh va bo'yinning teri nervlari

27. 31. 40. 41. 116-rasmlarga qarang.



Yuz nervi (n. facialis) va quloq oldi so'lak bezi

117-rasmga qarang.

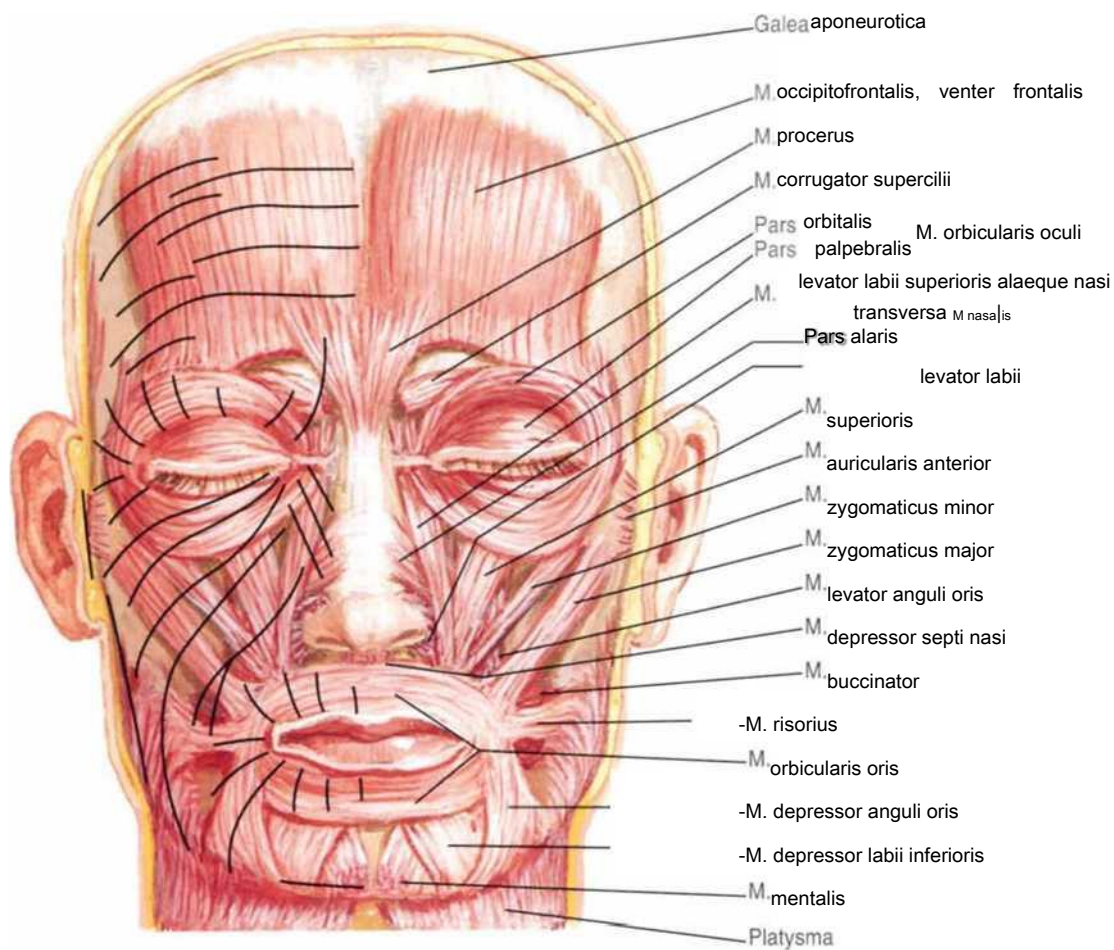


Yuzning tashqi yuzasi

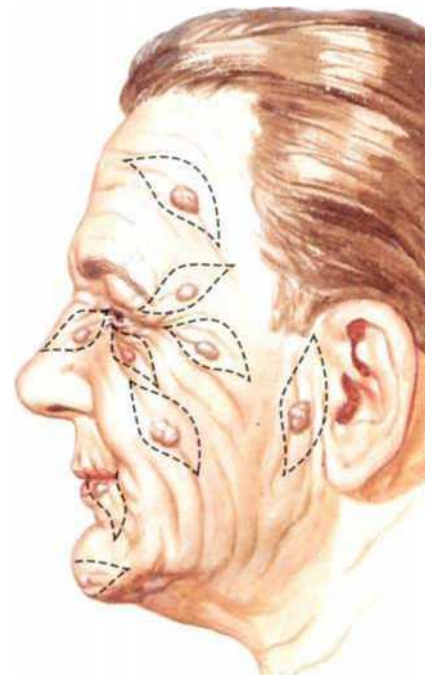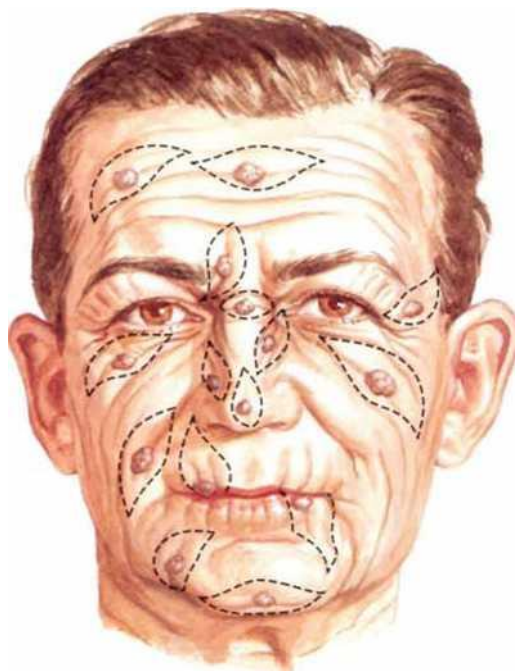
19-rasm

Mimika muskullari (musculi faciei), old tomondan ko'rinishi

48-rasmga qarang



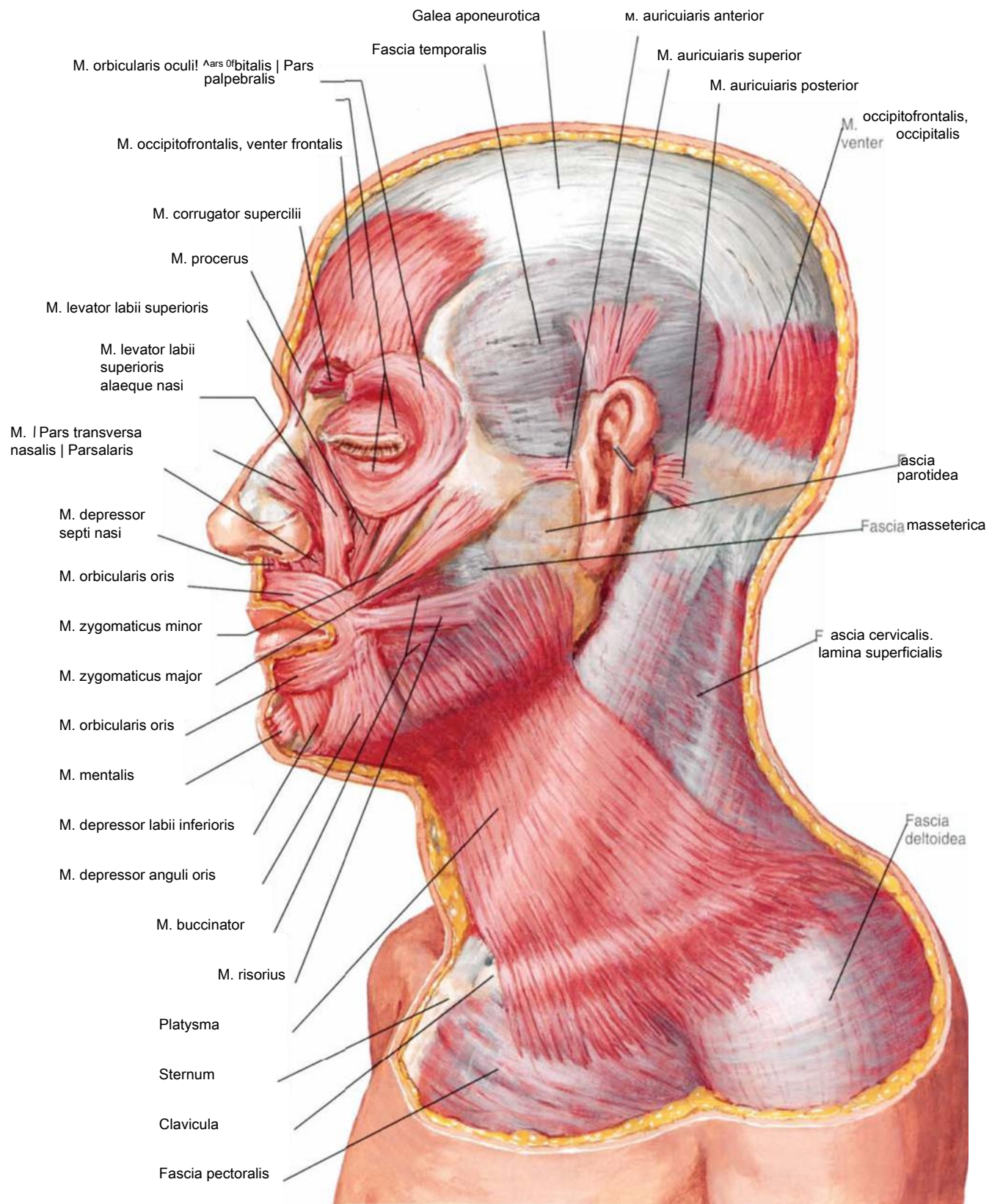
Teri ajinlarining yo'nalishi mimika muskul tolalari yo'nalishiga ko'n dalang. Teri o'smalarini olib tash lash uchun qo'llaniladigan ellips simon kesmalar ajinlar yo'nalishi ga to'g'ri keladi.



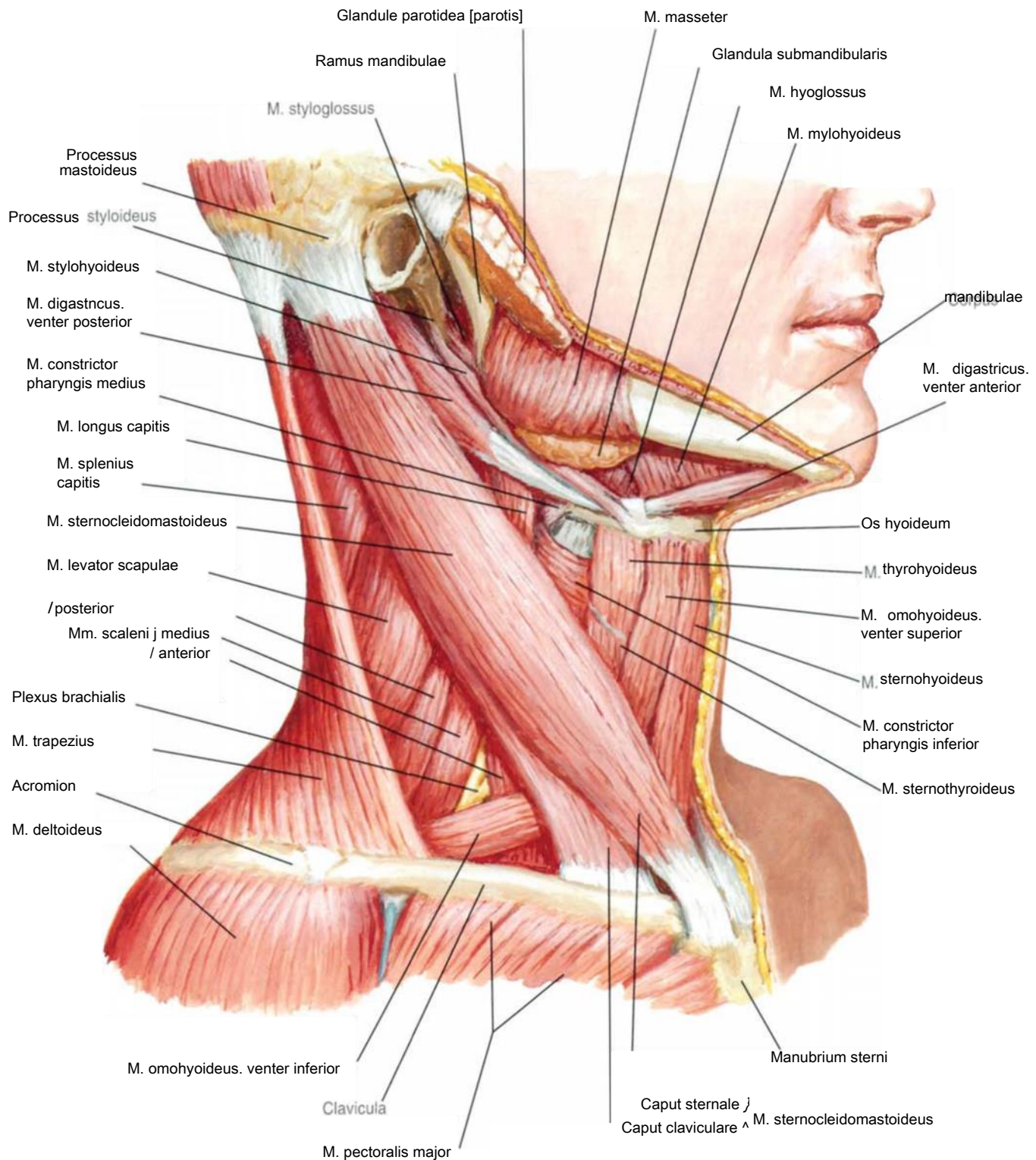
20-rasm

BOSH VA BO'YIN

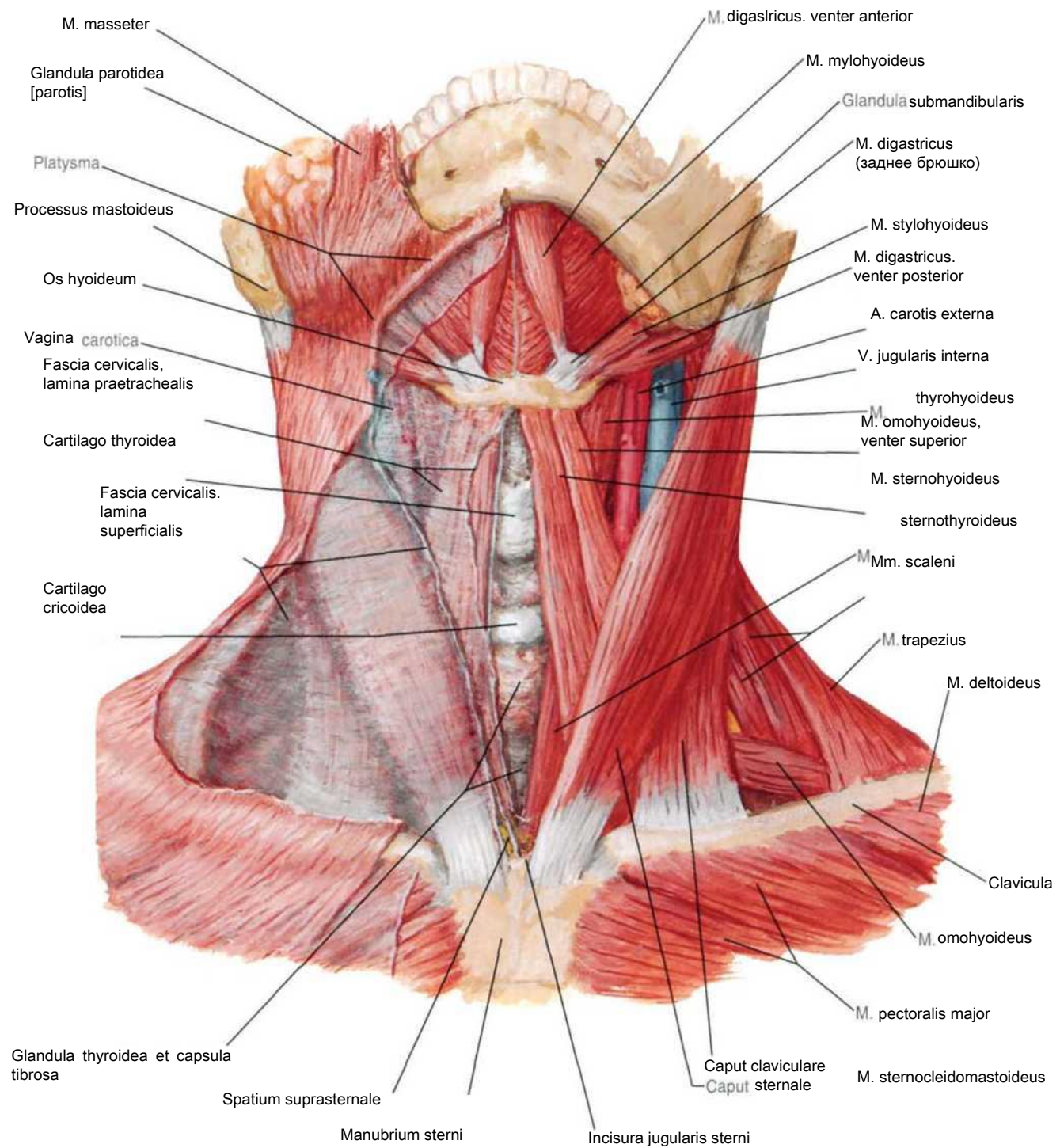
Mimika muskullari (musculi faciei), yon tomondan ko'rinishi



Bo'yin muskullari (musculi colli), yon tomondan ko'rinishi

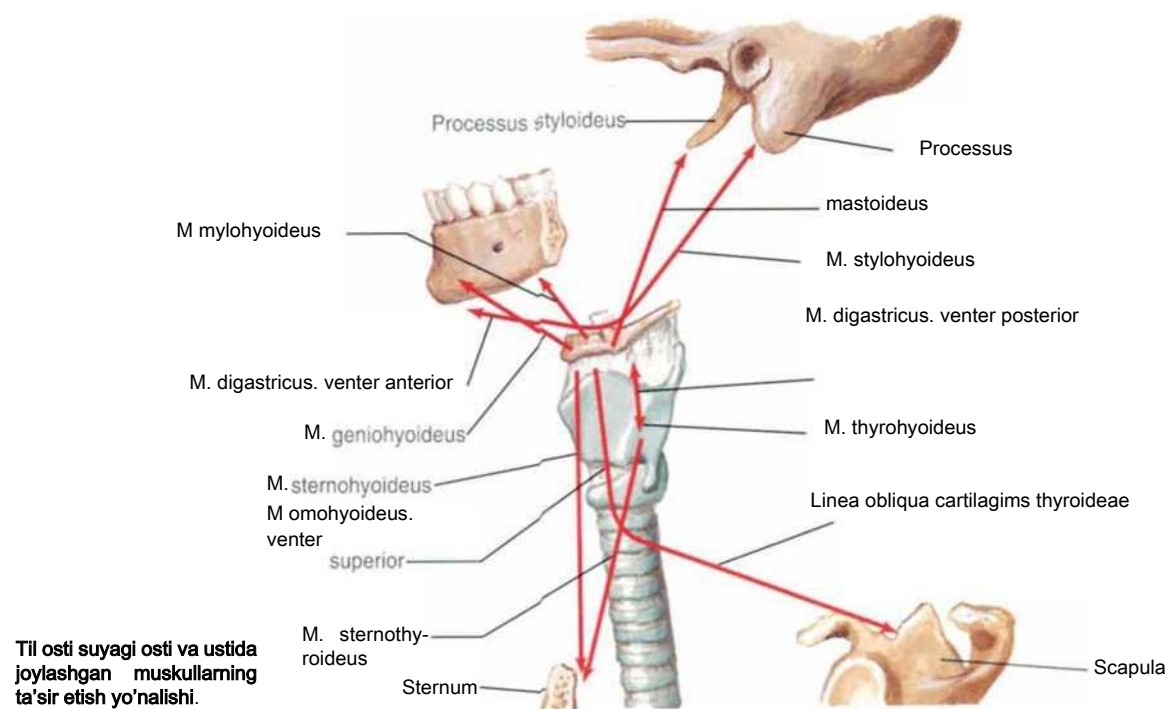
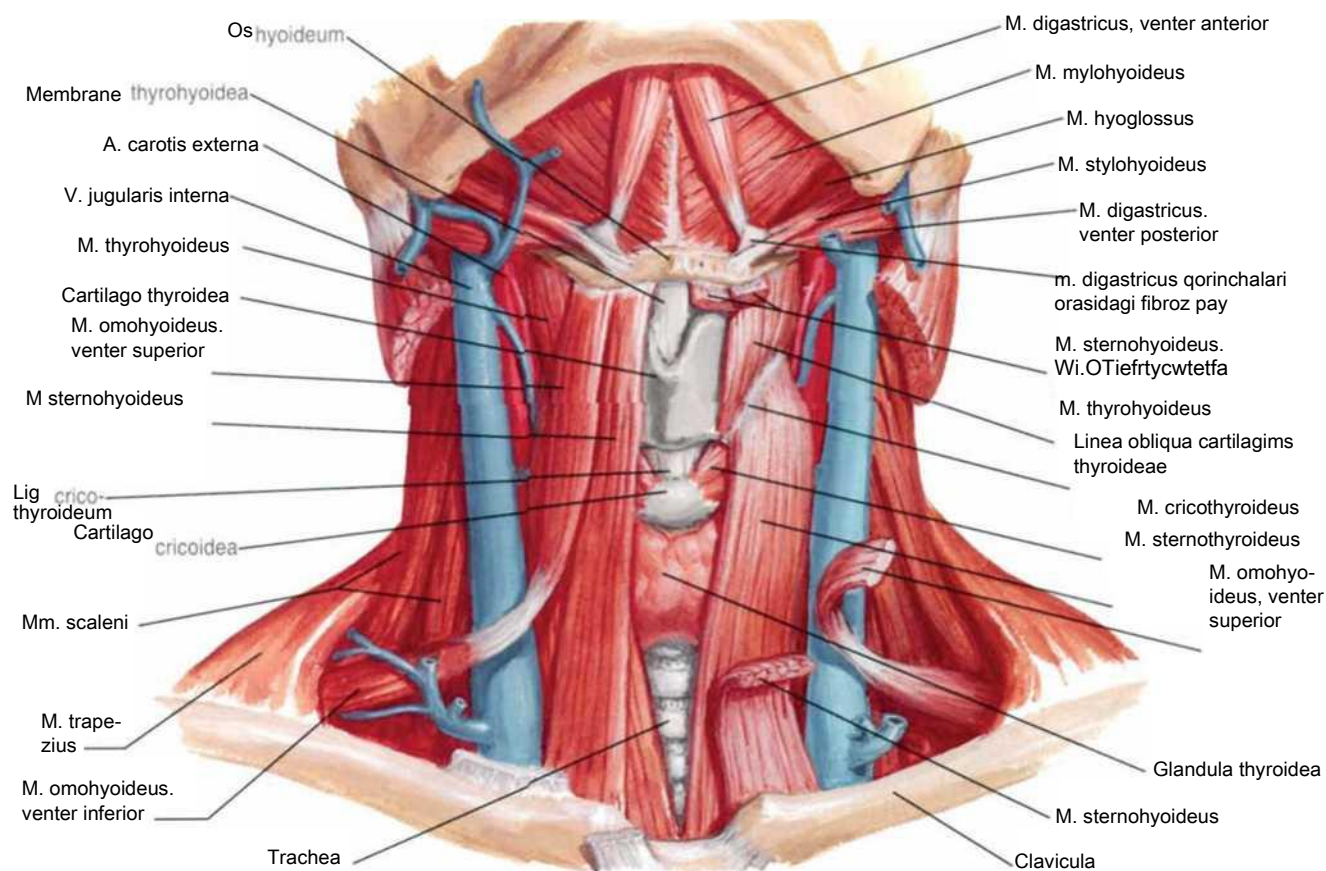


Bo'yin muskullari (musculi colli), old tomondan ko'rinishi



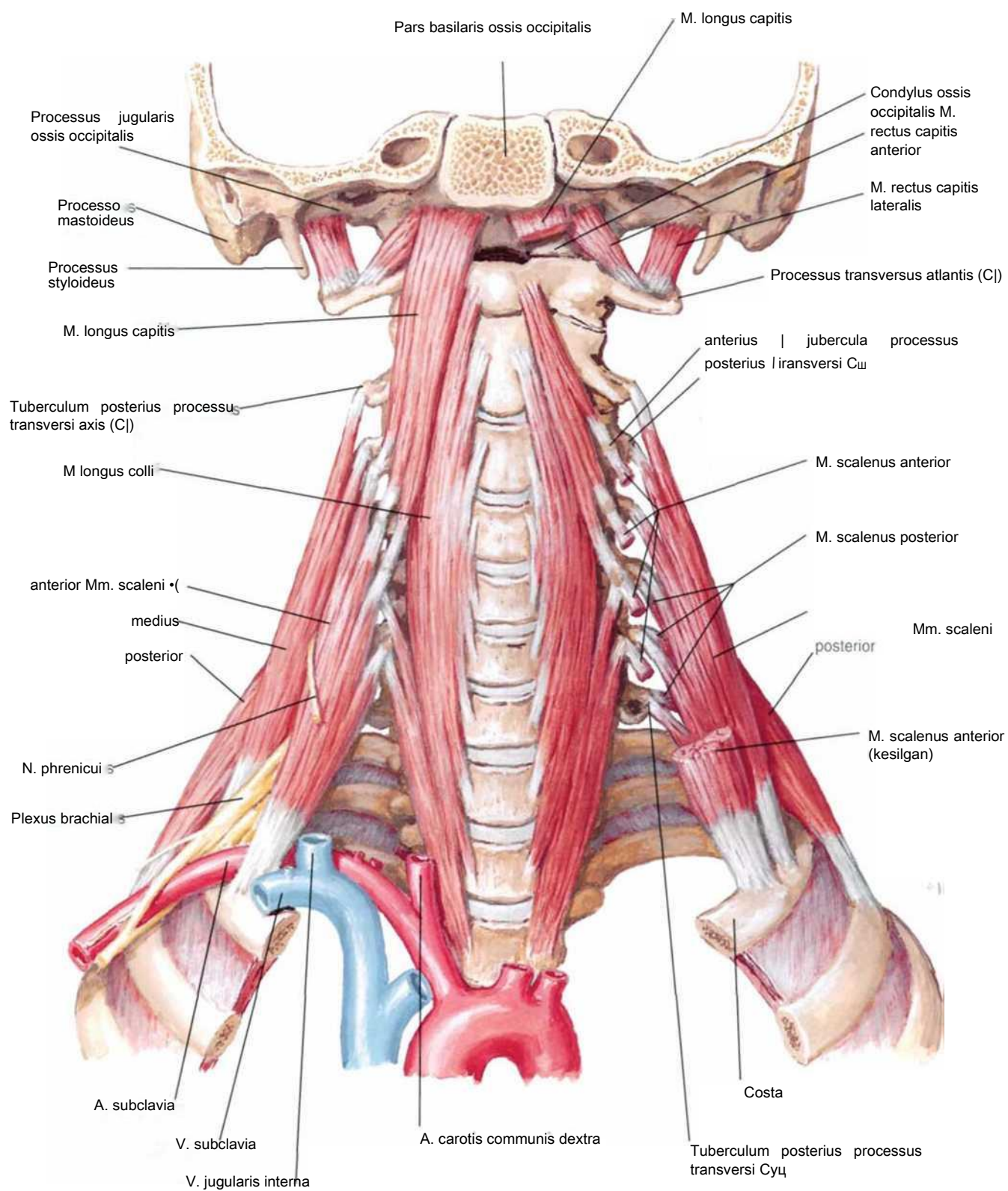
Til osti suyagi osti va ustki qismida joylashgan muskullar

47-rasmga qarang.



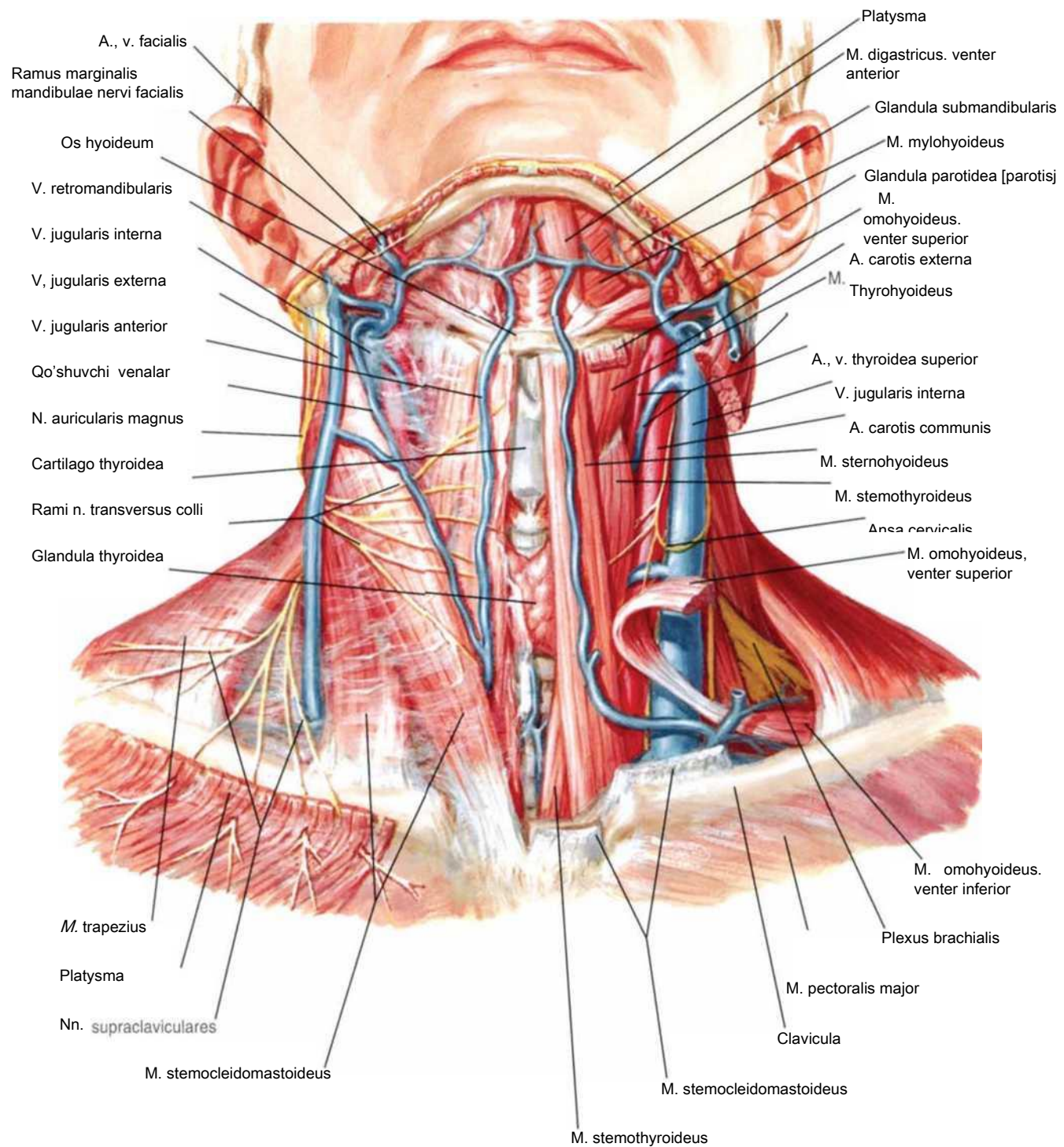
Til osti suyagi osti va ustida joylashgan muskullarning ta'sir etish yo'nalishi.

Umurtqa oldi va narvonsimon muskullar



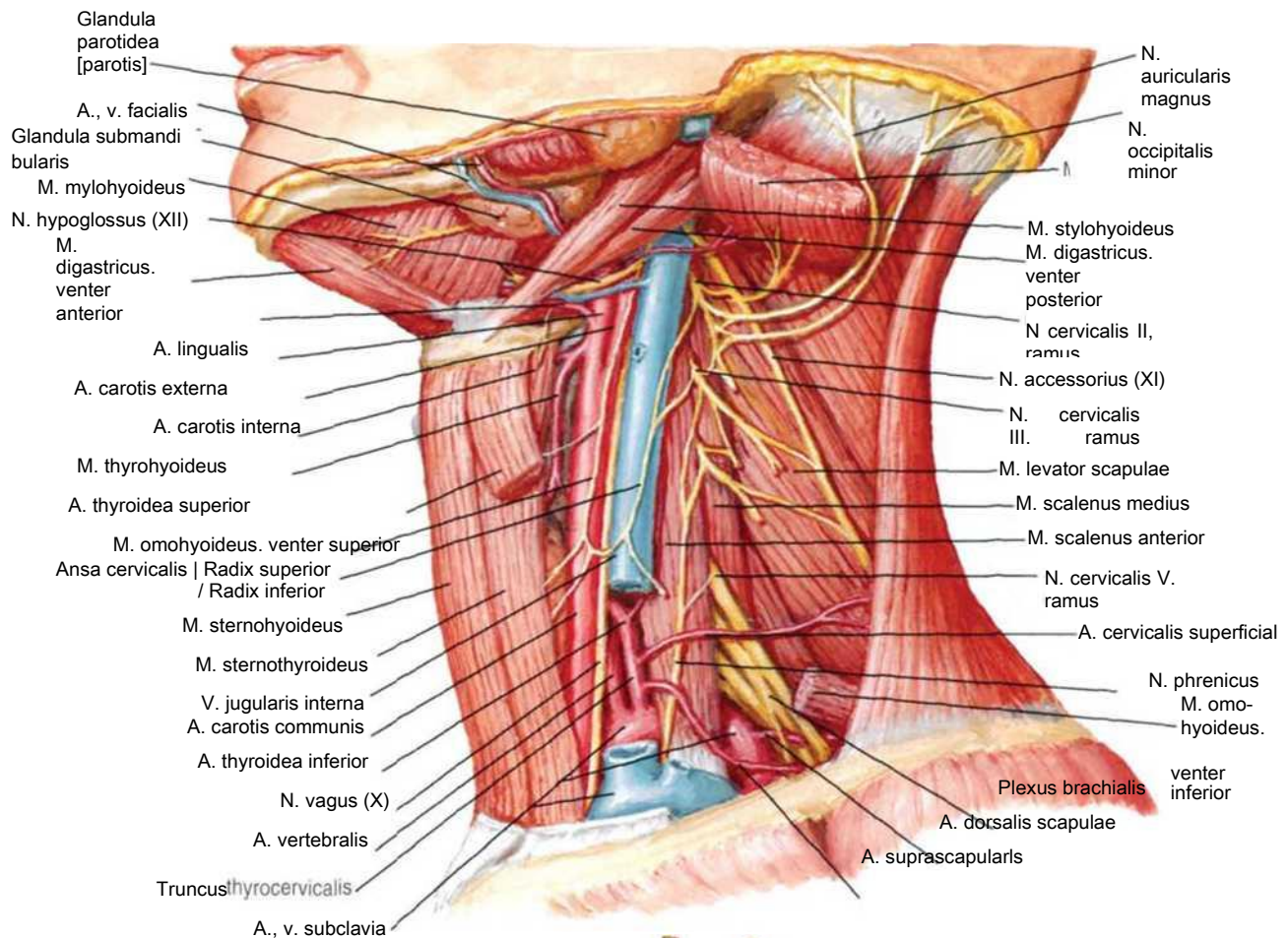
Bo'yinning teri nervlari va yuza joylashgan venalari

64-rasmda bo'yin chuqur venalari ko'rsatilgan



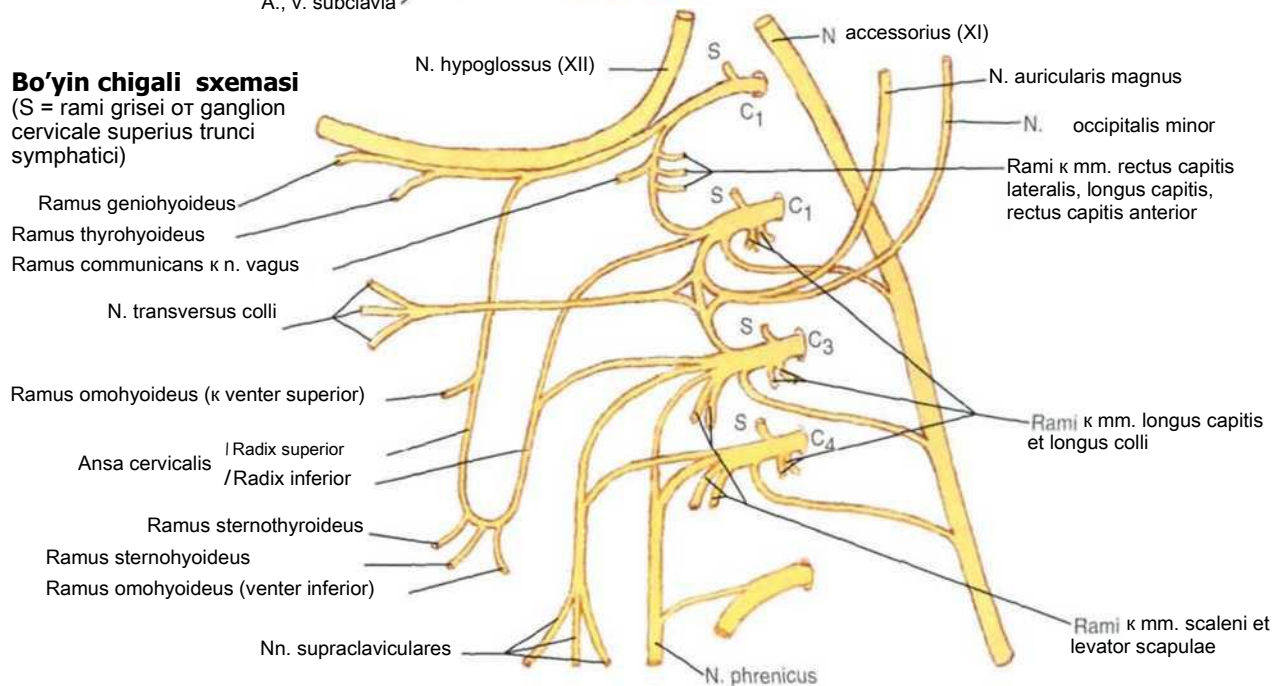
Bo'yin chigali

121-123. 182-rasmga qarang



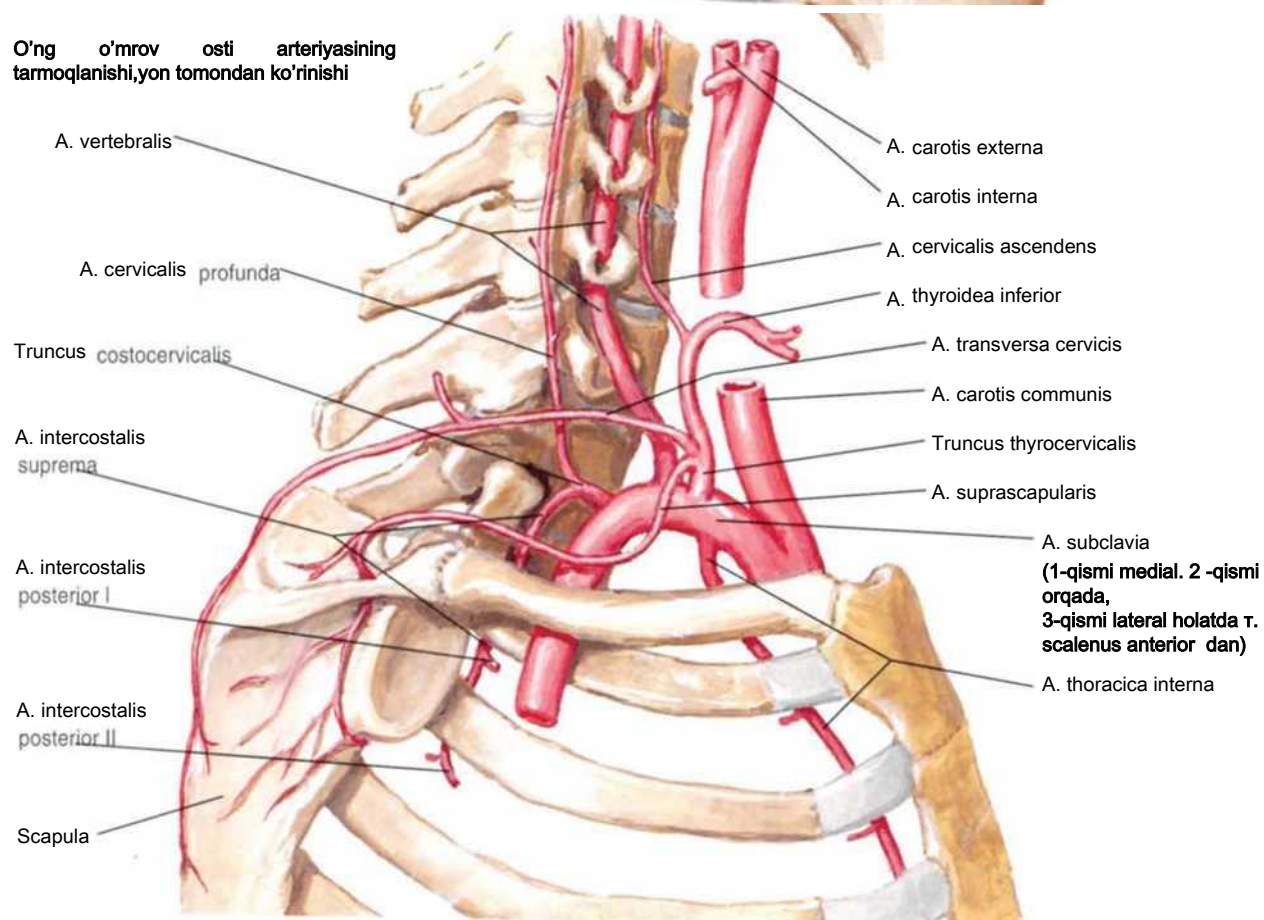
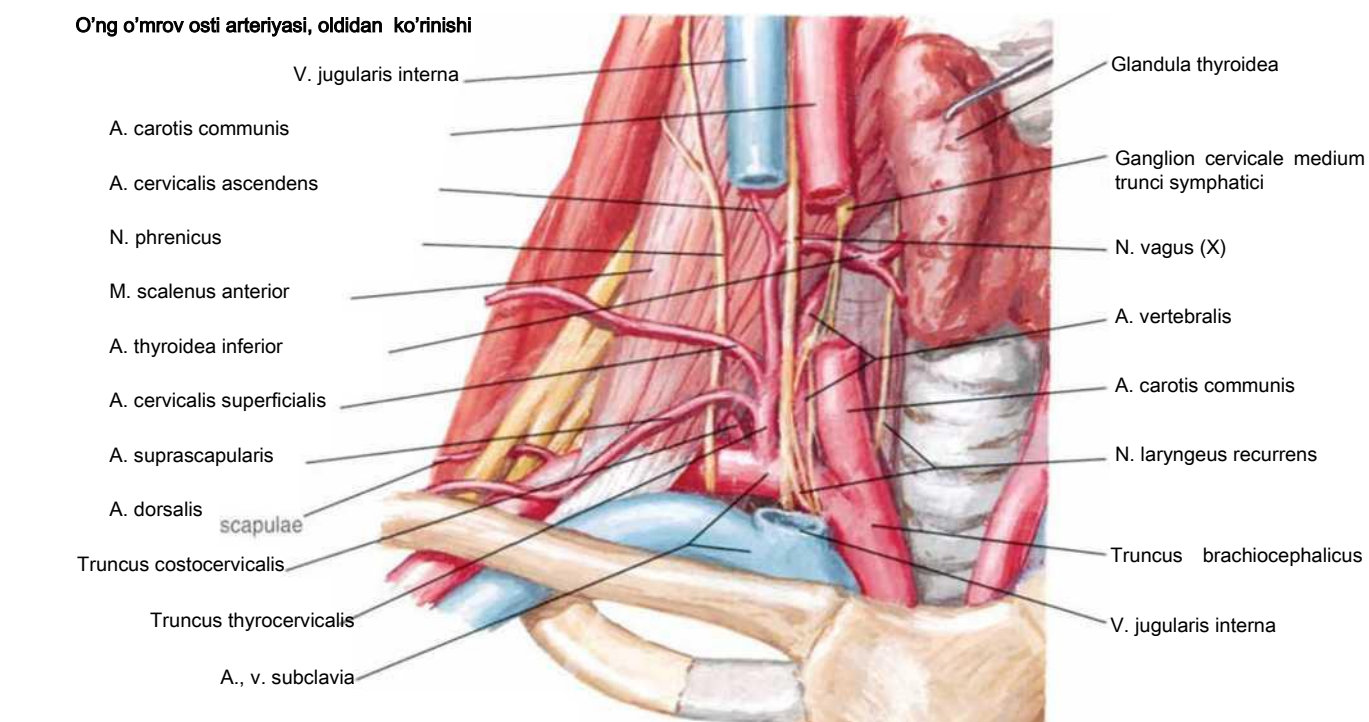
Bo'yin chigali sxemasi

(S = rami grisei ot ganglion cervicale superius trunci sympathici)



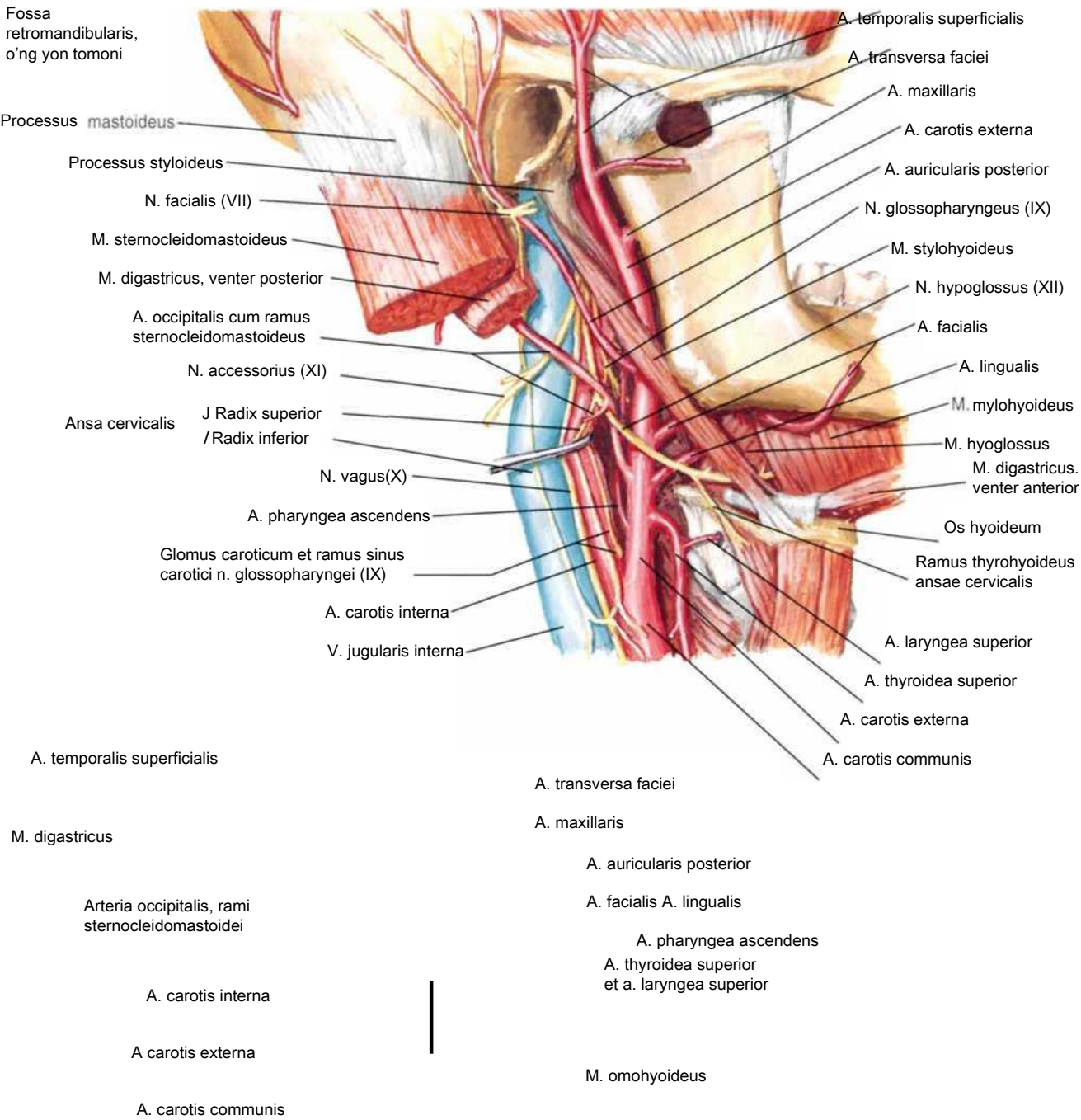
O'mrov osti arteriyasi (a. subclavia)

398-rasmga qarang.



Tashqi uyqu arteriyasi (a. carotis externa)

130. 131-rasmlarga qarang.

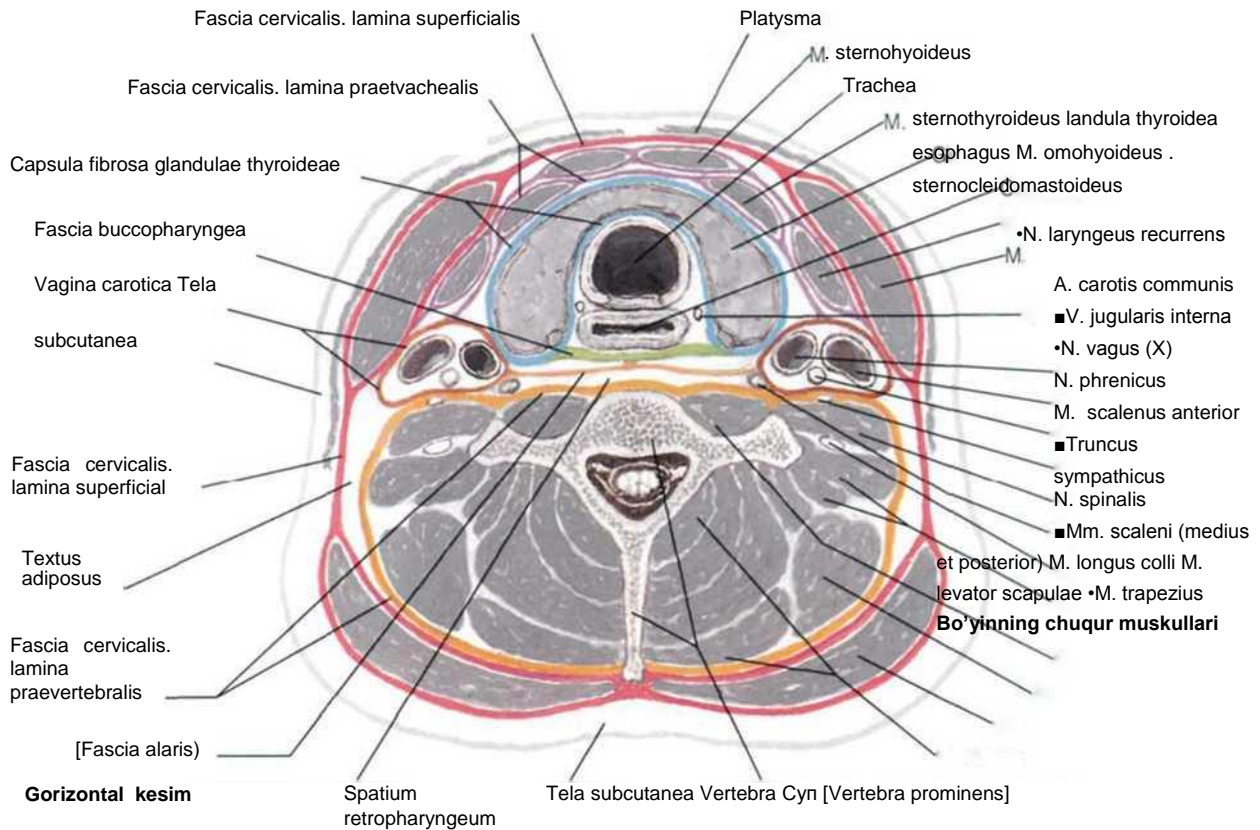


Tashqi uyqu arteriyasi tarmoqlanish sxemasi

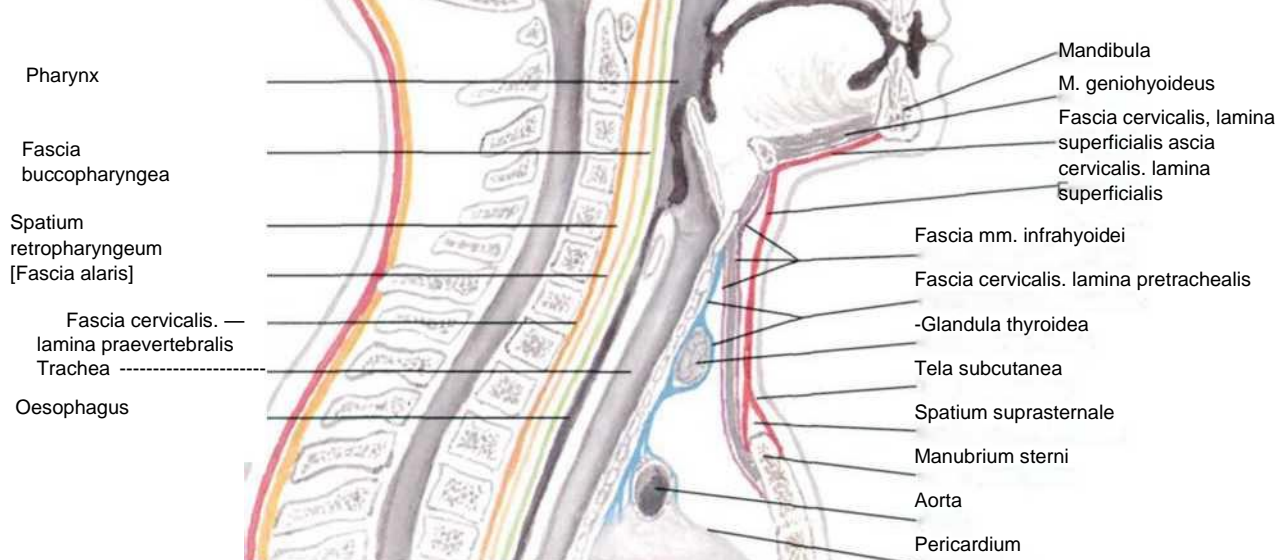
Truncus thyrocervicalis

Bo'yin fassiyalari

63-65-rasmlarda qon tomir nerv tutami ko'rsatilgan.

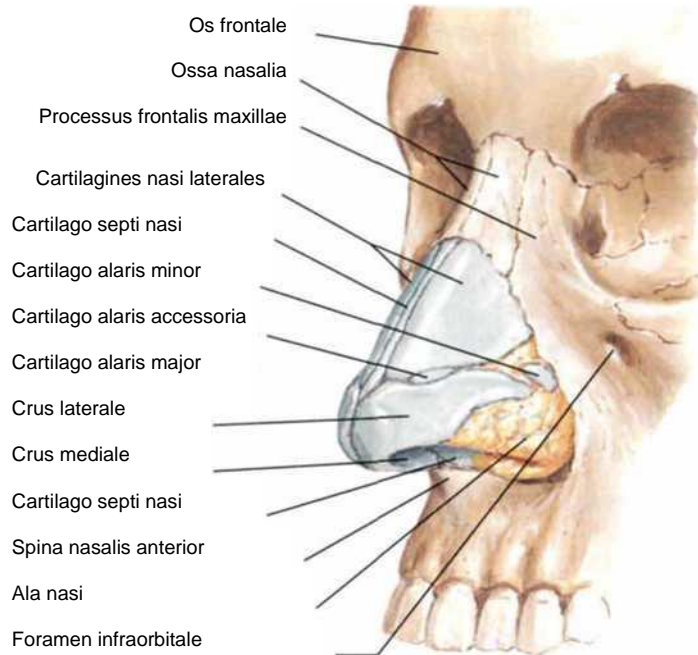


Sagittal kesim

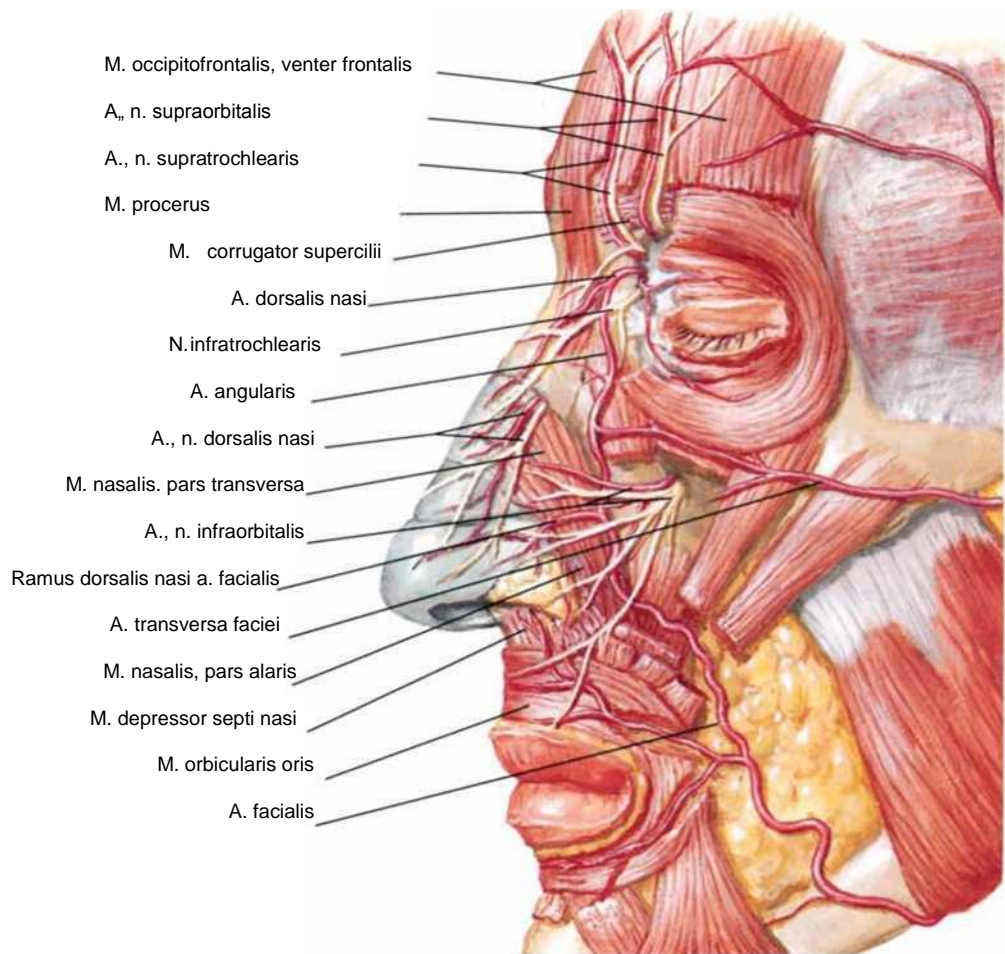
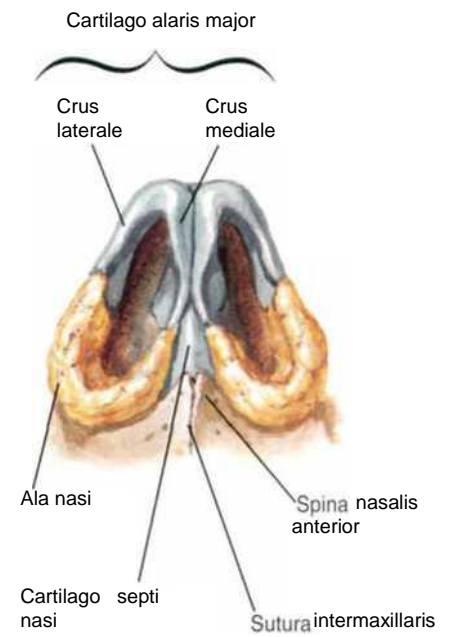


Tashqi burun (nasus externus)

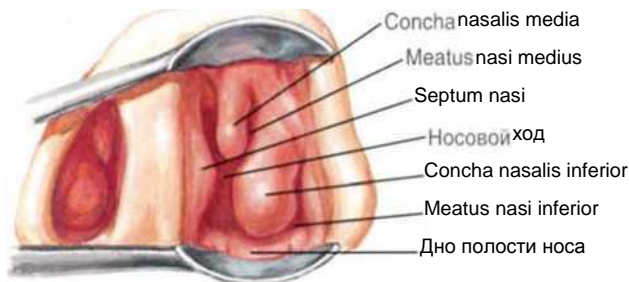
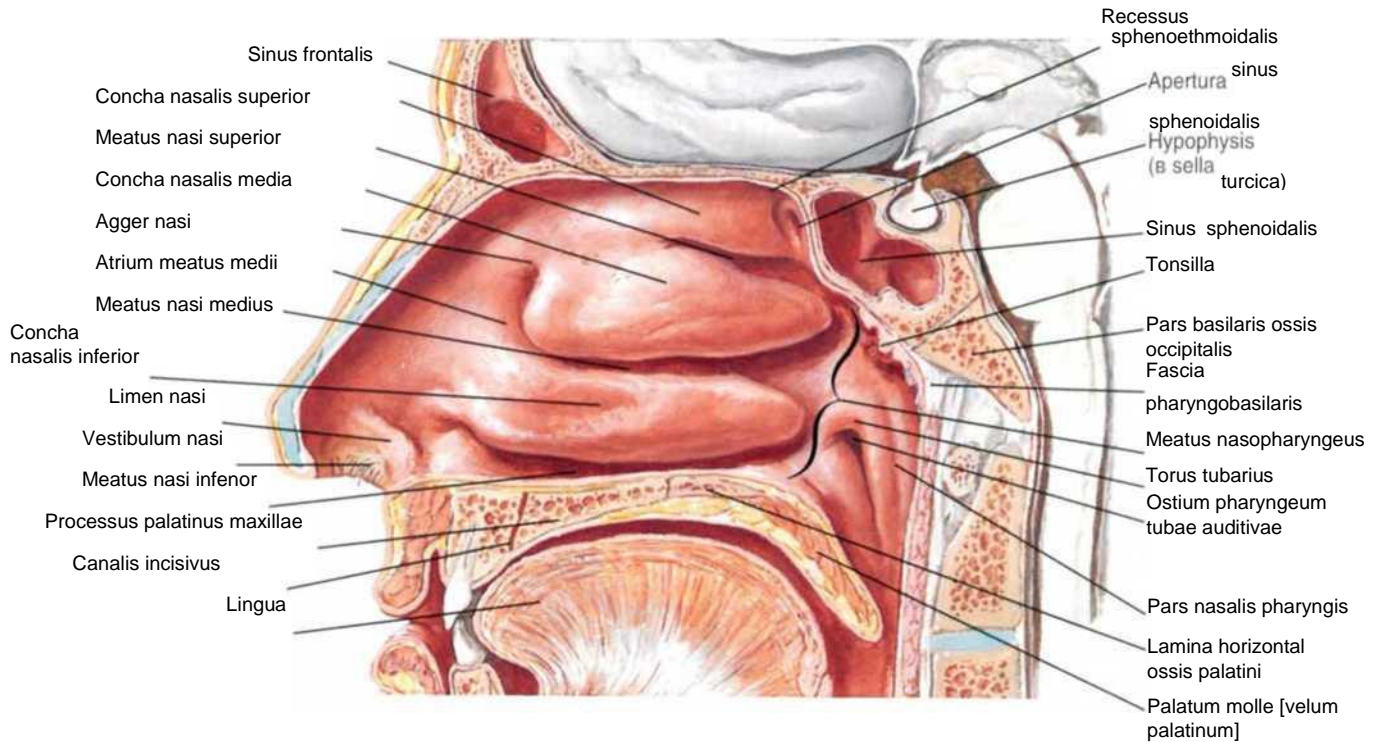
Oldidan va yon tomonidan



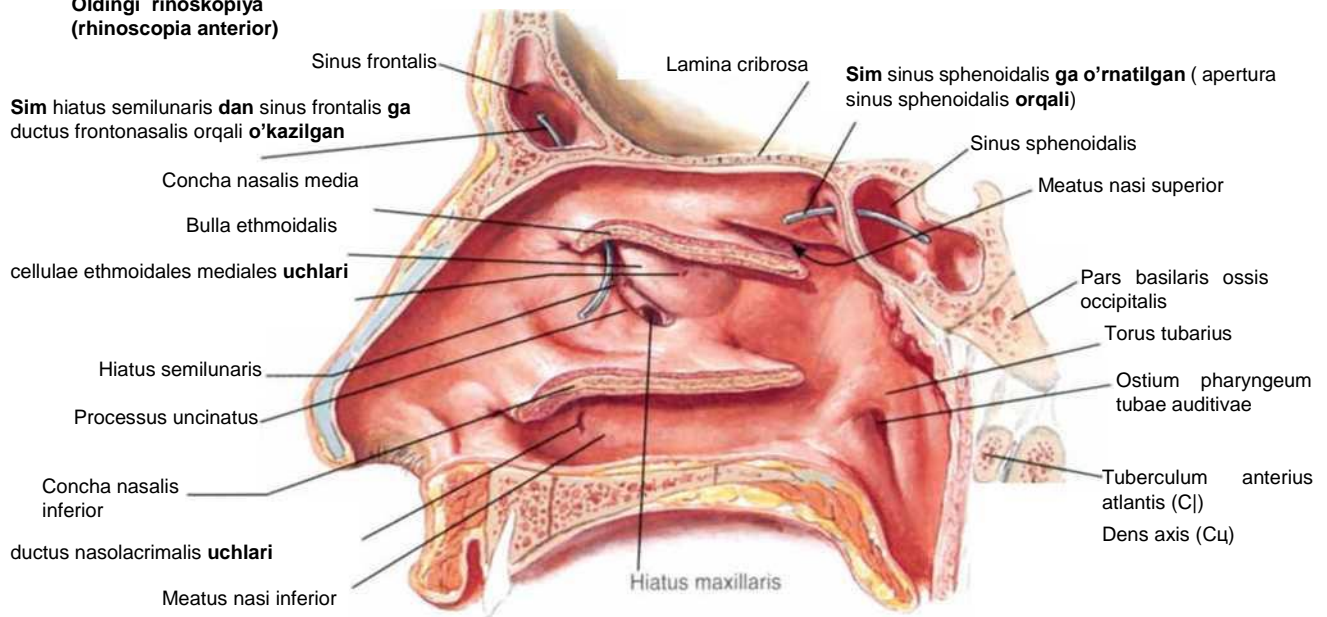
Pastdan ko'rinishi



Burun bo'shlig'ining lateral devori (cavitas [cavum] nasi)

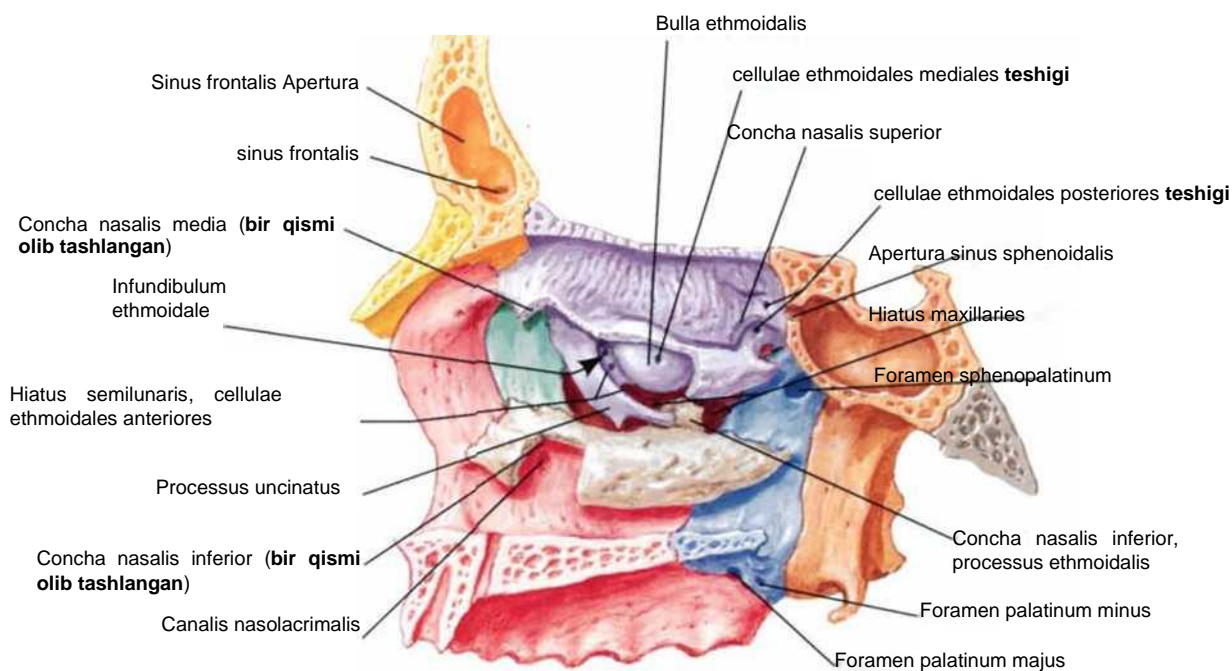
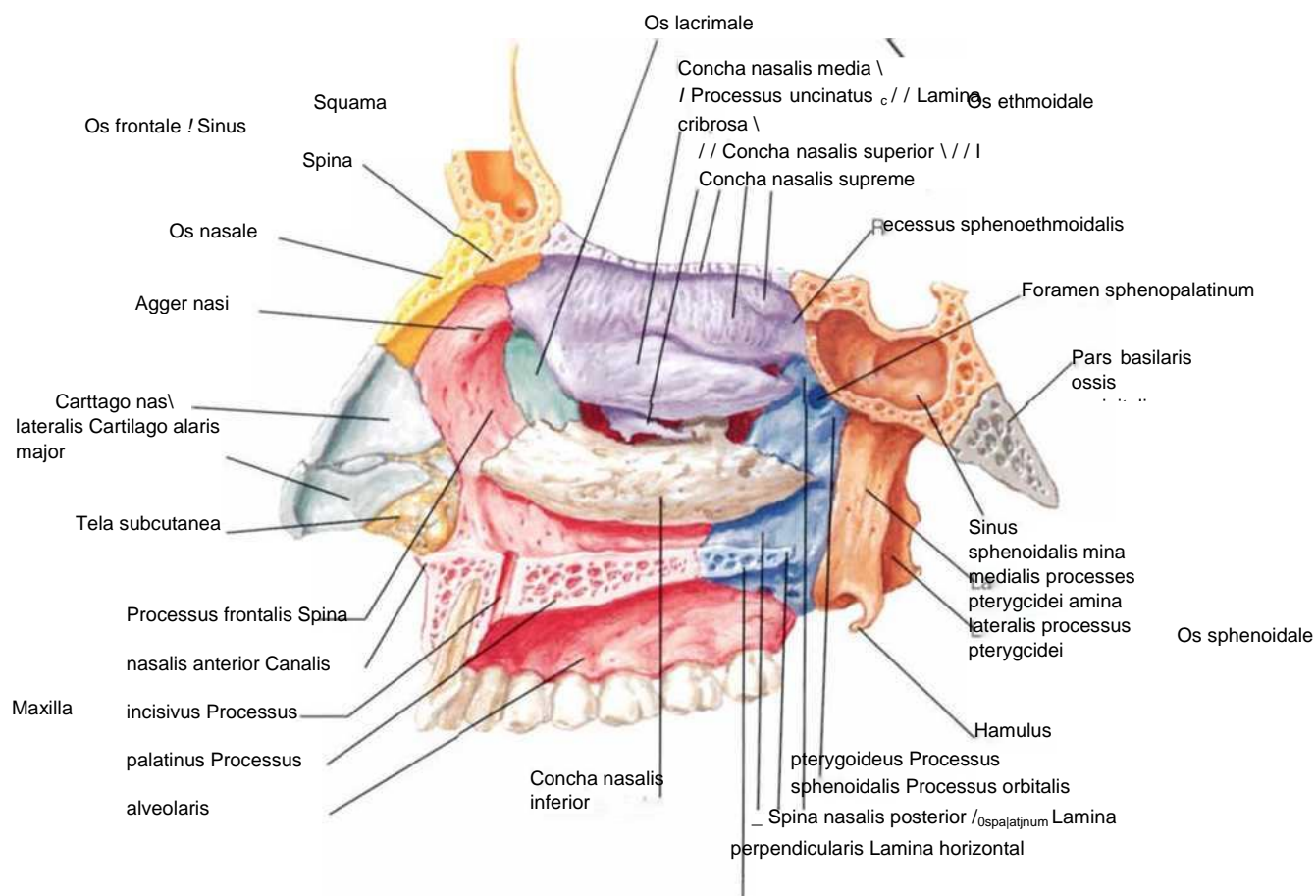


Oldingi rinokopiya (rhinoscopia anterior)

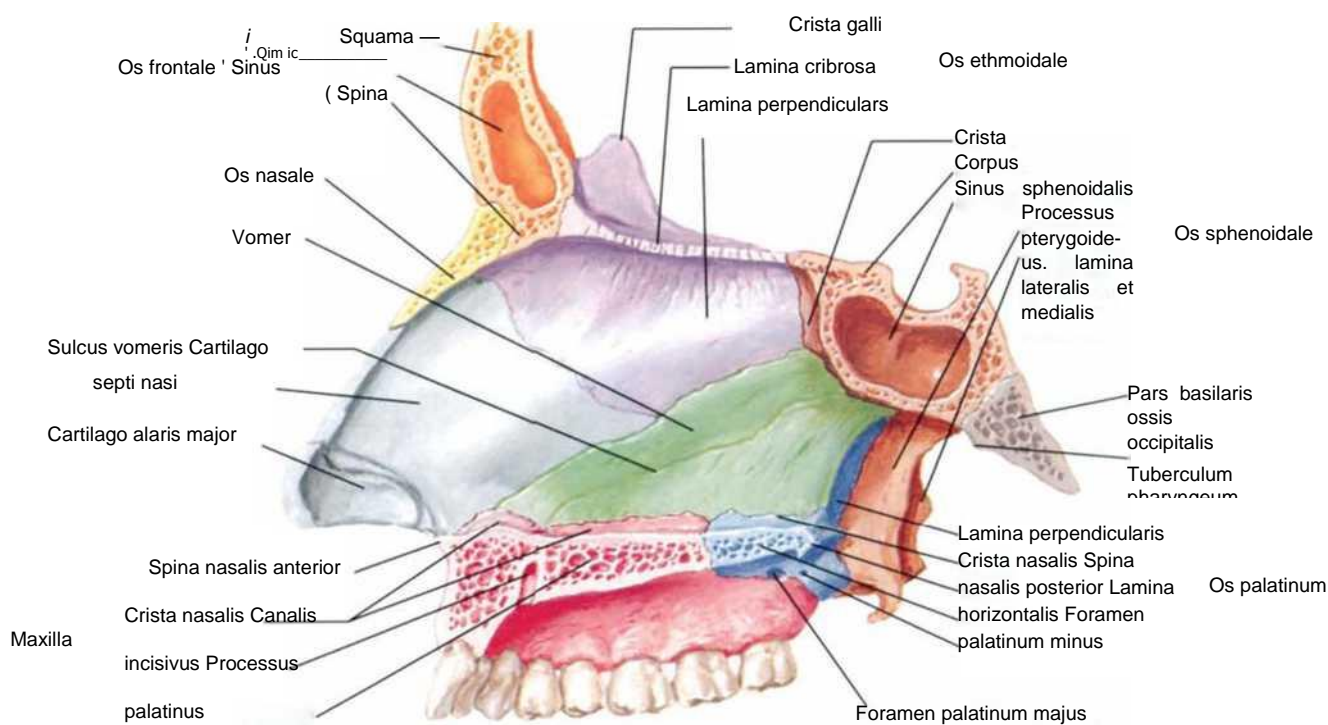
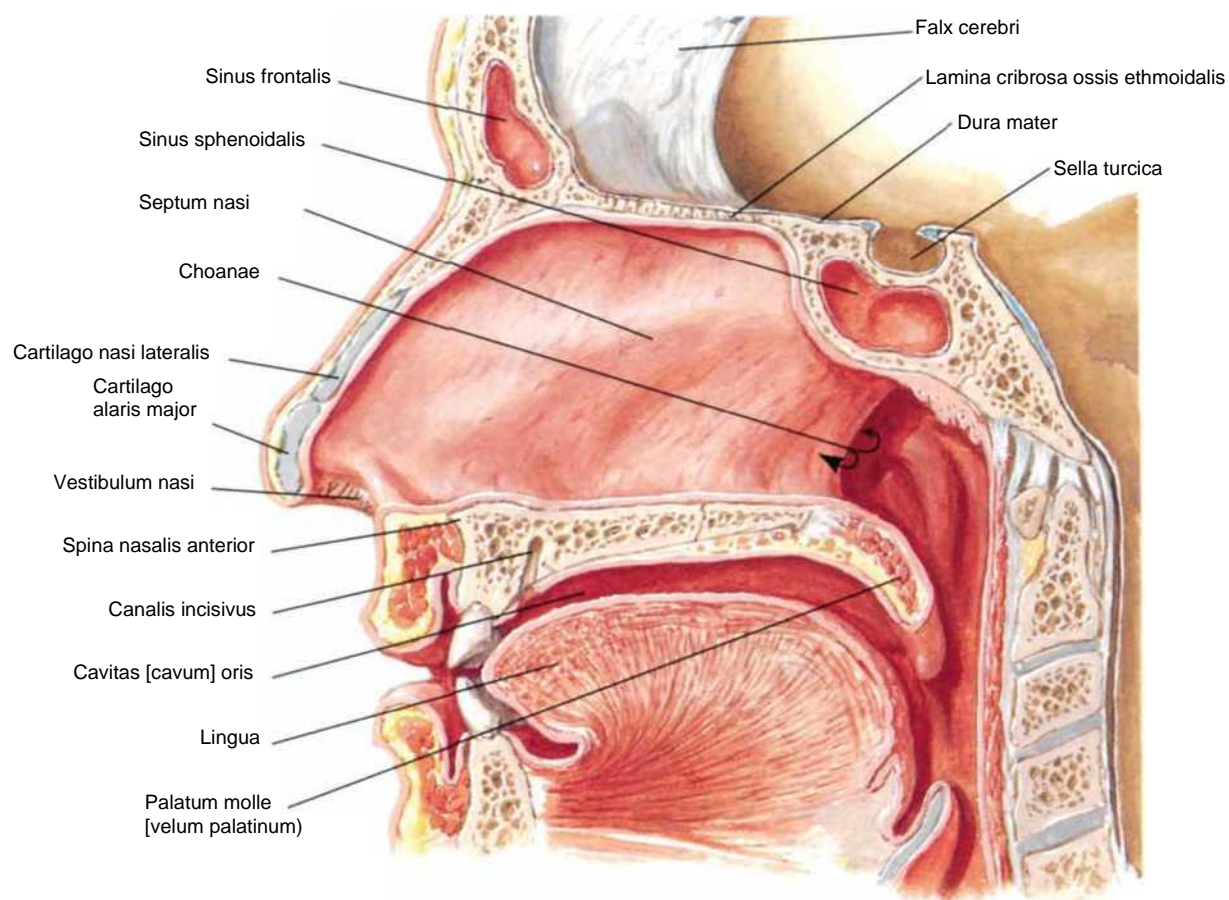


Burun bo'shlig'ining lateral devoir (davomi)

3-rasmga qarang.

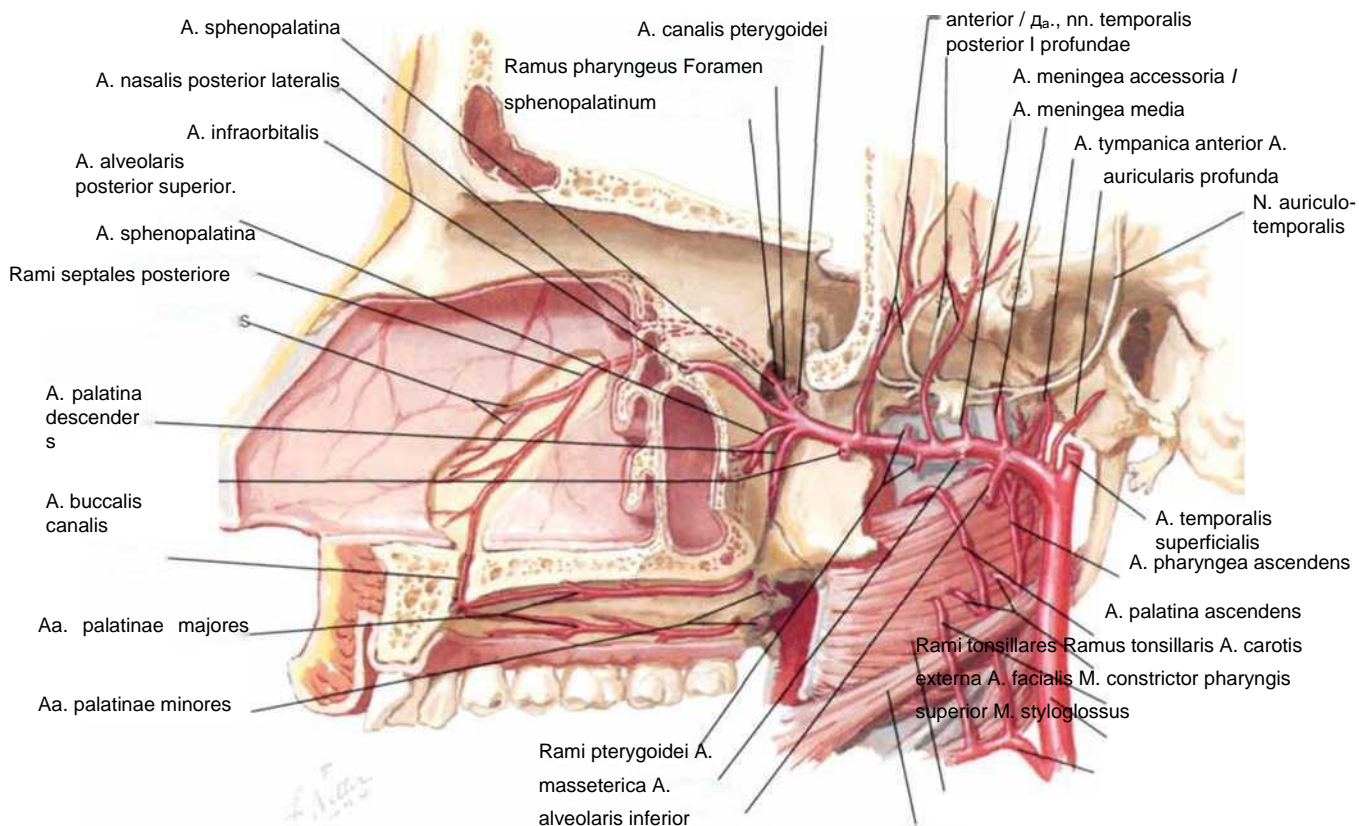
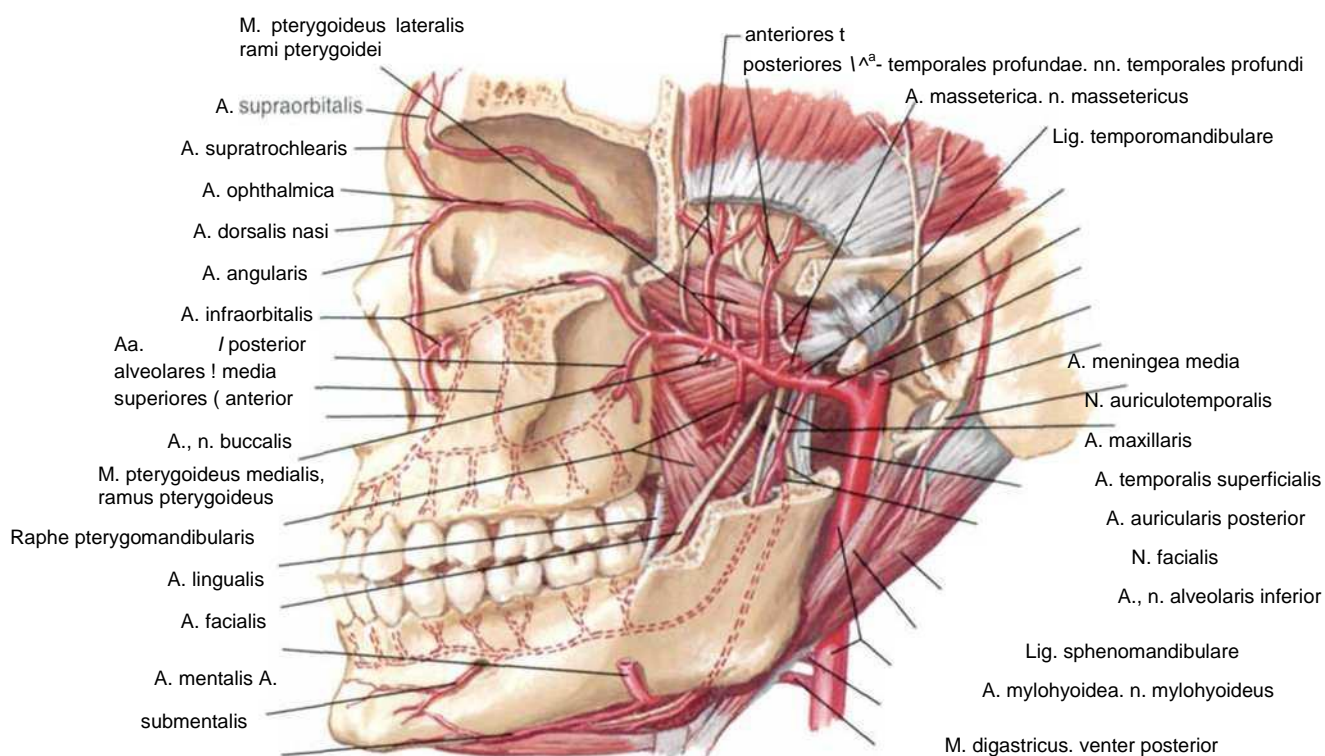


Burun bo'shlig'ining medial devoir (septum nasi)

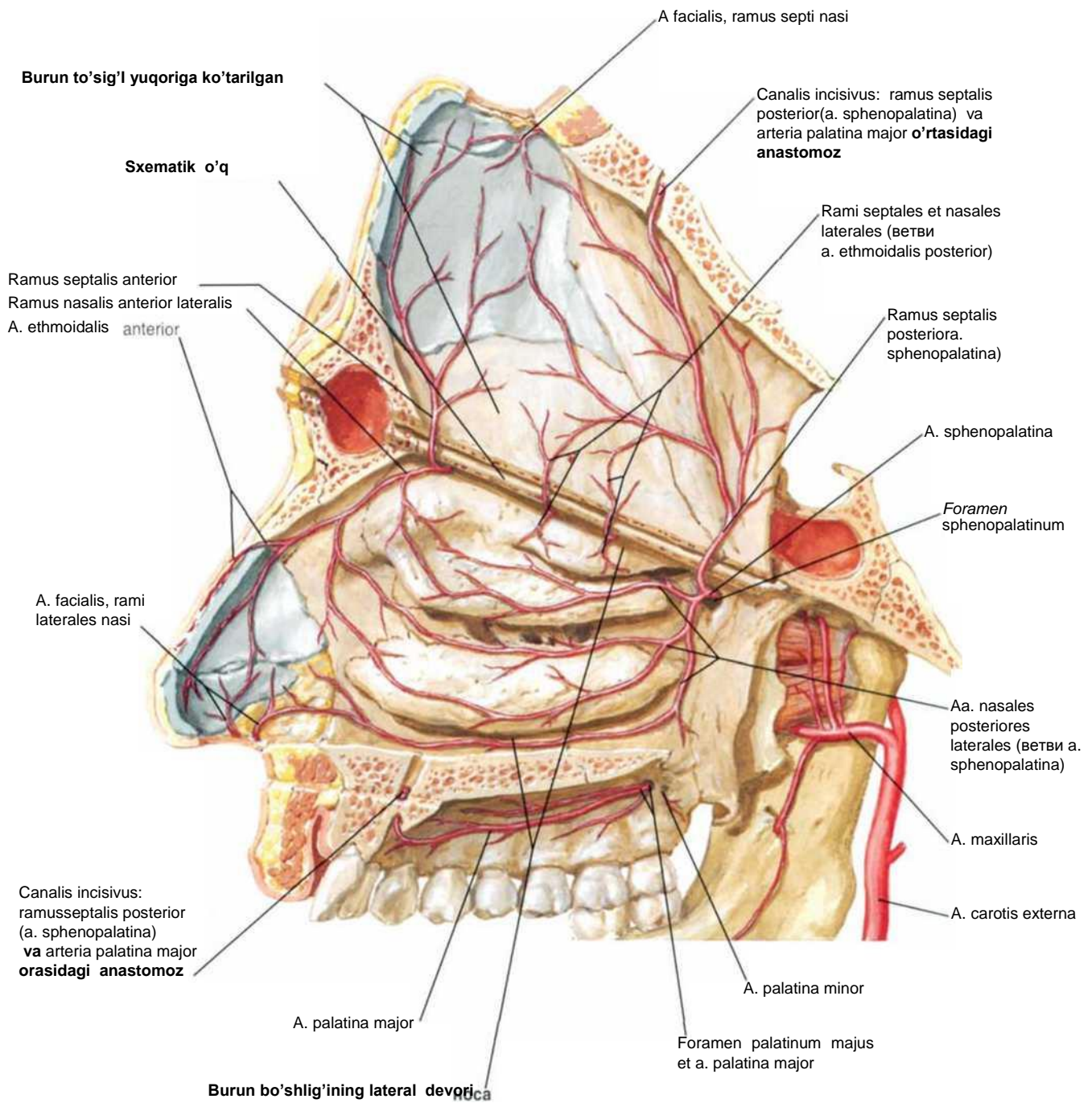


Yuqori jag' arteriyasi (a. maxillaris)

29-rasm

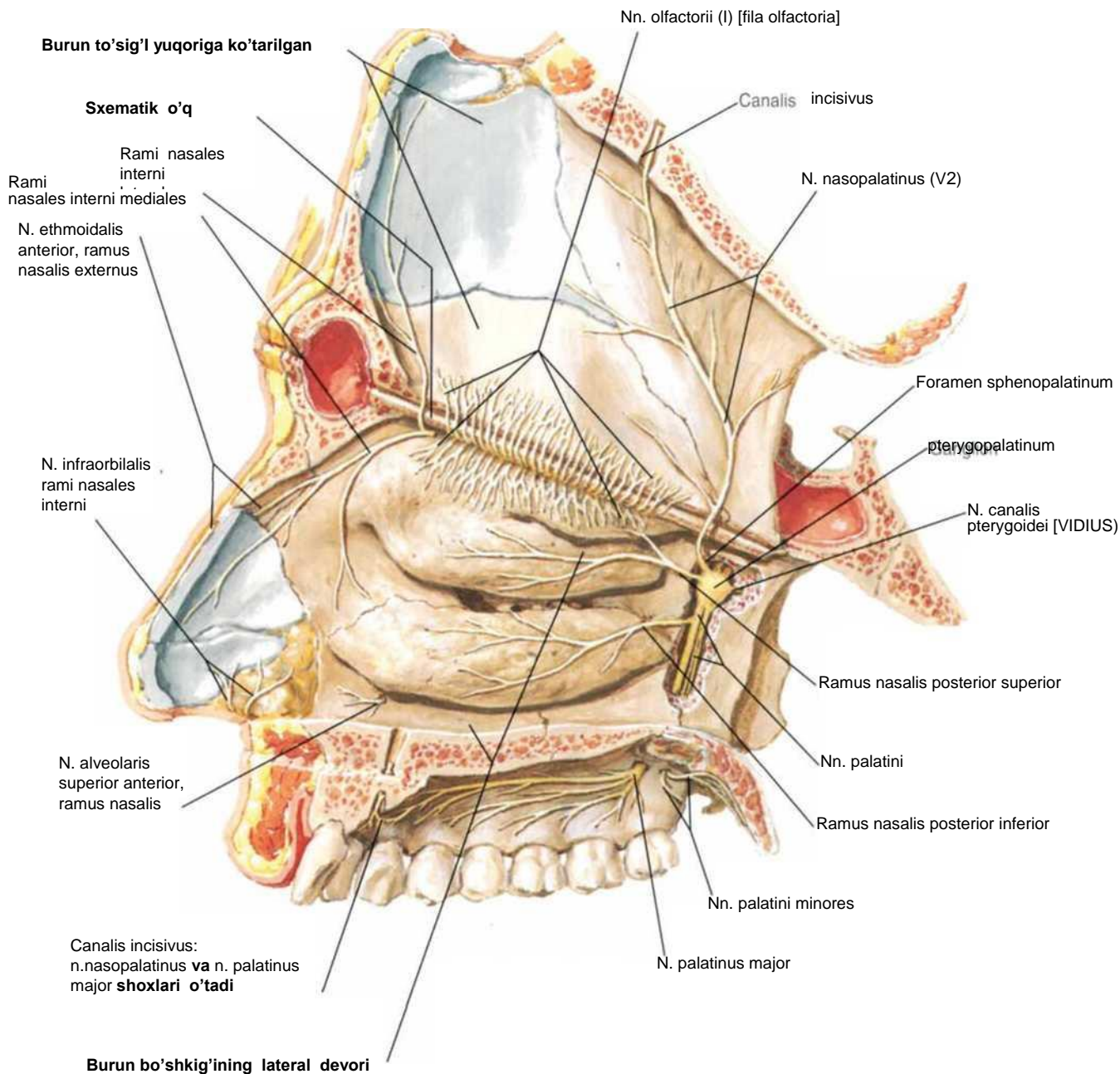


Burun bo'shlig'I arteriyalari:burun to'sig'l yuqoriga ko'tarilgan



Burun bo'shlig'i nervlari: burun to'sig'l yuqoriga ko'tarilgan

39. 40. 113-rasmlarga qarang.



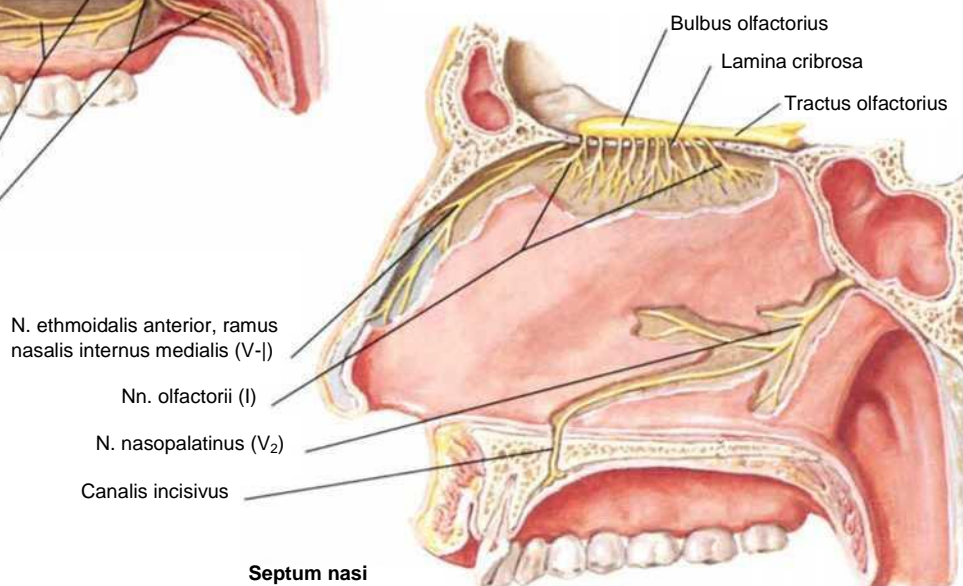
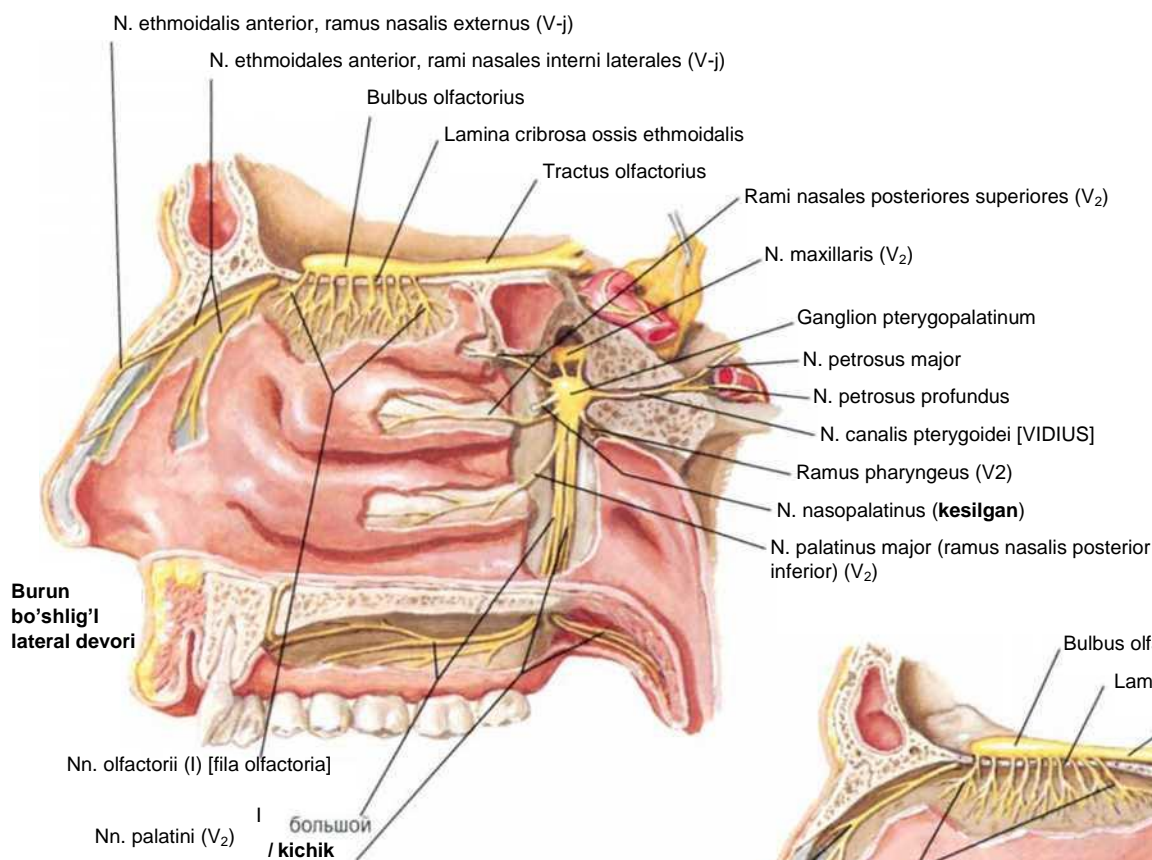
Burun bo'shlig'i nervlari (davomi)

113-rasmga qarang.

Burun shilliq qavatida xid bilish qismining tarqalishi (ko'k rangda)

Burun bo'shlig'ining lateral devori

Septum nasi



Burun bo'shlig'ini vegetativ innervatsiyasi

116. 125. 127-rasmlarga qarang.

Nucleus salivatorius superior N.

facialis (VII)

Ganglion geniculi

N. pefrosus major

N. pefrosus profundus

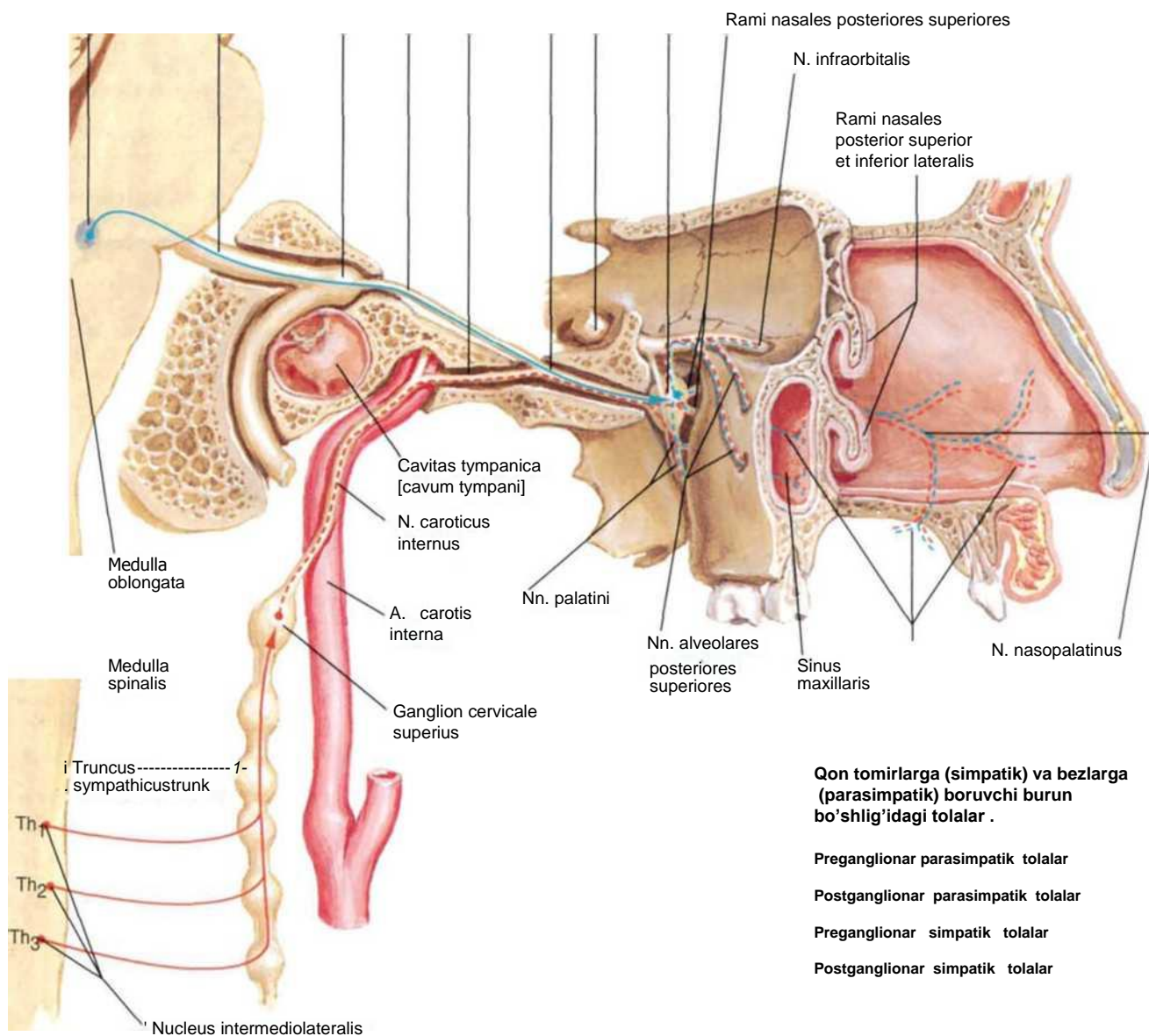
N. canalis pterygoidei [VIDIUS)

N. maxillaris (V2). foramen rofundum dan o'tadi

Ganglion pterygopalatinum
e fossa pterygopalatine

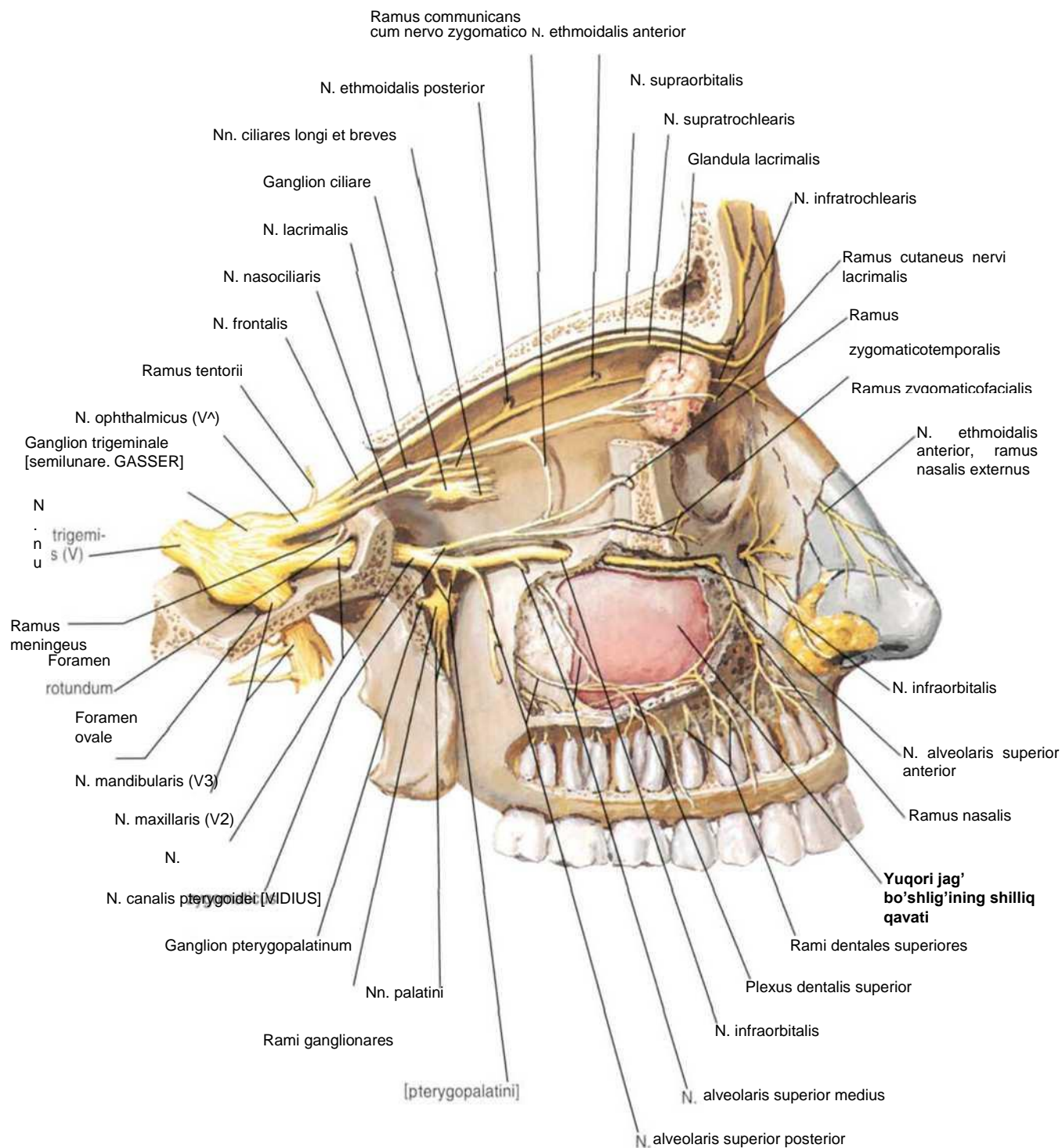
Γ>τ

"V



Ko'z (n. *ophthalmicus*) va yuqori jag' (n. *maxillaris*) nervlari

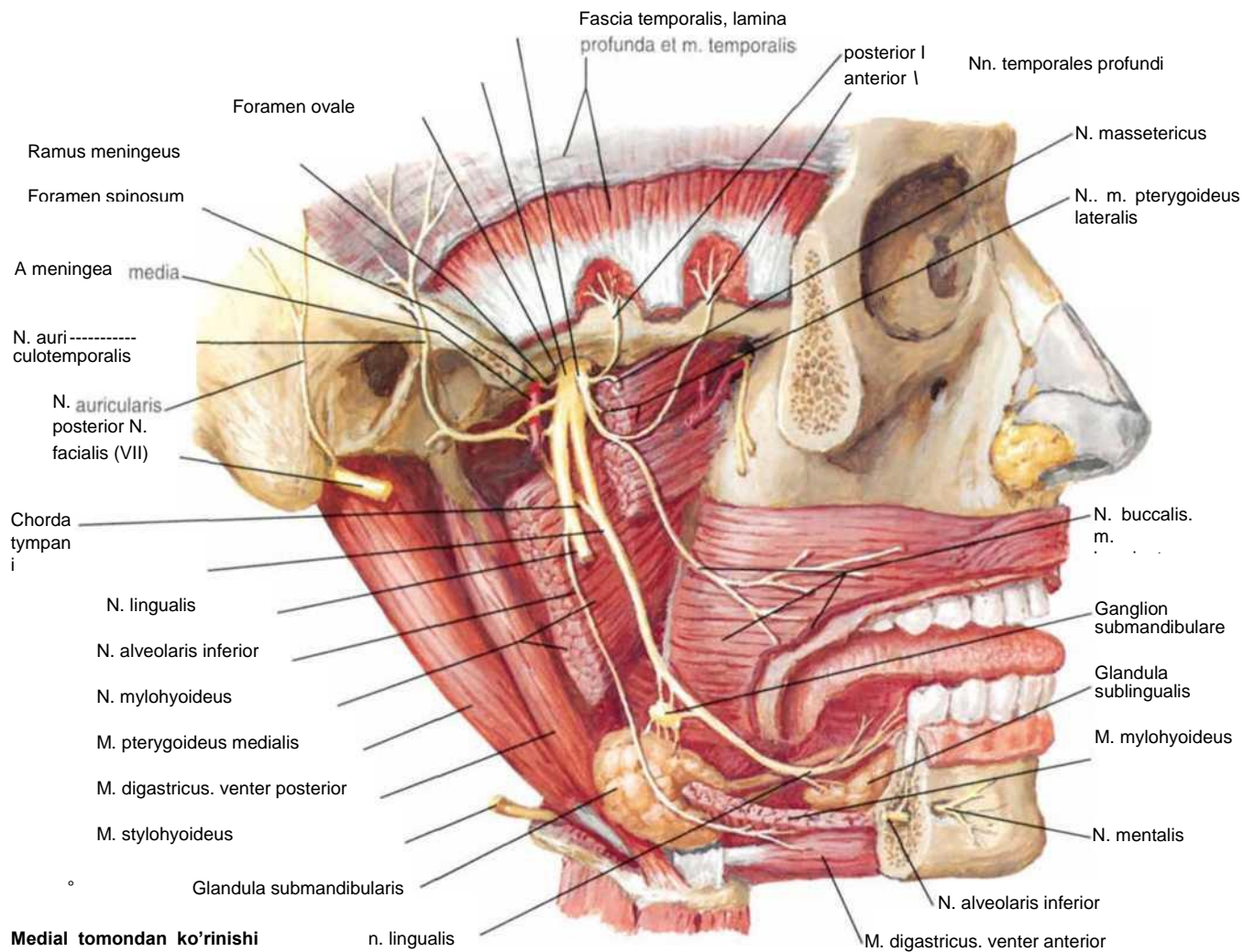
116-rasmga qarang.



Pastki jag' nervi (n. mandibularis)

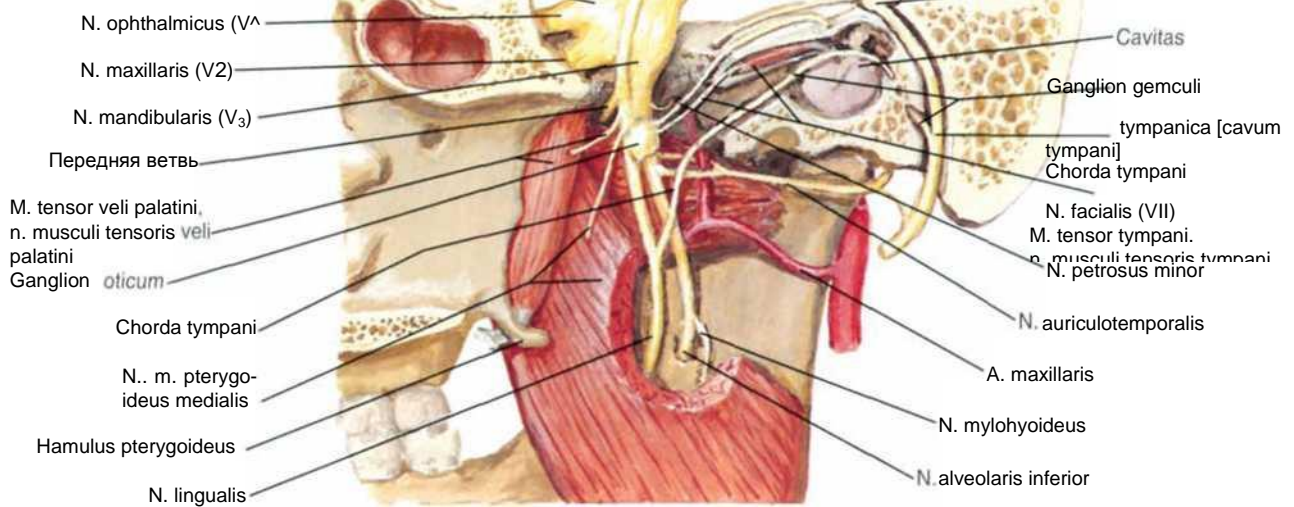
Lateral tomonidan ko'rinishi

65-116-rasmlarga qarang.



Medial tomondan ko'rinishi

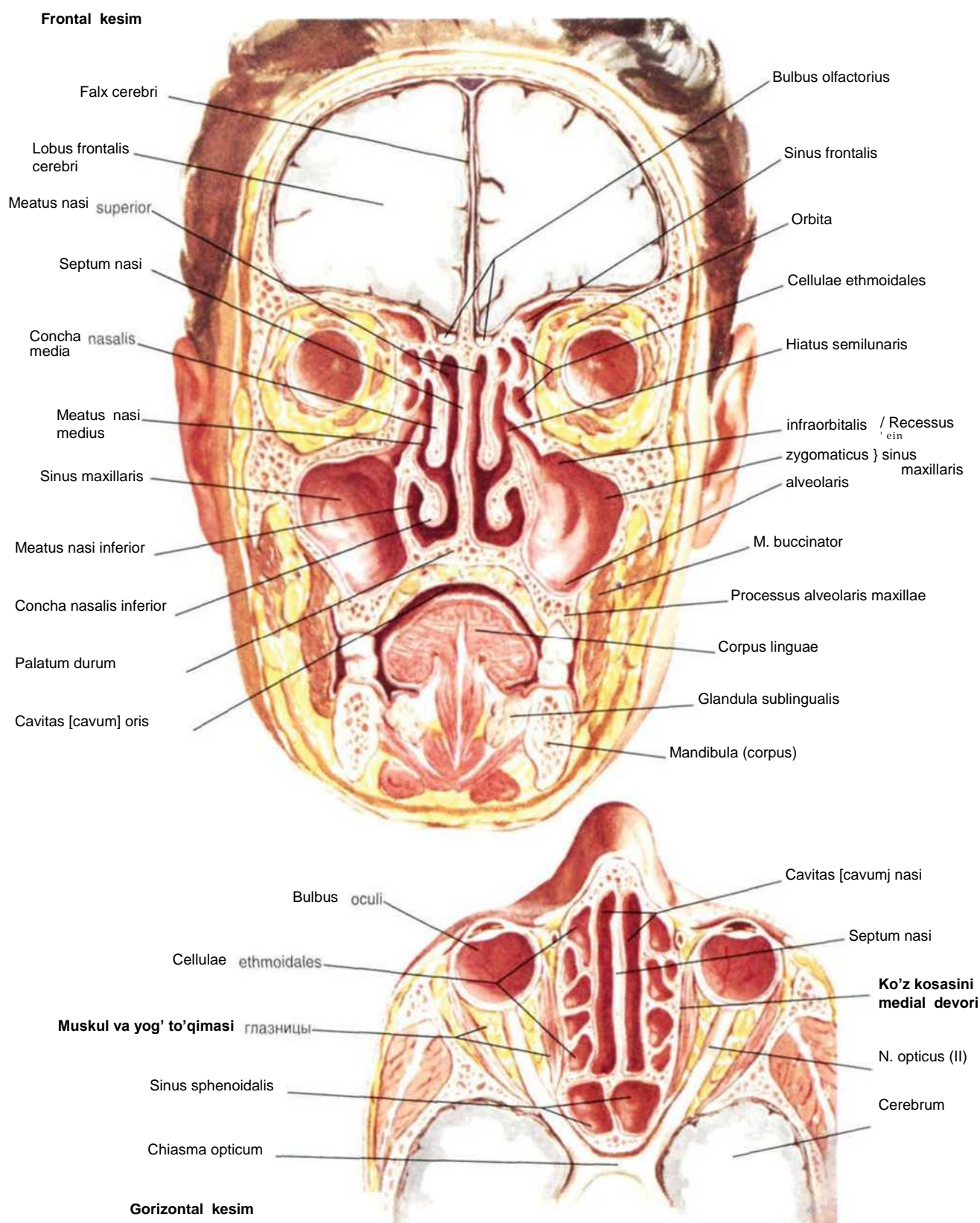
Ganglion trigeminale [semilunare, GASSER]-----



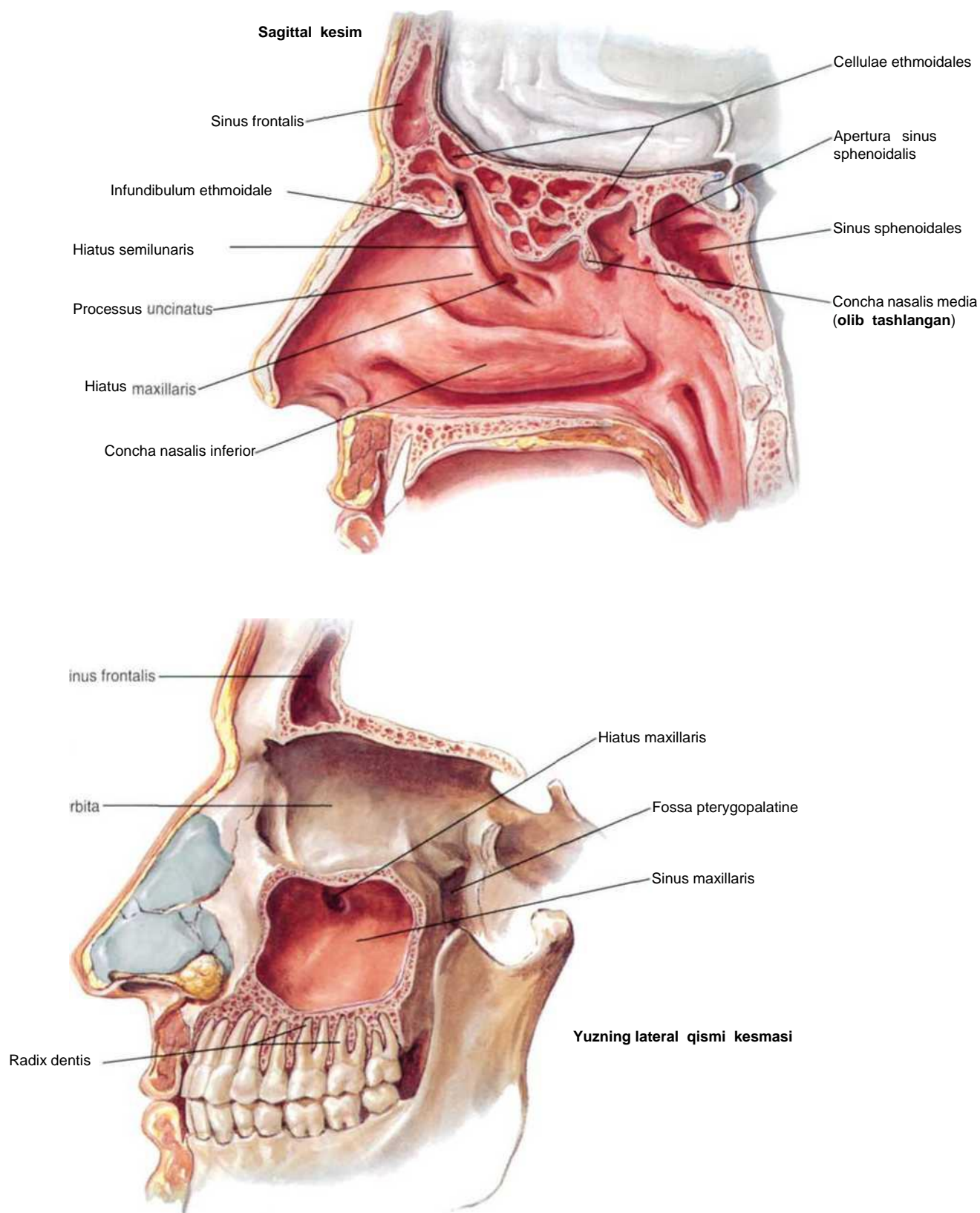
BURUN SOHASI

41-rasm

Burun yondosh bo'shliqlari (sinus paranasales)

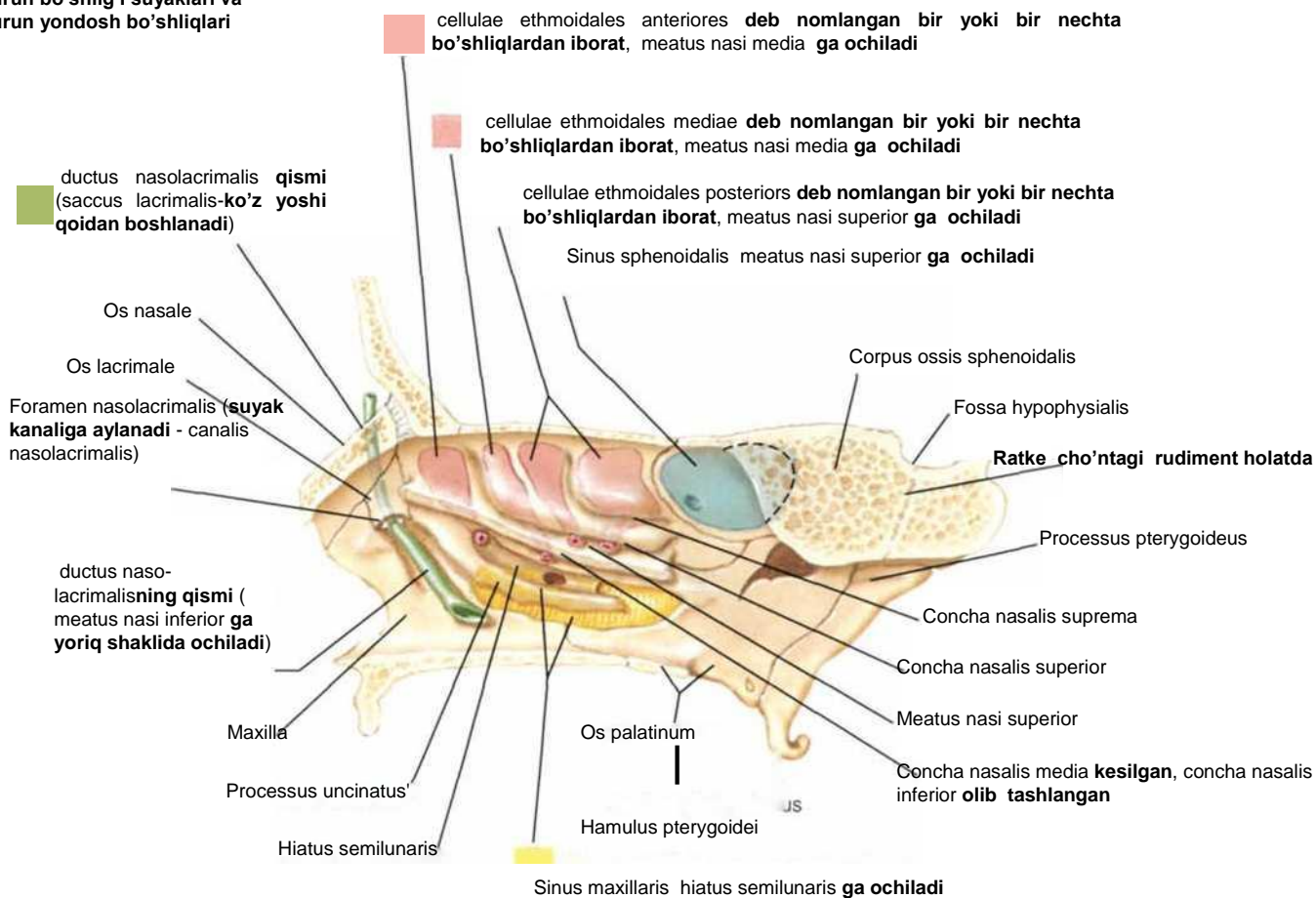


Burun yondosh bo'shliqlari (sinus paranasales)



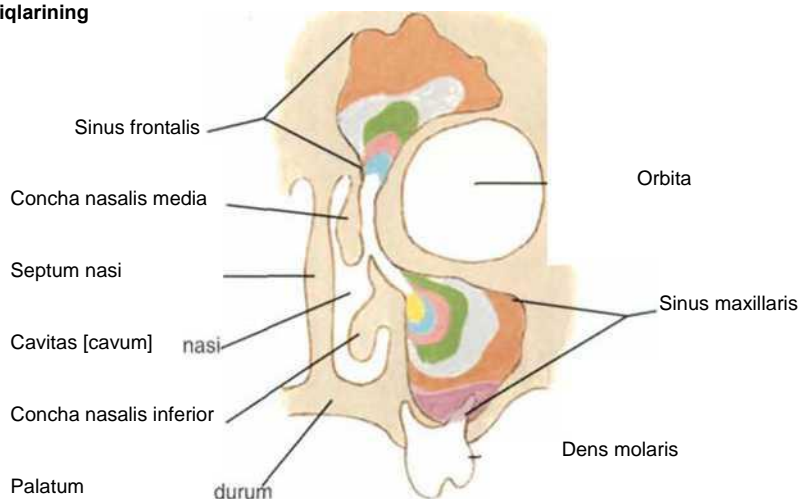
Burun yondosh bo'shliqlari (sinus paranasales), yoshga doir o'zgarishlar

Yangi tug'ilgan chaqaloqlarning
burun bo'shlig'i suyaklari va
burun yondosh bo'shliqlari

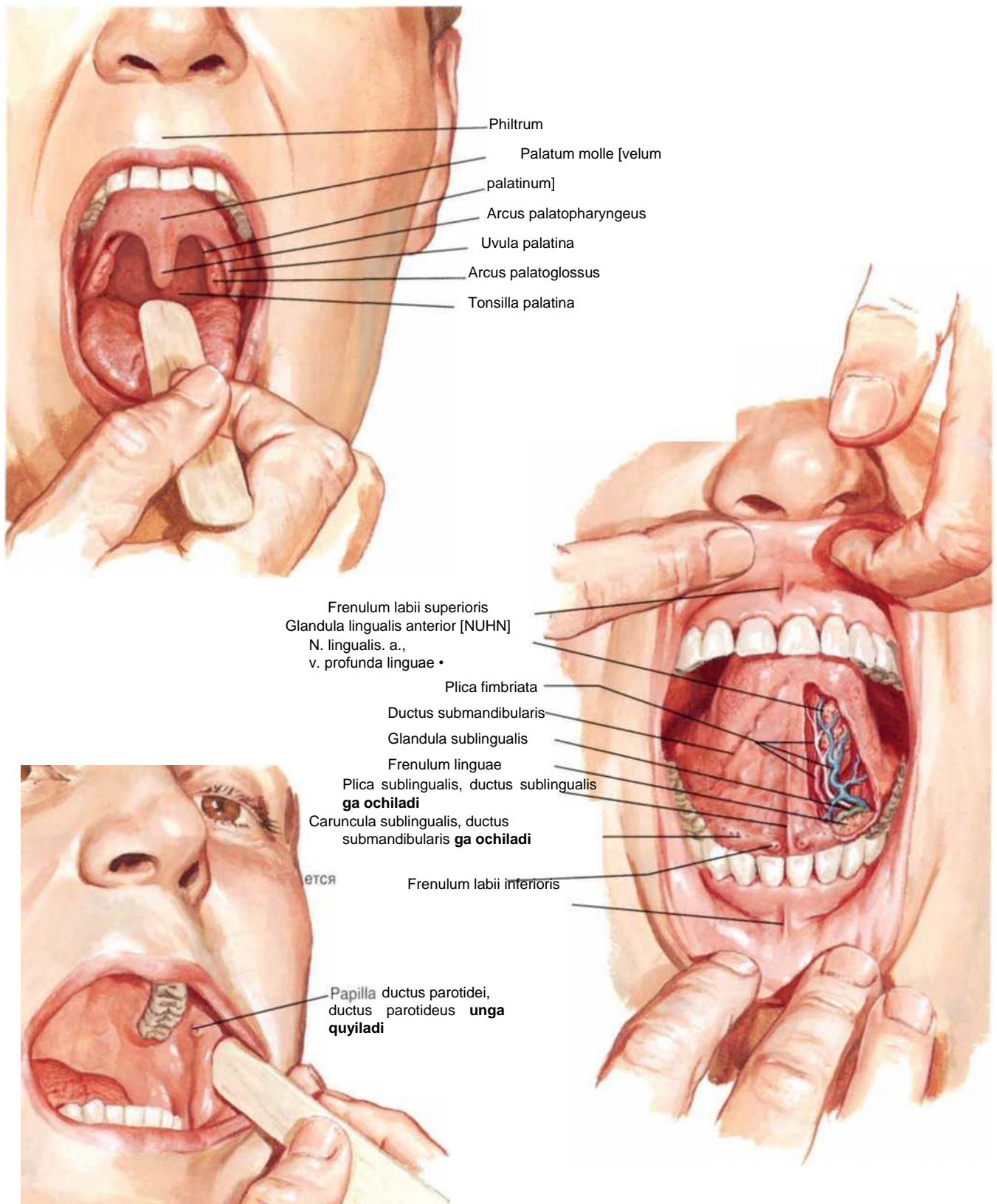


Yuqori jag' va peshona bo'shliqlarining
yoshga doir o'zgarishlari

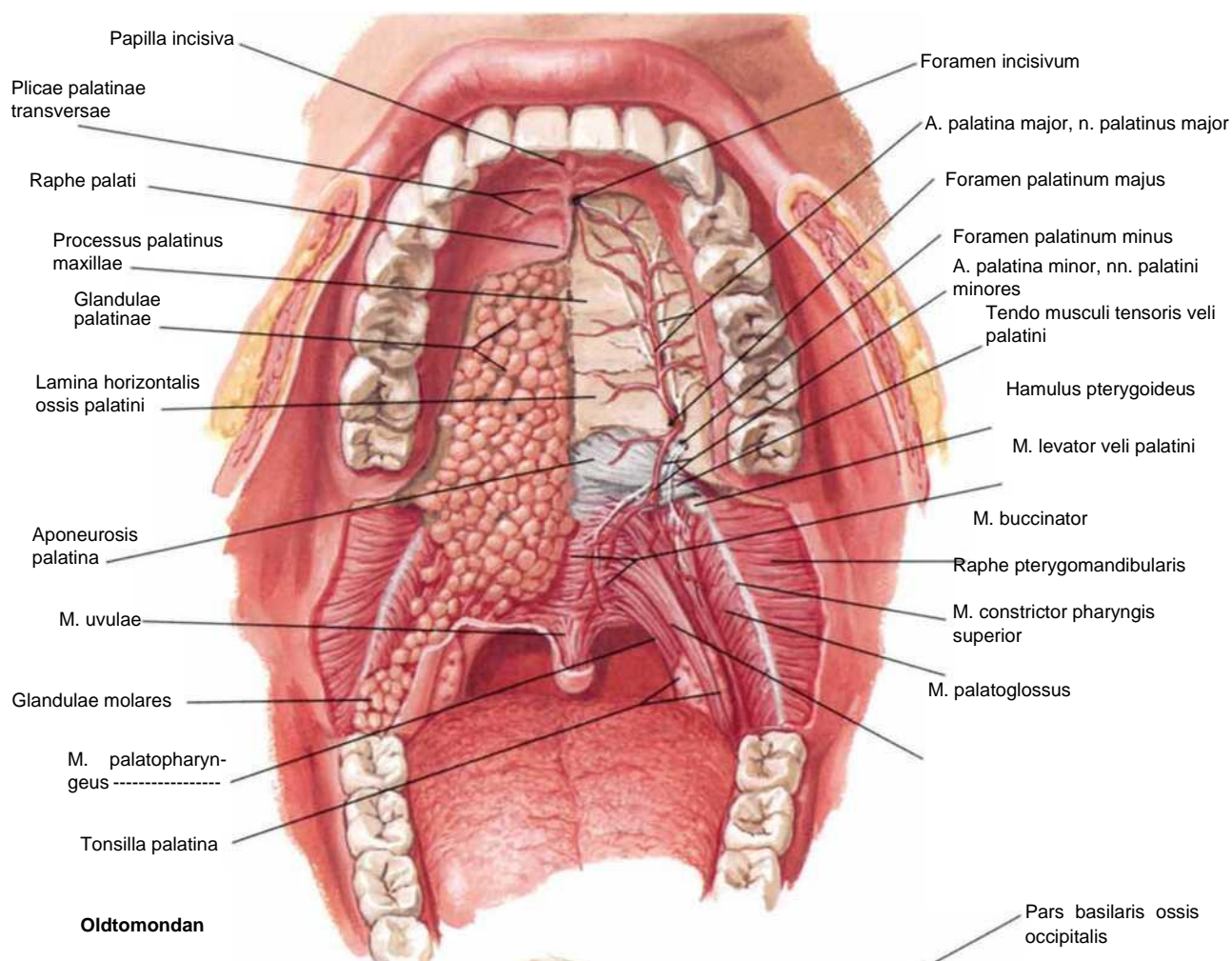
- Chaqaloqlarda**
- 1-yoshda
 - 4-yoshda
 - 7-yoshda
 - 12-yoshda
 - Kattalarda
 - Keksayganda



Og'iz bo'shlig'ini tekshirish

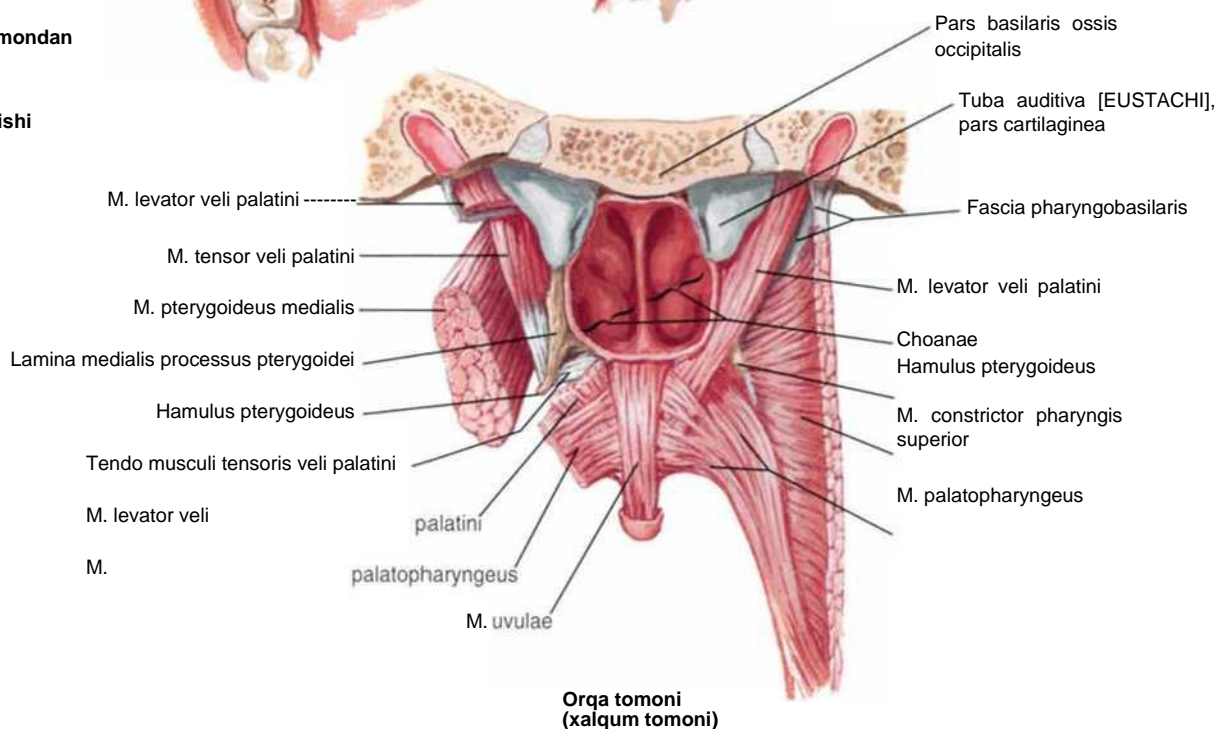


Og'iz bo'shlig'ining yuqori devori



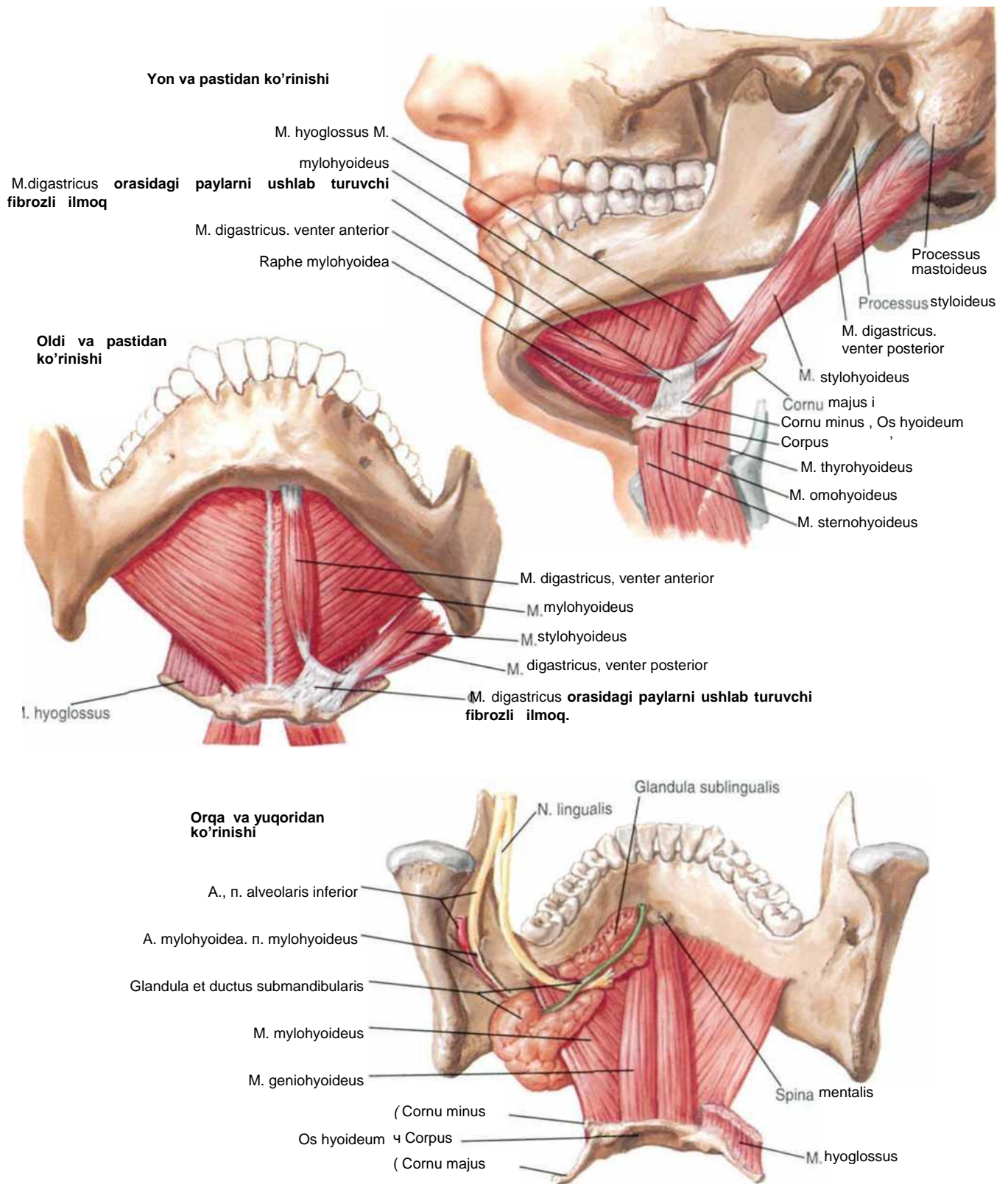
Oldtomondan

ko'rinishi



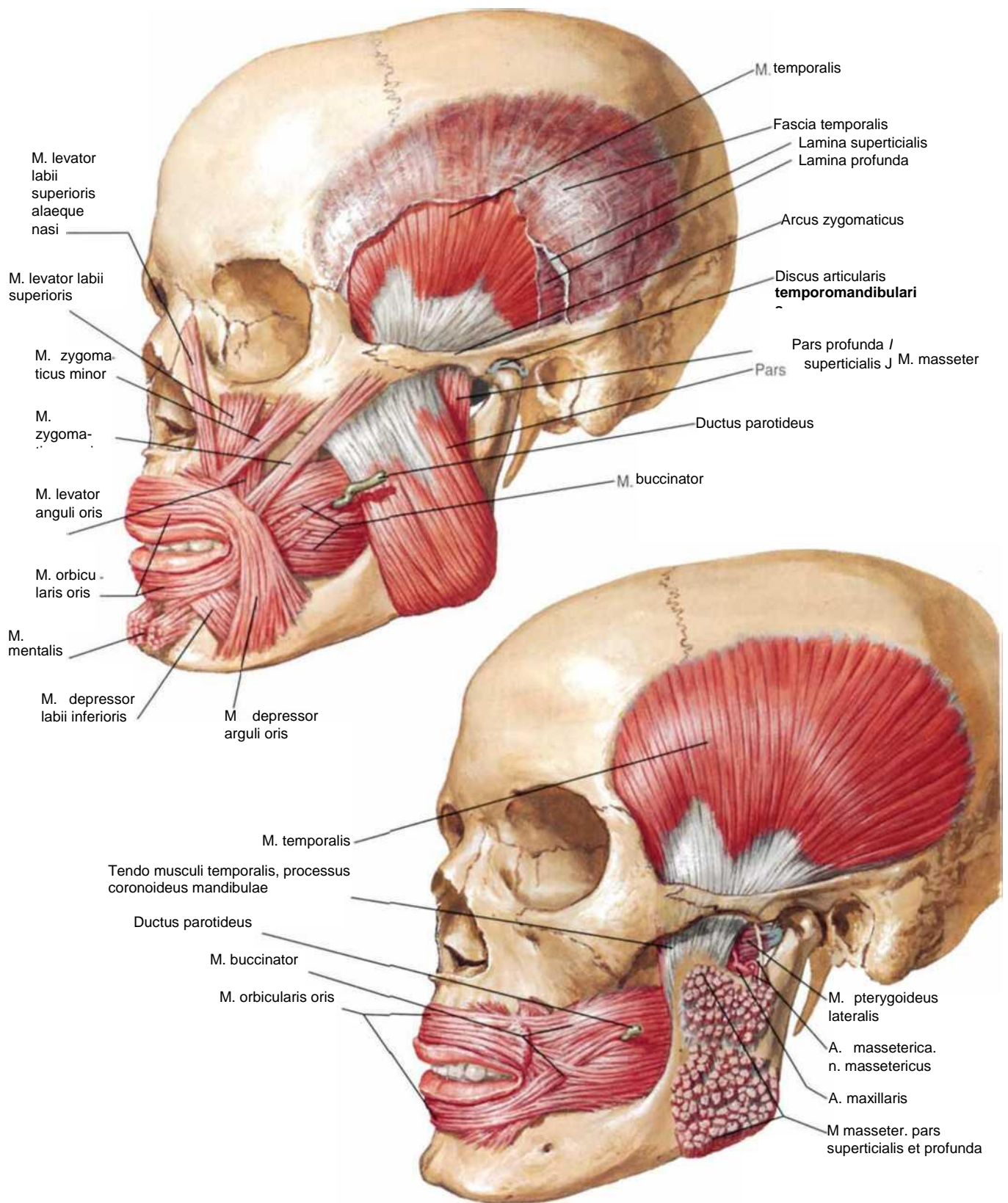
Og'iz bo'shlig'ining tubi

24-rasmga qarang.

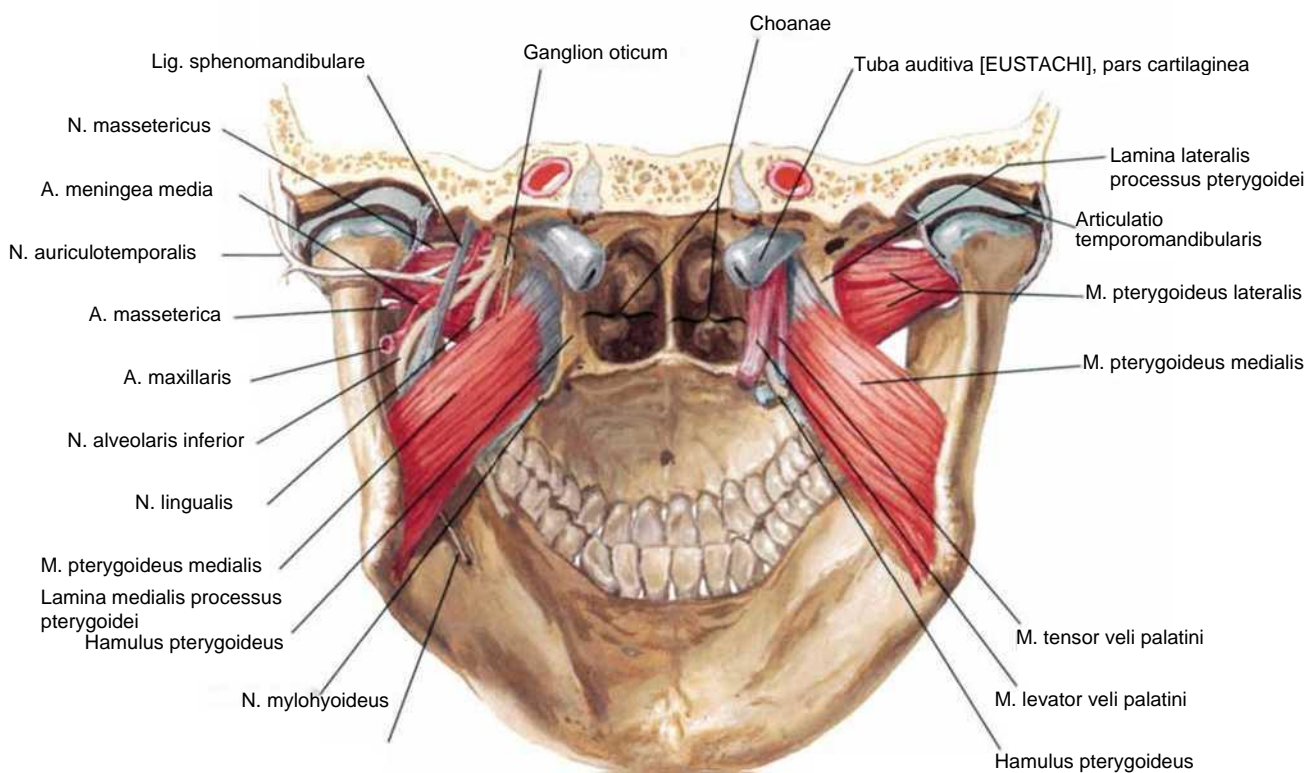
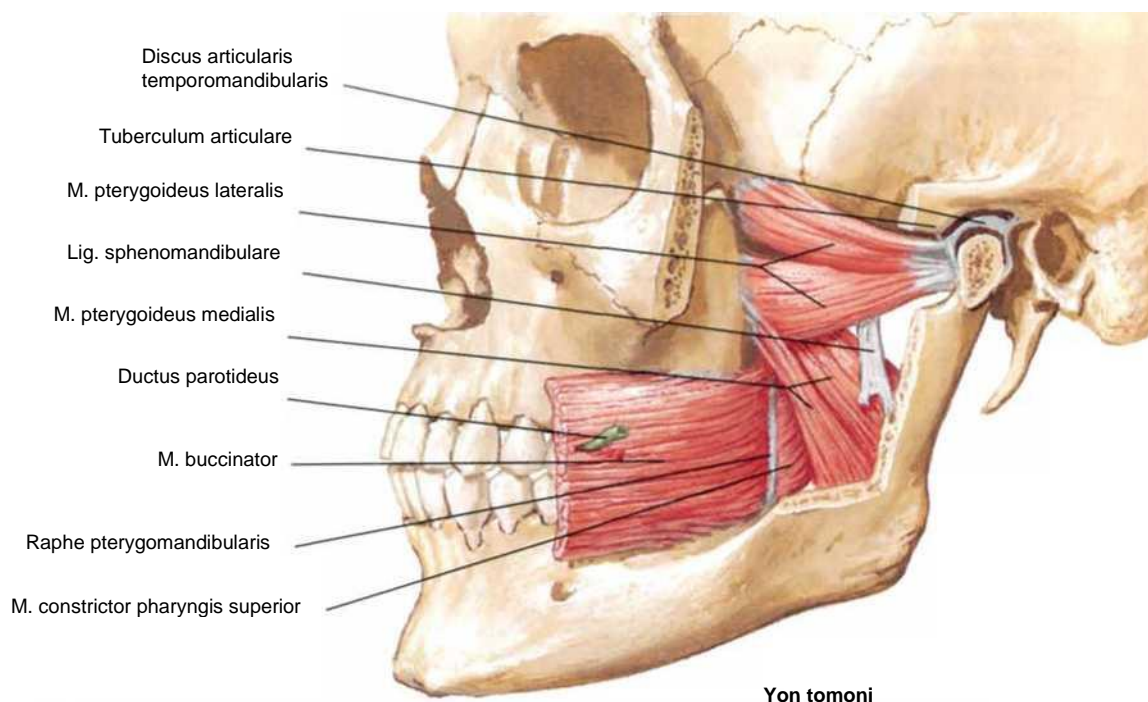


Chaynov va mimika muskullari

20. 21-rasmlarda mimika muskullarini ko'ring.

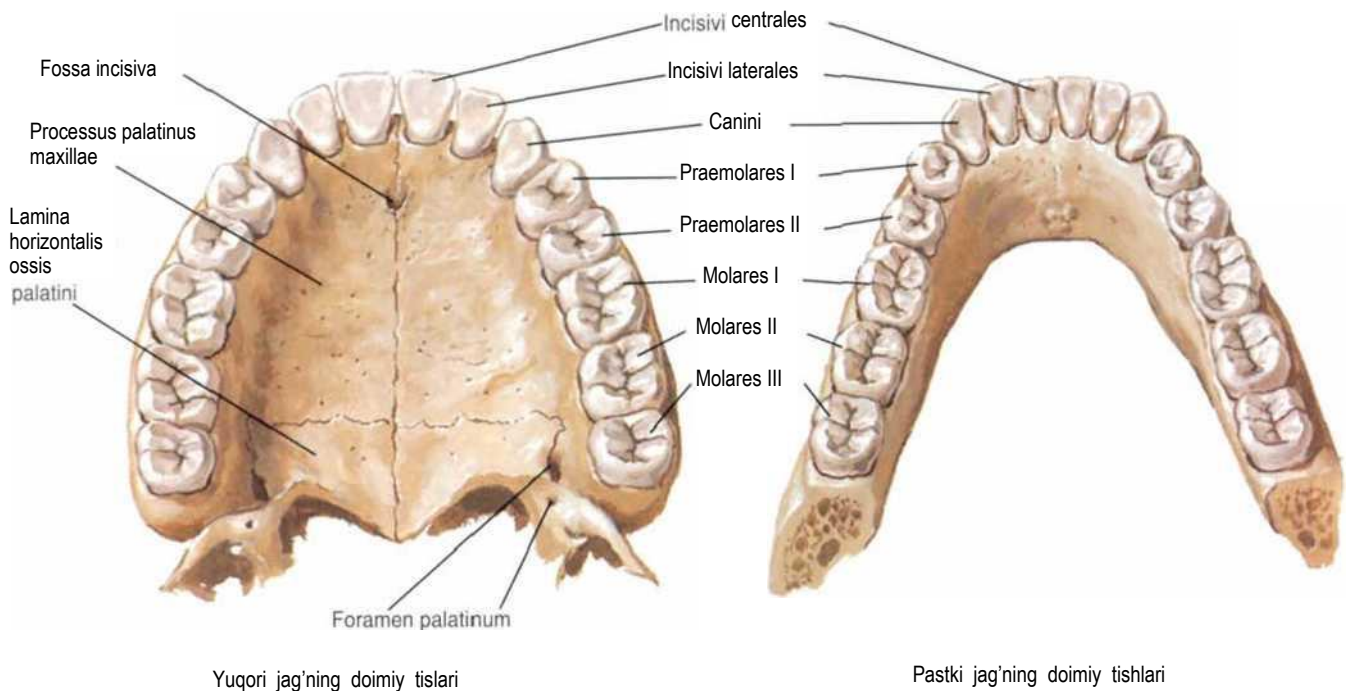
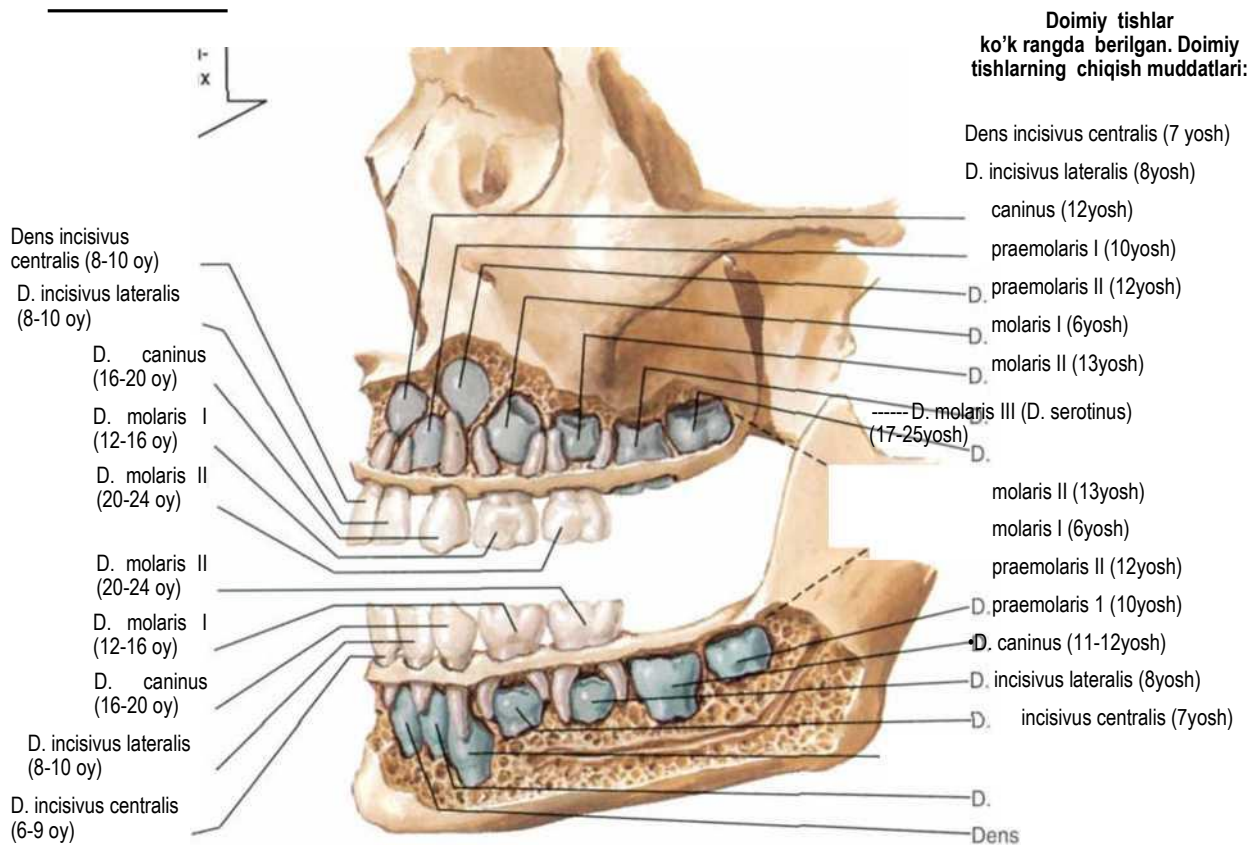


Chaynov muskullari, mm. masticatorii (davomi)

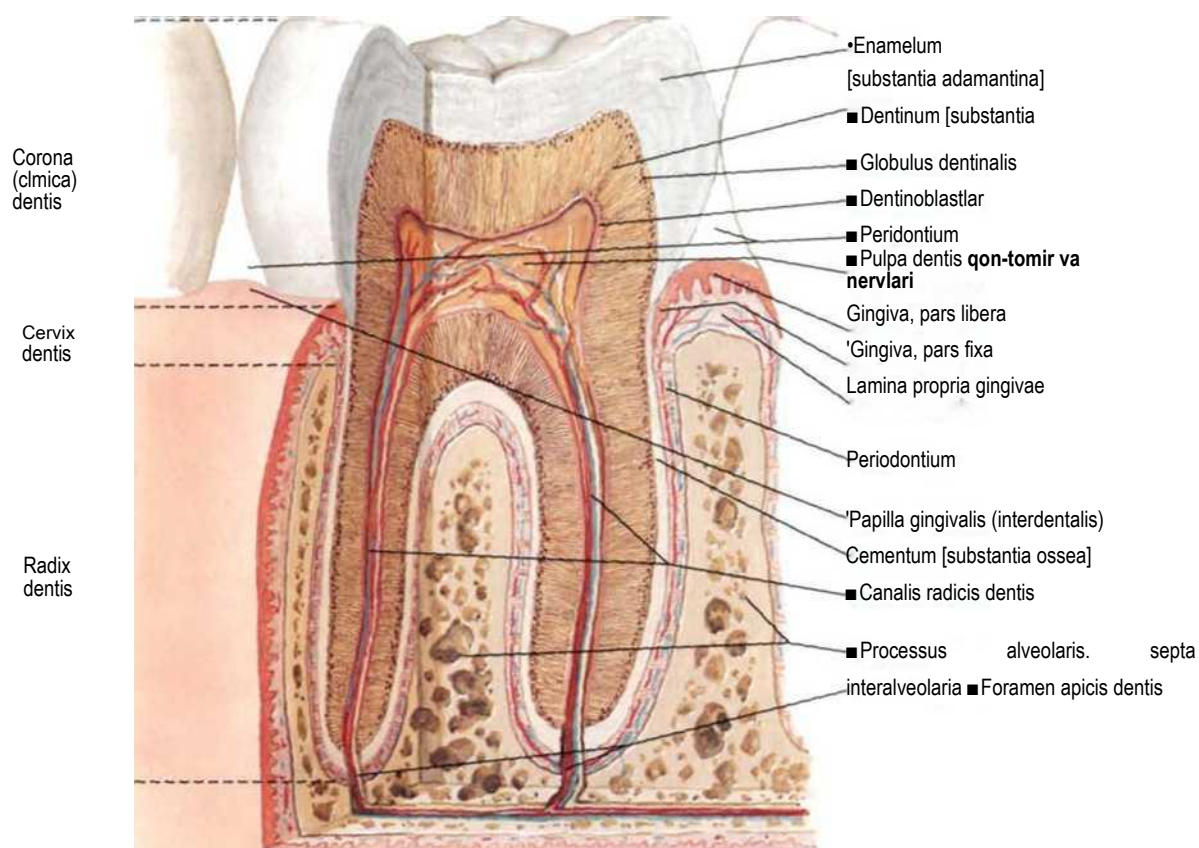


Orqa tomoni

Tishlar (dentes)

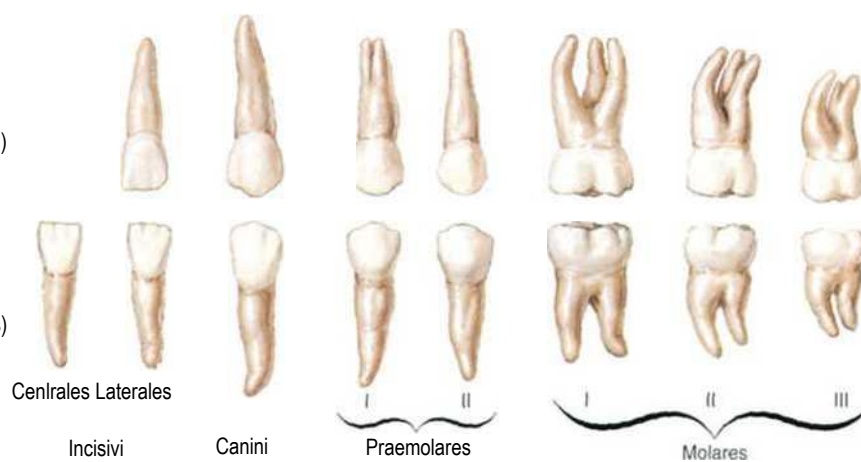


Tishlar (dentes) , davomi

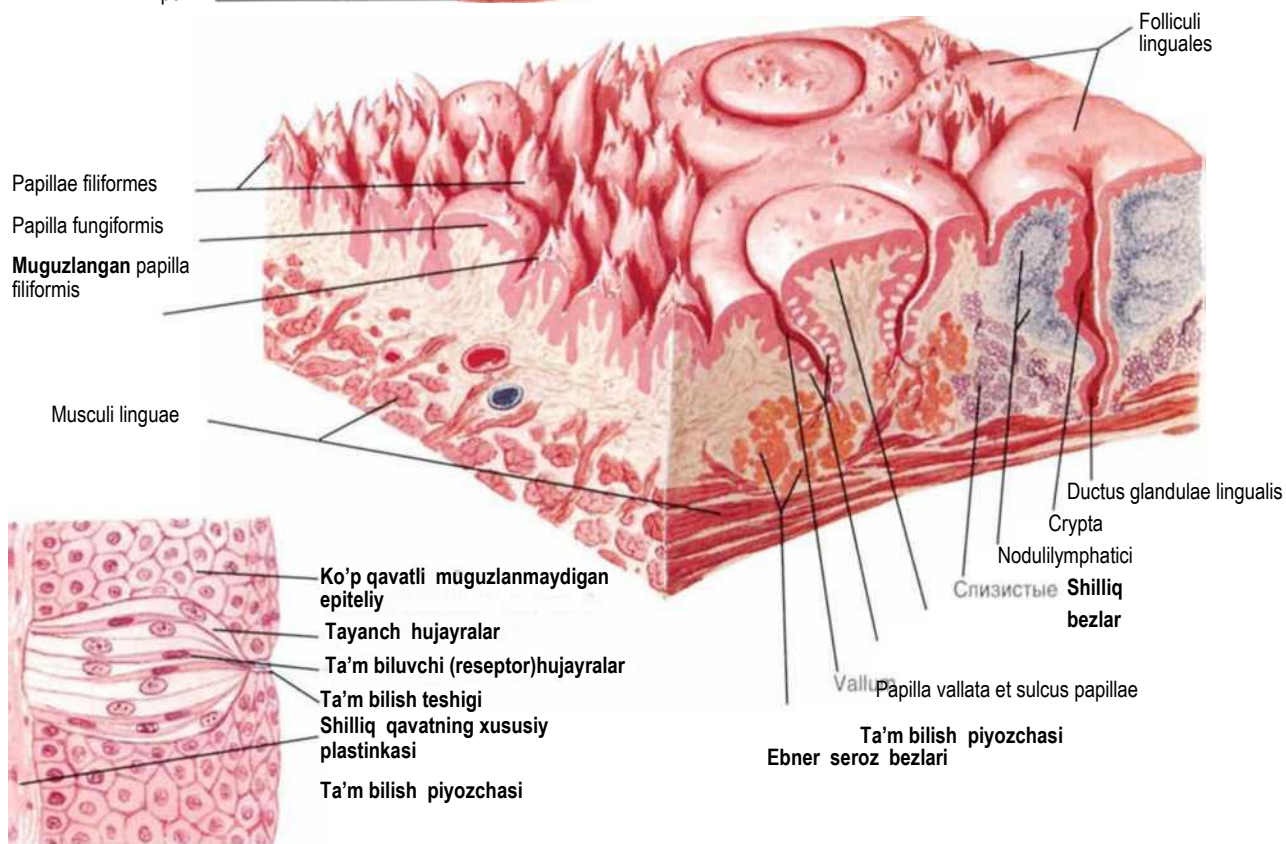
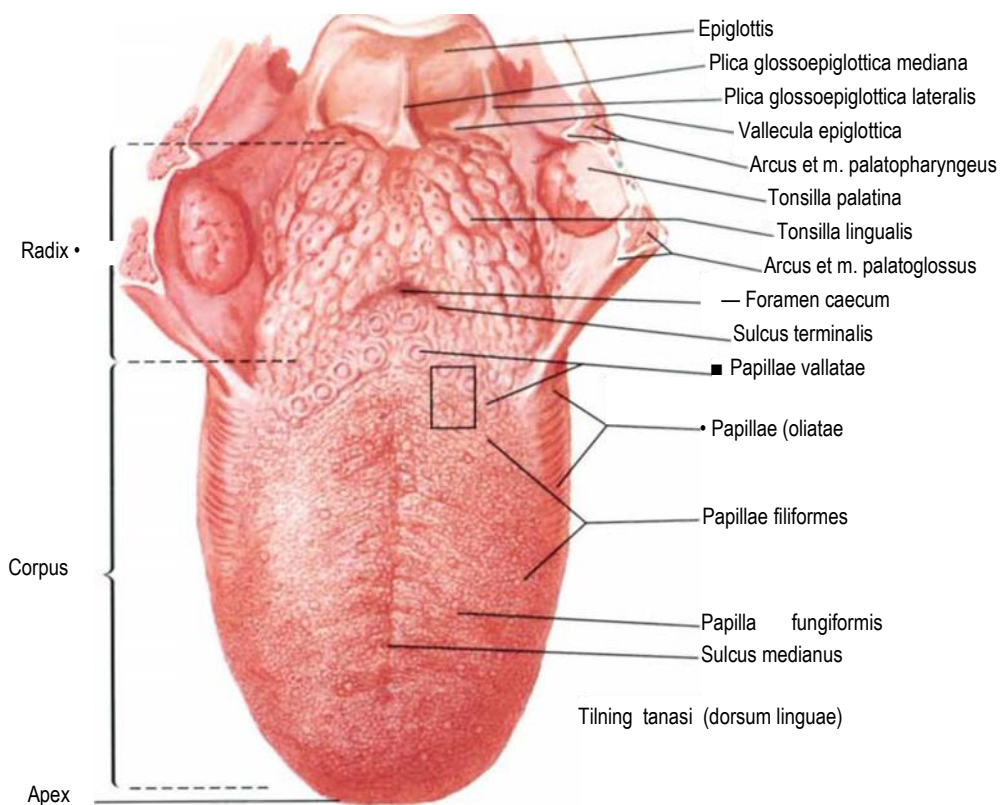


**Yuqori jag'ning
chap yarmi
doimiy tishlari**
(facies vestibularis)

**Pastki jag'ning
chap yarmi
doimiy tishlari**
(facies vestibularis)

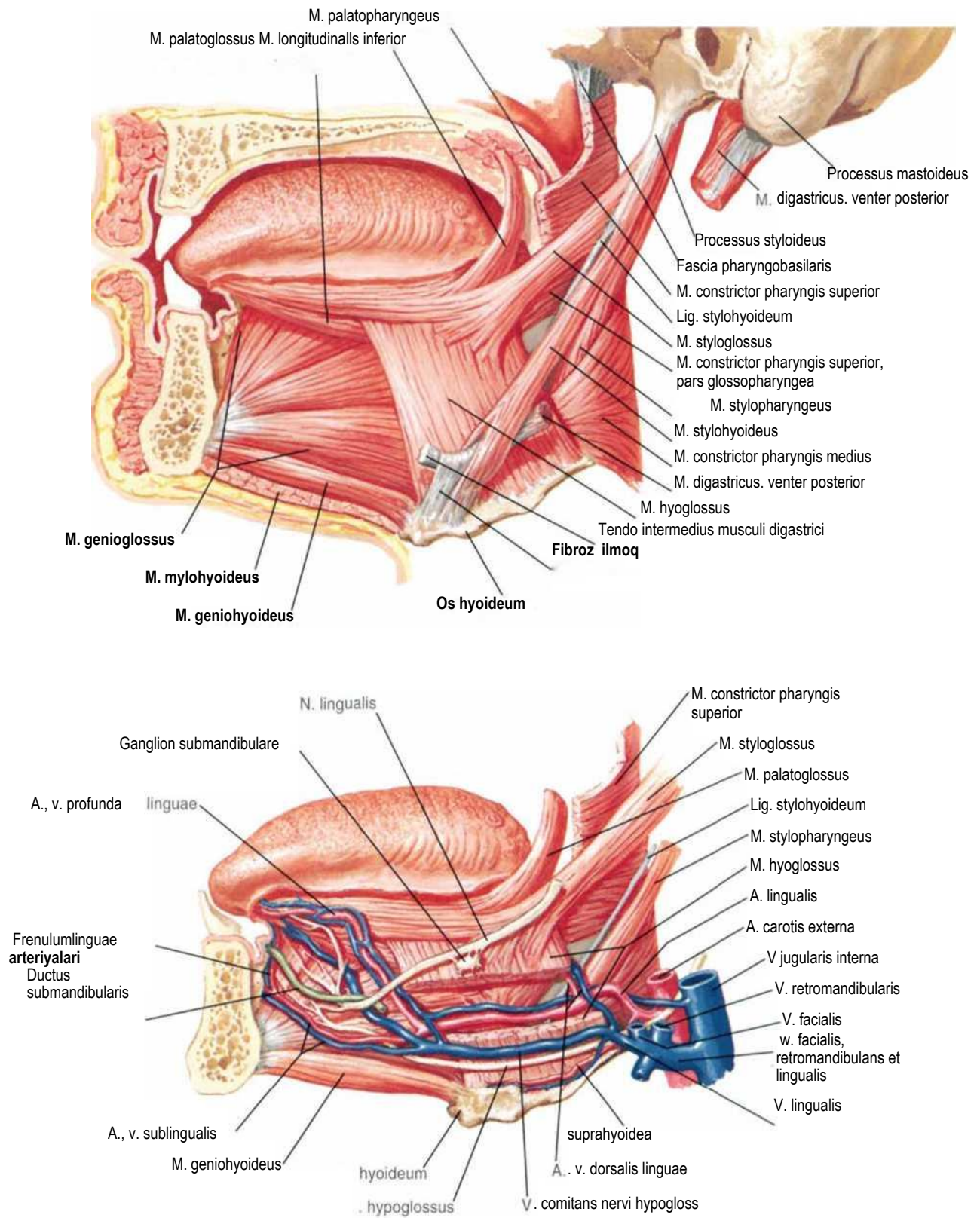


Til (lingua)



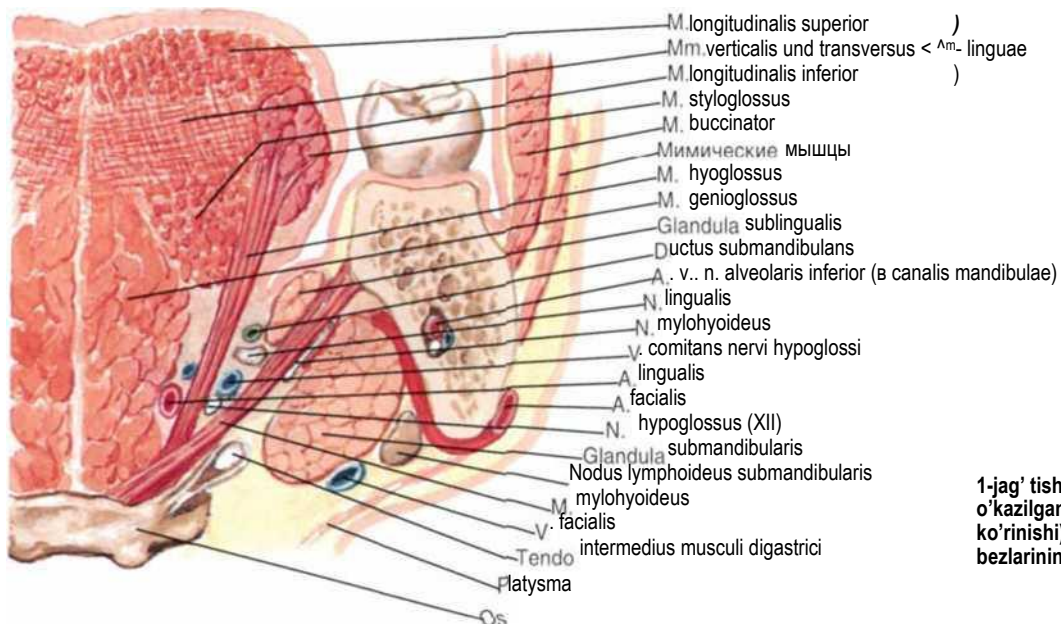
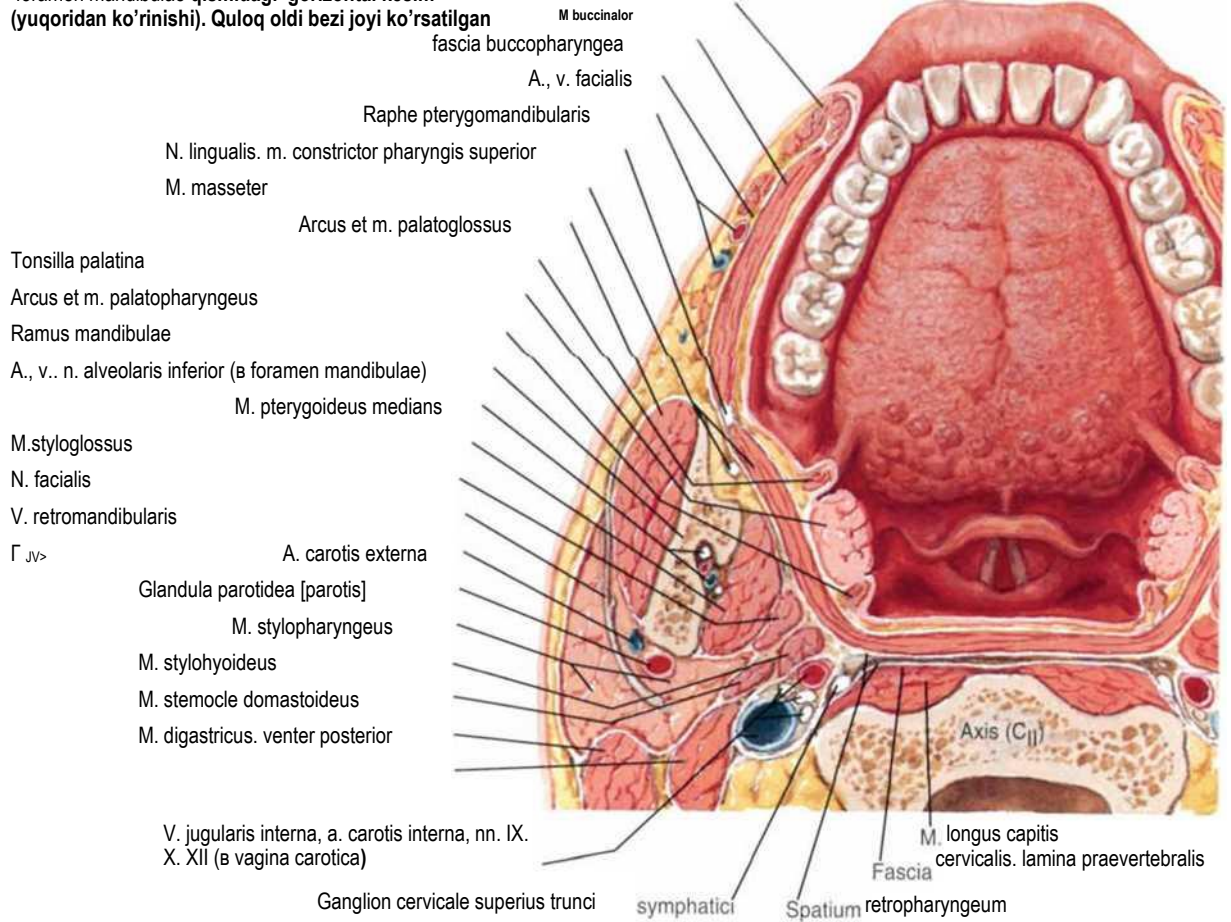
Til (lingua)

29. 41. 47. 122-rasmlar.



Til va so'lak bezlari (kesimlarda)

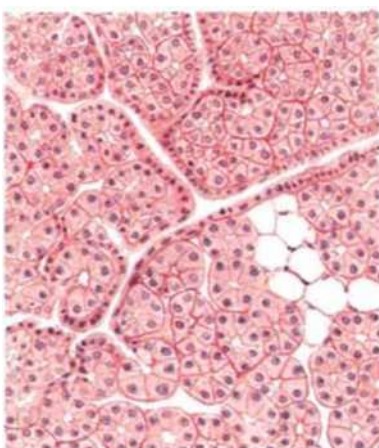
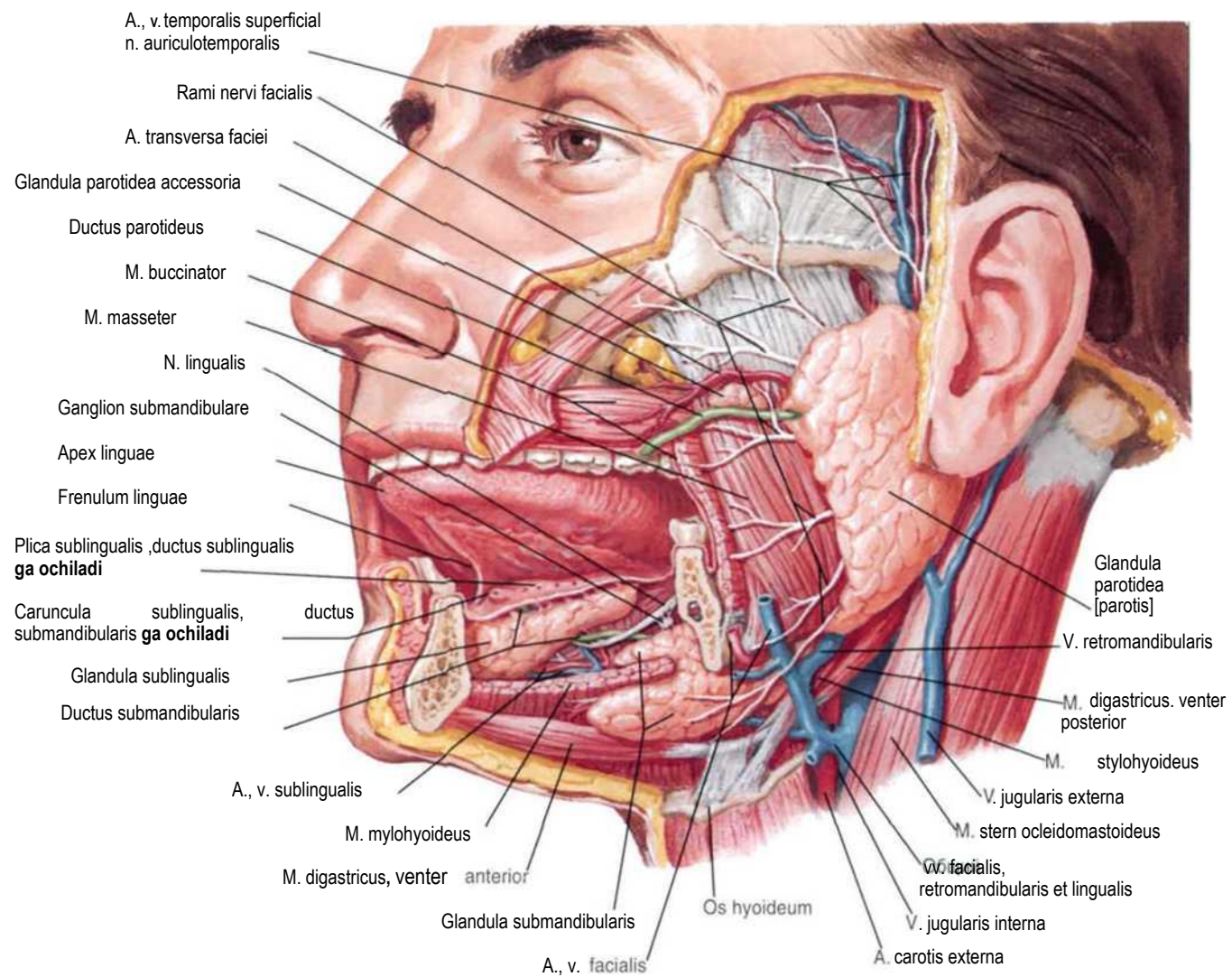
foramen mandibulae qismidagi gorizonttal kesim
(yuqoridan ko'rinishi). Quloq oldi bezi joyi ko'rsatilgan



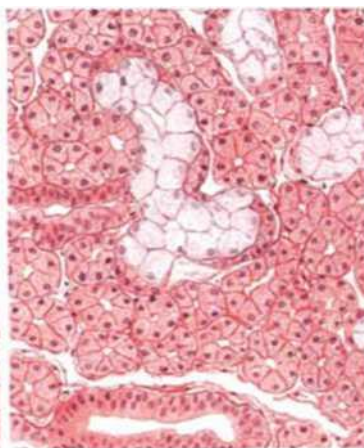
1-jag' tishini orqa tomonidan o'kazilgan frontal kesim(old ko'rinishi). Jag'osti va tilosti so'lak bezlarining joylashuvi ko'rsatilgan.

So'lak bezlari (glandulae salivariae)

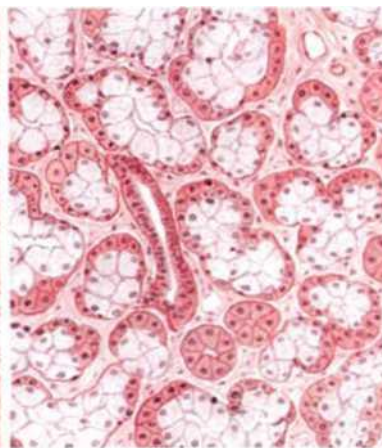
19. 47. 127. 128. 153-rasmlarga qarang.



Glandula parotidea
(«seroz bez»)



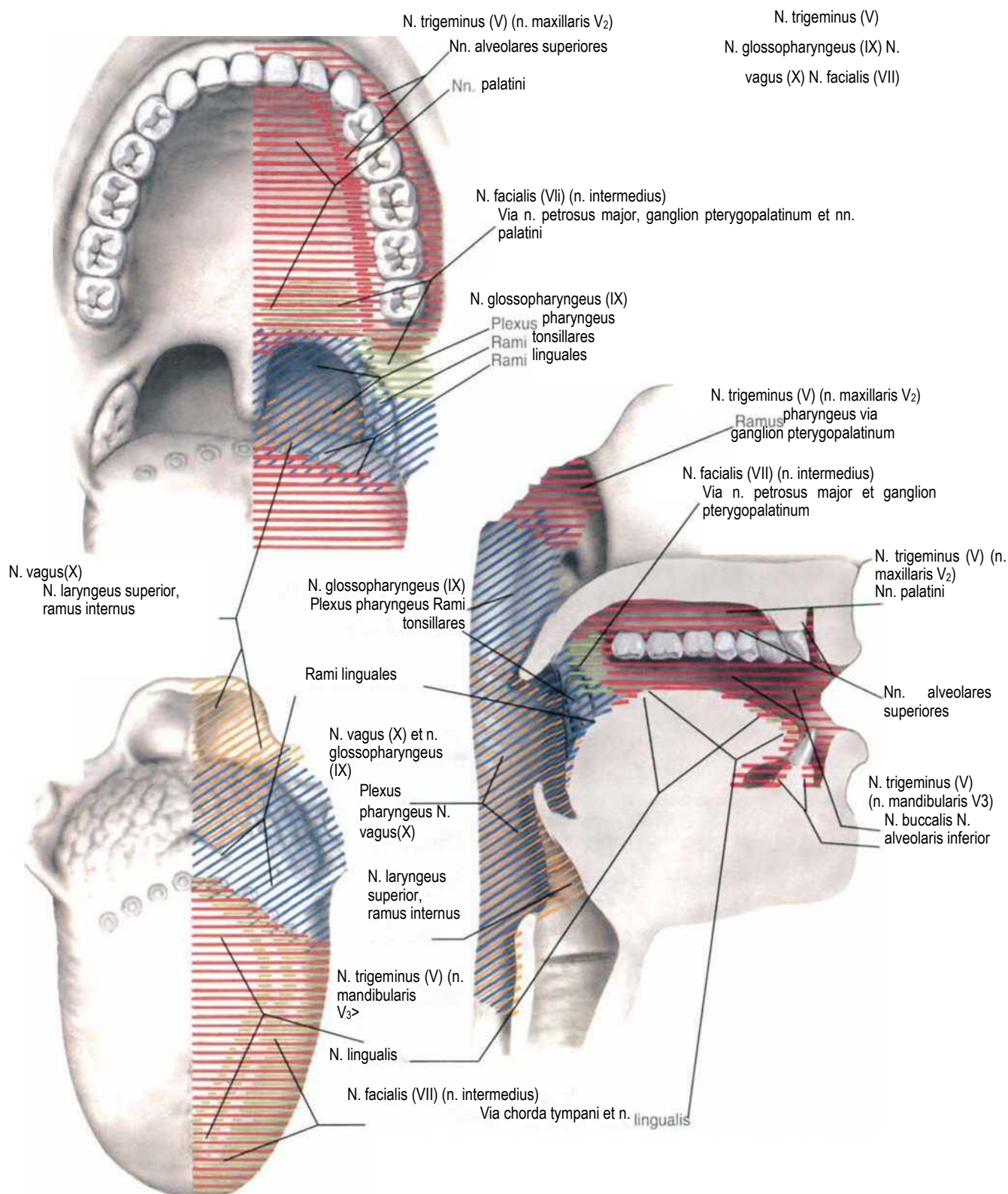
Glandula submandibularis
(«seroz-shilliq» bez)



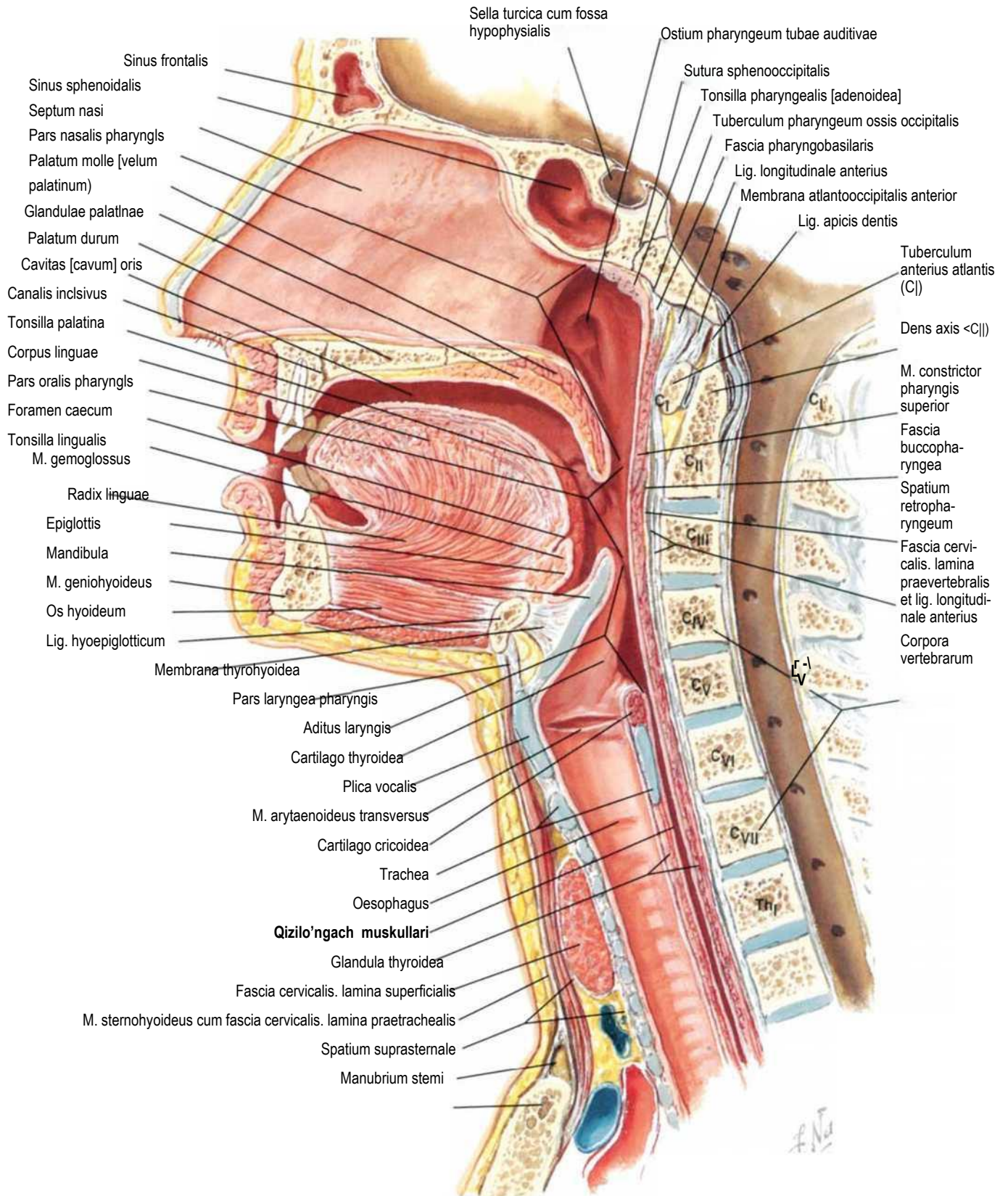
Glandula sublingualis
(«shilliq» bez)

Og'iz bo'shlig'ining sezuvchi (afferent) innervatsiyasi

41. 46. 53. 58. 116 117. 119. 127. 129-rasmlarga qarang.

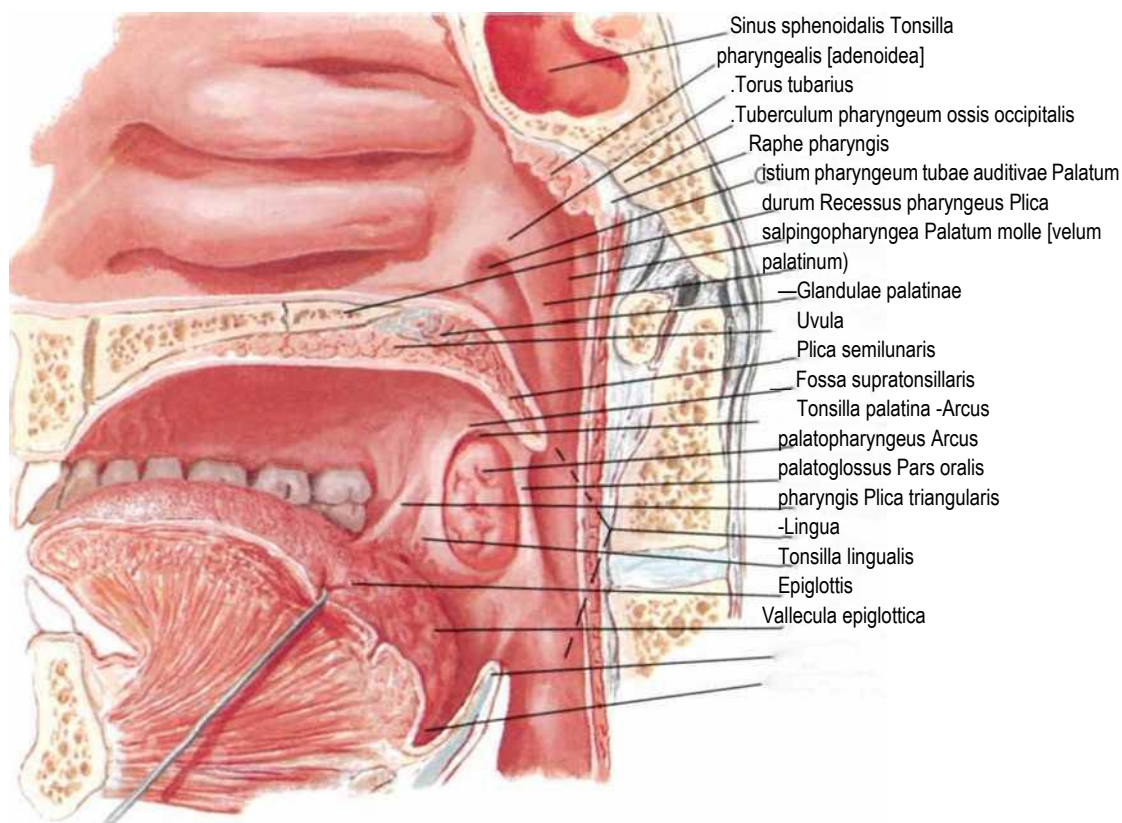


Halqum (pharynx): o'rta sagittal kesimi

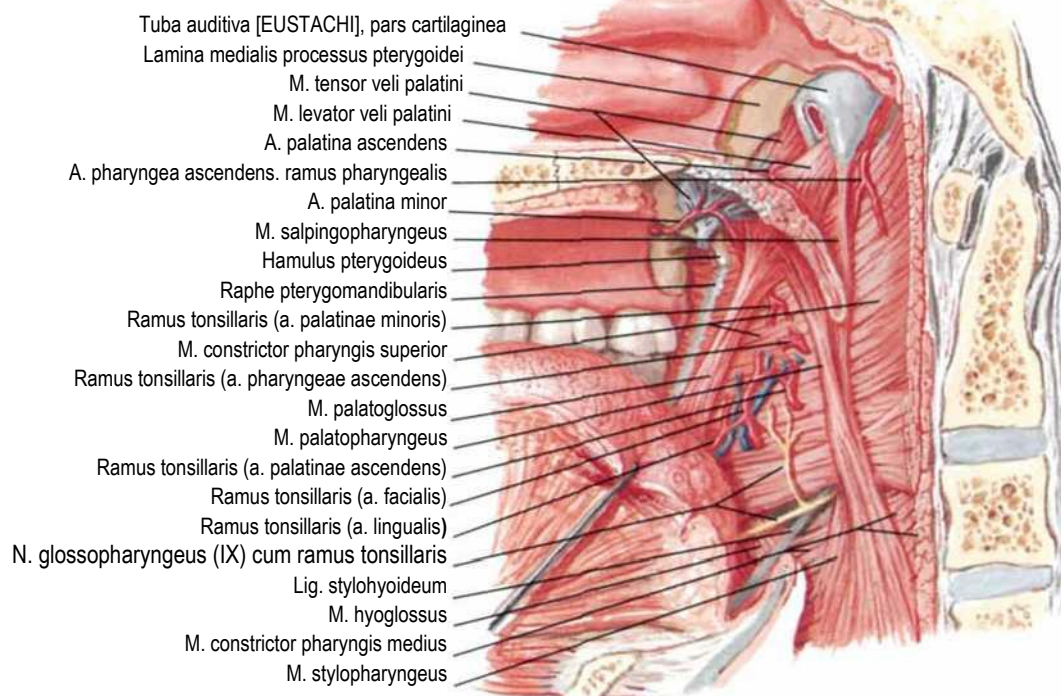


Og'iz bo'shlig' orqa devori (faucis)

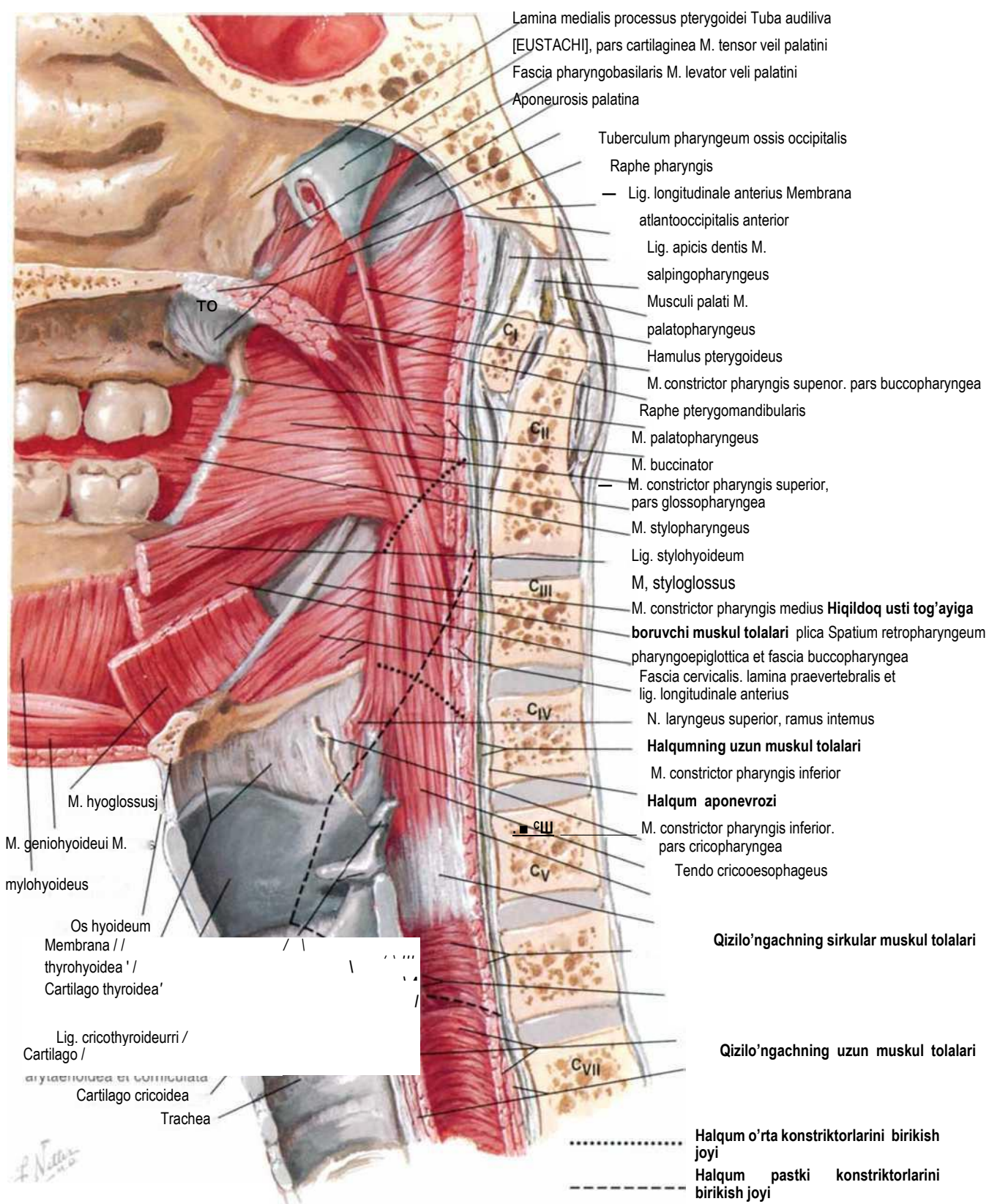
O'rta sagittal kesim



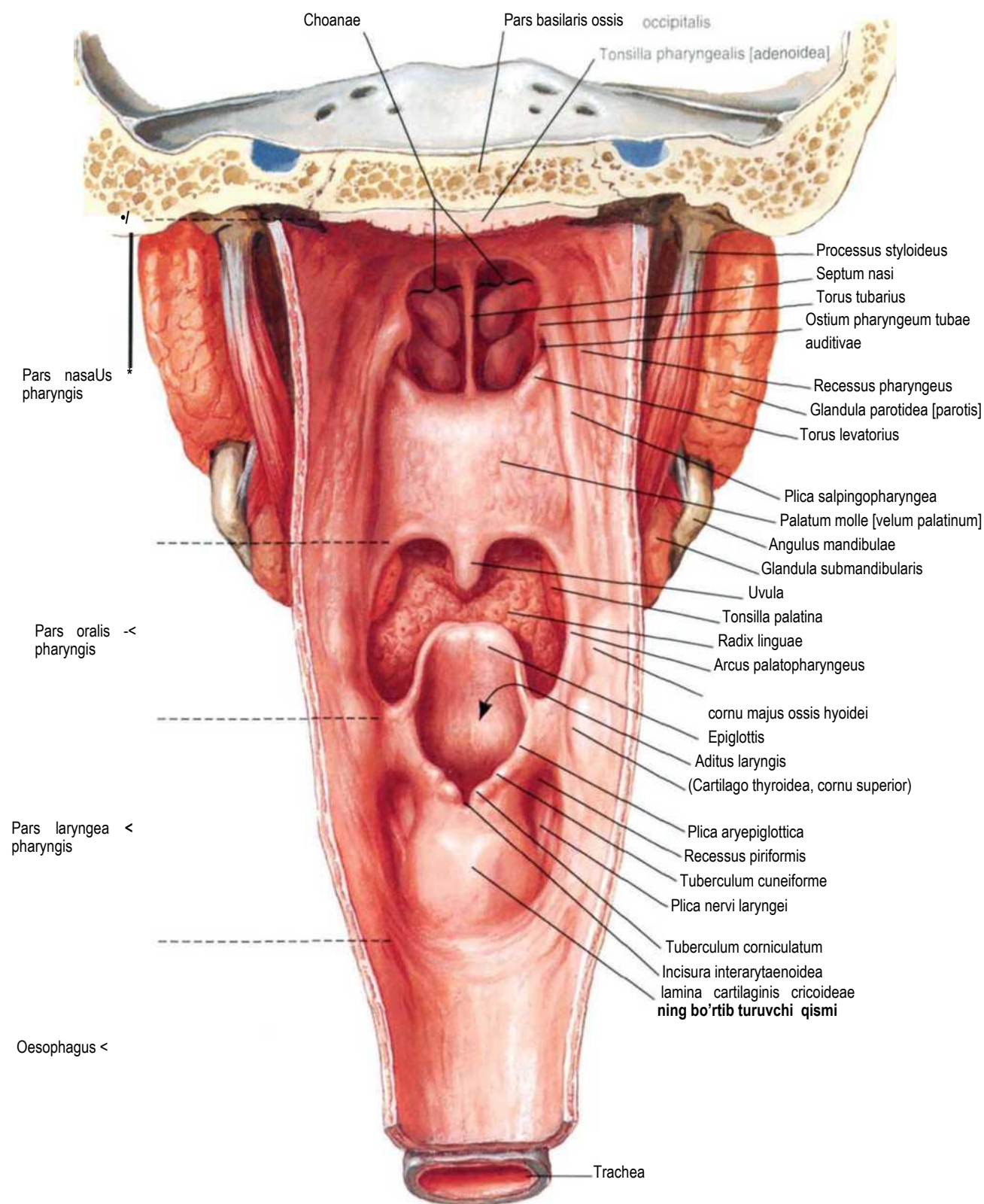
Halqumning shilliq qavati olib tashlangan



Halqum muskullari: o'rta sagittal kesim

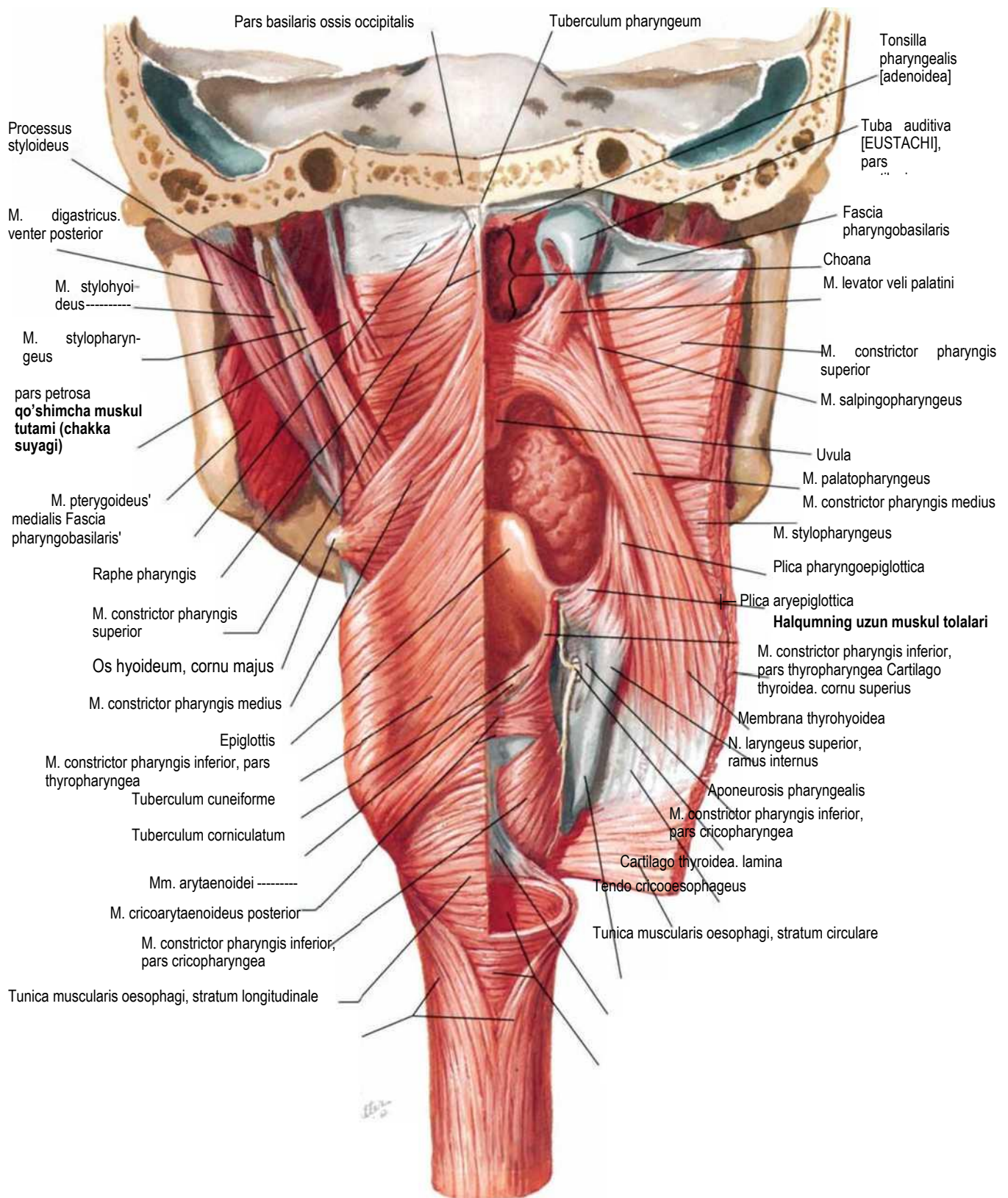


Halqum (ochilgan), orqa tomondan ko'rinishi

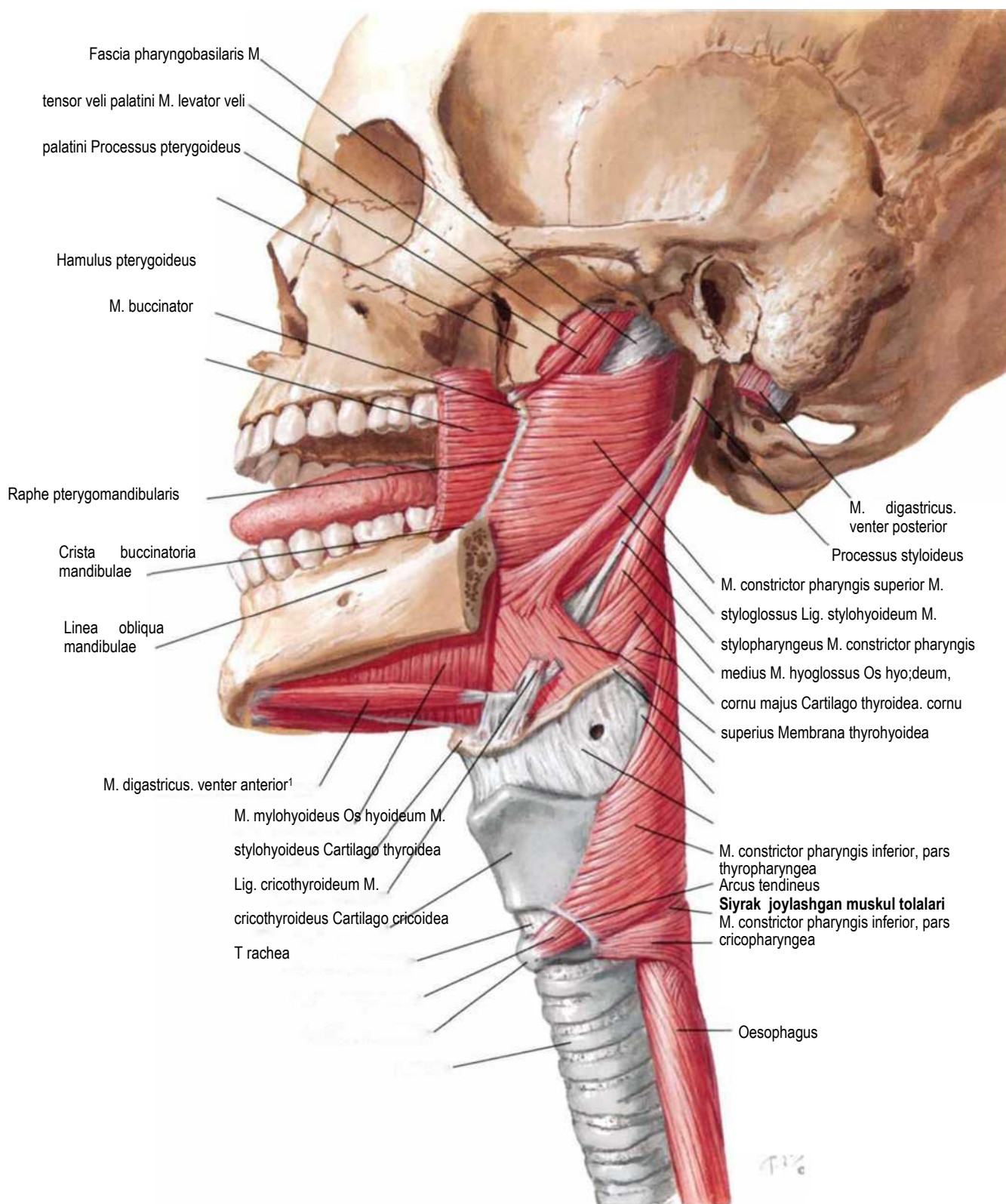


Halqum muskullari: orqa devoir qisman ochilgan

223-rasm

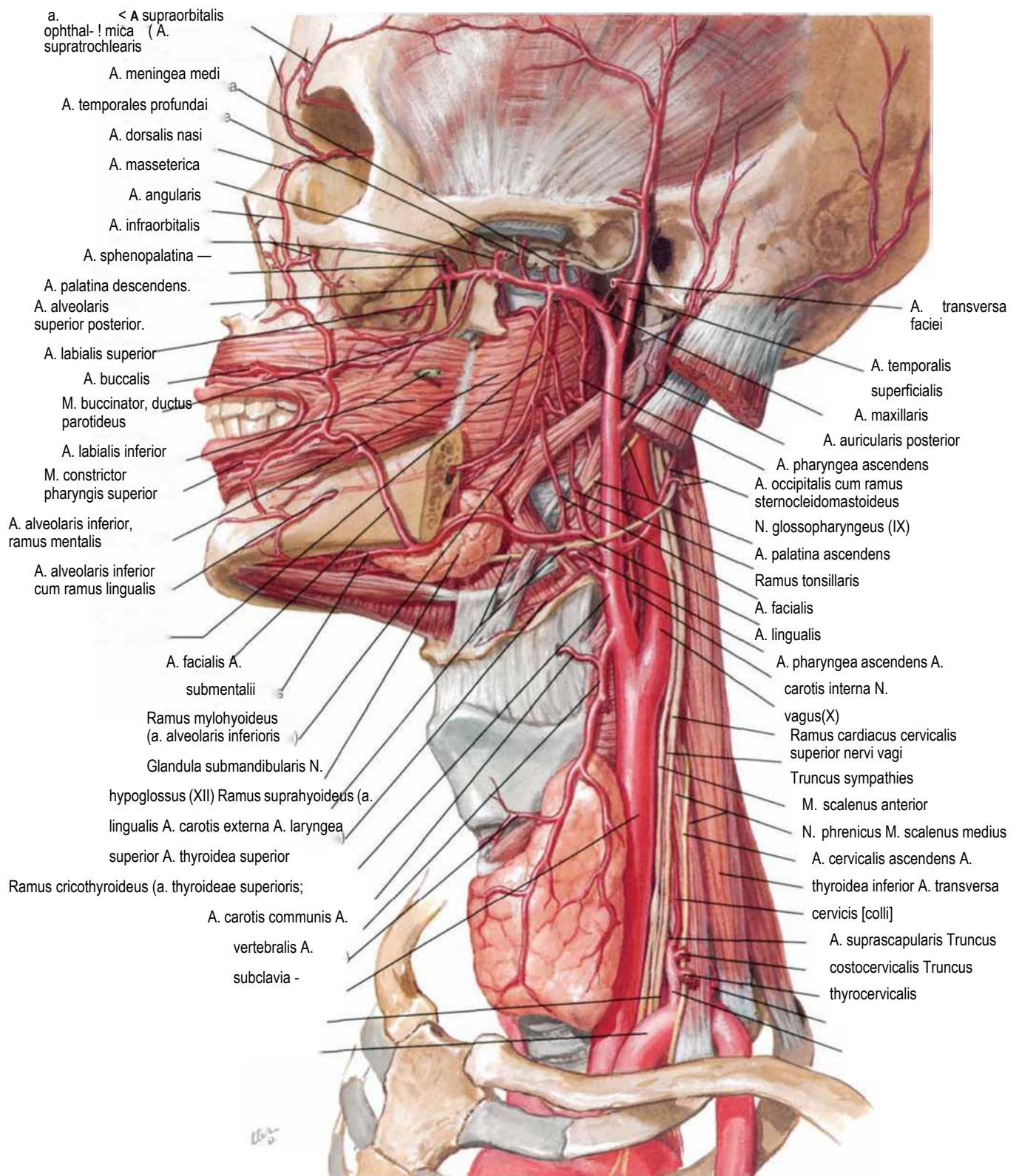


Halqum muskullari: yon tomondan ko'rinishi



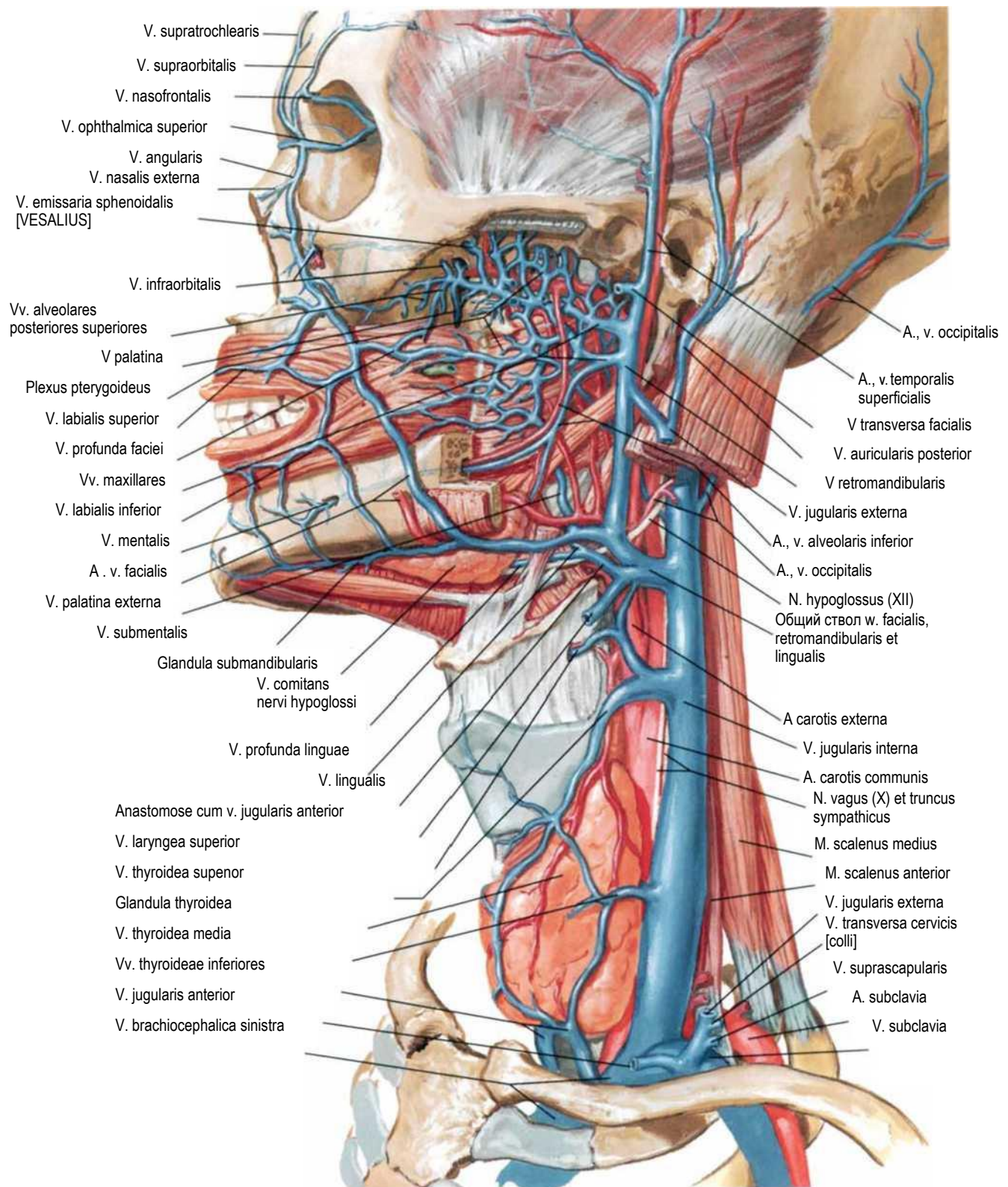
Og'iz bo'shlig'i va halqum arteriyalari

29. 35-rasmlar



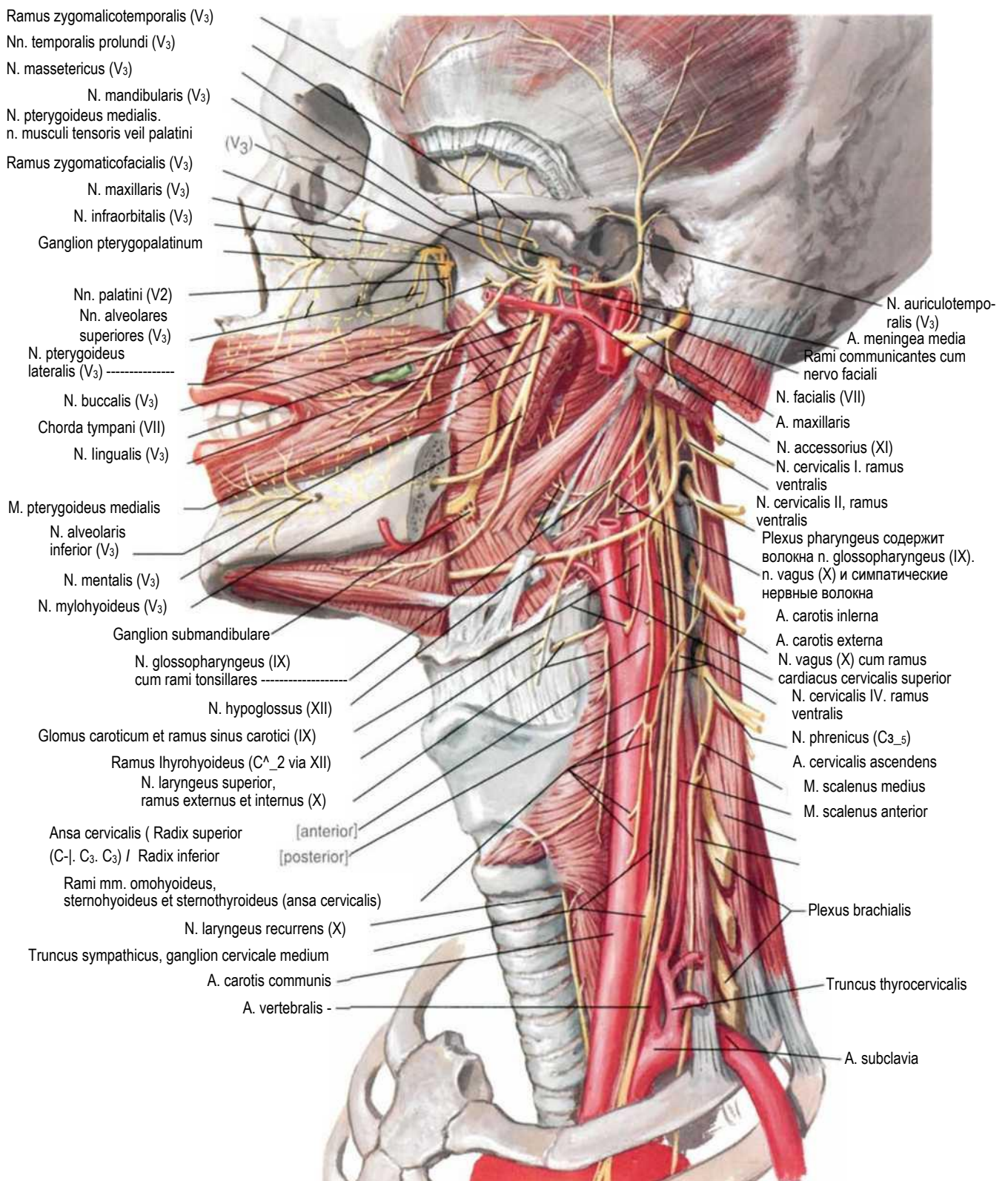
Og'iz bo'shlig'i va halqum venalari

17. 26. 98-rasmlar



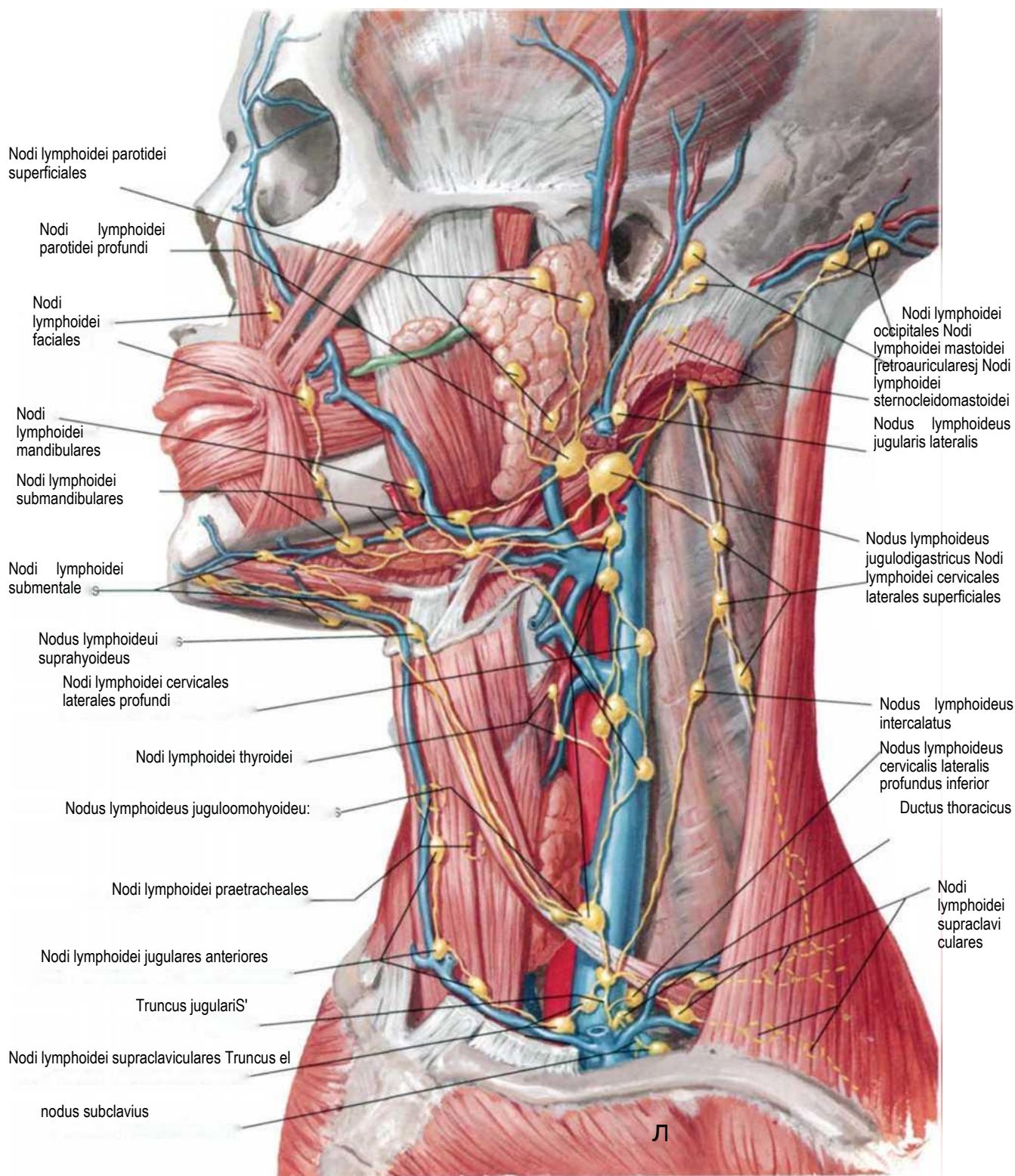
Og'iz bo'shlig'i va halqum nervlari

19. 40. 41. 116. 119. 120-rasmlar.



Bosh va bo'yinning limfatik tomirlari va tugunlari

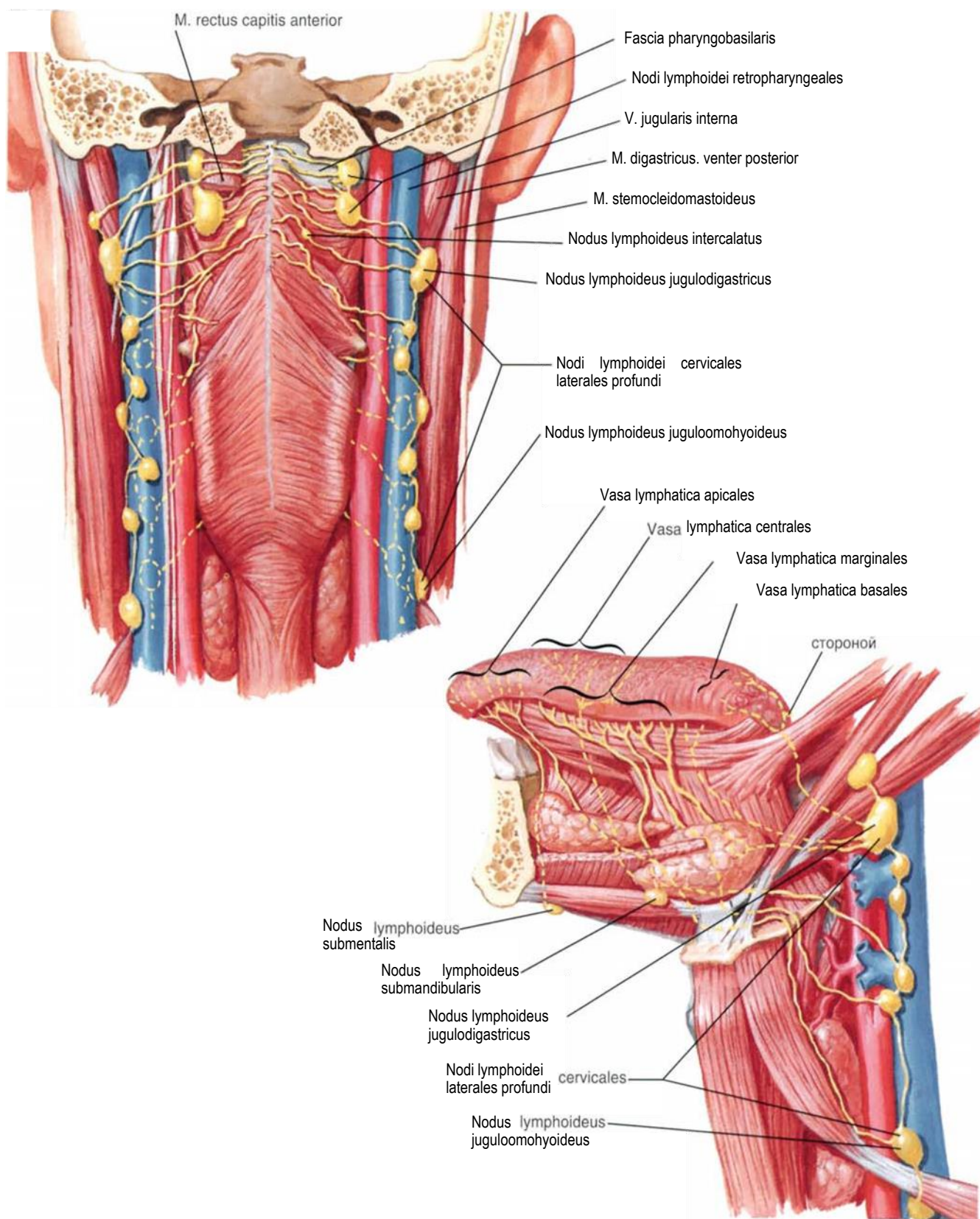
197-rasm.



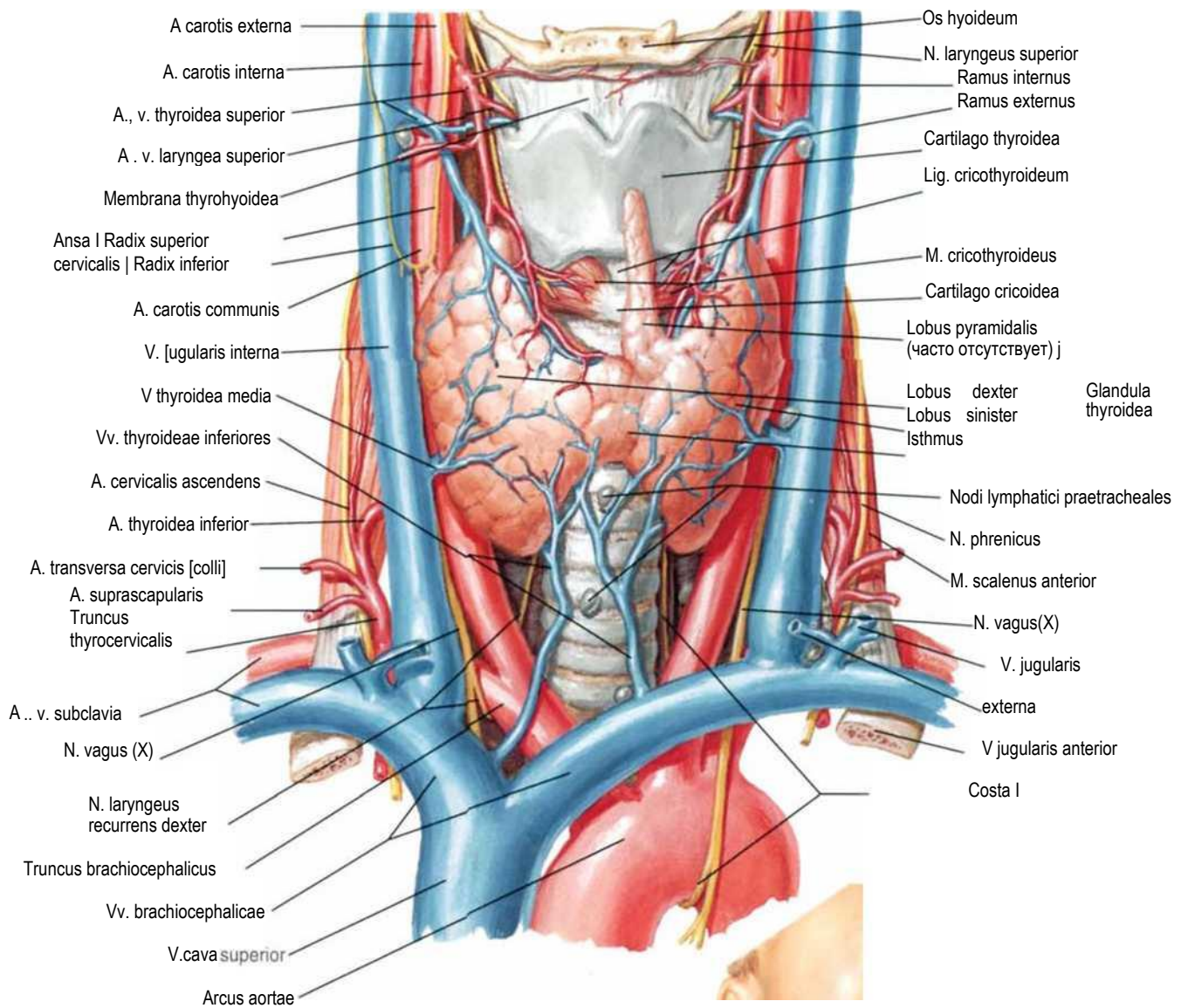
66-rasm

BOSH VA BO'YIN

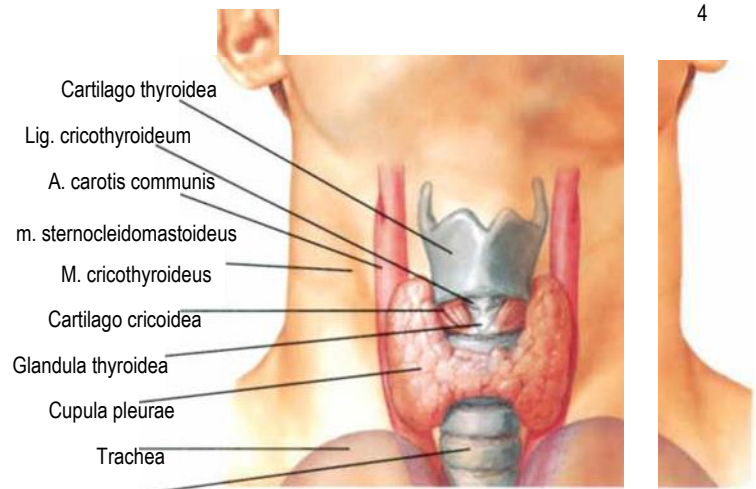
Til va halqumning limfatik tomirlari va tugunlari



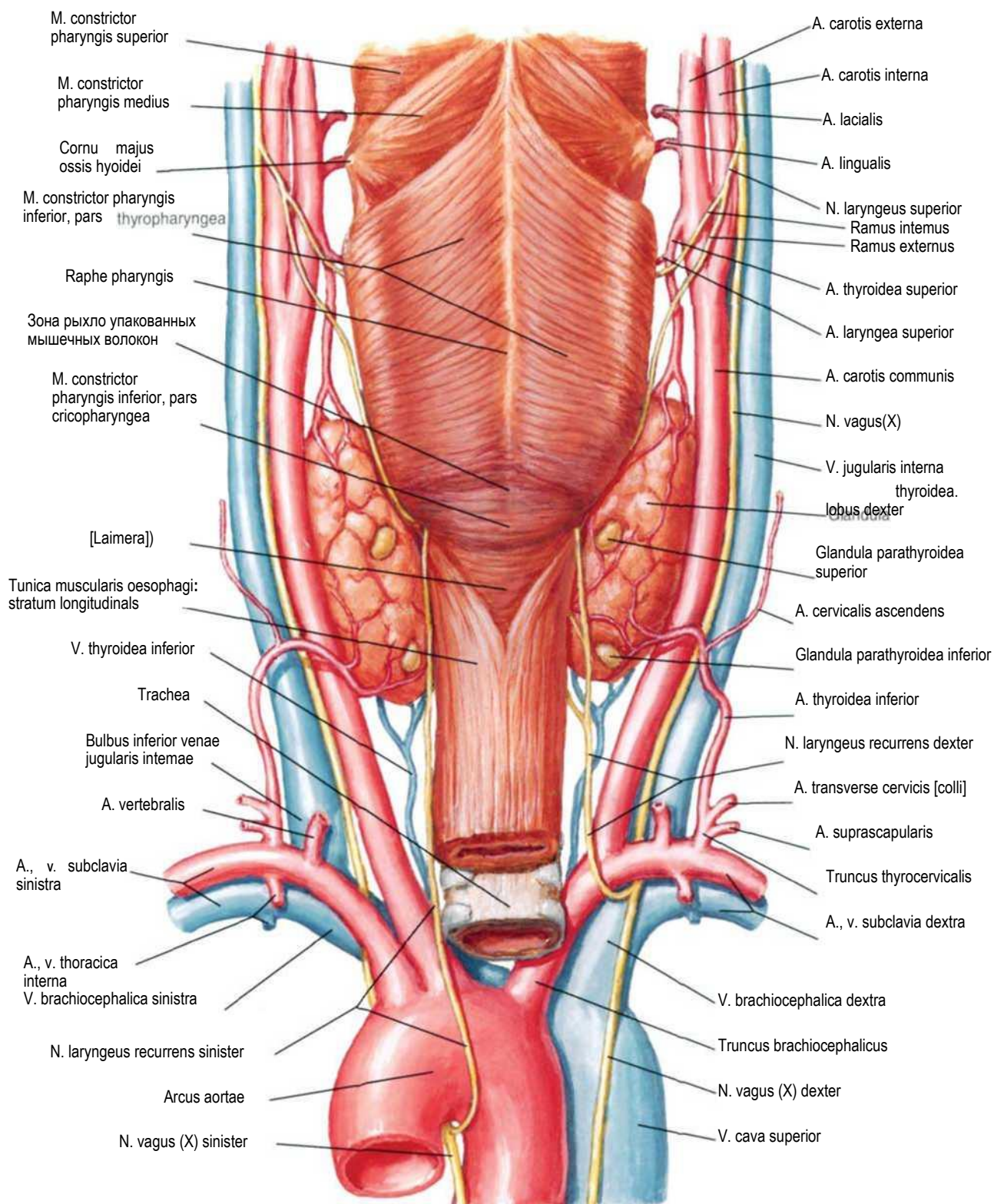
Qalqonsimon bez (glandula thyroidea), oldidan ko'rinishi



Л " IfeM

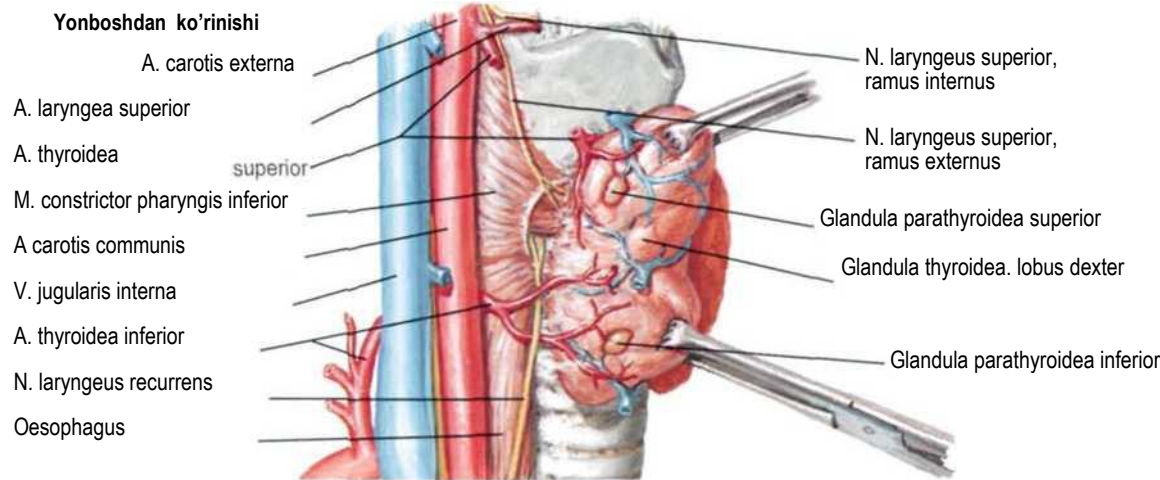
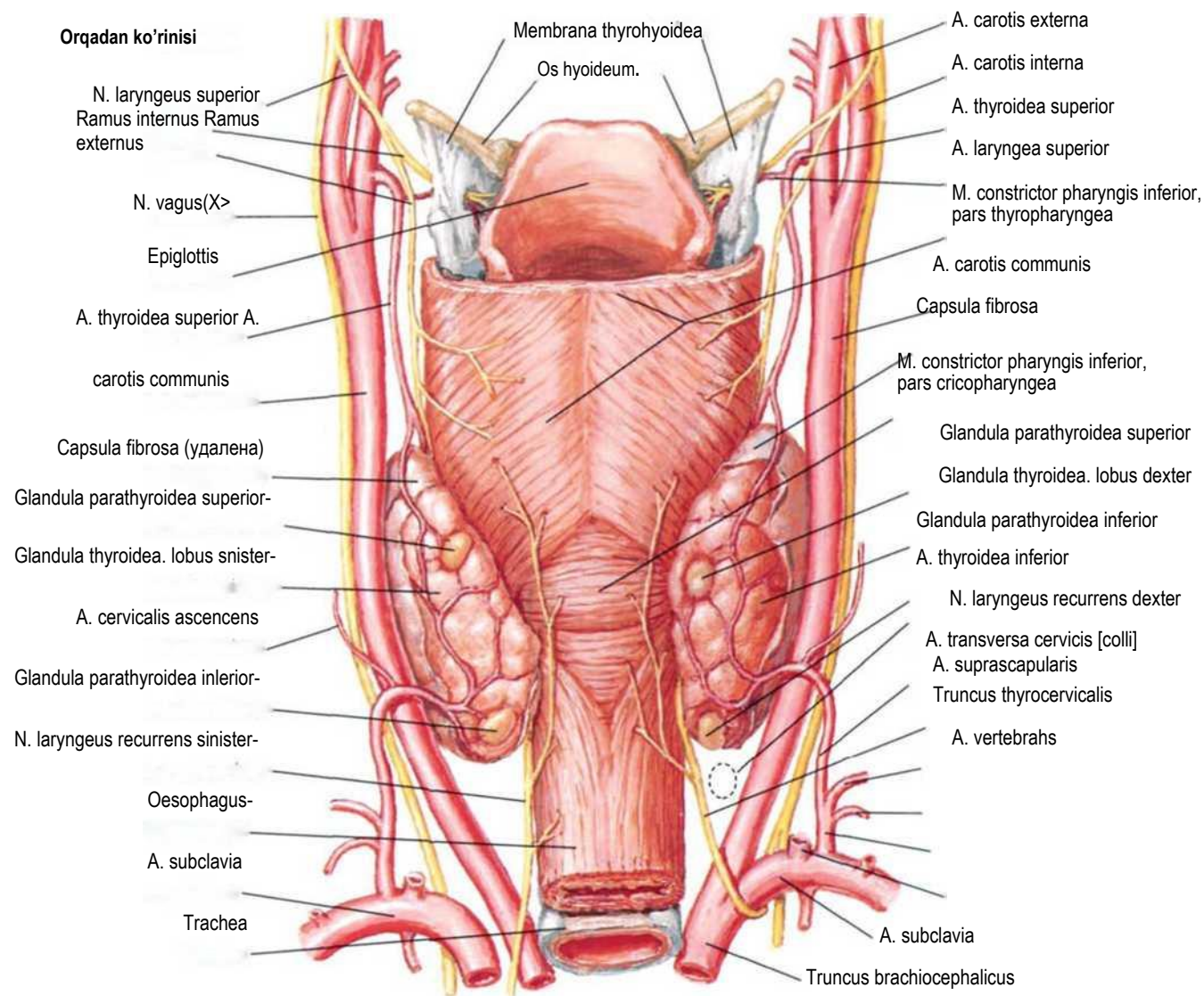


Halqum va qalqonsimon bez: orqadan ko'rinishi



Qalqon oldi bezlari (glandulae parathyroideae)

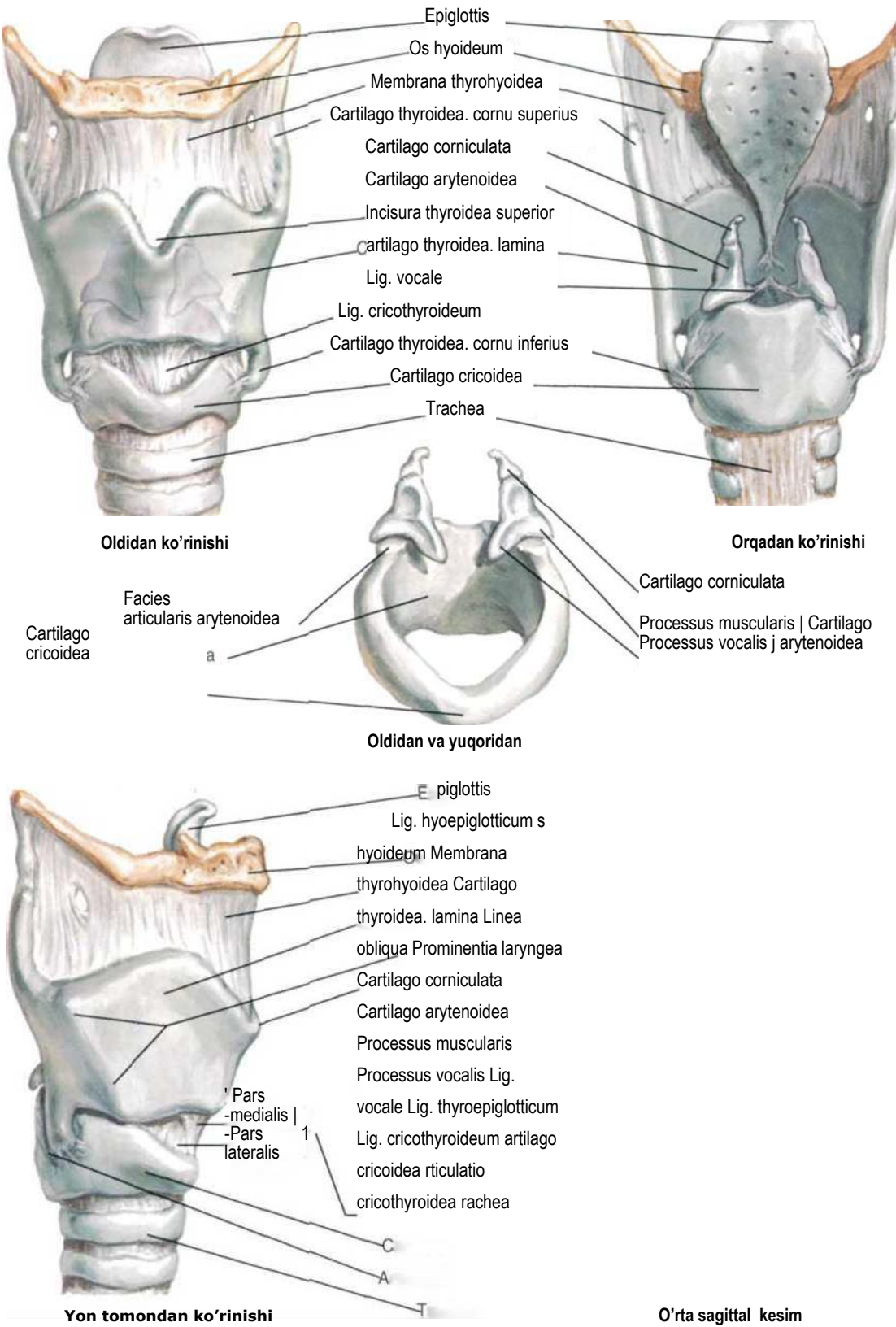
74-rasm.



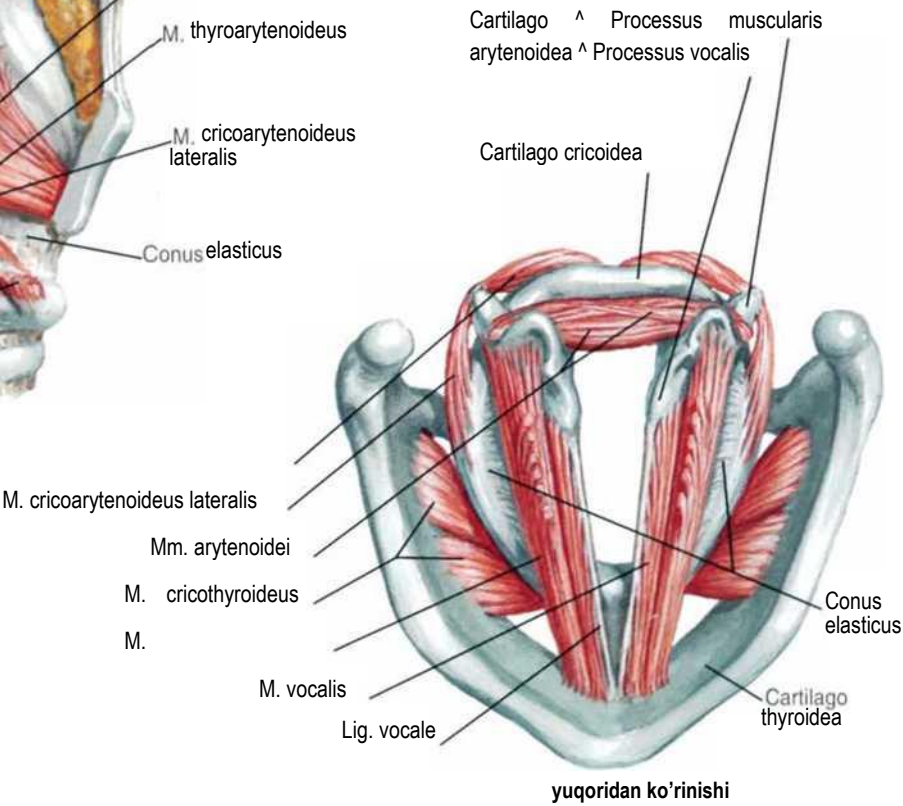
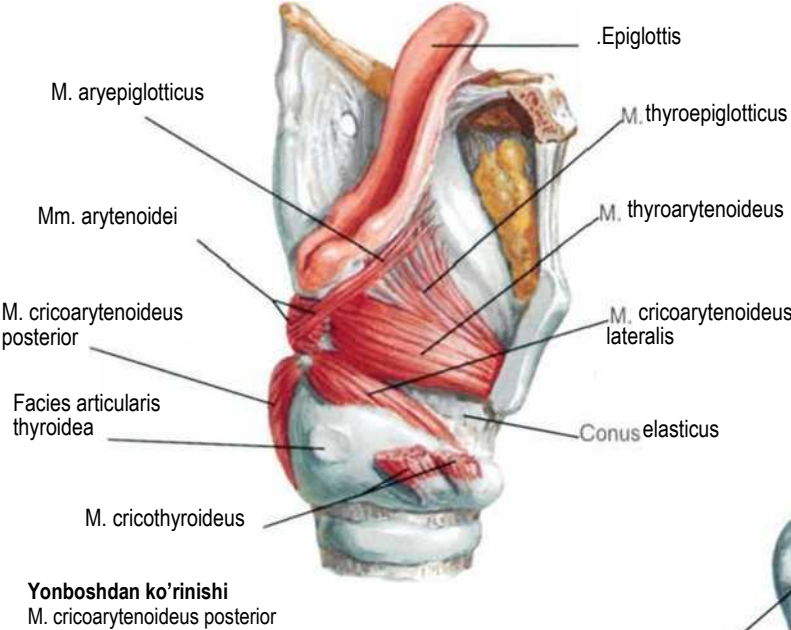
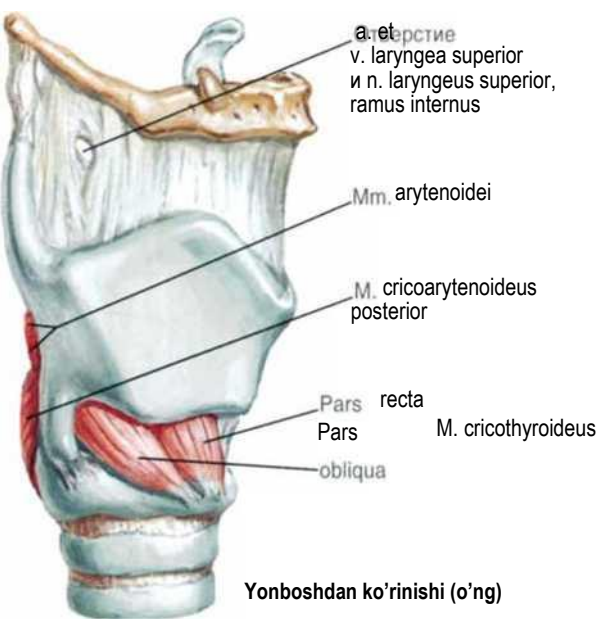
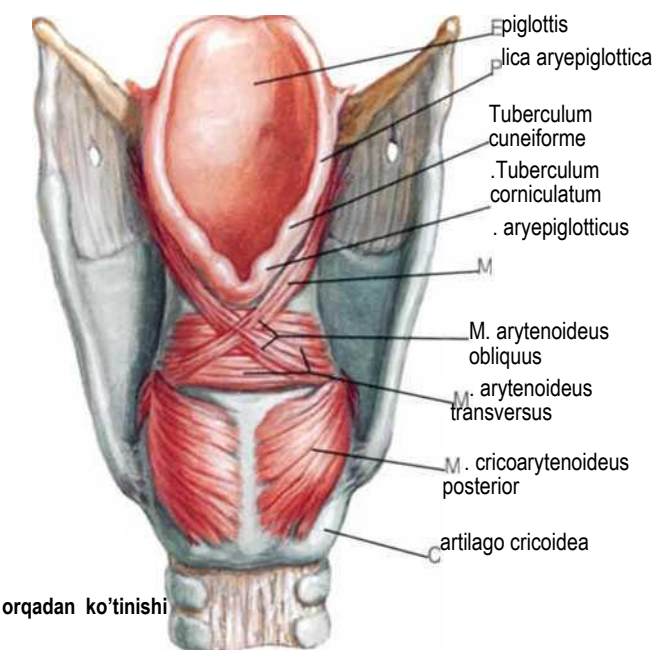
70-rasm

BOSH VA BO'YIN

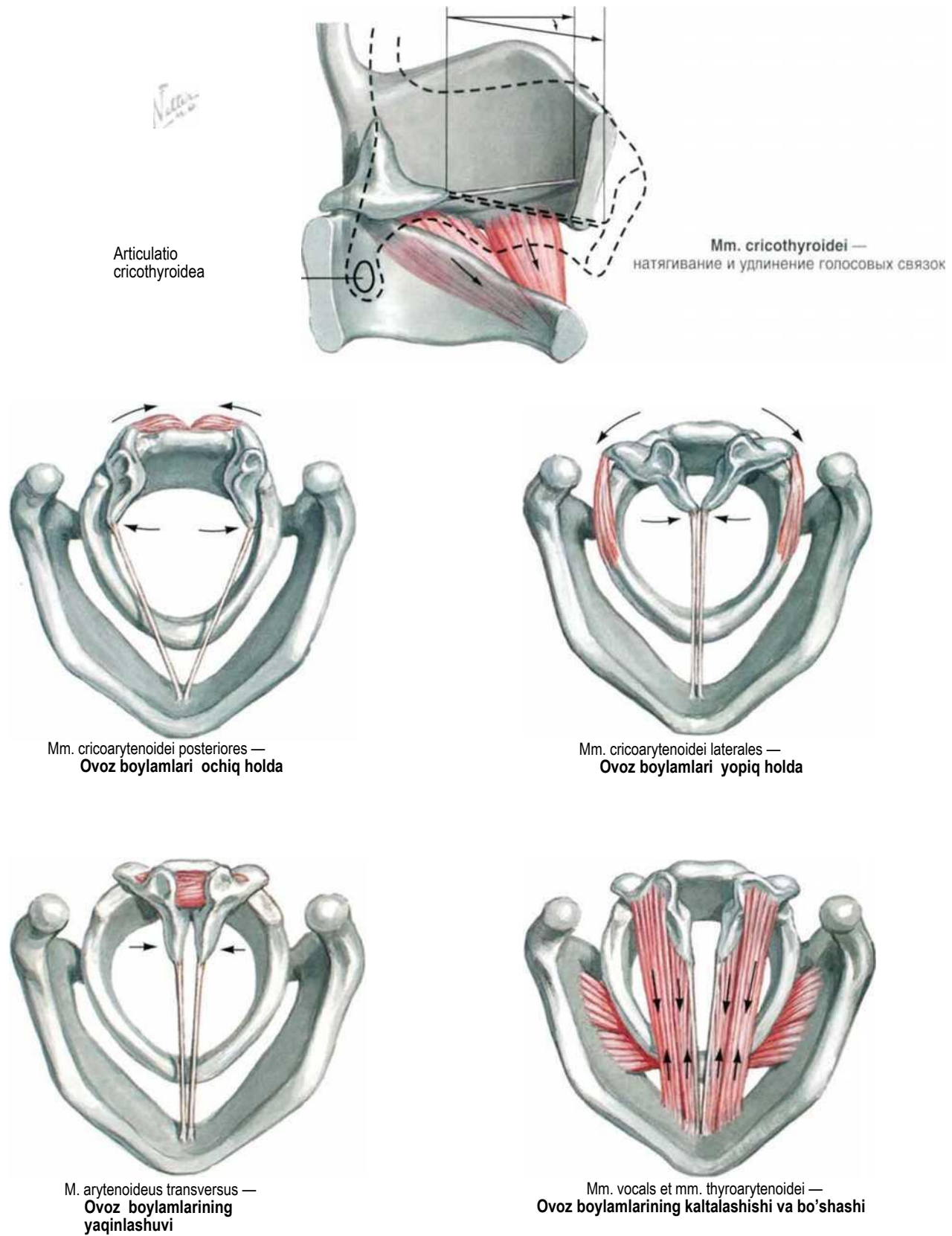
Hiqildoq tog'aylari



Hiqildoq muskullari (musculi larynges)

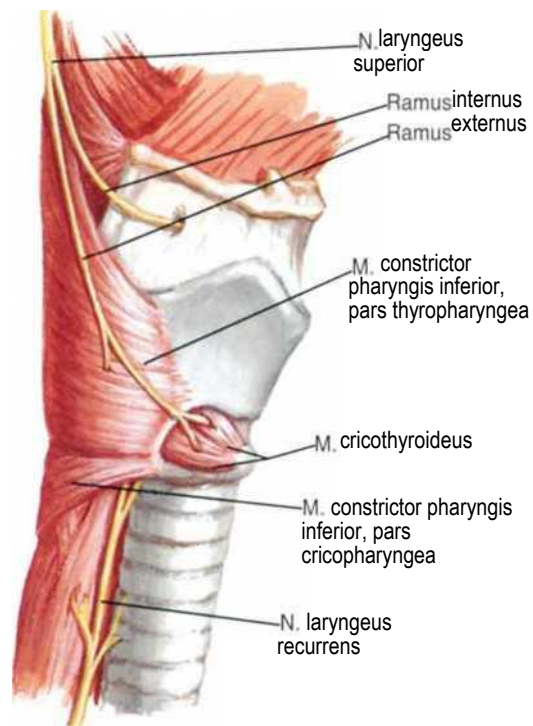


Hiqildoq muskullarining ta'sir etish mexanizmi

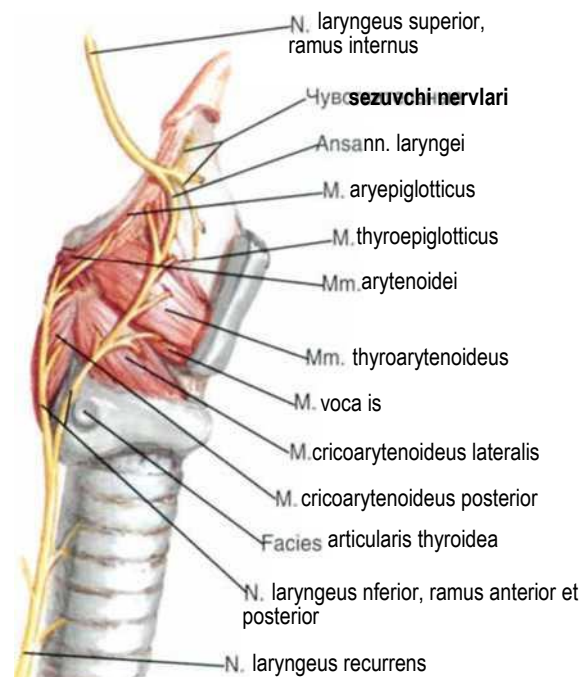


Hiqildoq nervlari

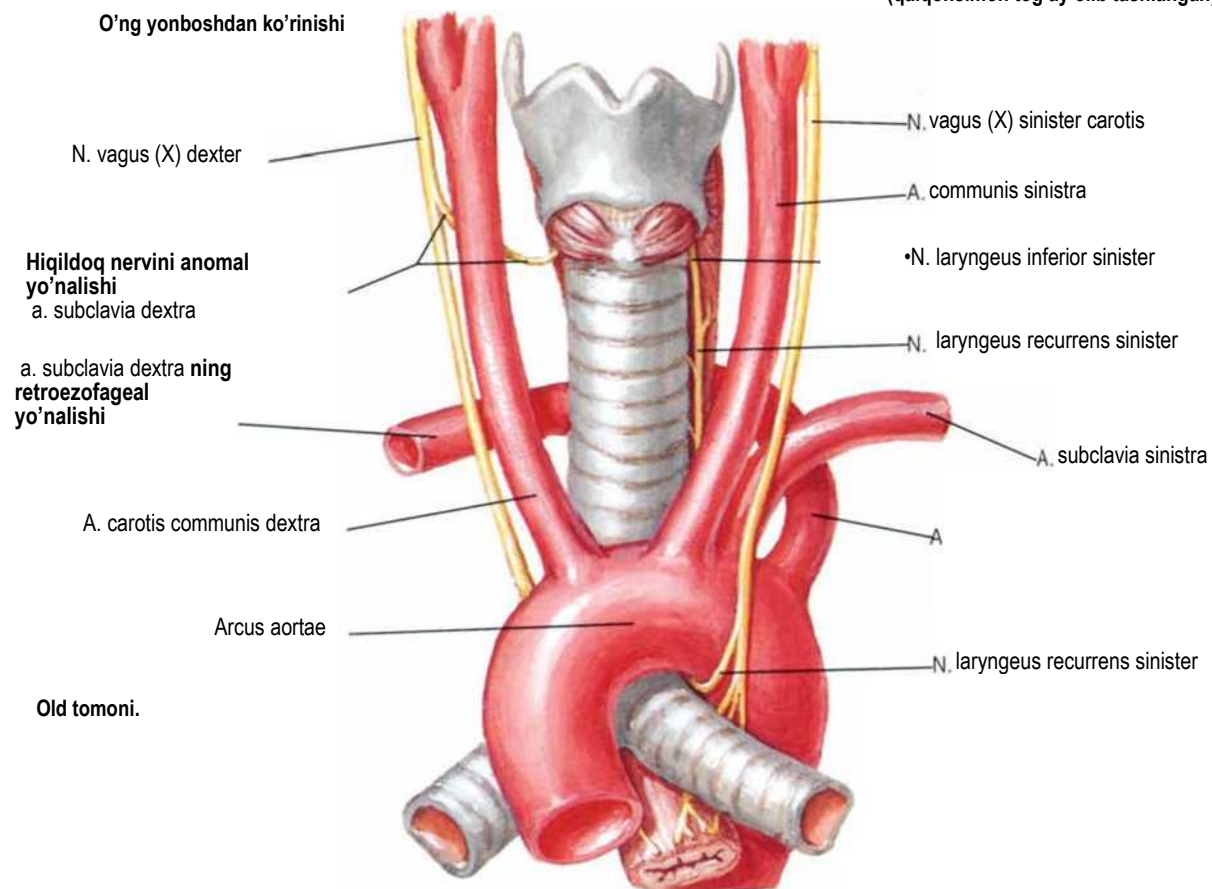
68-70. 223-rasmlar.



O'ng yonboshdan ko'rinishi

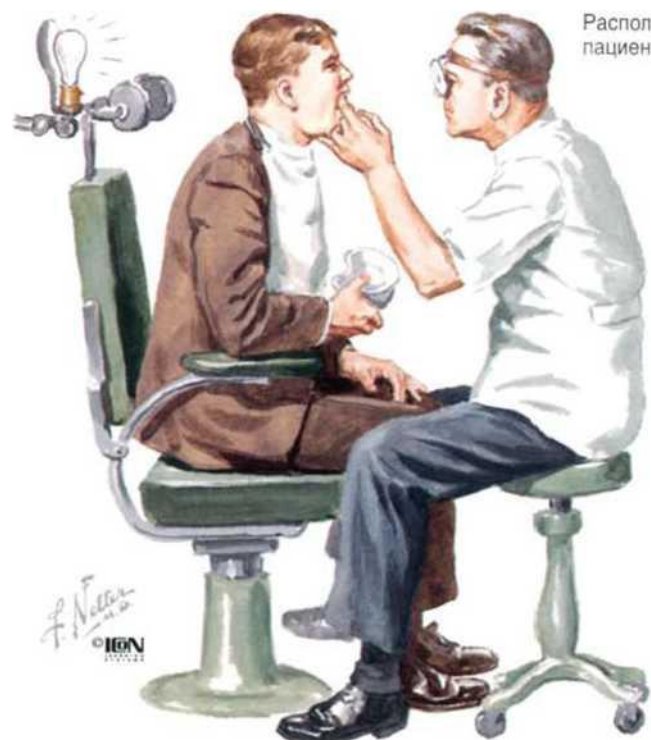


yon tomoni
(qalqonsimon tog'ay olib tashlangan)

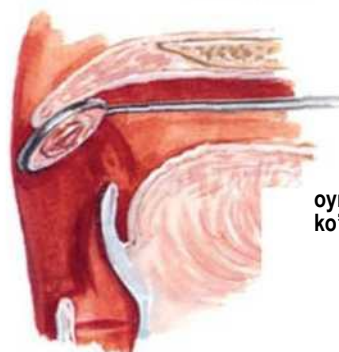
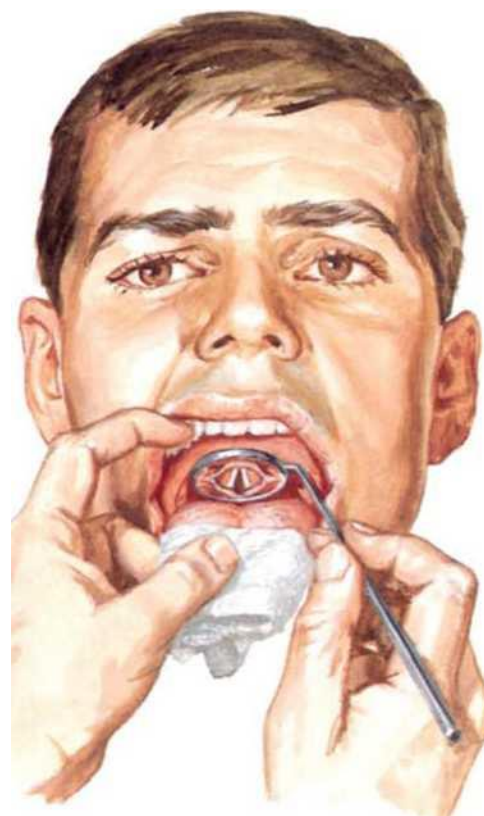


Old tomoni.

Hiqildoqni tekshirish

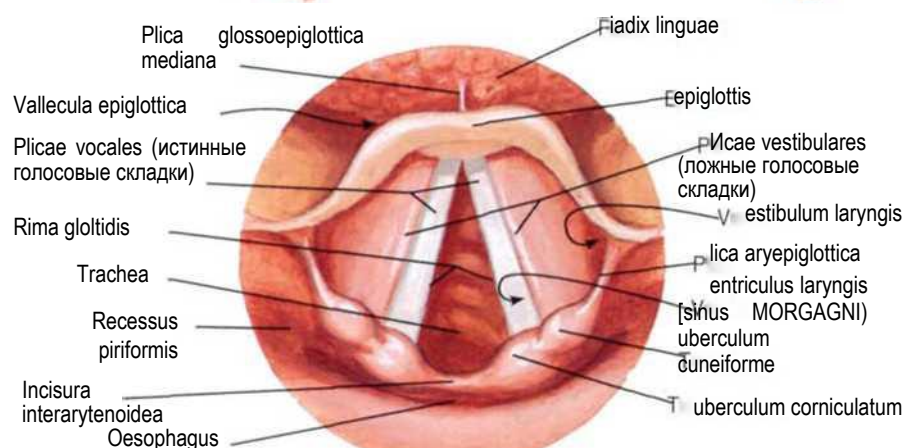


Spirтли olovda oyna isitiladi

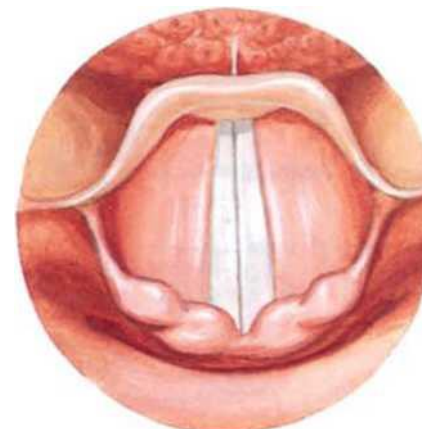


texnikasi

oyna bilan til ko'tariladi



Normal hiqildoq: nafas olish

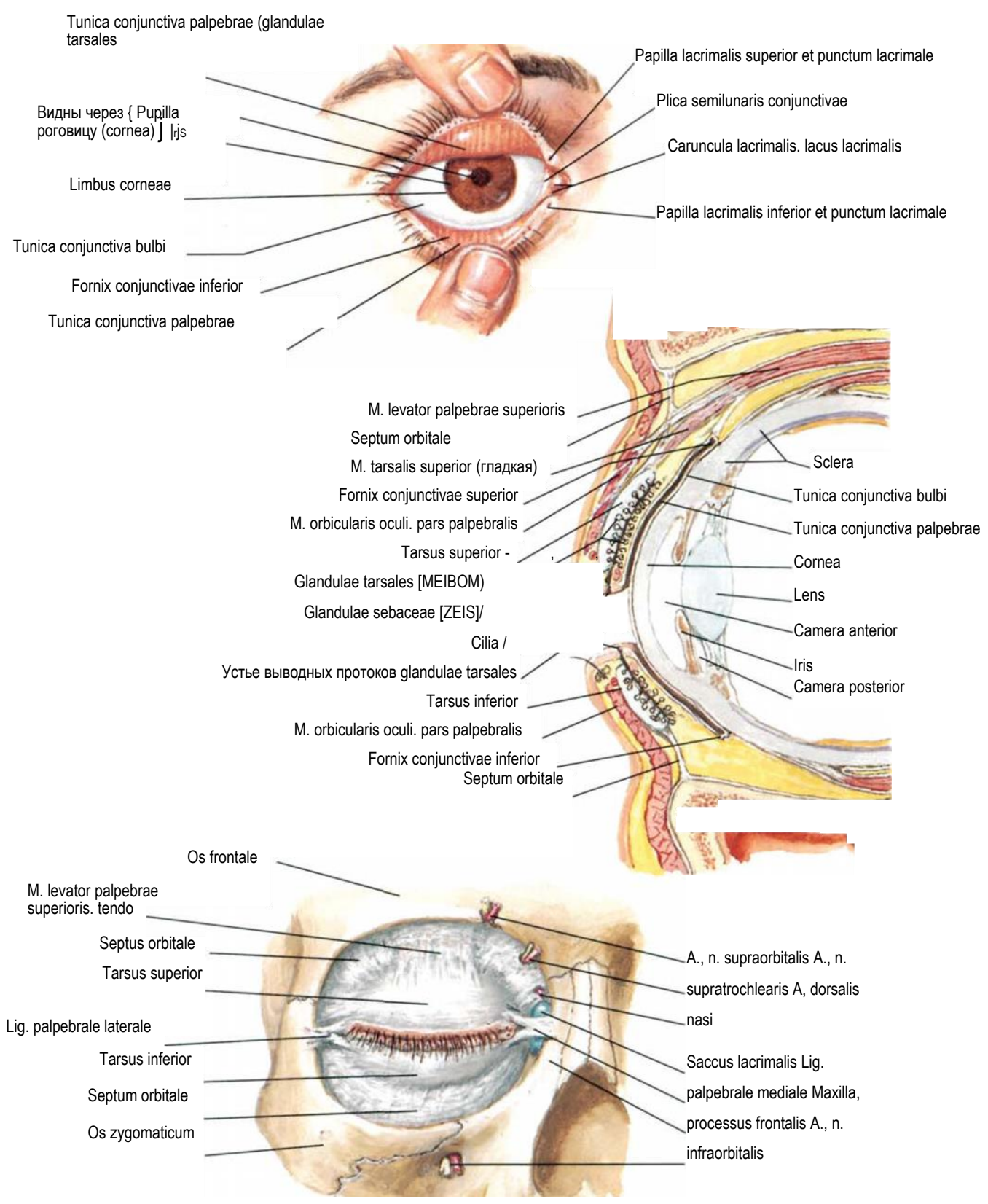


Normal hiqildoq: ovoz hosil bo'lishi

Qalqonsimon bez va hiqildoq

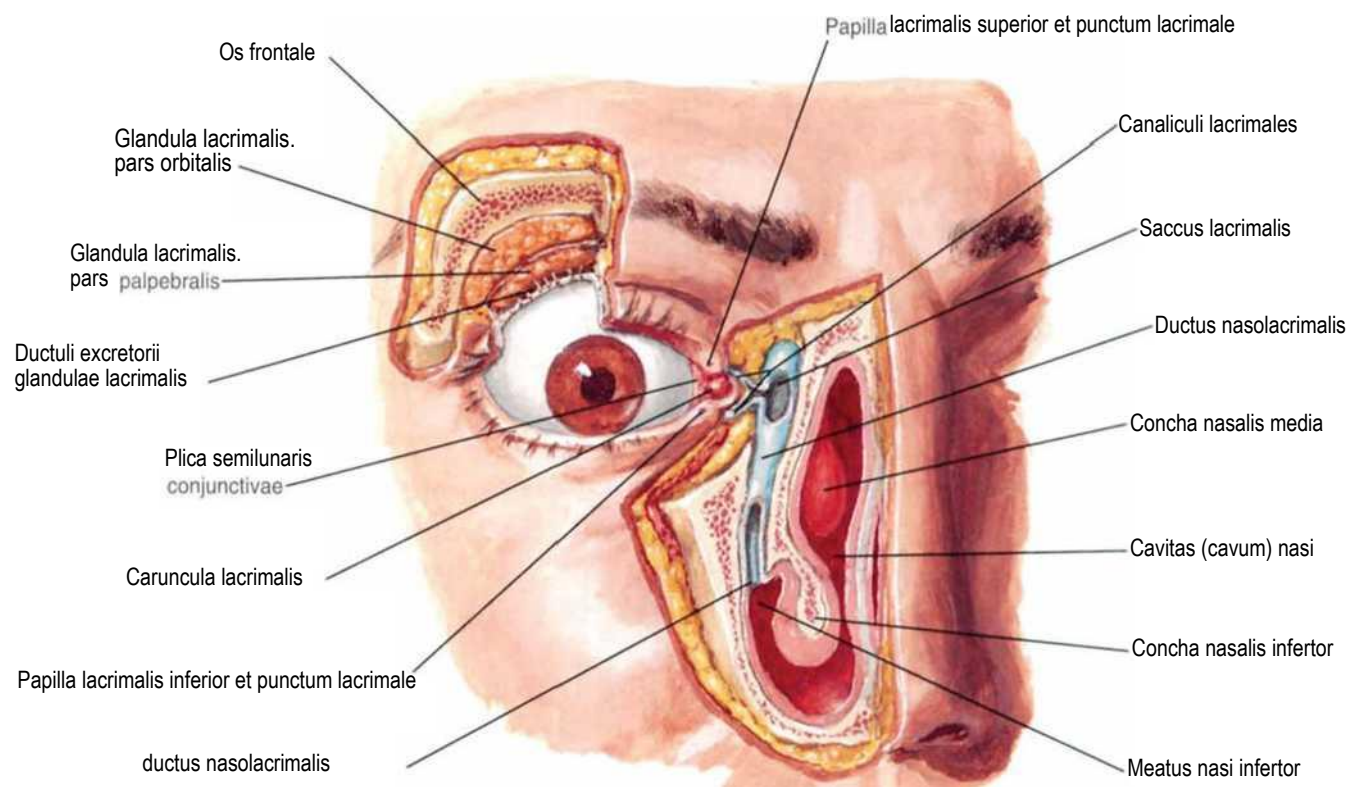
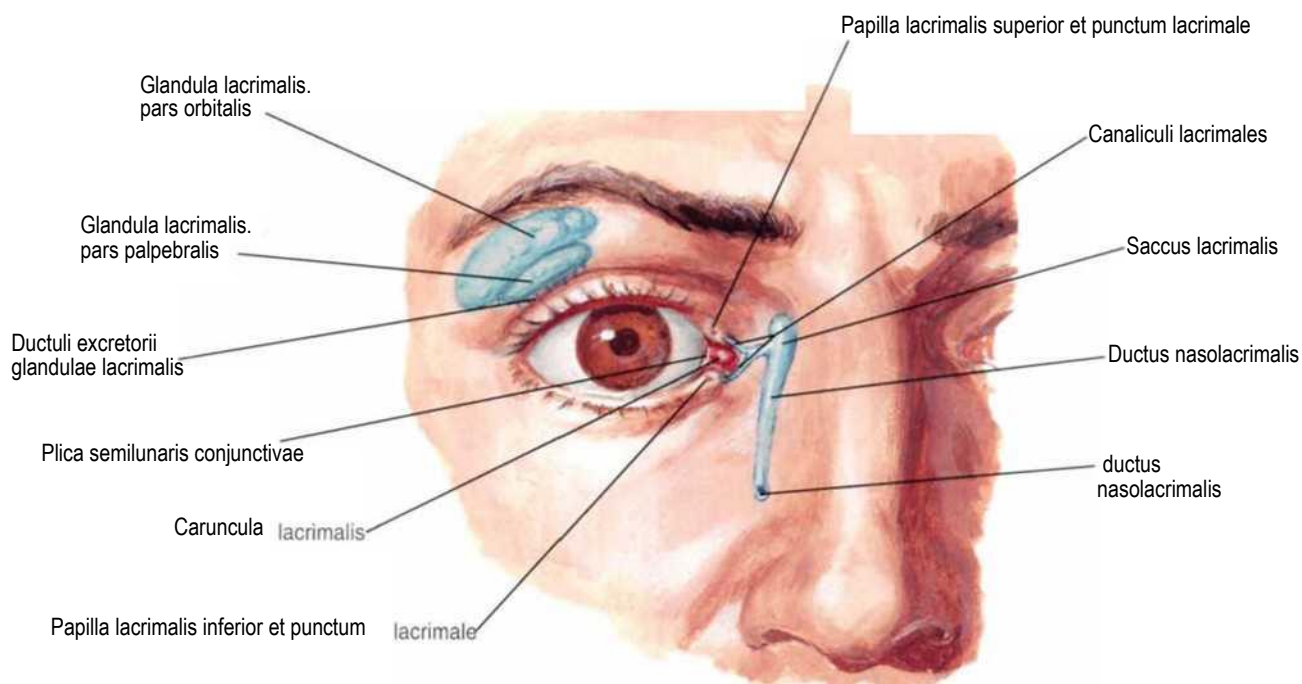
75-rasm

Qovoqlar (palpebrae)



Ko'z yoshi apparati (apparatus lacrimalis)

40. 127-rasmlar.

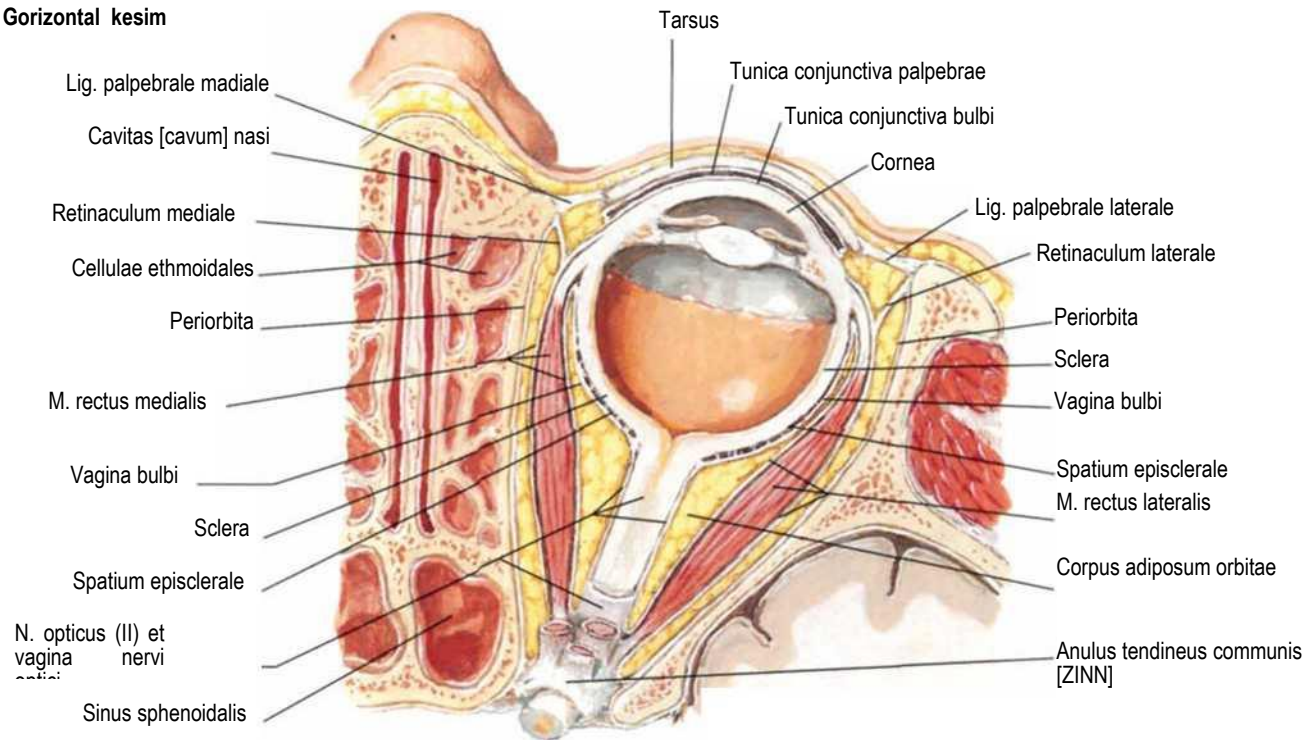


Ko'z kosasi tarkibi

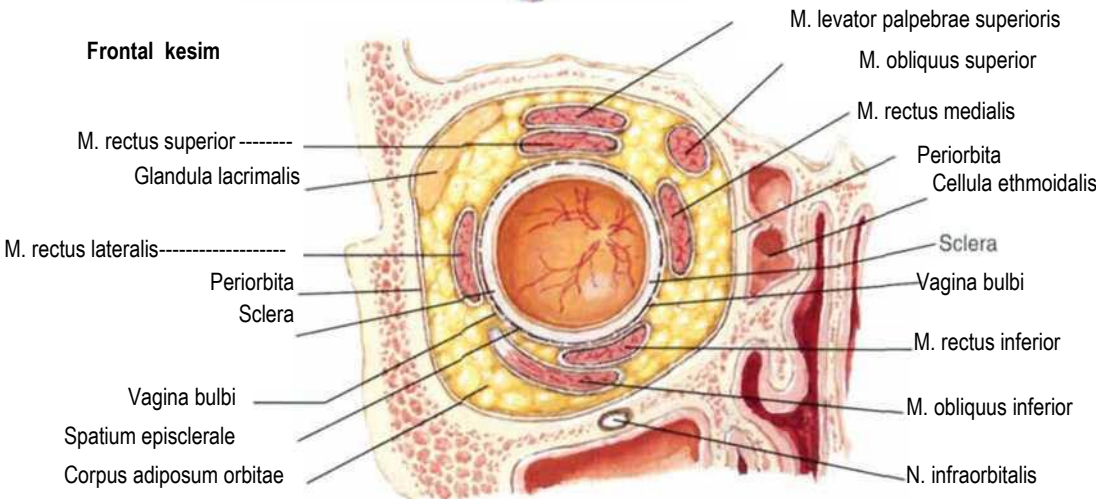
77-rasm

Ko'z kosasi (orbita): ko'zning tarkibi

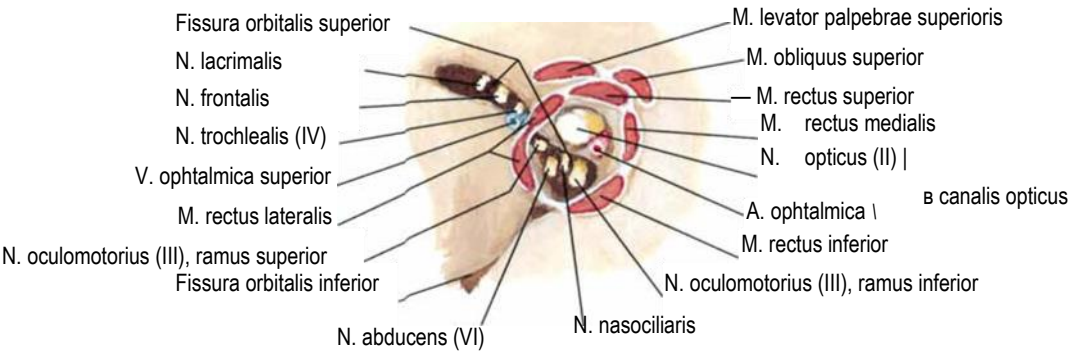
Gorizantal kesim



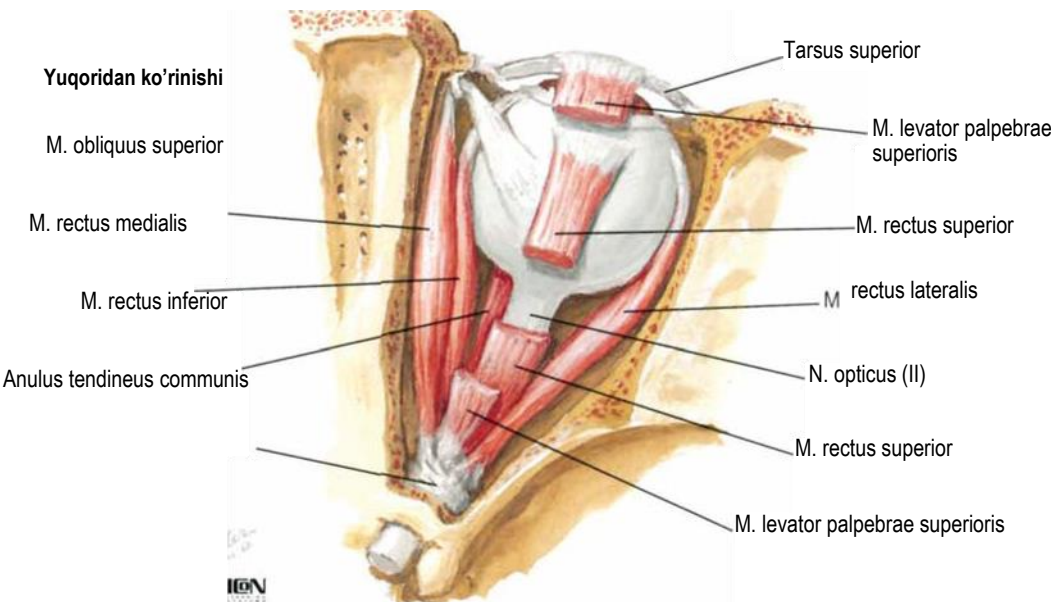
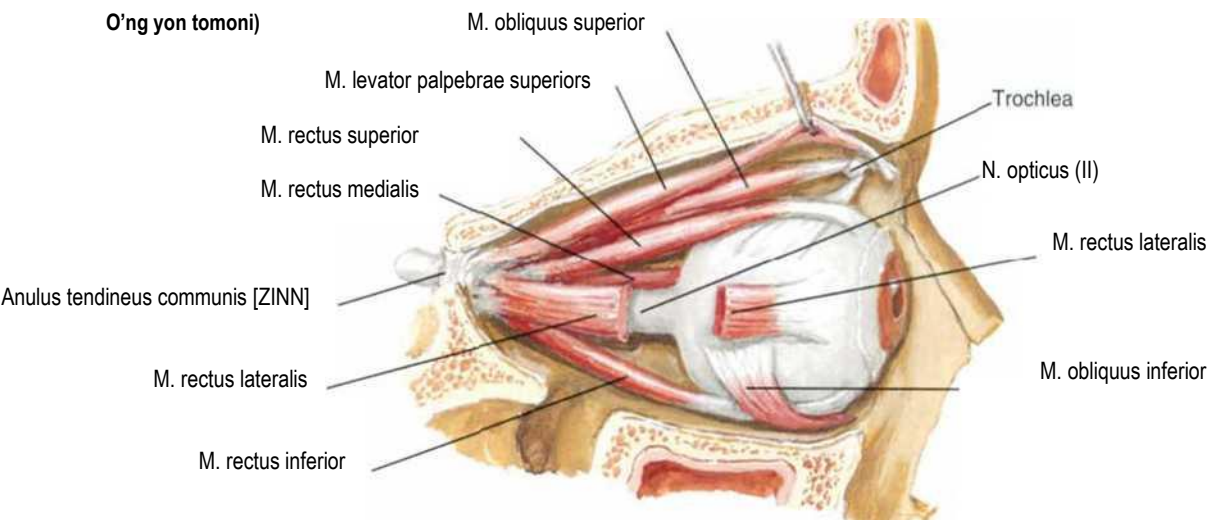
Frontal kesim



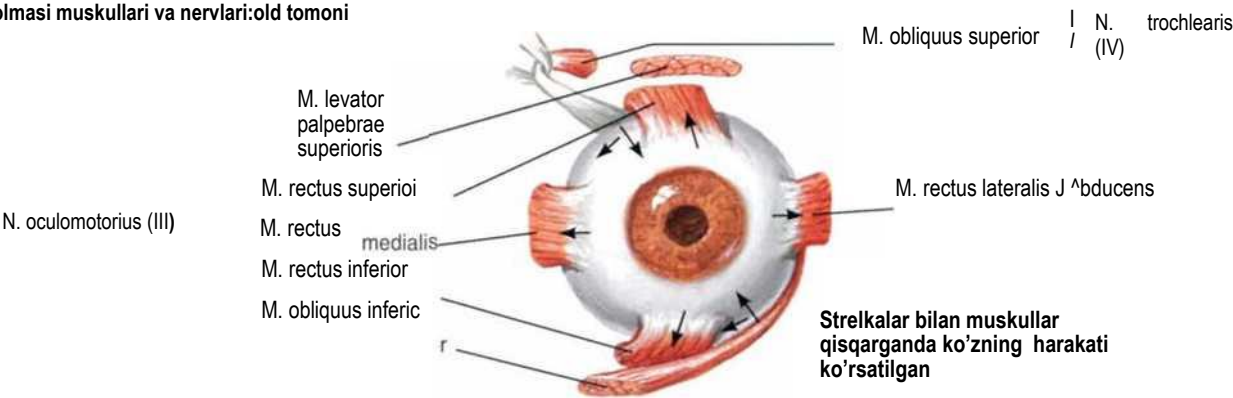
Ko'z kosasi qon-tomir,nervlari va muskullarining joylashishi



Ko'z olmasining muskullari (musculi bulbi)

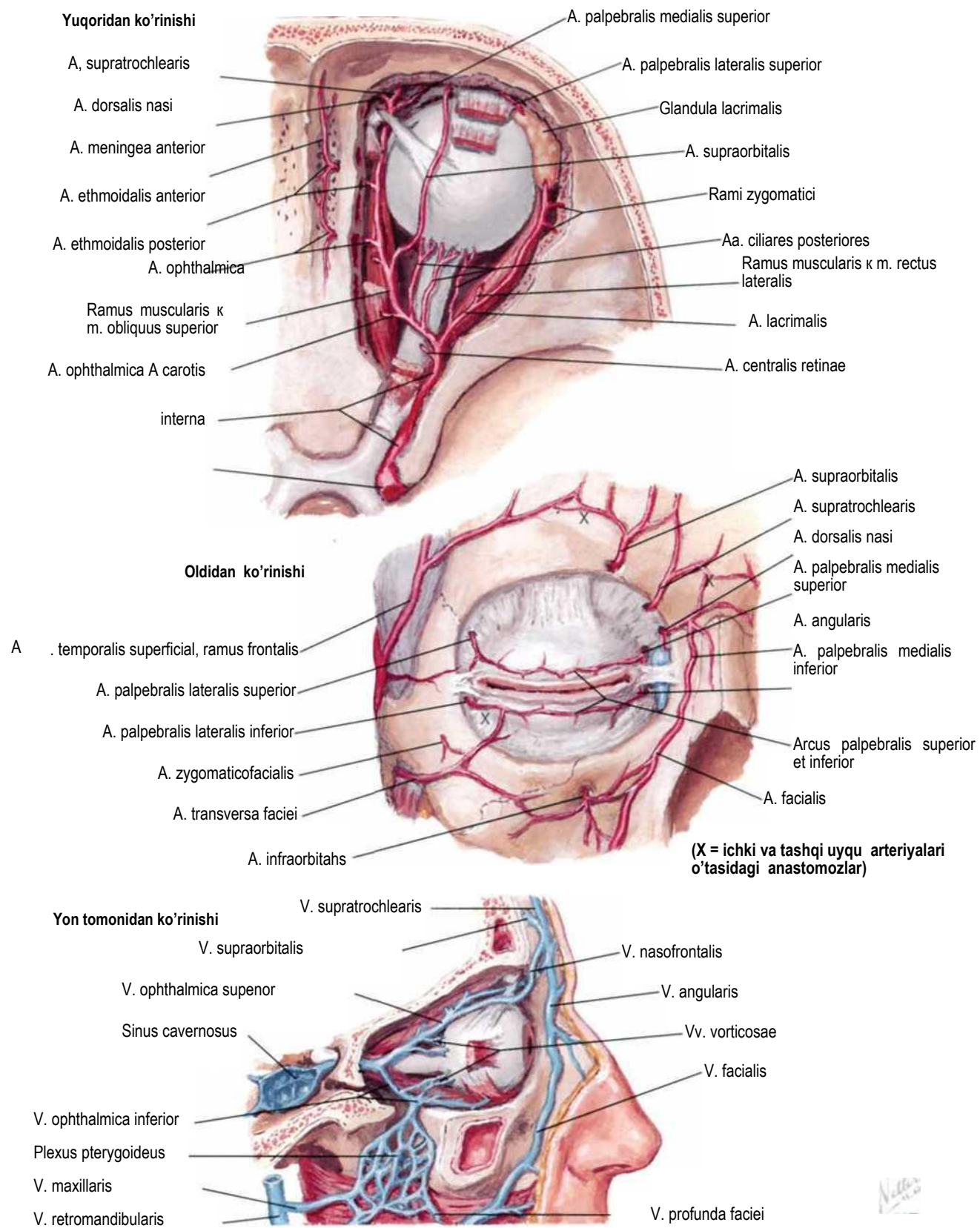


Ko'z olmasi muskullari va nervlari:old tomoni



Ko'z olmasi va ko'z kosasining arteriya va venalari

17. 98-rasmlar.



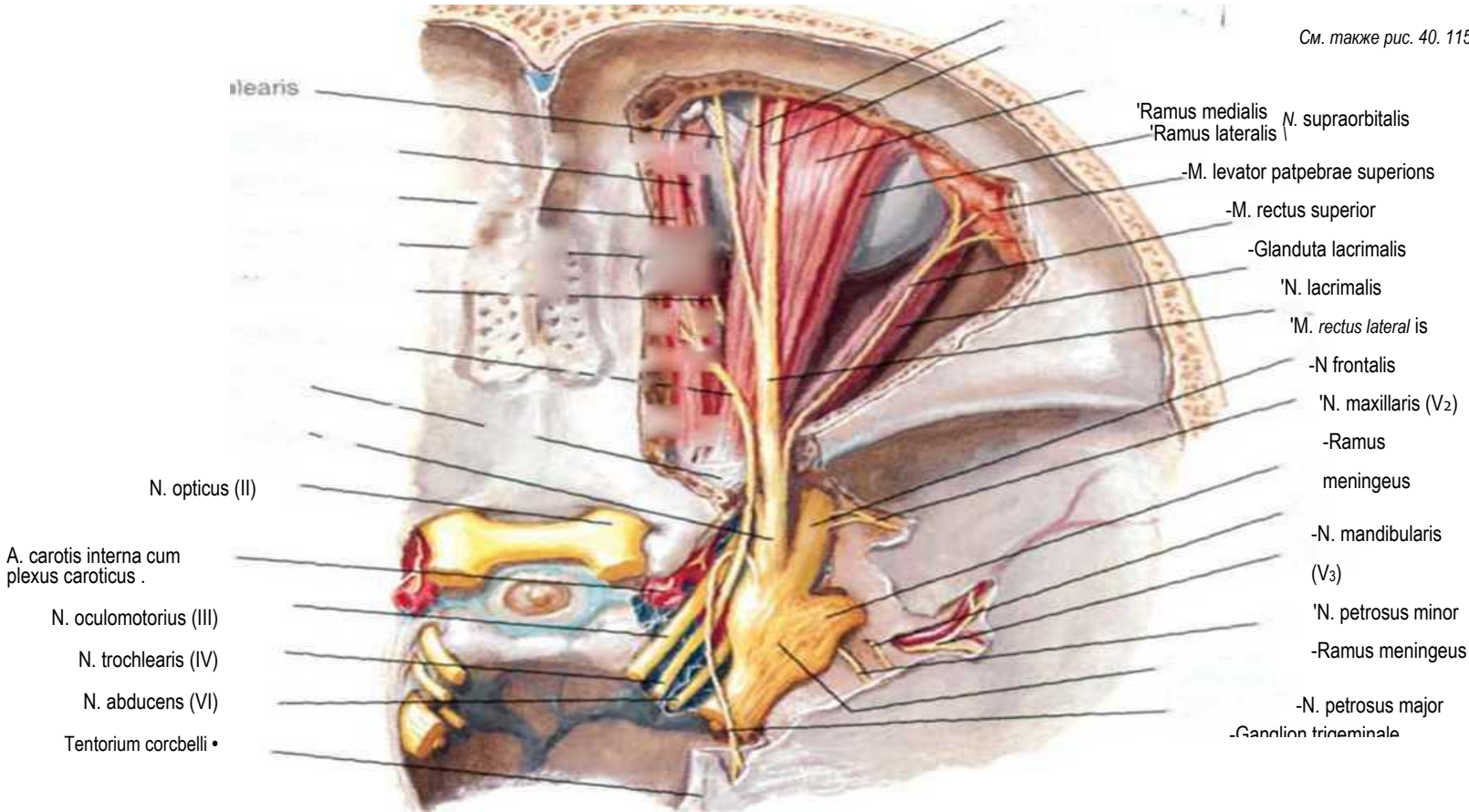
80-rasm

BOSH VA BO'YIN

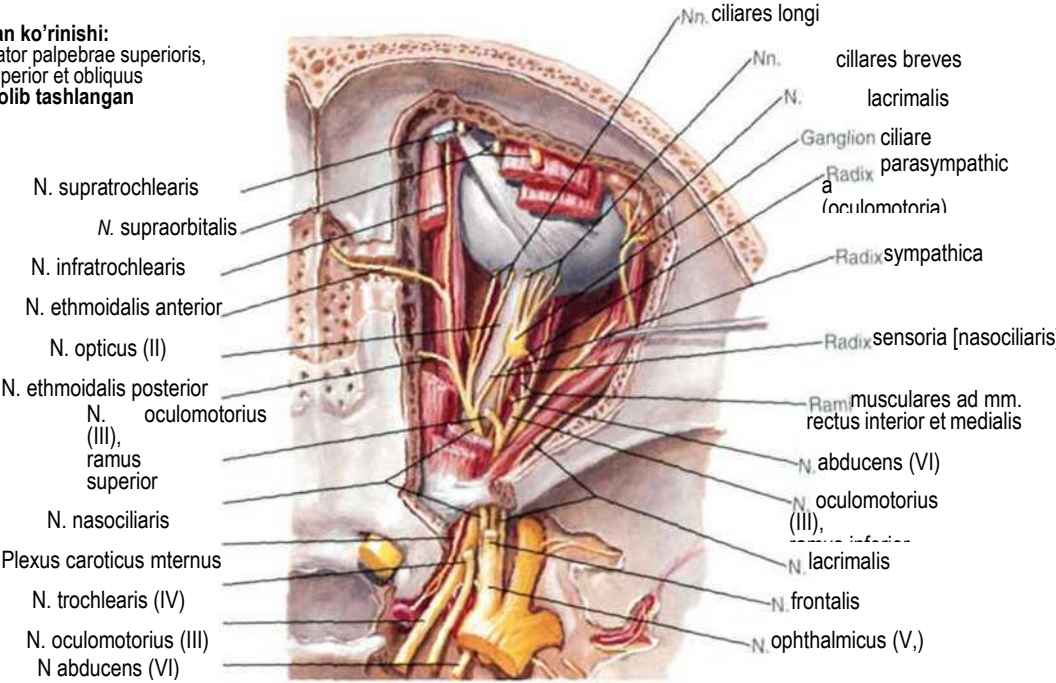
Yuqoridan ko'rinishi

ервы глазниц,

См. также рис. 40. 115. 126



yuqoridan ko'rinishi:
mm. levator palpebrae superioris,
rectus superior et obliquus
superior olib tashlangan

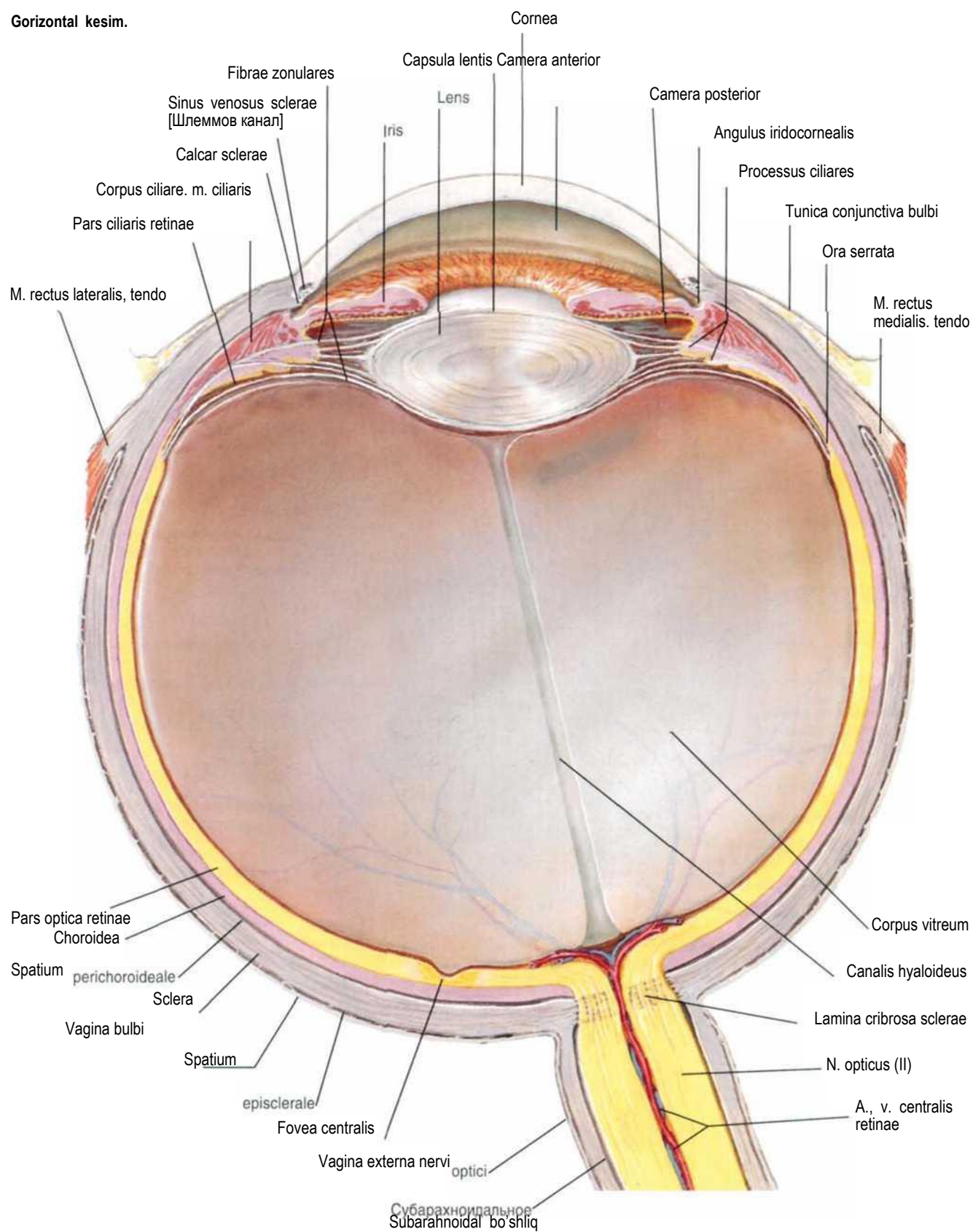


IBM

KO'ZNING TARKIBI

Ko'z olmasi (bulbus oculi)

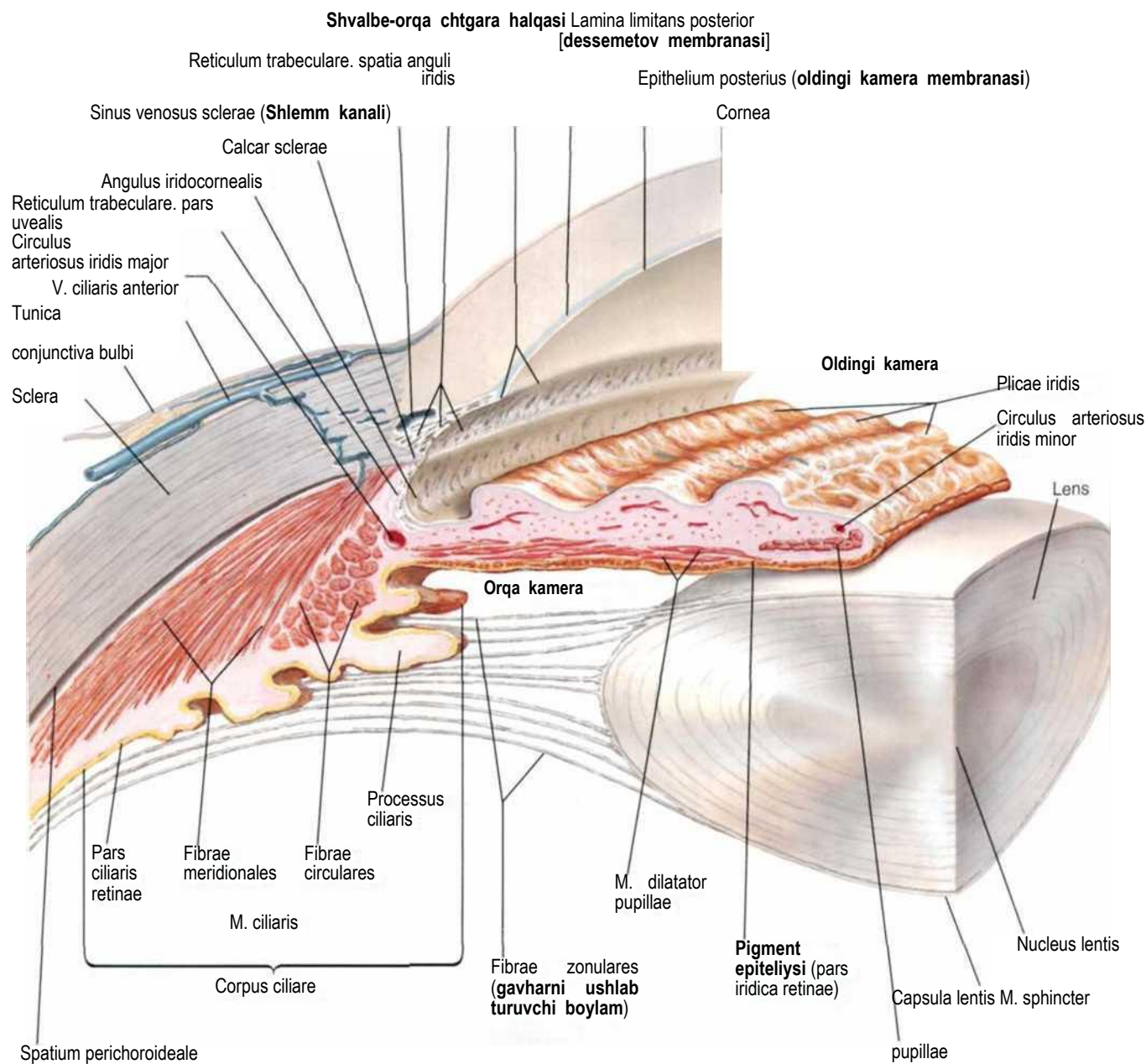
Gorizantal kesim.



82-rasm

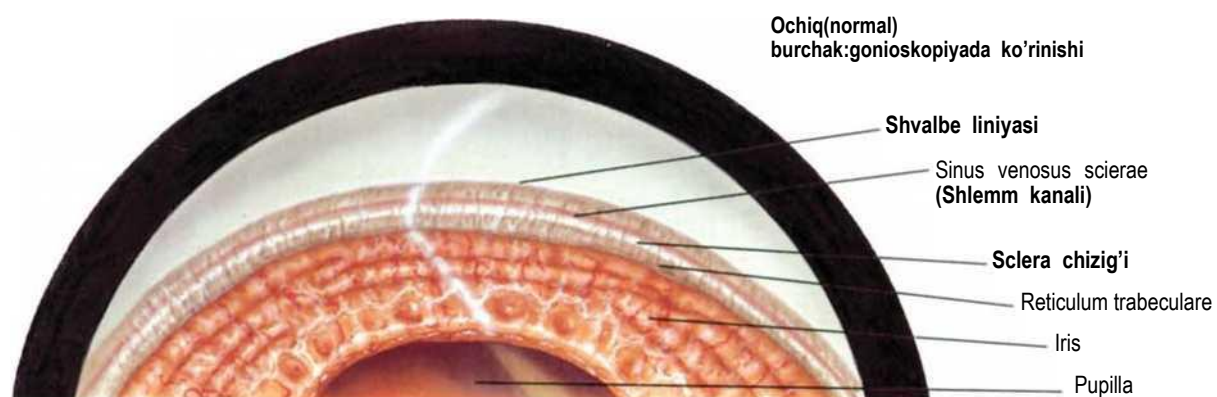
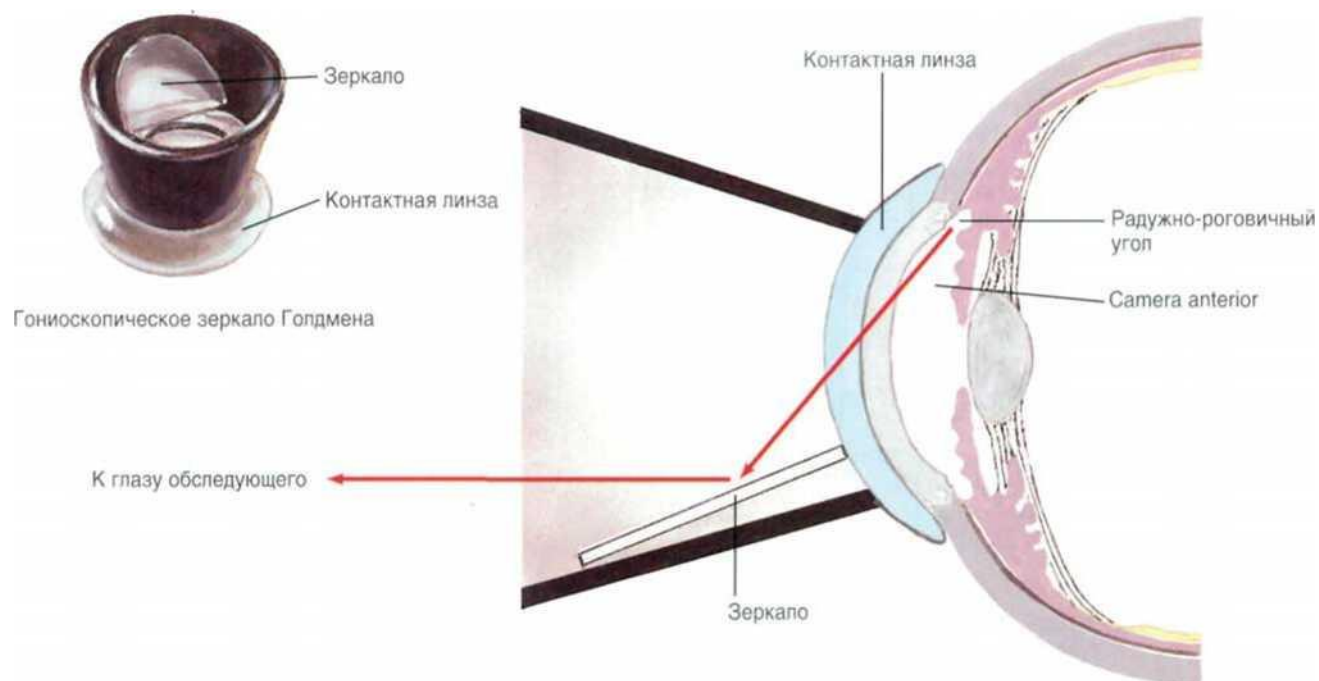
BOSH VA BO'YIN

Ko'zning oldingi va orqa kameralari

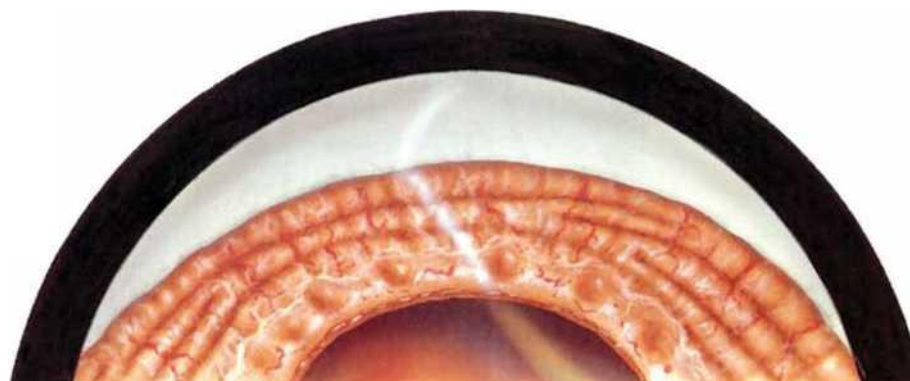

Rasmda faqat ayrim boylamlarning tolalari ko'rsatilgan,aslida boylamlar gavharning hamma tomoniga birikadi.

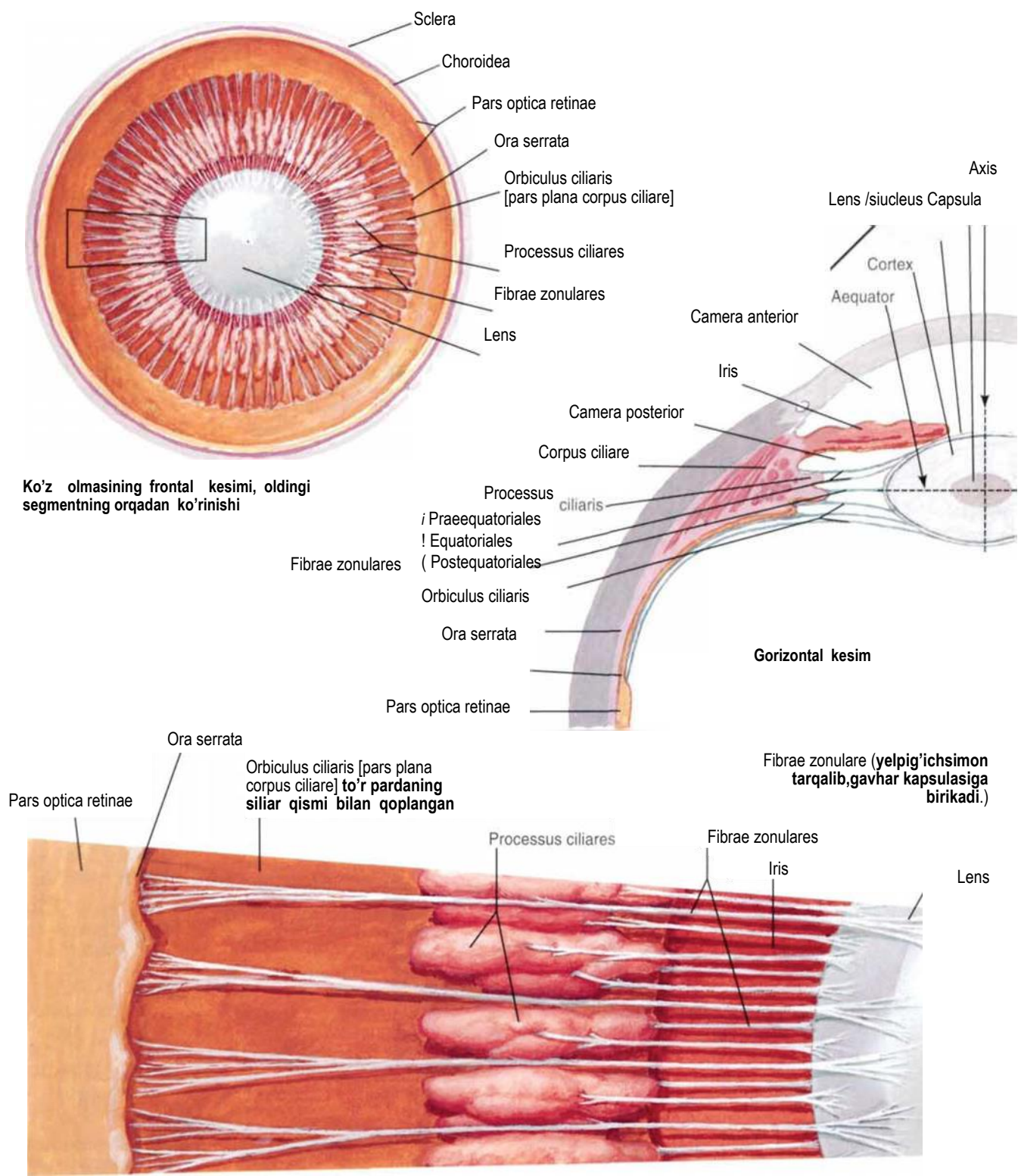
Rangdor-shox parda burchagi va ko'zning oldingi kamerasi



Yopiq burchak:
gonioskopiyada
ko'rinishi



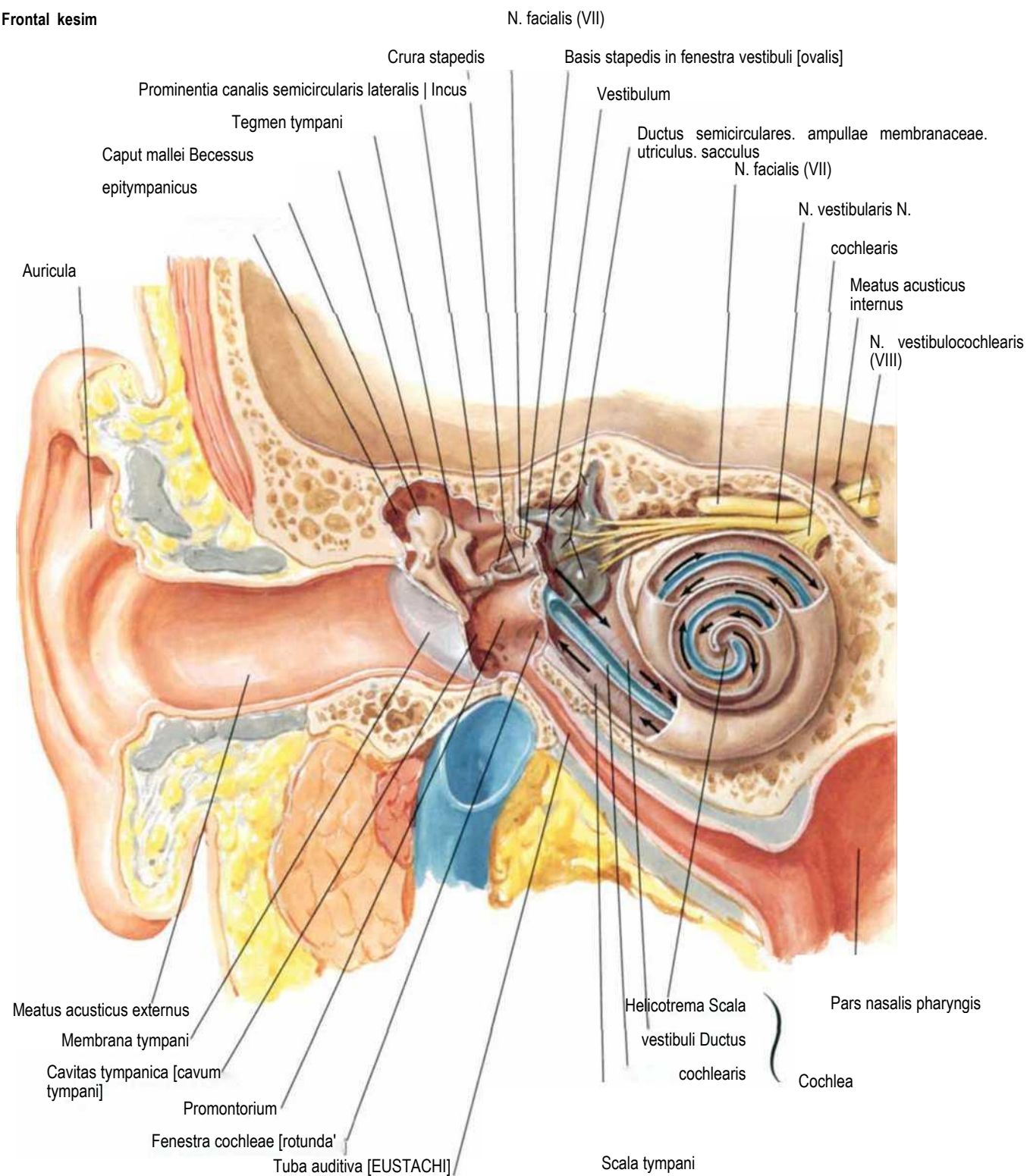
Gavhar (lens) va uning tayanch tuzilmalari



Yuqorida ajratib ko'rsatilgan segmenti sxemasi

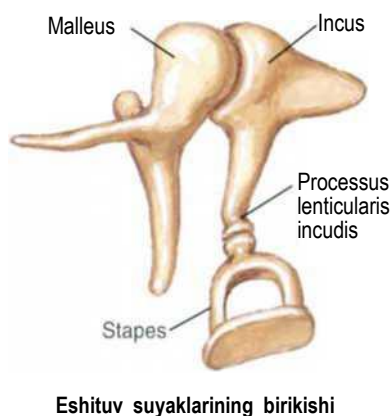
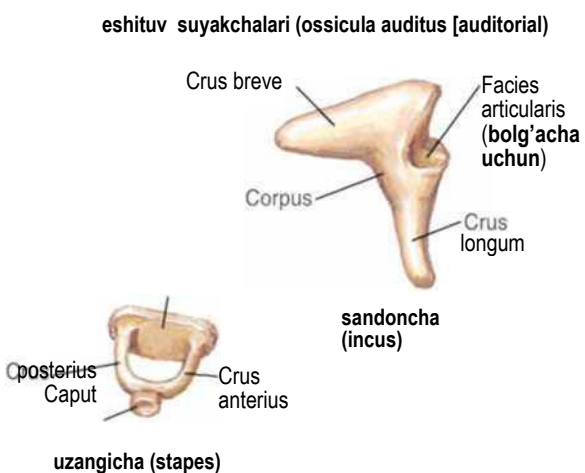
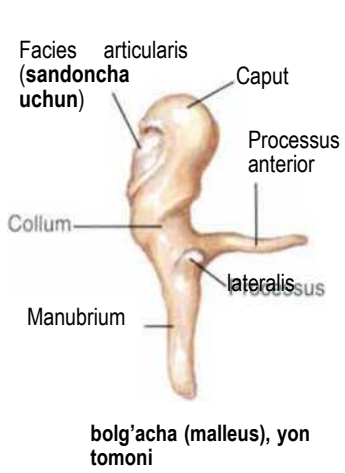
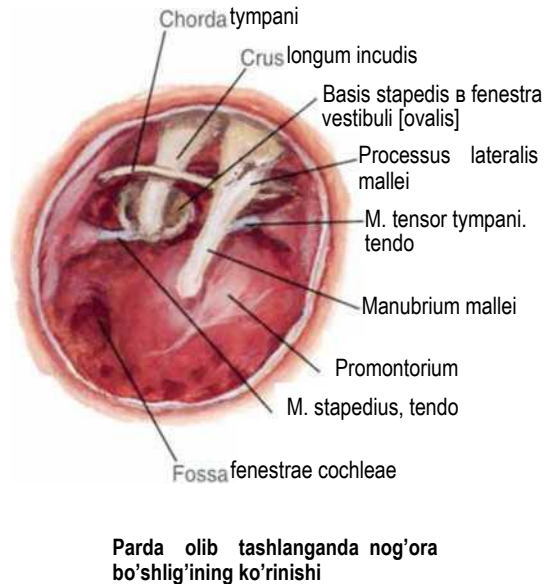
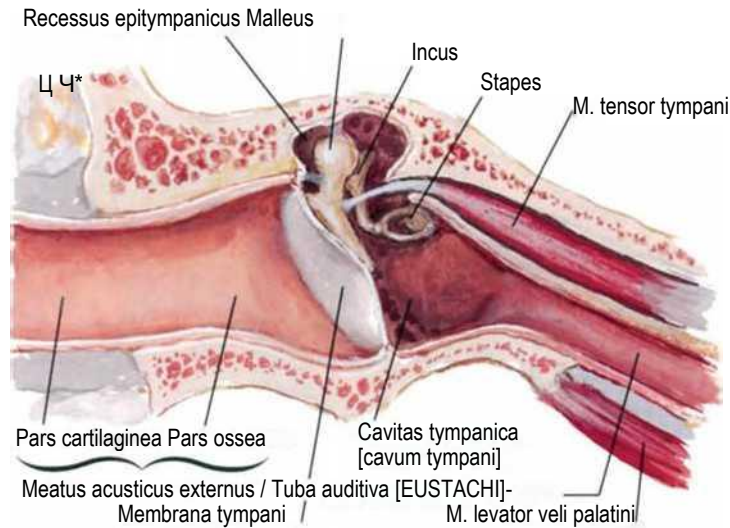
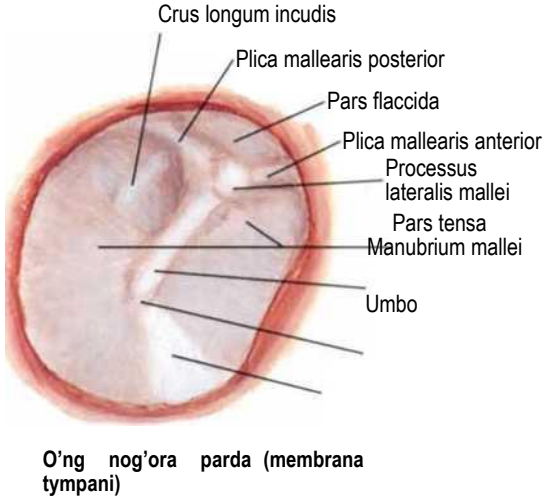
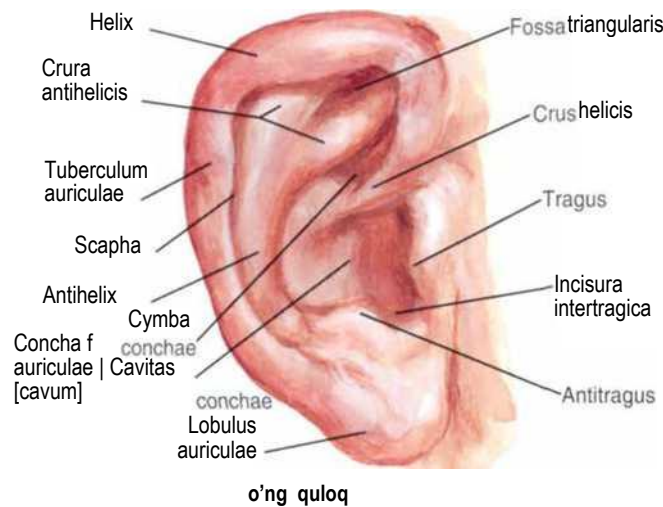
Eshitish analizatorining yo'llari

Frontal kesim



Strelkalar bilan tovush yo'nalishi ko'rsatilgan

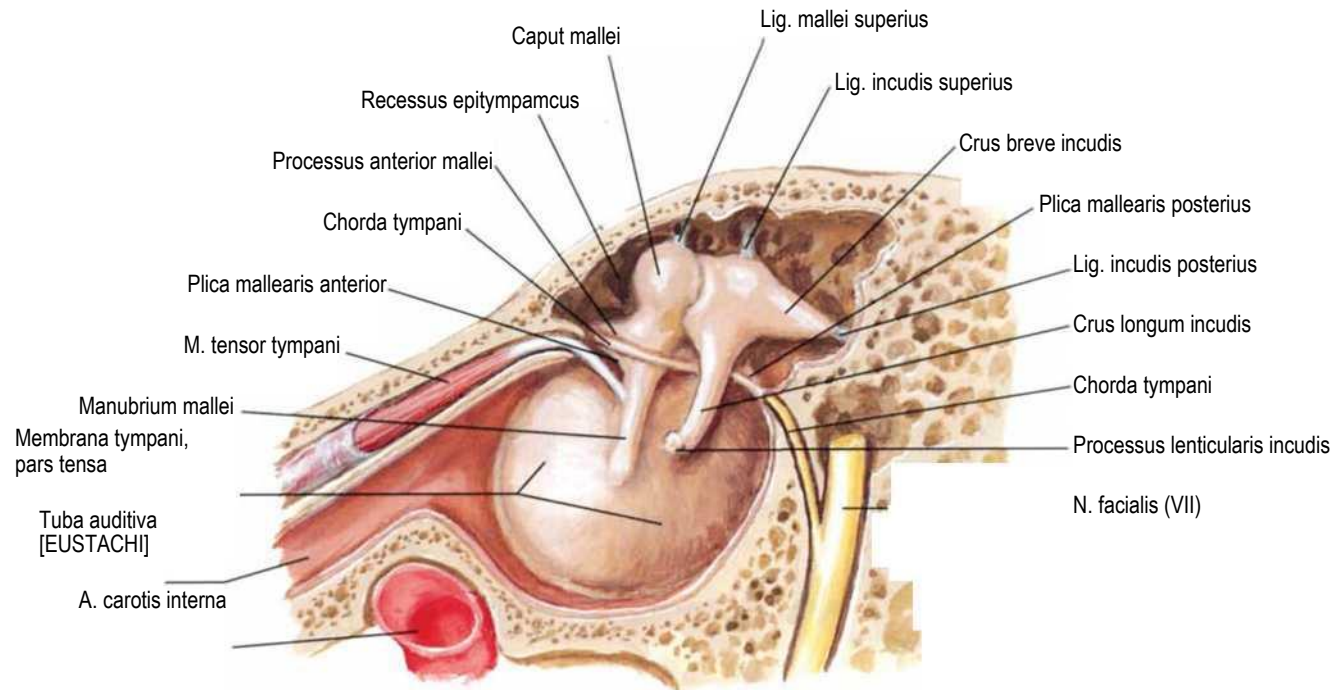
Tashqi va ichki quloq (auris externa et auris media)



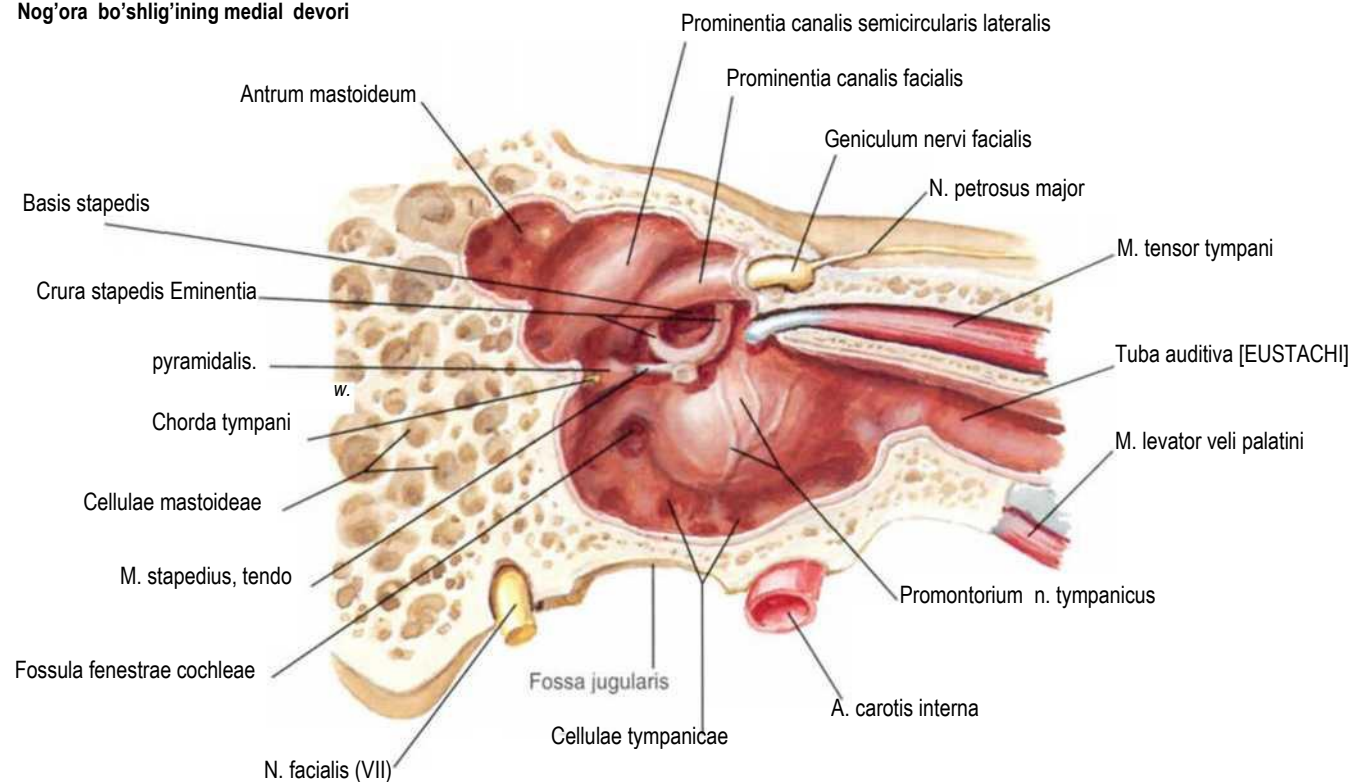
Nog'ora bo'shlig'i (cavitas tympani)

41. 117. 118.129-rasmlar.

Nog'ora bo'shlig'ining lateral devori, ichki tomonidan ko'rinishi



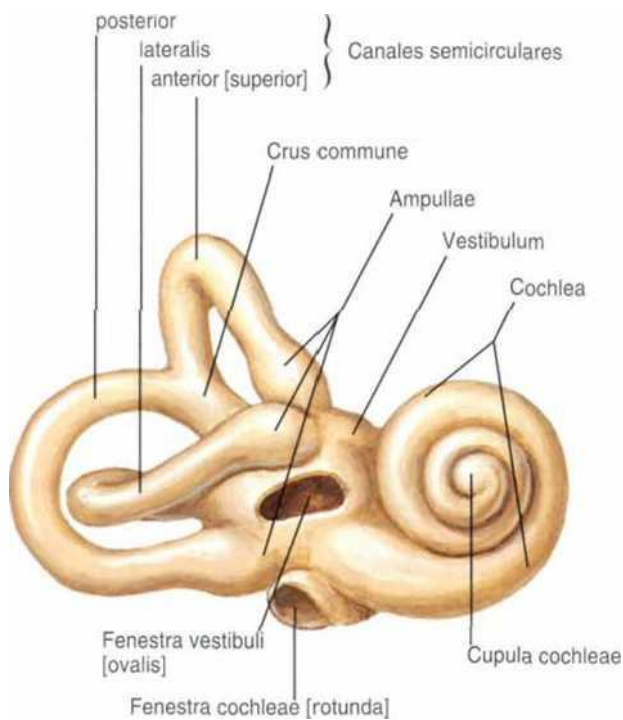
Nog'ora bo'shlig'ining medial devori



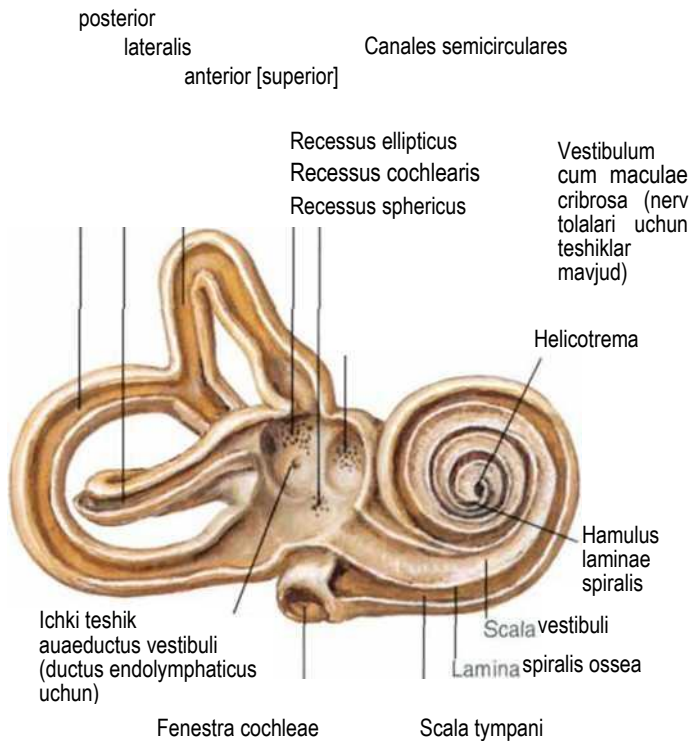
Suyak va parda labirinti

118-rasmga qarang.

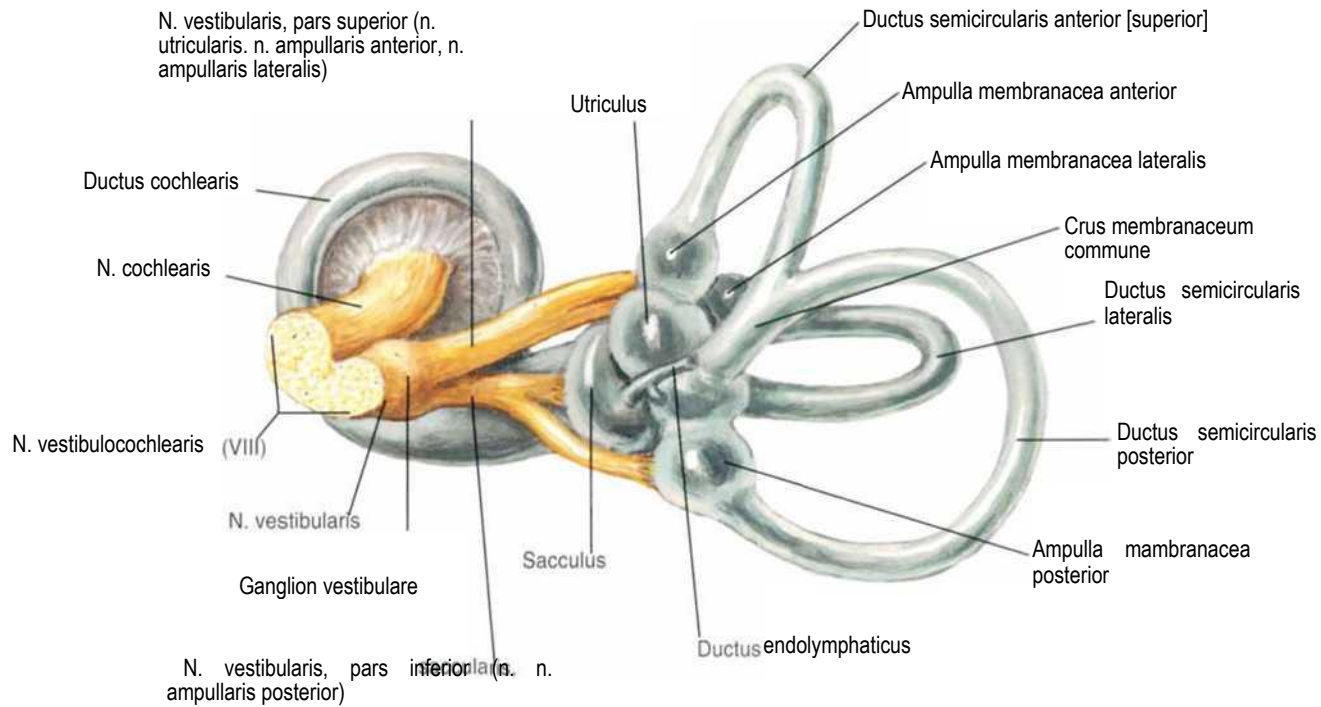
O'ng suyak labirinti, oldingi lateral tomoni



ong suyak labirintining kesmasi
(parda labirinto olib tashlangan)



O'ng parda labirinti nervlari bilan, orqa medial tomonidan ko'rsatilgan

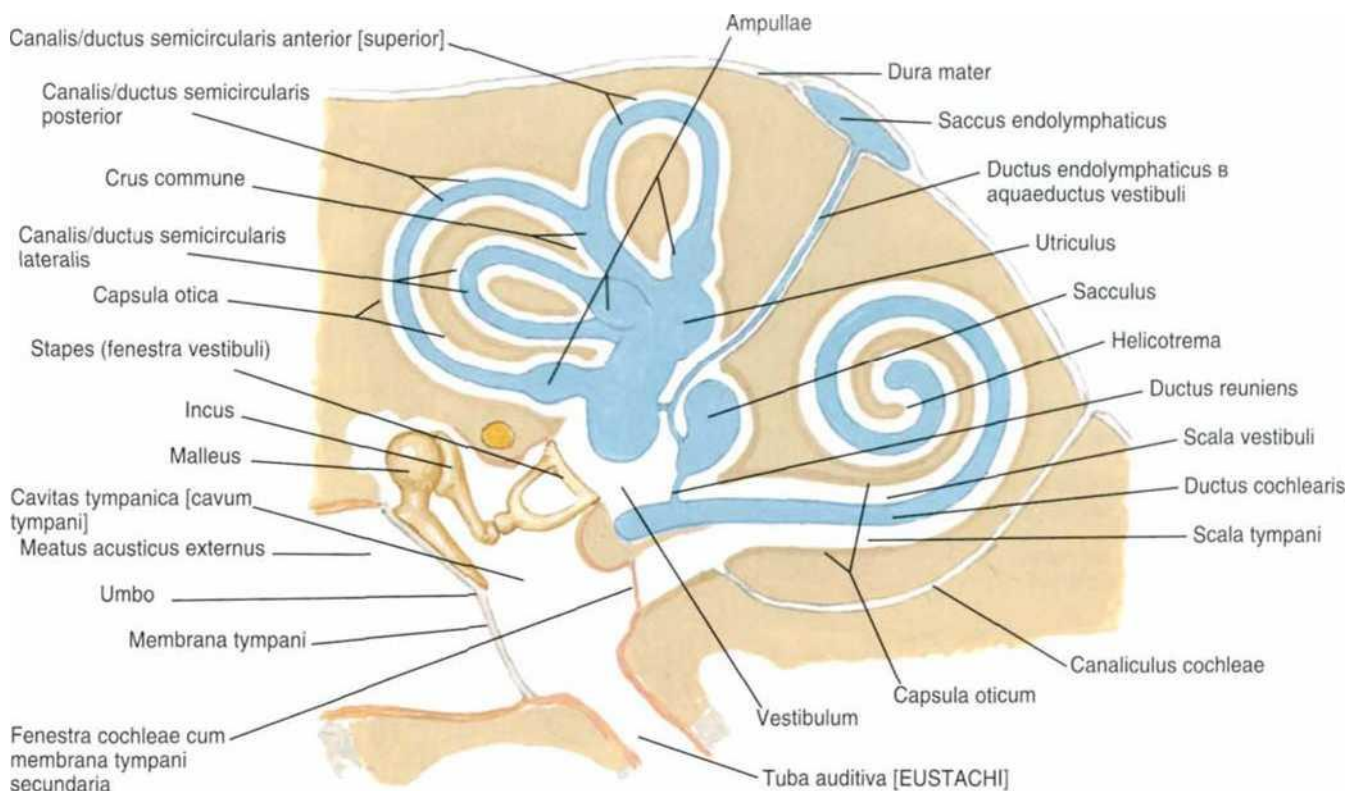


90-rasm

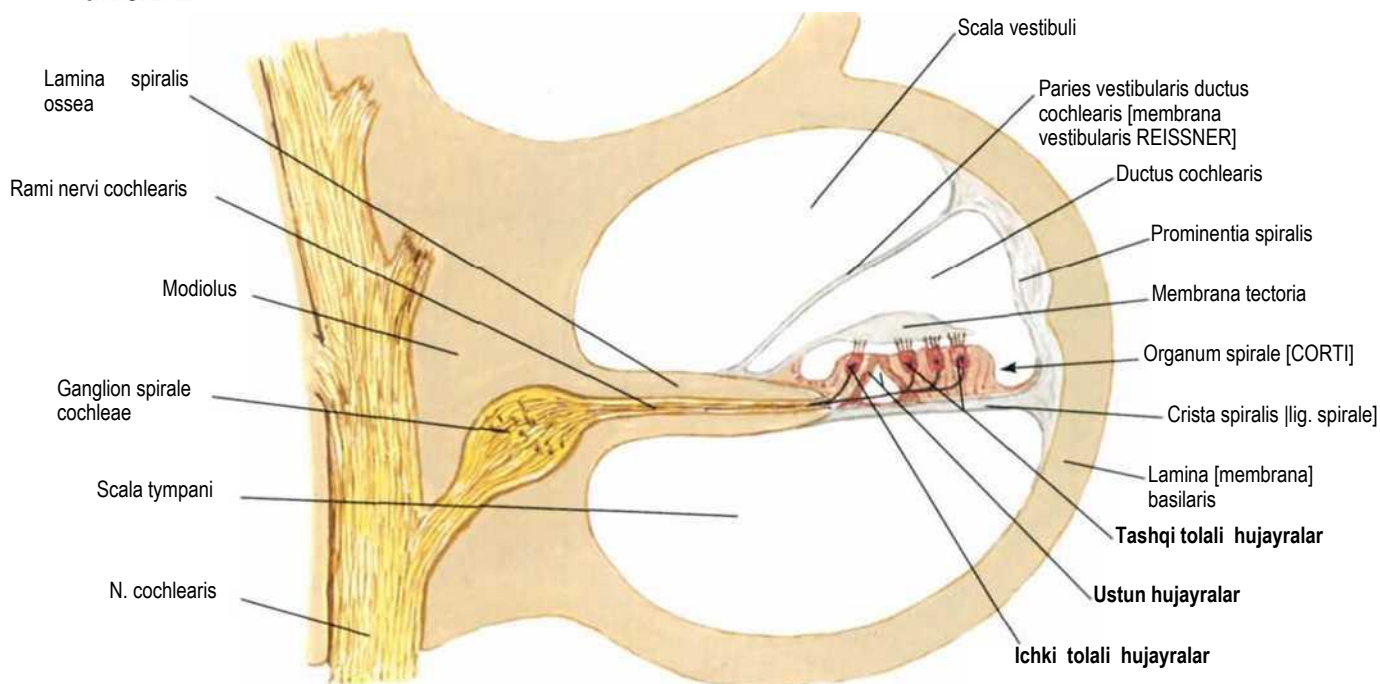
BOSH VA BO'YIN

Suyak va parda labirinti (davomi)

Suyak va parda labirintining sxemasi

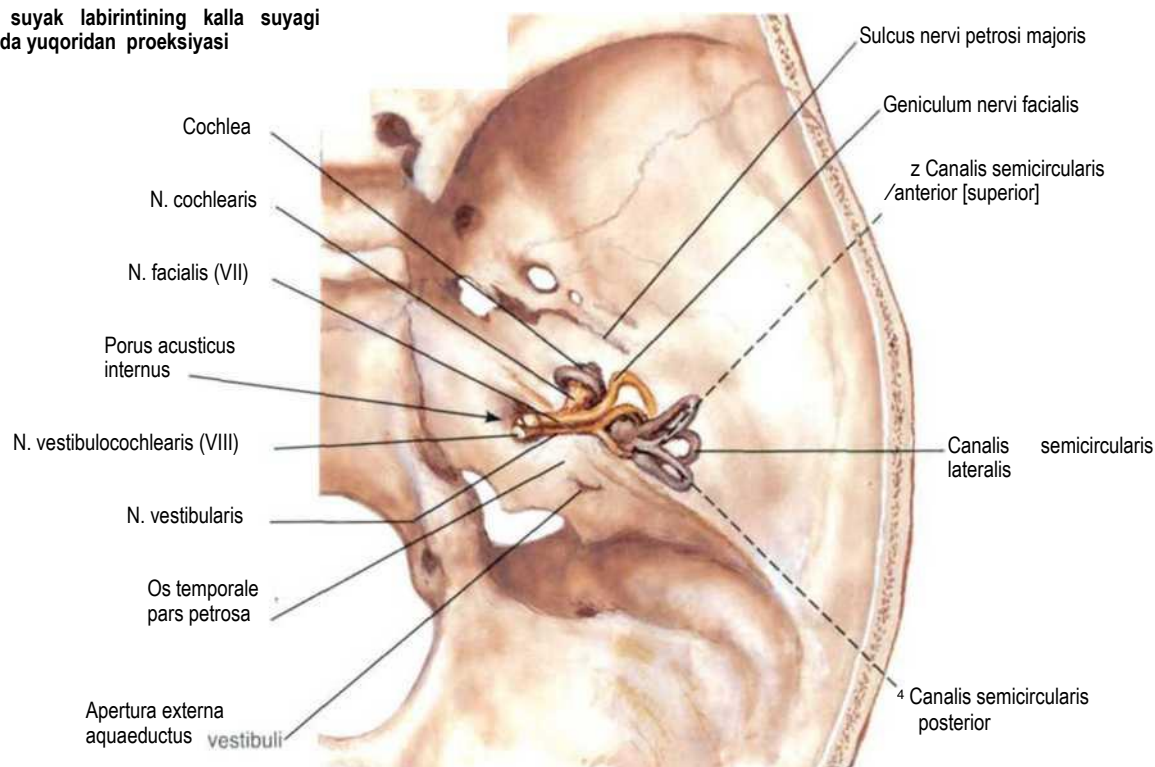


Срез улитки

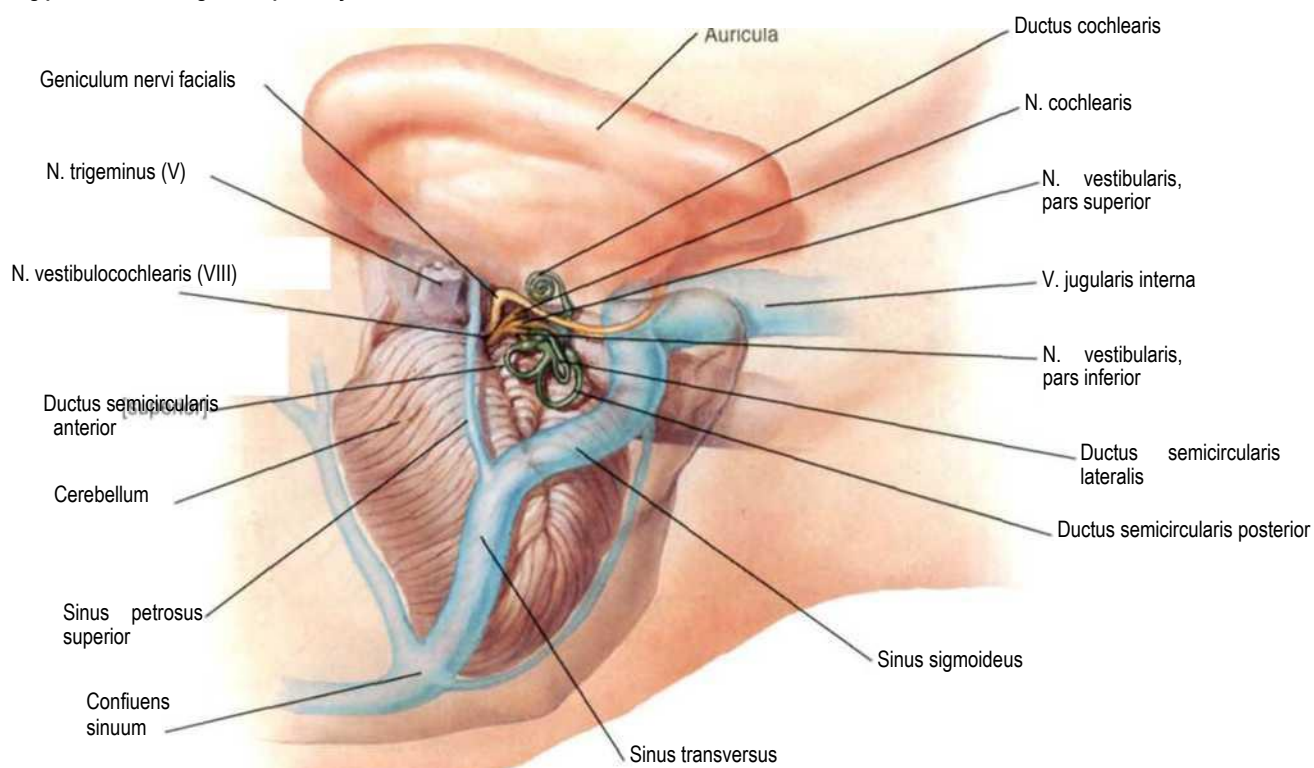


Kalla suyagida labirintning joylashuvi

O'ng suyak labirintining kalla suyagi asosida yuqoridan proeksiyasi



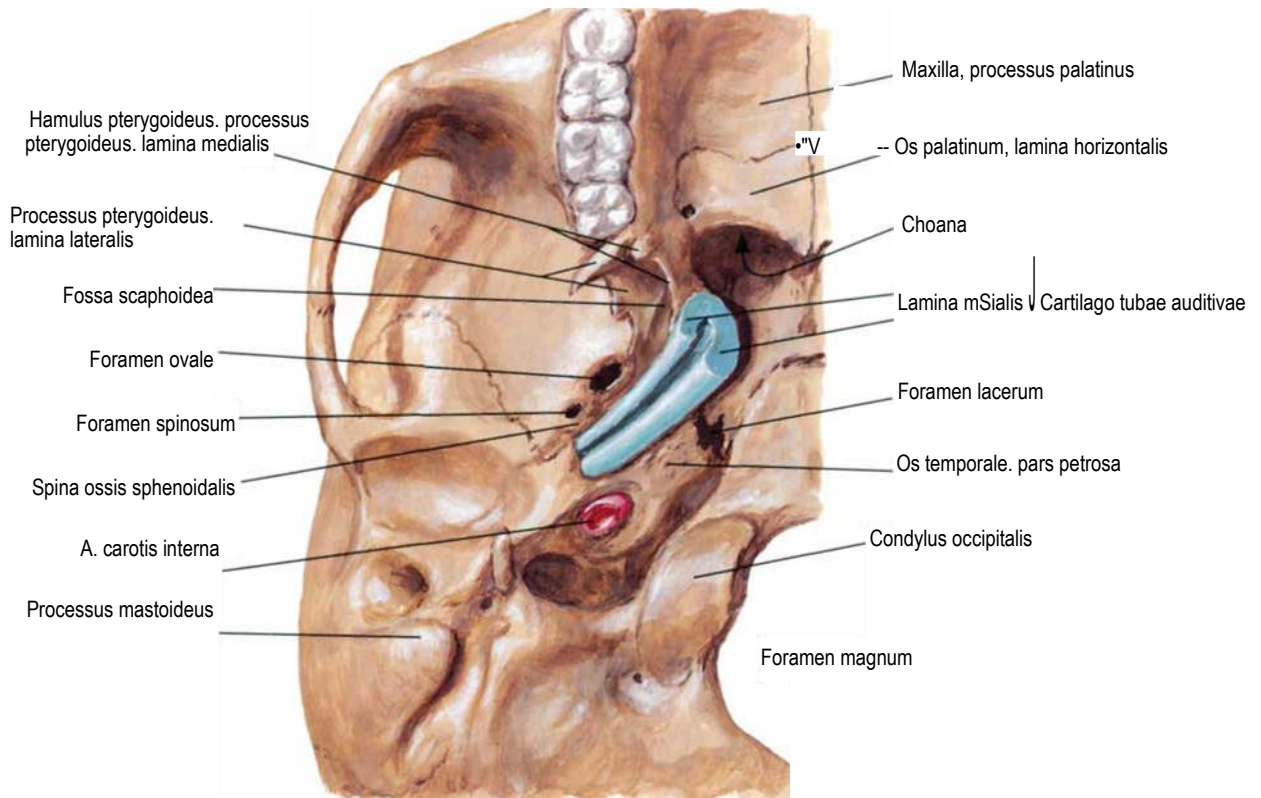
o'ng parda labirintining lateral proeksiyasi



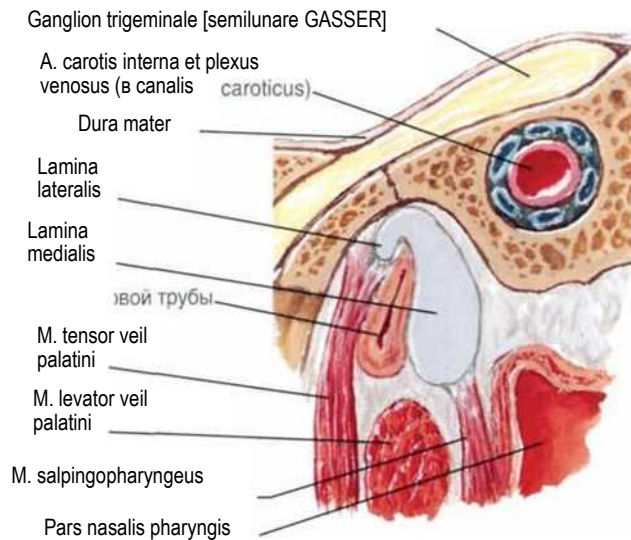
Eshituv nayi (tuba auditiva)

46. 49. 59-rasmlar

Kalla suyagi asosida eshituv nayining tog'ayli qismi, pastdan ko'rinishi

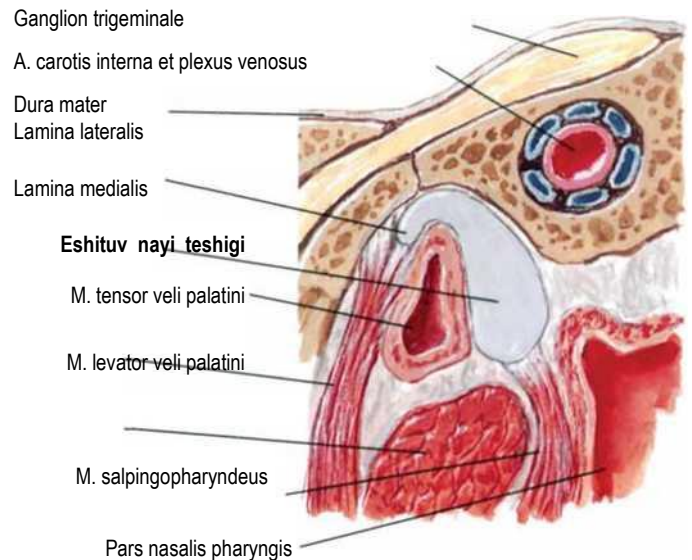


Eshituv nayining tog'ayli qismidan o'tkazilgan kesim, nay yopilgan holatda



Medial plastinkada m. Salpingopharyngeus hisobiga hosil boluvchi bosim eshituv nayini yopib qo'yadi

Eshituv nayining tog'ayli qismidan o'tkazilgan kesim, nay ochilgan holatda

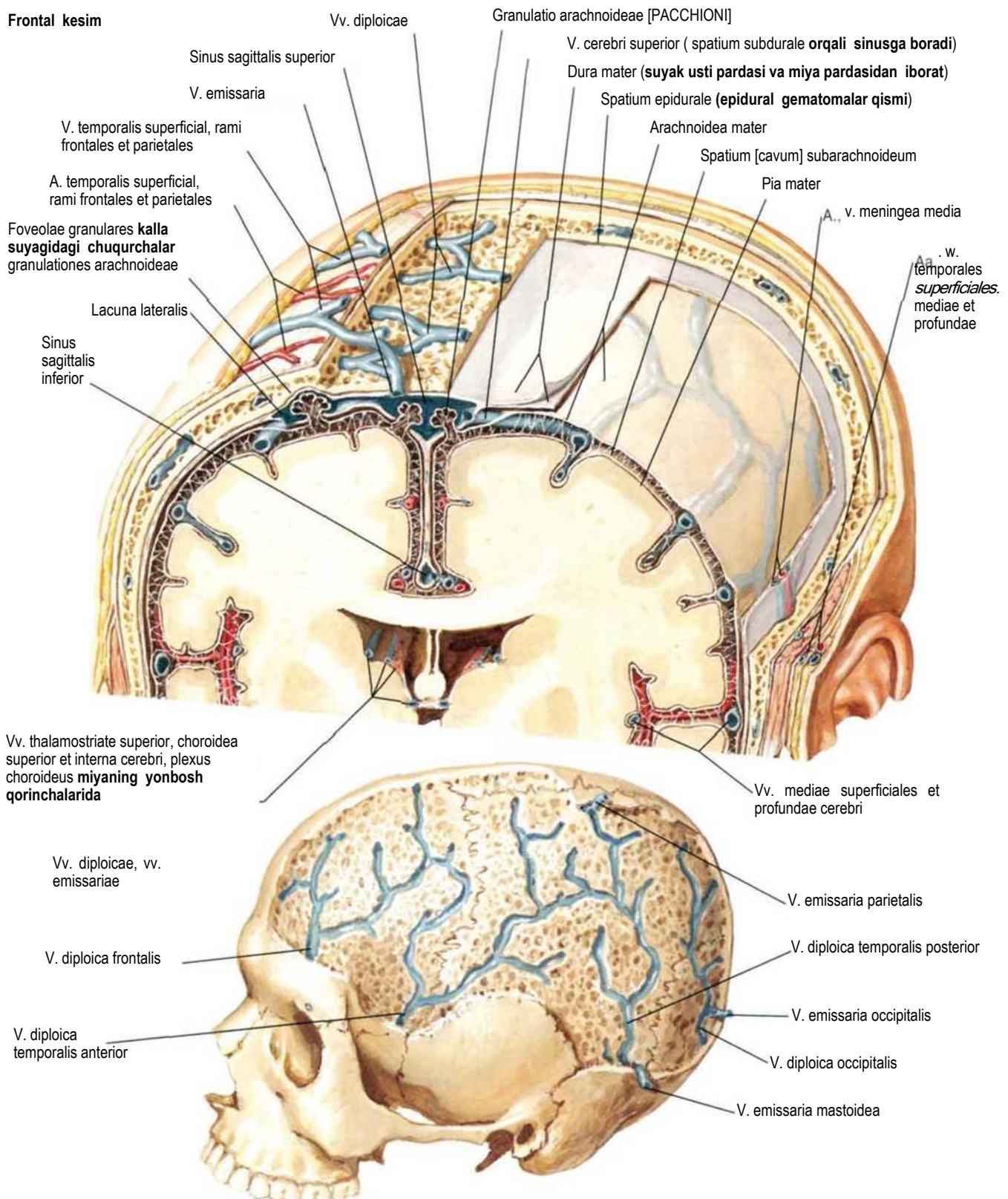


m. tensor veli palatini, qisqarishi hamda yutinish natijasida lateral plastinka surilib eshituv nayini ochib beradi

Miya pardalari (meninges) va diploik venalar (venae diploicae)

17-rasm

Frontal kesim

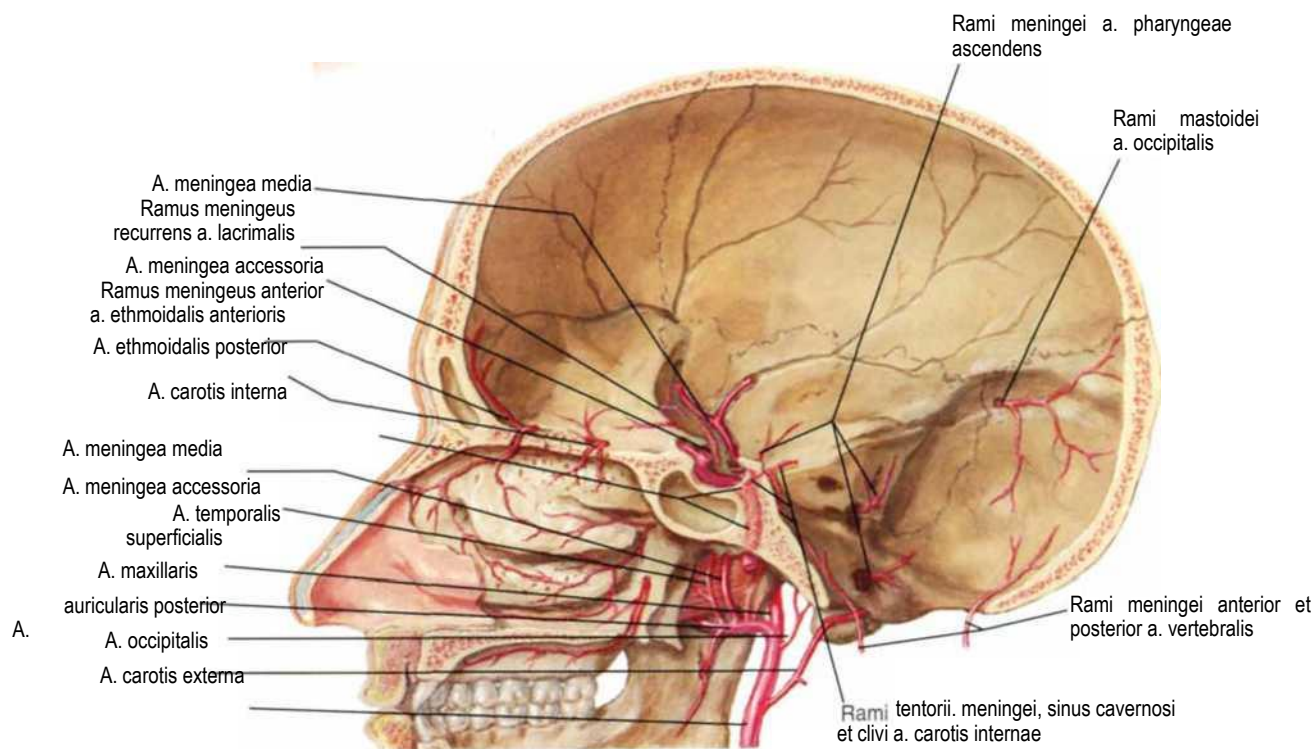
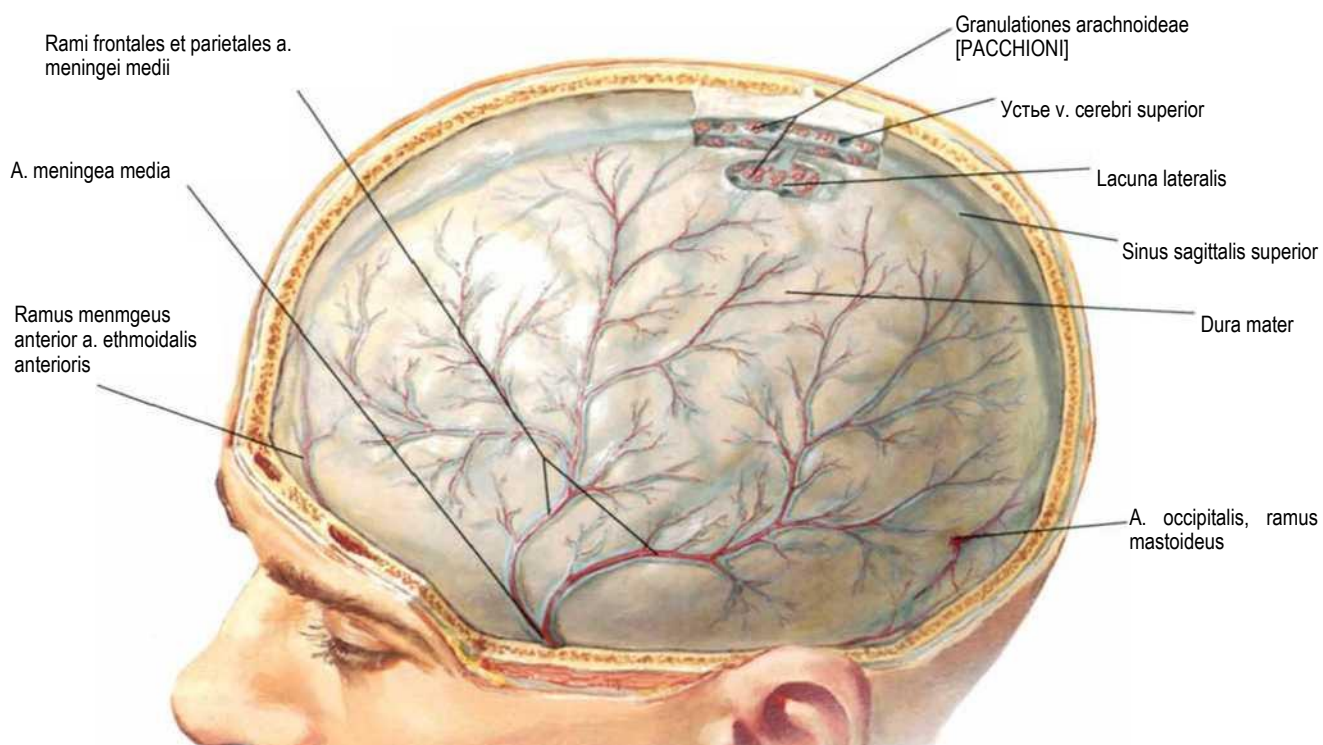


94-rasm

BOSH VA BO'YIN

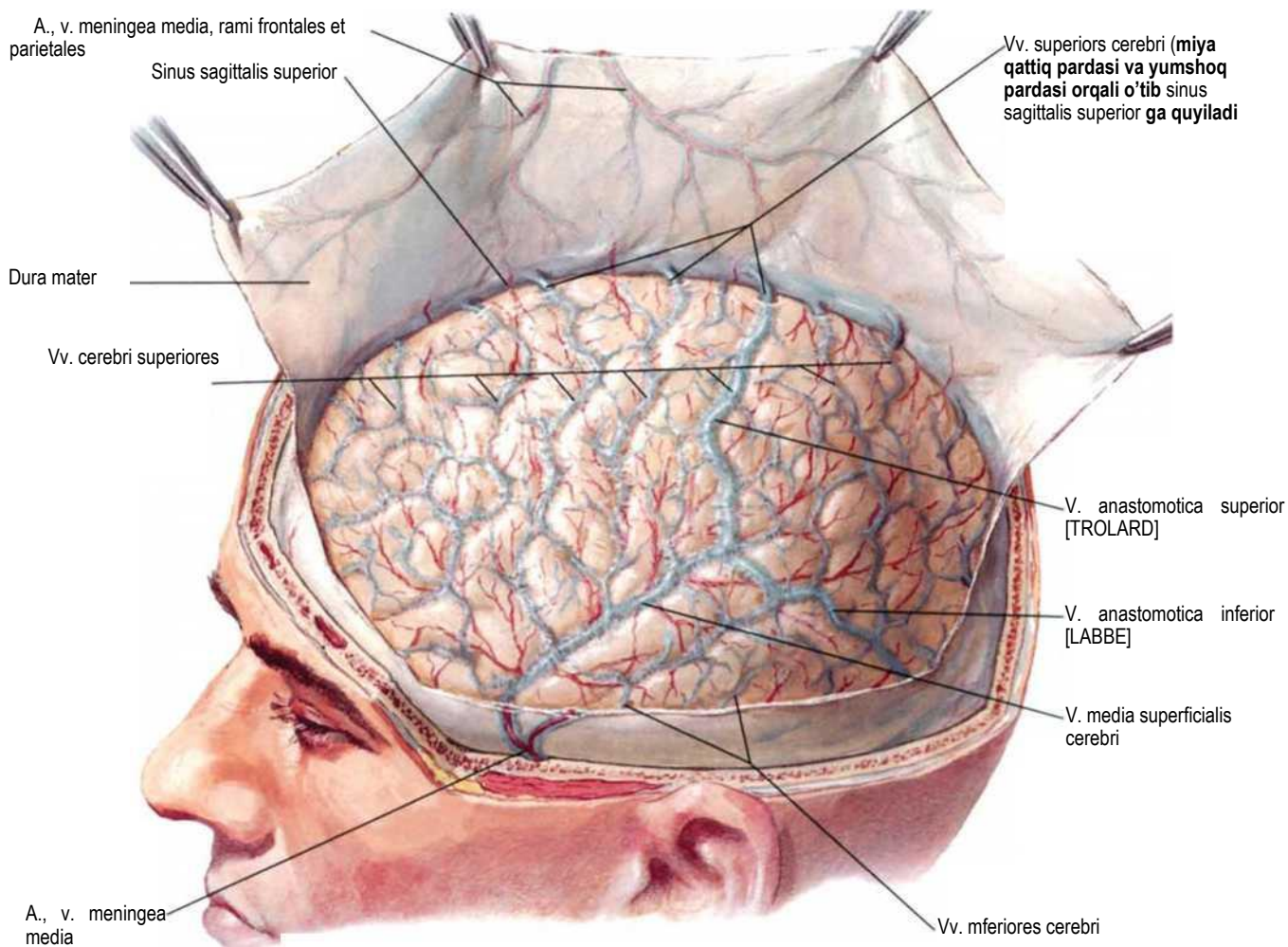
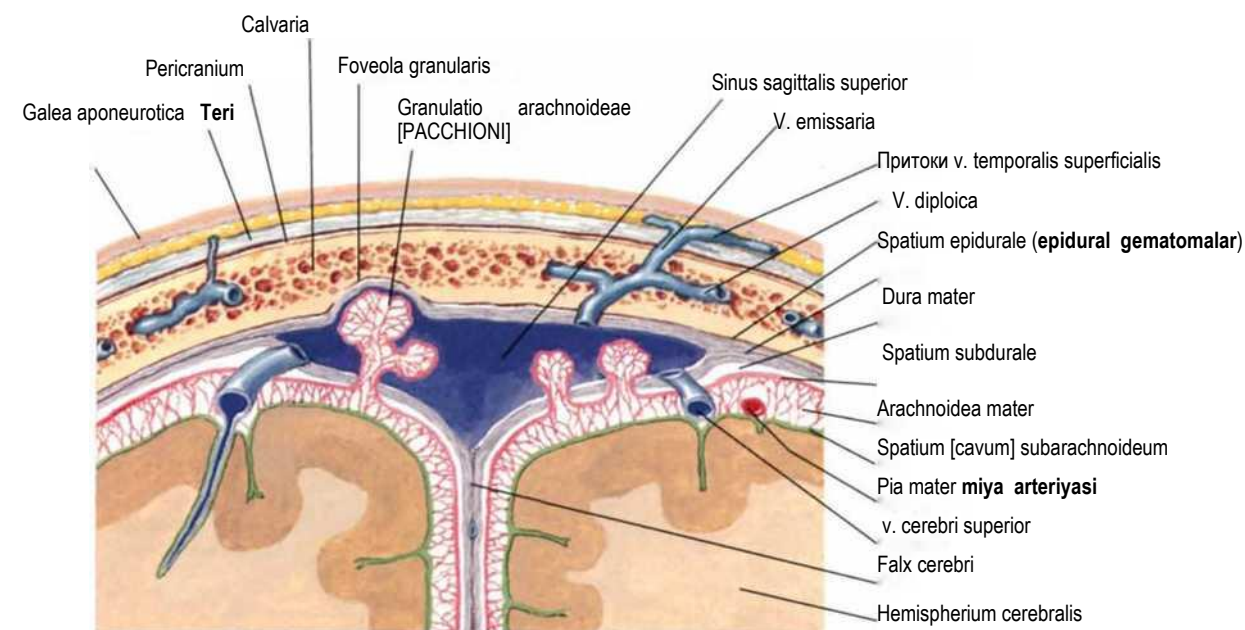
Meningeal arteriyalar (arteriae meningeae)

35. 130-rasmlar.

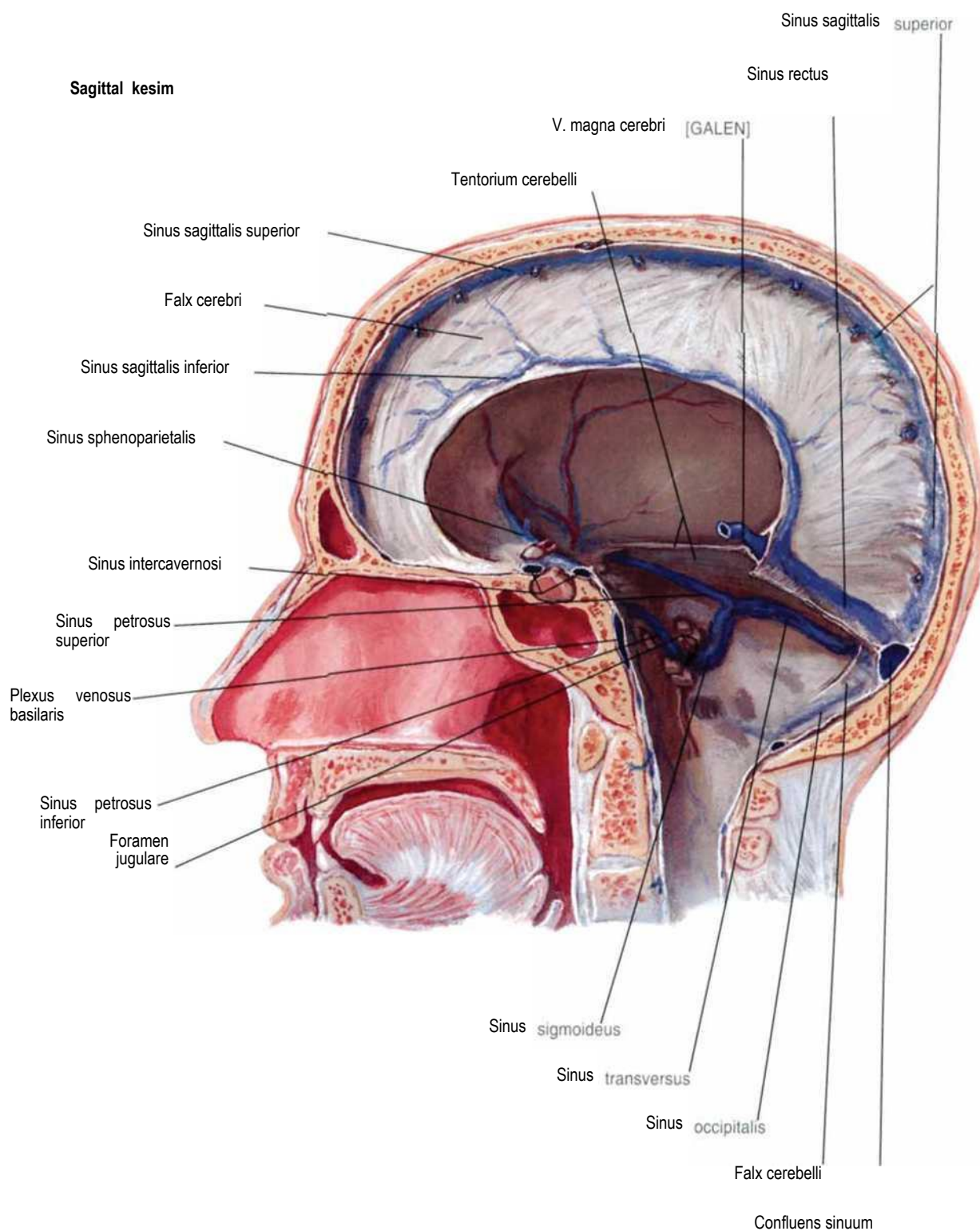


Miya pardalari va miyaning yuza venalari

38-rasmda chuqur venalar berilgan.



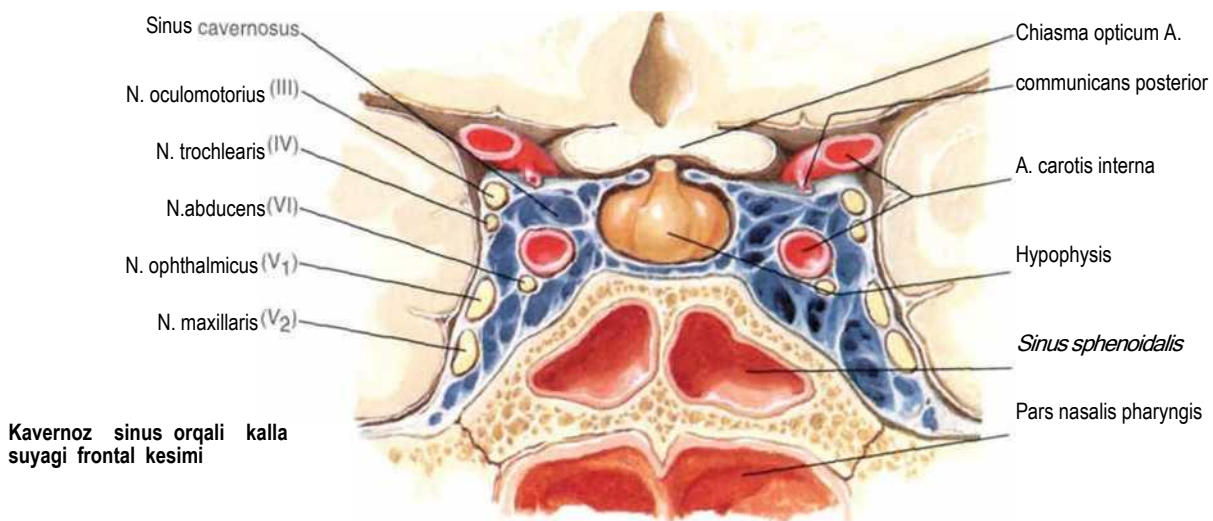
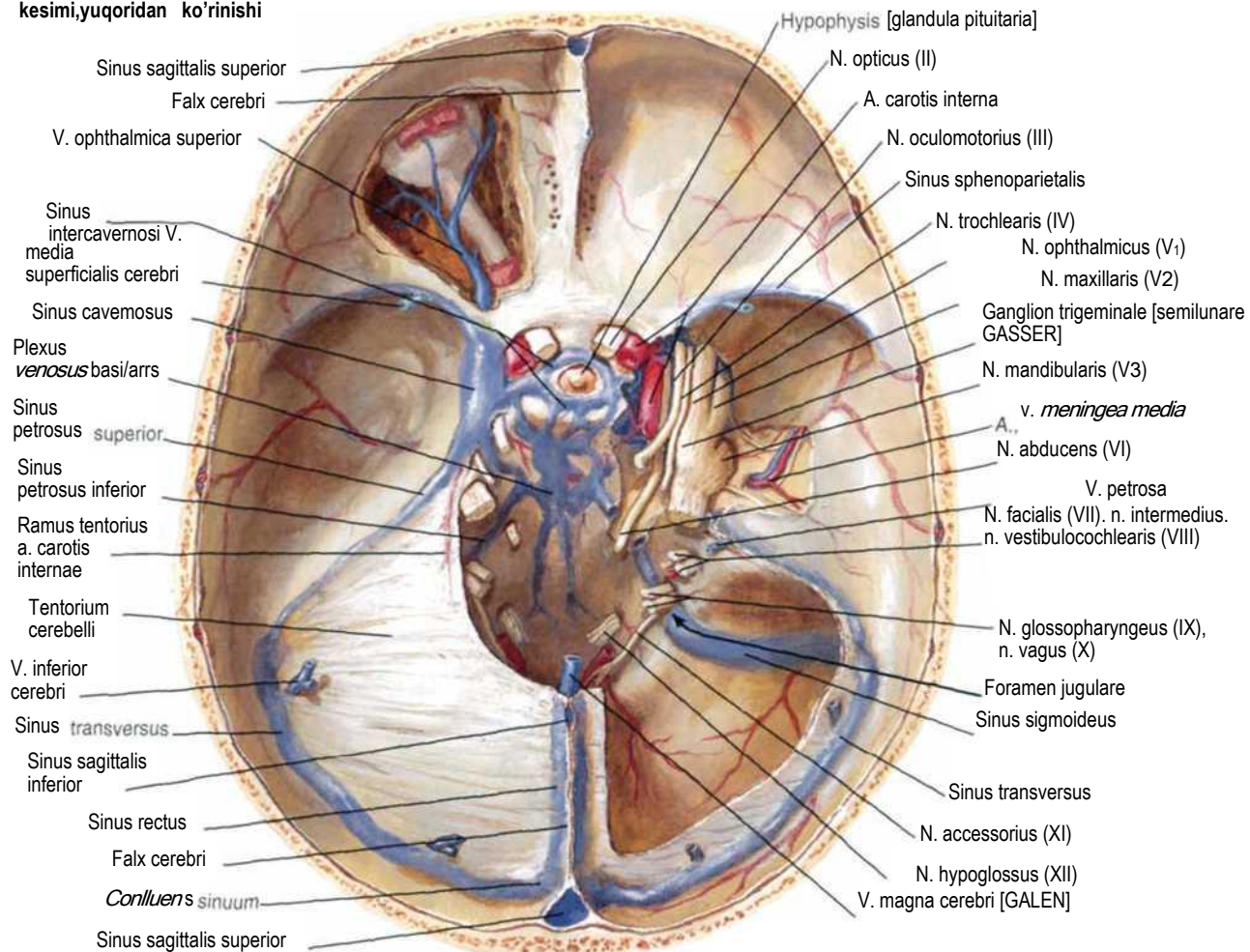
Miyaning qattiq pardasi sinuslari (sinus durae matris)



Miyaning qattiq pardasi sinuslari (davomi)

80-rasm

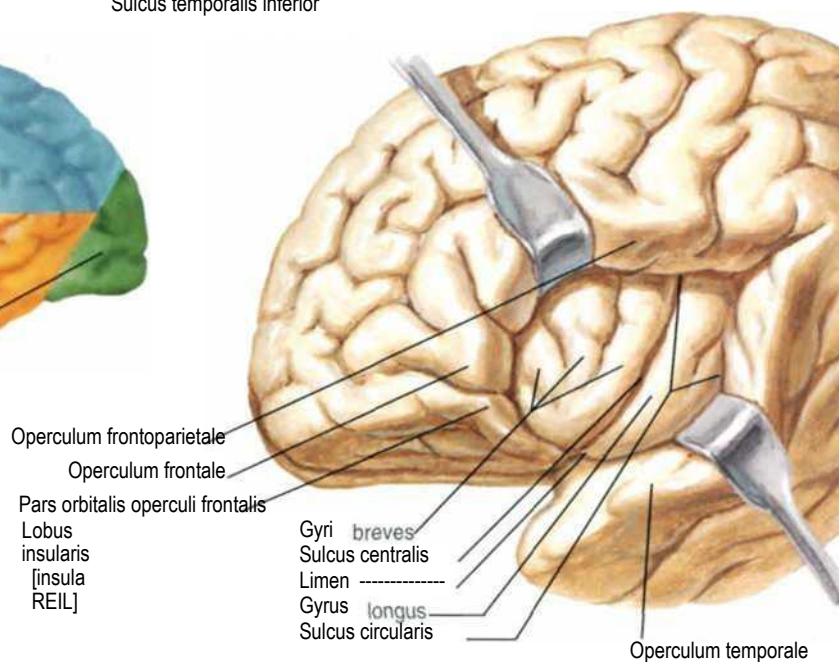
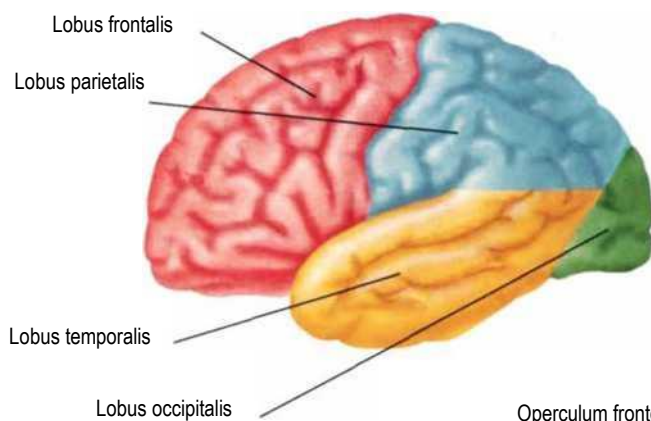
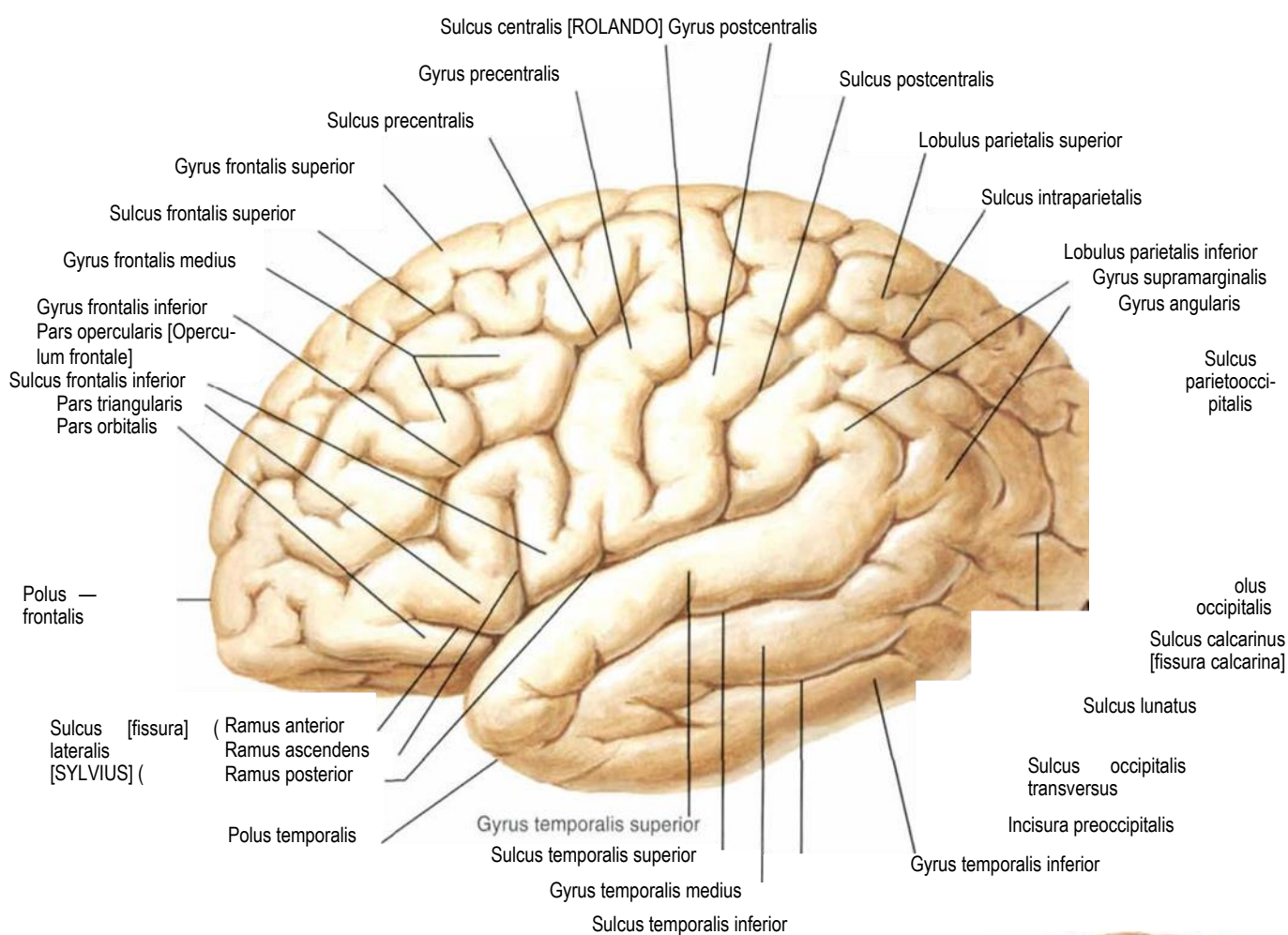
Kalla suyag igorizental kesimi, yuqoridan ko'rinishi



98-rasm

BOSH VA BO'YIN

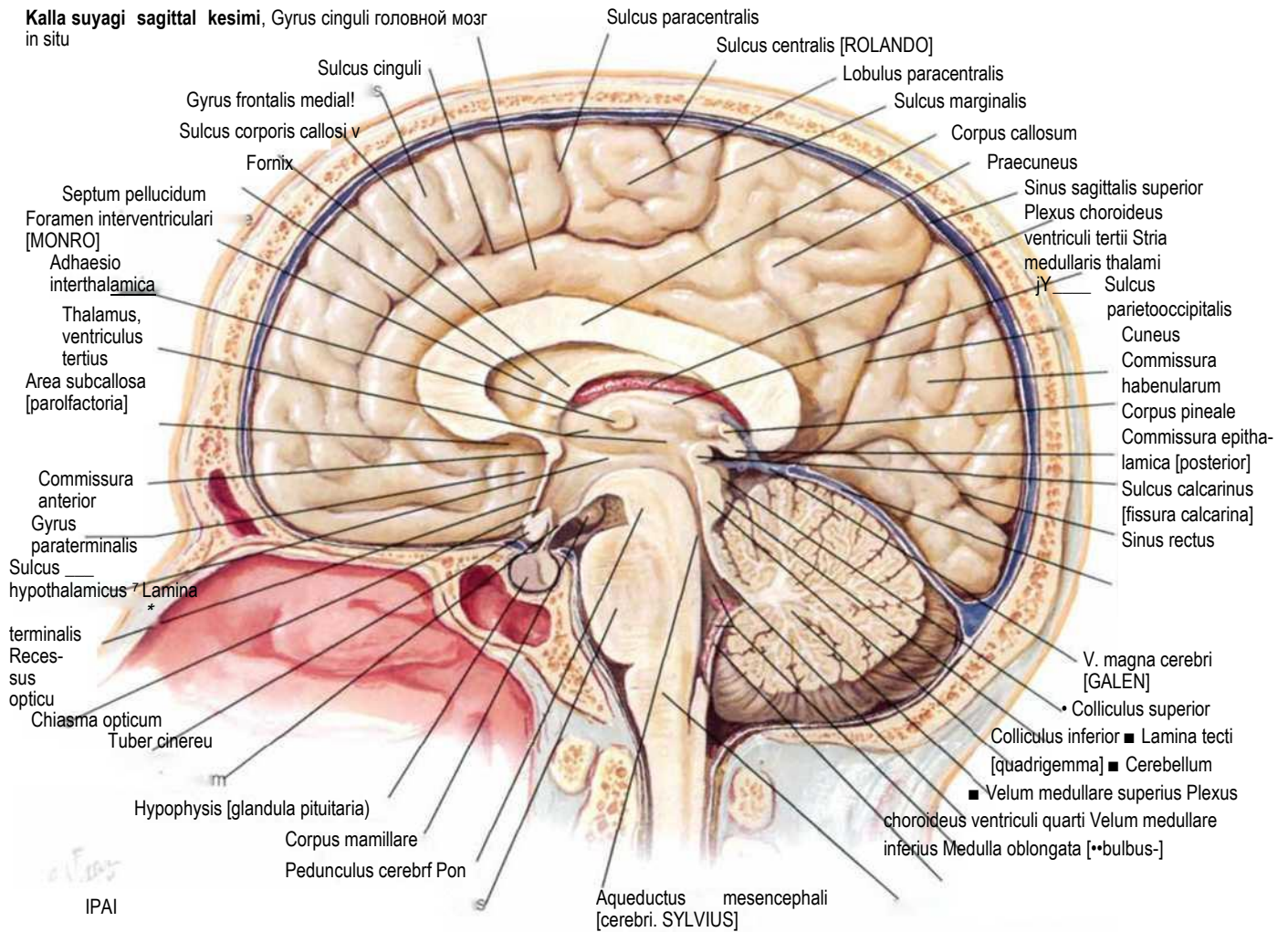
Bosh miya (cerebrum): lateral tomondan ko'inishi



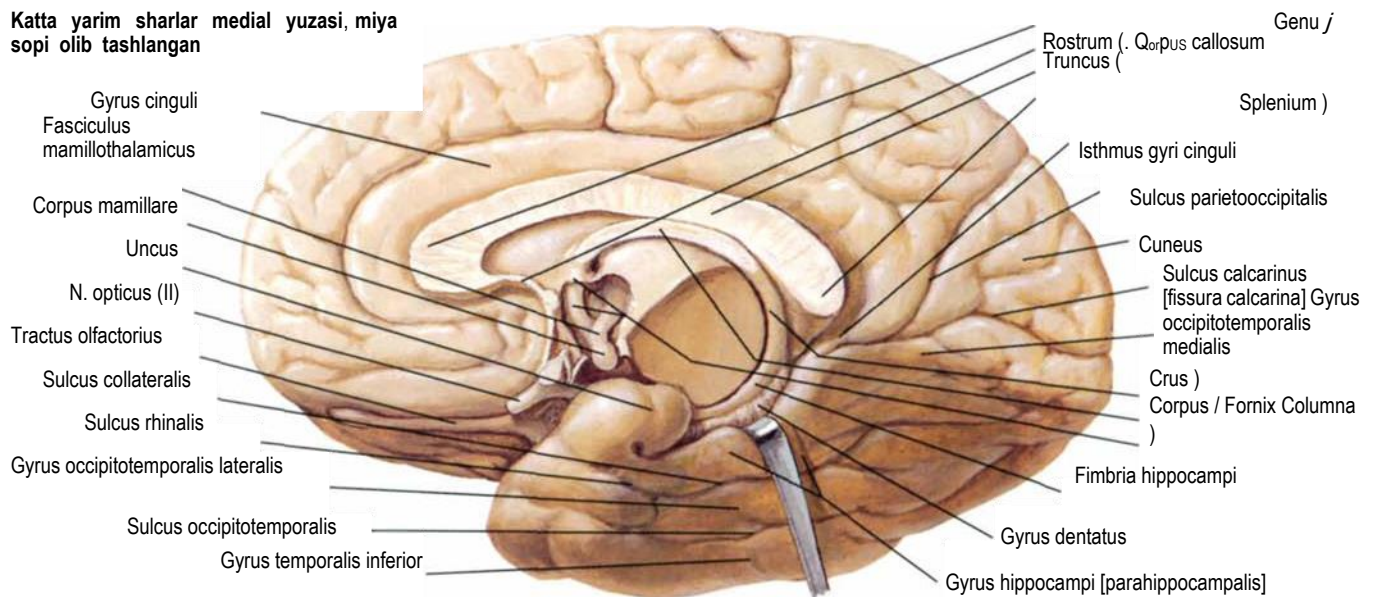
Bosh miya (cerebrum): medial tomondan ko'rinishi

140-rasm (gipofiz)

Kalla suyagi sagittal kesimi, Gyrus cinguli головной мозг in situ



Katta yarim sharlar medial yuzasi, miya sopi olib tashlangan



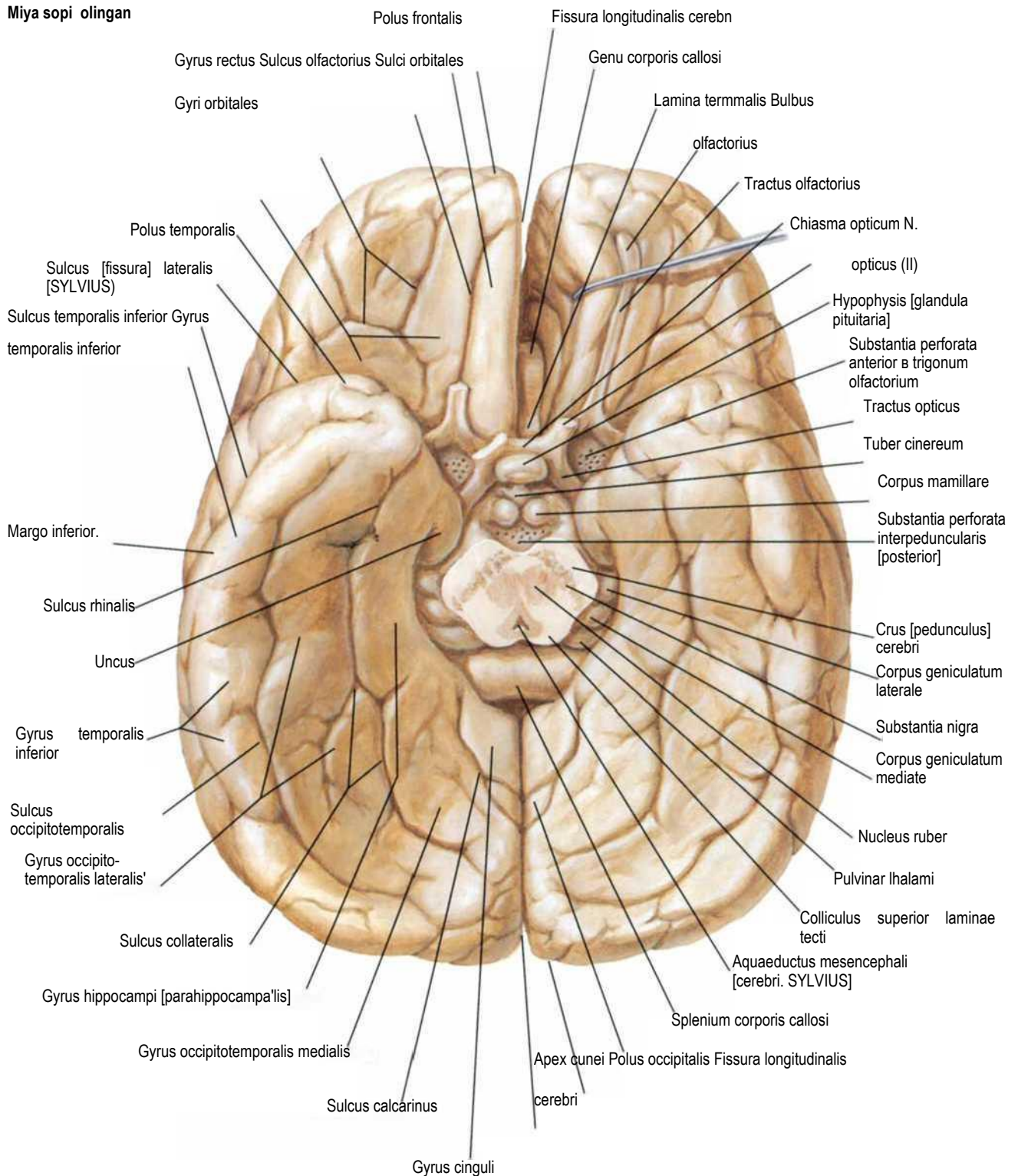
100-rasm

BOSH VA BO'YIN

Bosh miya (cerebrum): pastki yuzasi

140-rasm(gipofiz,

Miya sopi olingan



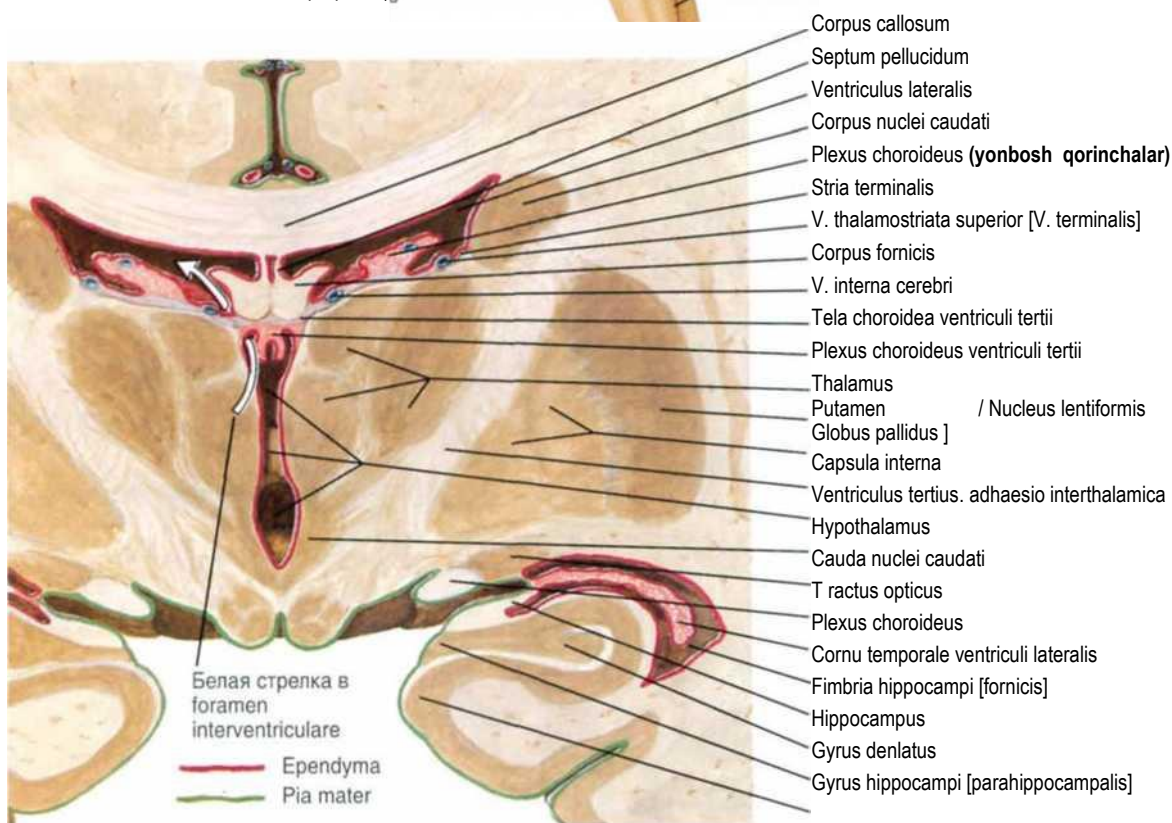
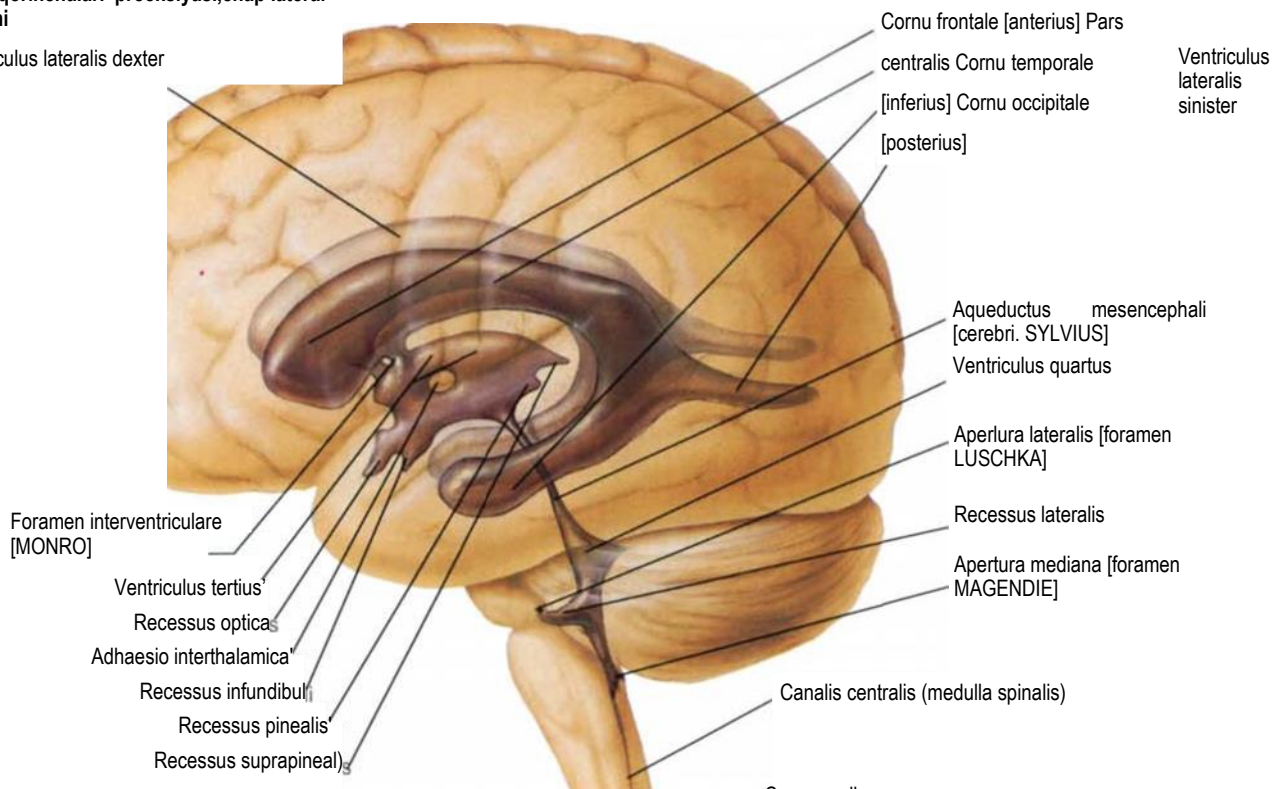
MIYA VA UNING PARDALARI

101-rasm

Miya qorinchalari

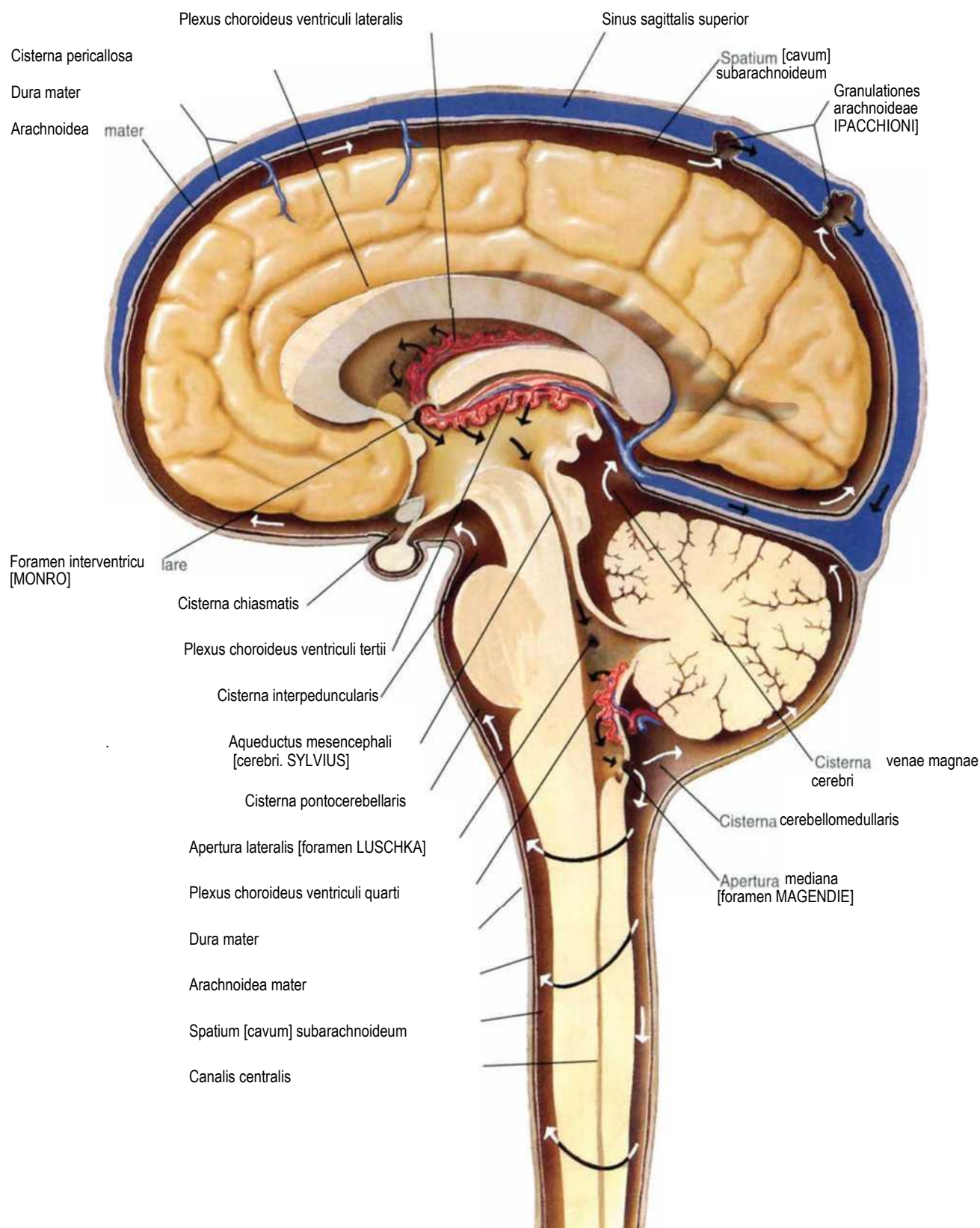
Miya qorinchalari proeksiyasi, chap lateral tomoni

Ventriculus lateralis dexter



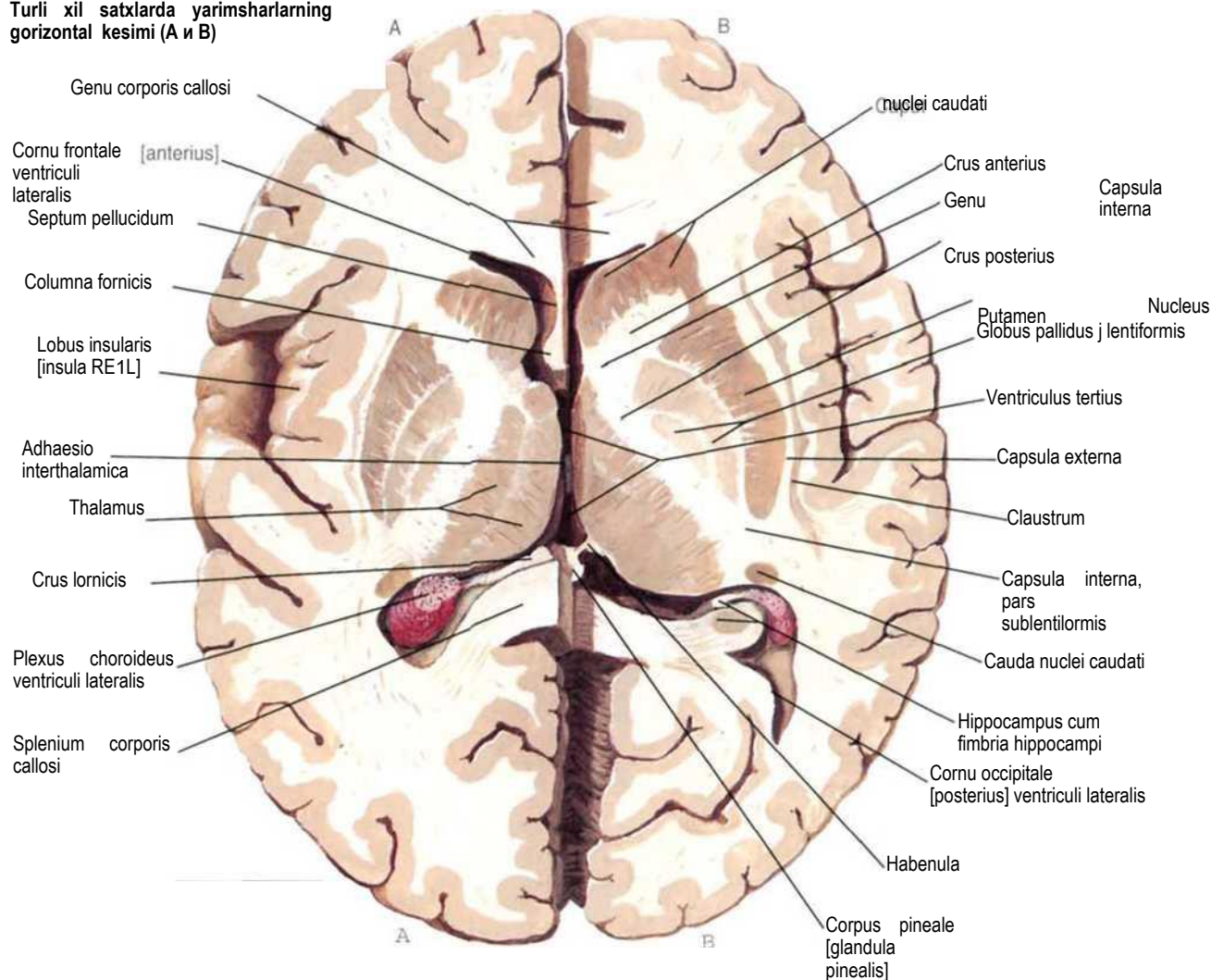
corpus mamillare orqali miyaning frontal kesimi

Orqa miya suyuqligining sirkulyatsiyasi

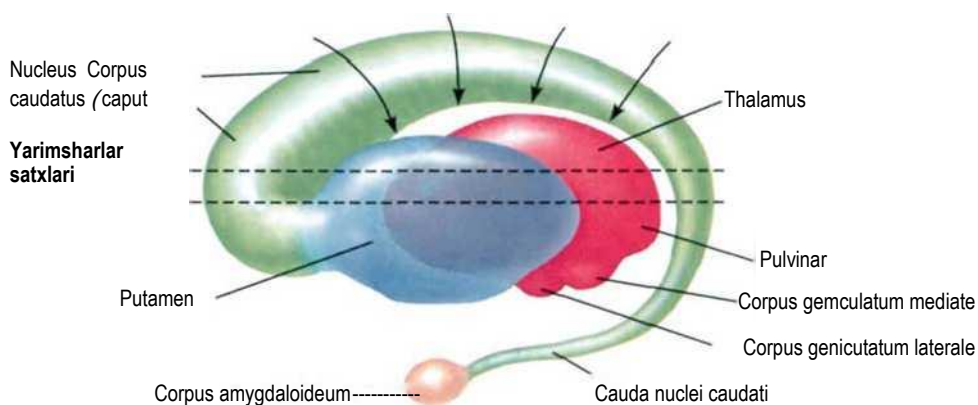


Bazal yadrolar (nuclei basales)

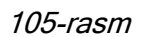Turli xil satxlarda yarimsharlarning
gorizontal kesimi (A va B)



capsula interna, ichki kapsula bilan to'lib turuvchi bo'shliq

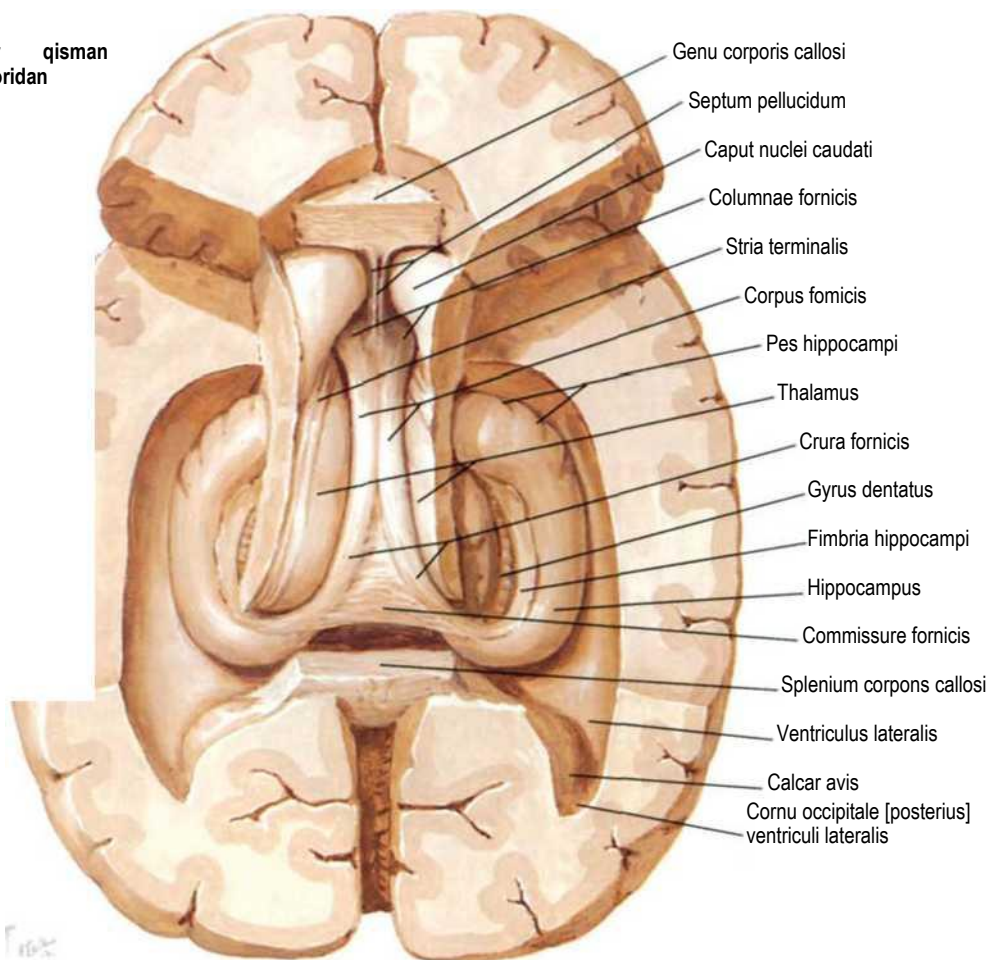


Bazal yadro va thalamus sxemalari: lateral ko'rinishi



Gippokamp va gumbaz (hippocampus et fornix)

Yarimsharlar qisman
olingan, yuqoridan
ko'rinishi



IBN

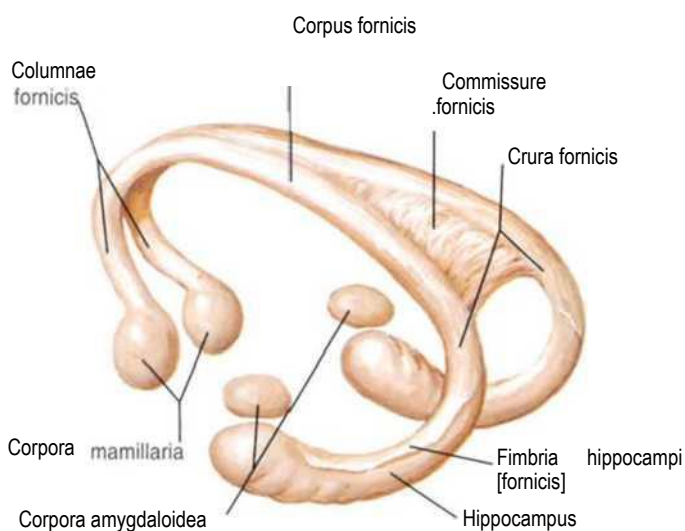
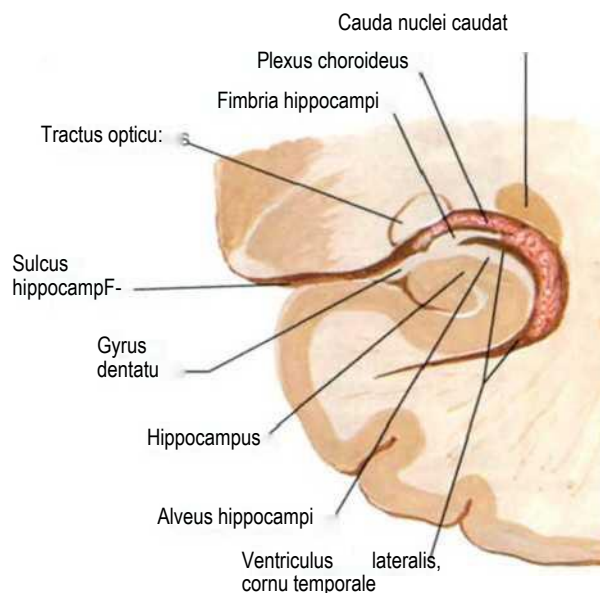


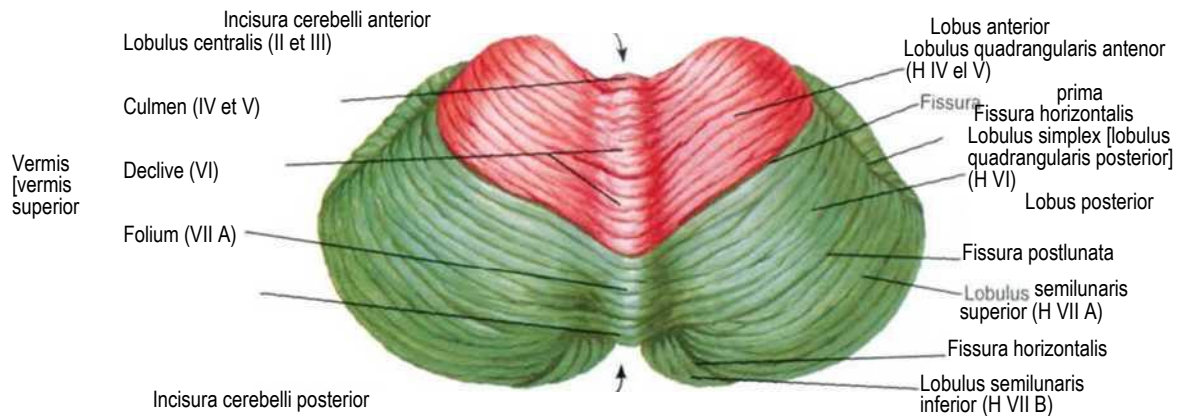
Схема свода



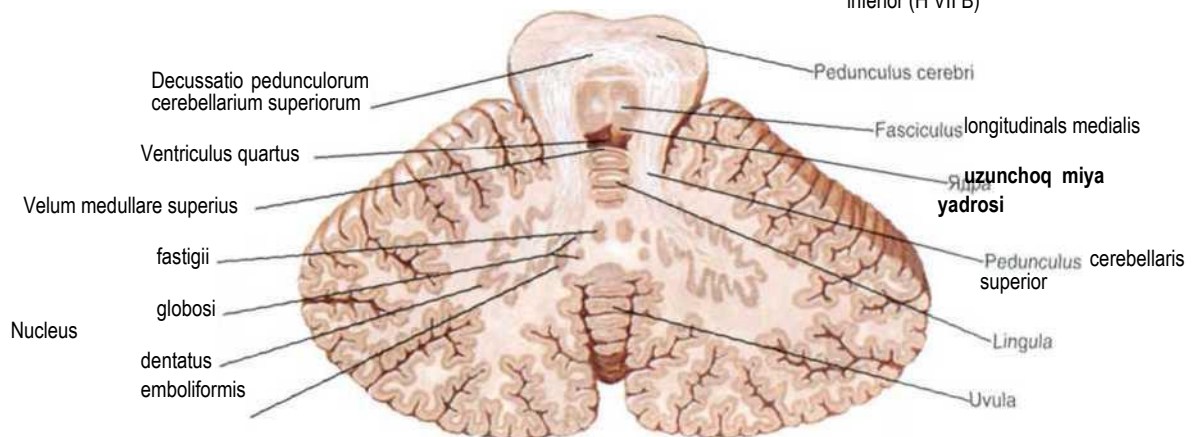
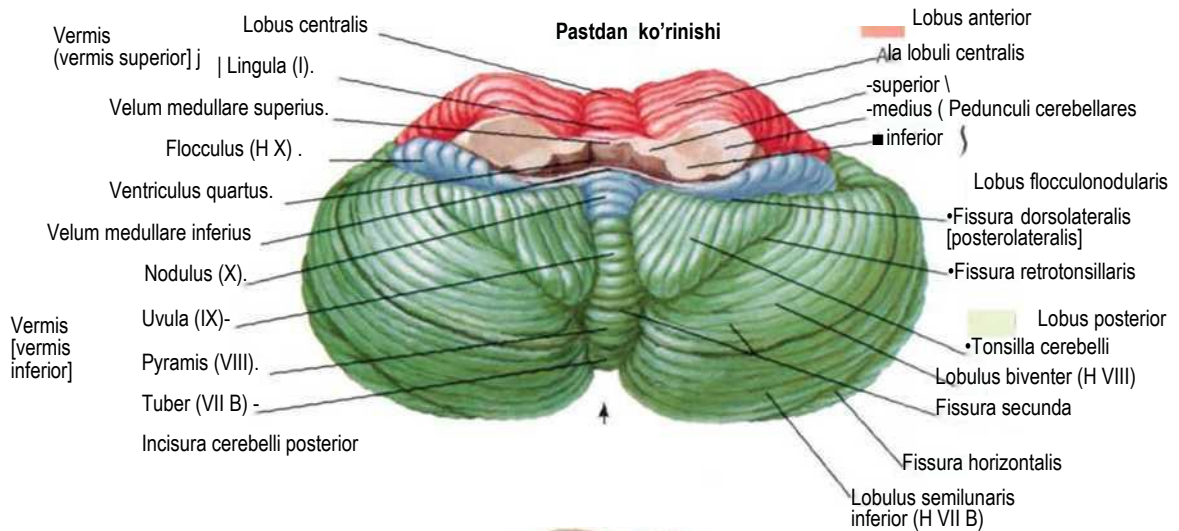
Frontal kesim ,orqadan ko'rinishi

Miyacha (cerebellum)

Yuqoridan ko'rinishi

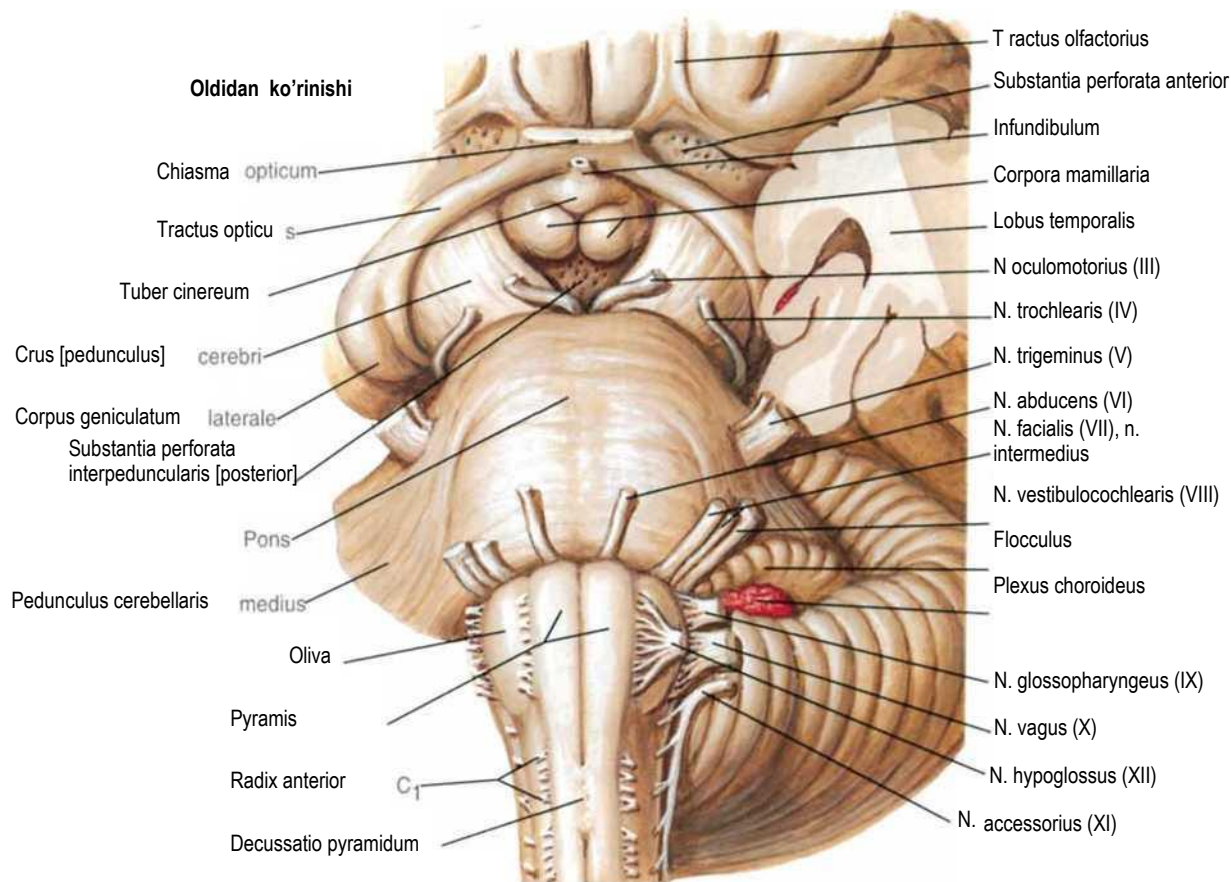
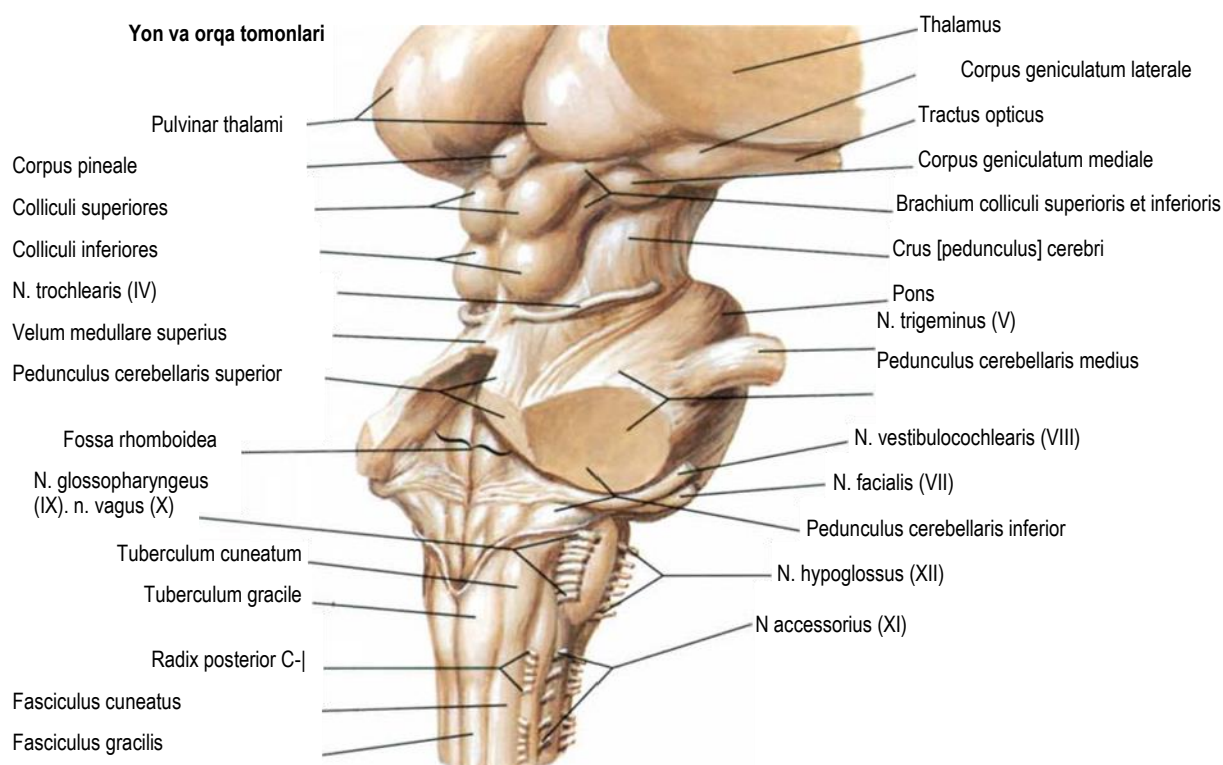


Pastdan ko'rinishi

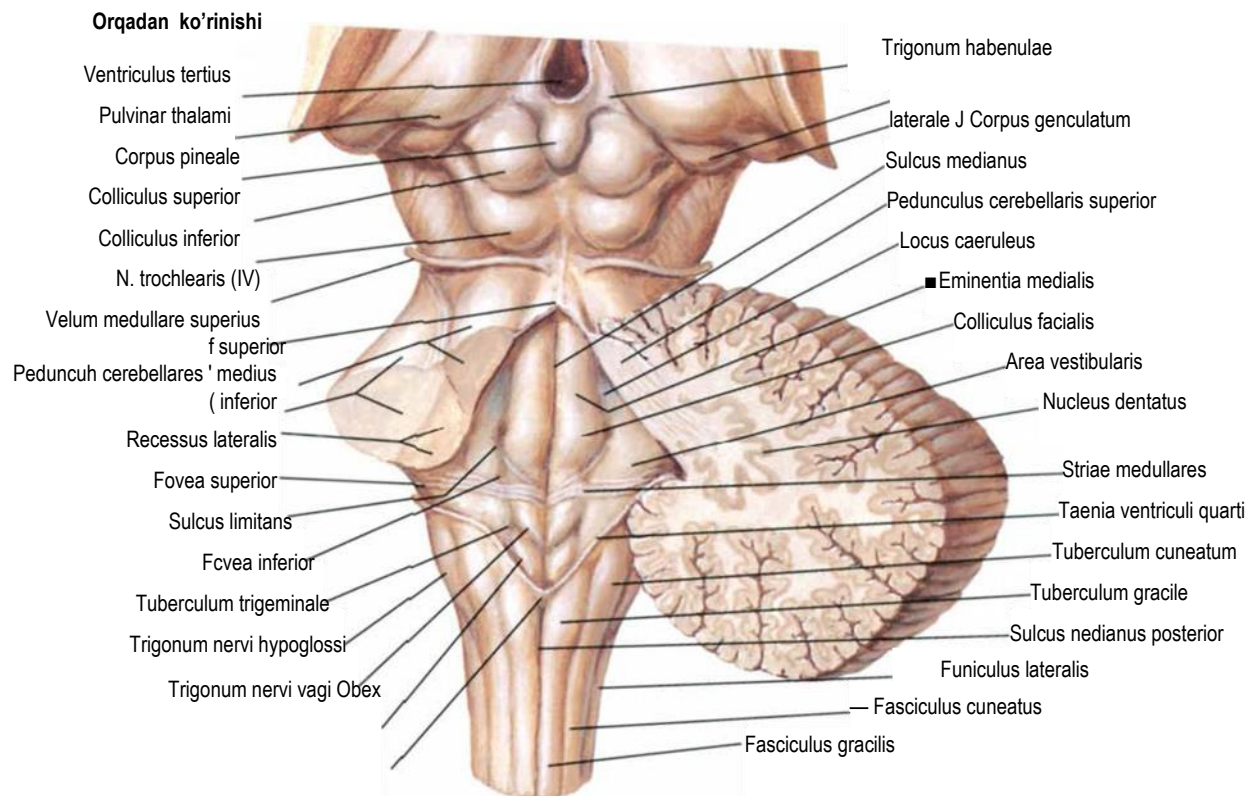


Miyacha tepa oyoqchalari sohasidagi kesim

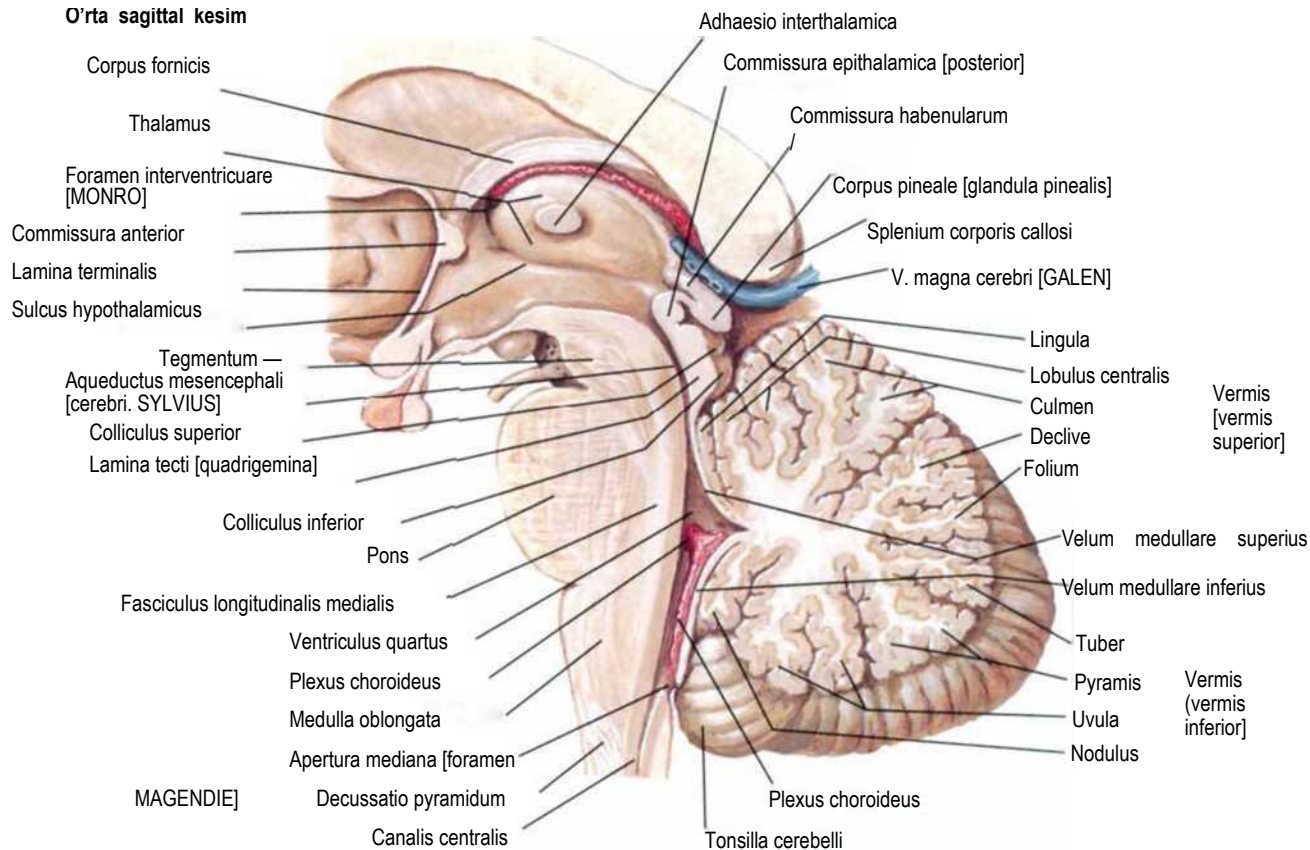
Miya ustuni (truncus encephali)



To'rtinchi qorincha va miyacha



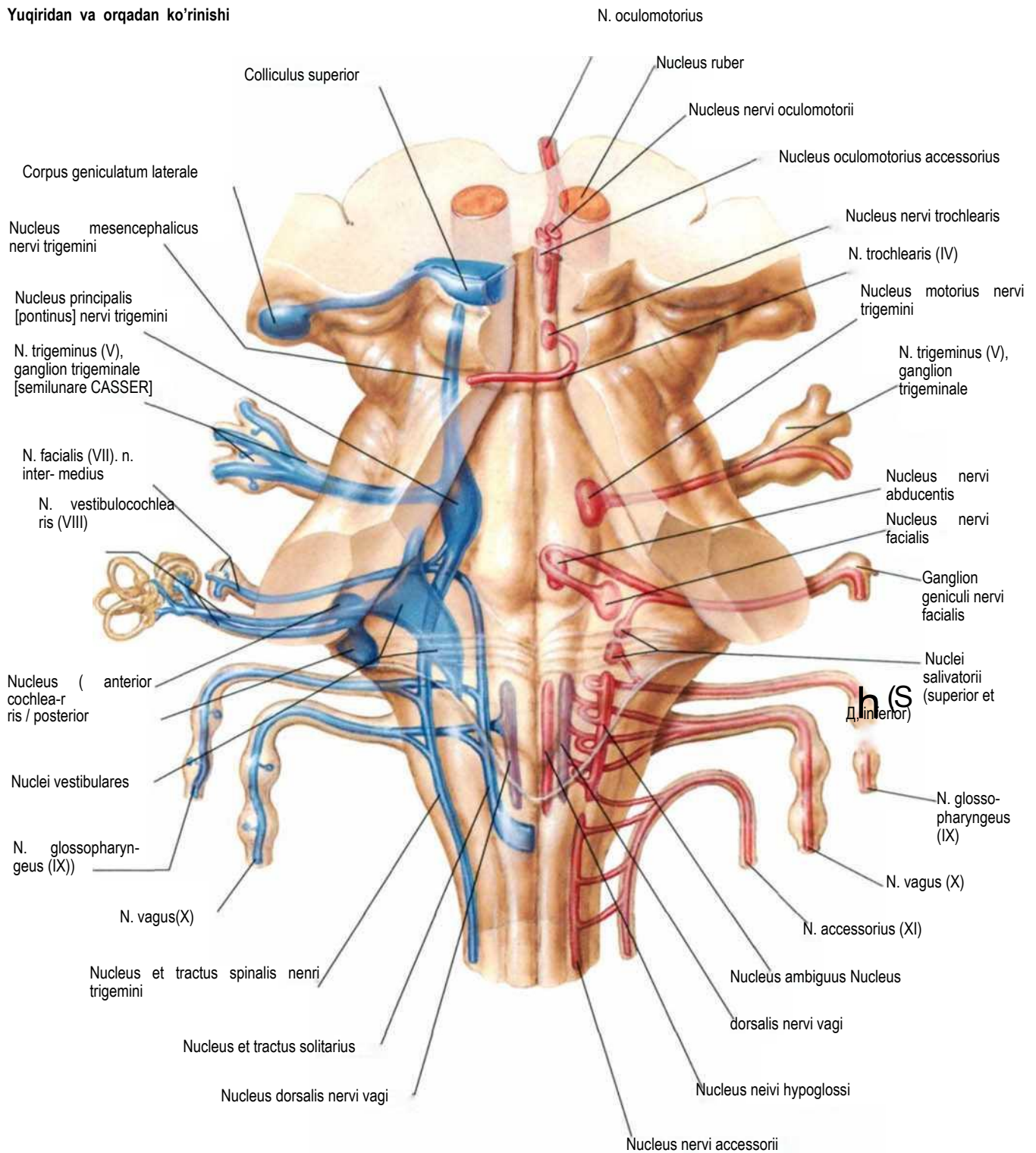
O'rta sagittal kesim



MIYA VA UNING PARDALARI

Miya ustunining bosh miya nervlari sxemasi

Yuqiridan va orqadan ko'rinishi



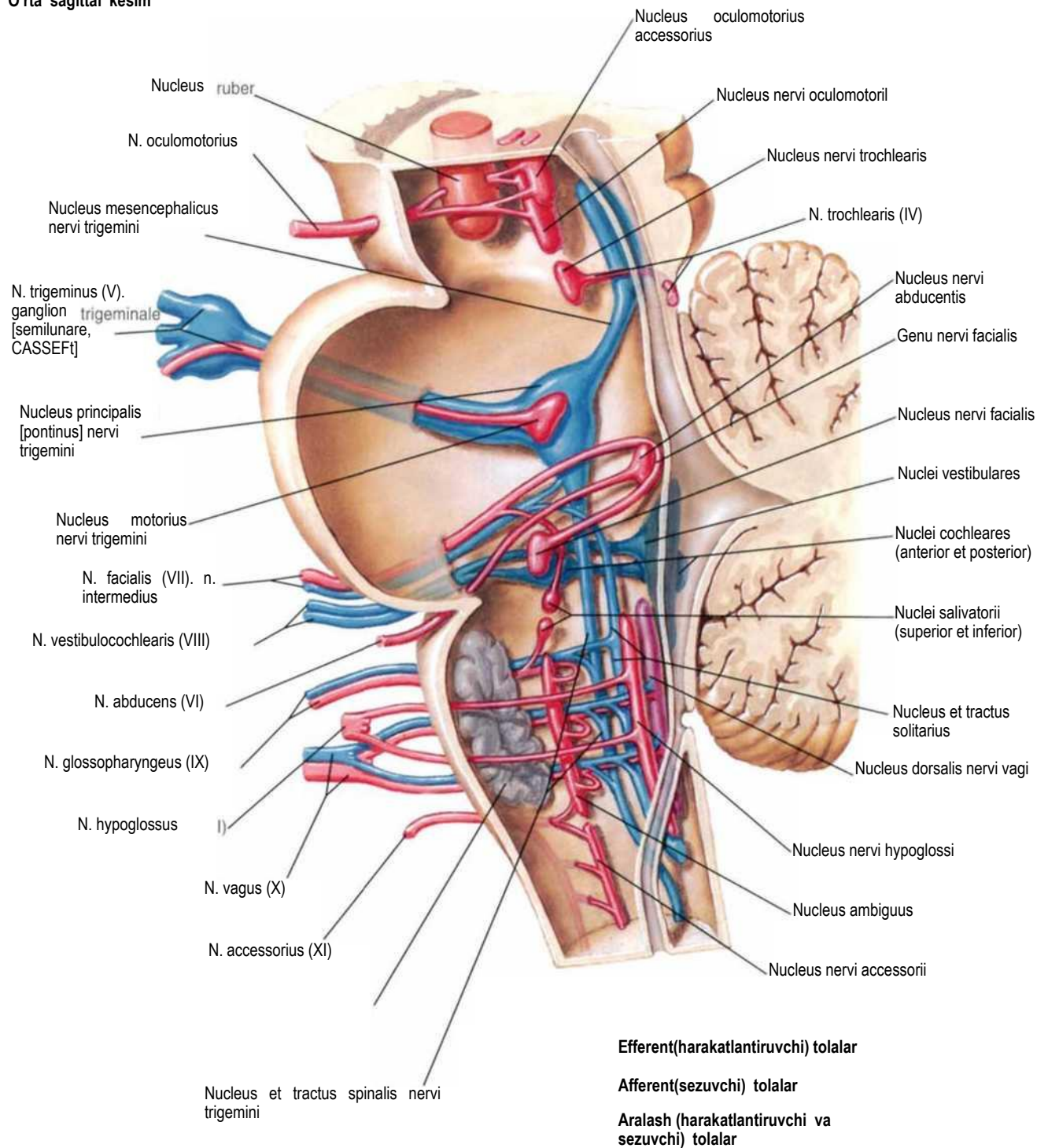
Efferent(harakatlantiruvchi)tolalar

Afferent(sezuvchi)tolalar

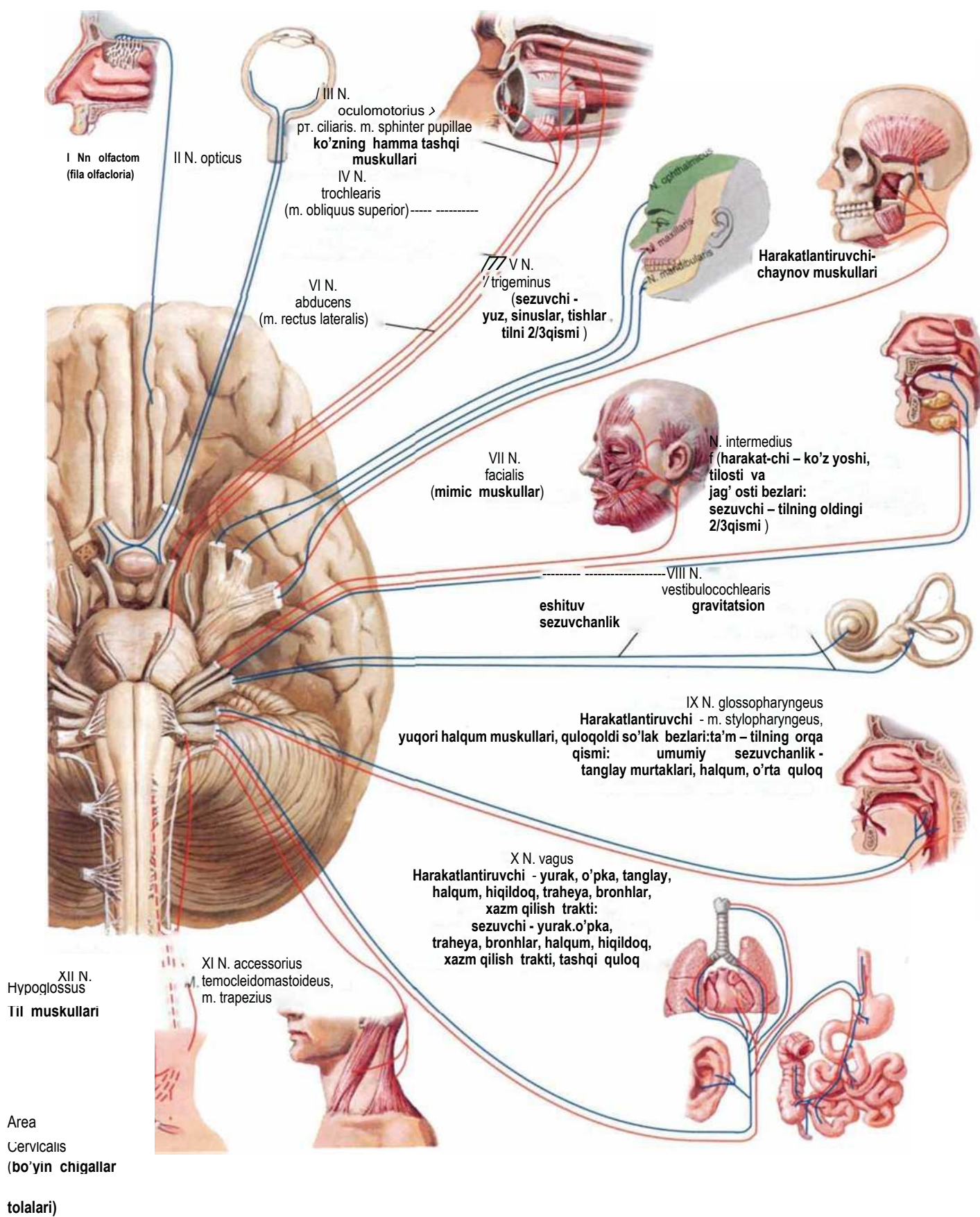
Aralash(harakatlantiruvchi va sezuvchi) tolalar

Miya ustunidagi bosh miya nervlarining sxemasi (davomi)

O'rta sagittal kesim

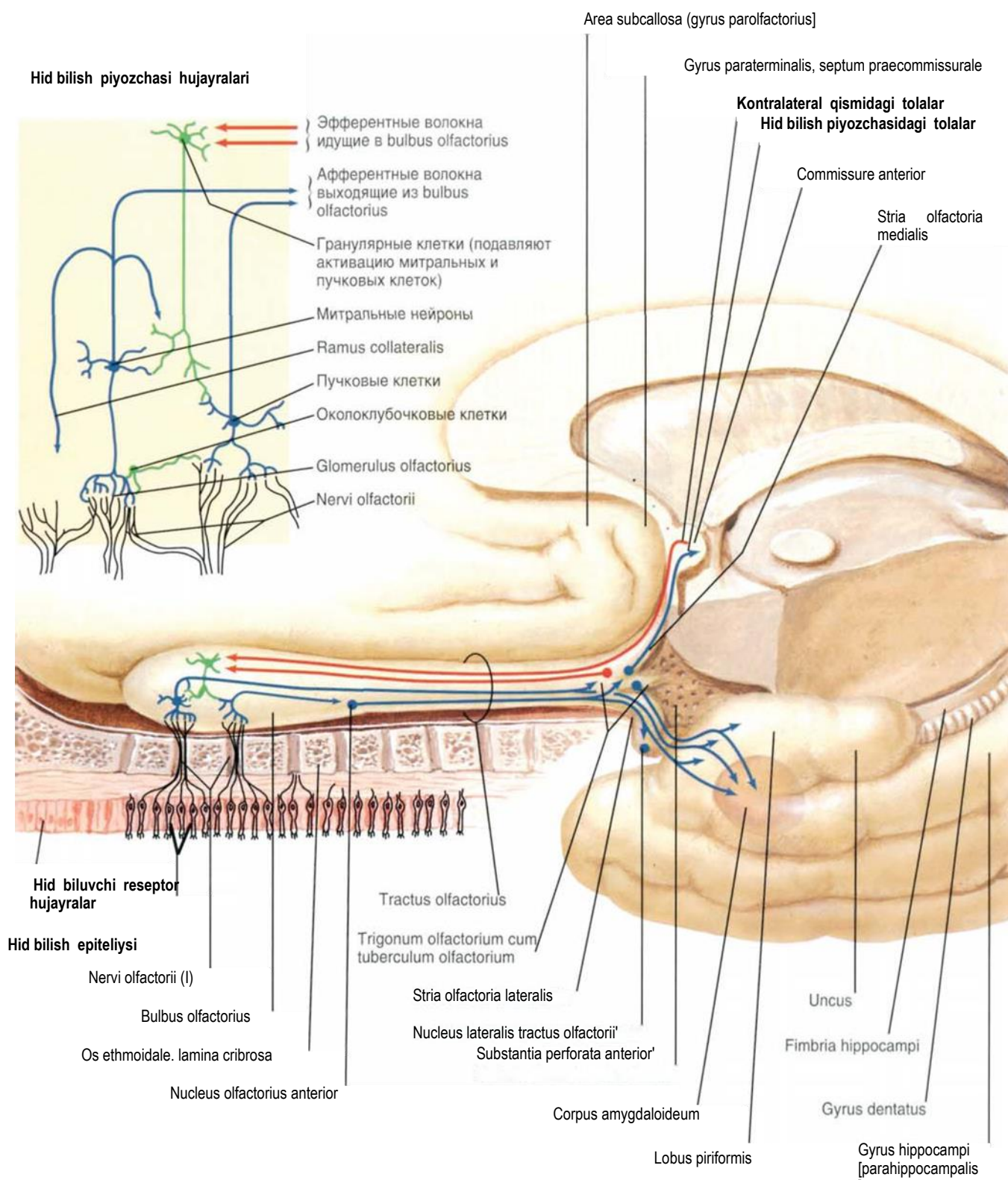


Bosh miya nervlarining harakatlantiruvchi va sezuvchi tolalari

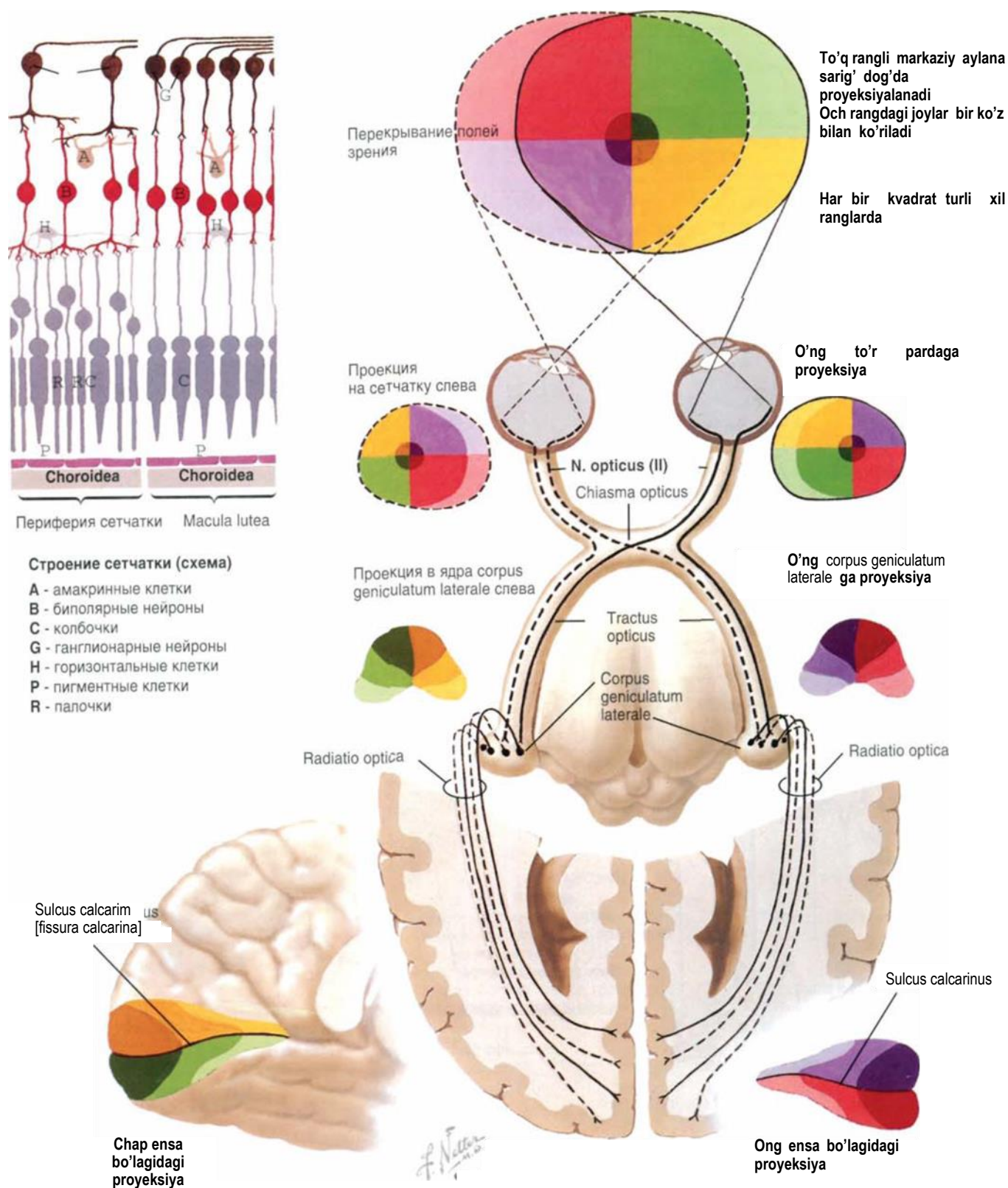


BOSH VA BO'YIN

Hid bilish nervi (nervus olfactorius [fila olfactoria])

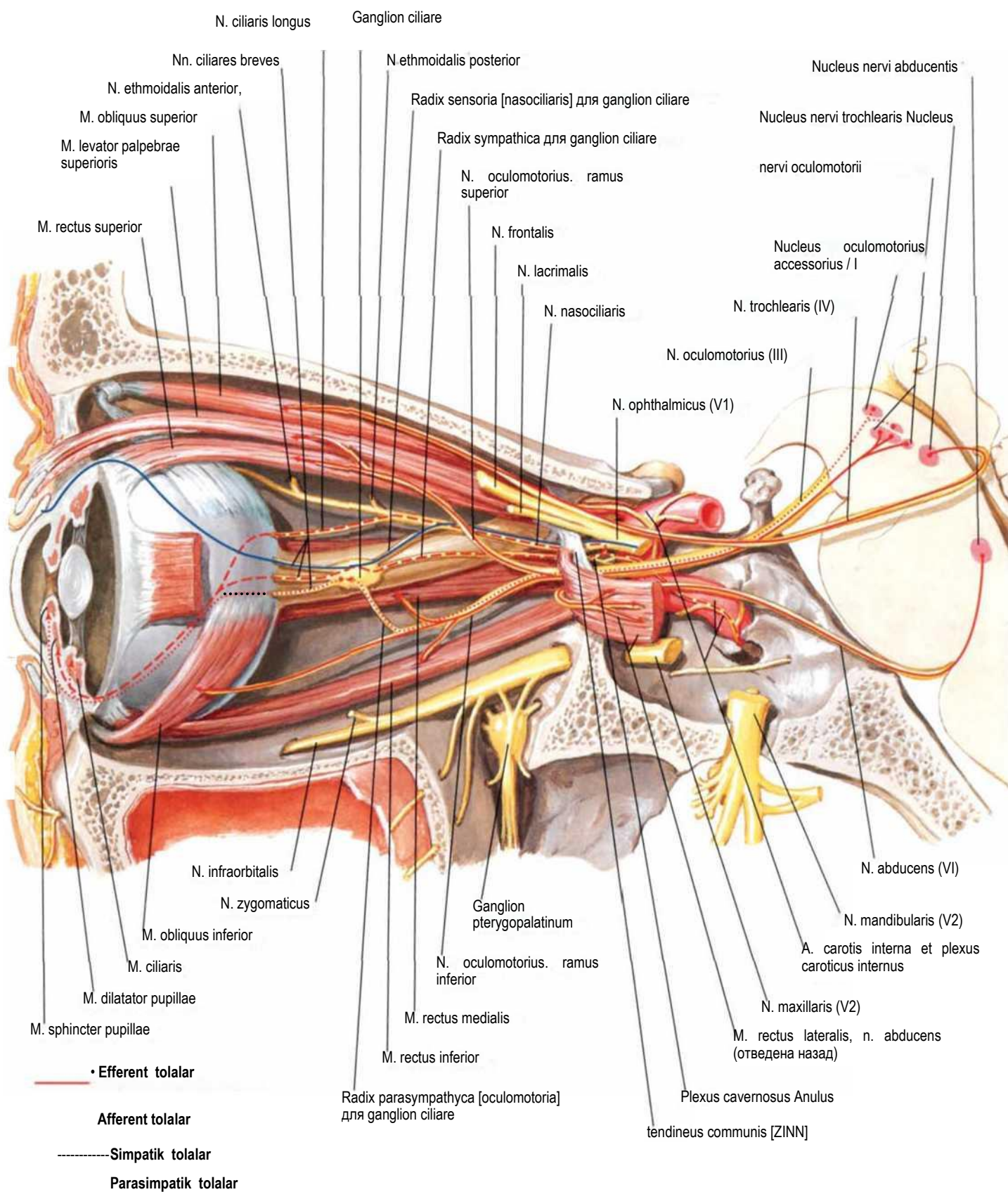


Ko'ruv nervi (nervus opticus)



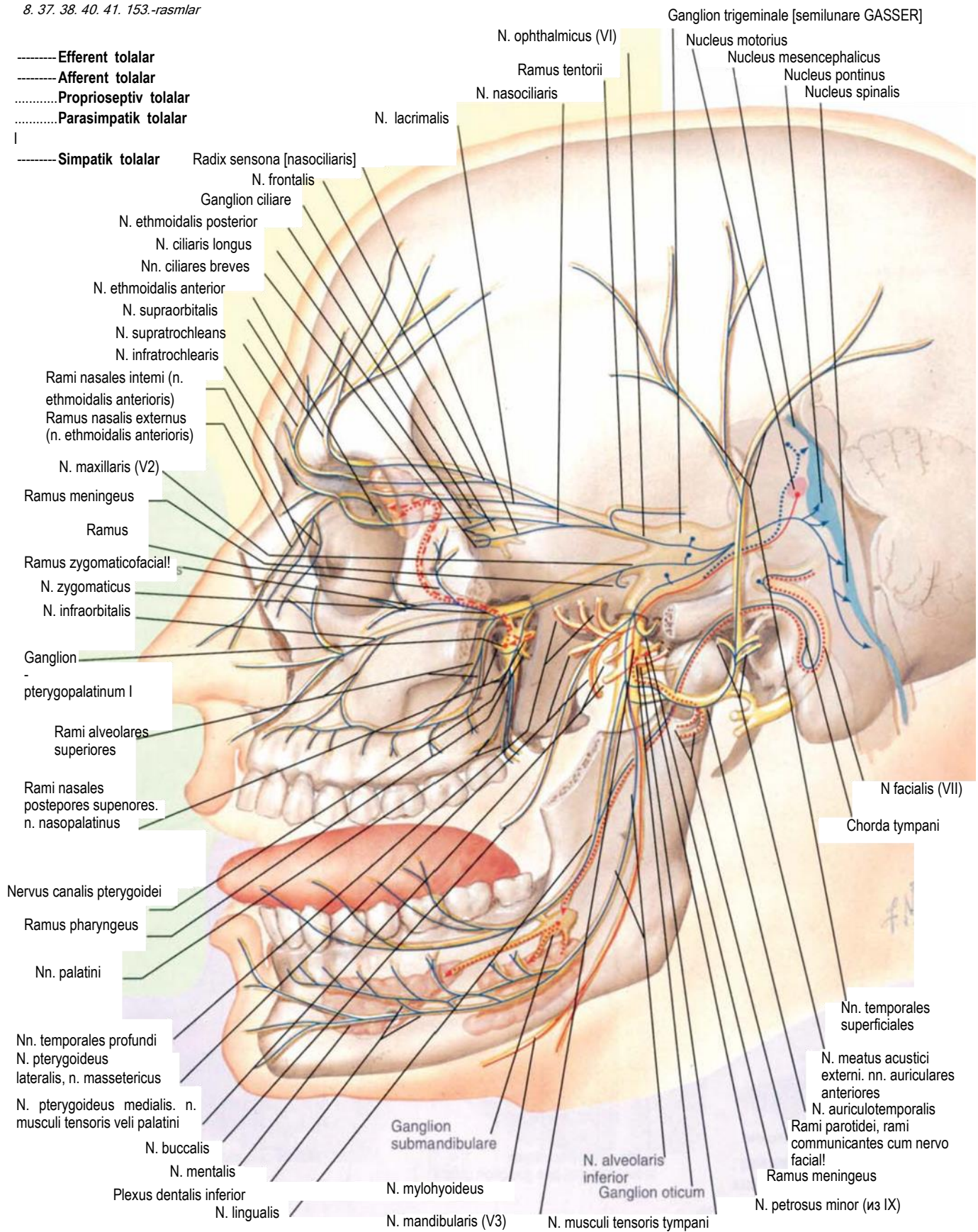
Ko'zni harakatlantiruvchi, uzoqlashtiruvchi va g'altak nervi

81. 126. 153-rasmlar



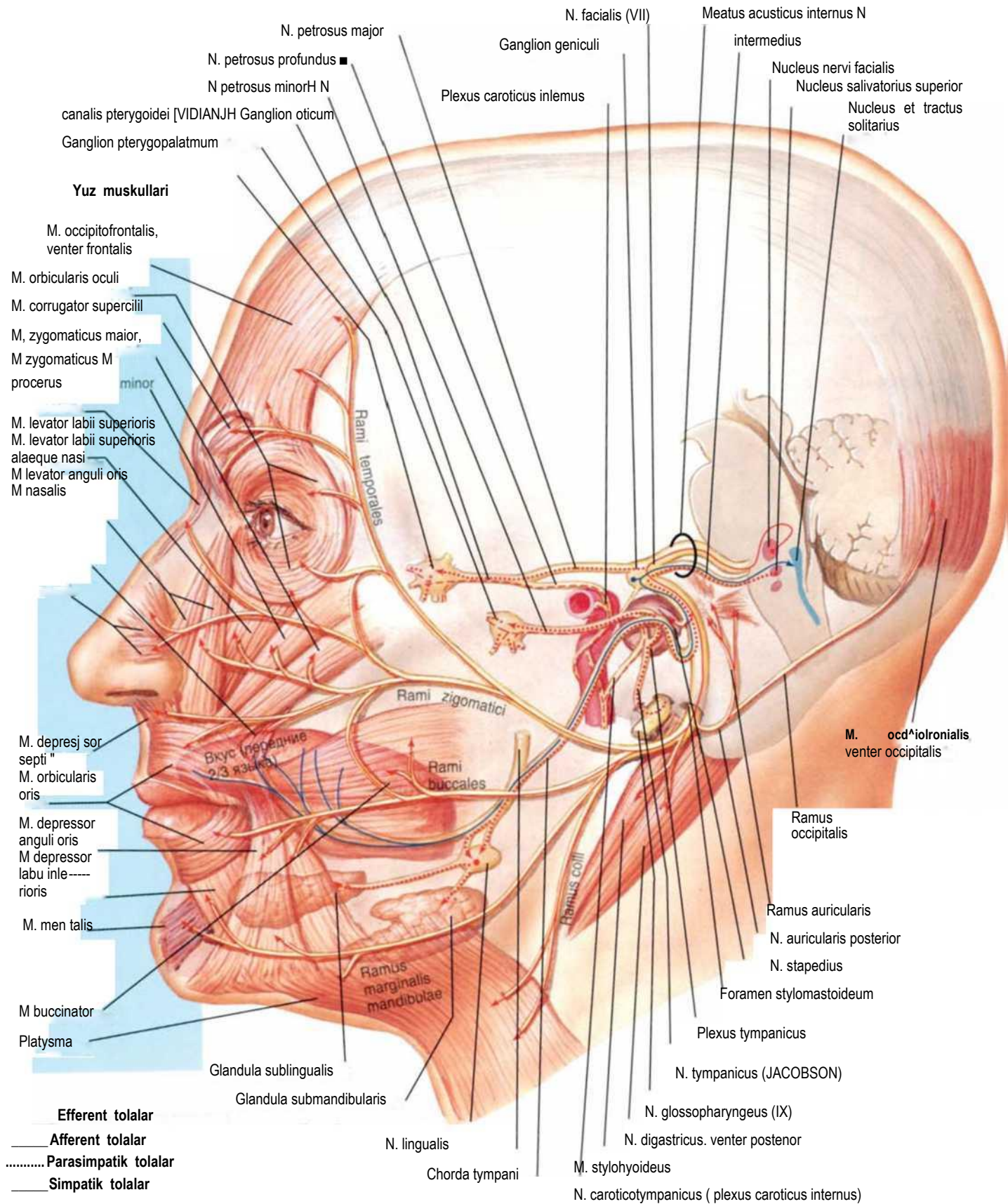
Uch shoxli nerv (n. trigeminus)

8. 37. 38. 40. 41. 153.-rasmlar

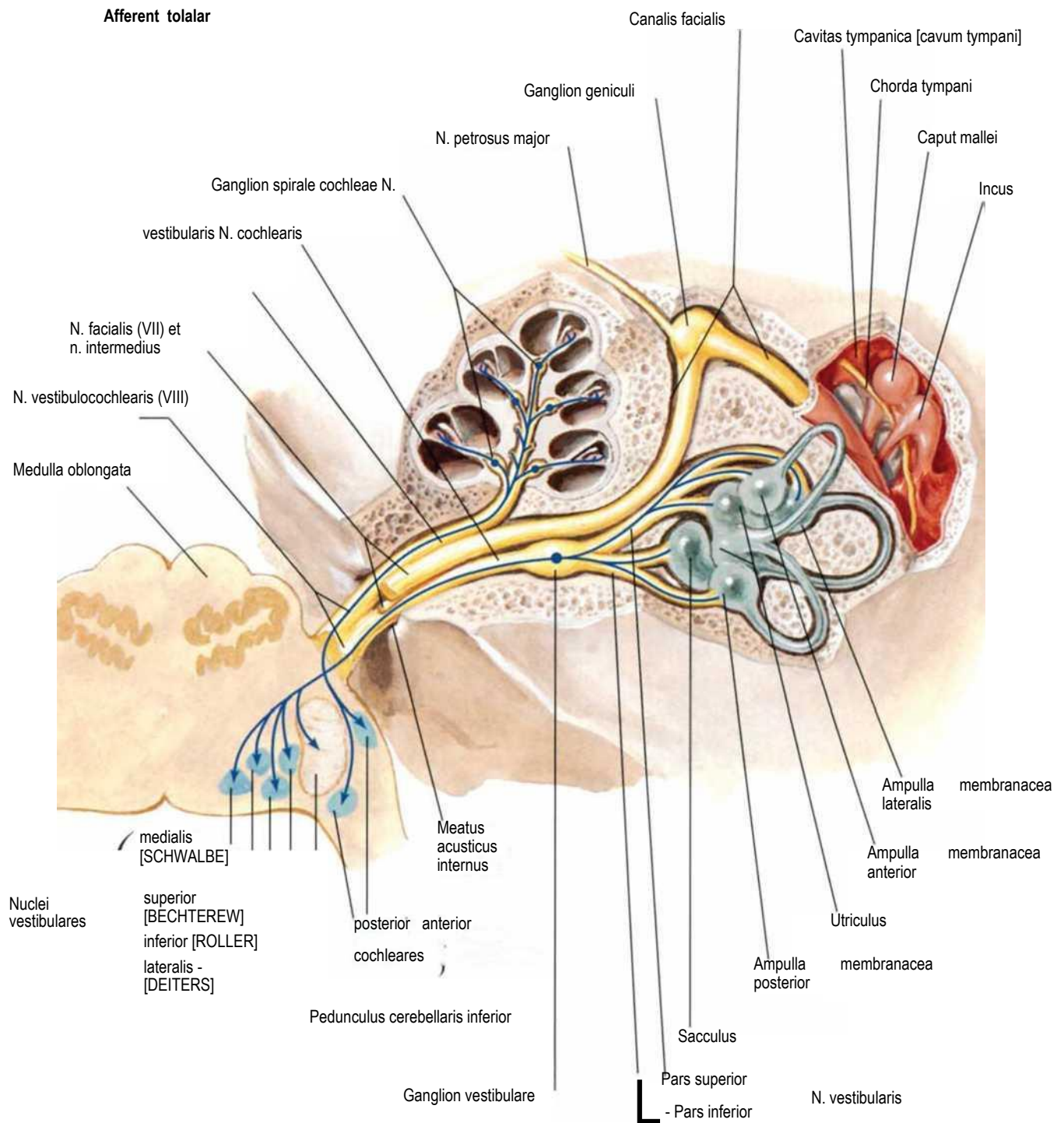


Yuz nervi (n. facialis)

19. 153-rasmlar.

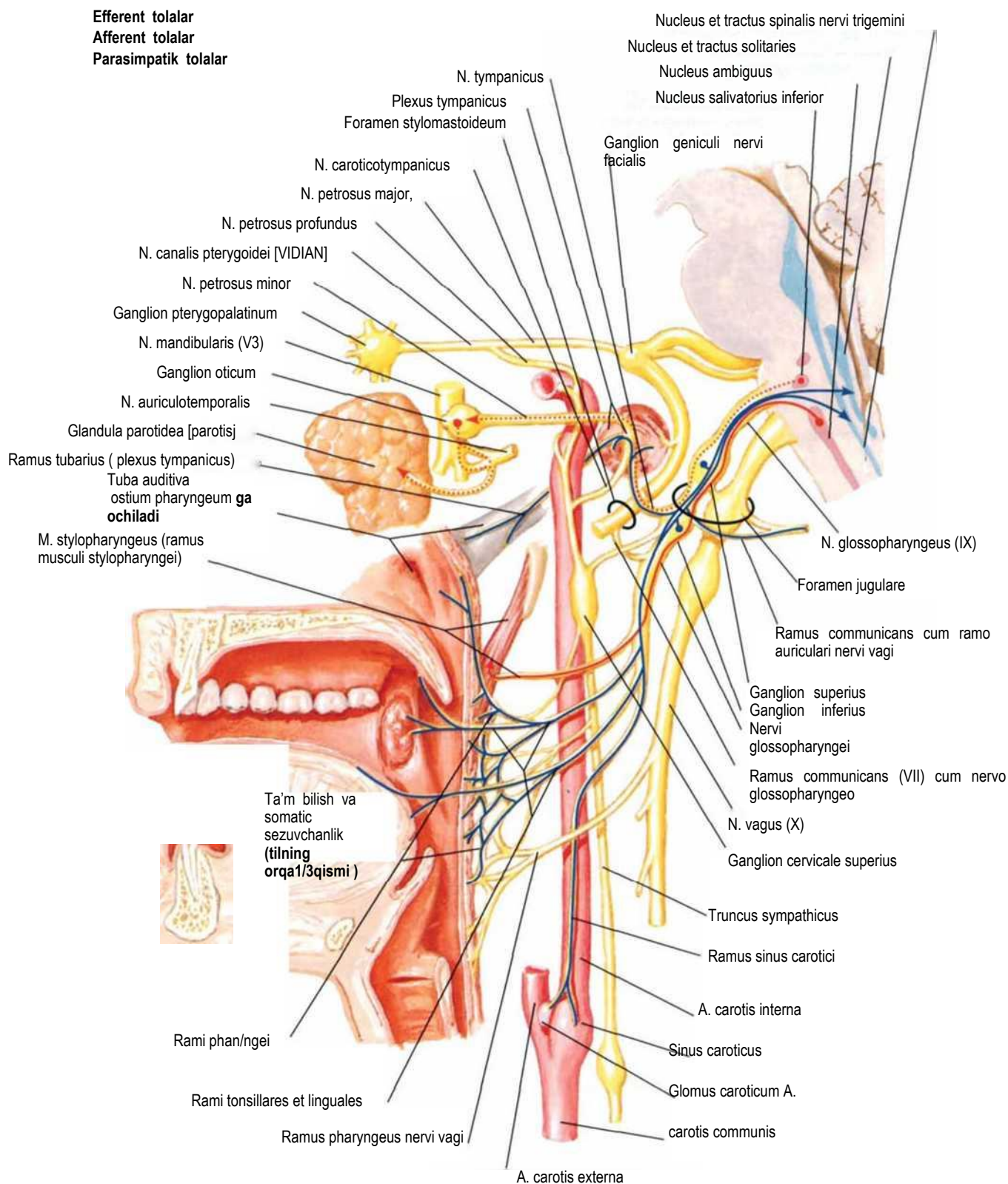


Daxliz-chig'anoq nervi (n. vestibulocochlearis)



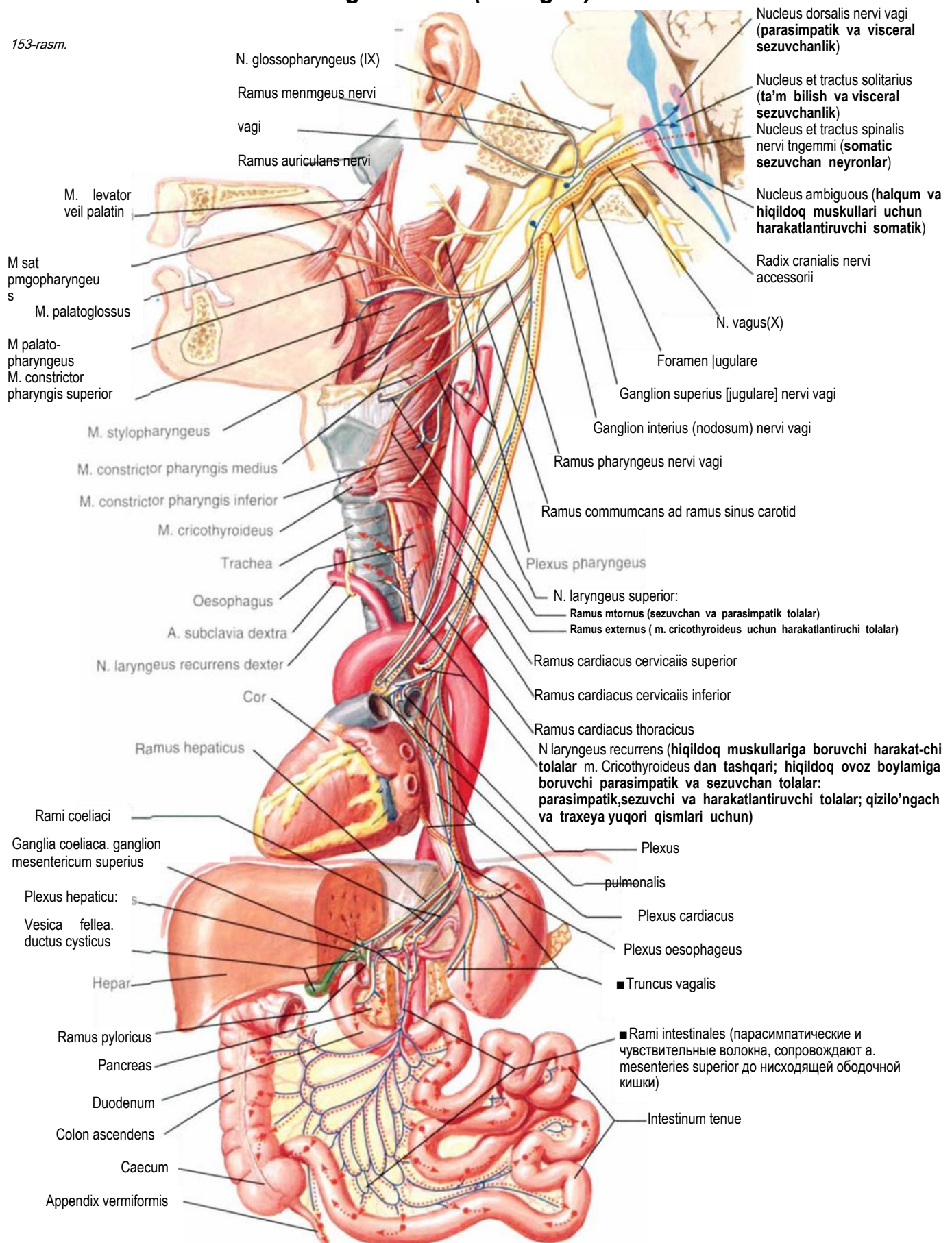
Til-halqum nervi (n. glossopharyngeus)

153-rasm.



Adashgan nerv (n. vagus)

153-rasm.

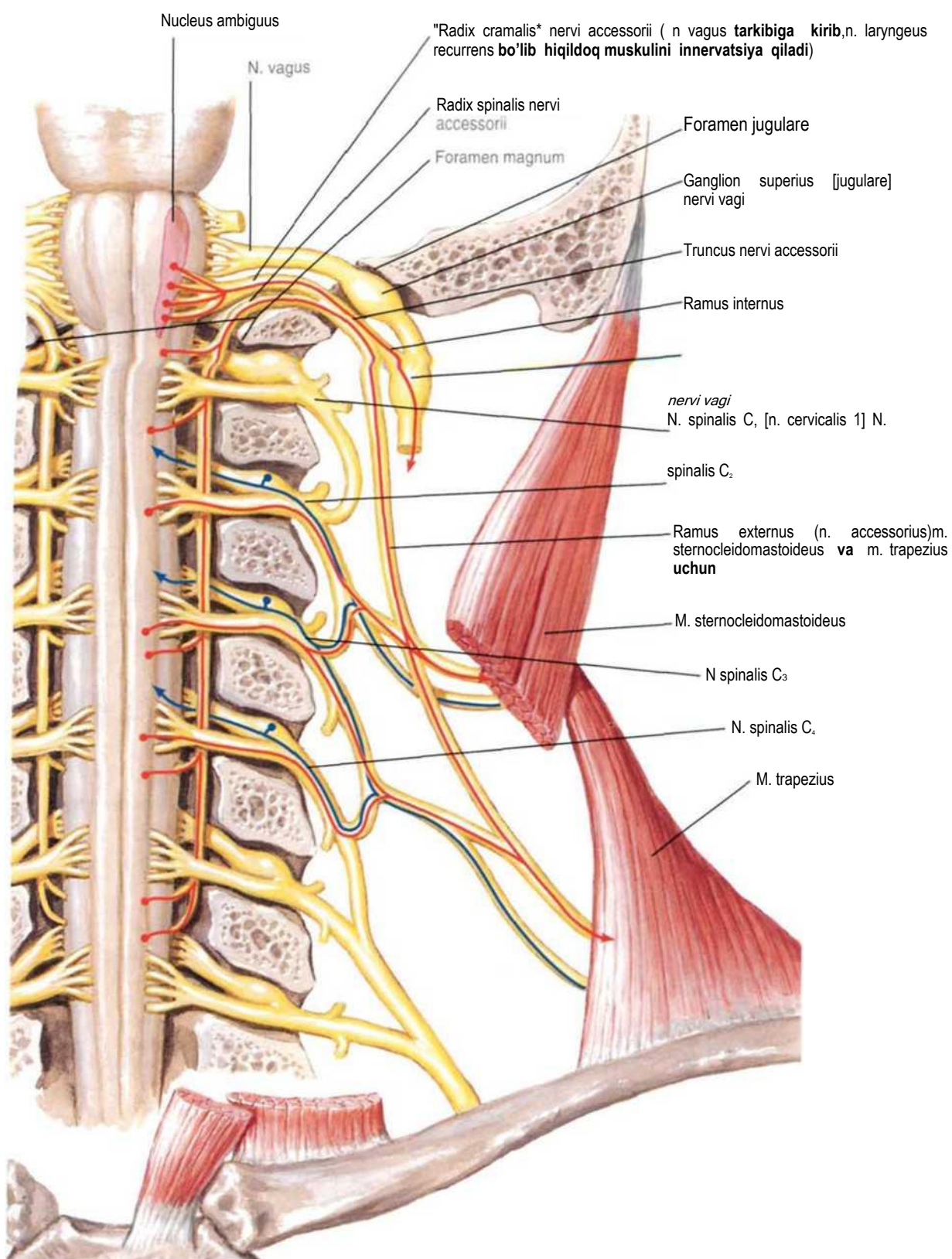


120-rasm

BOSH VA BO'YIN

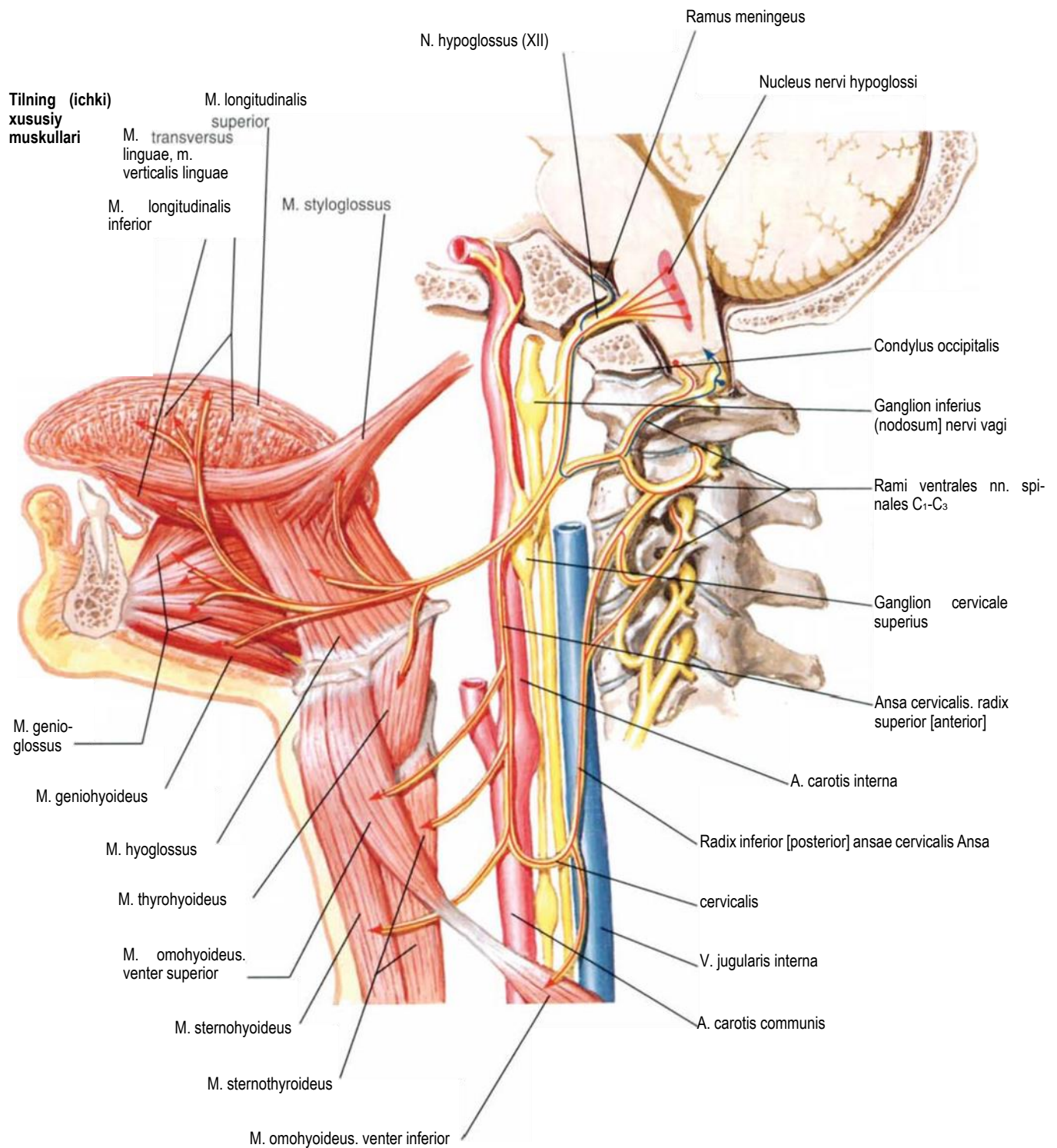
Qo'shimcha nerv (n. accessorius)

27-rasm.



Tilosti nervi (n. hypoglossus)

27-rasm.

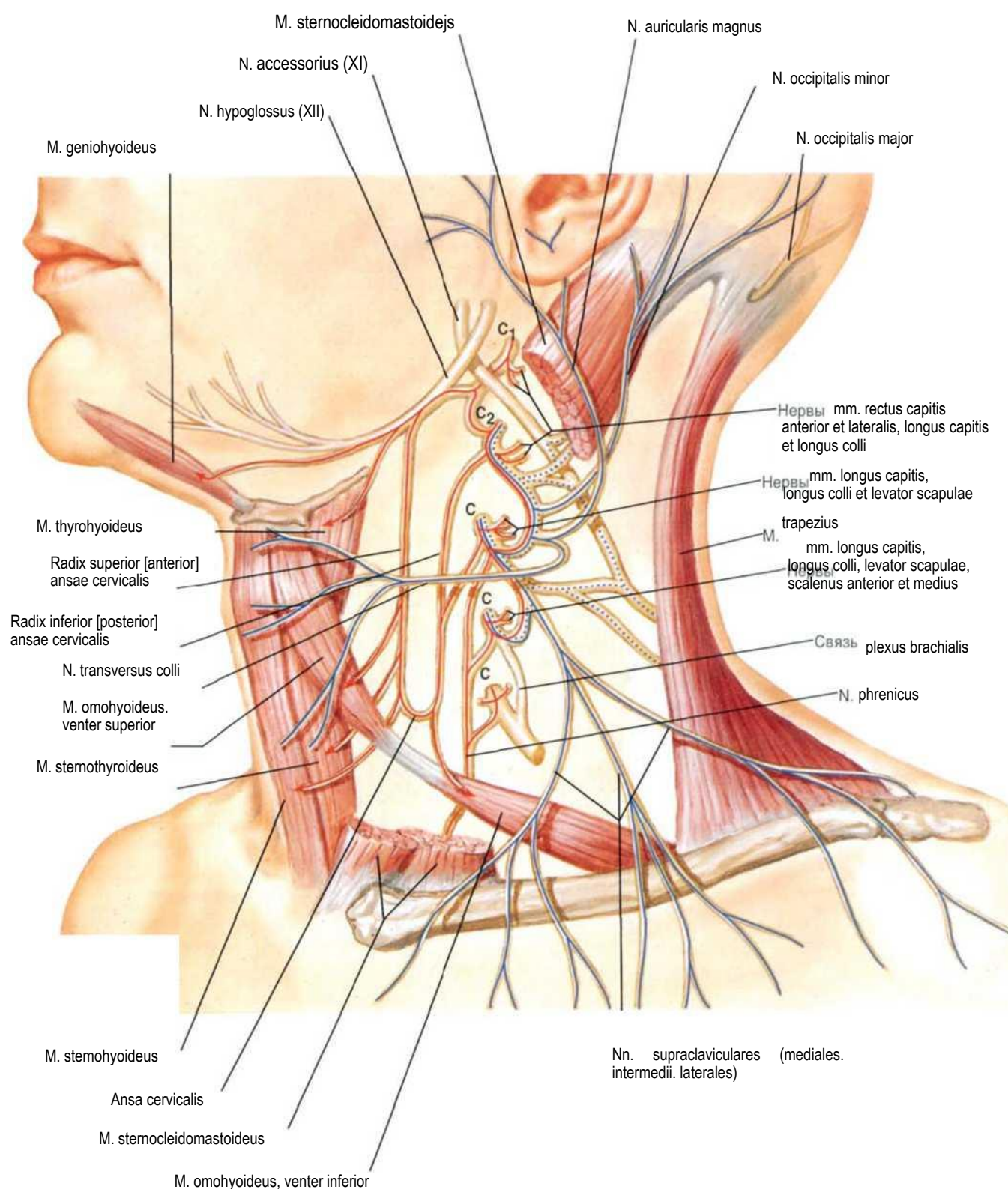


122-rasm

BOSH VA BO'YIN

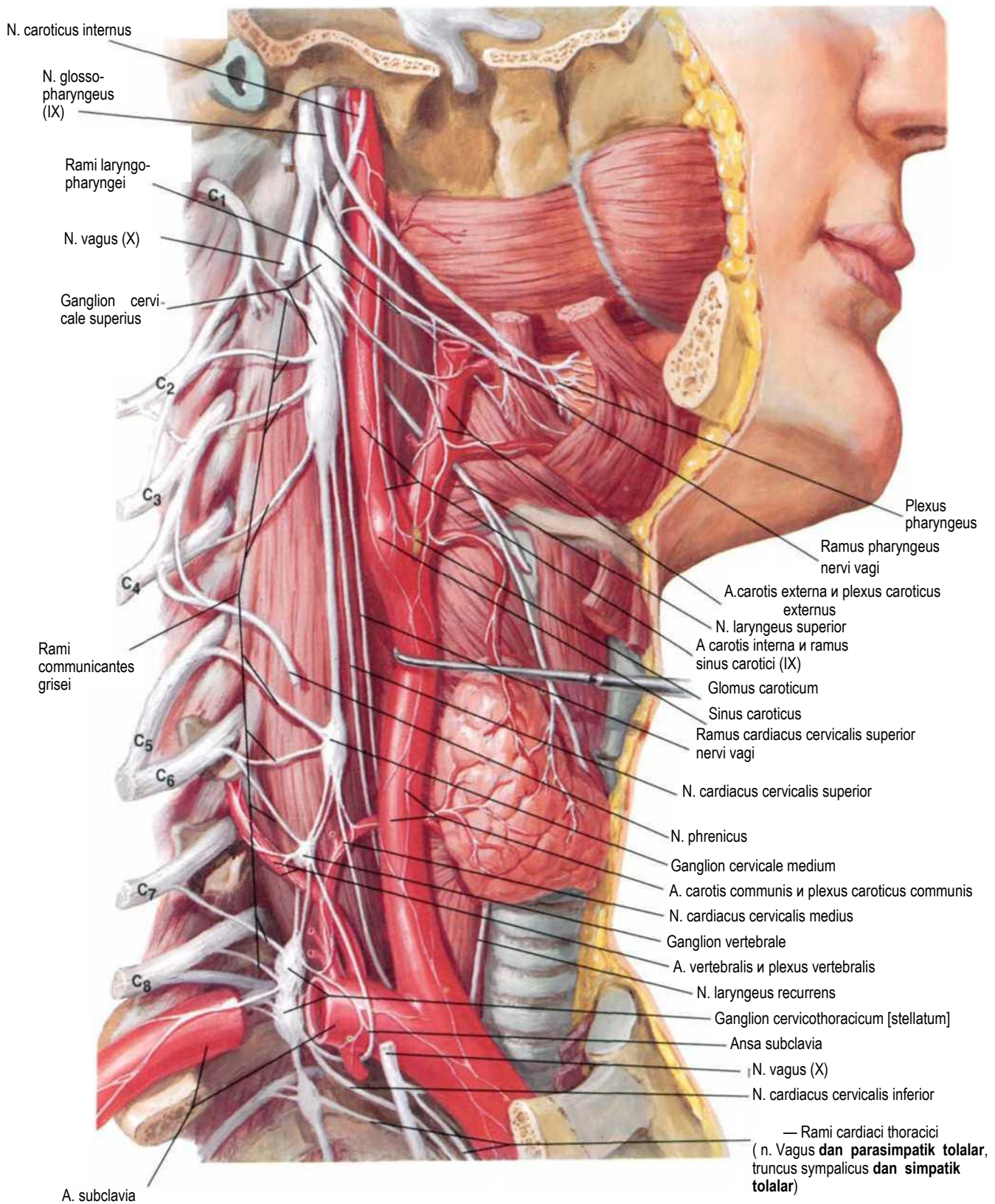
Bo'yin chigali (plexus cervicalis)

27-rasm.



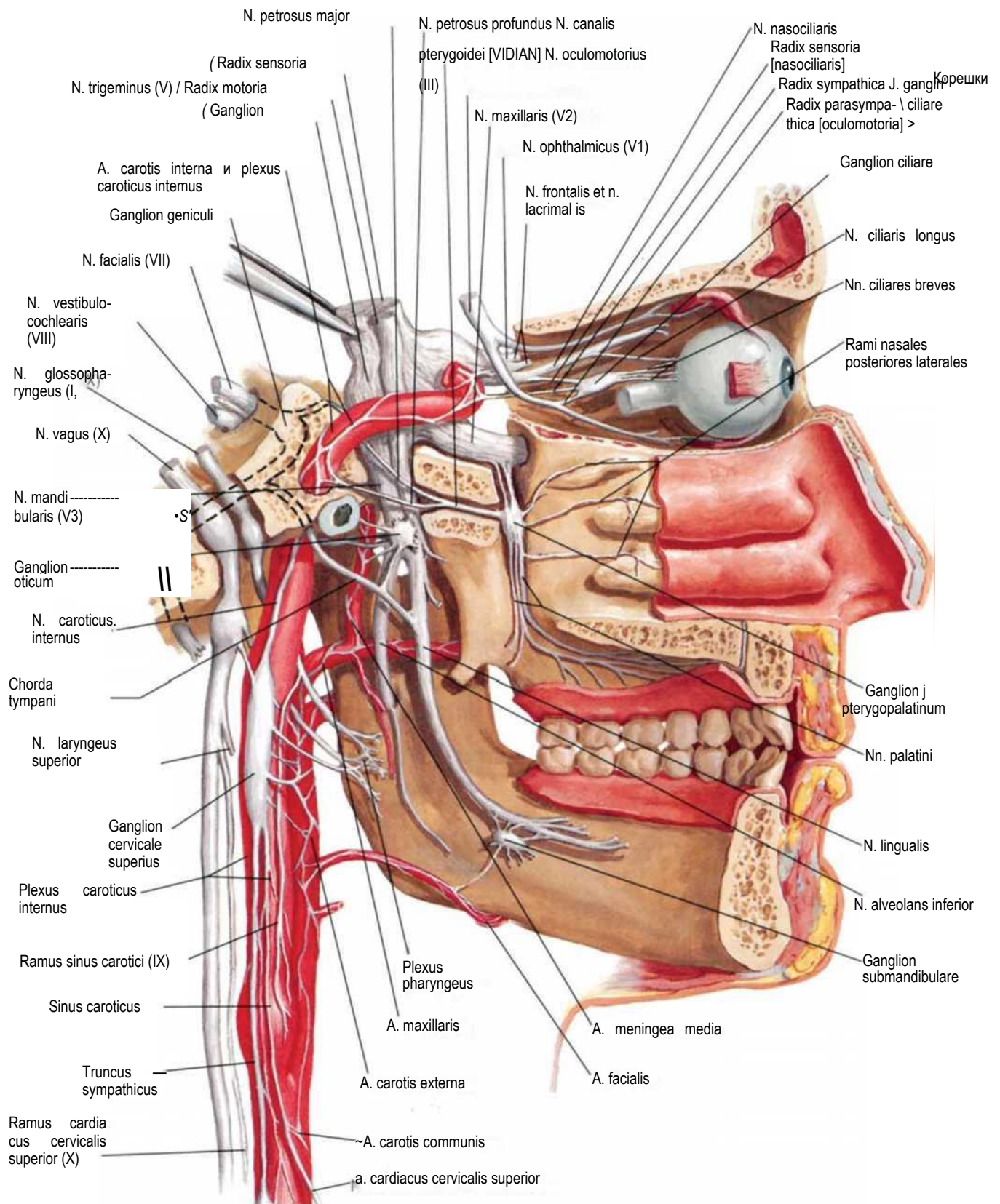
Bo'yinning avtonom (vegetativ) nervlari

65. 119. 120. 152. 198. 214. 228. 300-rasmlar



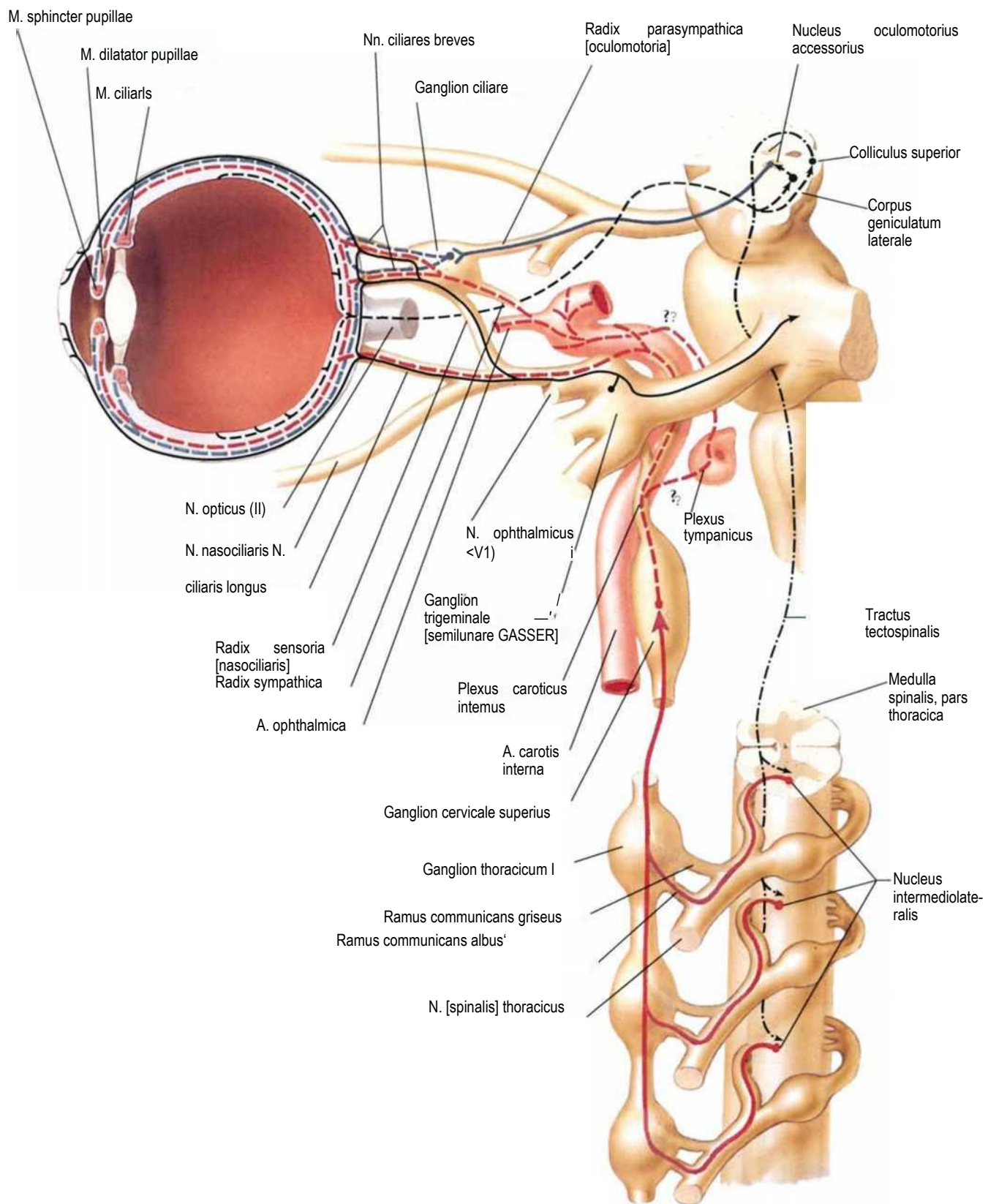
Boshning avtonom (vegetativ) nervlari

39. 40. 41. 81. 115. 126-128. 152-rasmlar.



Kiprikli tugun (ganglion cilia re)

153-rasm.

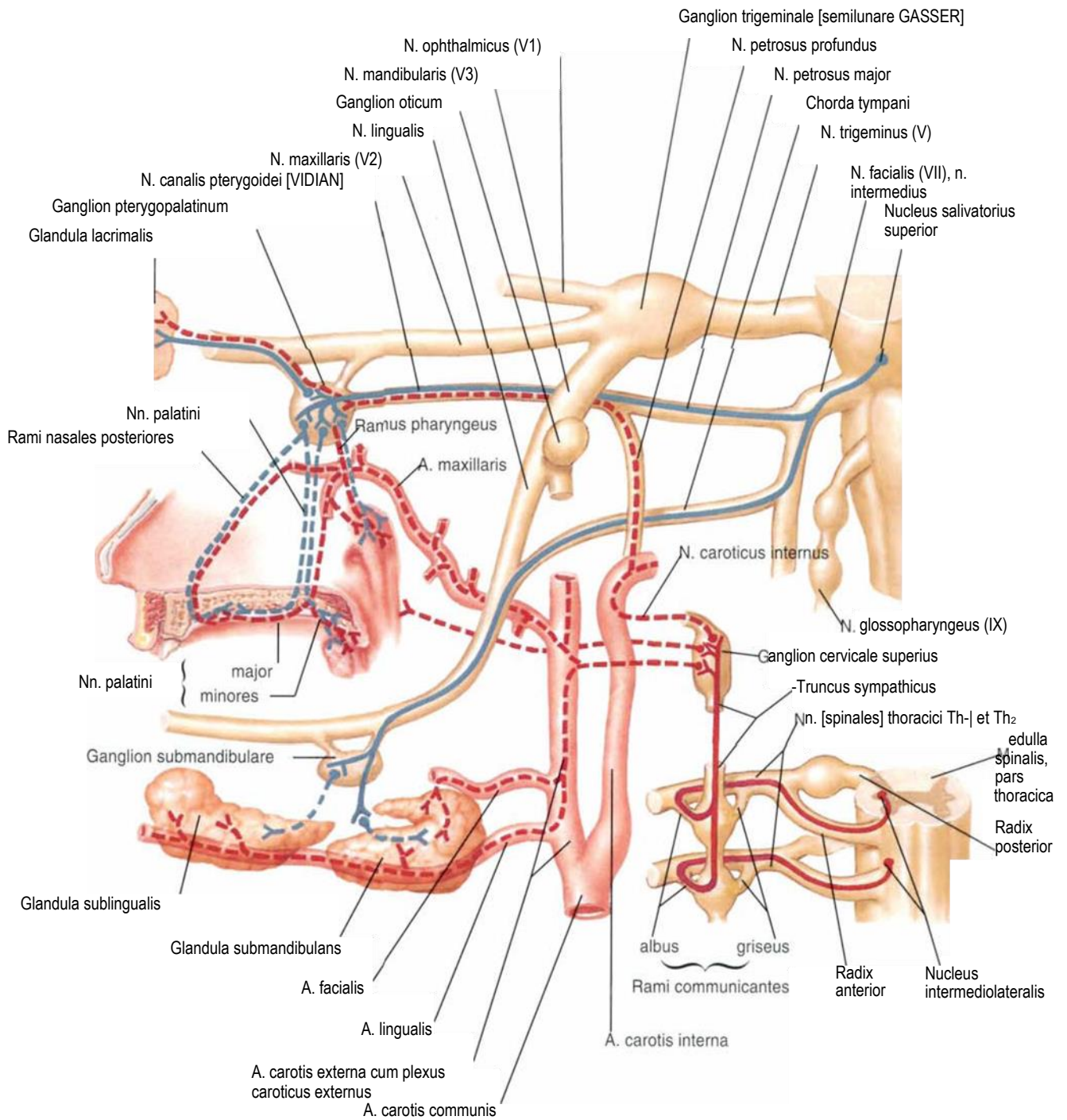


126-rasm

BOSH VA BO'YIN

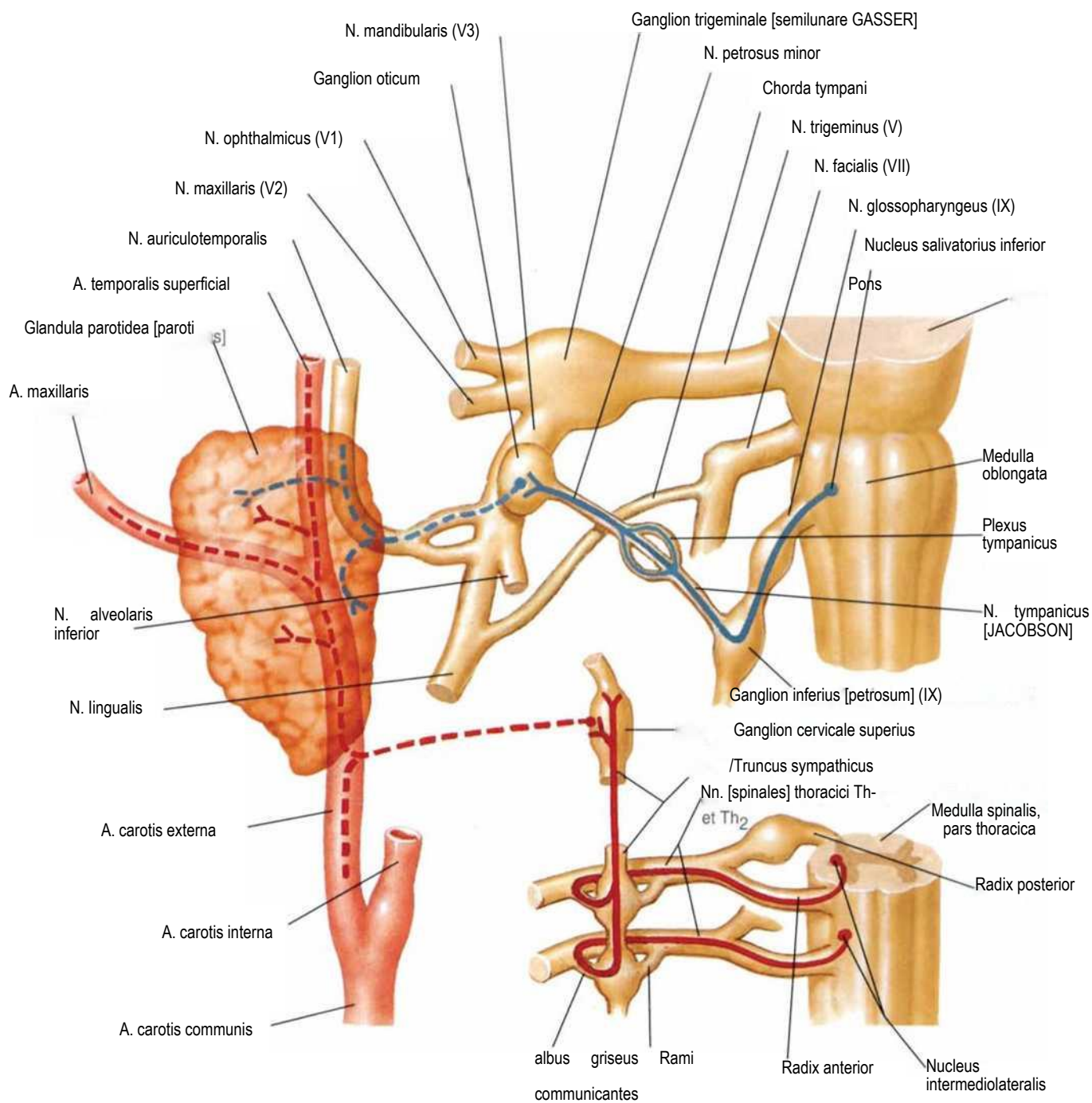
Qanot-tanglay va jag'osti tugunlari

153-rasm.



Quloq tuguni (ganglion oticum)

153-rasm.

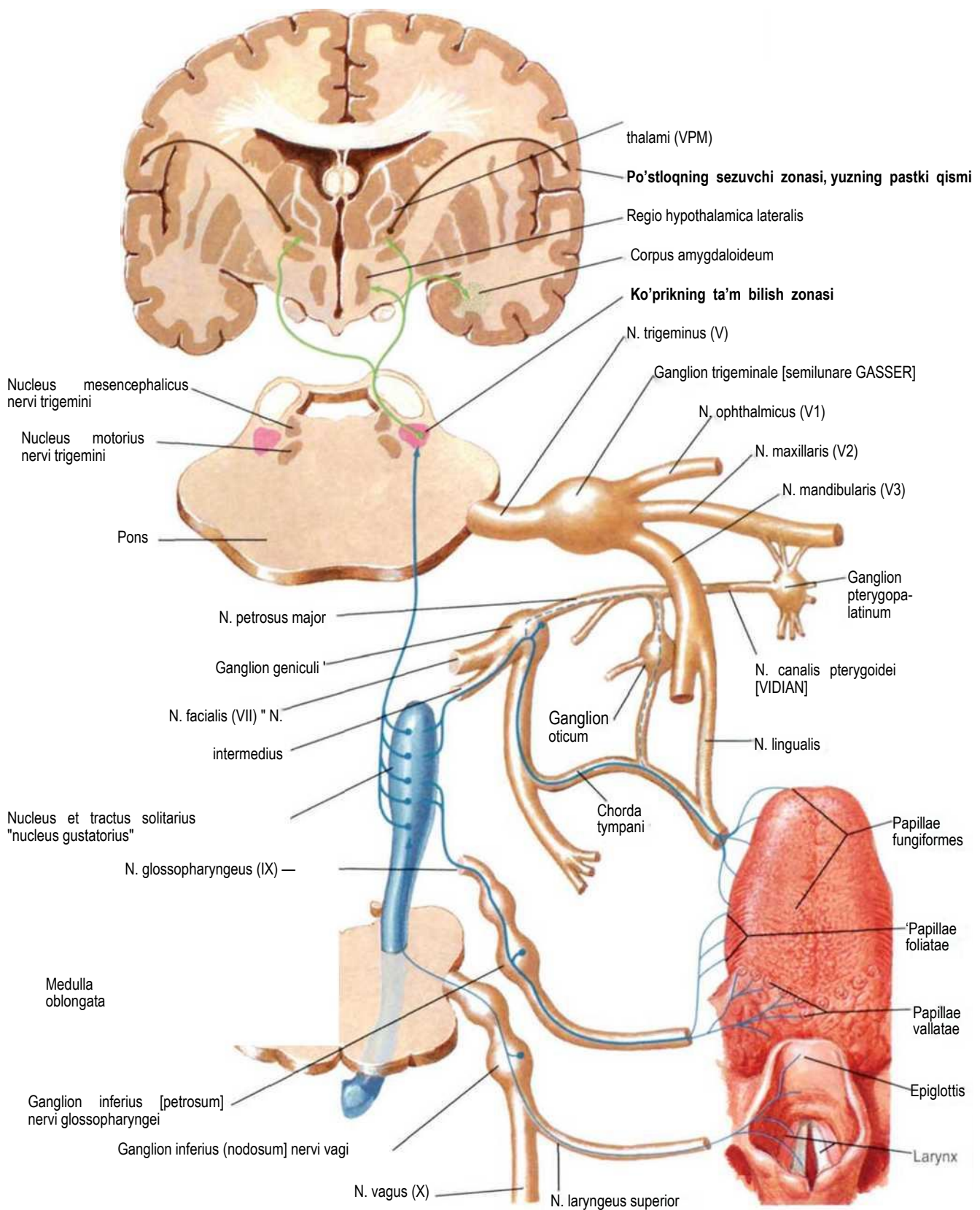


128-rasm

BOSH VA BO'YIN

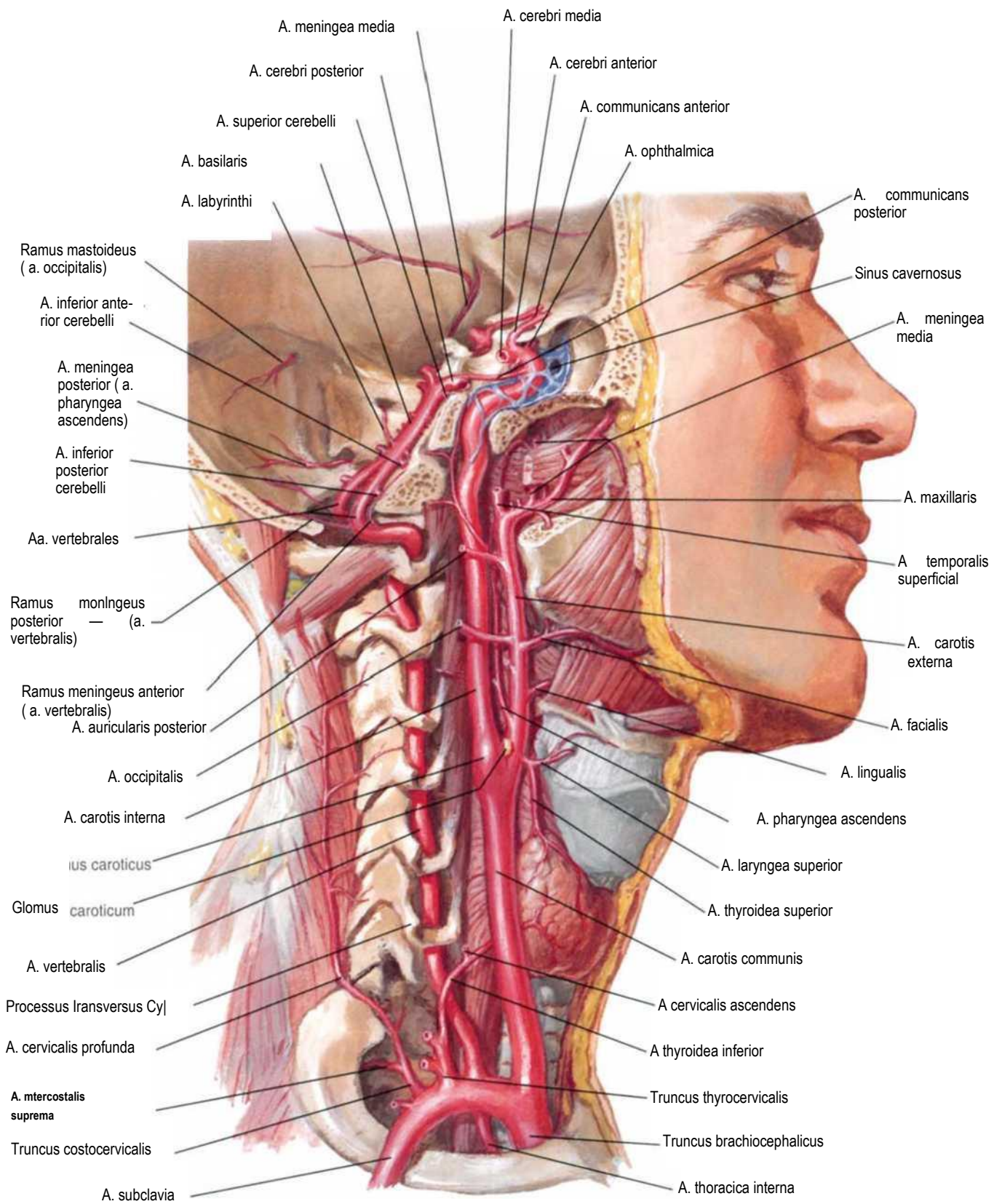
Ta'm bilish sezgisi

41. 89. 117. 119. 120-rasmlar.



Bosh miya va uning pardasining arteriyalari

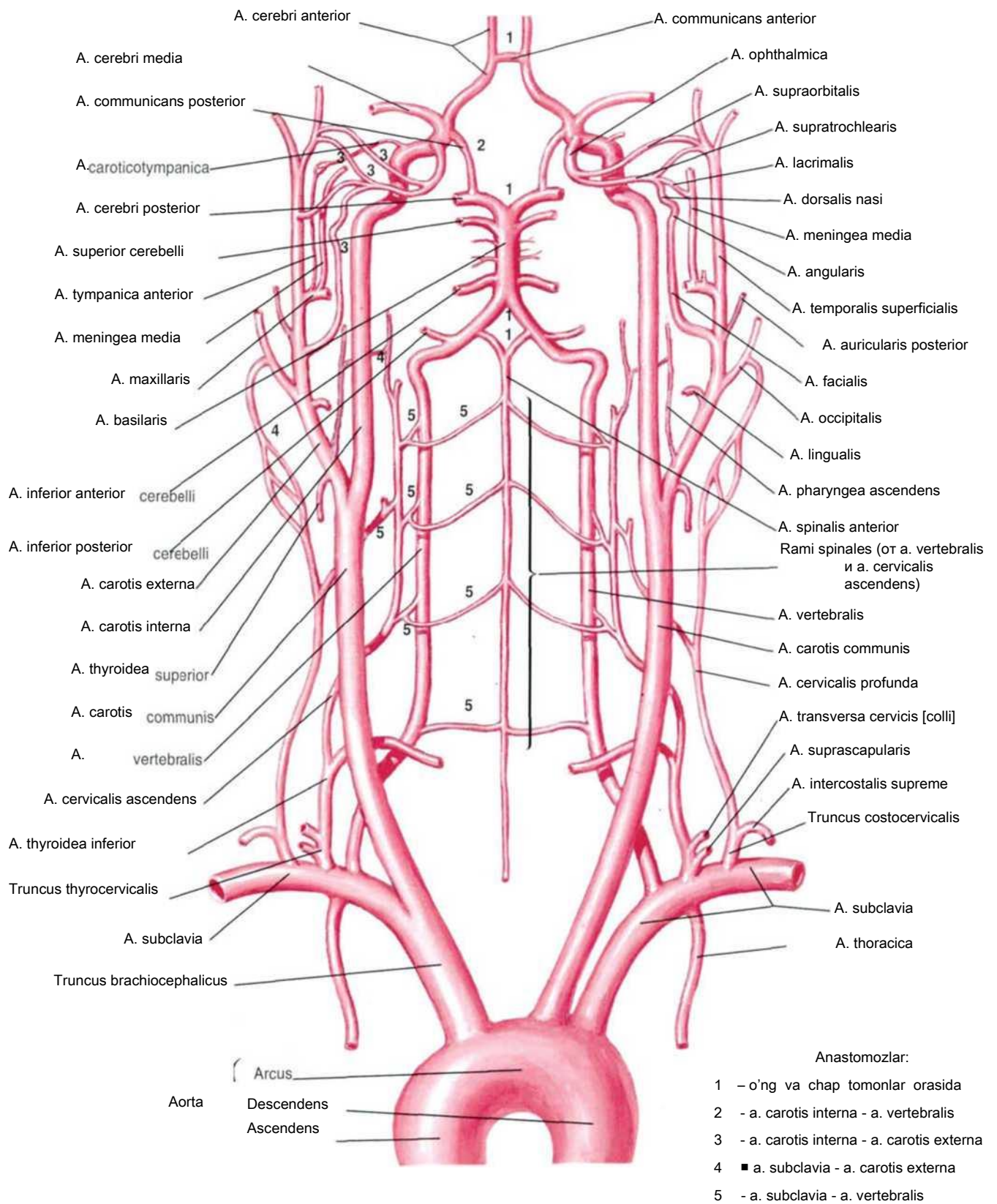
28. 29-rasmlar.



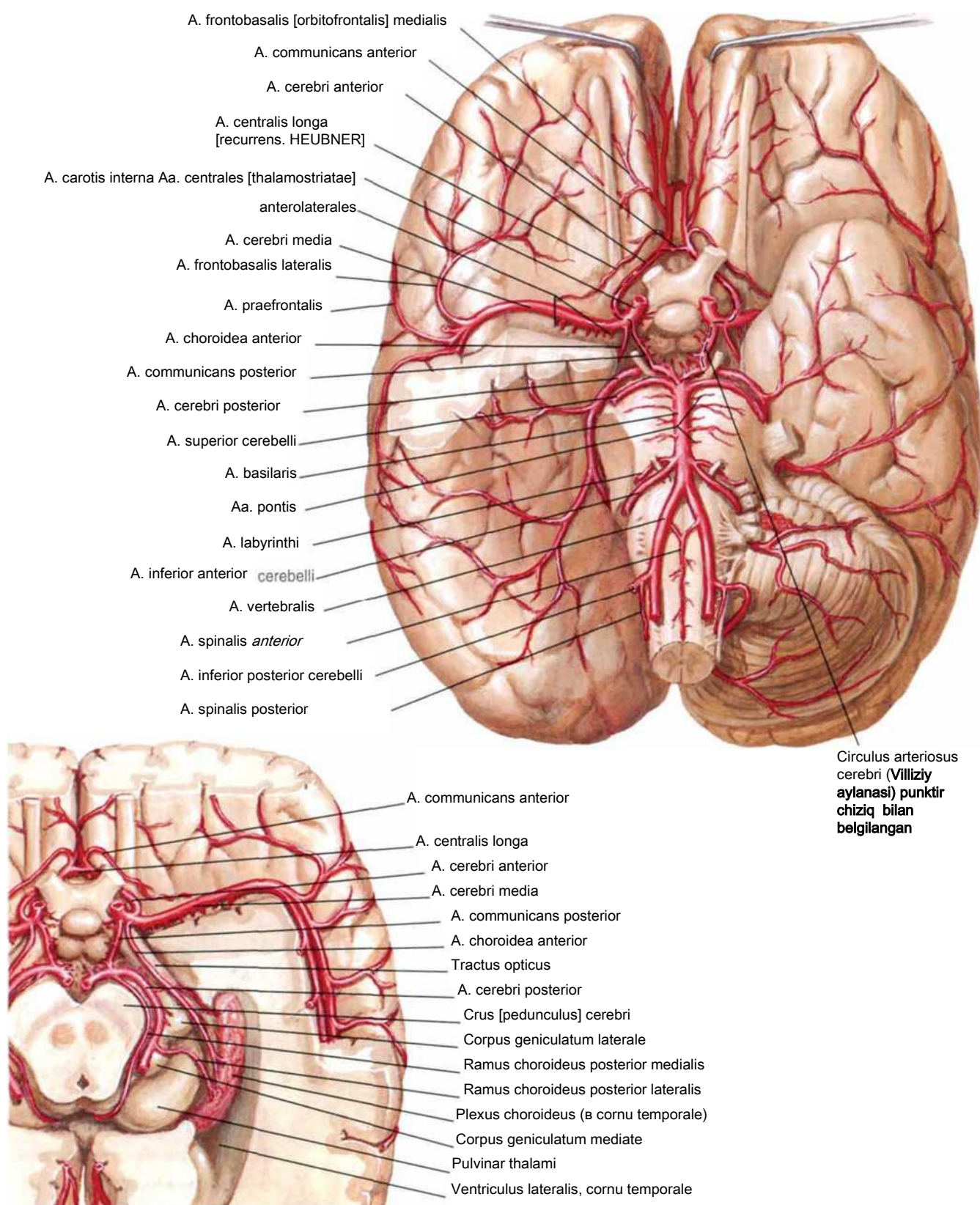
130-rasm

BOSH VA BO'YIN

Bosh miya arteriyalari sxemasi



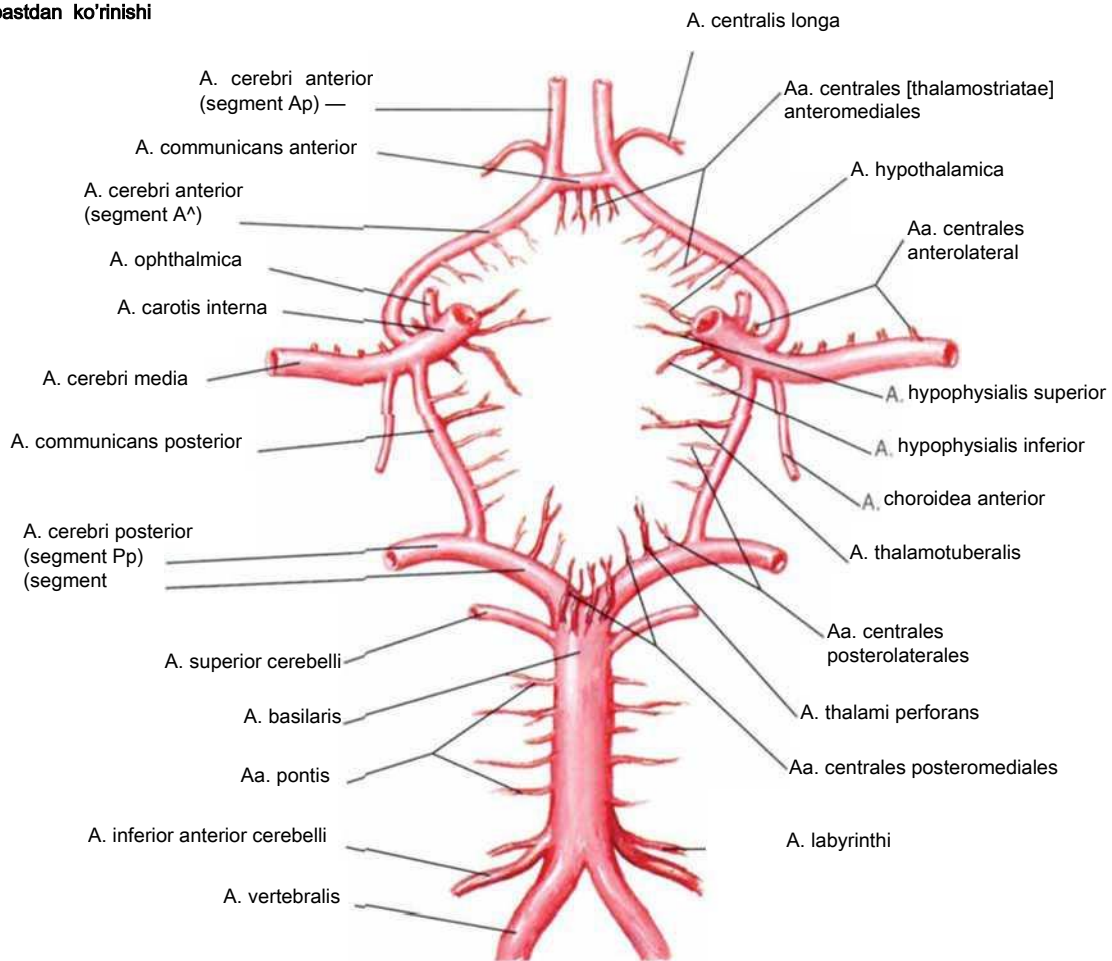
Bosh miya arteriyalari (pastdan ko'rinishi)



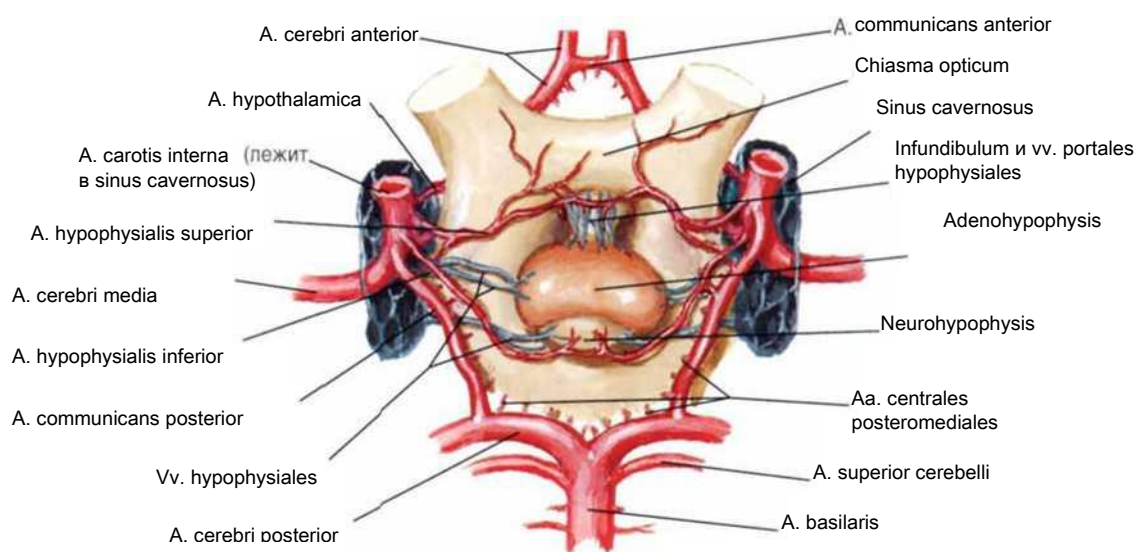
Bosh miya arteriyalari, Villiziy aylanasi

141-rasmda gipofiz arteriyalari ko'rsatilgan

Arterial doiraning ajratib olingan tomirlari: pastdan ko'rinishi



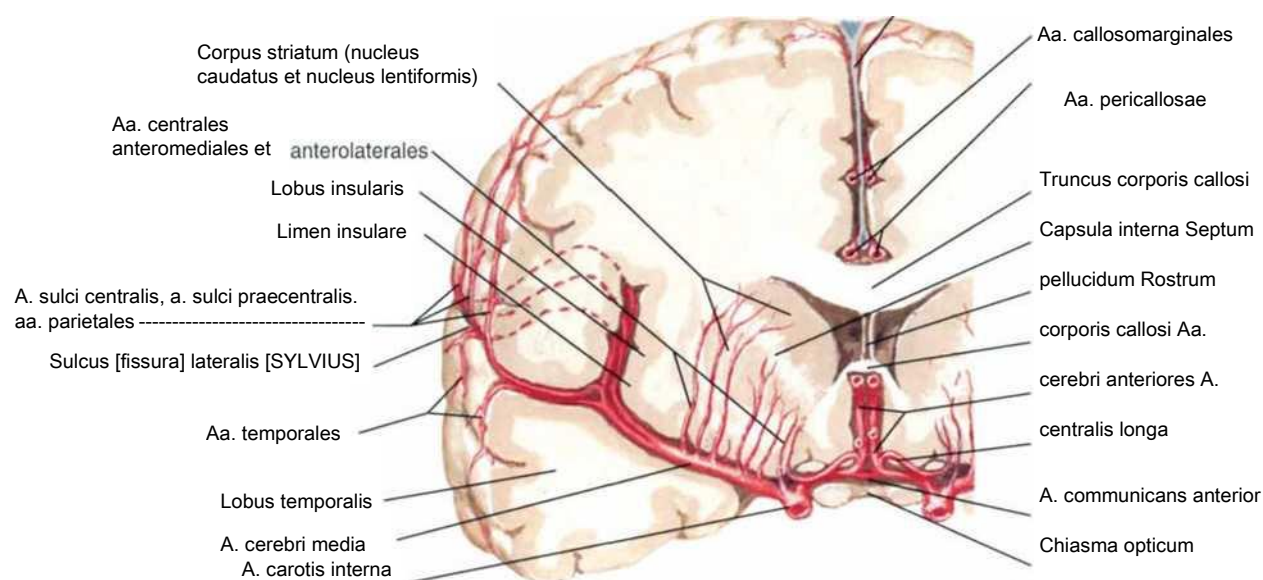
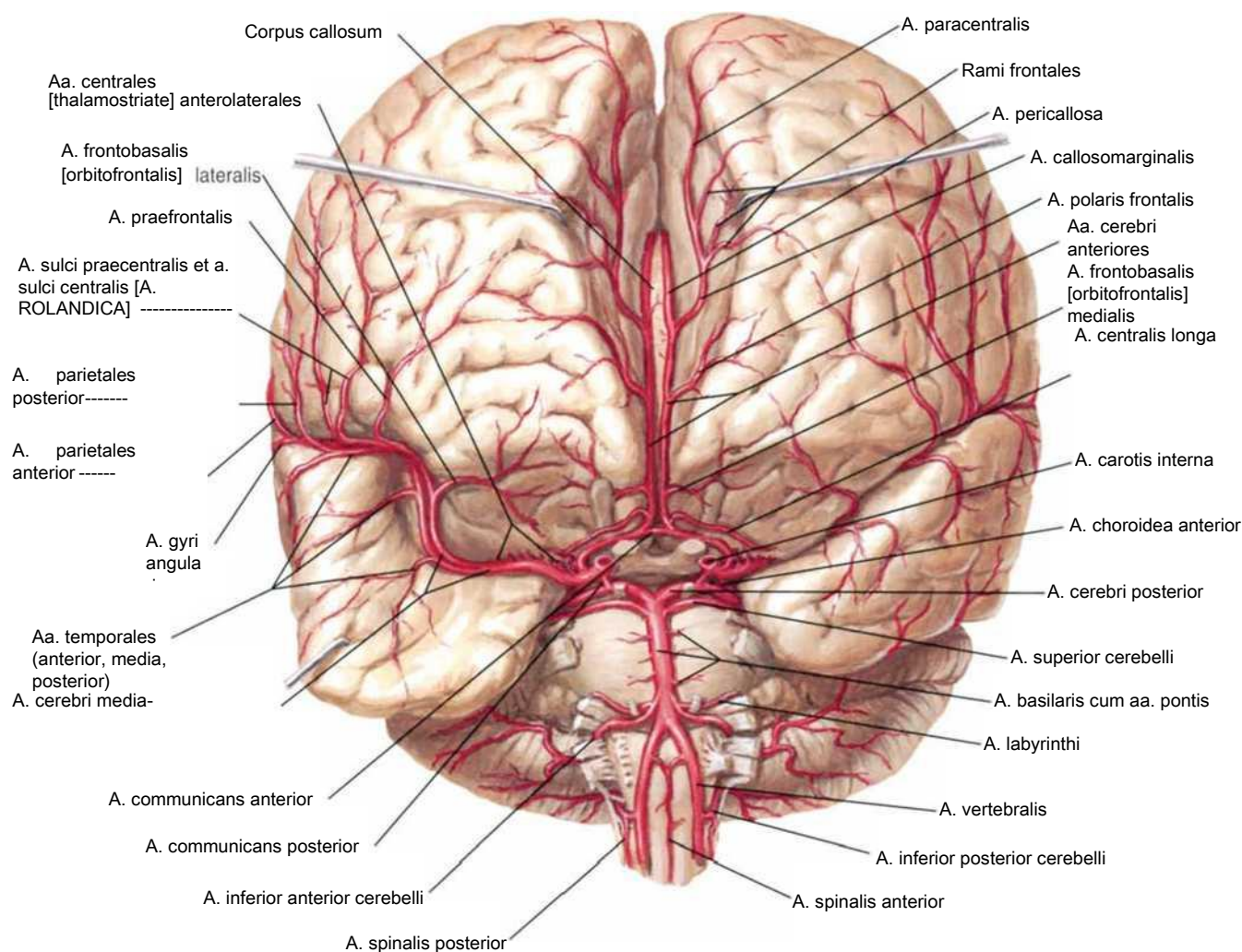
Atriy a'zolarining qon bilan ta'minlanishi: pastdan ko'rinishi



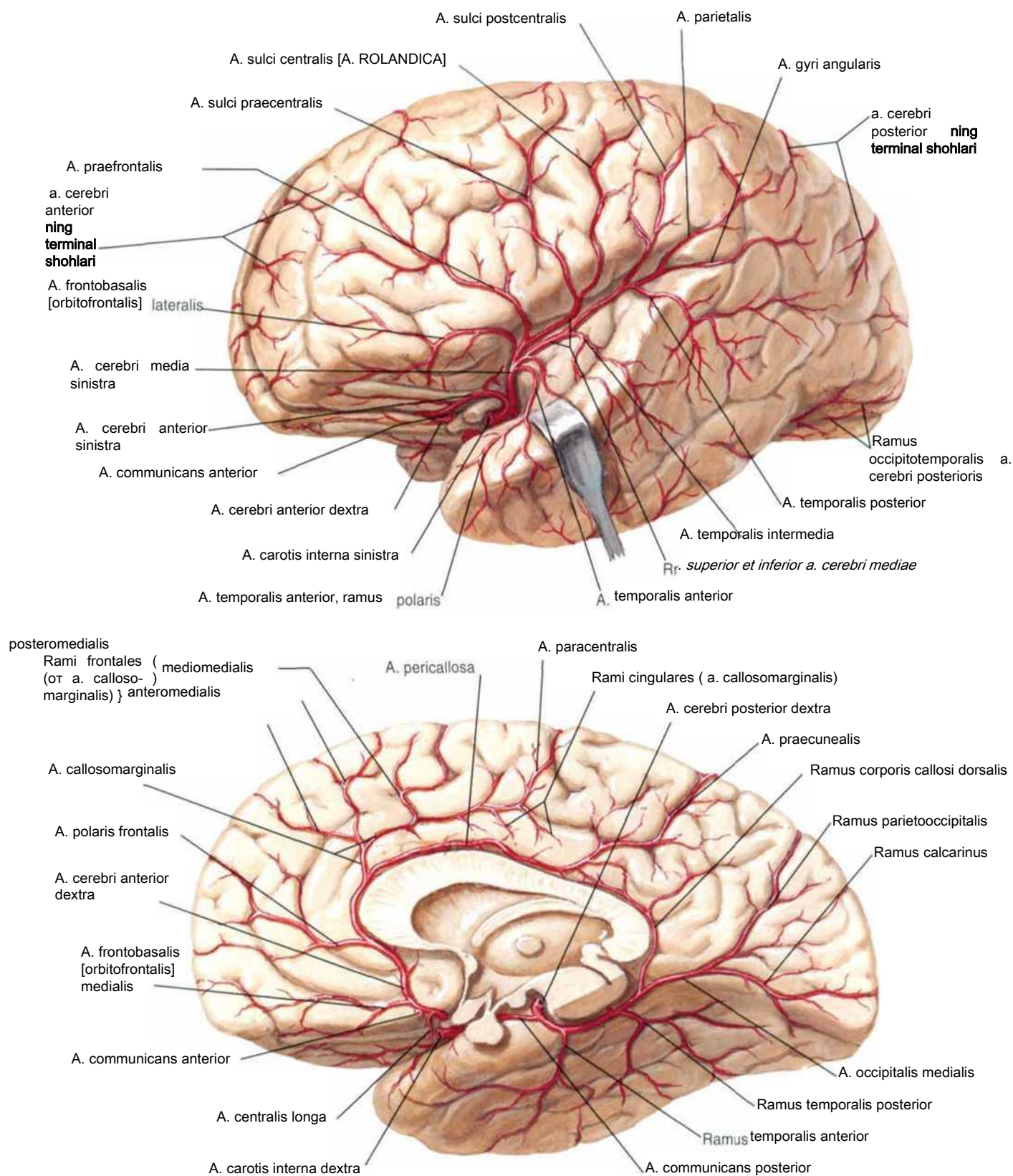
Miya tomirlari

133-rasm

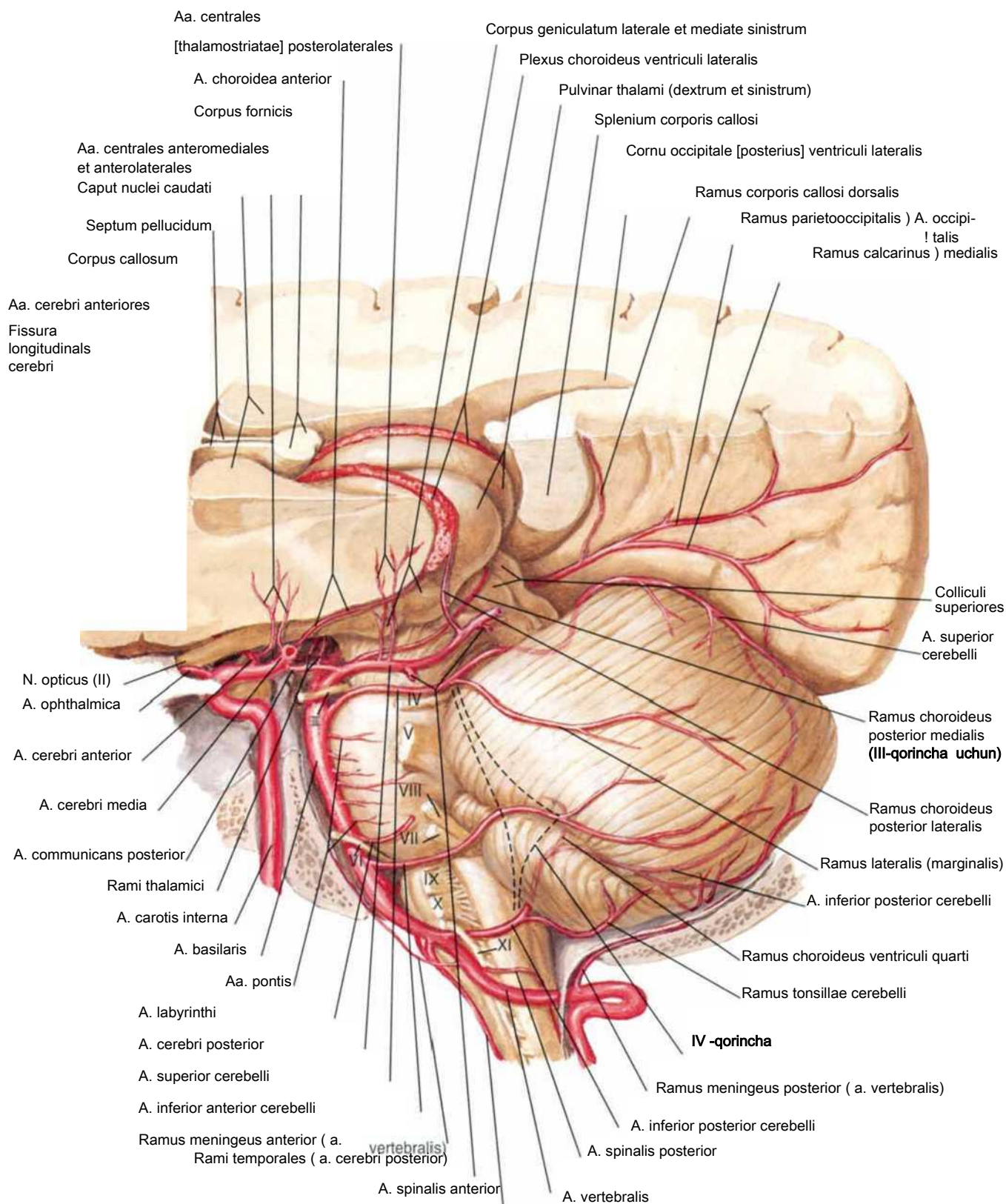
Bosh miya arteriyalari: frontal kesim va oldidan ko'rinishi



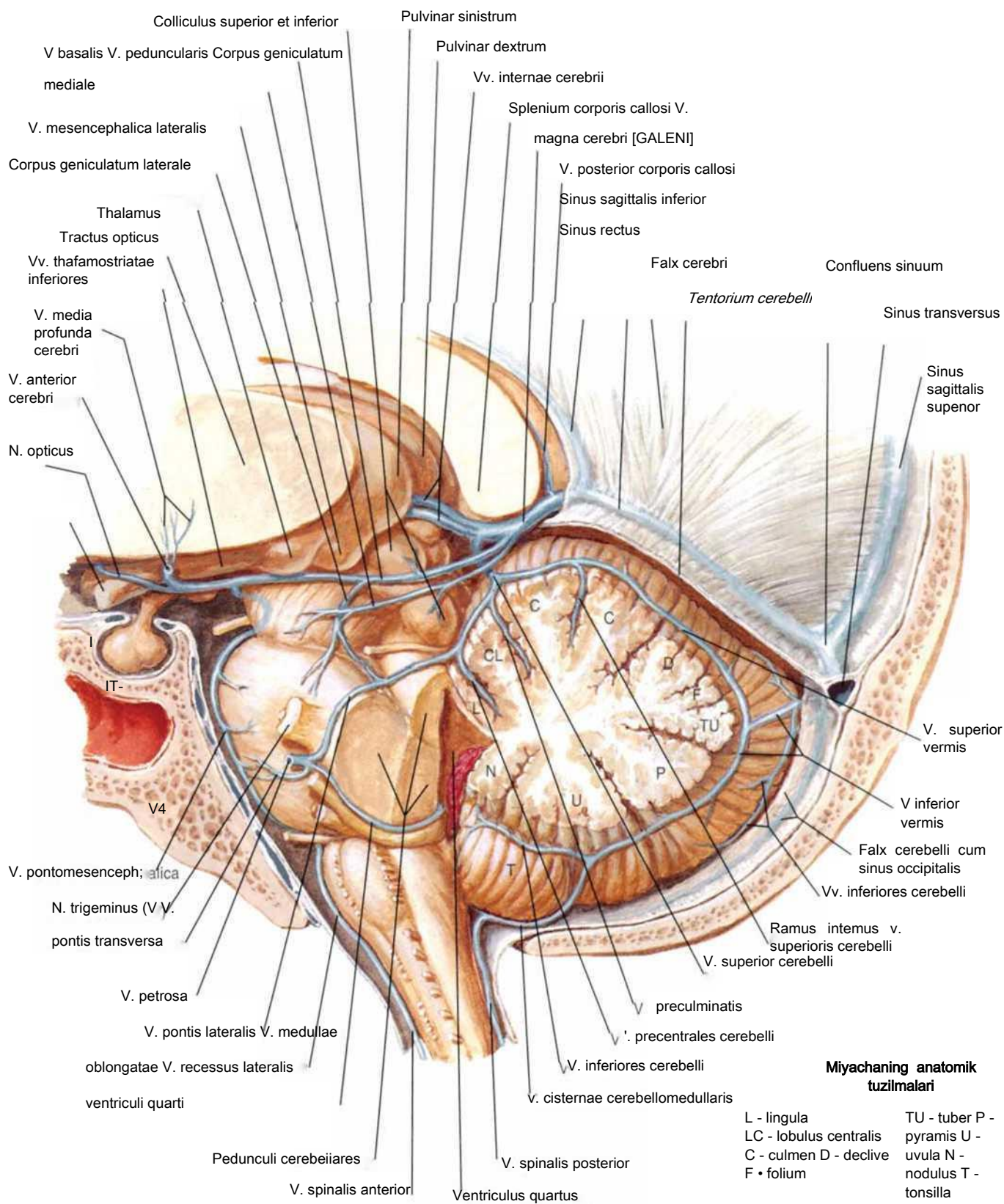
Bosh miya arteriyalari: medial va lateral tomondan ko'rinishi



Kalla suyagi orqa chuqurchasining arteriyalari



Kalla suyagi chuqurchasining venalari

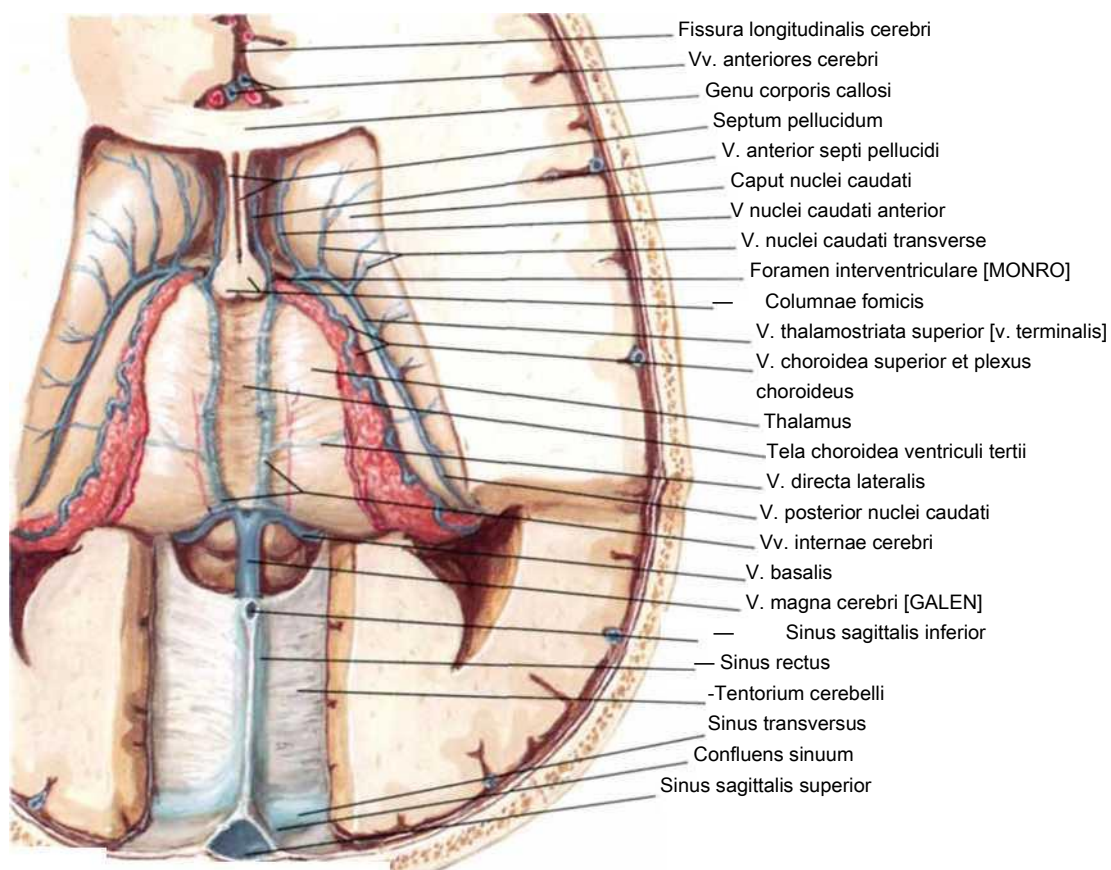


Bosh miya tomirlari

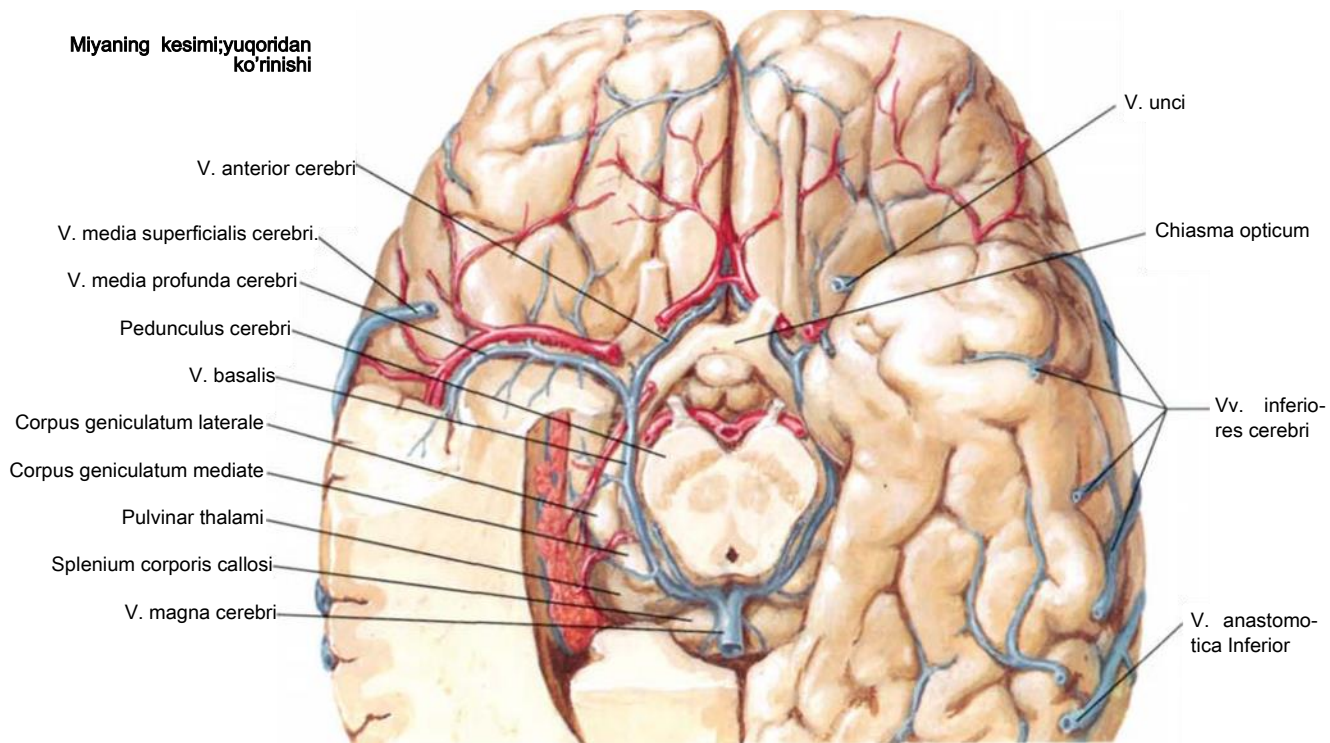
137-rasm

Bosh miyaning chuqur venalari

96-rasm.



Miyaning kesimi; yuqoridan ko'rinishi

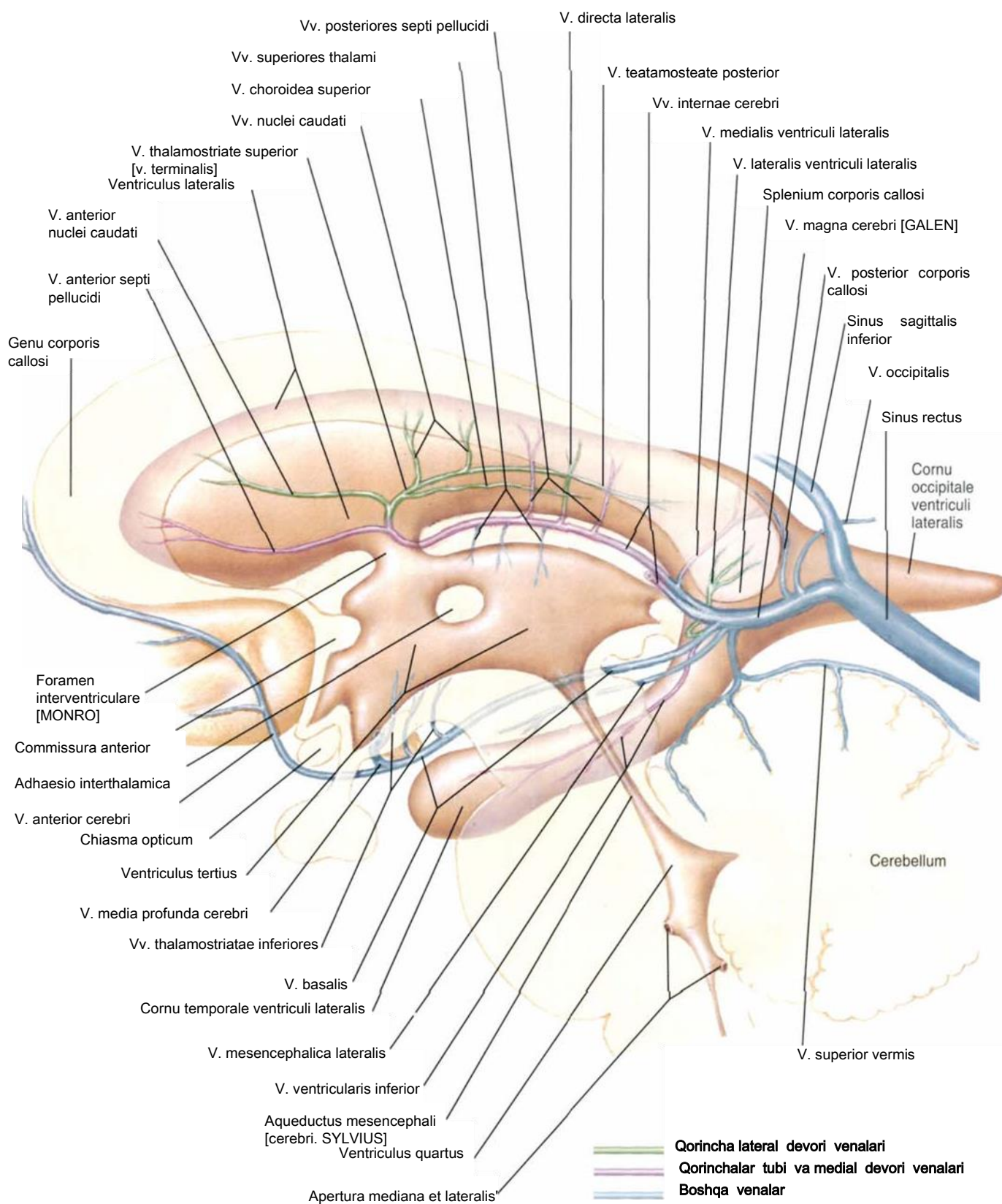


Miyaning kesimi; pastdan ko'rinishi

138-rasm

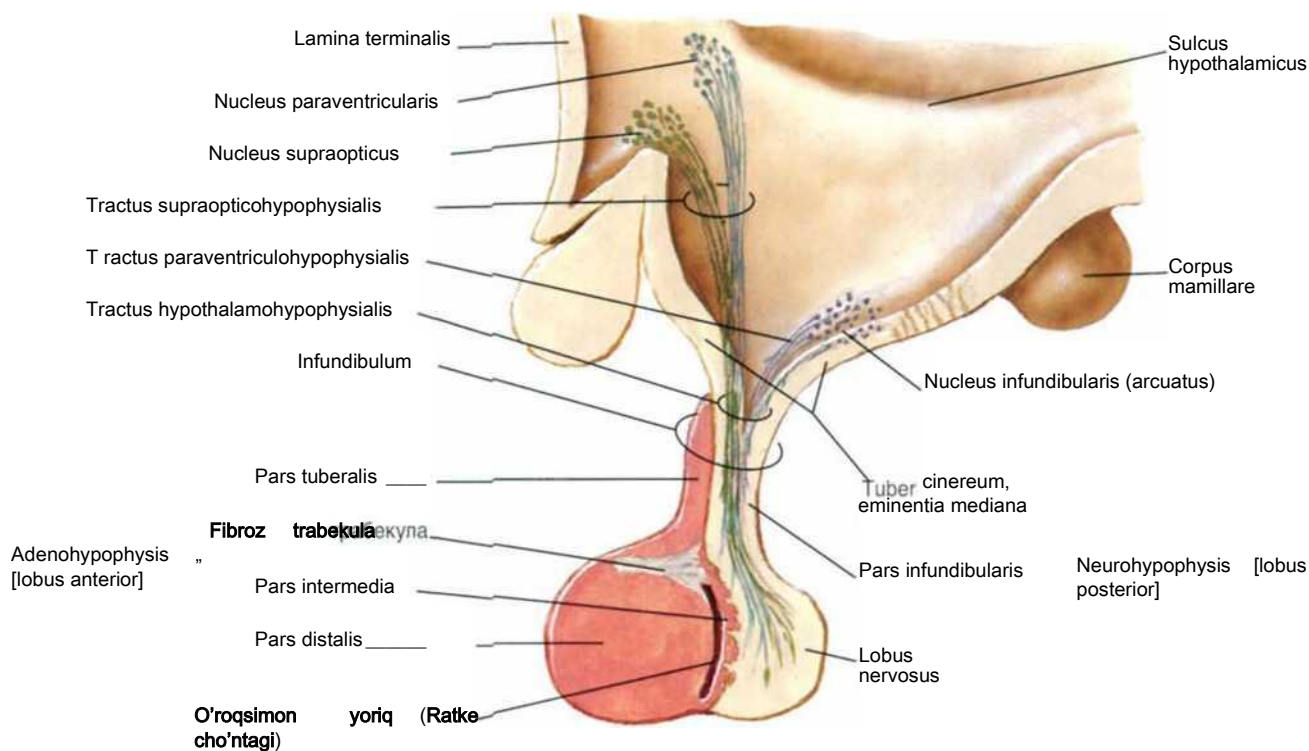
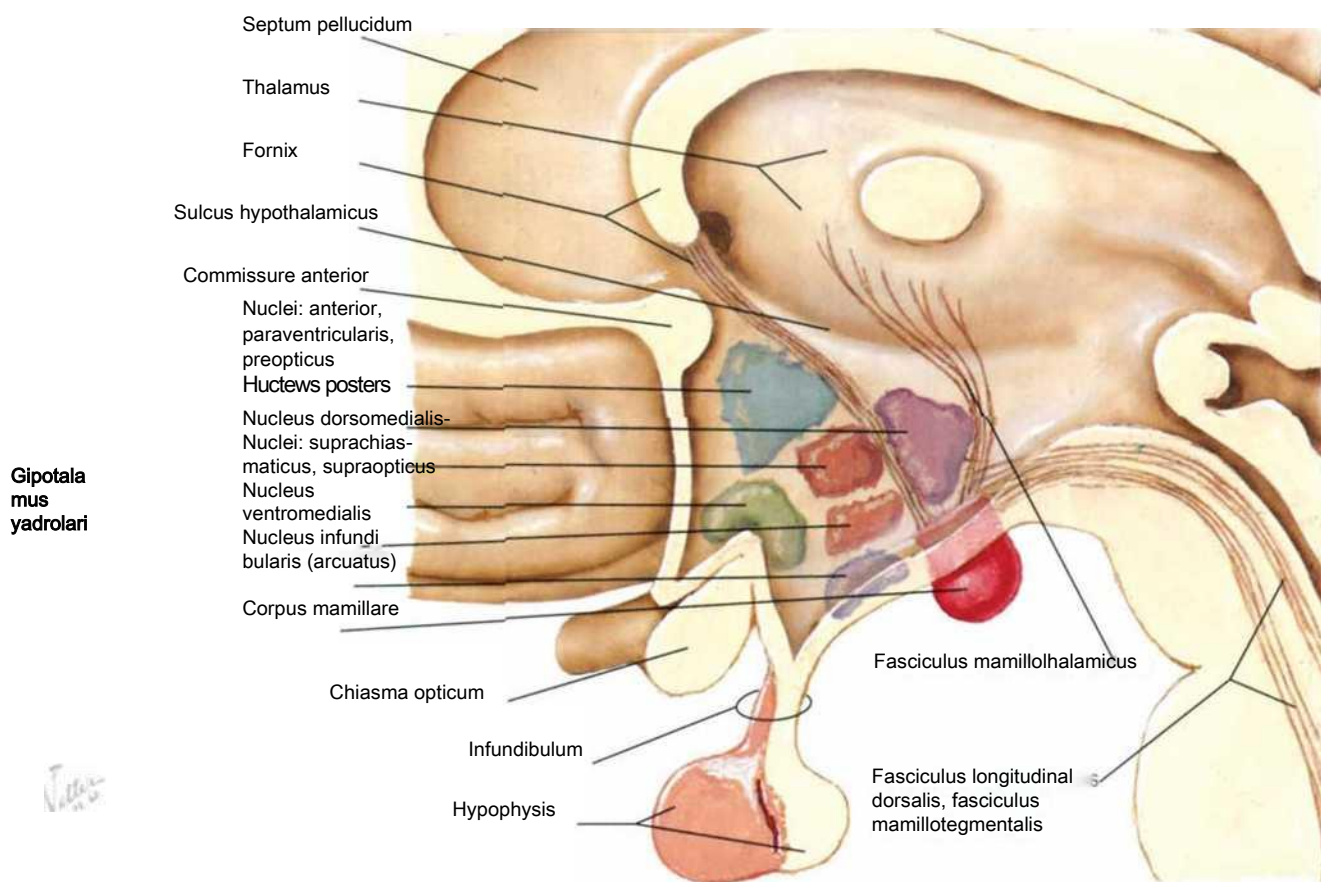
BOSH VA BO'YIN

Bosh miyaning chuqur venalari tuzilishi



Gipofiz va gipotalamus

100. 101-rasmlar.

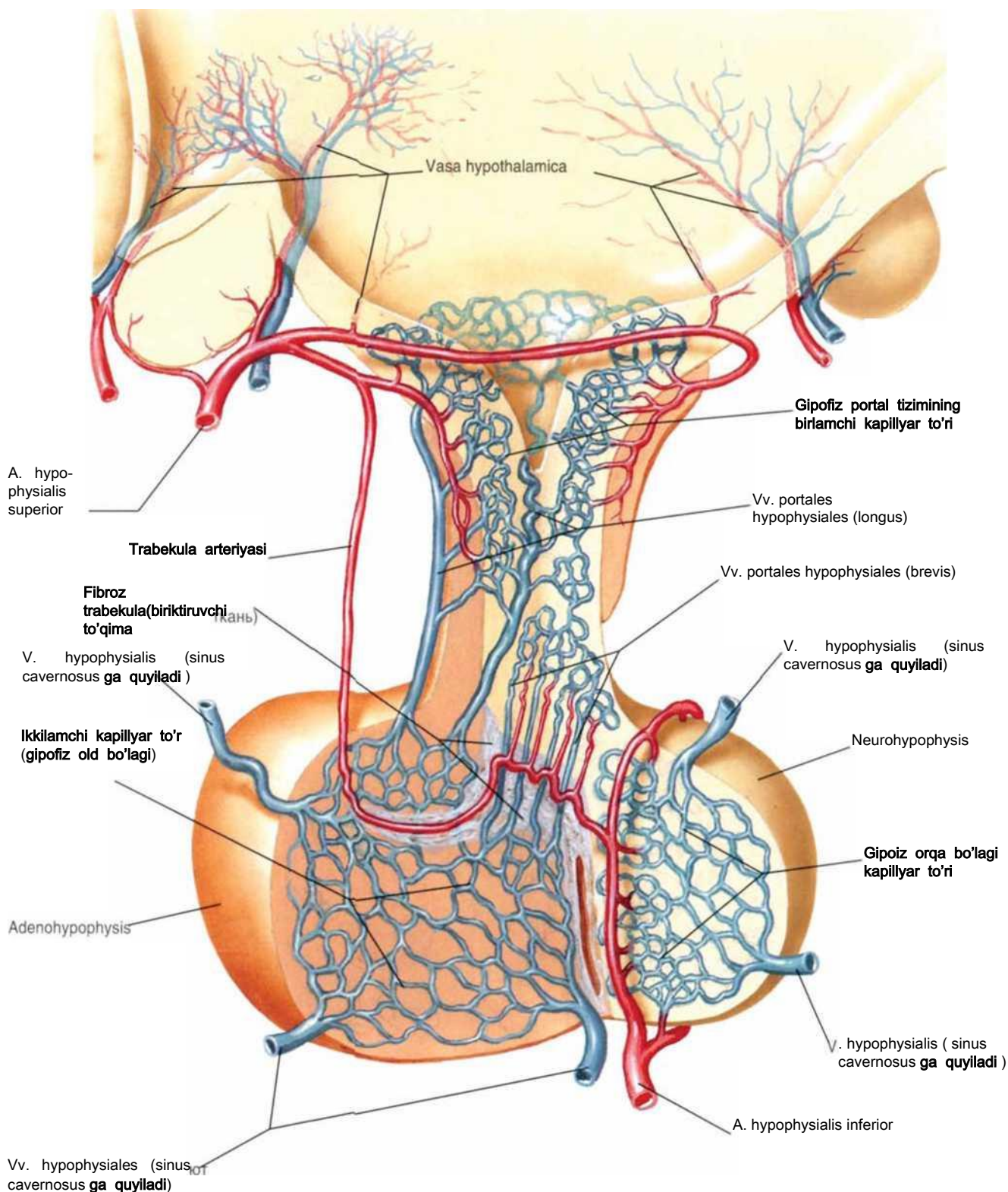


140-rasm

BOSH VA BO'YIN

Gipotalamus va gipofizning arteriya va venalari

133-rasm.



II-bo'lim

UMURTQA POG'ONASI VA GAVDANING ORQA QISMI

SUYAKLAR VA BOYLAMLAR

142-147 rasmlar.

- 142. Umurtqa pog'onasi (columna vertebralis)
- 143. Ko'krak umurtqalari (vertebrae thoracicae)
- 144. Bel umurtqalari (vertebrae lumbales)
- 145. Dumg'aza(os sacrum) va dum suyagi (os coccyges)
- 146. Umurtqa pog'onasi bel qismining boylamlari
- 147. Umurtqa pog'onasi bel-dumg'aza qismining boylamlari

ORQA MIYA

148-159 rasmlar

- 148. Orqa miya (medulla spinalis)
- 149. Orqa miya nervlari va umurtqalarining o'zaro joylashuvi
- 150. Dermatomlar
- 151. Orqa miyaning ko'ndalang kesimi va o'tkazuvchi yo'llar
- 152. Vegetativ(avtonom) tizimi: topografiyasi
- 153. Vegetativ(avtonom) tizimi: tuzilishi

- 154. Holinergik va adrenergic sinapslar: tuzilishi
- 155. Orqa miya pardalari va ildizlari
- 156. Orqa miya nervlarini hosil bo'lishi: ko'ndalang kesimi
- 157. Orqa miya arteriyalari: tuzilishi
- 158. Orqa miya arteriyalari
- 159. Umurtqa pog'onasi va orqa miya venalari

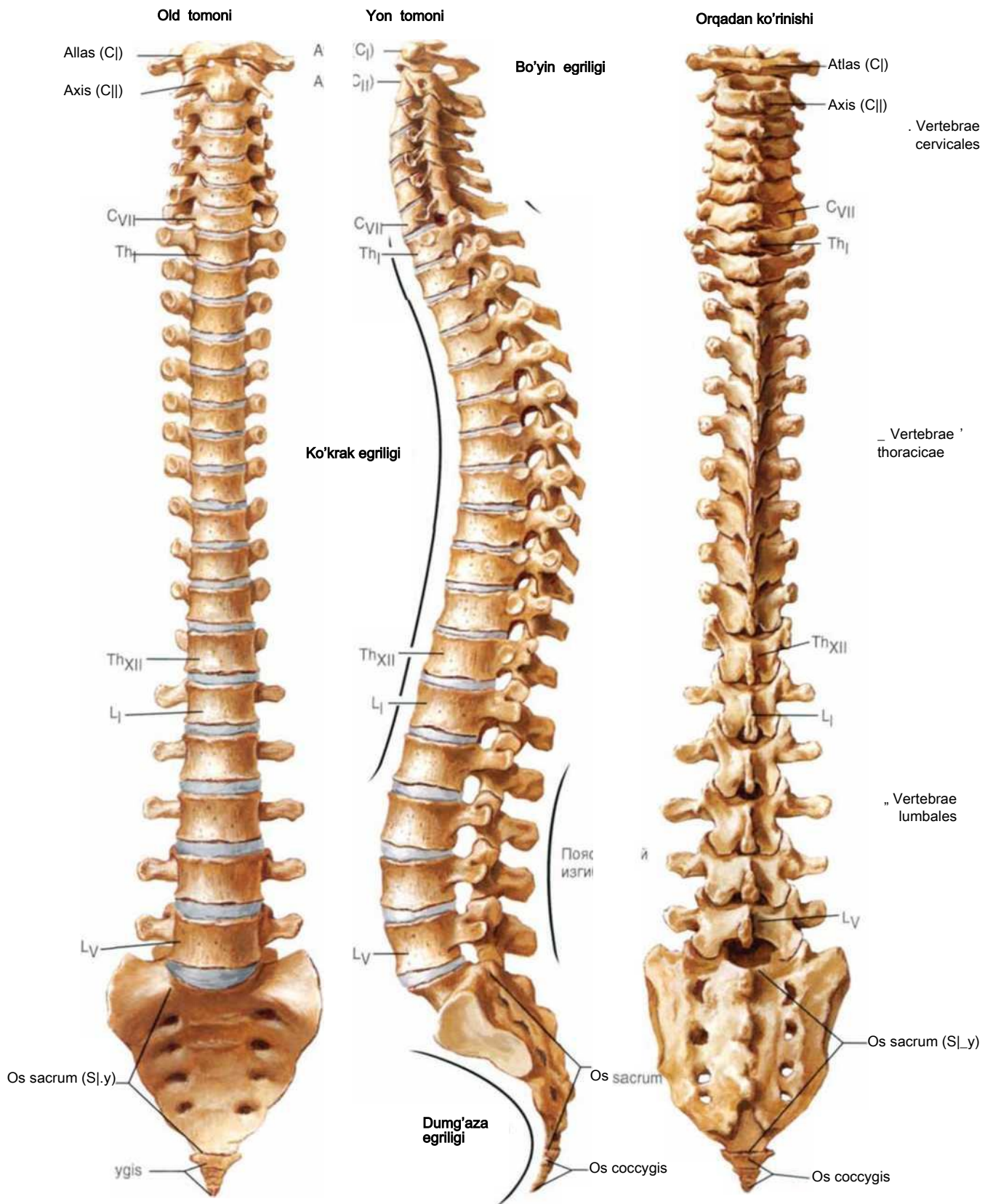
МЫШЦЫ И НЕРВЫ

Рис. 160-166

- 160. Gavdaning orqa muskullari (musculi dorsi): yuza qavati
- 161. Gavdaning orqa muskullari (musculi dorsi): o'rta qavati
- 162. Gavdaning orqa muskullari (musculi dorsi): chuqur qavati
- 163. Gavdaning orqa qismi nervlari
- 164. Bo'yinning orqa sohasi (regio cervicalis posterior [regio nuchalis])
- 165. Bel sohasi (regio lumbalis): gorizontal kesim
- 166. Ko'krak nervlari (nervi thoracici)

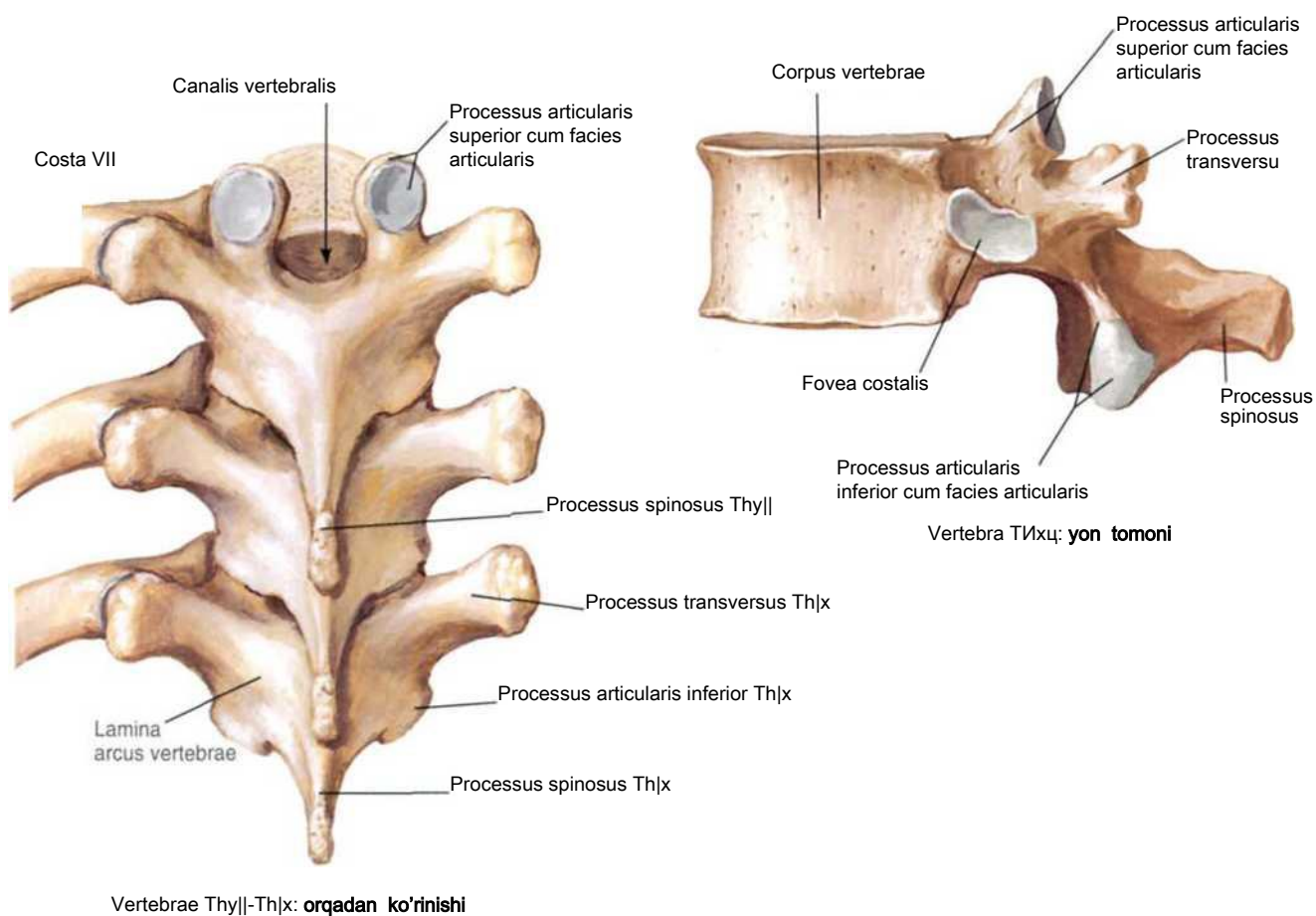
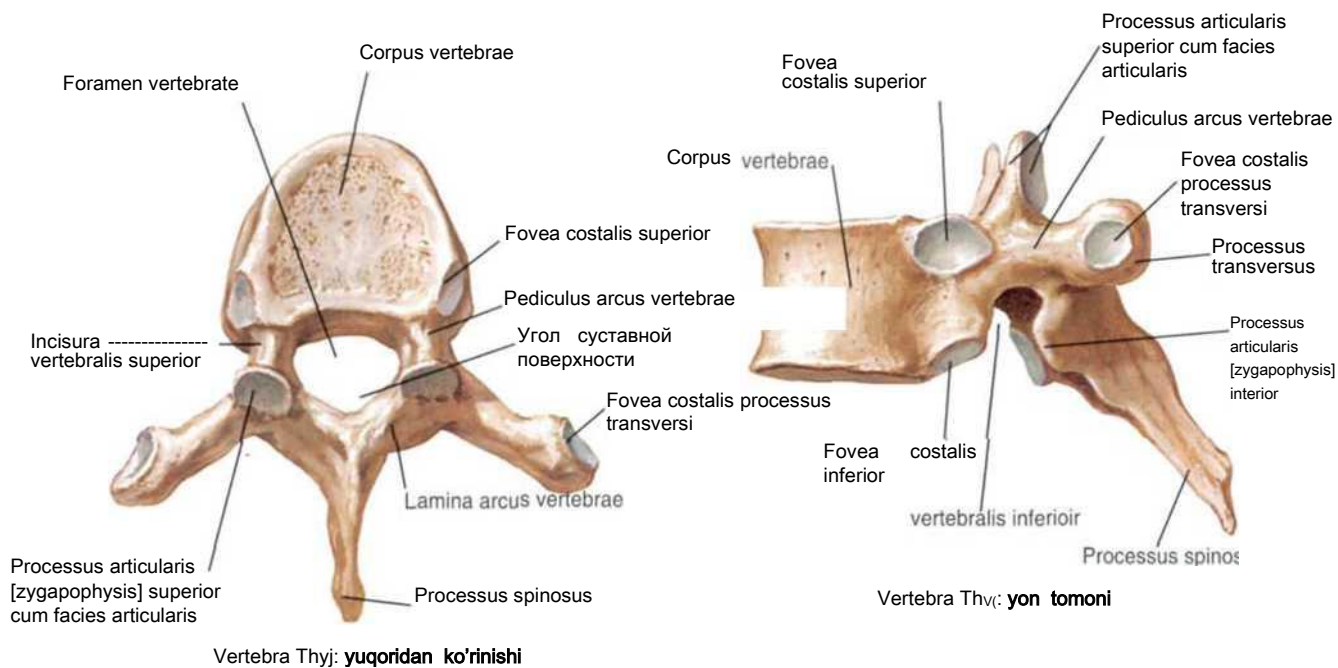
Umurtqa pog'onasi (columna vertebralis)

9. 12. 13. 143-145. 170. 231-rasmlar.



Ko'krak umurtqalari (vertebrae thoracicae)

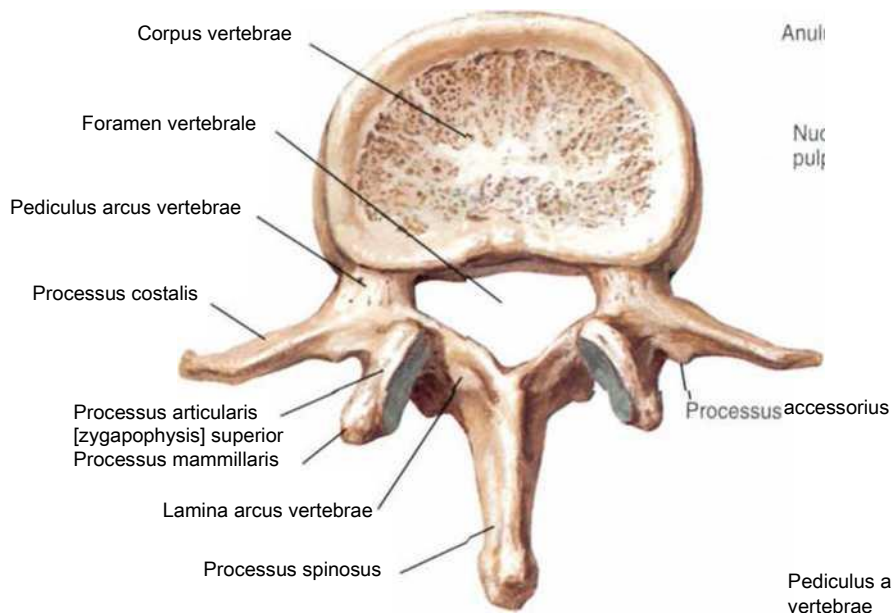
172-rasm.



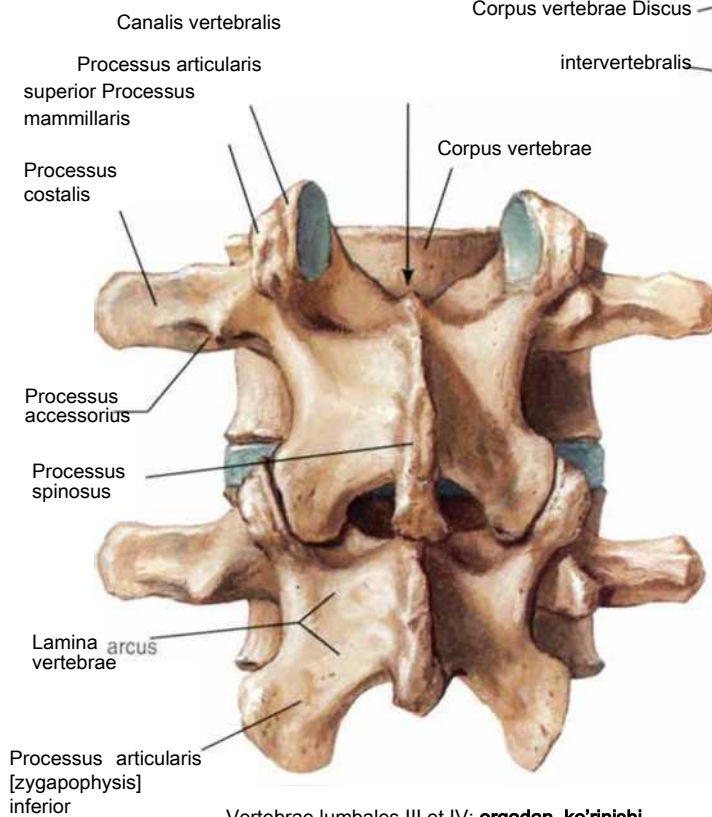
143-rasm

UMURTQA POG'ONASI

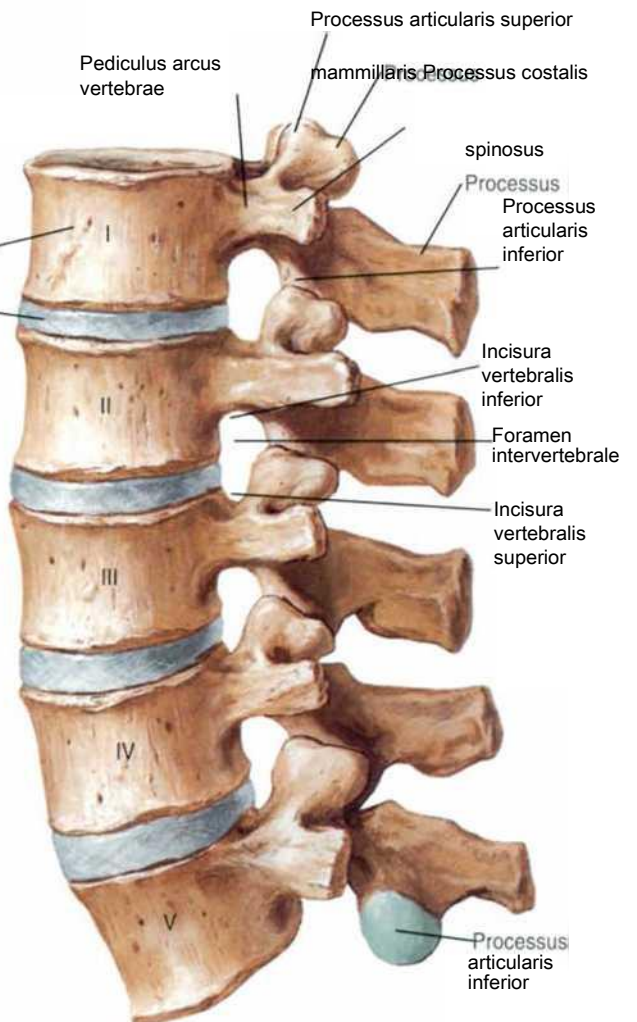
Bel umurtqalari (vertebrae lumbales)



Vertebra lumbalis II:
yuqoridan ko'rinishi



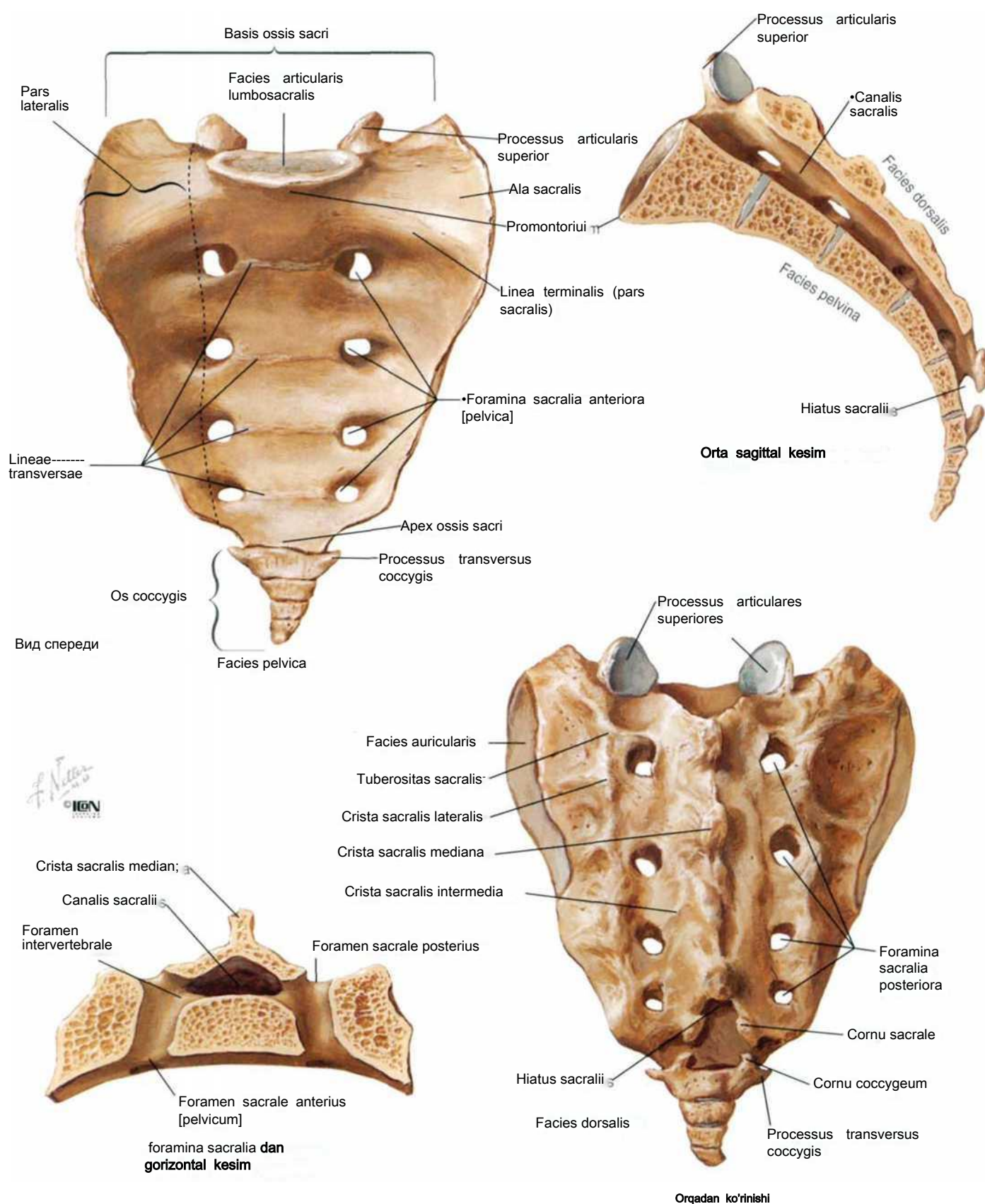
Vertebrae lumbales III et IV: orqadan ko'rinishi



Bel umurtqalari: yon tomoni

Dumg'aza (os sacrum) va dum suyagi (os coccygis)

142. 147.231. 330-332-rasmlar.

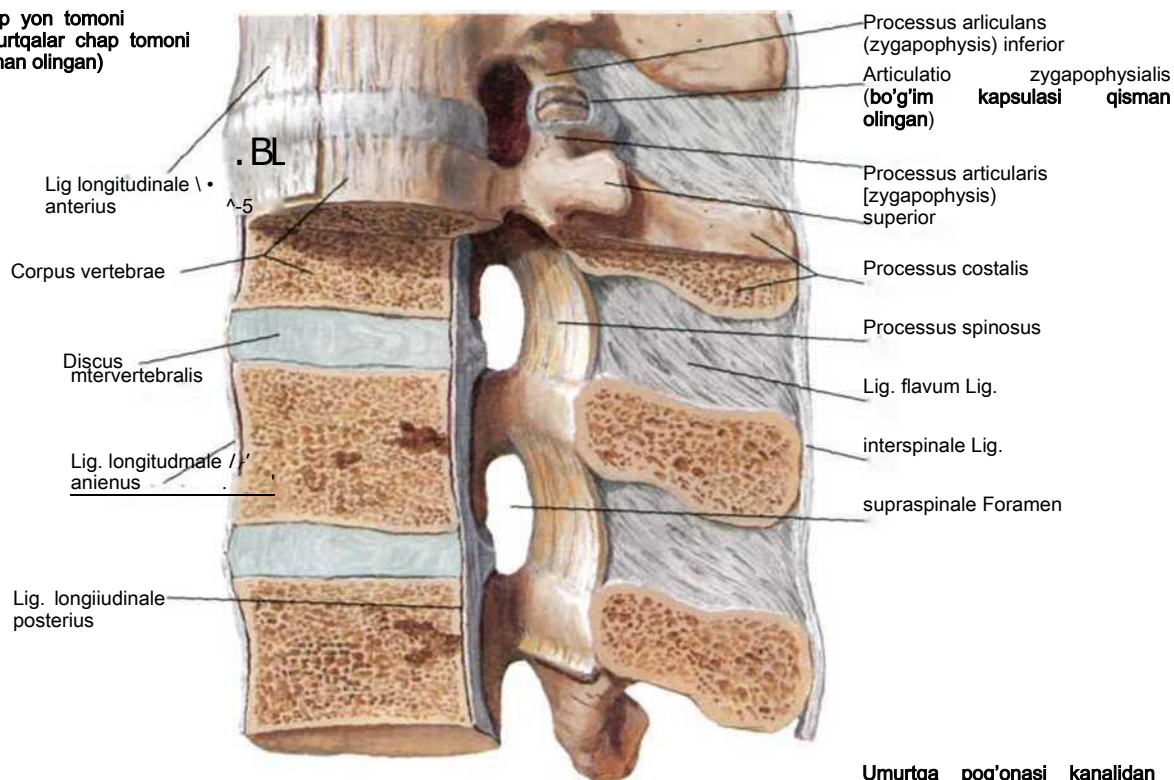


145-rasm

UMURTQA POG'ONASI

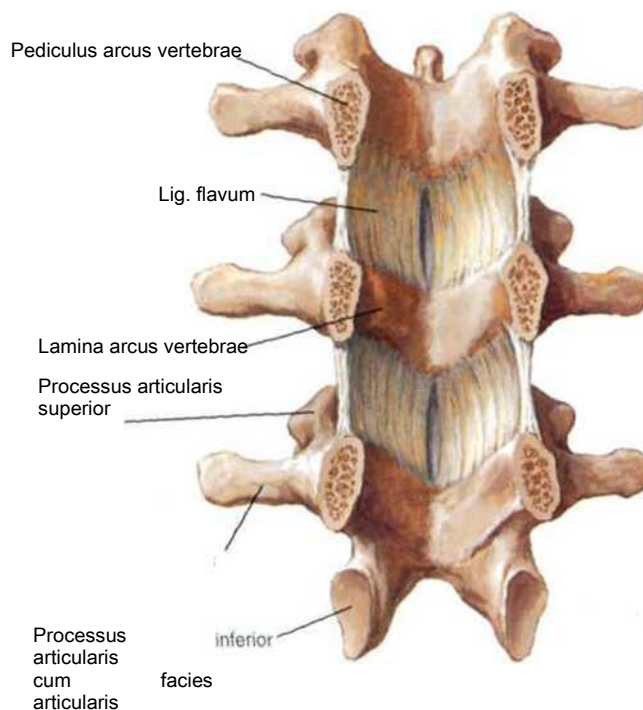
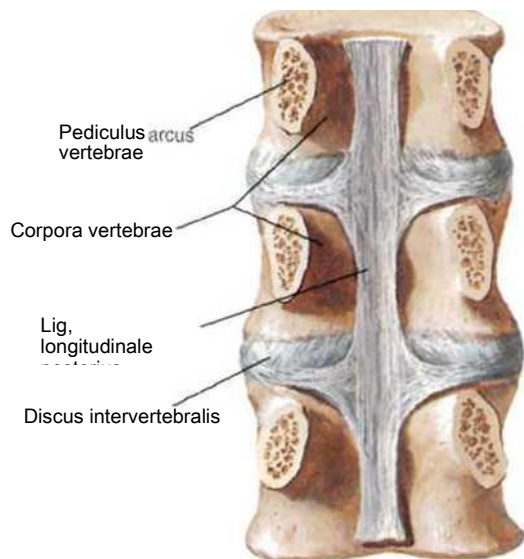
Umurtqa pog'onasi bel qismining boylamlari

Chap yon tomoni
(umurtqalar chap tomoni
qisman olingan)



Umurtqa pog'onasi kanalidan
ko'rinishi

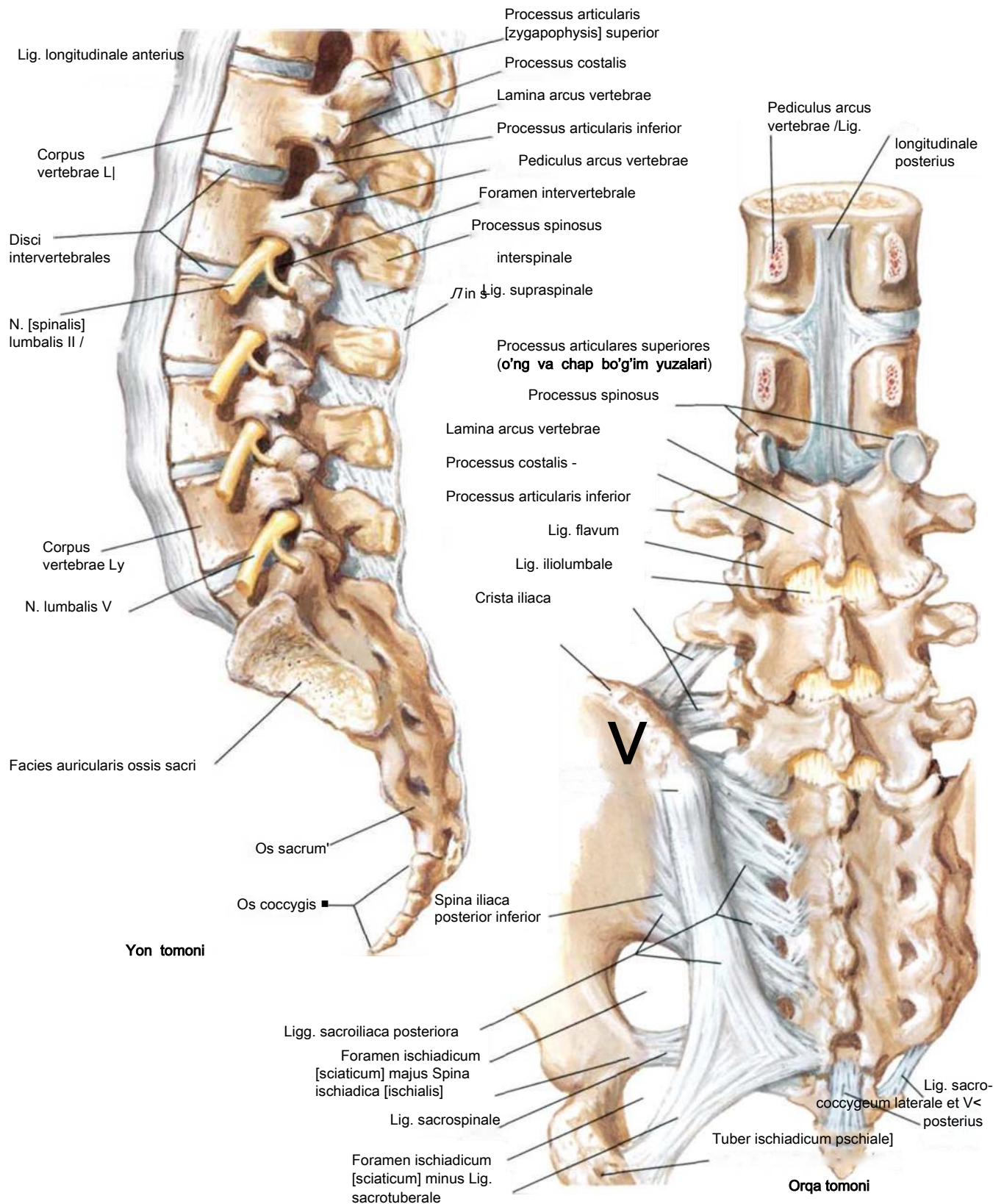
Orqa tomoni (umurtqa ravoqlari
olingan)



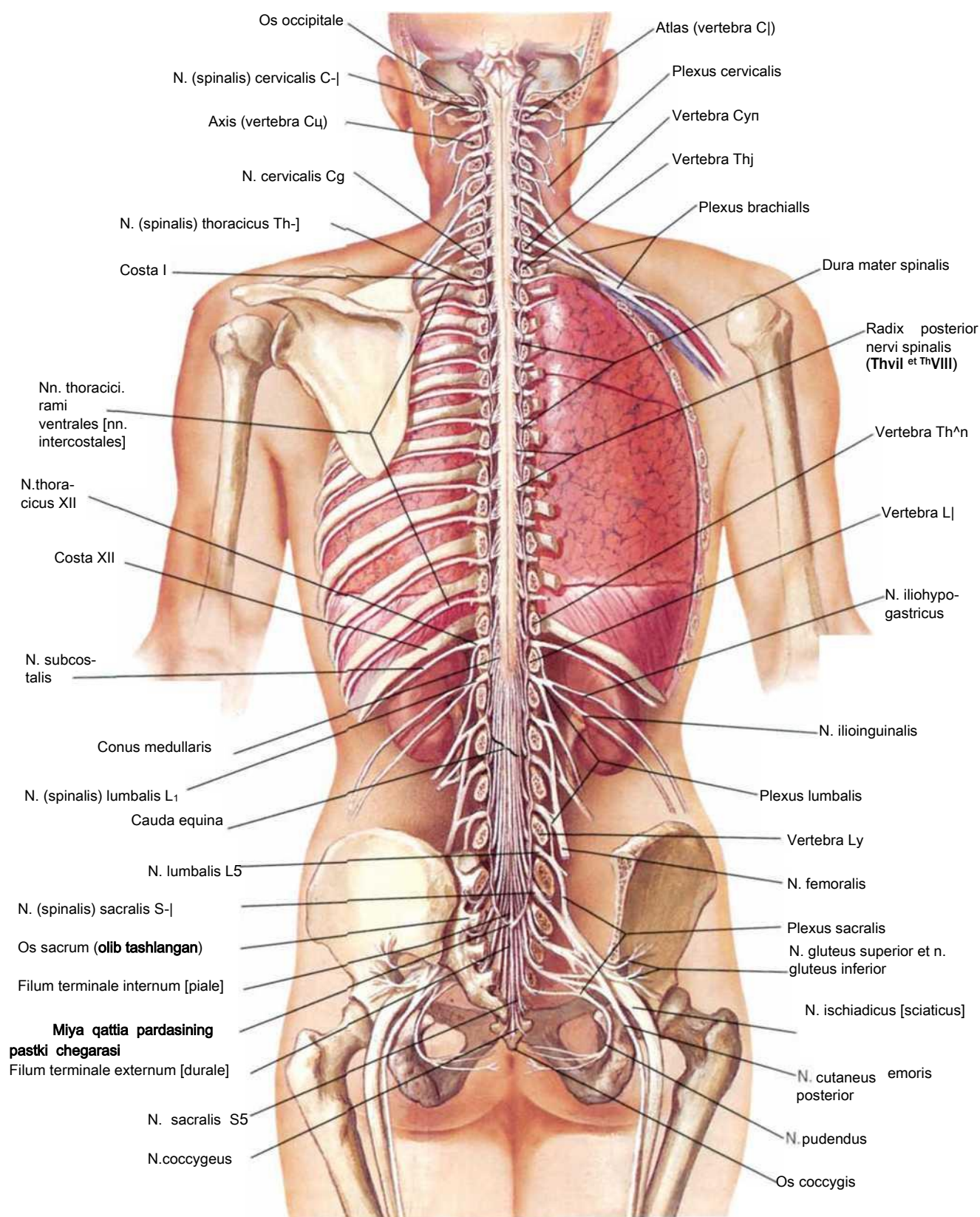
SUYAK VA BOYLAMLAR

146-rasm

Umurtqa pog'onasi bel-dumg'aza qismining boylamlari



Orqa miya (medulla spinalis)



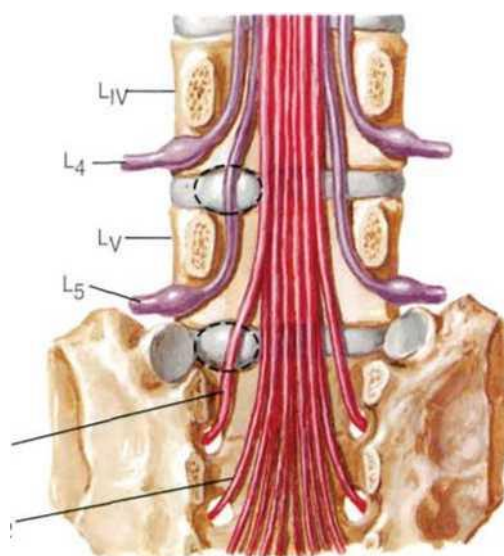
Umurtqalar va orqa miya nervlarining o'zaro joylashuvi

Kalla suyagi
asosi

Intumescentia
cervicalis

N. cervicalis C- birinchi
bo'yin umurtqasi
yuqorisidan boshlanadi

N. cervicalis Cg= 7-bo'yin
umurtqasi ostidan
boshlanadi (bo'yin
umurtqalari- 7ta, bo'yin
orqa miya nervlari esa -
8ta)



Intumescentia
lumbosacralis

Conus medullaris

Lo
- Cauda equina

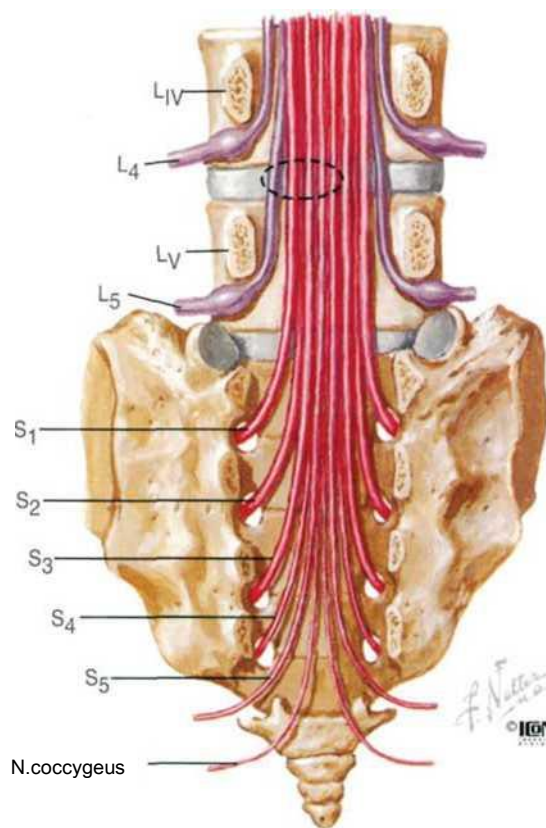
Filum terminale
internum [piale]

Os sacrum

Filum
terminale
externum
[durale]

- N. coccygeus

Os coccygis

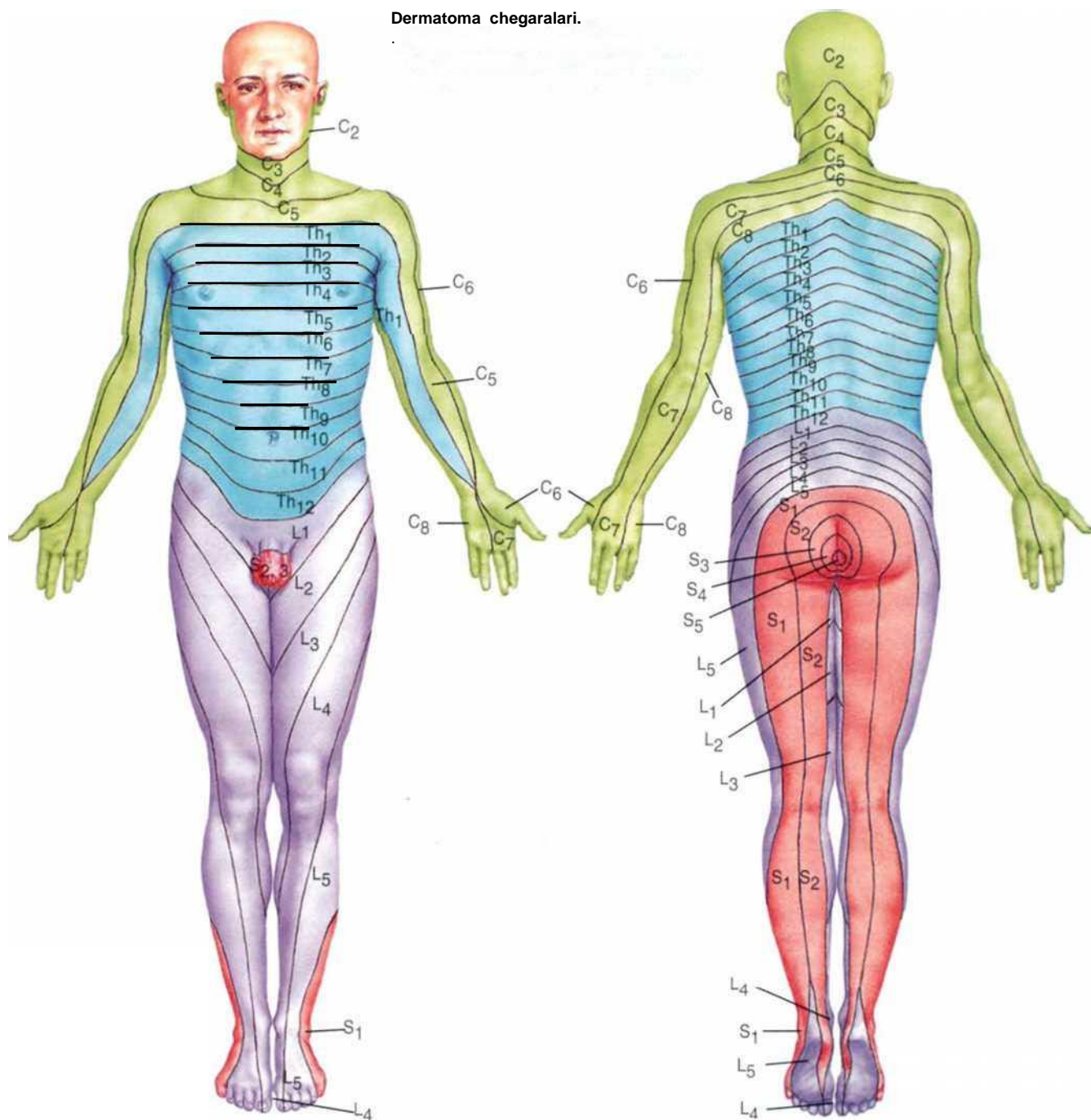


Nn. cervicales
Nn. thoracici Nn. lumbales
Nn. sacrales et n. coccygeus

Dermatomalar

18. 441, 443-445. 447, 450, 451. 502-507-rasmlar.

Dermatoma chegaralari.



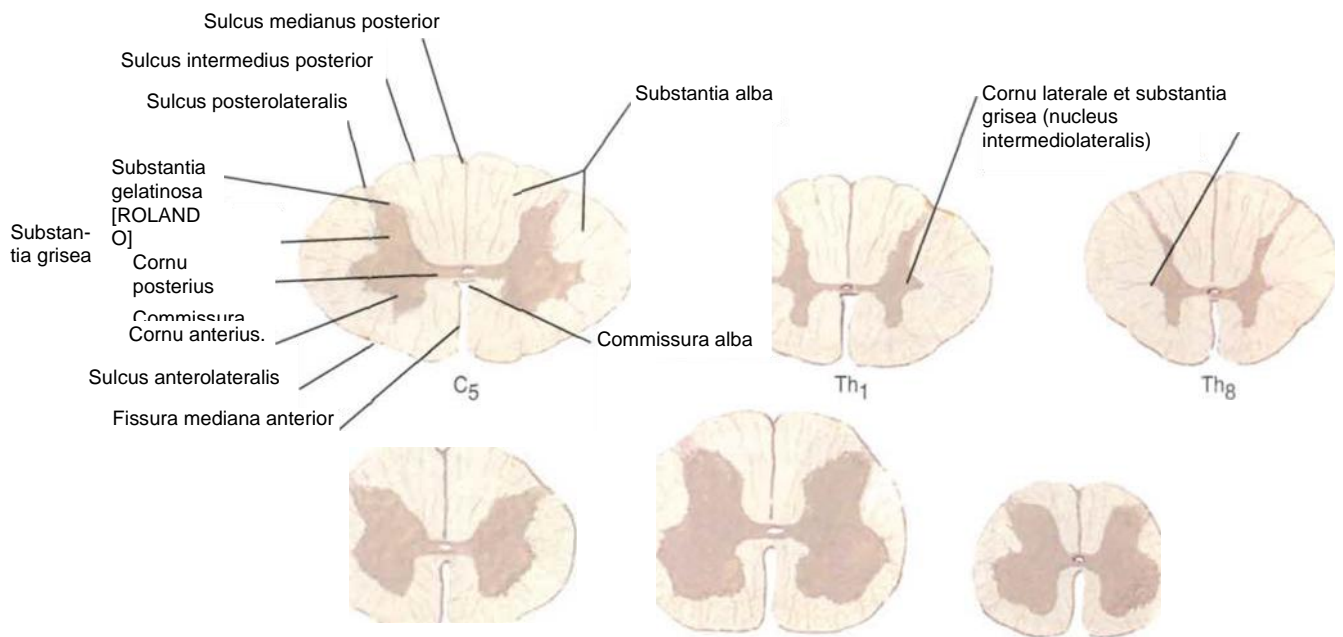
Dermatomalarning joylashuvi

C5 (C4) kurakda
 C5, 6,7 Bilak va yelkaning lateral yuzalari
 C9. Th1 Bilak va yelkaning medial yuzalari
 C9 Kaftning bosh barmog'i
 C9 7 d Kaft
 C4 4 va 5 barmoqlar
 Th14 So'rg'ichlar

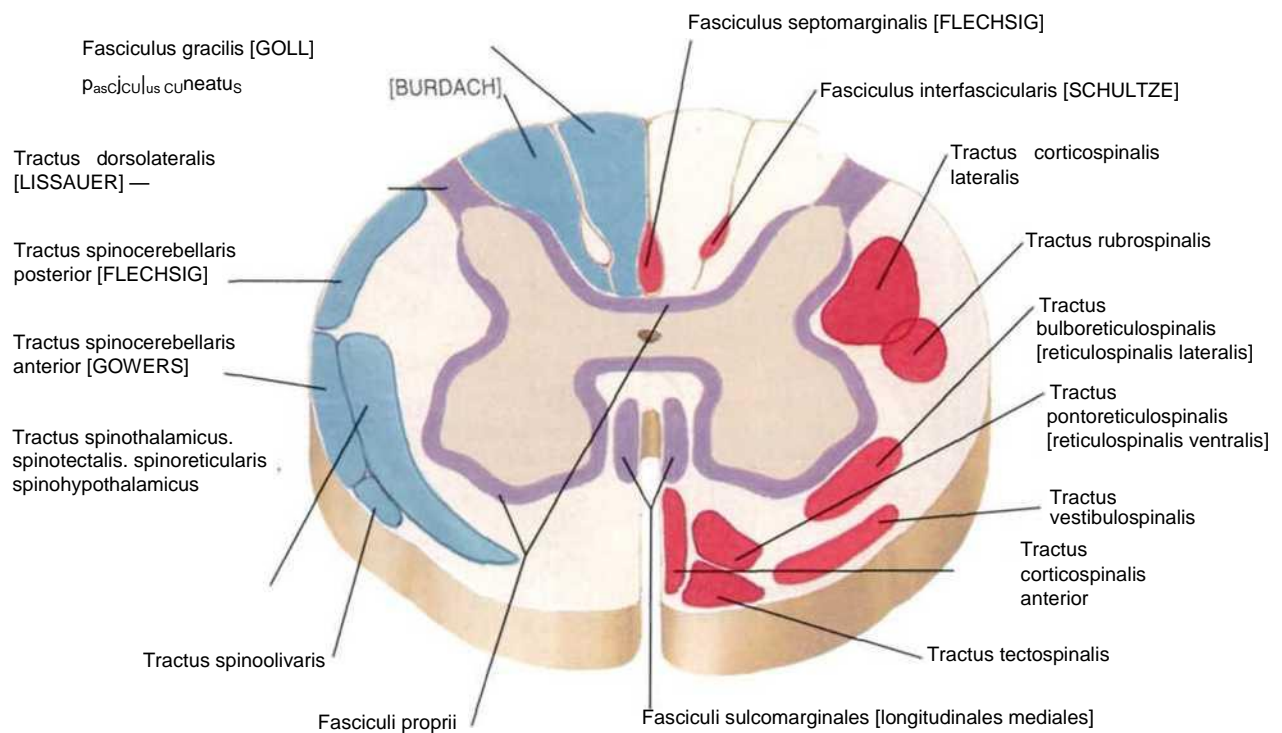
Th10 Kindik sohasi
 Th12 Chov sohasi
 L1,2,3,4 Oyoqlarning oldingi va ichki yuzalari
 L4,5 S1 Oyoq panjasi
 L4 1-barmoqning medial yuzasi
 S1,2 L5 Oyoqlarning orqa va tashqi yuzalari
 S1 Oyoq panjasining lateral yuzasi(5-barmoc
 S2,3,4 Oraliq

Orqa miyaning ko'ndalang kesimi va o'tkazuvchi yo'llari

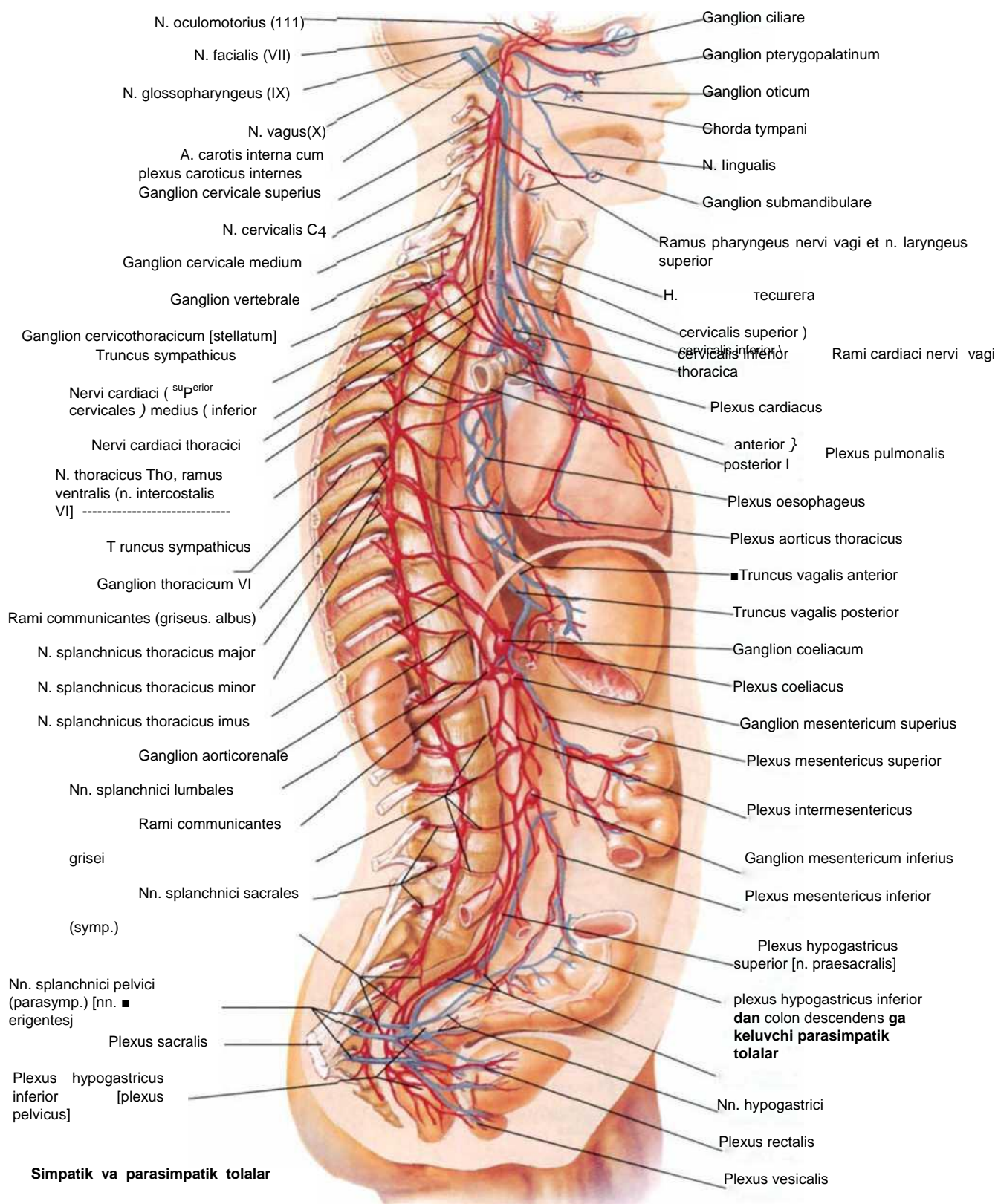
Orqa miyaning turli xil kesimlari



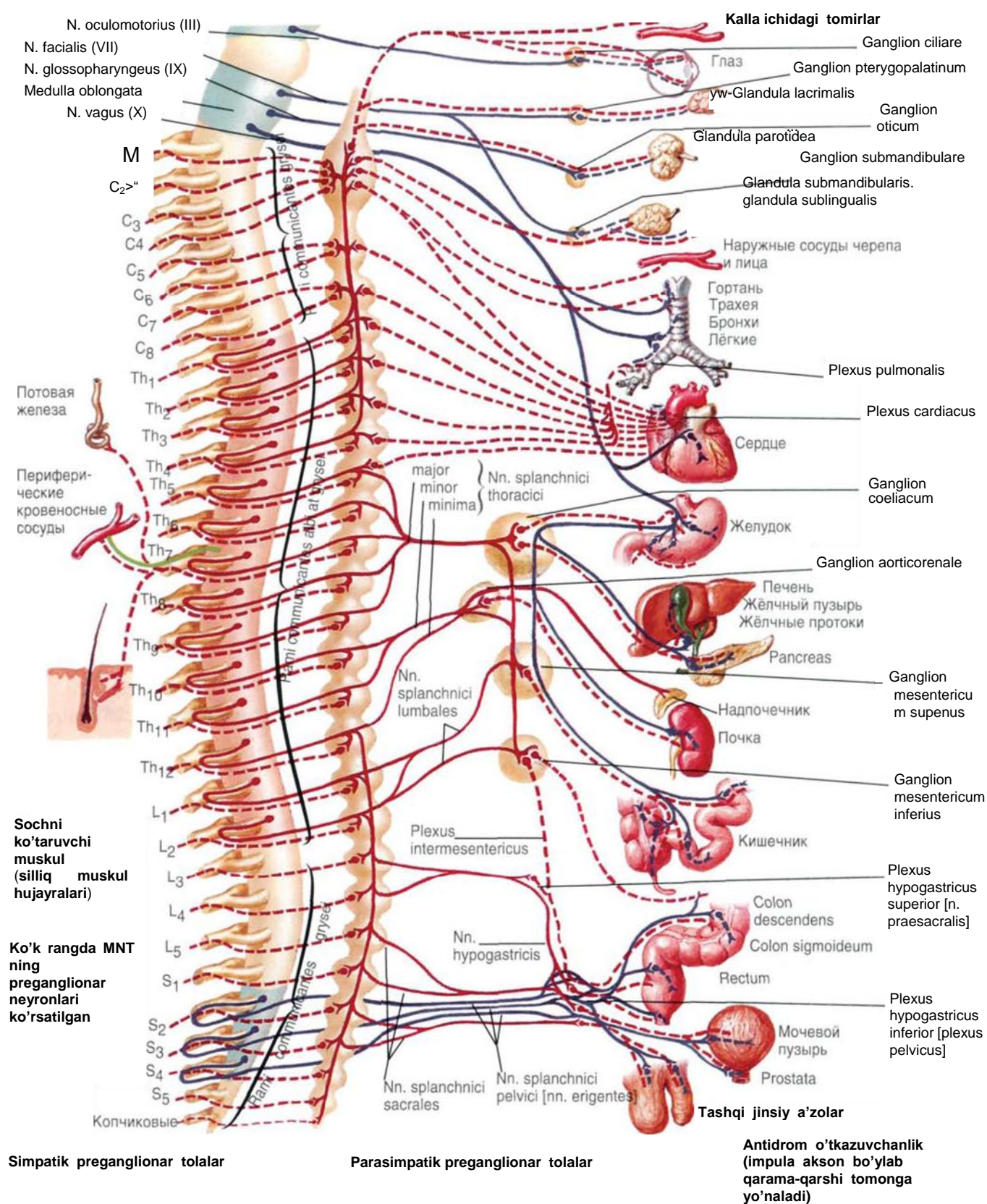
Orqa miyaning asosiy o'tkazuvchi yo'llari



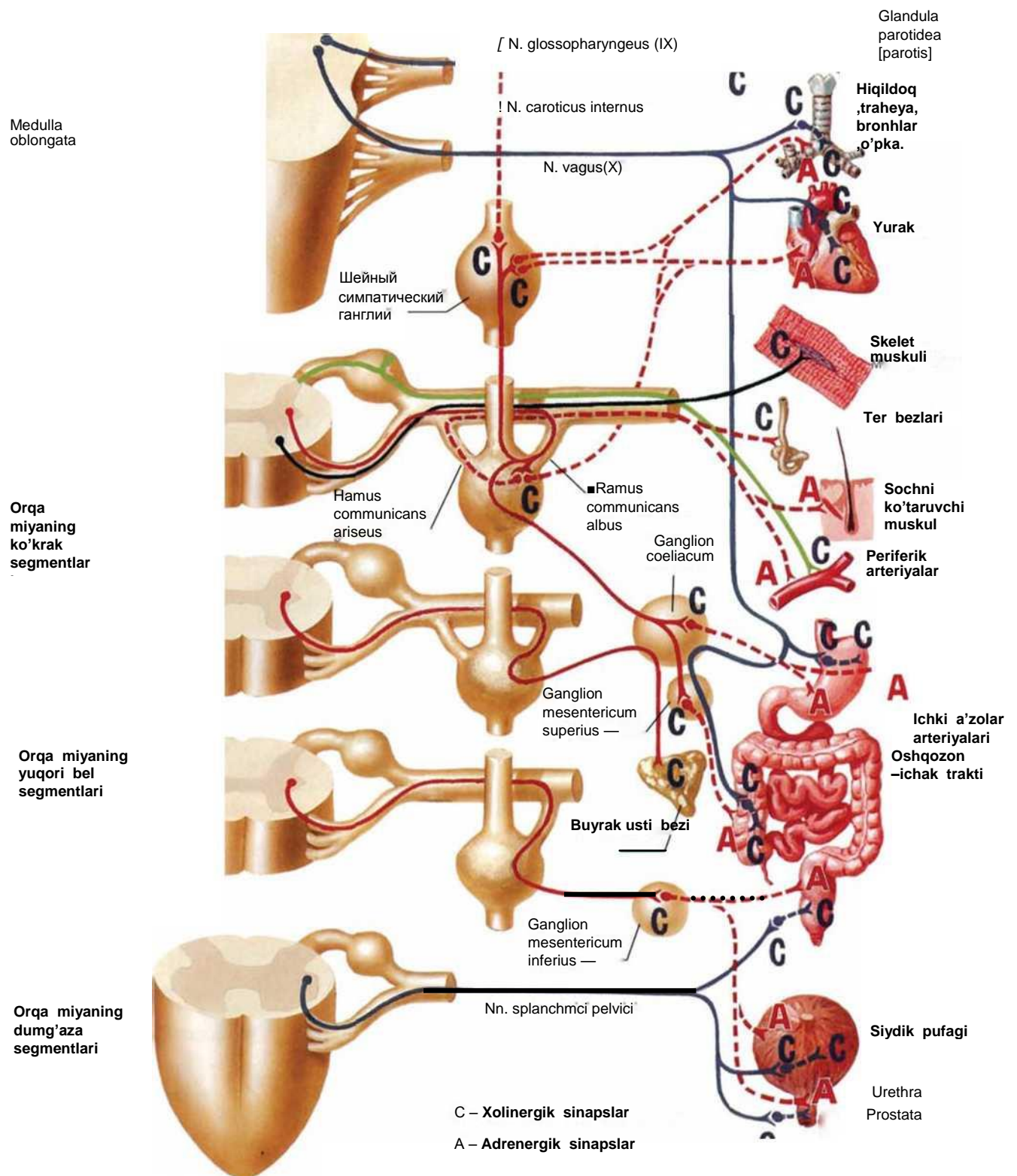
Vegetativ(avtonom) nerv tizimi: topografiyasi



Vegetativ(avtonom) nerv tizimi: tuzilishi

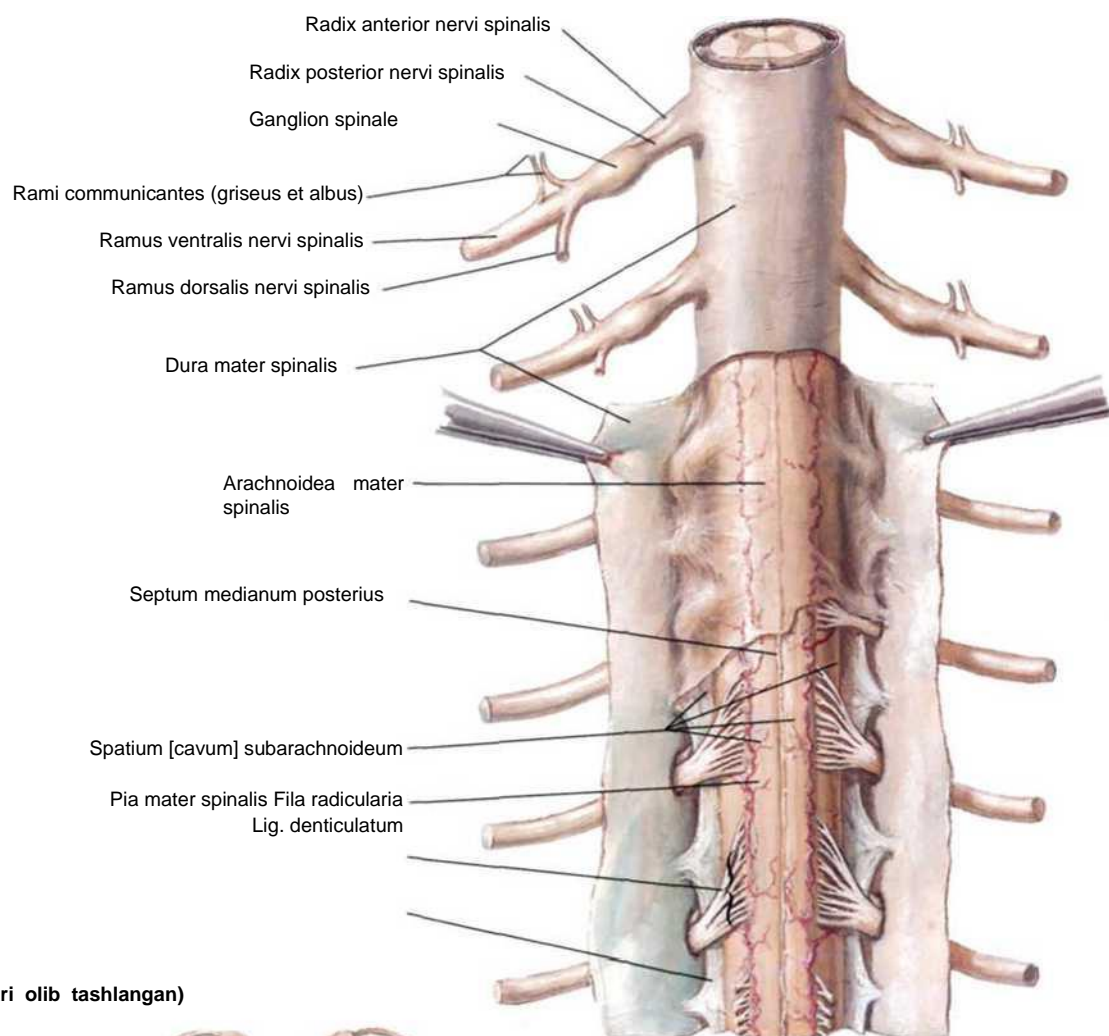


Xolinergik va adrenergik sinapslar: sxemasi

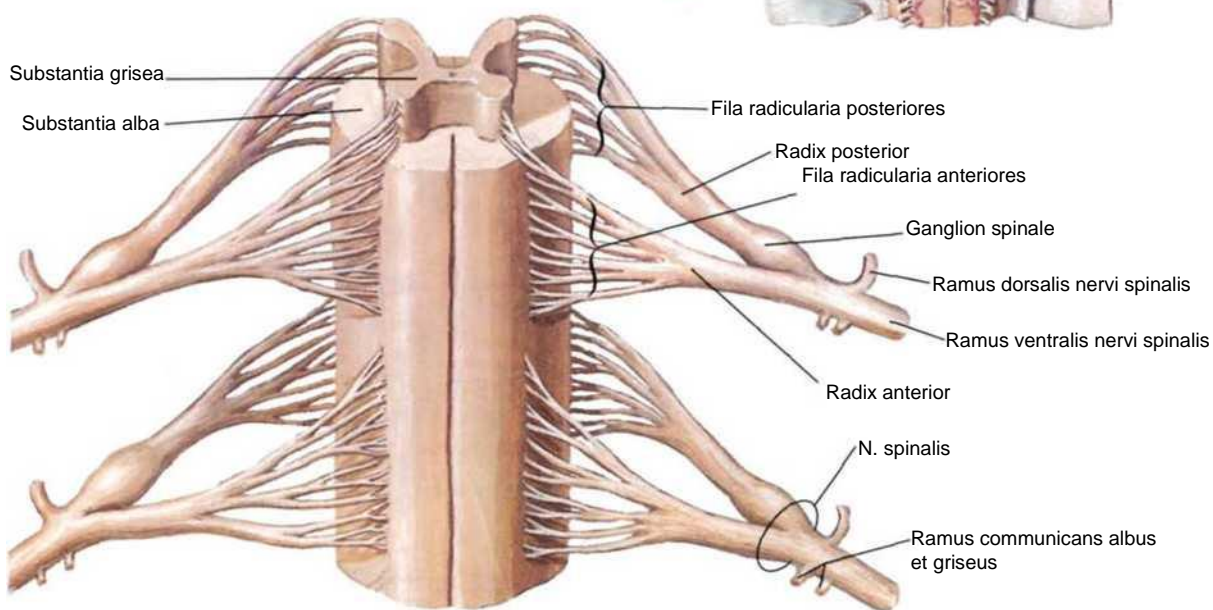


Orqa miya pardalari va ildizlari

Orqa tomoni

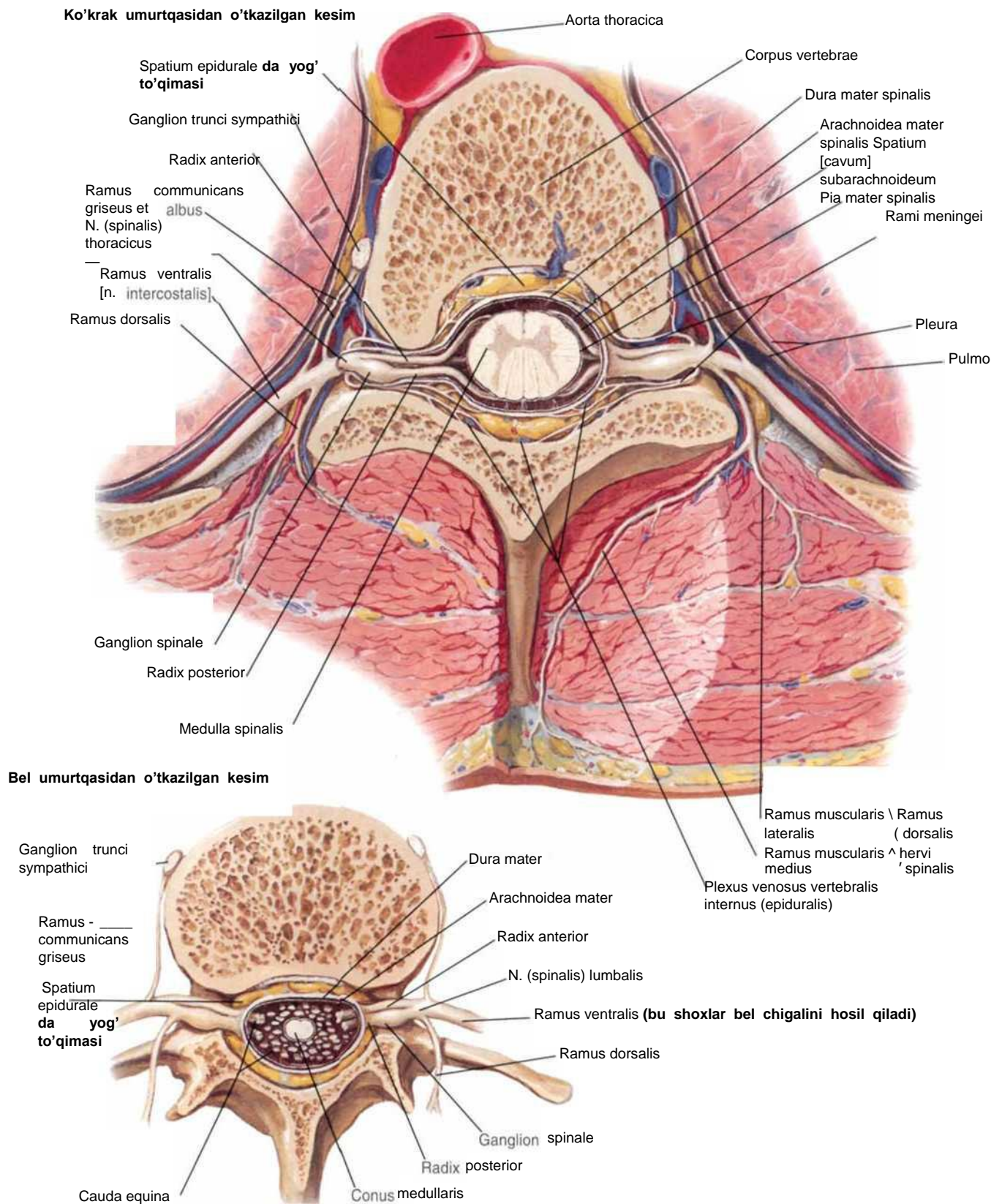


Old tomoni (qobiqlari olib tashlangan)



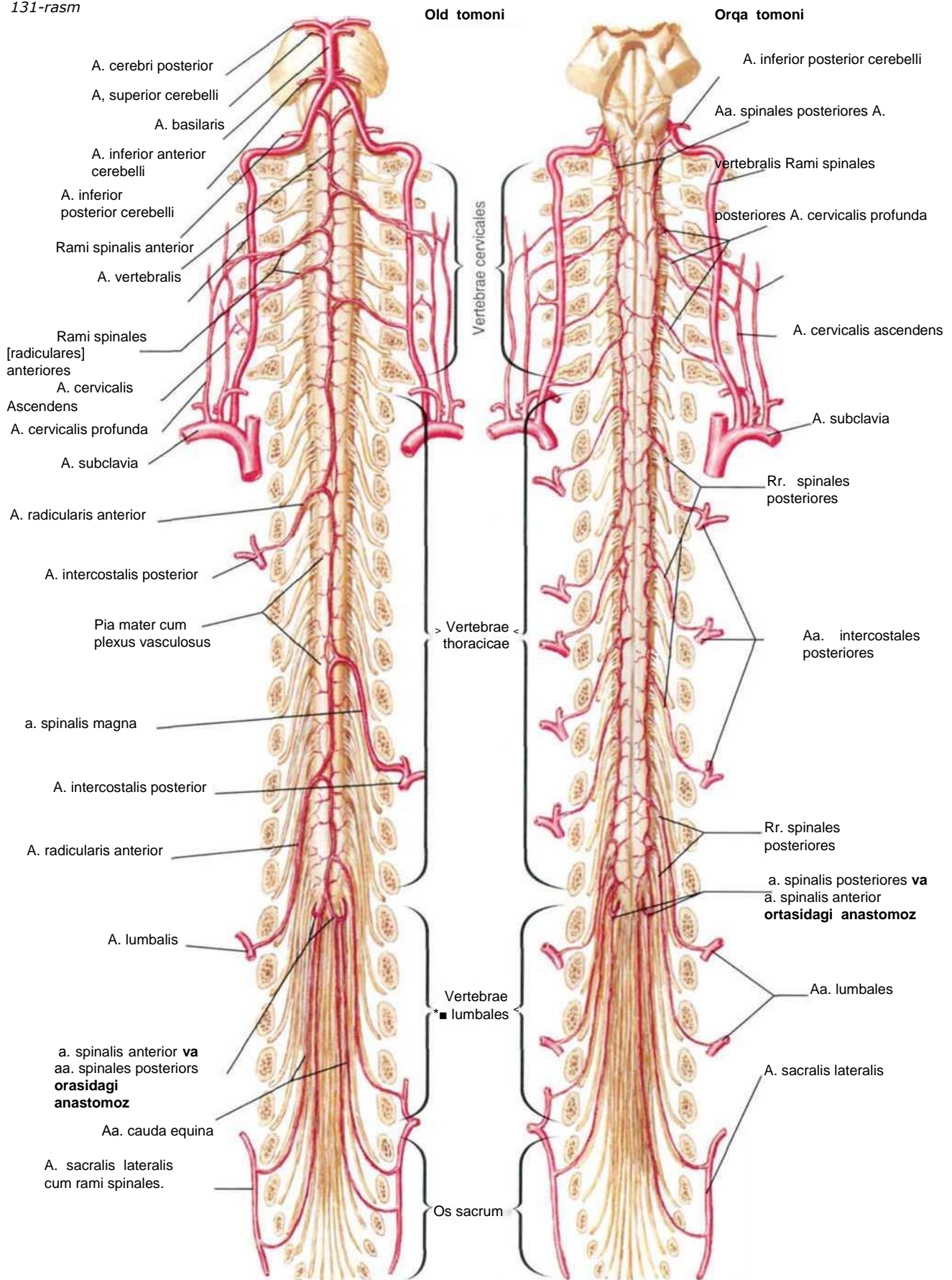
Orqa miya nervlarining hosil bo'lishi: ko'ndalang kesimi

154. 155. 158. 159-rasmlar.



Orqa miya arteriyalari: sxemasi

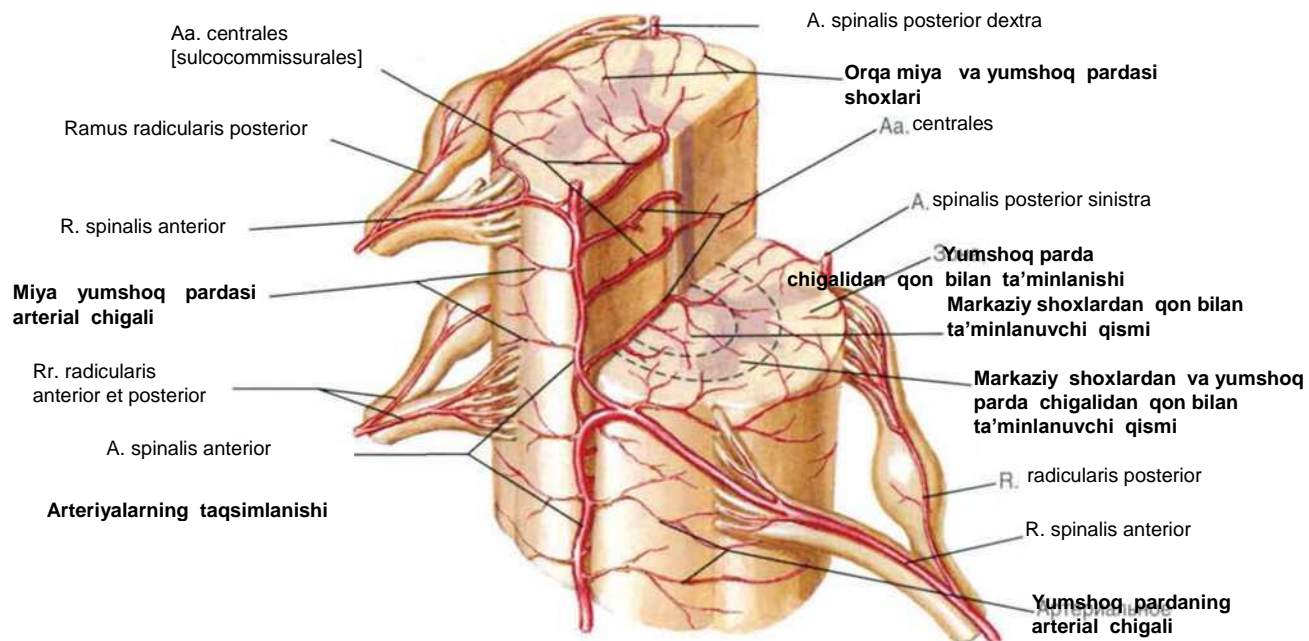
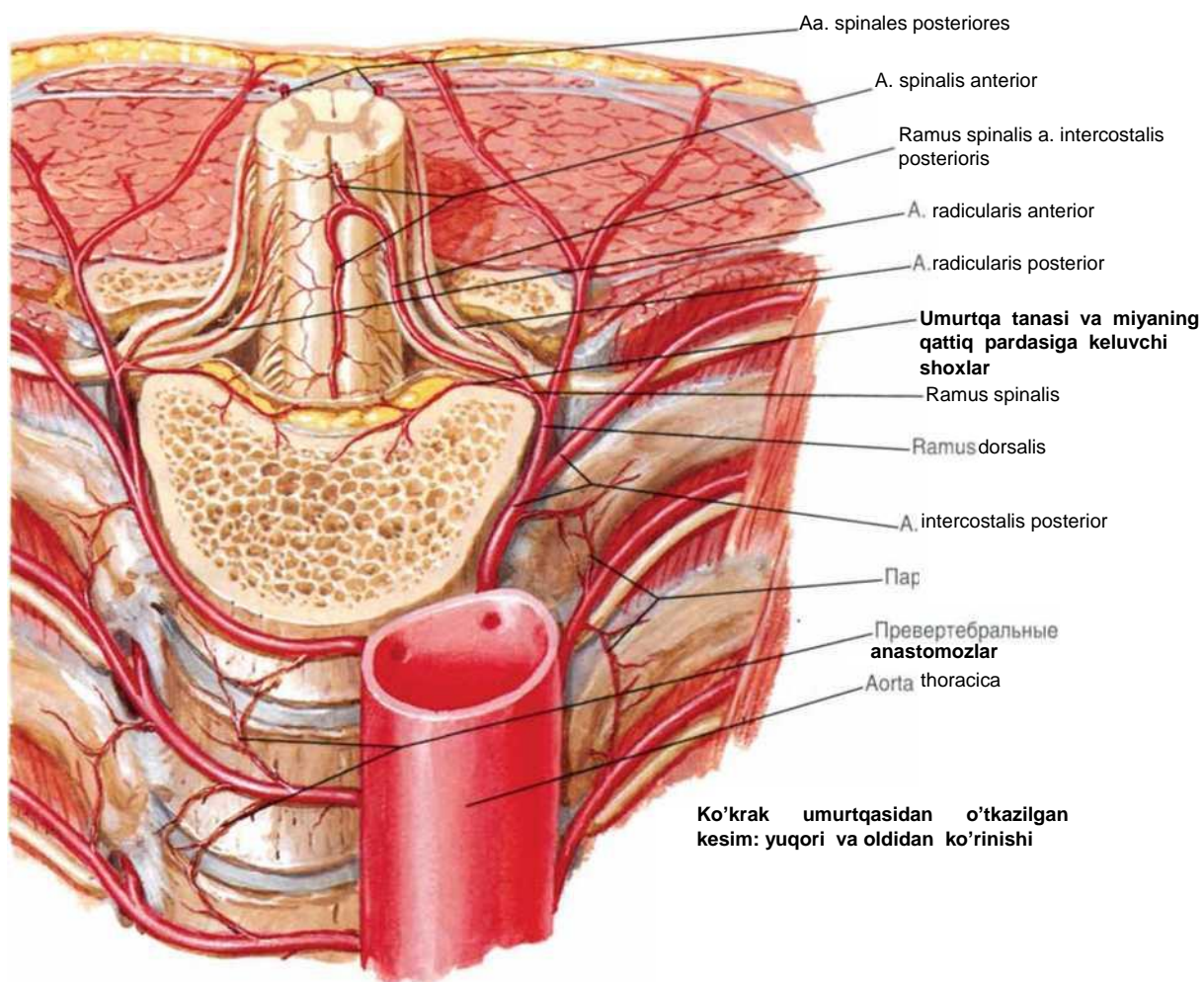
131-rasm



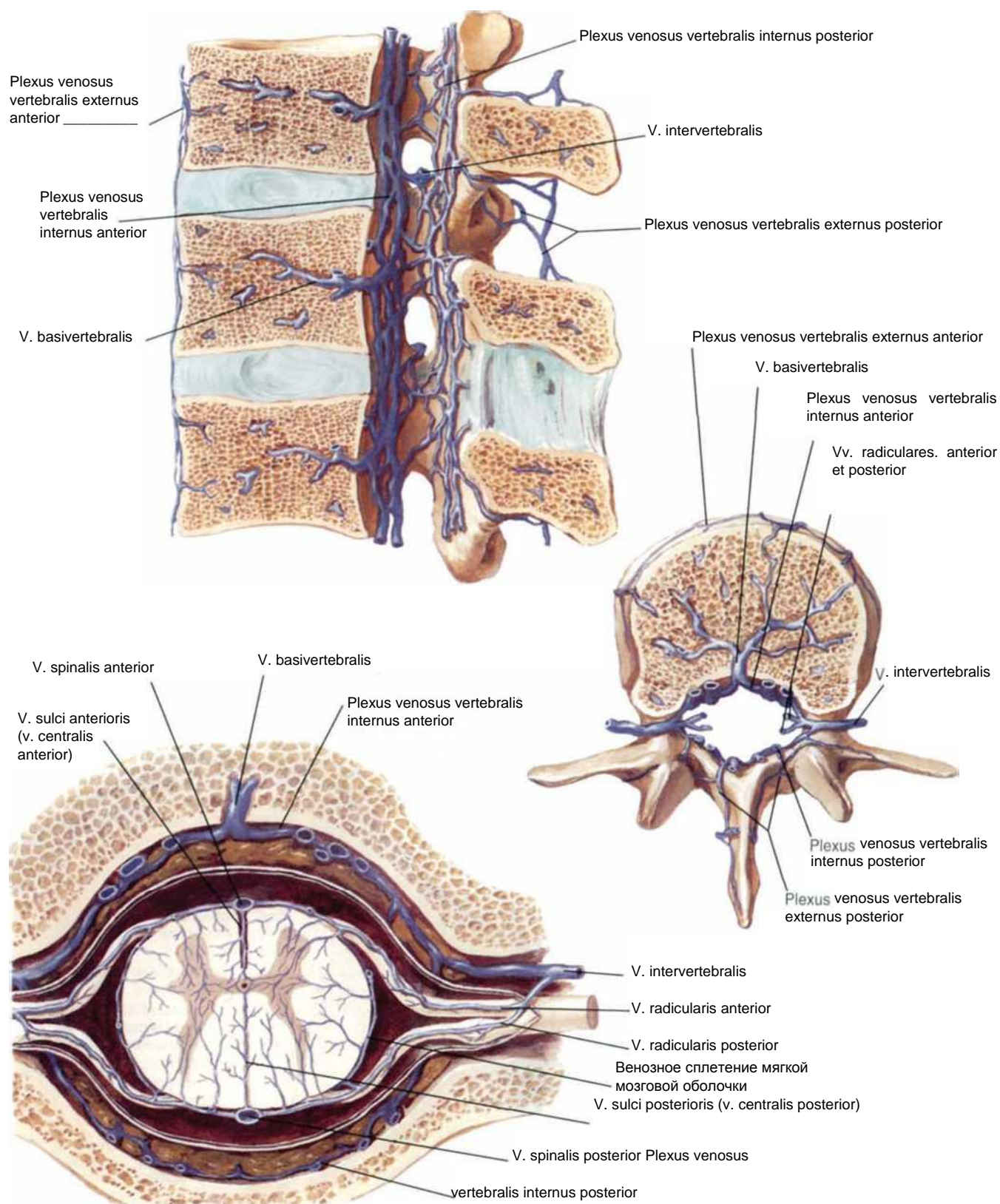
157-rasm

UMURTQA POG'ONASI

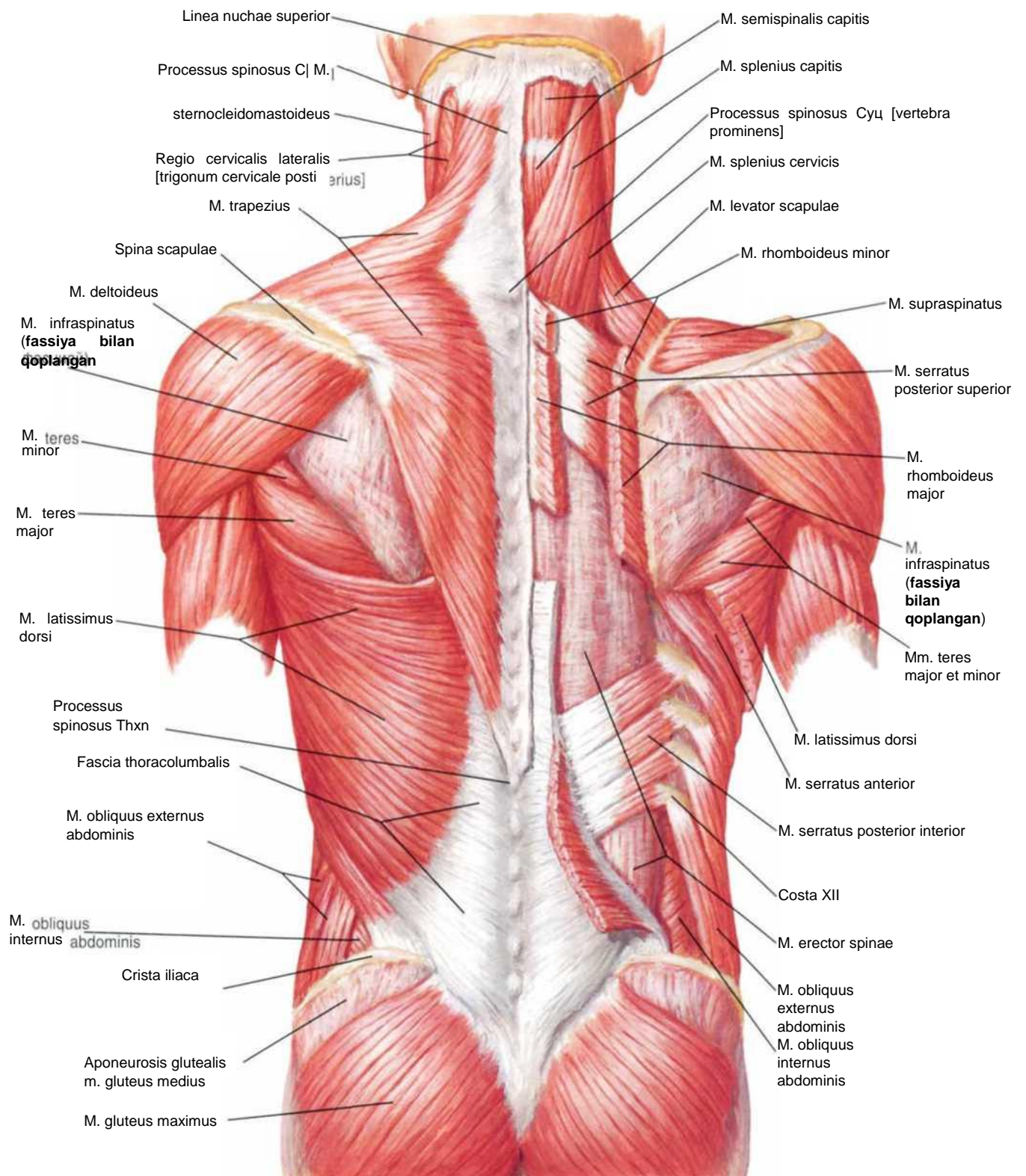
Orqa miya arteriyalari



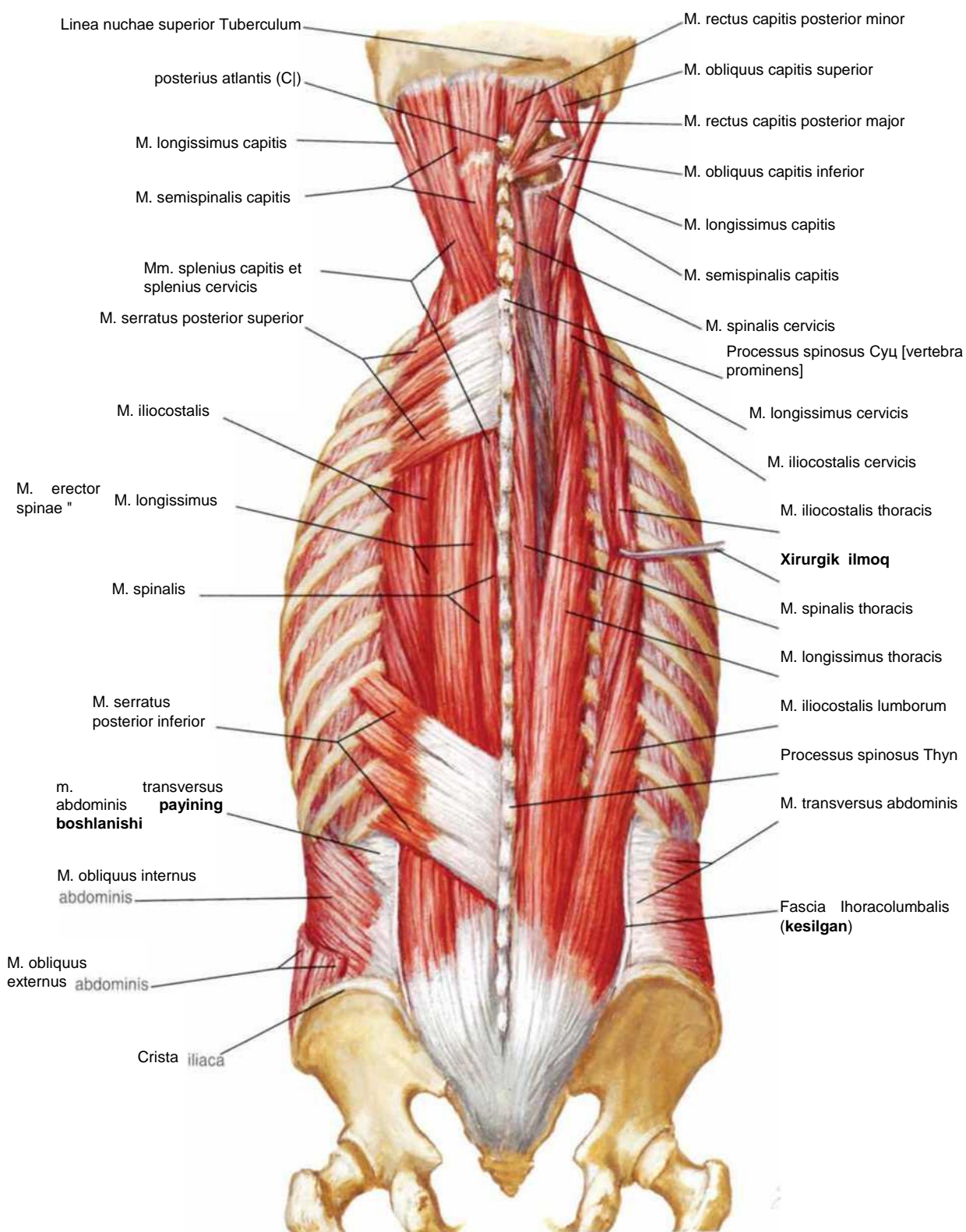
Umurtqa pog'onasi va orqa miyaning venalari



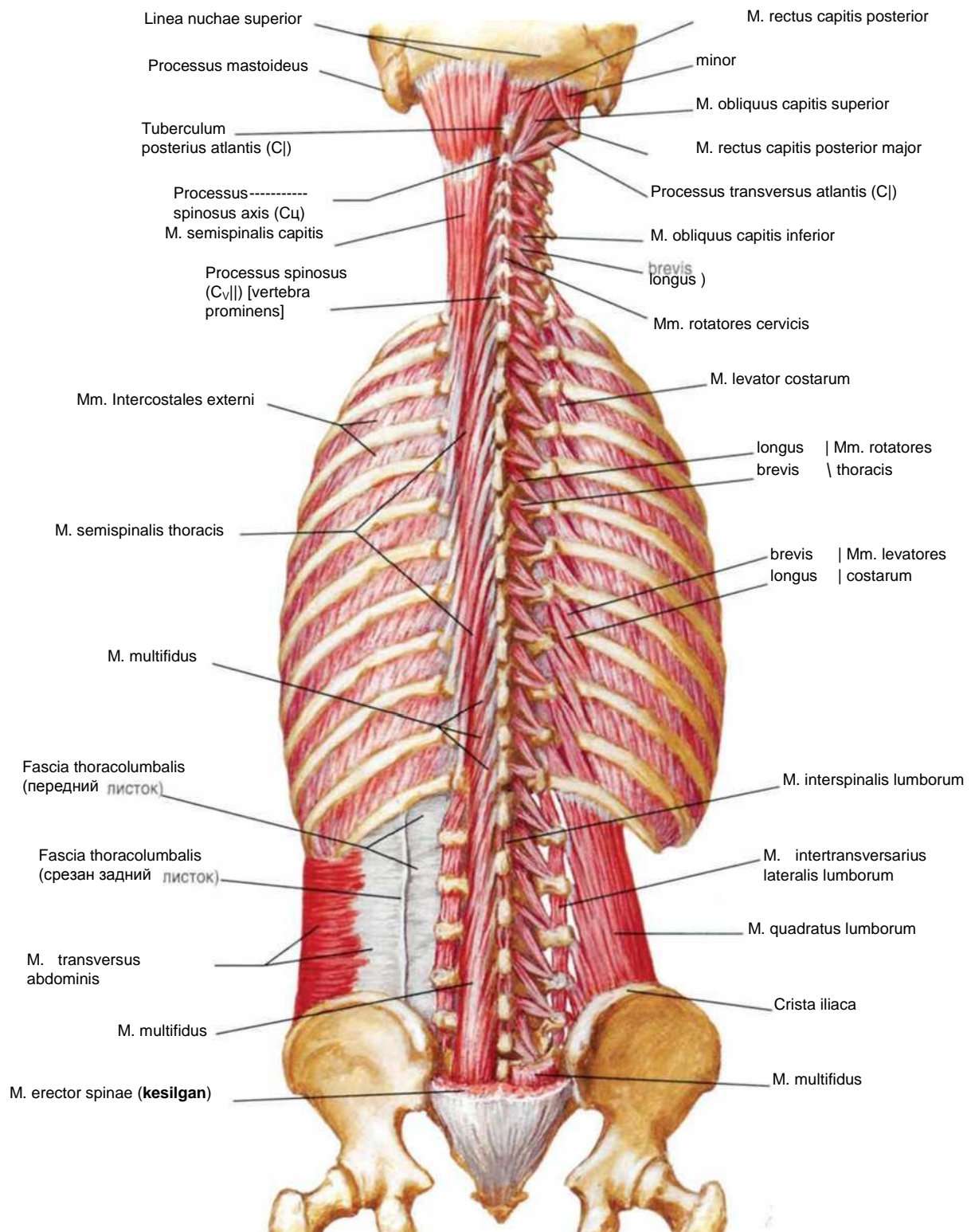
Gavdaning orqa muskullari(musculi dorsi):yuza qavati



Gavdaning orqa muskullari (musculi dorsi): o'rta qavati

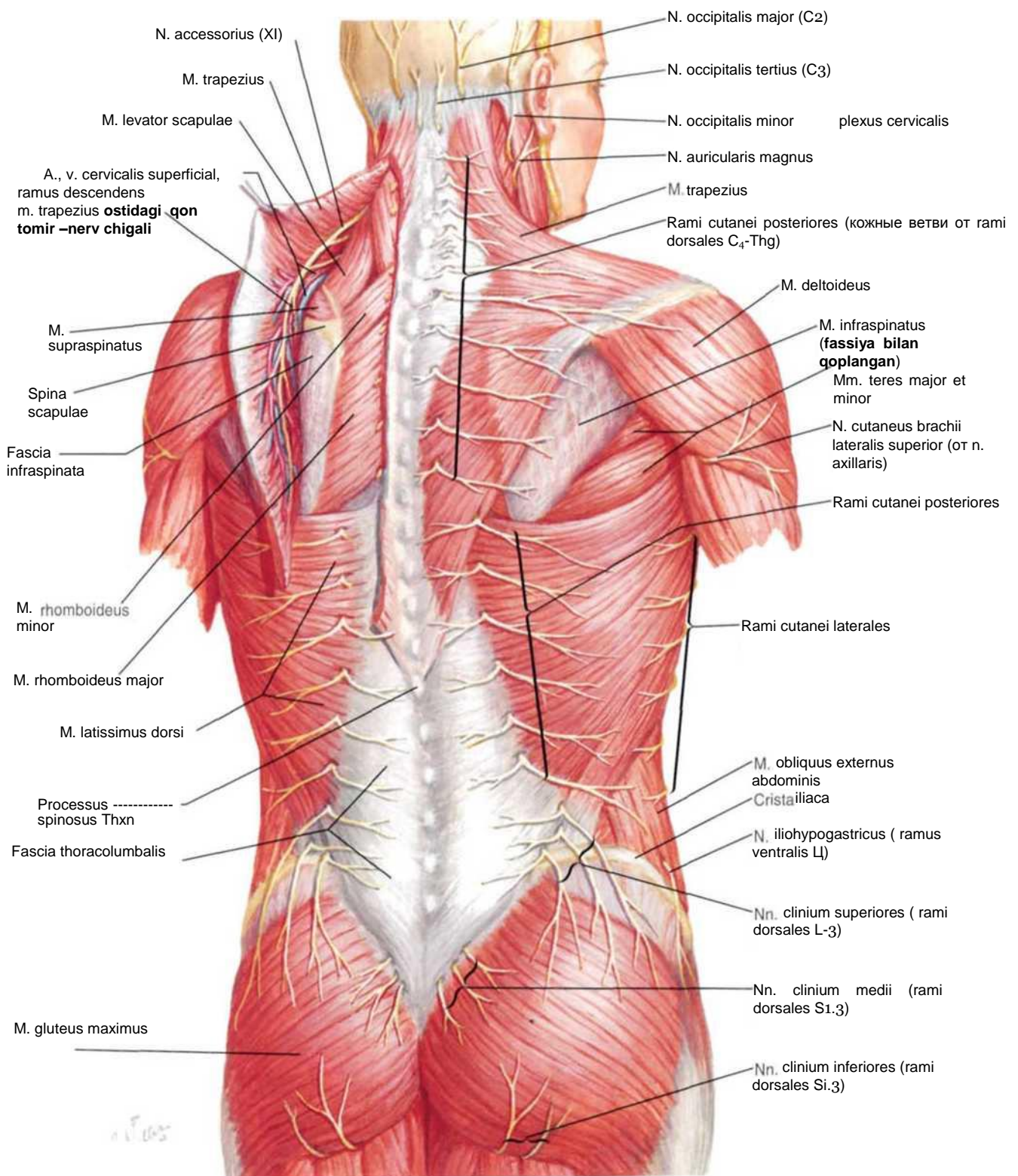


Gavdaning orqa muskullari (musculi dorsi): chuqur qavati



Gavda orqa sohasining nervlari

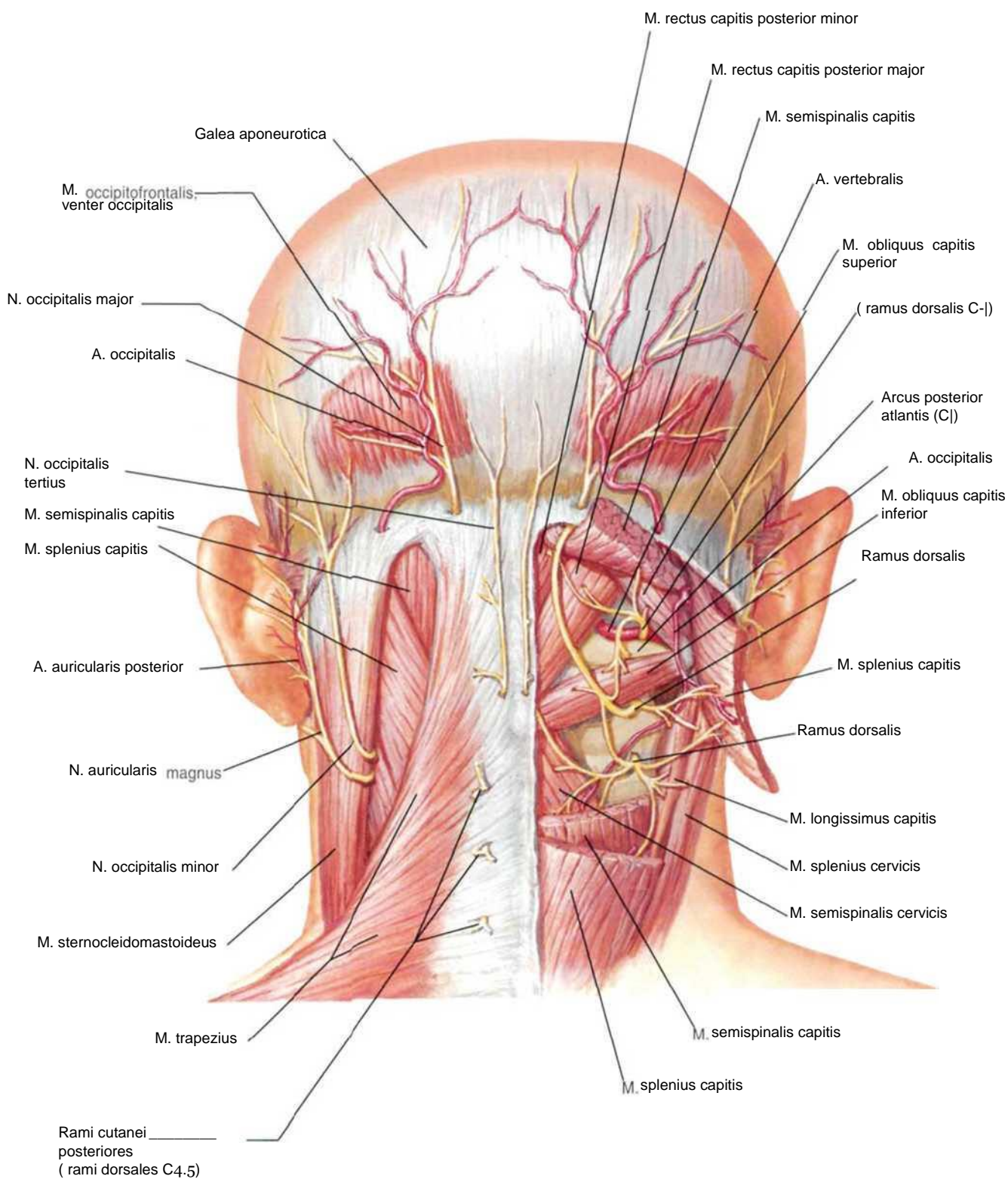
166, 179. 237. 241-rasmlar.



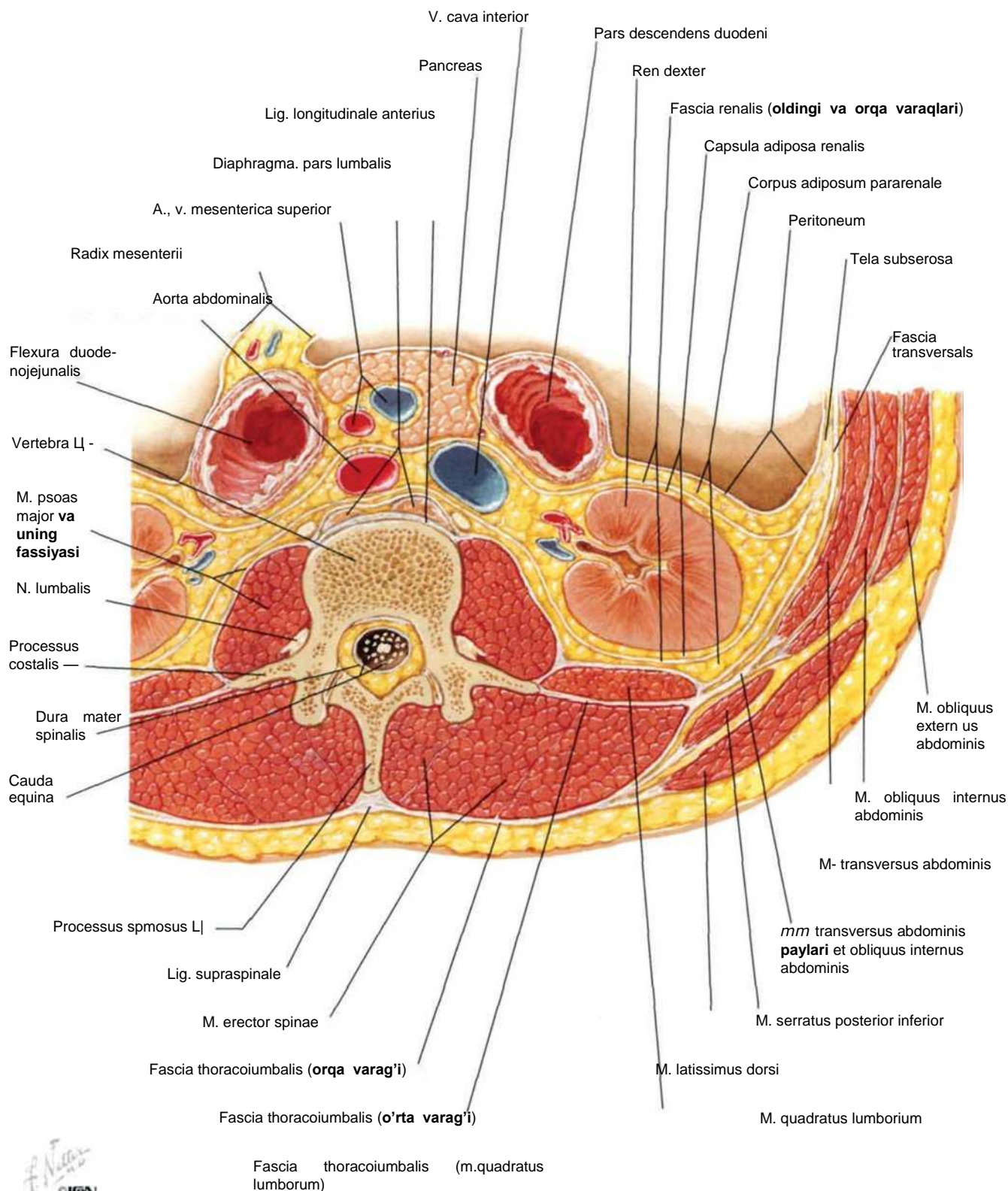
163-rasm

UMURTQA POG'ONASI

Bo'yinning orqa sohasi (regio cervicalis posterior [regio nuchalis])

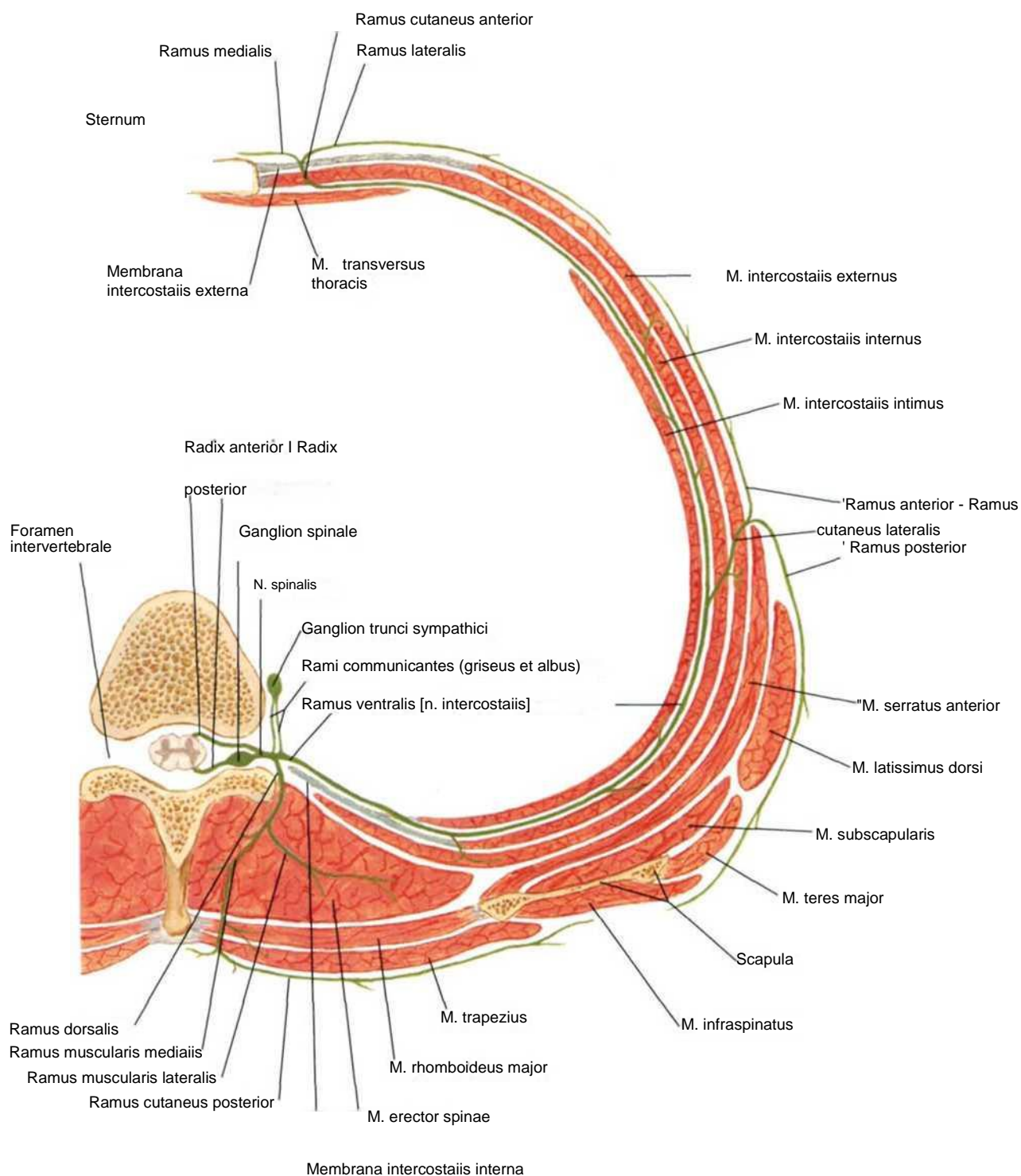


Bel sohasi (regio lumbalis): gorizontol kesim



Ko'krak nervlari (nervi thoracici)

179. 241-rasmlar.



III- Bo'lim

KO'KRAK

QAFASI

KO'KRAK BEZI

167-169 rasmlar

- 167. Ko'krak bezi (mamma)
- 168. Ko'krak besi arteriyalari
- 169. Ko'krak bezining limfatik tomirlari va tugunlari

Tananing devorlari

170-183 rasmlar

- 170. Ko'krak qafasi va yelka kamari suyaklari
- 171. Qovurg'a (costae) va to'sh-qovurg'a bo'g'imlari (articulationes sternocostales)
- 172. Qovurg'a-umurtqa bo'g'imlari (articulationes costovertebrales)
- 173. Bo'yin qovurg'alari va boshqa patologik holatlar
- 174. Ko'krak qafasining oldingi devori
- 175. Ko'krak qafasining oldingi devori(davomi)
- 176. Ko'krak qafasining oldingi devori: ichki tomoni
- 177. Ko'krak qafasining orqa va yonbosh devori
- 178. Gavdaning orqa sohasi (dorsum)

- 179. Qovurg'alararo nerv hamda arteriyalar
- 180. Diafragma (diaphragma):yuqoridan ko'rinishi
- 181. Diafragma (diaphragma):pastdan ko'rinishi
- 182. Diafragma nervi (nervus phrenicus)
- 183. Nafas olishda ishtirok etuvchi muskullar

O'PKALAR

184-199

rasmlar

- 184. O'pkalar topografiyasi:oldidan ko'rinishi
- 185. O'pkalar topografiyasi:orqadan ko'rinishi
- 186. O'pkalar (pulmones): oldidan ko'rinishi
- 187. O'pkalar (pulmones):medial tomoni
- 188. O'pkaning segmentlari
- 189. O'pkaning segmentlari (davomi)
- 190. Traxeya (trachea) va bronxlar (bronchi)
- 191. Bronxlar nomenklaturasi: sxemalarda
- 192. O'pka ichidagi havo o'tkazuvchi yo'llar
- 193. O'pka ichidagi qon sirkulyasiyasi: sxemasi
- 194. O'pka arteriya va venalari
- 195. Oldingi ko'ks oralig'ining yirik tomirlari
- 196. Bronxlarning arteriya va venalari

- 197. O'pkaning limfatik tomir va tugunlari
- 198. Ko'krak qafasining vegetative nervlari
- 199. Traxeya va bronxlar innervatsiyasi (sxemasi)

YURAK

200-217rasm

- 200. Yurak (cor) va perikard (pericardium)
- 201. Yurak (cor), old tomoni
- 202. Yurak: asosi va diafragmal yuzasi
- 203. Perikard (pericardium)
- 204. Yurakning toj arteriyalari (arteriae coronariae) va venalari (venae cordis)
- 205. Yurak toj arteriyalari va venalarining variantlari
- 206. Toj arteriyalar: arteriografiya
- 207. Toj arteriyalar: arteriografiya (davomi)
- 208. Ong bo'lmacha (atrium dextrum) va ong qorincha (ventriculus dexter)
- 209. Chap bo'lmacha (atrium sinistrum) va chap qorincha (ventriculus sinister)
- 210. Klapanlar (valvae) va yurakning fibroz skeleti
- 211. Klapanlar (valvae) va yurakning fibroz skeleti (davomi)
- 212. Bo'lmachalar, qorinchalar va qorinchalararo to'siq

- 213. Yurakning o'tkazuvchi tizimi
- 214. Yurak innervatsiyasi
- 215. Yurak innervatsiyasi (davomi)
- 216. Qon-tomirlar innervatsiyasi: sxemasi
- 217. Prenatal va postnatal qon aylanishi

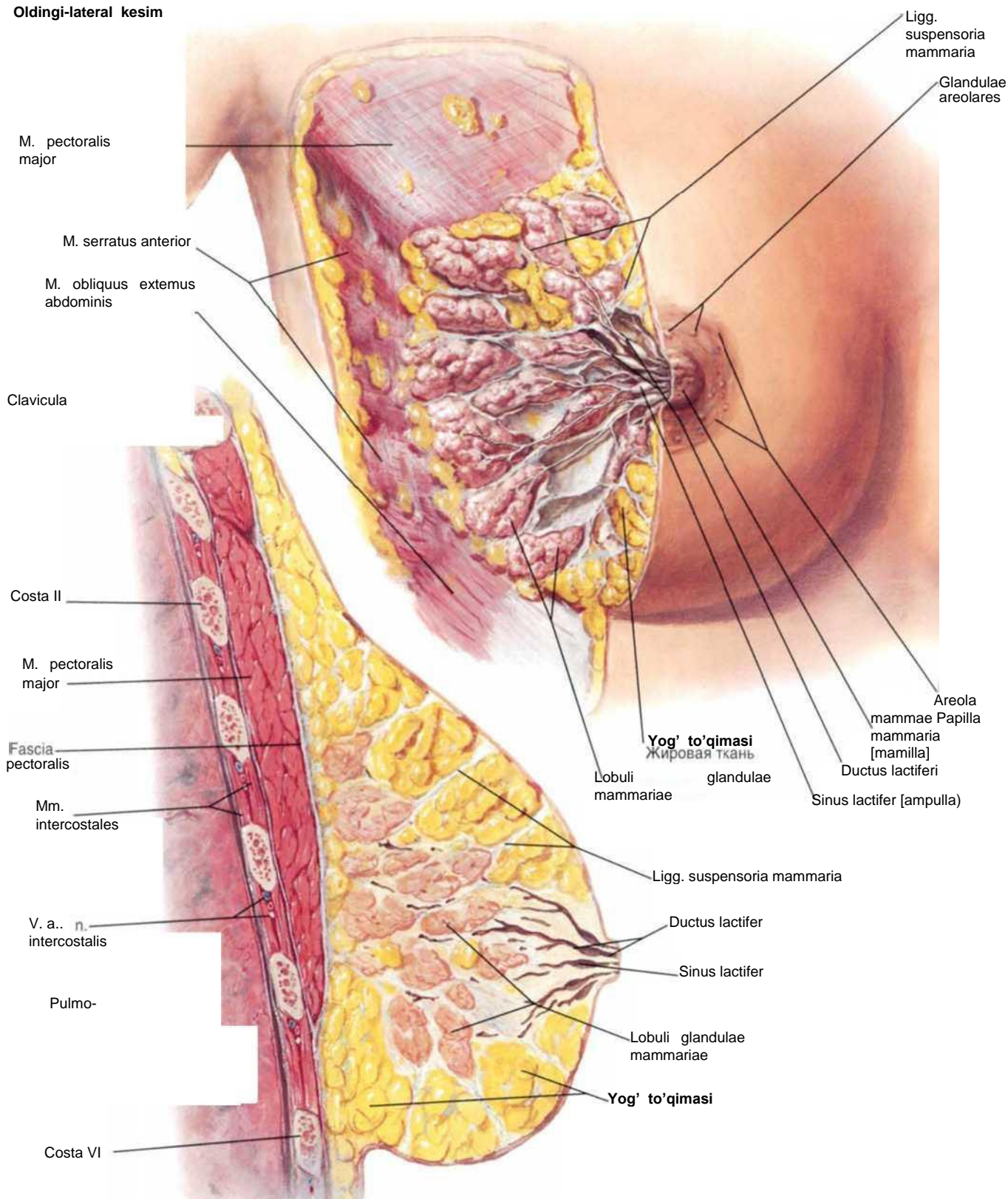
KO'KS ORALIG'I

218-230rasm

- 218. Ko'ks oralig'i (mediastinum), o'ng yonboshdan ko'rinishi
- 219. Ko'ks oralig'i (mediastinum), chap yonboshdan ko'rinishi
- 220. Qizilo'ngach (oesophagus):topografiyasi
- 221. Qizilo'ngach toraymalari va topografiyasi
- 222. Qizilo'ngach muskullari
- 223. Halqumdan qizilo'ngachga o'tish qismi
- 224. Qizilo'ngachdan me'daga o'tish qismi
- 225. Qizilo'ngach arteriyalari
- 226. Qizilo'ngach venalari
- 227. Qizilo'ngach limfatik tomir va tugunlari
- 228. Qizilo'ngach innervatsiyasi
- 229. Ichki nervlar va qizilo'ngach nervlarining turlari
- 230. Ko'ks oralig'i (mediastinum), gorizontal kesim (yuqoridan ko'rinishi)

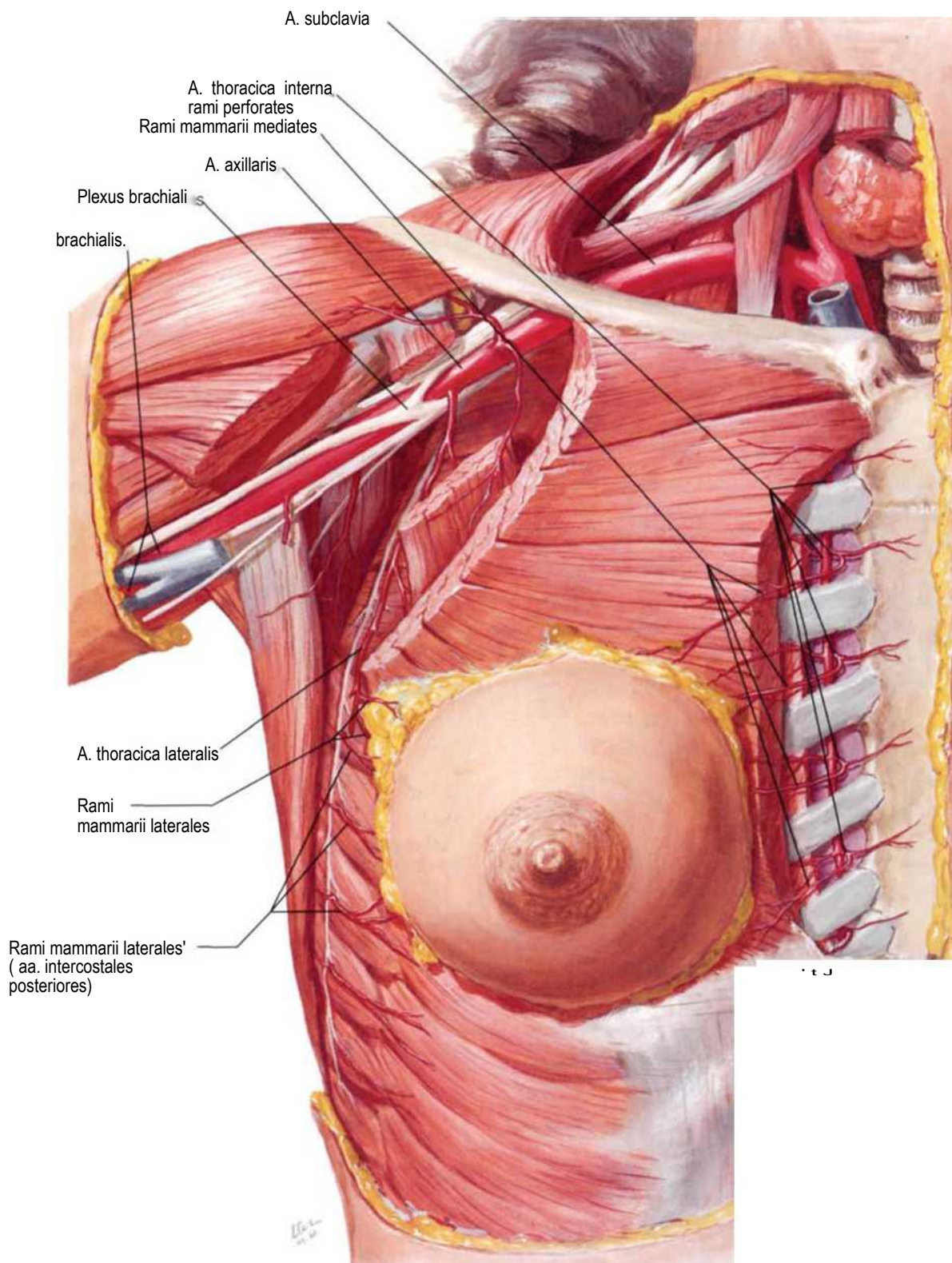
Ko'krak bezi (mamma)

Oldingi-lateral kesim

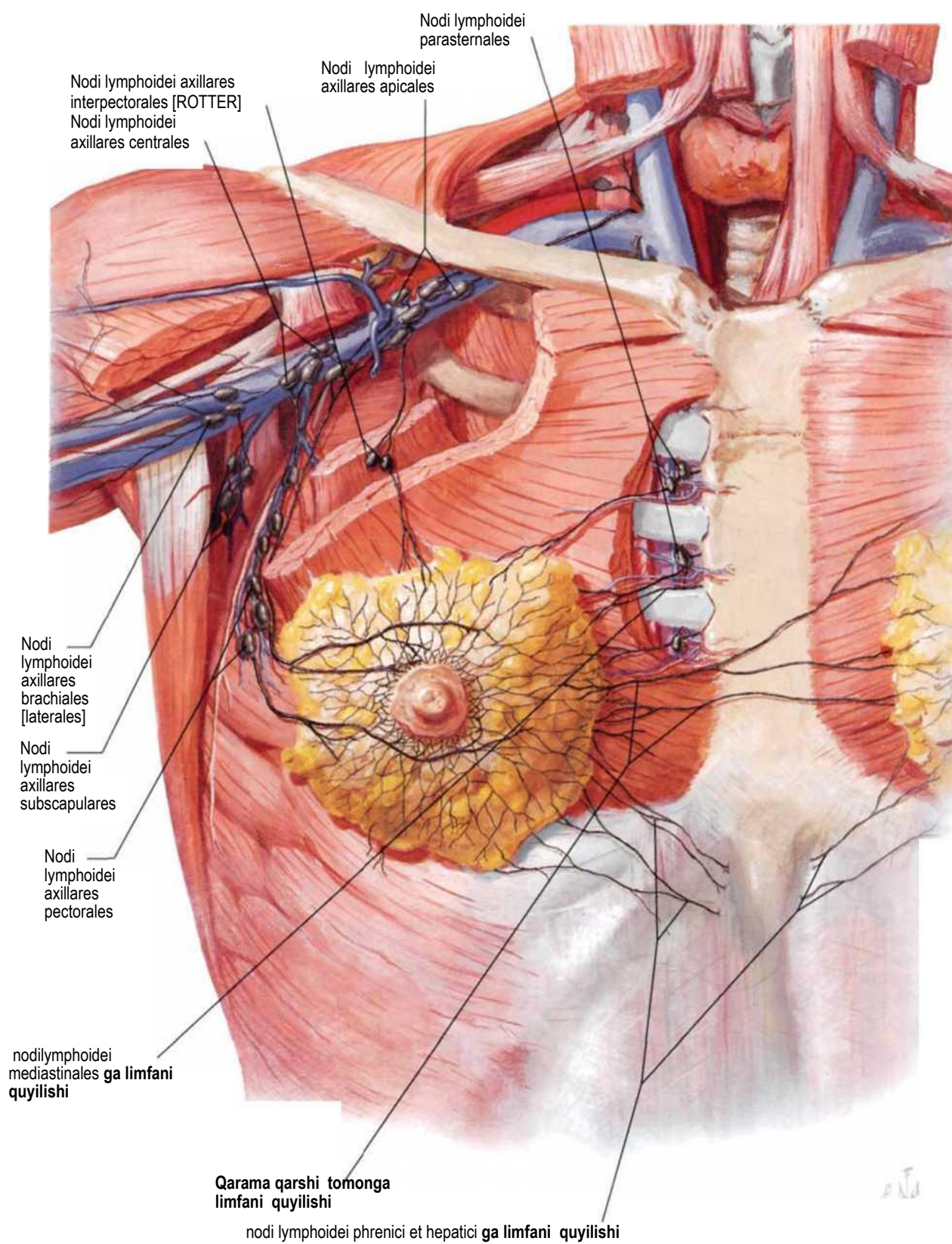


Sagittal kesim

Ko'krak bezi arteriyalari



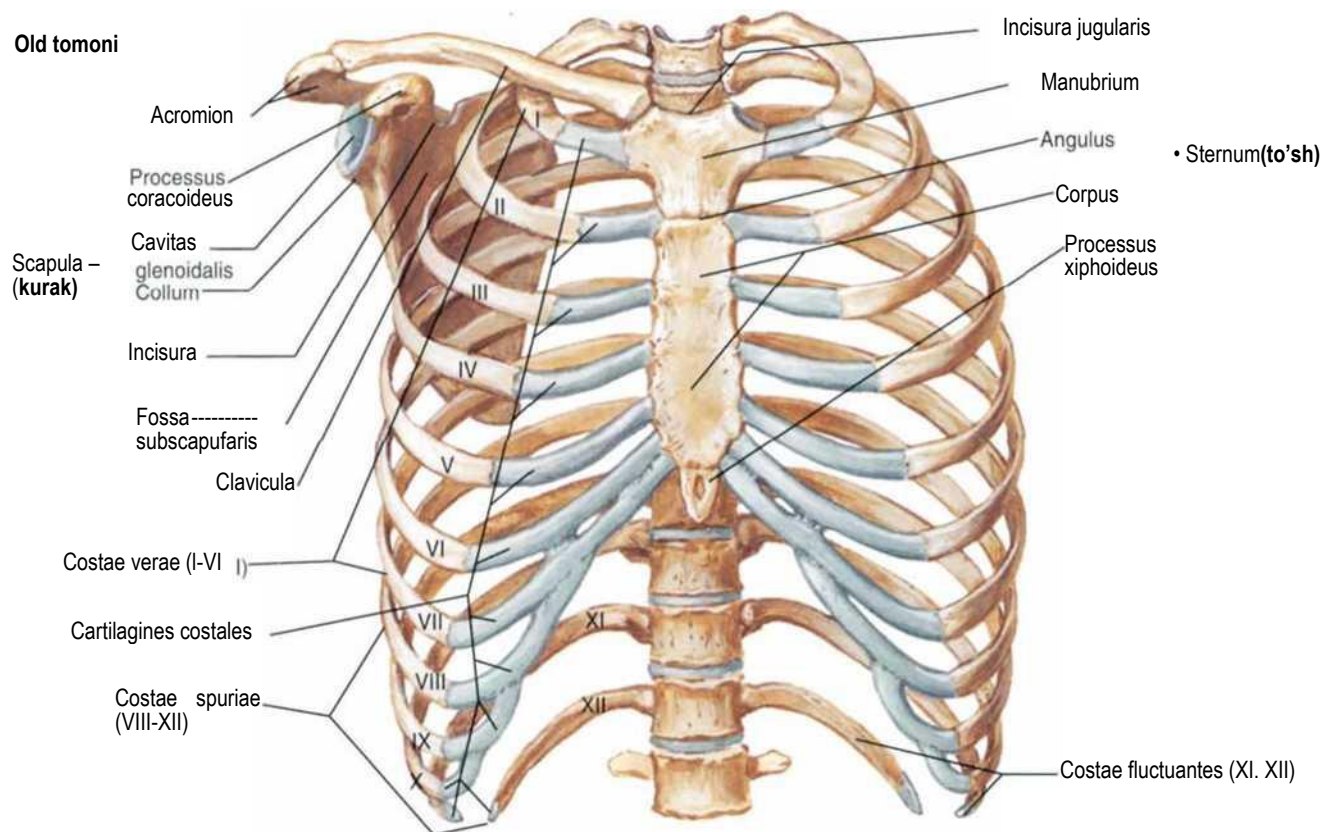
Ko'krak bezining limfa tomirlari va tugunlari



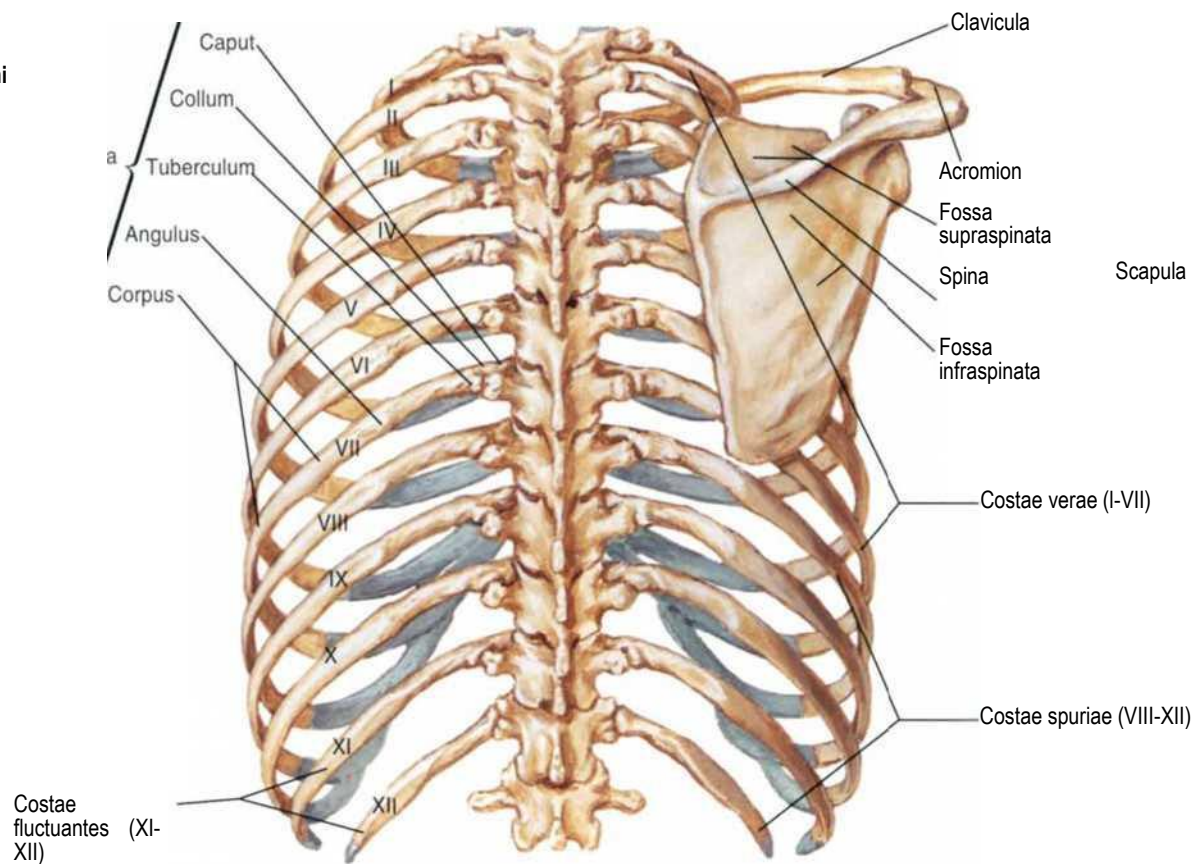
Ko'krak qafasi va yelka kamari suyaklari

231-rasm.

Old tomoni



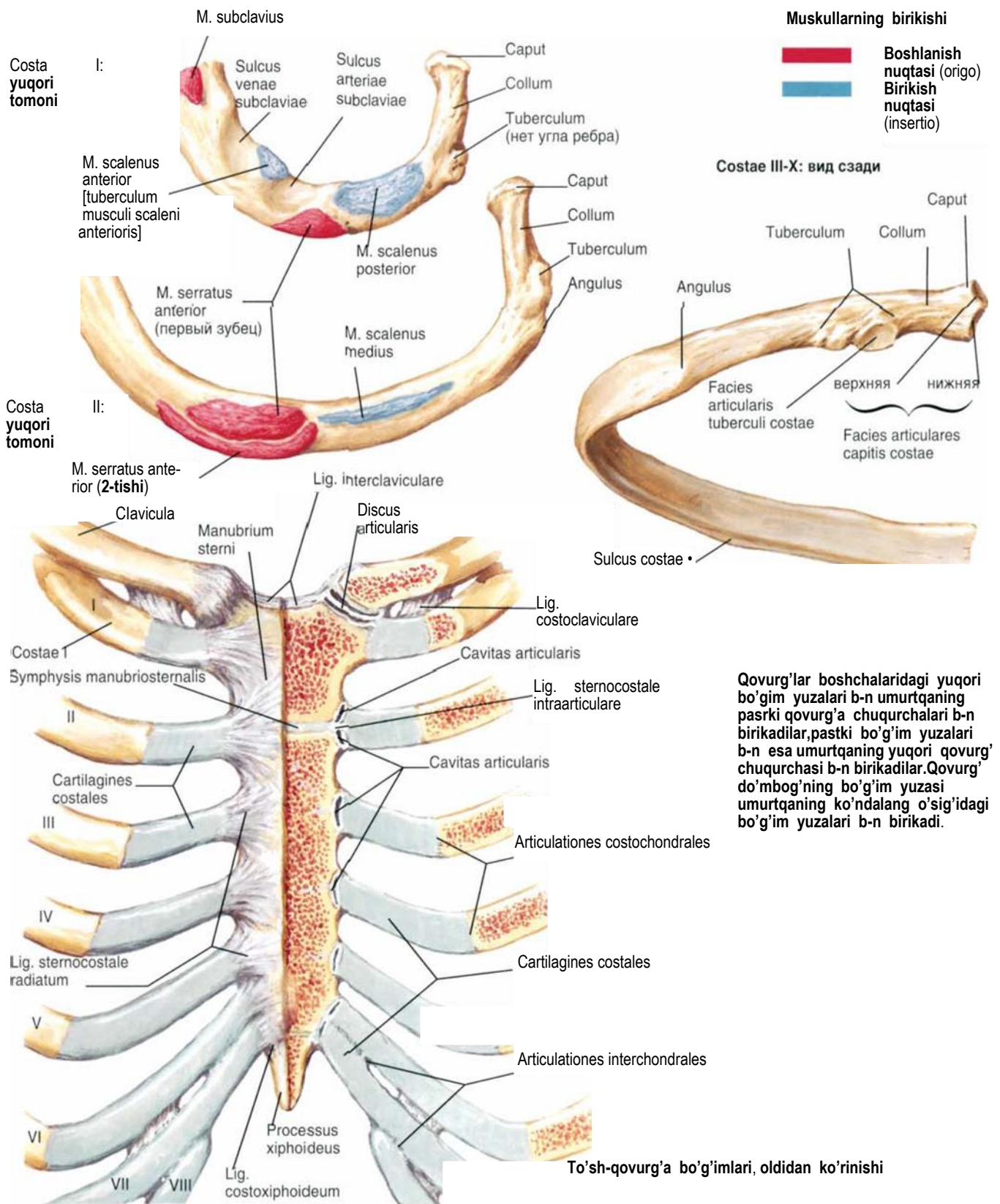
Orqa tomoni



170-rasm

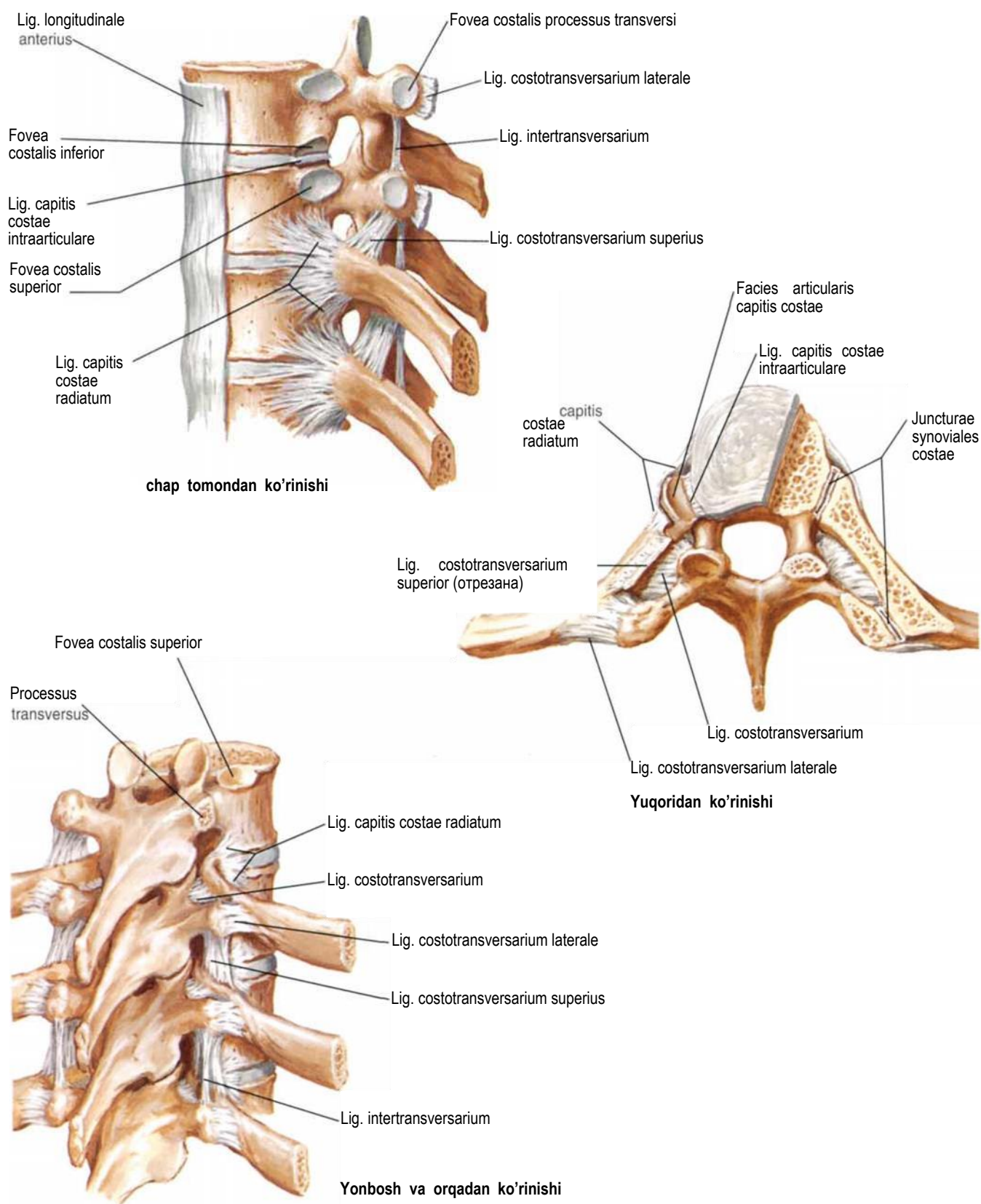
KO'KRAK QAFASI

Quvurg'lar (costae) va to'sh-qovurg'a bo'g'imlari



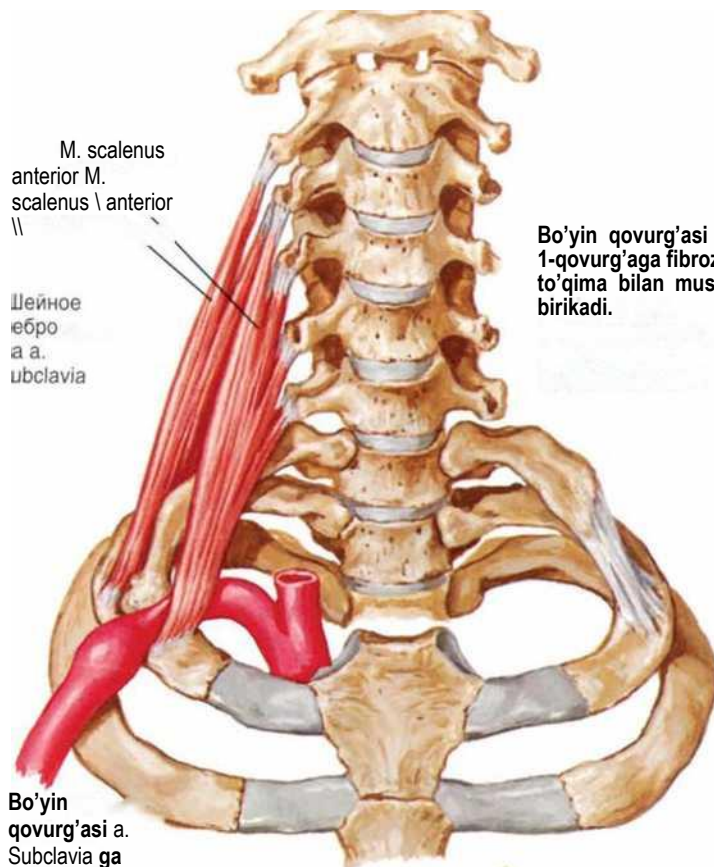
Qovurg'a-umurtqa bo'g'implari (articulationes costovertebrales)

143-rasm

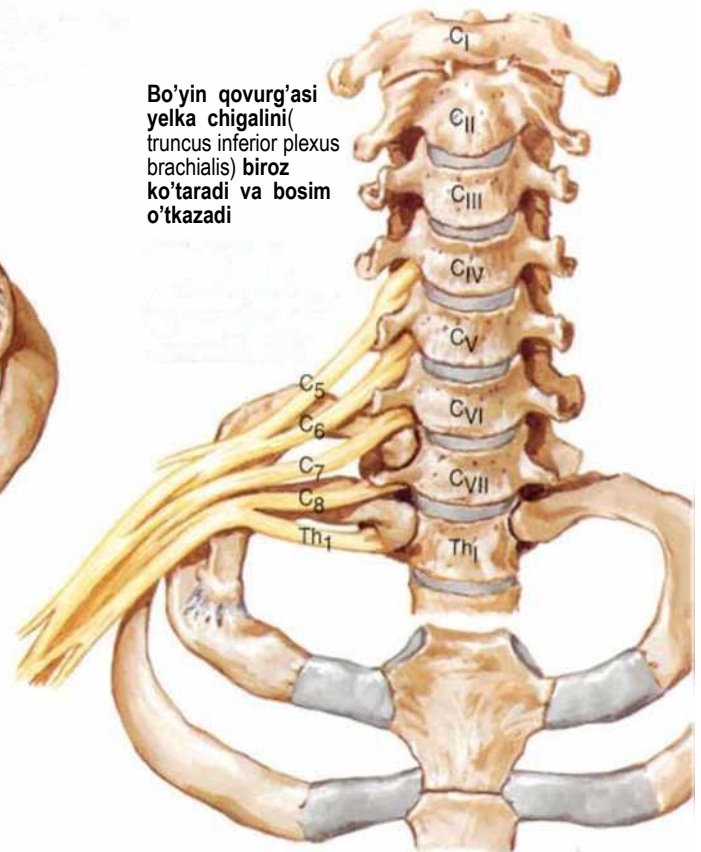


172-rasm

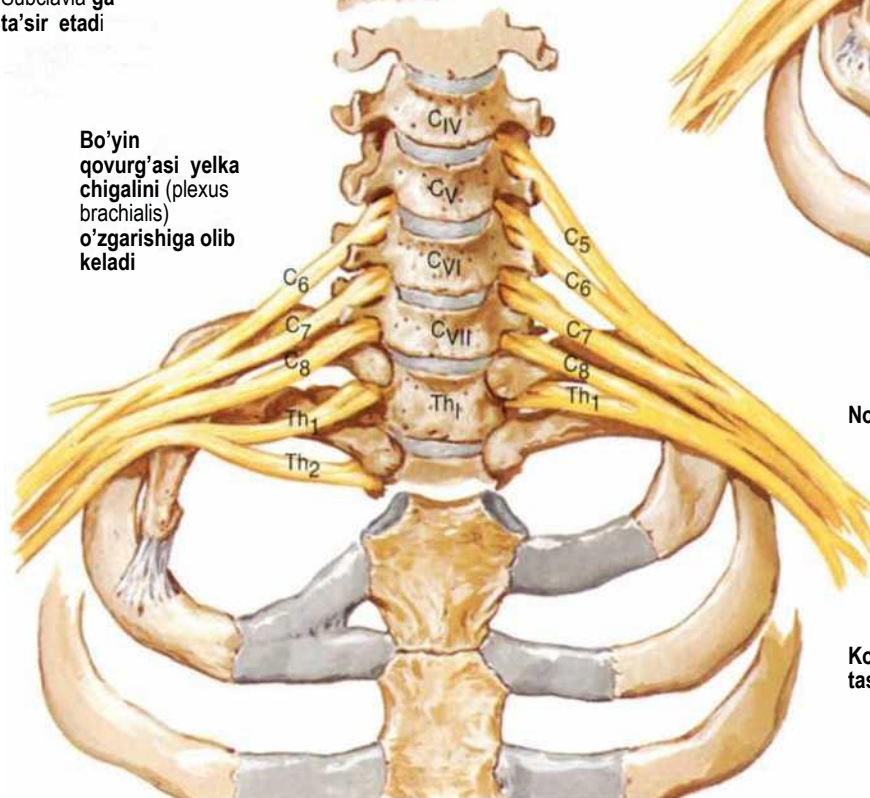
KO'KRAK QAFASI



Bo'yin qovurg'asi 1-qovurg'aga fibroz to'qima bilan mustahkam birikadi.



Bo'yin qovurg'asi yelka chigalini (truncus inferior plexus brachialis) biroz ko'taradi va bosim o'tkazadi

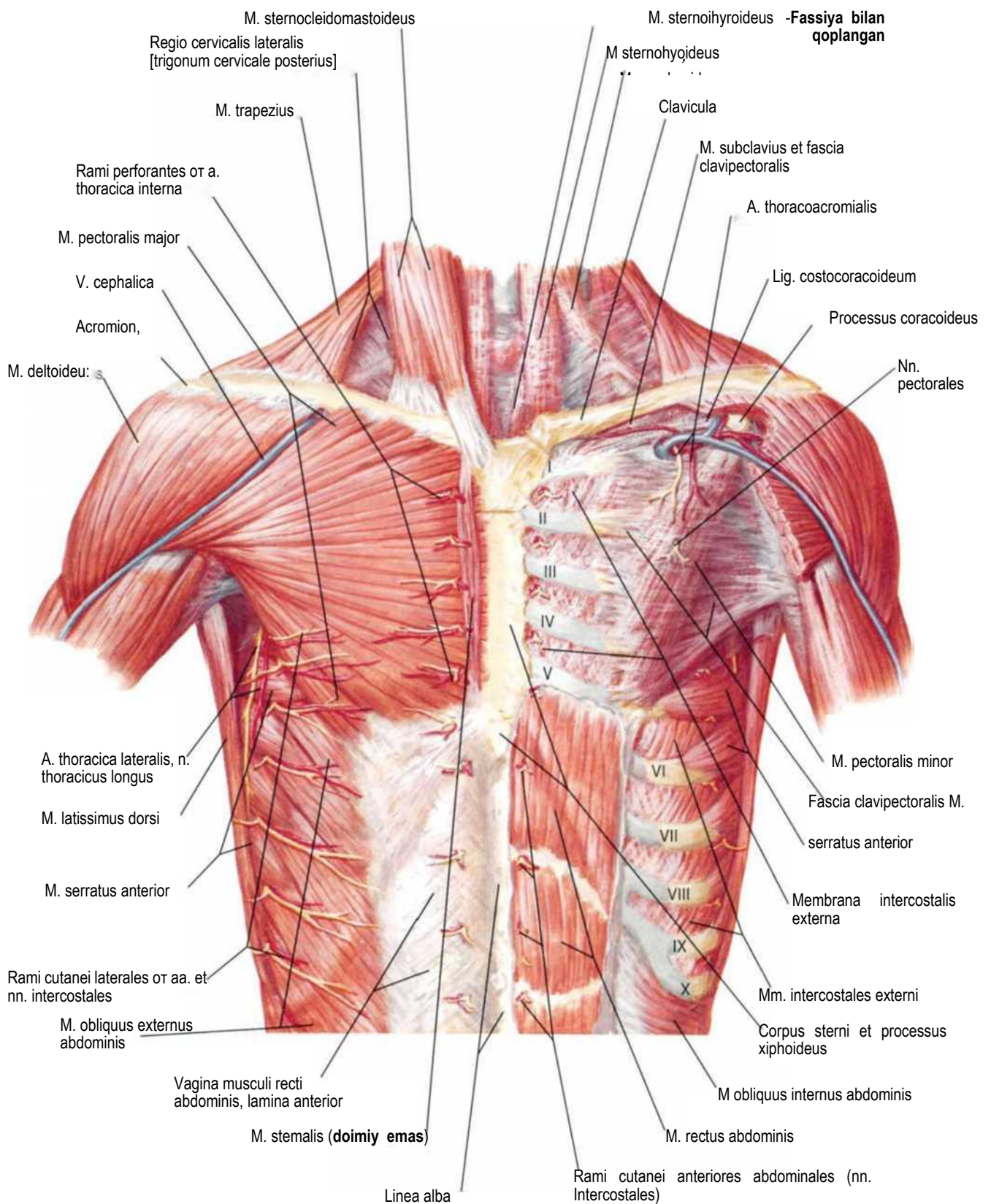


Bo'yin qovurg'asi yelka chigalini (plexus brachialis) o'zgarishiga olib keladi

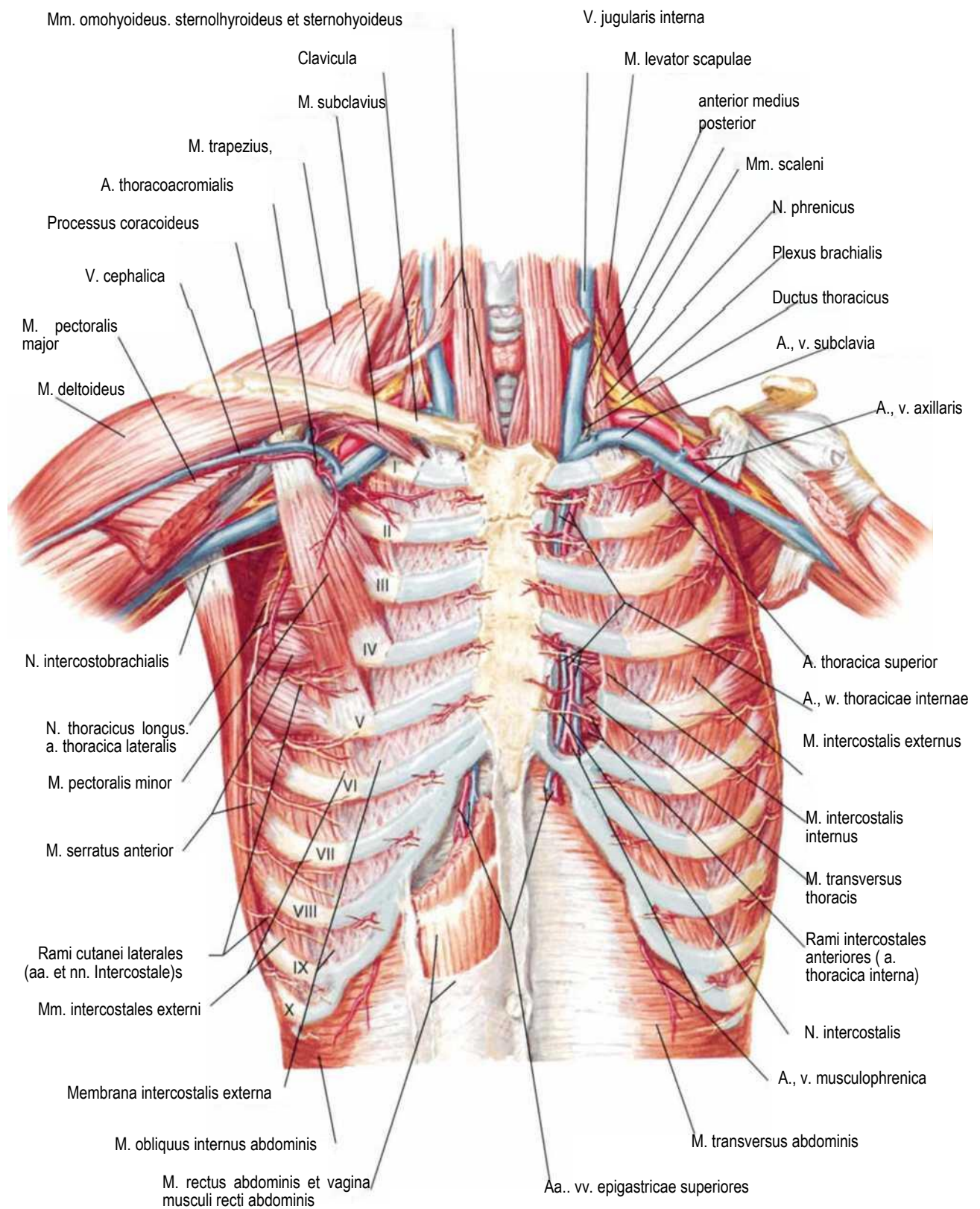
Normal holat

Ko'p hollarda Bo'yin qovurg'lari tashqi klinik aniqlanmaydi

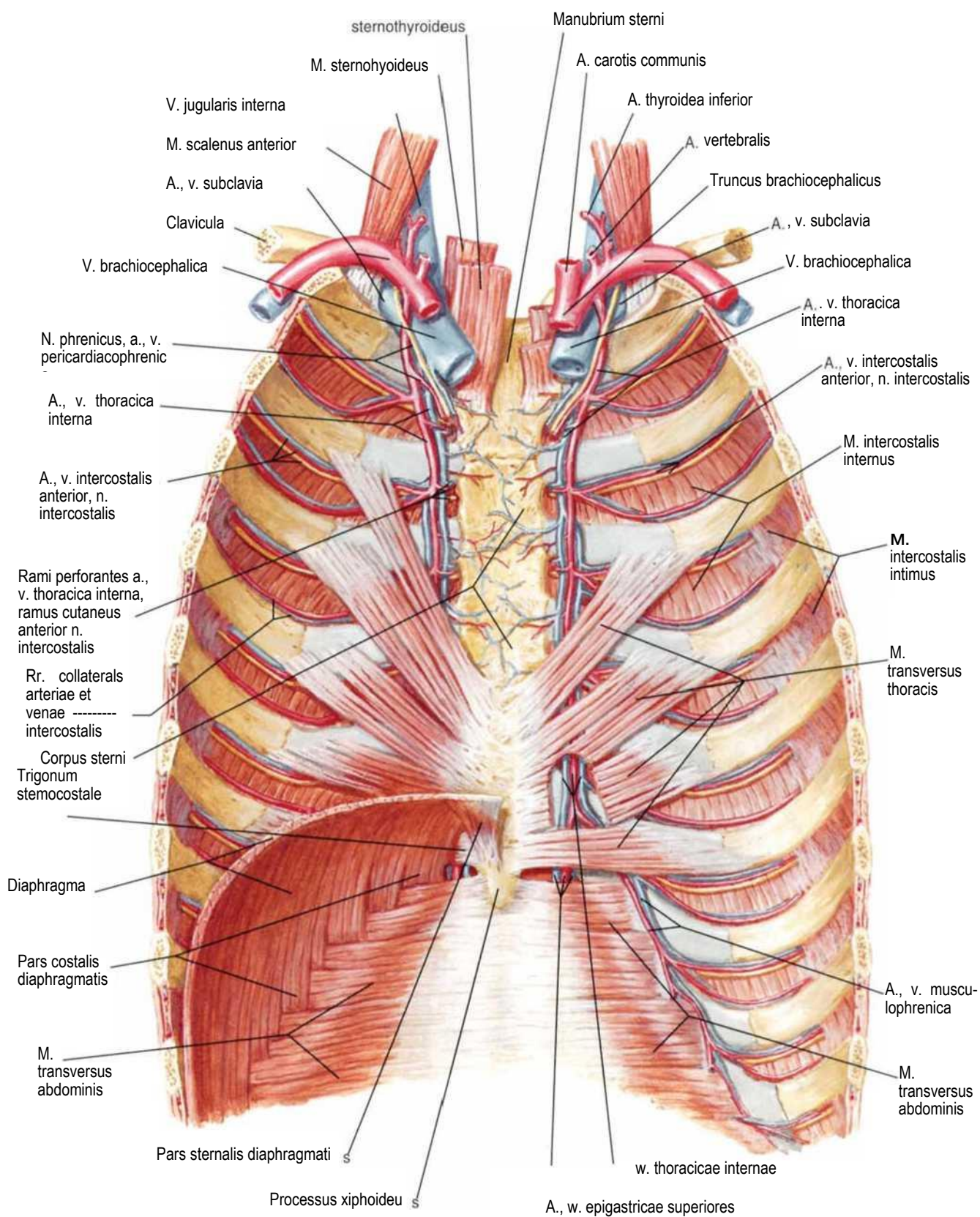
Ko'krak qafasining oldingi devori



Ko'k rak qafasining oldingi devori (davomi)

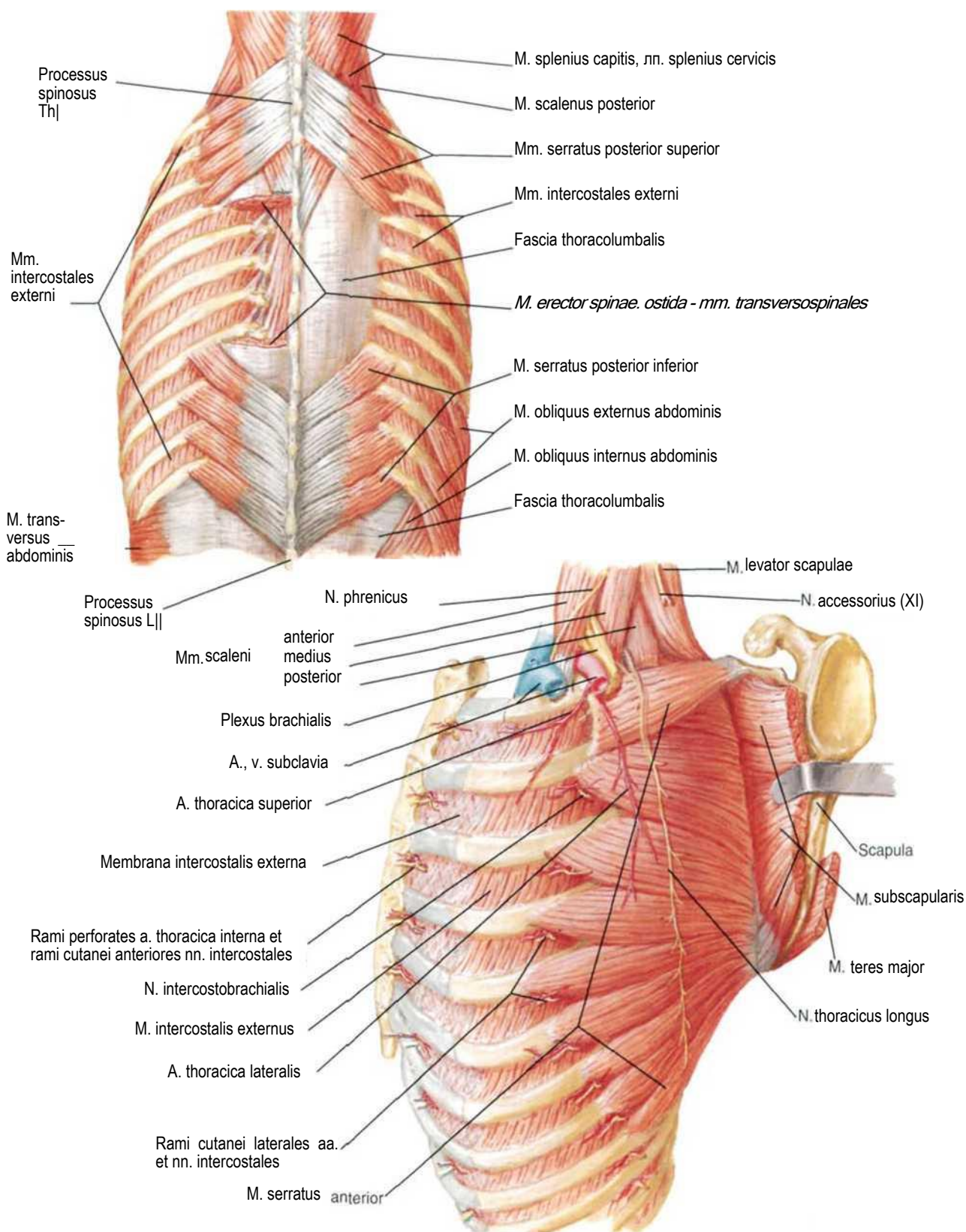


Ko'krak qafasining oldingi devori: ichki tomoni



Ko'krak qafasining yonbosh va orqa devorlari

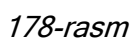160-162-rasmlar.

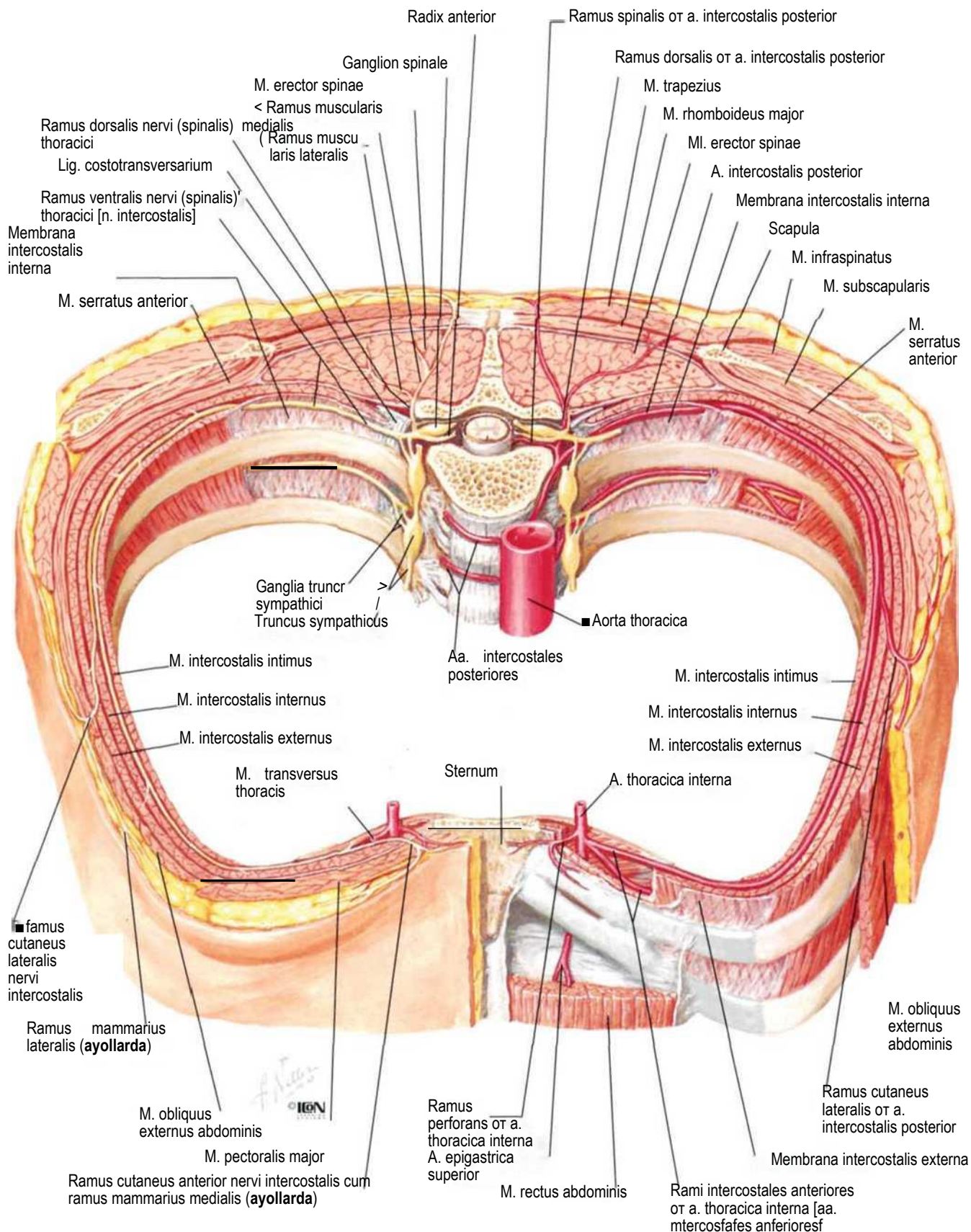


TANA DEVORLARI

177-rasm

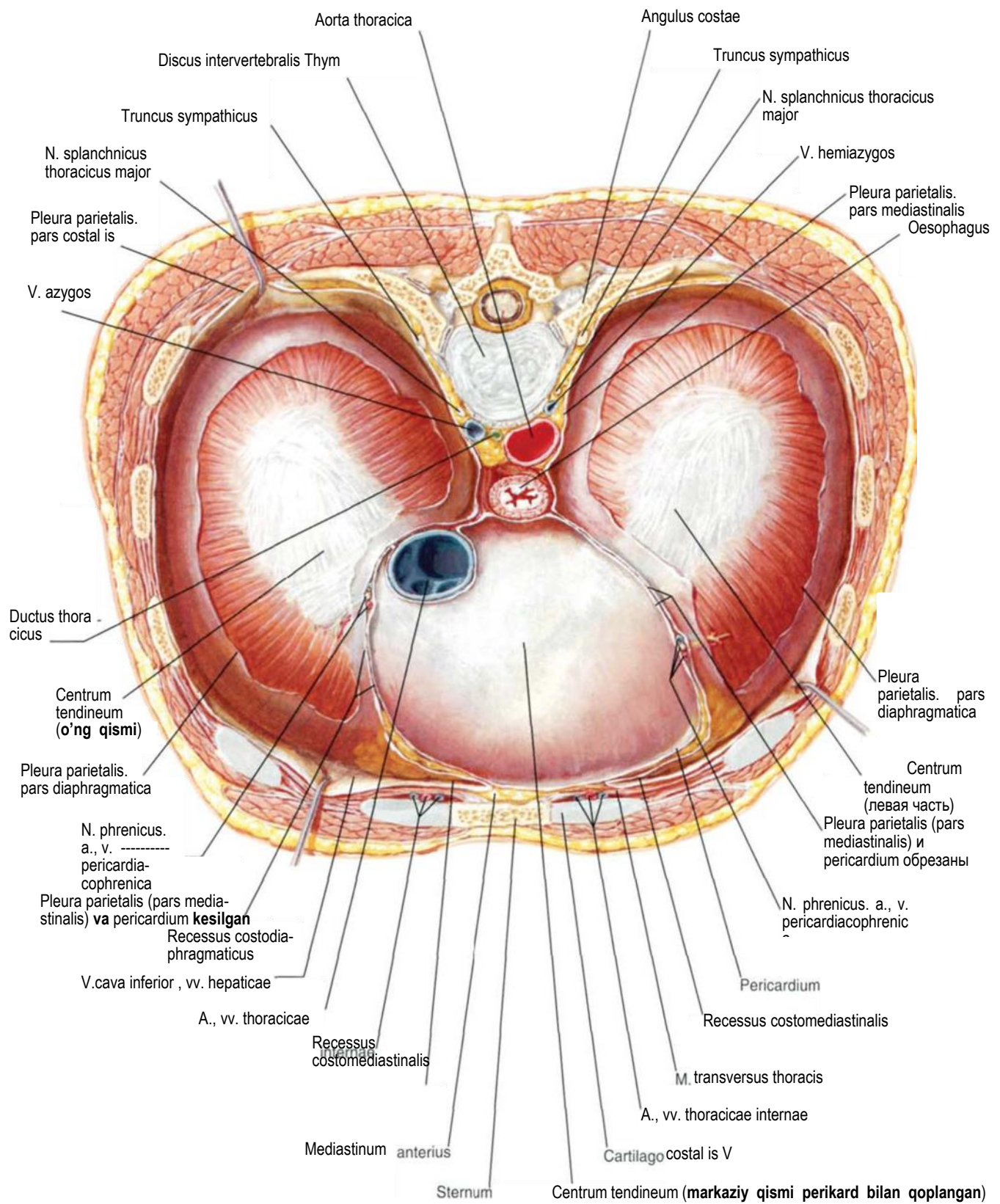
mediale Rami cutanei posteriores rami
laterale dorsales nn. Spinals dan boshlanadi





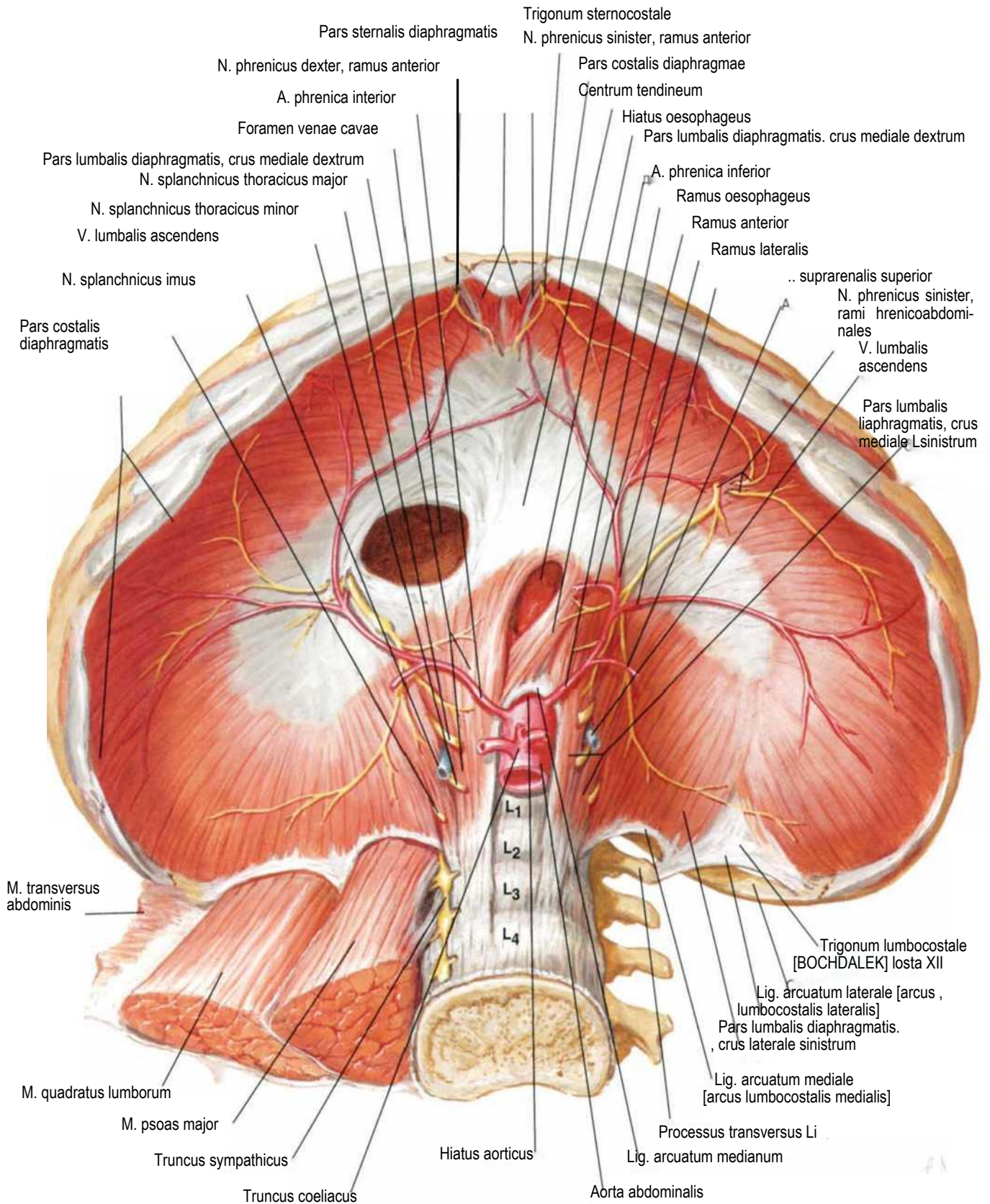
Diaphragma (diaphragms): yuqoridan ko'rinishi

218. 219-rasmlar



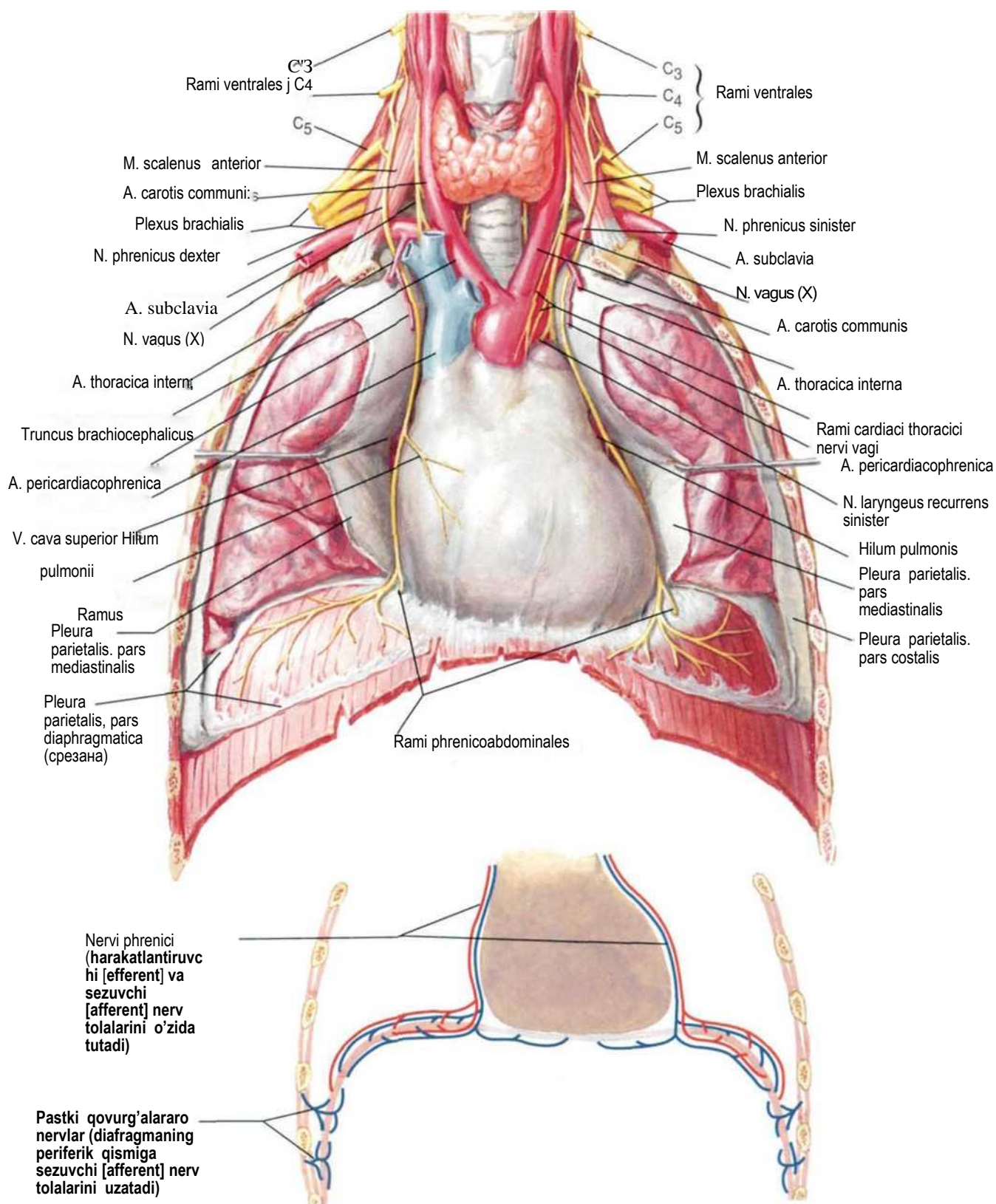
Diafragma (diaphragma): pastdan ko'rinishi

236.246. 253-rasmlar.



Diafragma nervi (nervus phrenicus)

27. 123-rasmlar.



Nafas olishda ishtirok etuvchi muskullar

162. 177-rasmlar.

Nafas oluvchi muskullar

Nafas chiqarishda ishtirok etuvchi muskullar

Nafas chiqarish passiv jarayon bo'lib, o'pralarning elastikligi hisobiga hamda qovurg'alarining pastga tortilishi hisobiga sodir bo'ladi.

Aktiv nafas chiqarish mm. intercostales interni ning qisqarishi (pars intercartilaginea) dan tashqari Qorin devori muskullarining qisqarishi (pastki qovurg'larni tushiradi, qorin ichki bosimini ko'tarib, diafragma yuqoriga ko'tariladi)

M. rectus abdominis
M. obliquus externus abdominis
M. obliquus internus abdominis
M. transversus abdominis

Qo'shimchalari

M. sternocleidomastoideus (to'shni ko'taradi)

Mm. scaleni anterior medius posterior

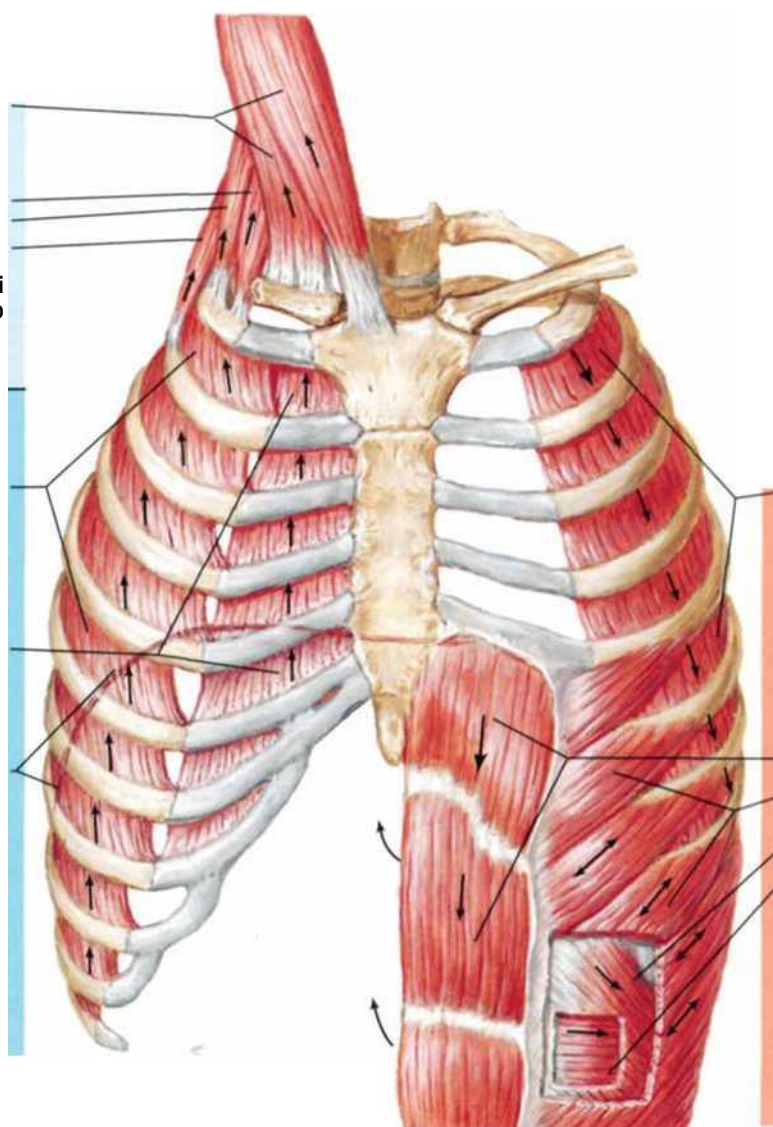
Yuqoridagi qovurg'larni ko'taradi va ushlab turadi

Asosiyilar

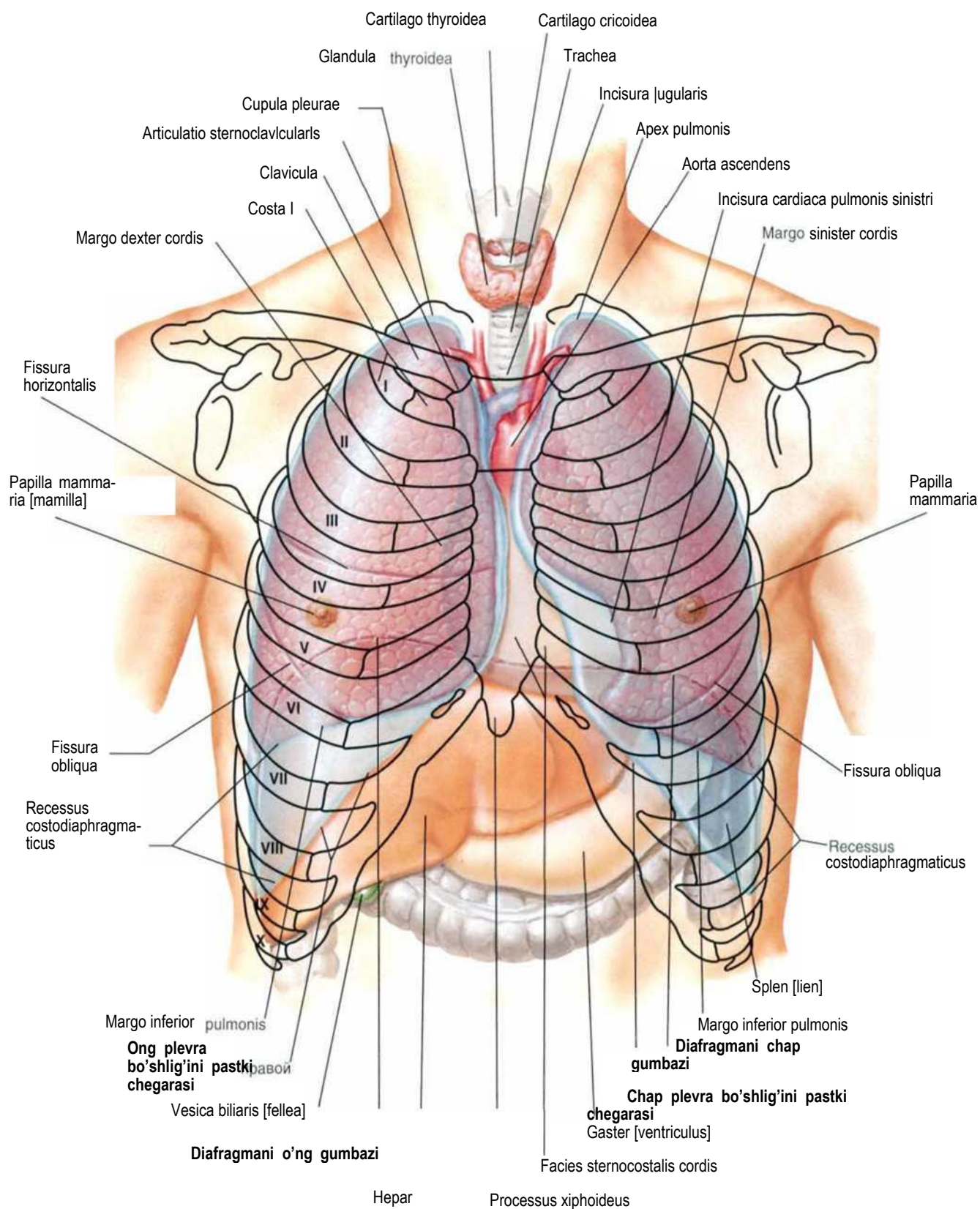
Mm. intercostales externi (qovurg'alarini ko'tarib ko'krak qafasini kengaytiradi)

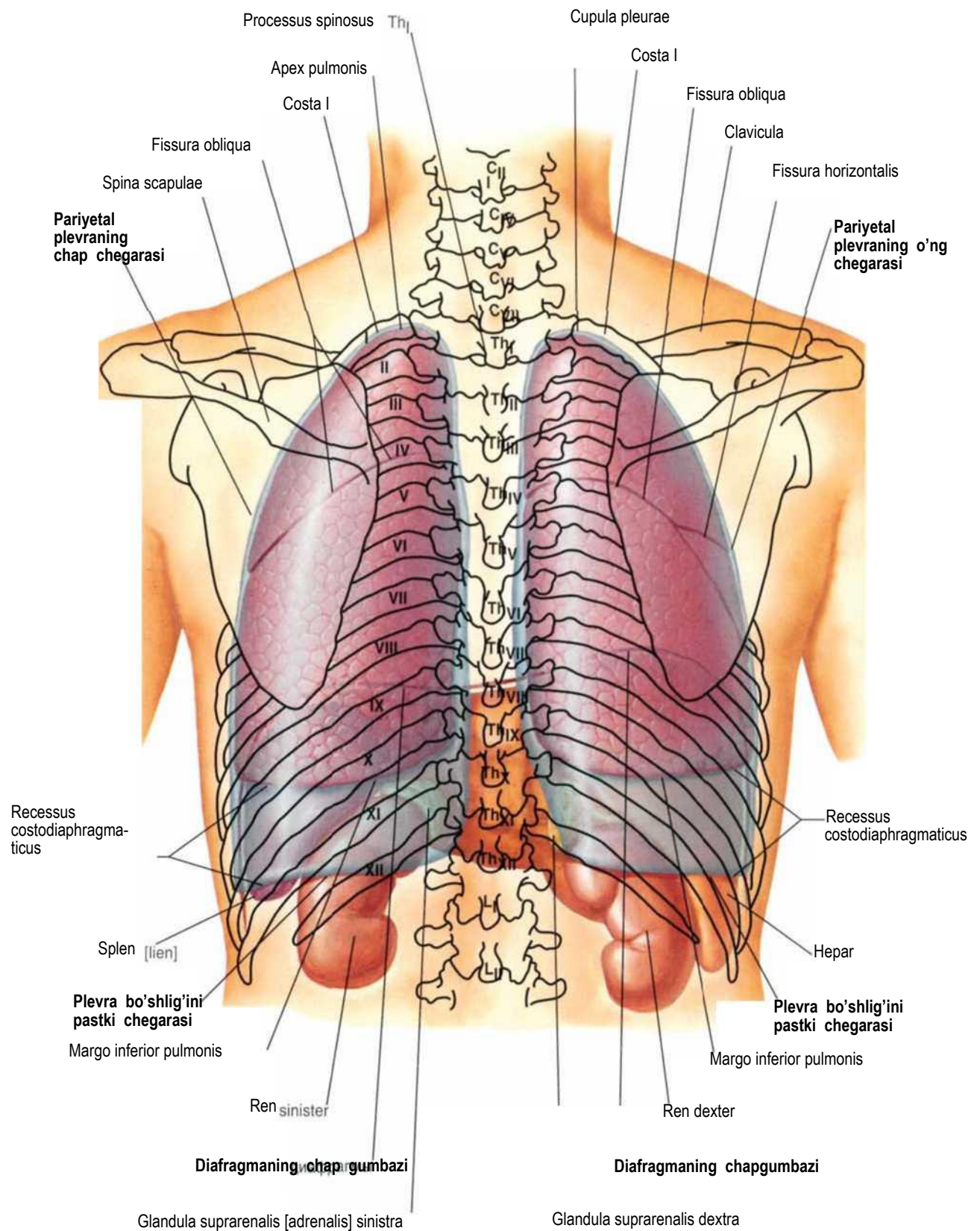
Mm. intercostales interni, pars intercartilaginea (qovurg'alarini ko'taradi)

Diafragma (pastki qovurg'alarini ko'tarib, qisqarganda ko'krak qafasini vertical hajmini ko'paytiradi)

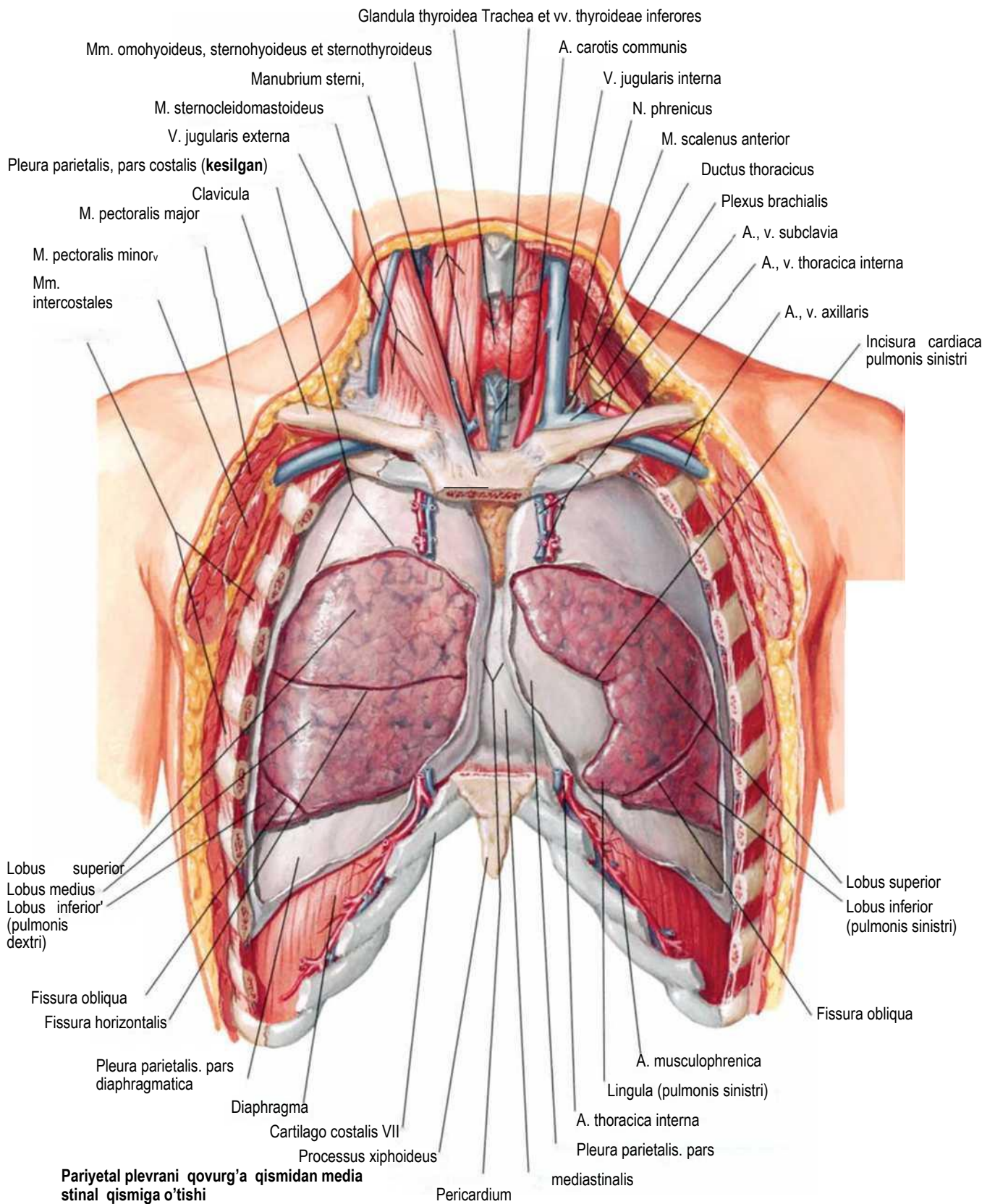


O'pka topografiyasi: old tomoni

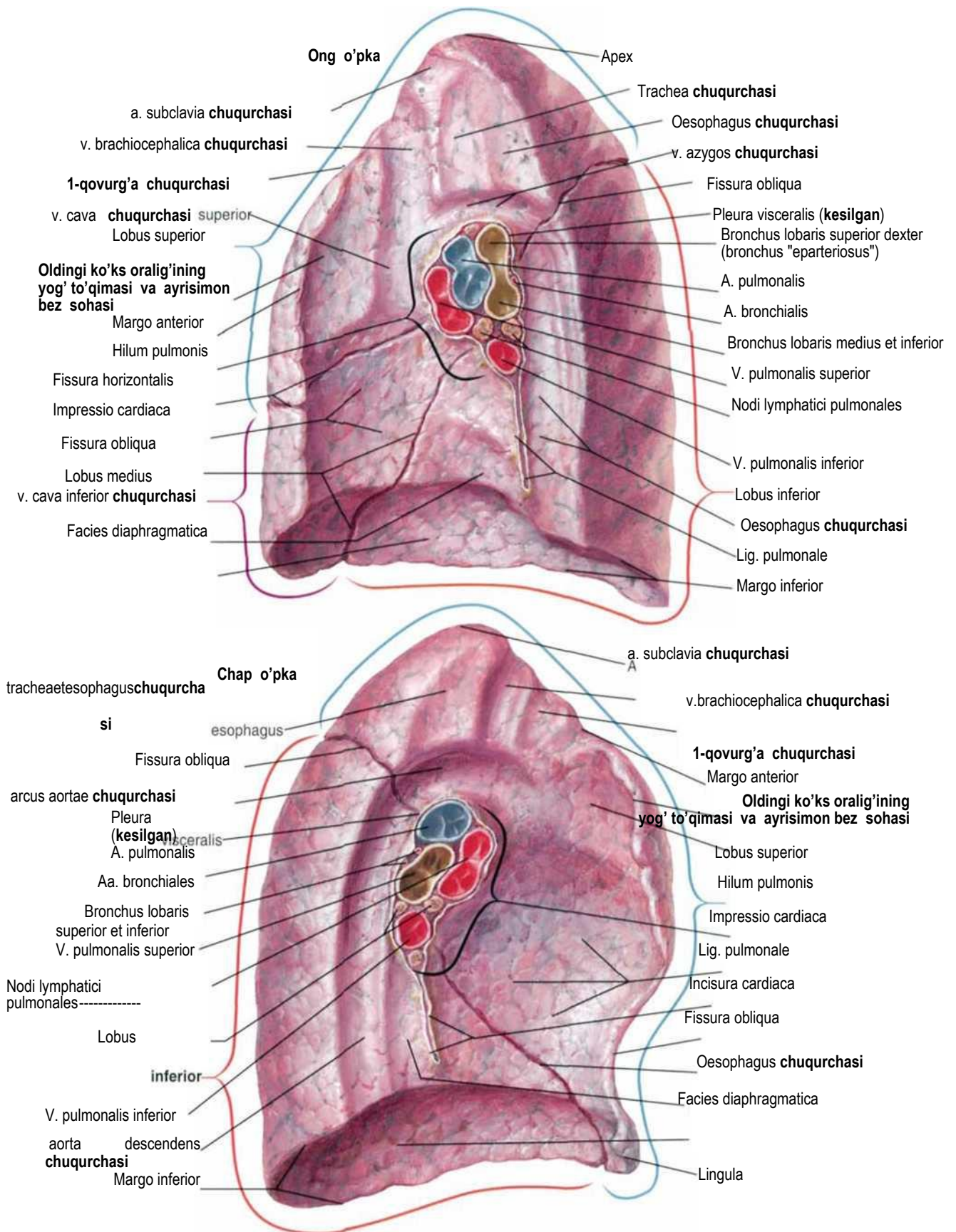




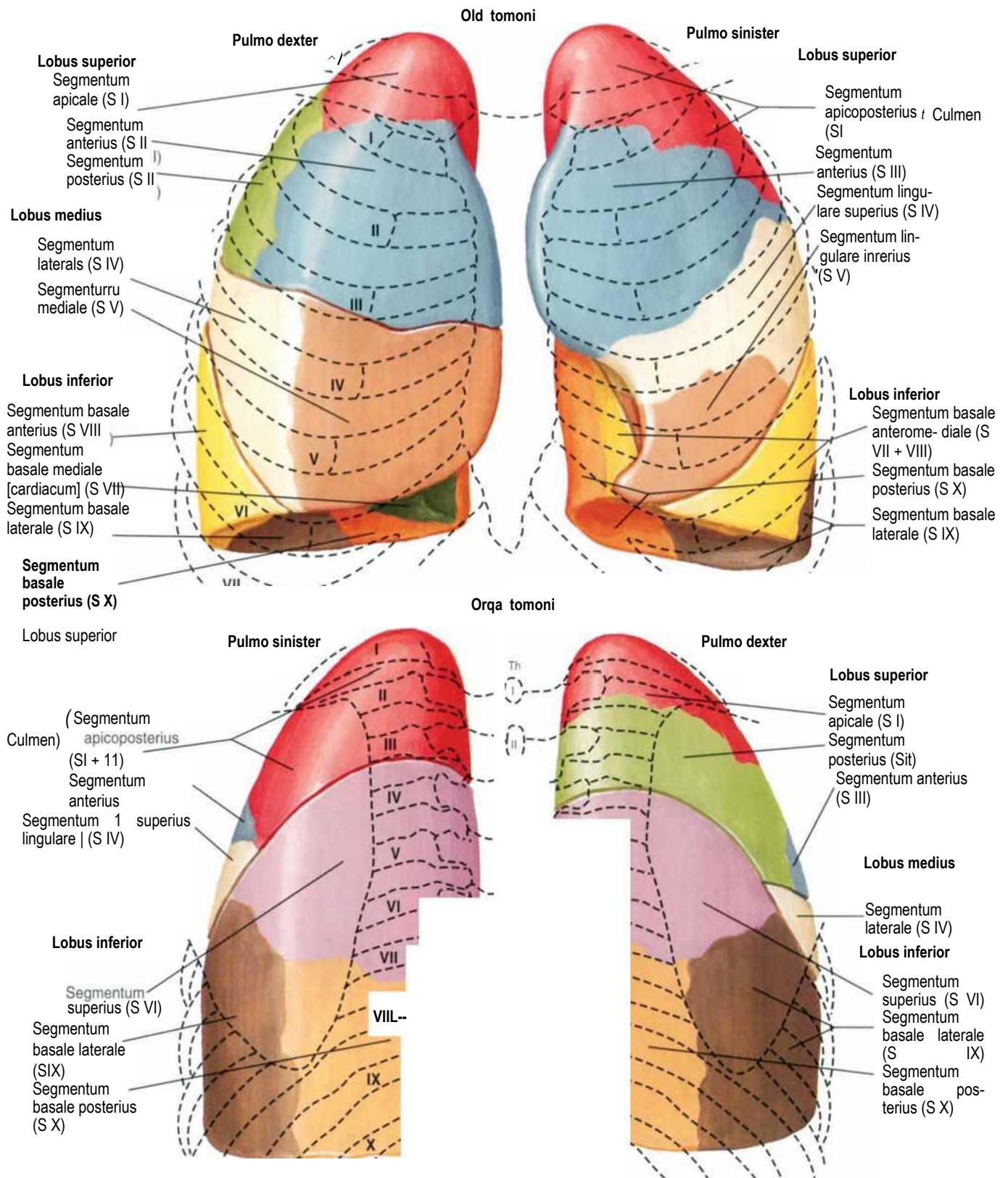
O'pkalar (pulmones): old tomoni



O'pkalar (pulmones): medial tomondan ko'rinishi

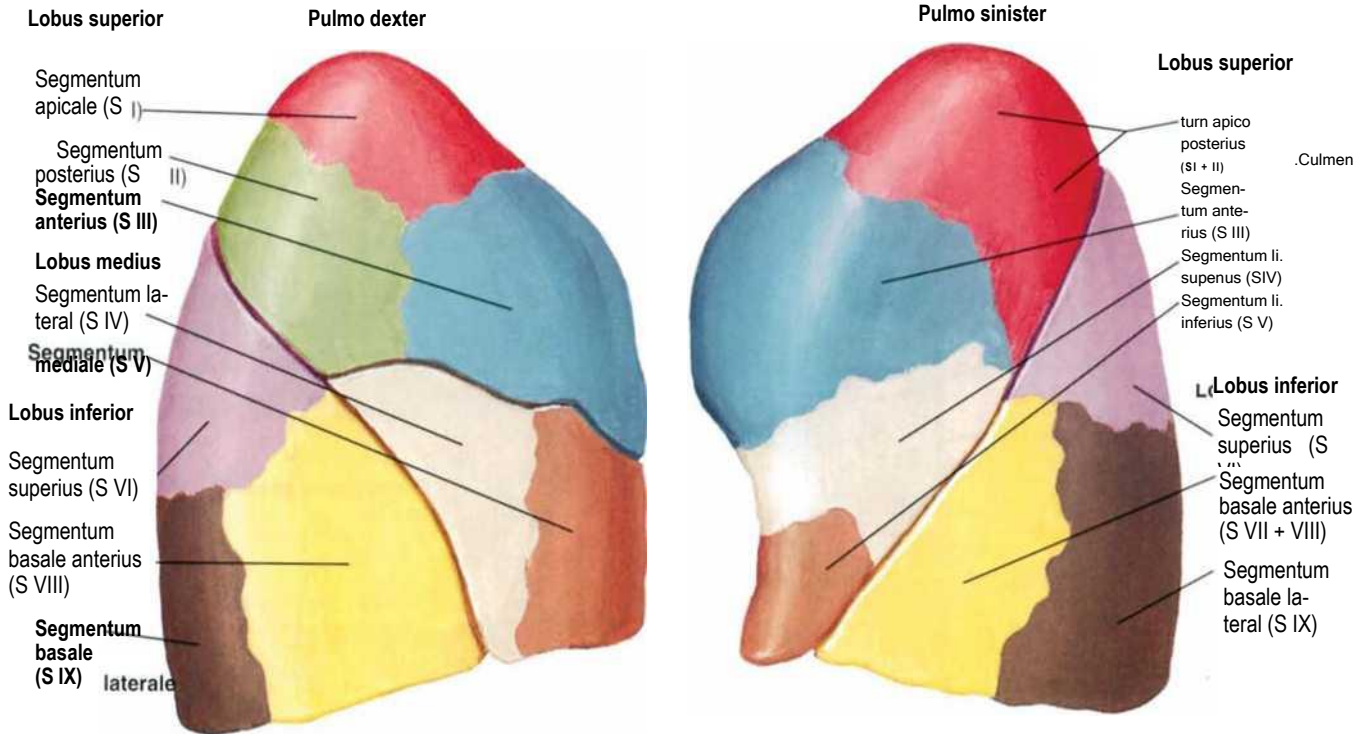


O'pka segmentlari

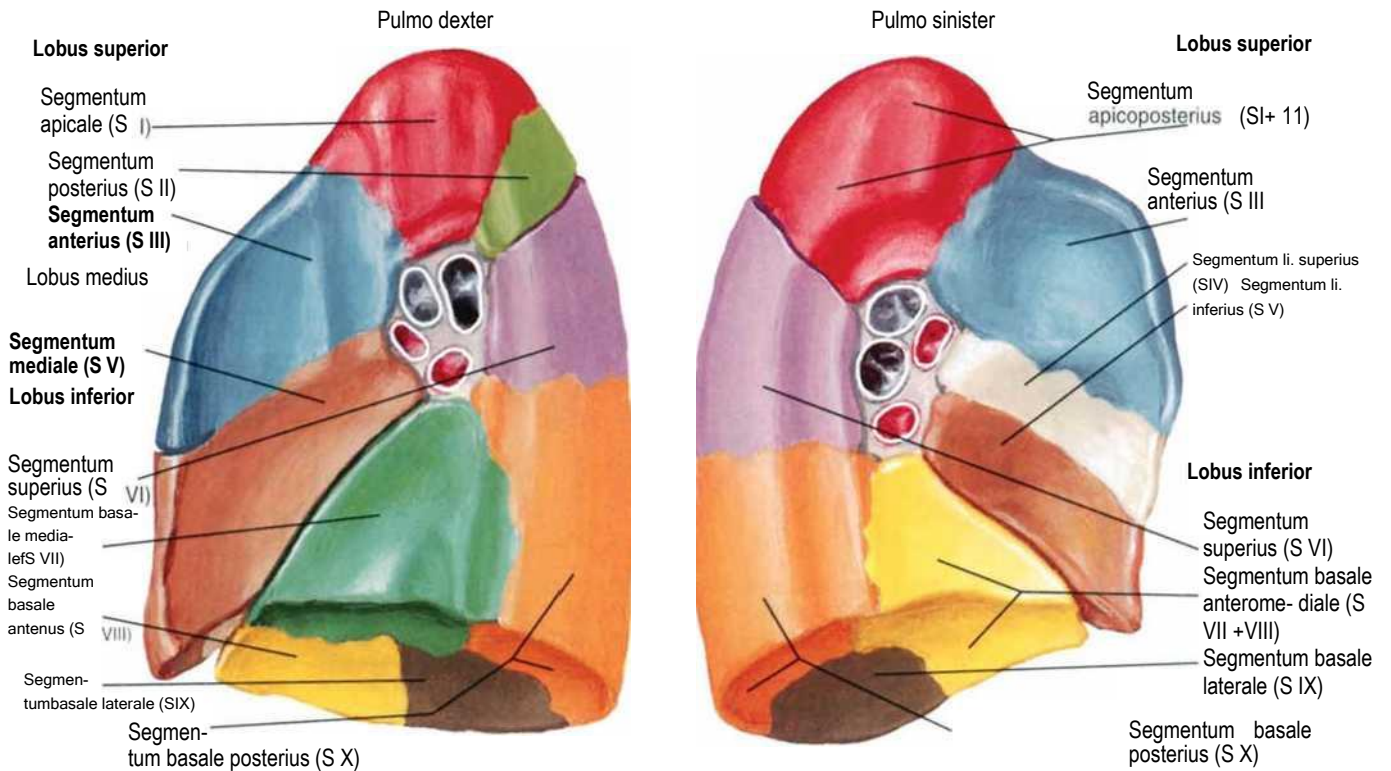


O'pka segmentlari (davomi)

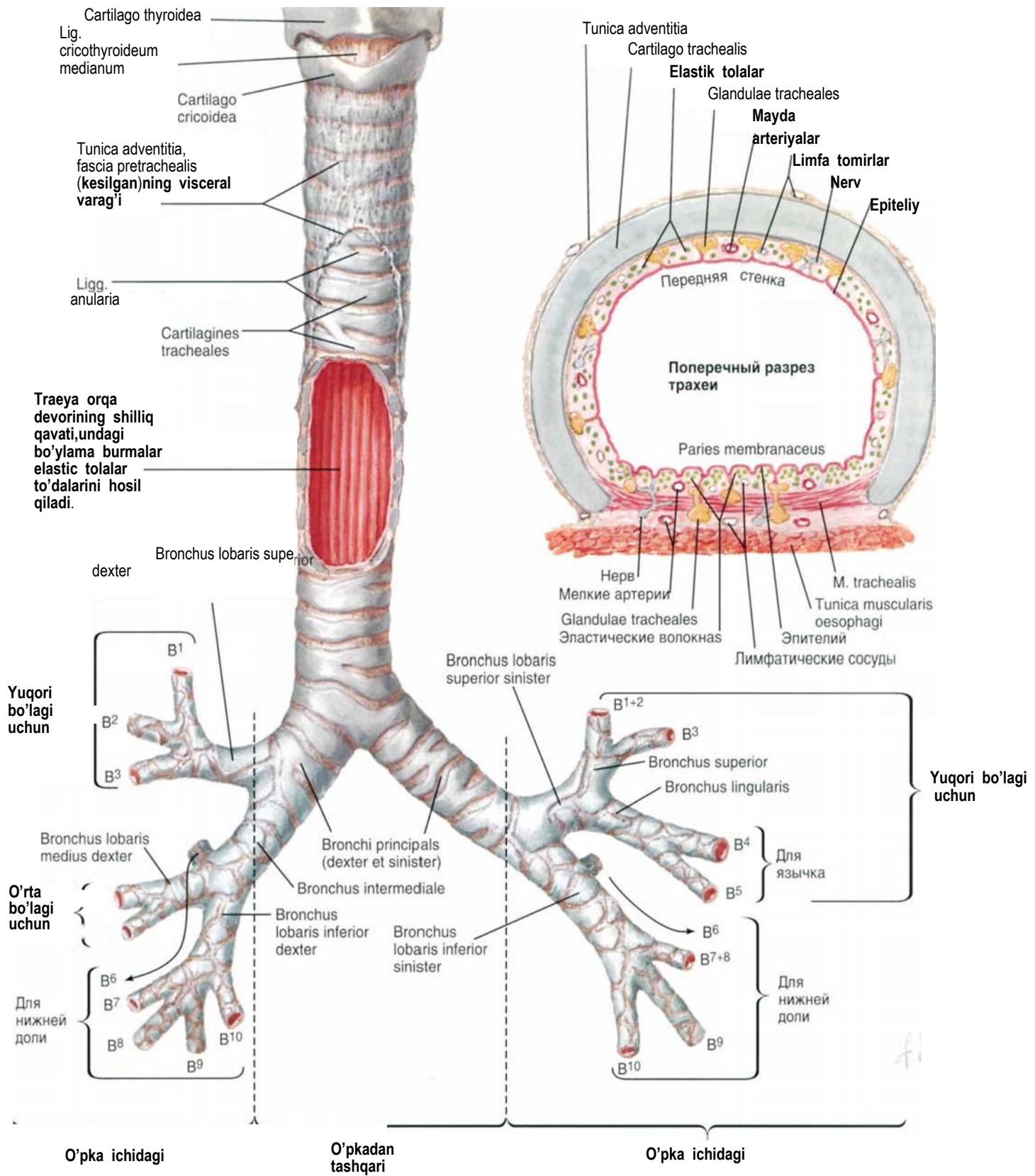
Lateral tomoni



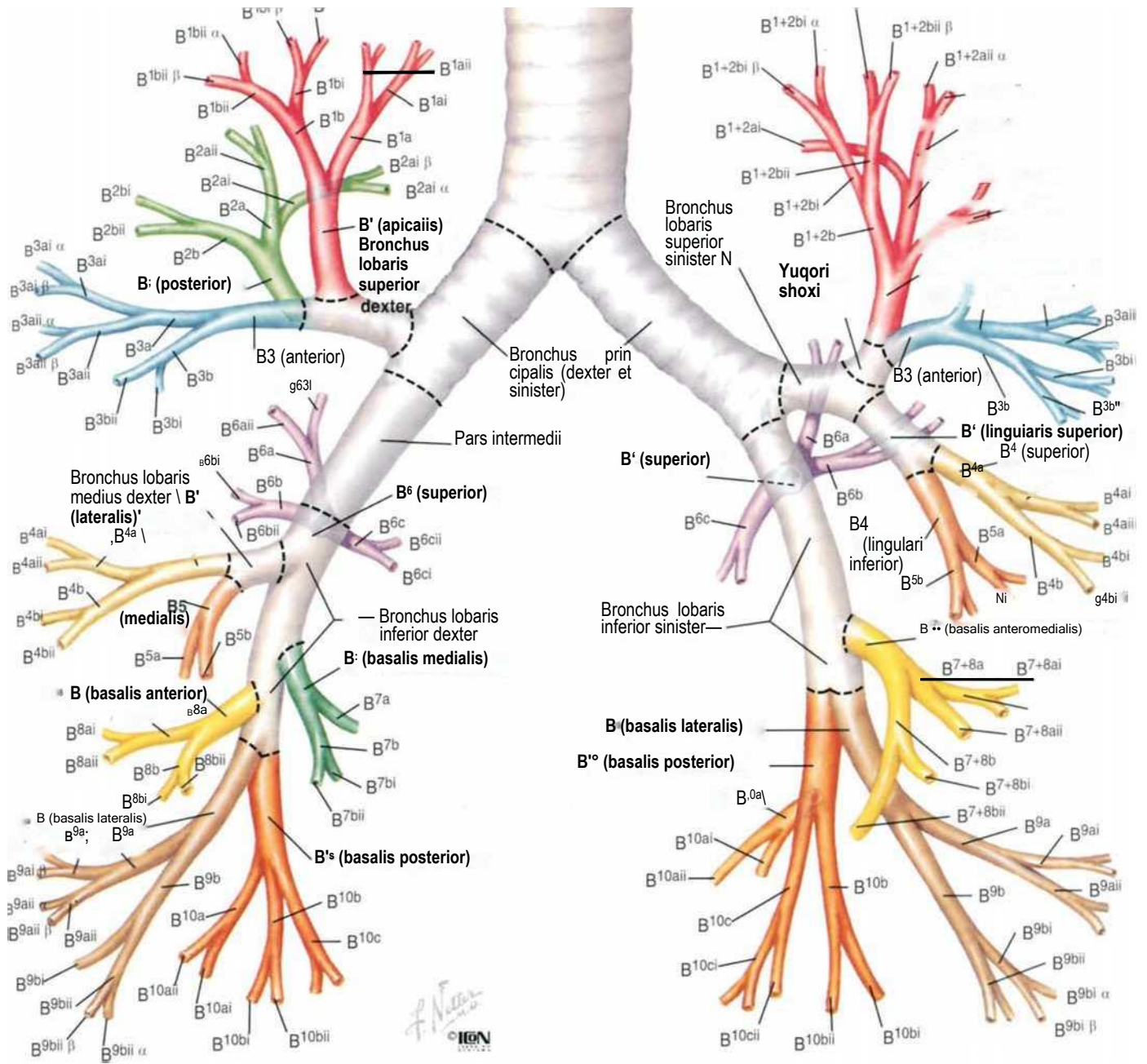
Medial tomoni



Traxeya (trachea) va bronxlar (bronchi)

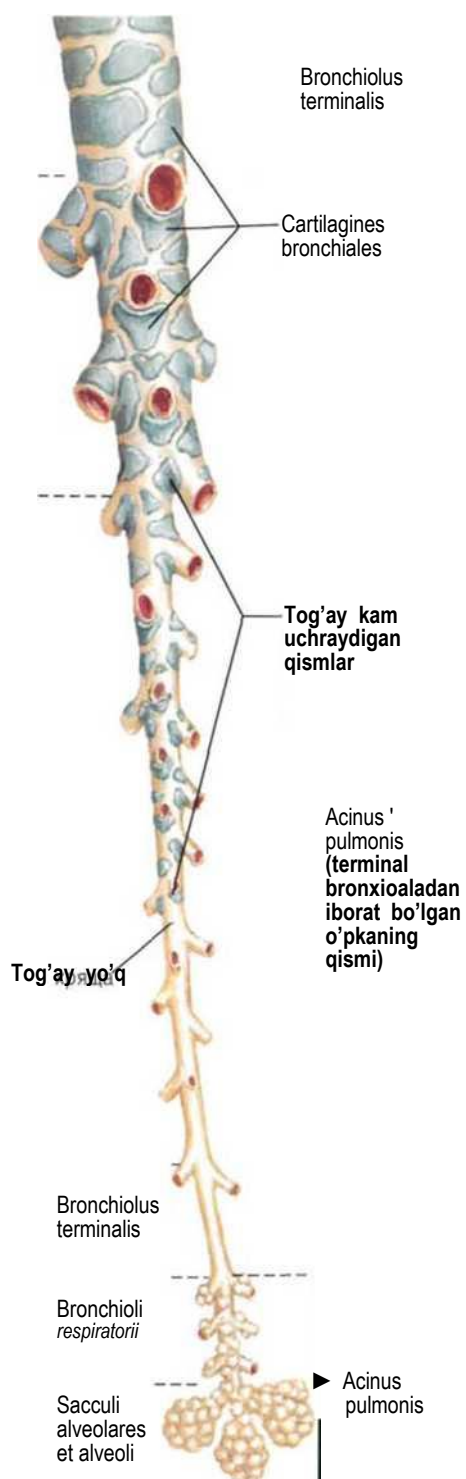


Bronxlar nomenklaturasi: sxemasi

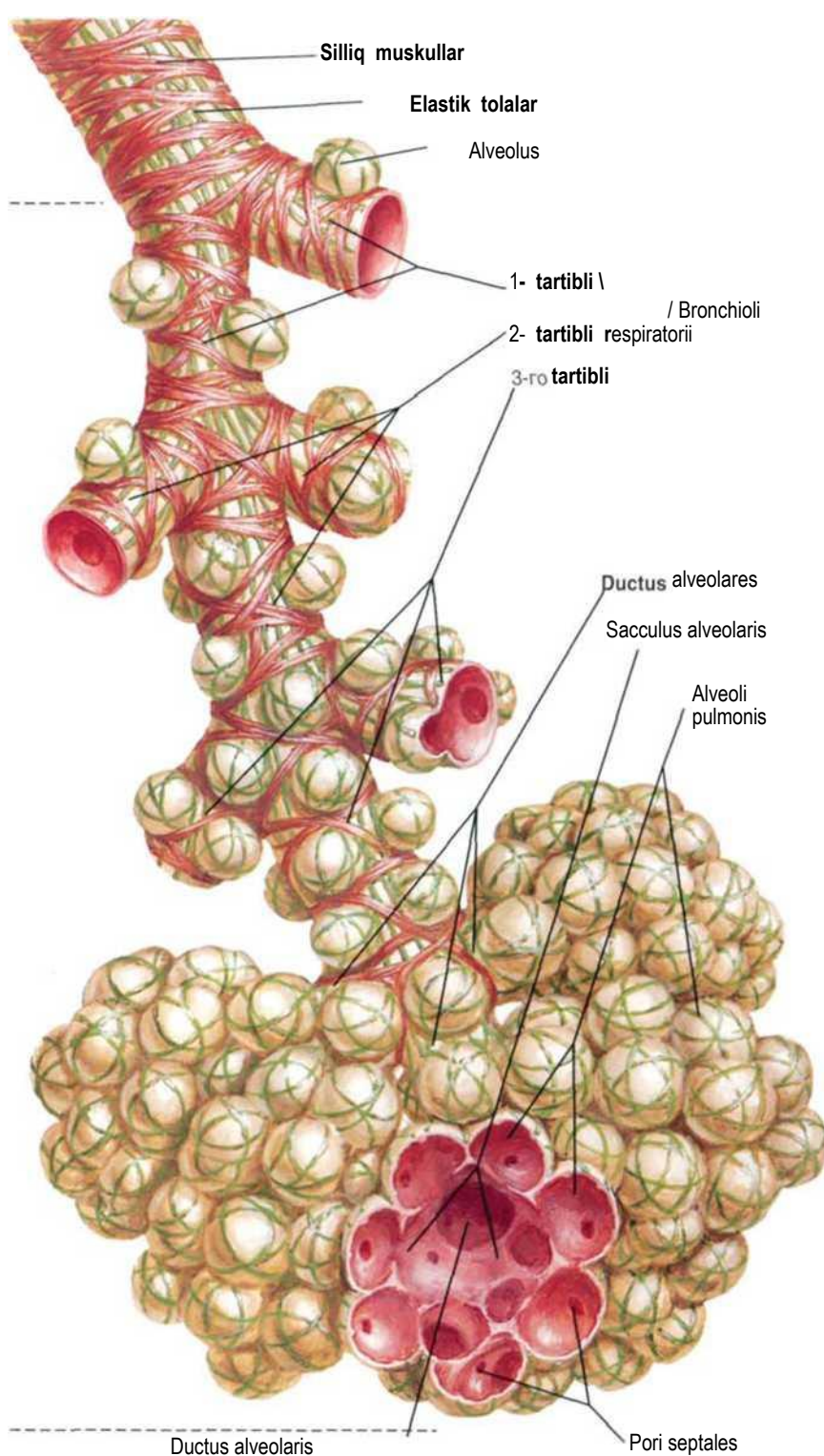


Klinika amaliyotida o'pka-bronx segmentlarini klassifikatsiyasi Djekson va Xuberlarning klassifikatsiyasi bo'yicha qo'llaniladi, segmentar bronxlarning nomlanishi esa Ikeda (1970) bo'yichadir (6-tartibli bronxlargacha). Segmentar bronxlar o'pka segmentlariga mos ravishda har bir o'pkada 1dan to 10 gacha raqamlangan. Chap o'pkada B1va B2, B7va B8 segmentlari birlashtirilgan. 4-tartibli bronxlarni belgilash uchun a, b, c harflaridan foydalaniladi. 6-tartibli bronxlarni belgilash uchun a va b harflaridan foydalanilgan. Boshqa ko'pgina adabiyotlarda boshqa belgilardan ham foydalaniladi. Ammo ko'pchilik xollarda bu yerda keltirilgan bronxlarning shoxlanishi klassifikatsiyasi uchraydi.

O'pka ichidagi havo o'tkazuvchi yo'llar

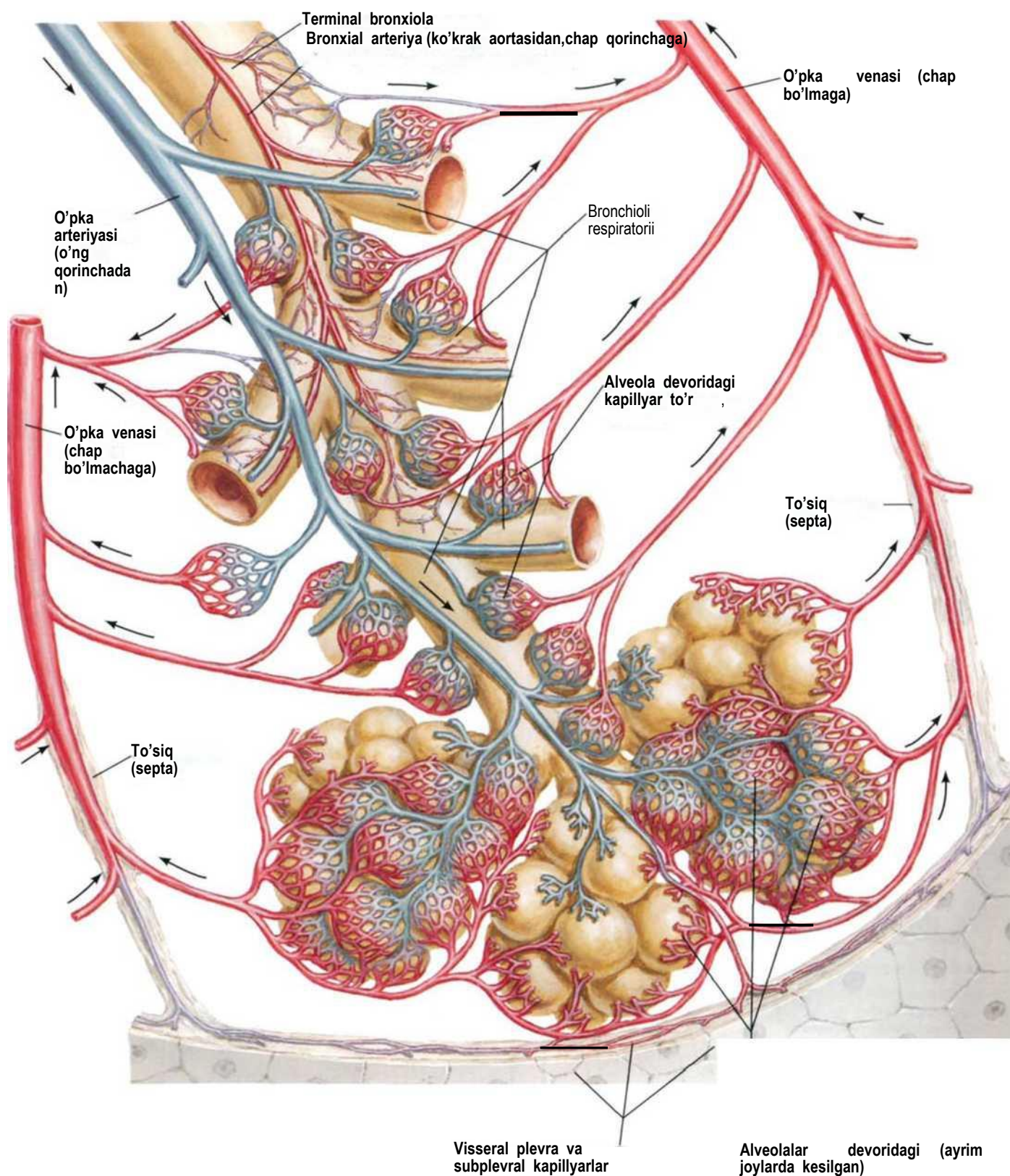


O'pka ichidagi havo yo'llari bo'limlari

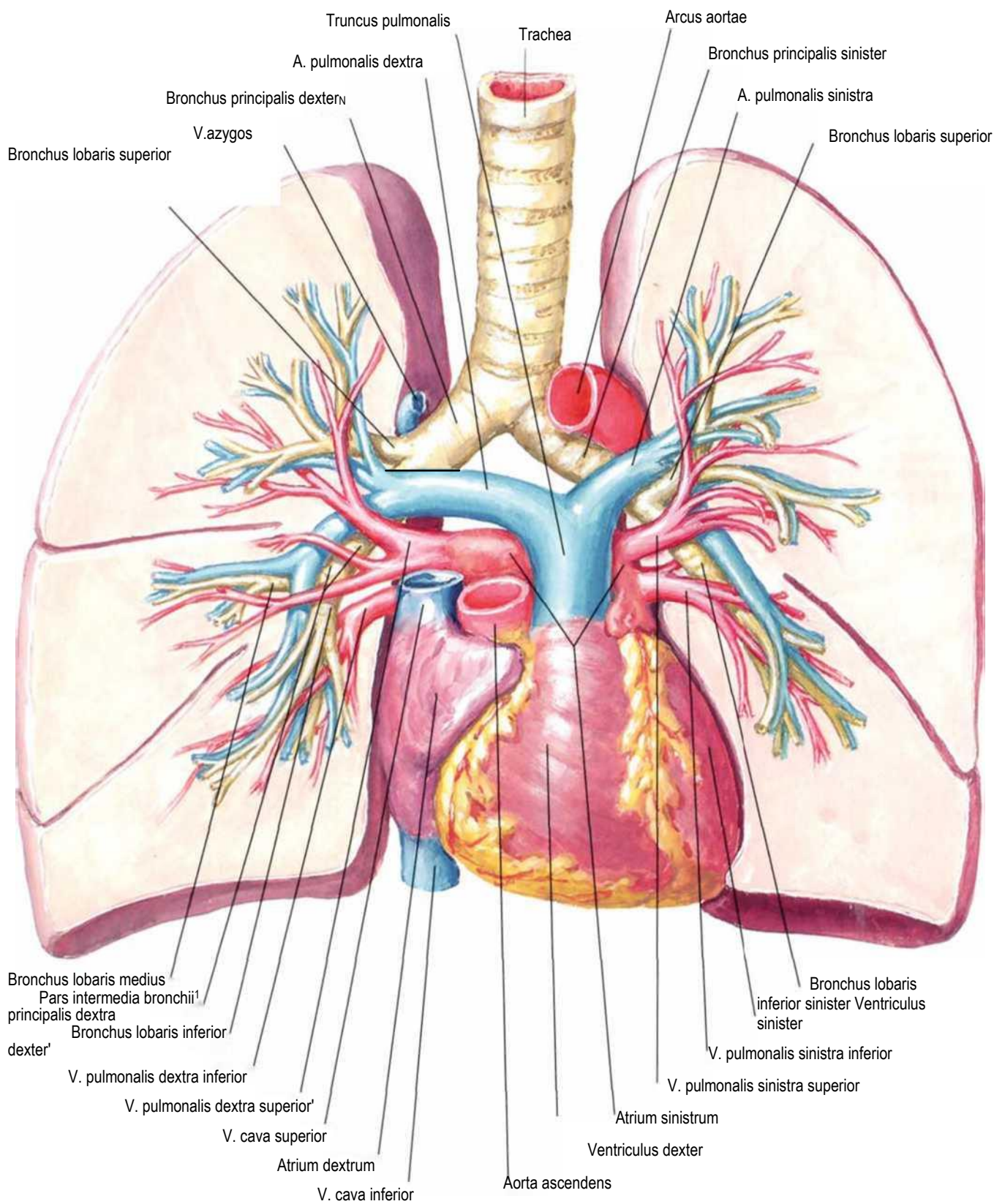


Asinusning tuzilishi

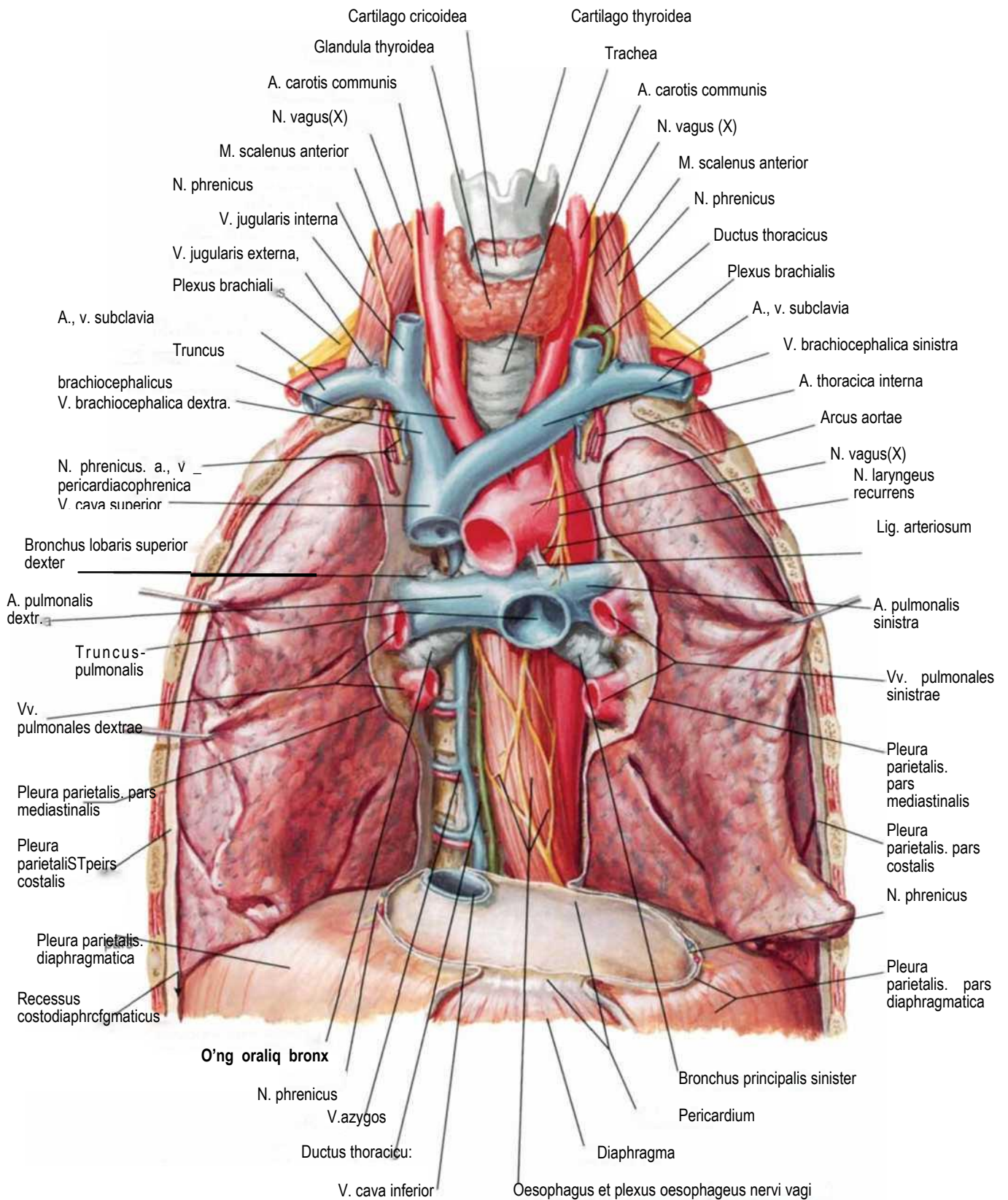
O'pka ichidagi qon aylanishi : sxemasi



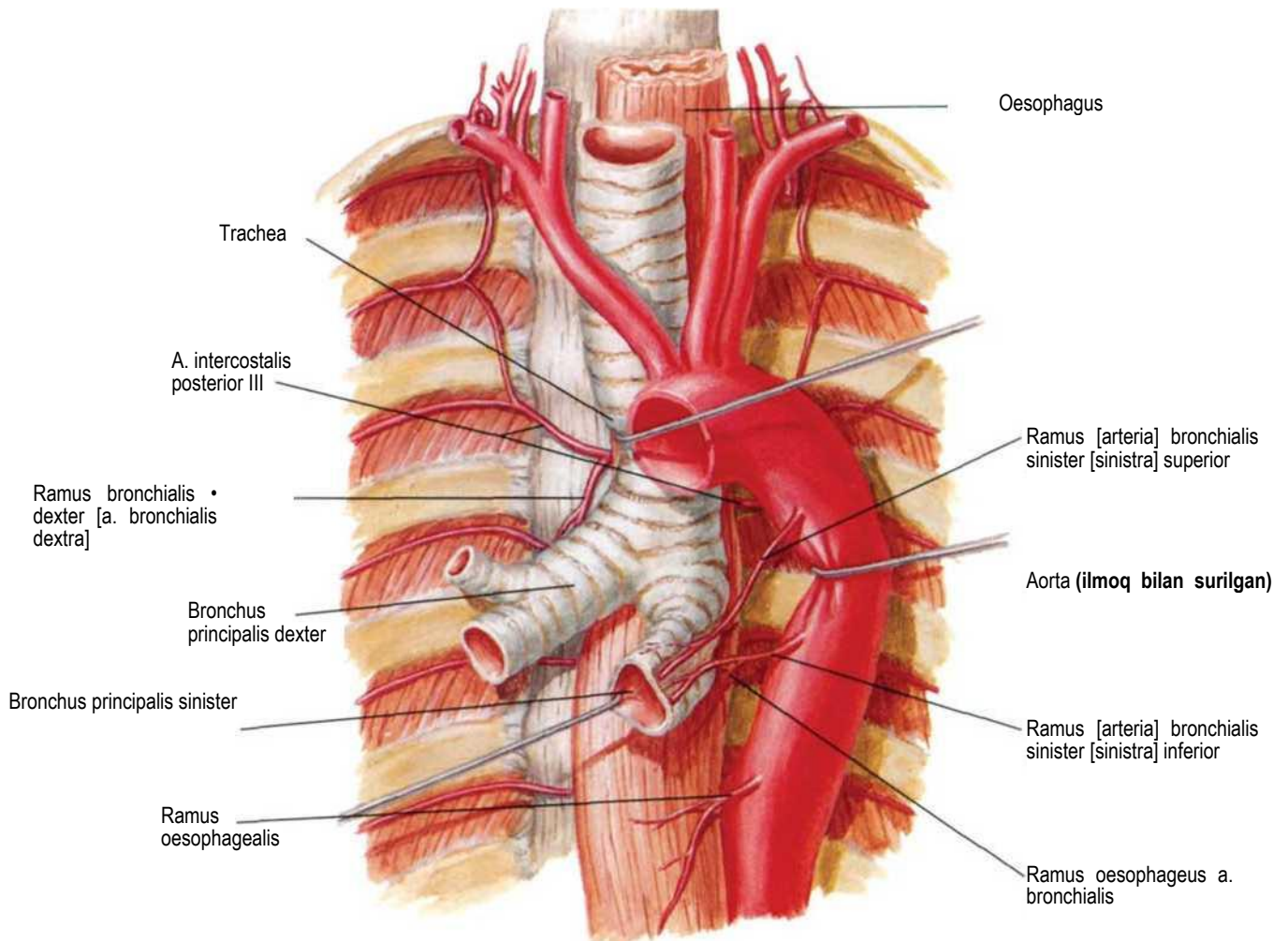
O'pka arteriyalari va venalari



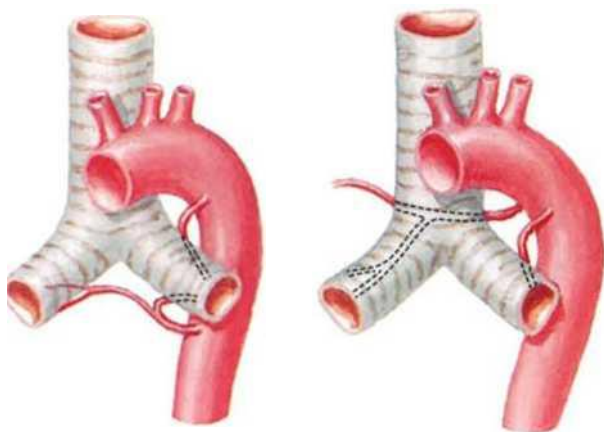
Oldingi ko'ks oralig'ining yirik qon tomirlari



Bronx arteriyalari va venalari



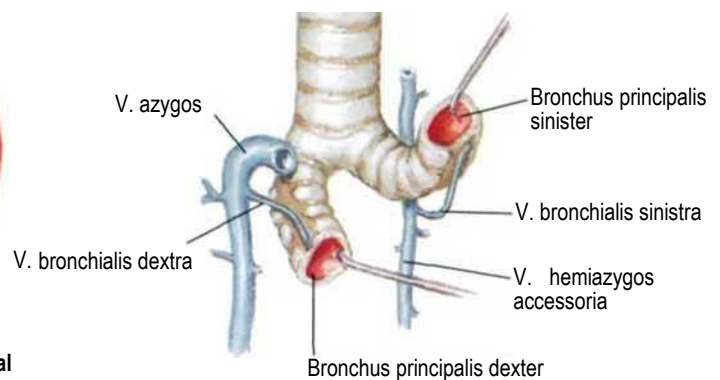
Bronxial arteriya turlari



Har bir bronxni odatda bitta arteriya qon bilan ta'minlaydi (ayrim hollarda esa chap bronxda 2ta arteriya bo'ladi)

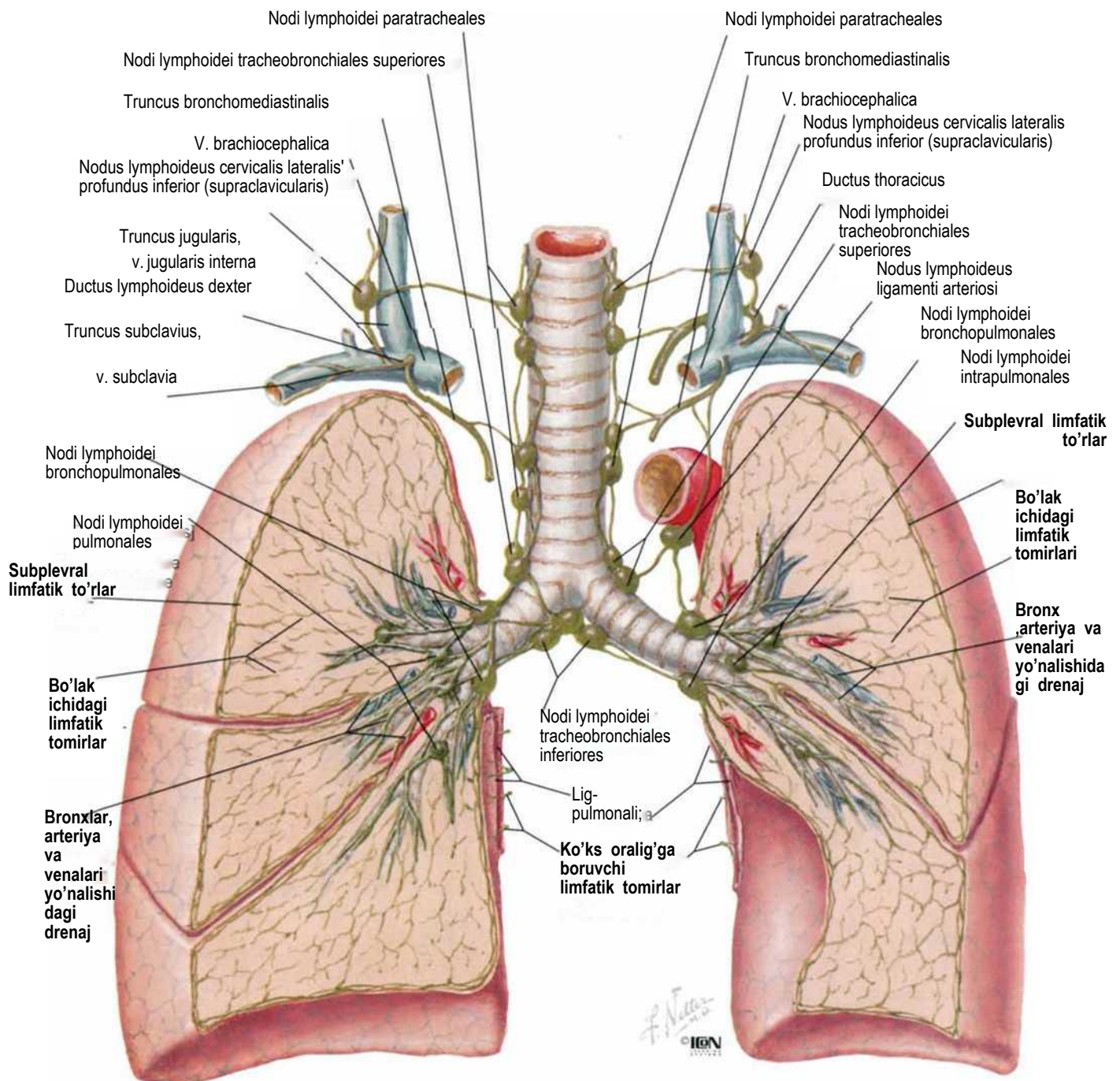
O'ng va chap bronxial arteriyalar aortadan alohida shoxlanadi.

Bronxial venalar



O'pkalarning limfa tomirlari va tugunlari

66. 169. 227-rasmlar.



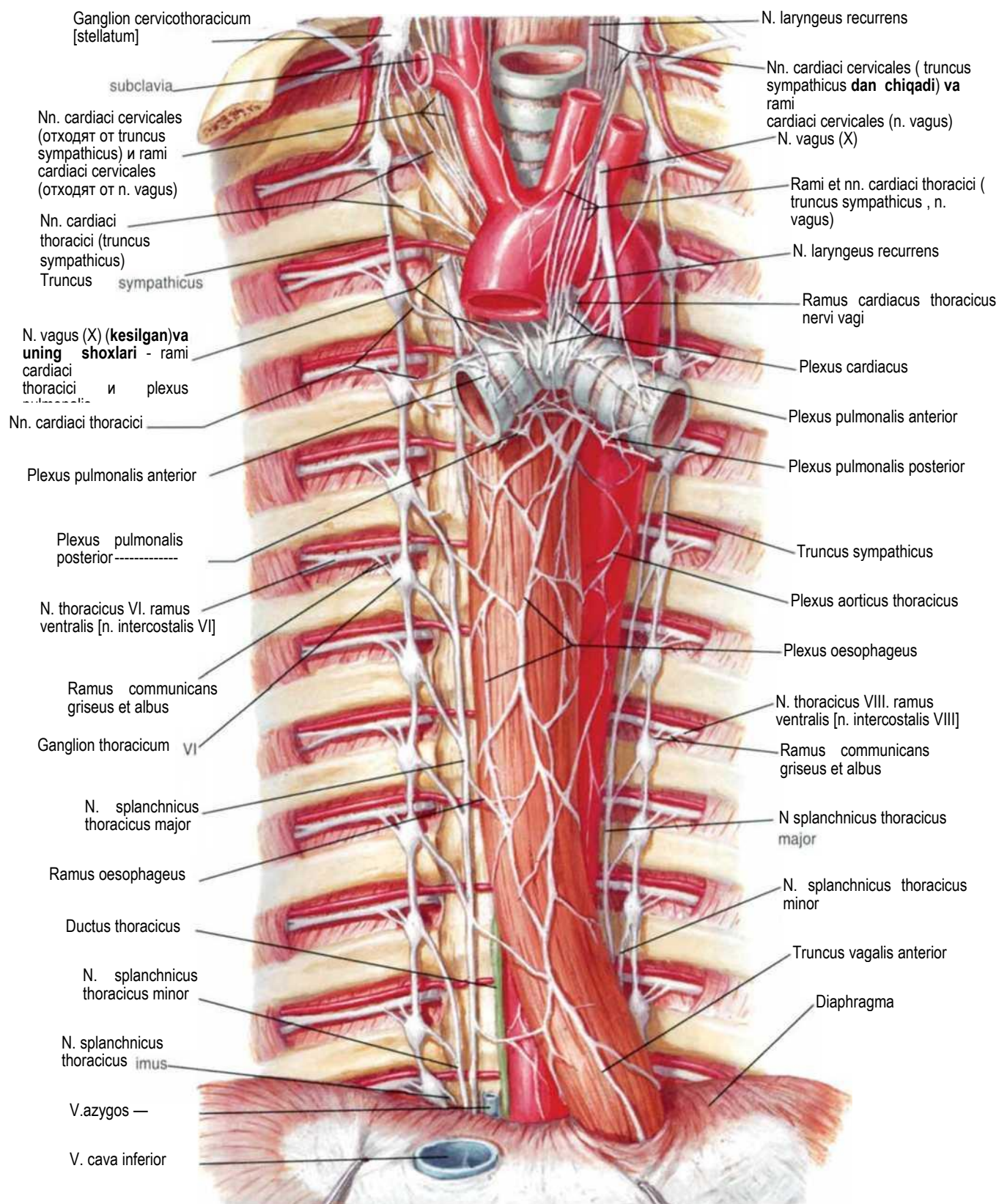
O'pkalardan limfaning drenaji

O'ng o'pka: hamma bo'laklardan limfa o'pka va bronx-o'pka tugunlariga drenajlanadi, undan keyin pastki traxeobronxial tugunlarga, yuqorigi o'ng traxeobronxial tugunlarga va paratraxial tugunlarga drenajlanadi. Bronxomediastinal limfatik stvol yoki pastki chuqur (narvonsimon) tugunlar orqali yelka-bosh venasiga quyiladi.

Chap o'pka: yuqori bo'laklardan limfa o'pka va bronx-o'pka tugunlariga, pastki traxeobronxial tugunlarga, yuqorigi chap traxeobronxial tugunlarga, chap paratraxial tugunlarga va arterial boylam hamda aorta ravog'iga, keyin esa chap bronxomediastinal stvol va ko'krak yo'li orqali yelka-bosh venasiga quyiladi. Pastki bo'lakdan limfa o'pka va bronx-o'pka tugunlariga, pastki traxeobronxial tugunlarga, lekin limfaning ko'p qismi o'ng yuqori traxeobronxial tugunlarga quyiladi va o'ng o'pka limfasi bilan birga quyiladi.

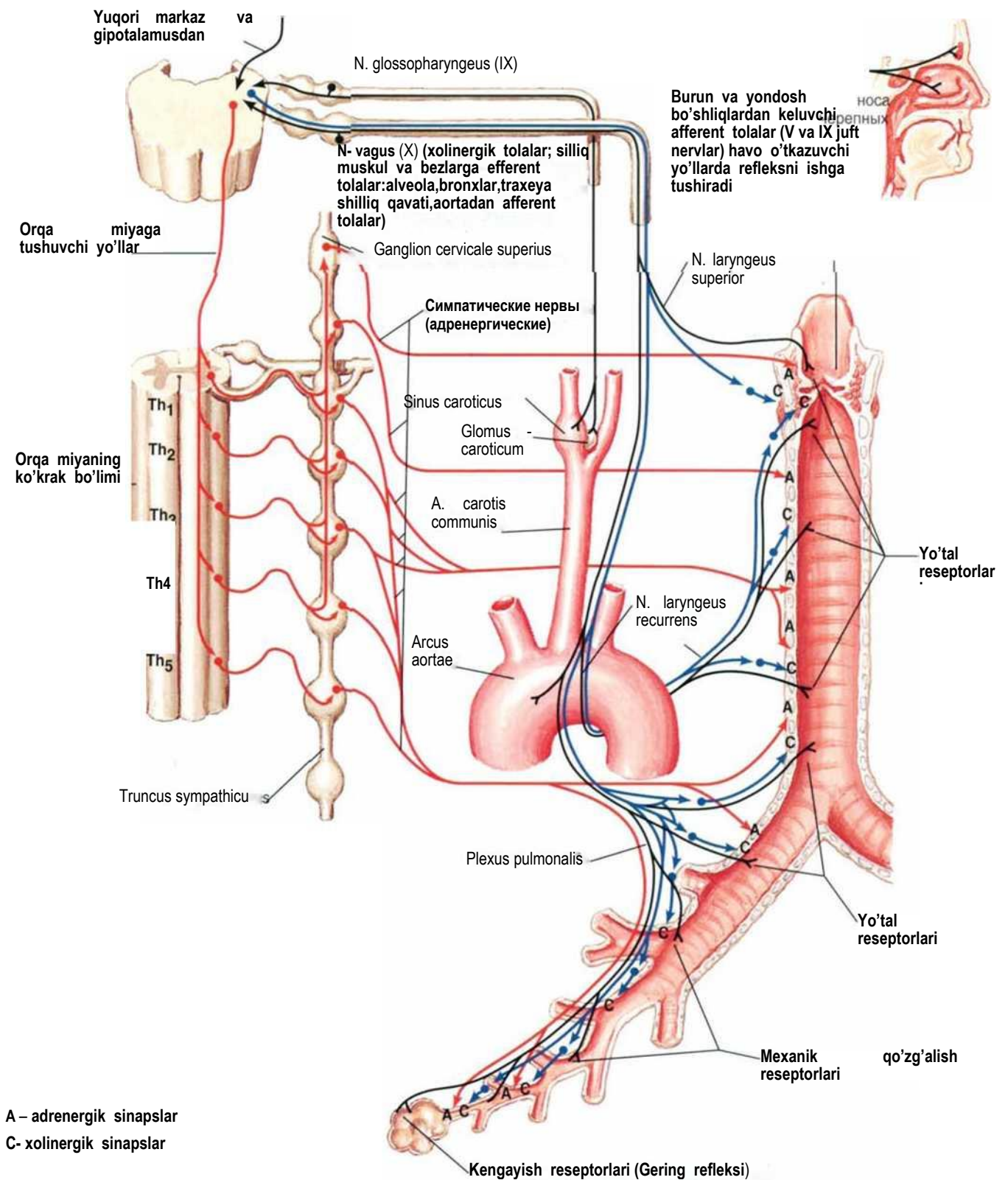
Ko'krak qafasining vegetativ nervlari

124. 125. 152. 300-rasmlar.

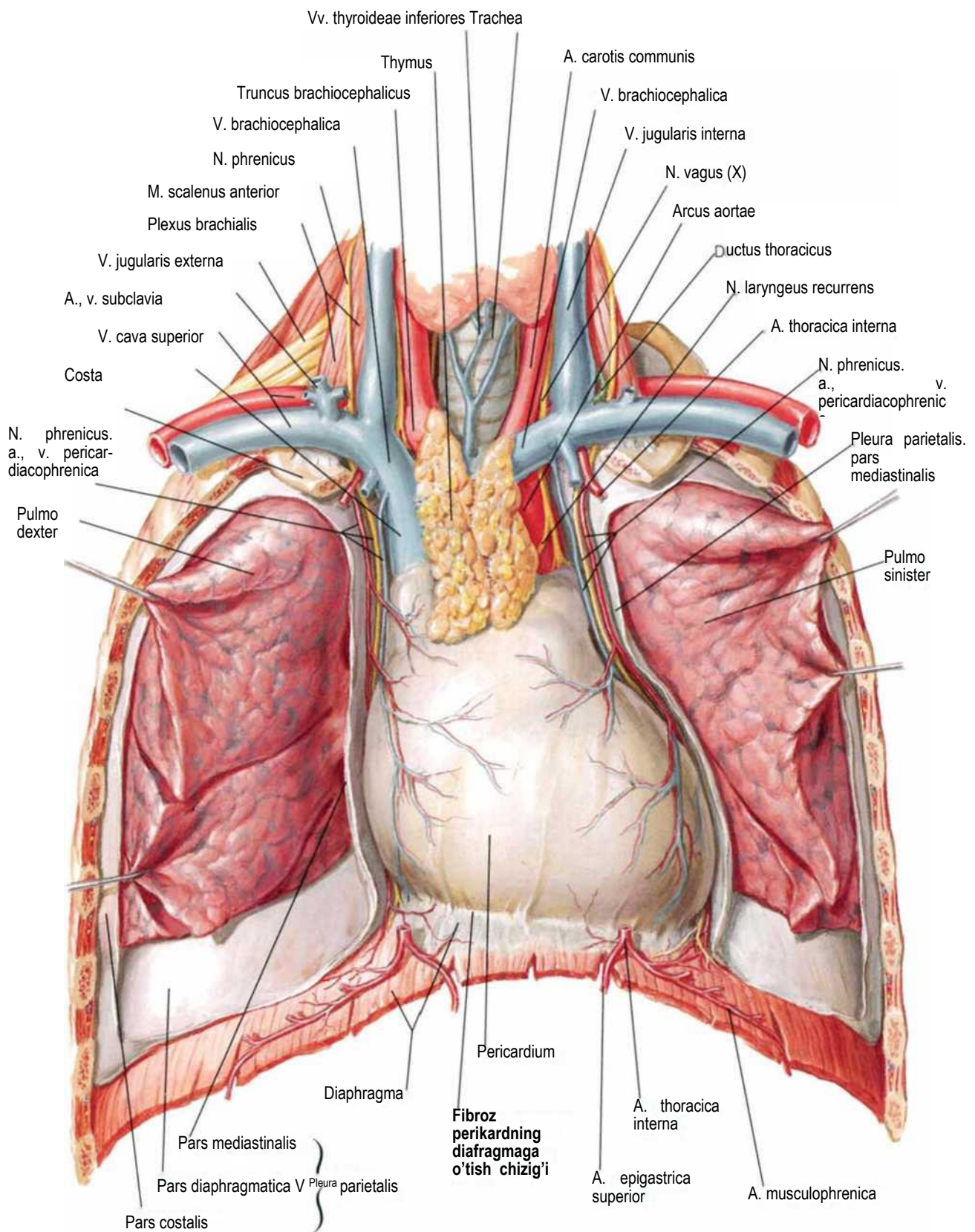


Traxeya va bronx innervatsiyasi (sxemasi)

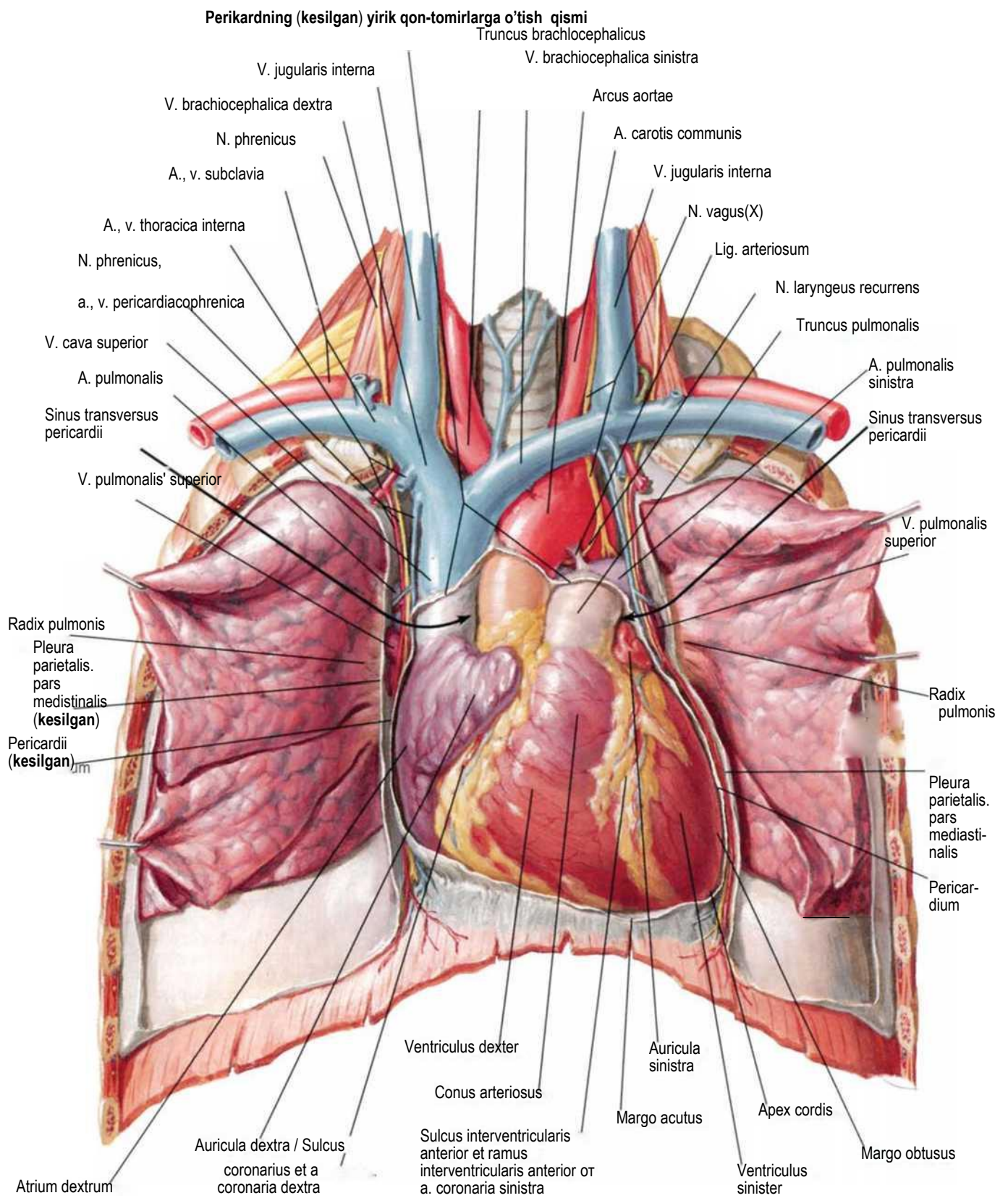
153-rasm.



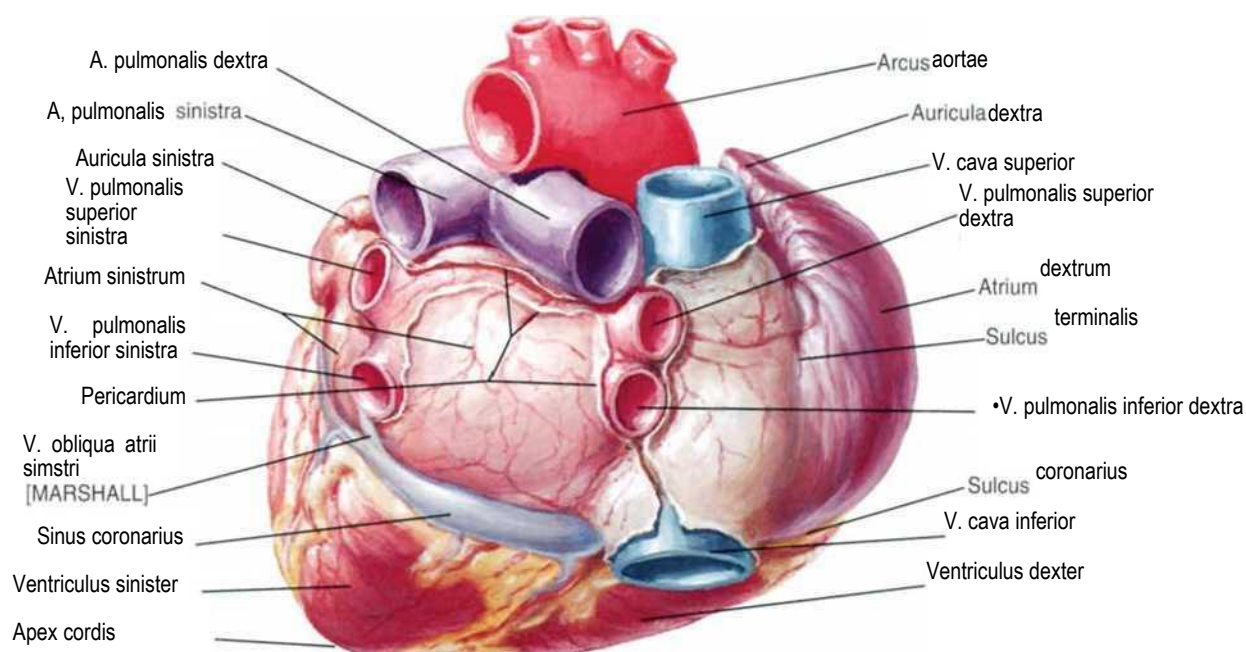
Yurak (cor) va perikard (pericardium)



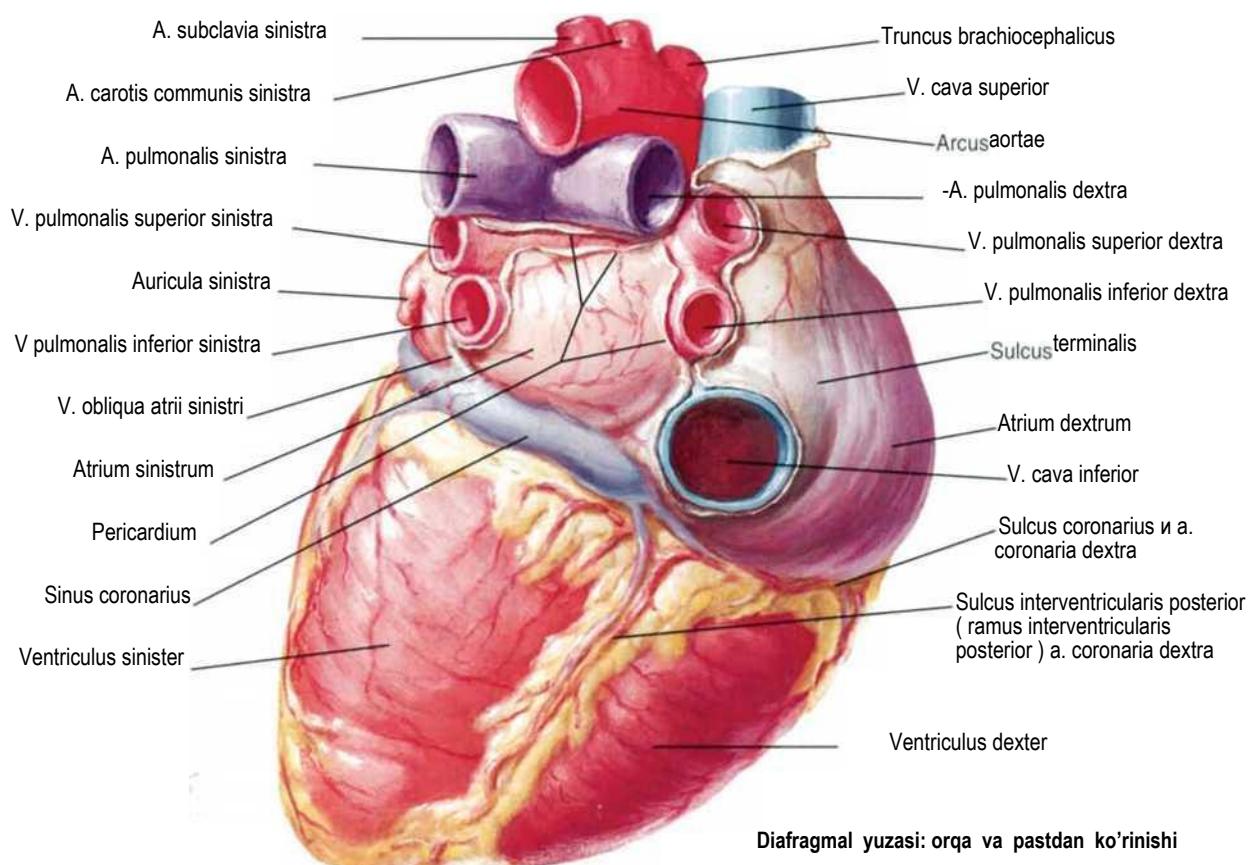
Yurak (cor), old tomoni



Yurak : asosi va diafragmal yuzasi

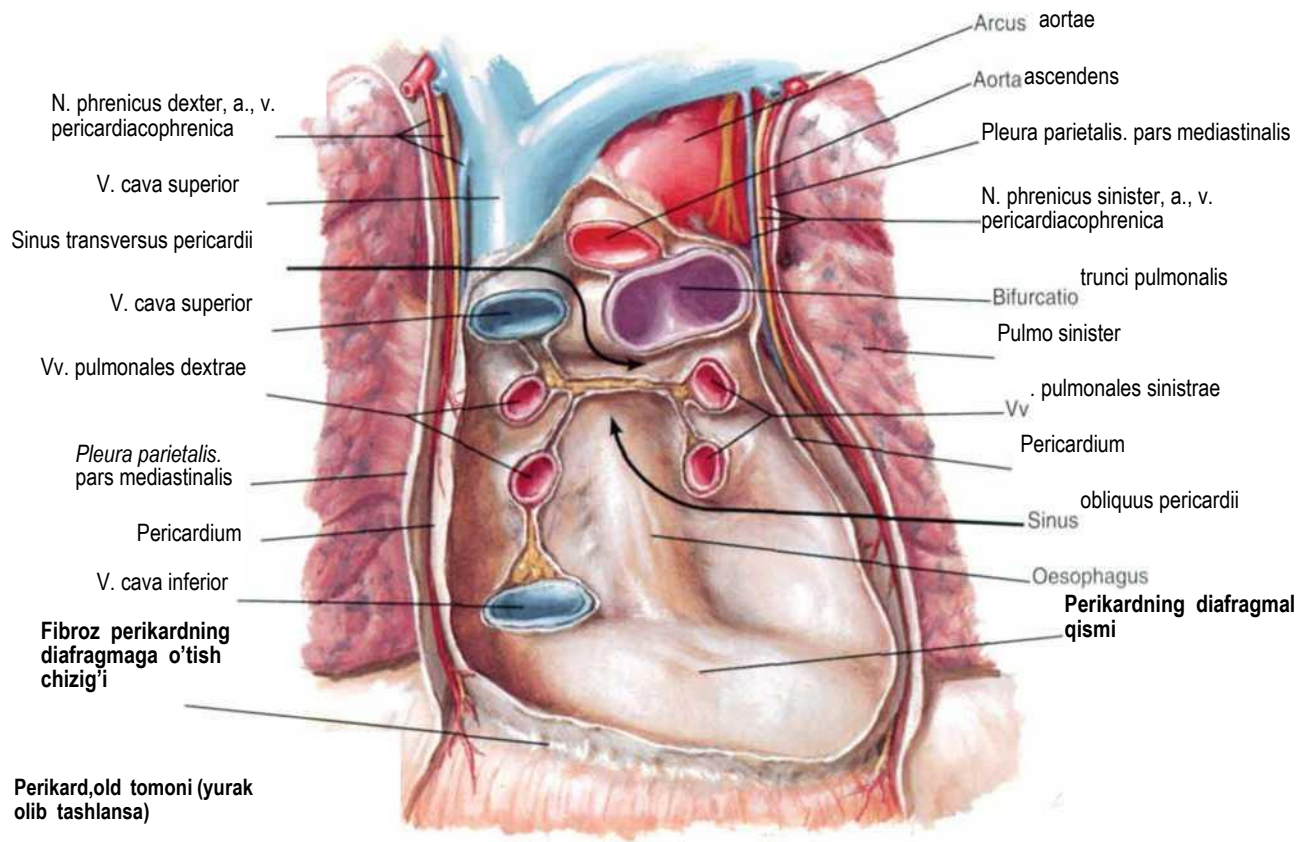
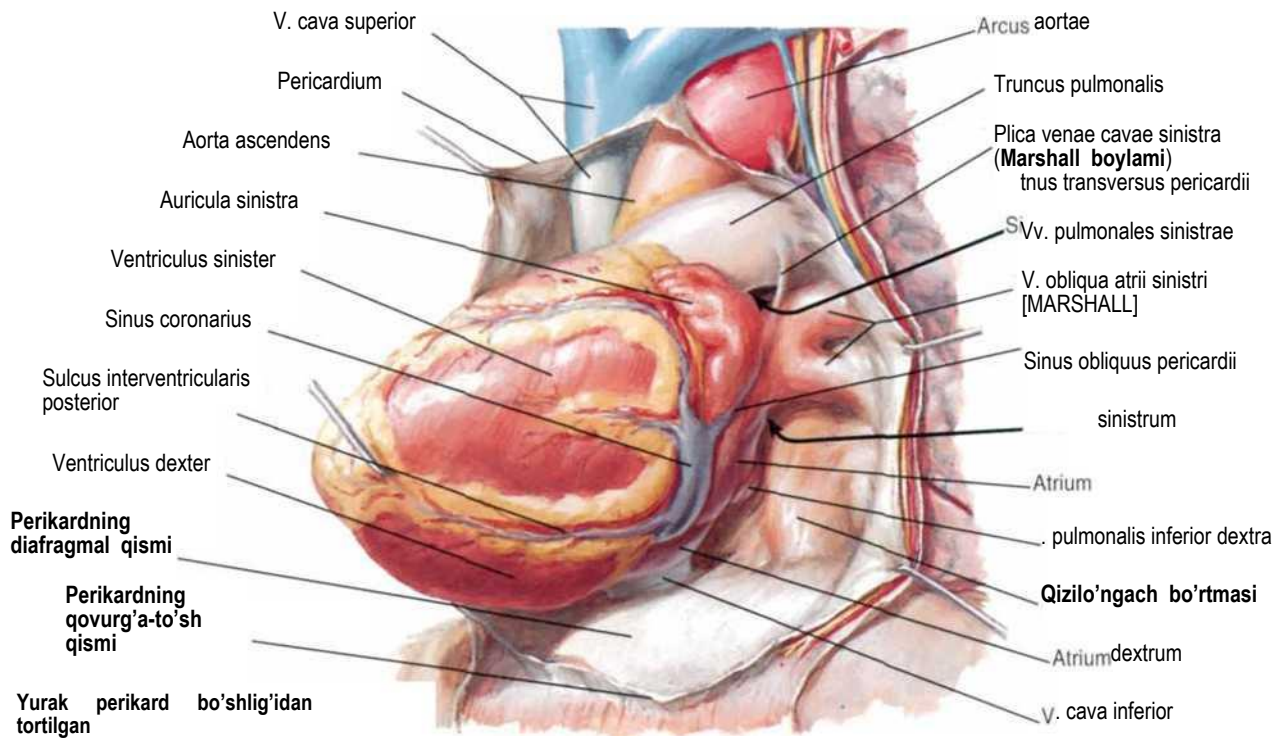


Yurak asosi: orqadan ko'rinishi

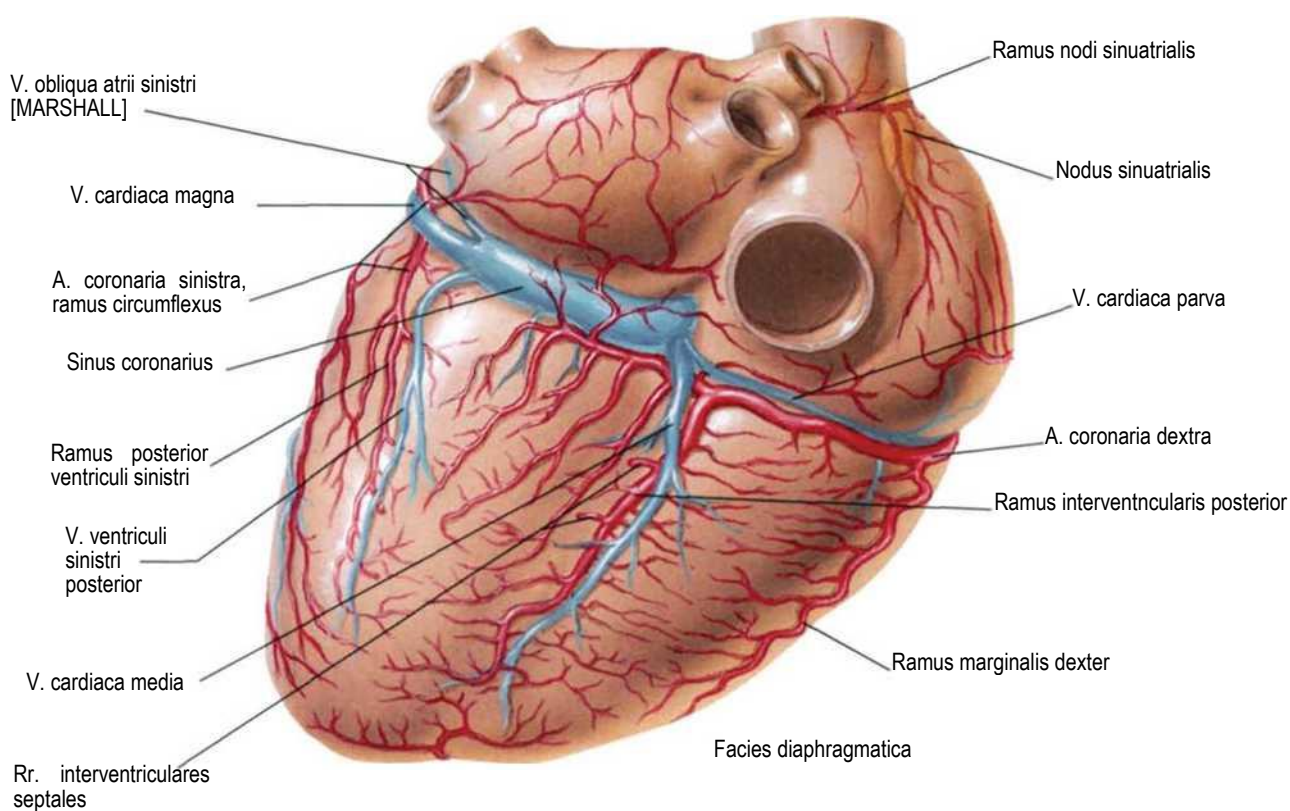
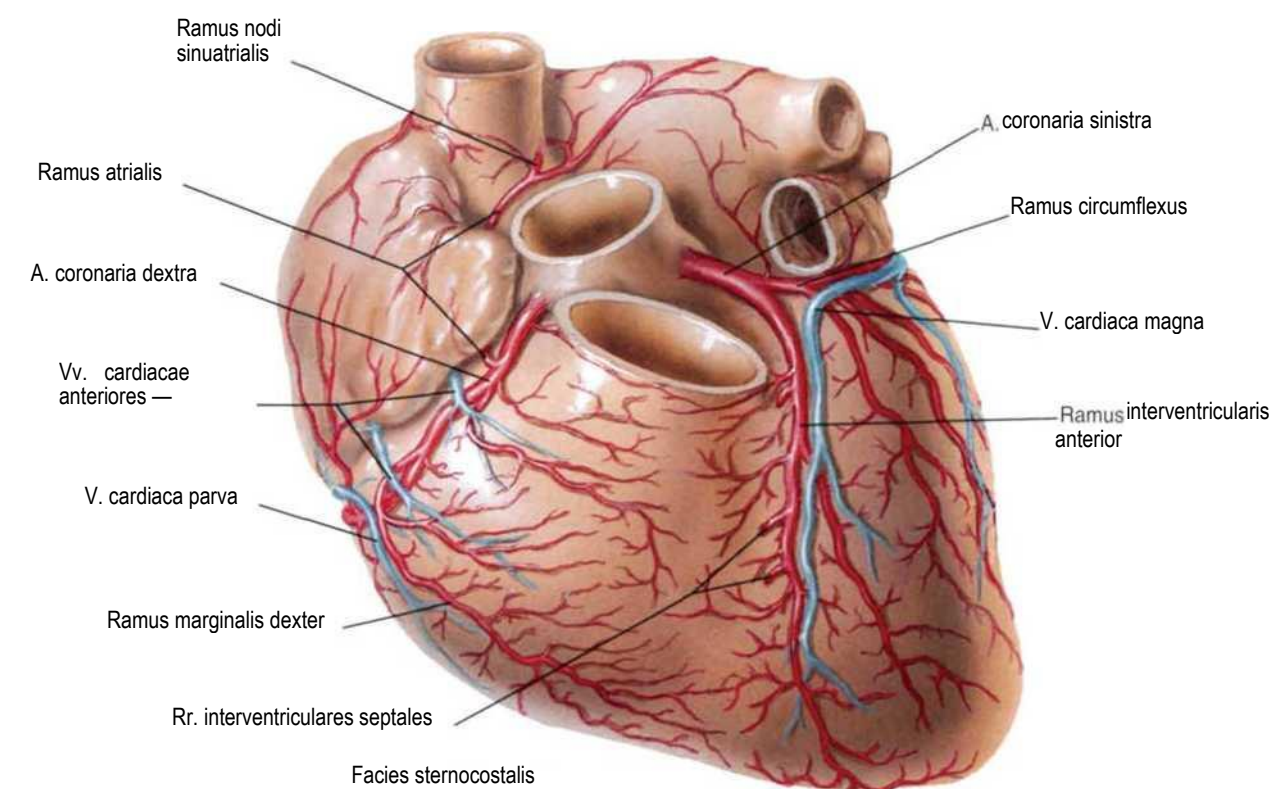


Diafragmal yuzasi: orqa va pastdan ko'rinishi

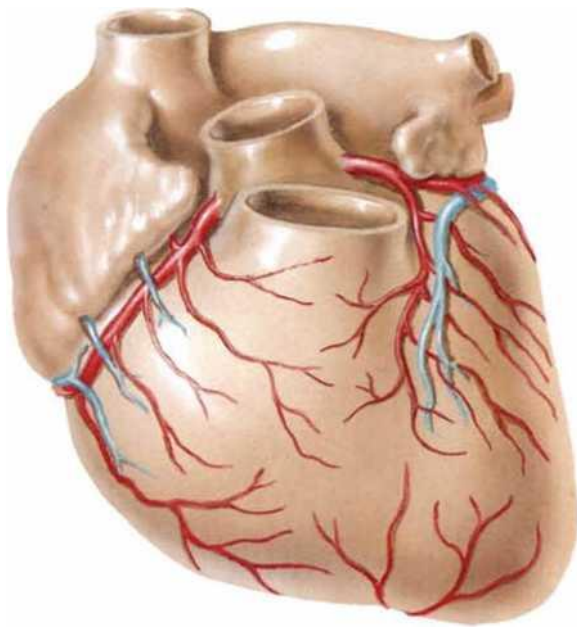
Perikard (pericardium)



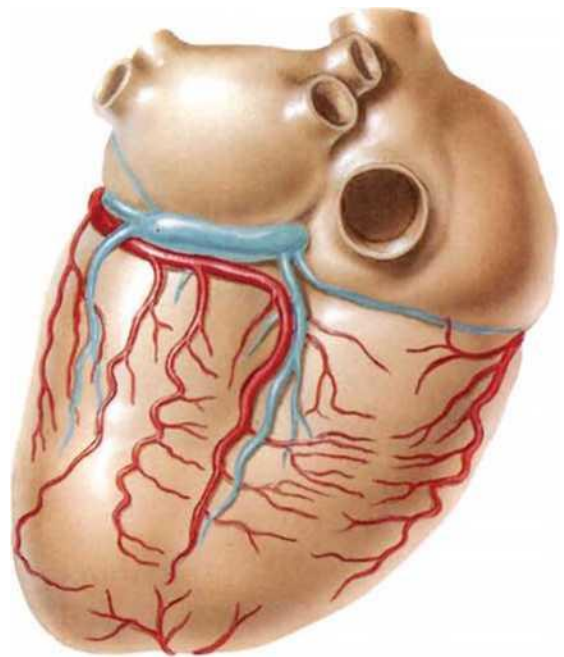
Yurakning tojsimon arteriyalari va venalari



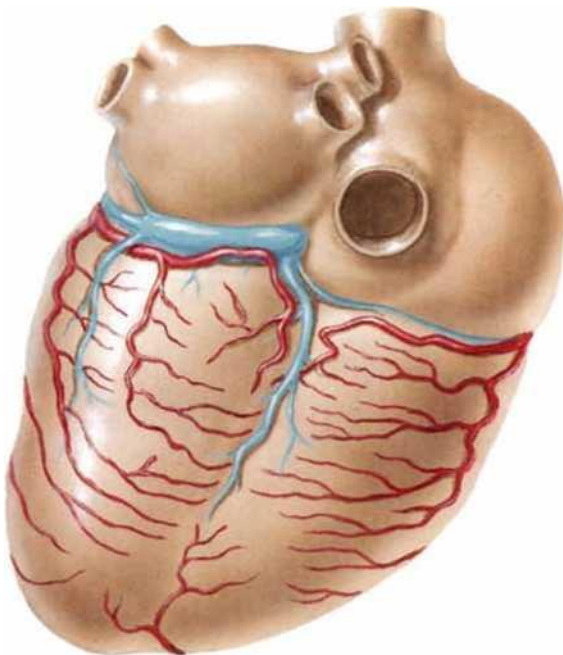
Yurakning tojsimon arteriyalari va venalarining turlari



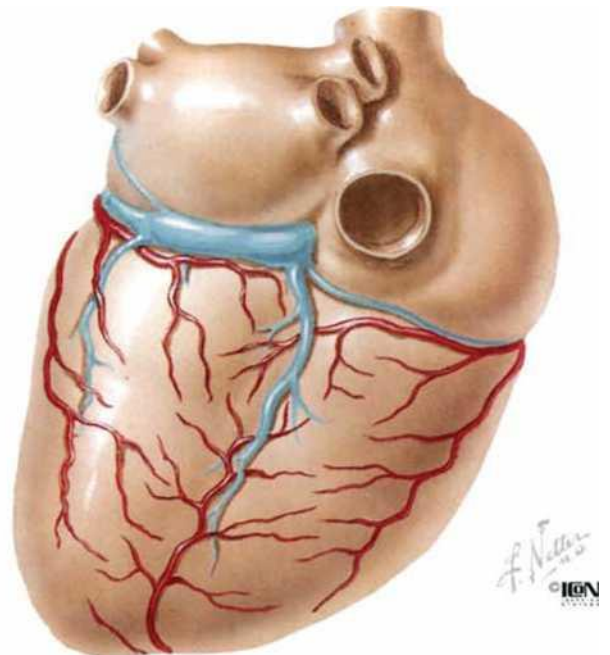
Ramus interventricularis anterior juda qisqa bo'lib, yurakning chap tojsimon arteriyasining shoxi hisoblanadi. Yurakning uchi va uning oldingi devori ramus interventricularis posterior dan qon oladi (u o'ng tojsimon arteriyaning shoxi hisoblanadi).



Ramus interventricularis posterior ramus circumflexus ning shoxi bo'lib, chap tojsimon arteriyadan chiqadi.



Ramus interventricularis posterior bu yerda yo'q. Yurak orqa devori ramus circumflexus ning shoxlari bilan qon bilan ta'minlanadi (a. coronaria sinistra) va a. coronaria dextra



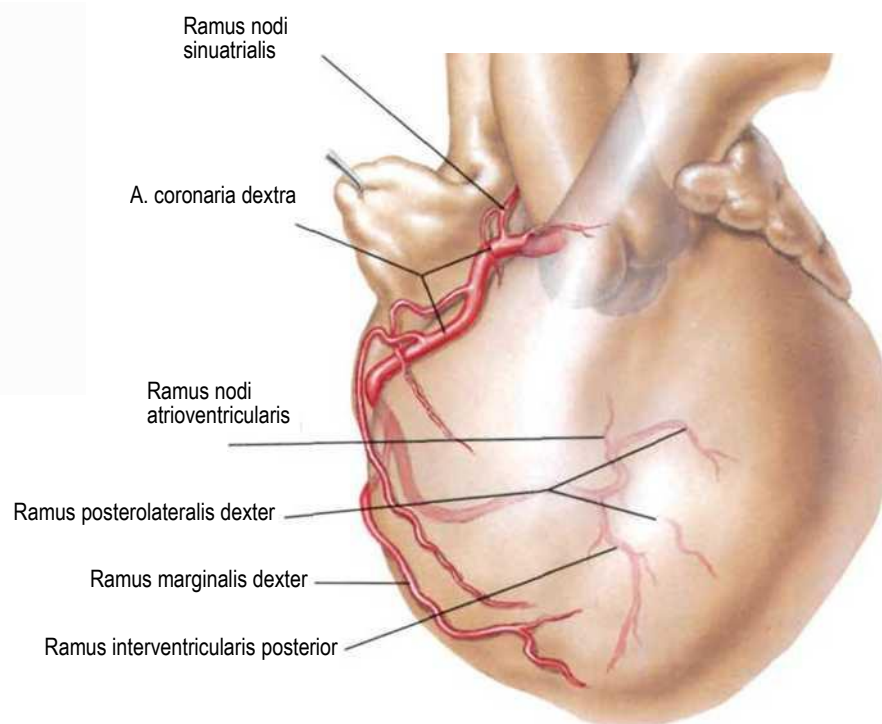
Ramus interventricularis posterior yo'q. Yurak orqa devori ramus interventricularis anterior ning shoxlari bilan qon bilan ta'minlanadi (chap tojsimon arteriya shoxlari)

Tojsimon arteriyalar: arteriografiya

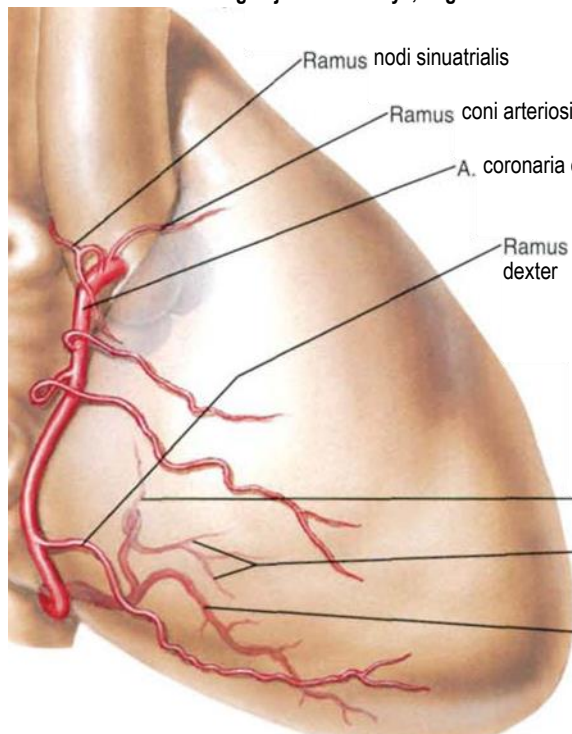
O'ng tojsimon arteriya,old tomoni



Angiogramma



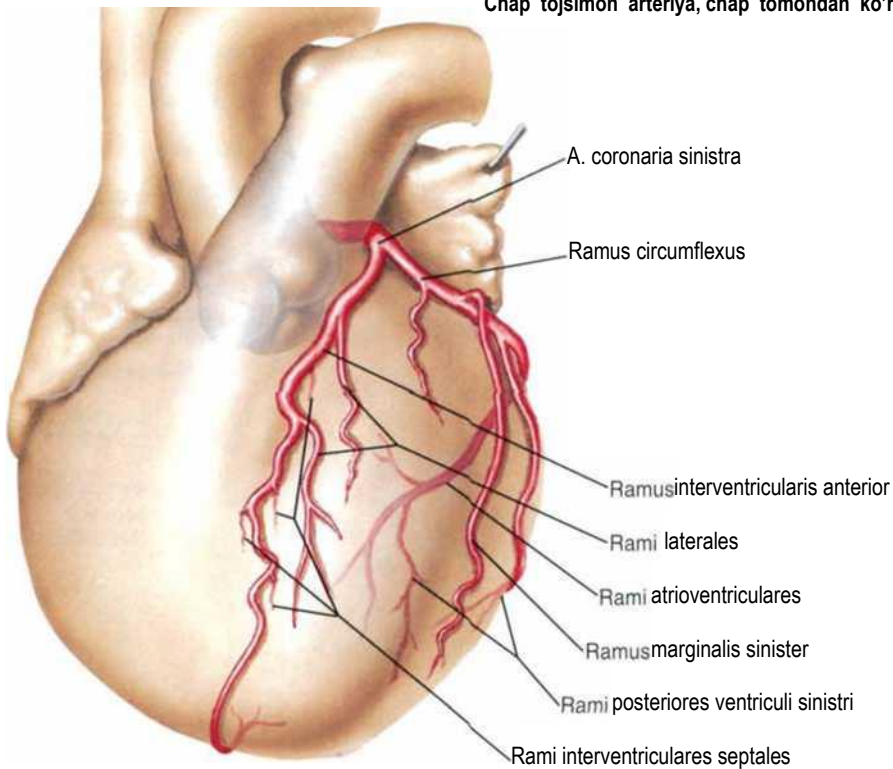
O'ng tojsimon arteriya,o'ng tomoni



Angiogramma

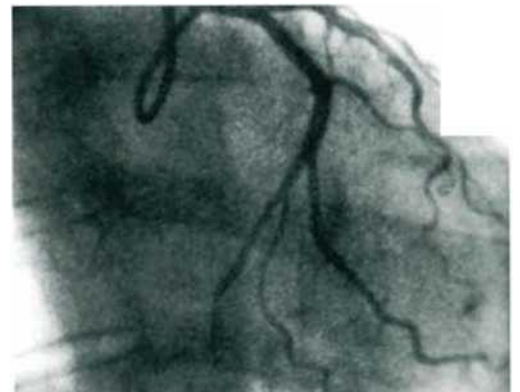
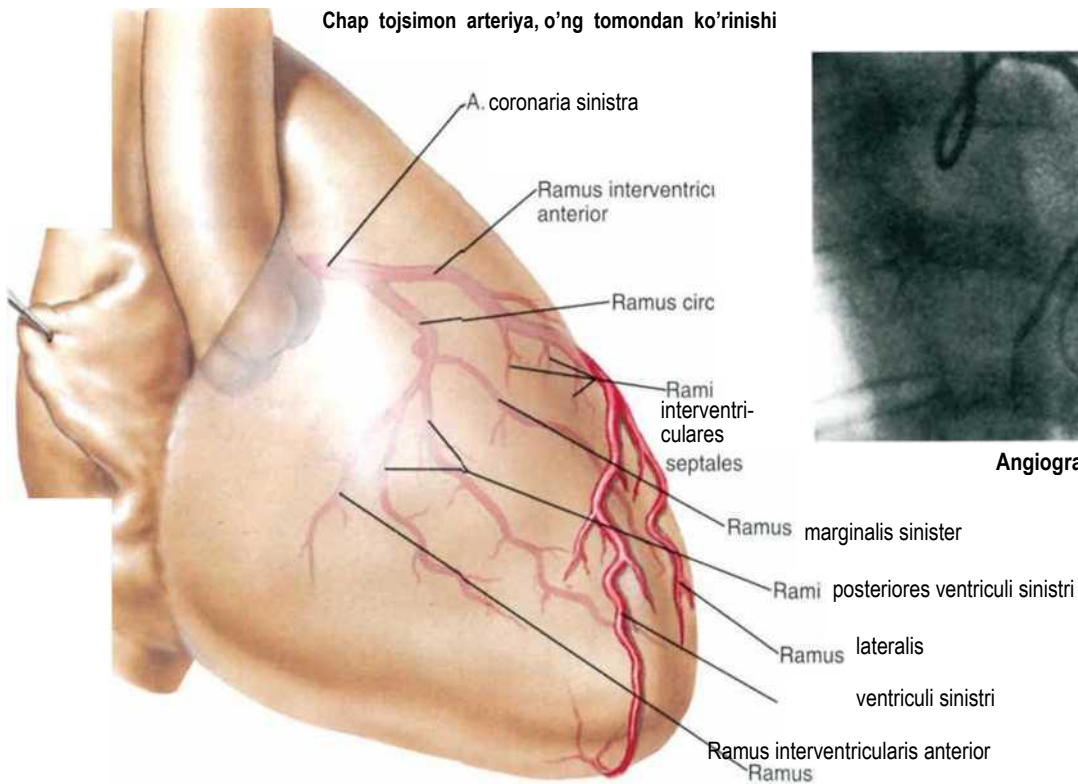
Tojsimon arteriyalar: arteriografiya (davomi)

Chap tojsimon arteriya, chap tomondan ko'rinishi



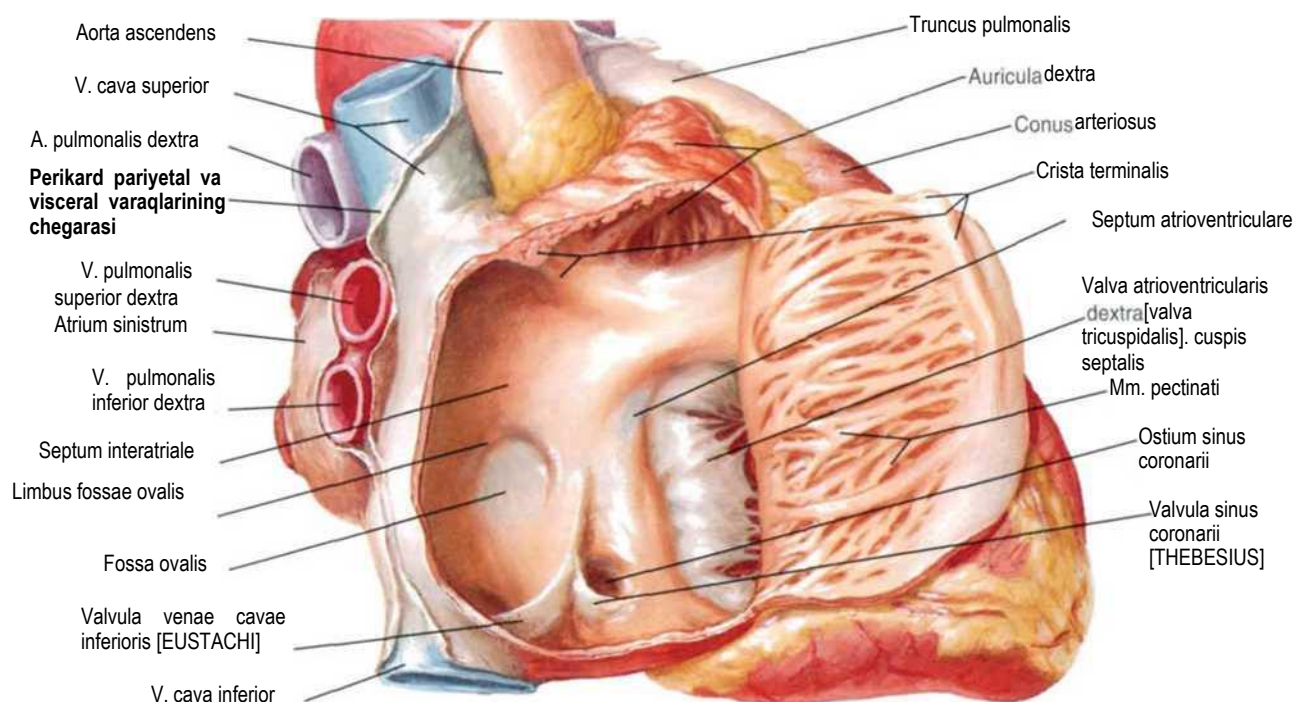
Angiogramma

Chap tojsimon arteriya, o'ng tomondan ko'rinishi

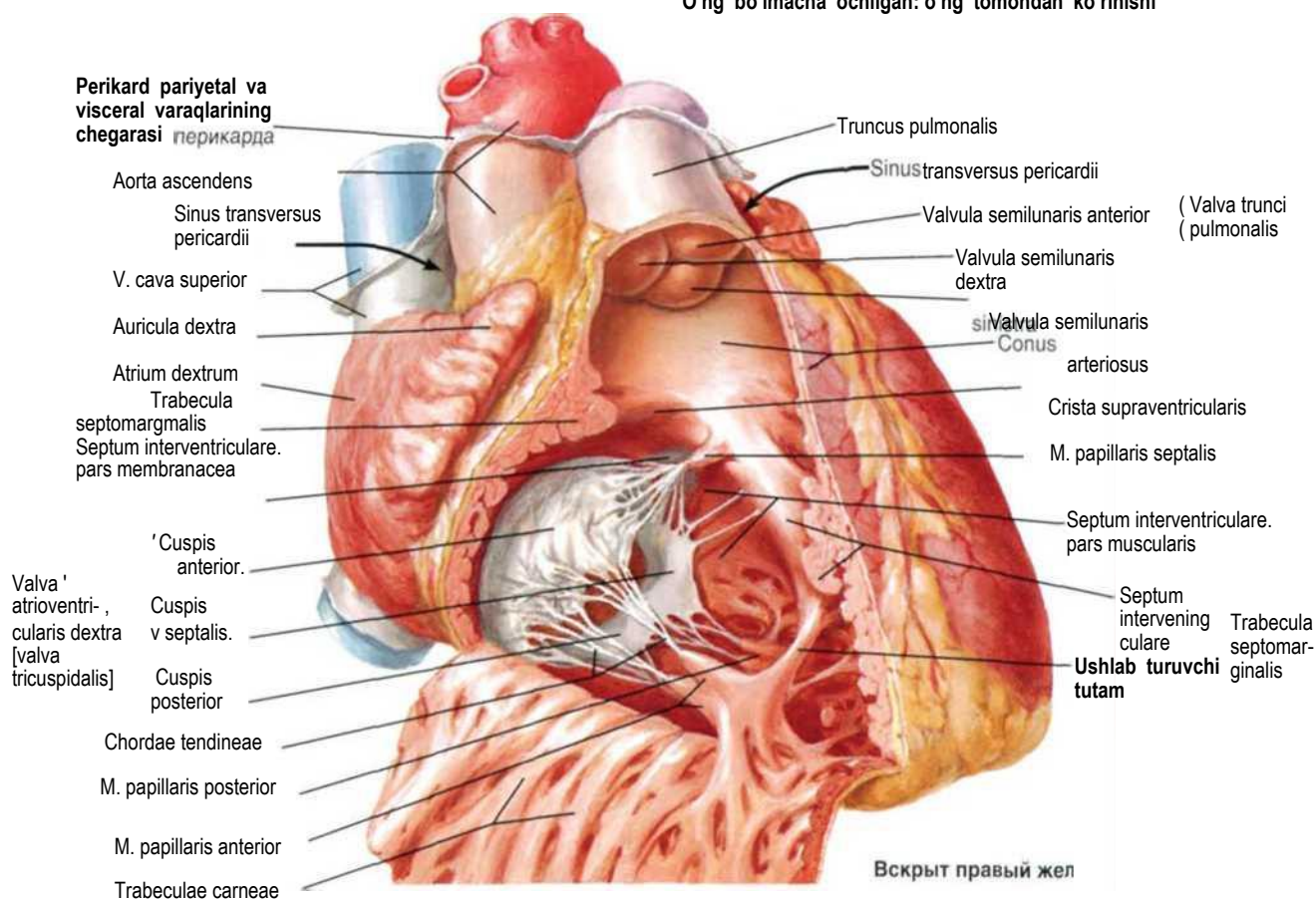


Angiogramma

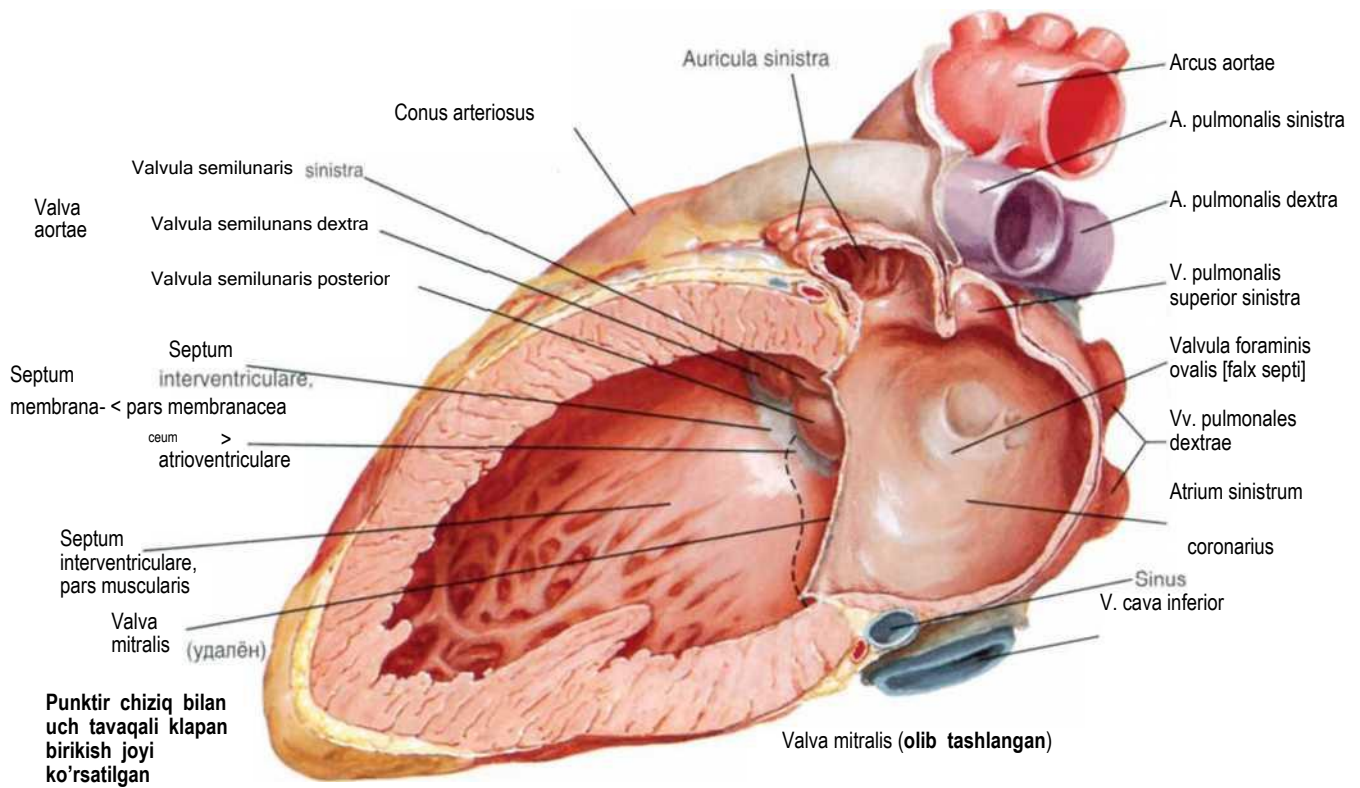
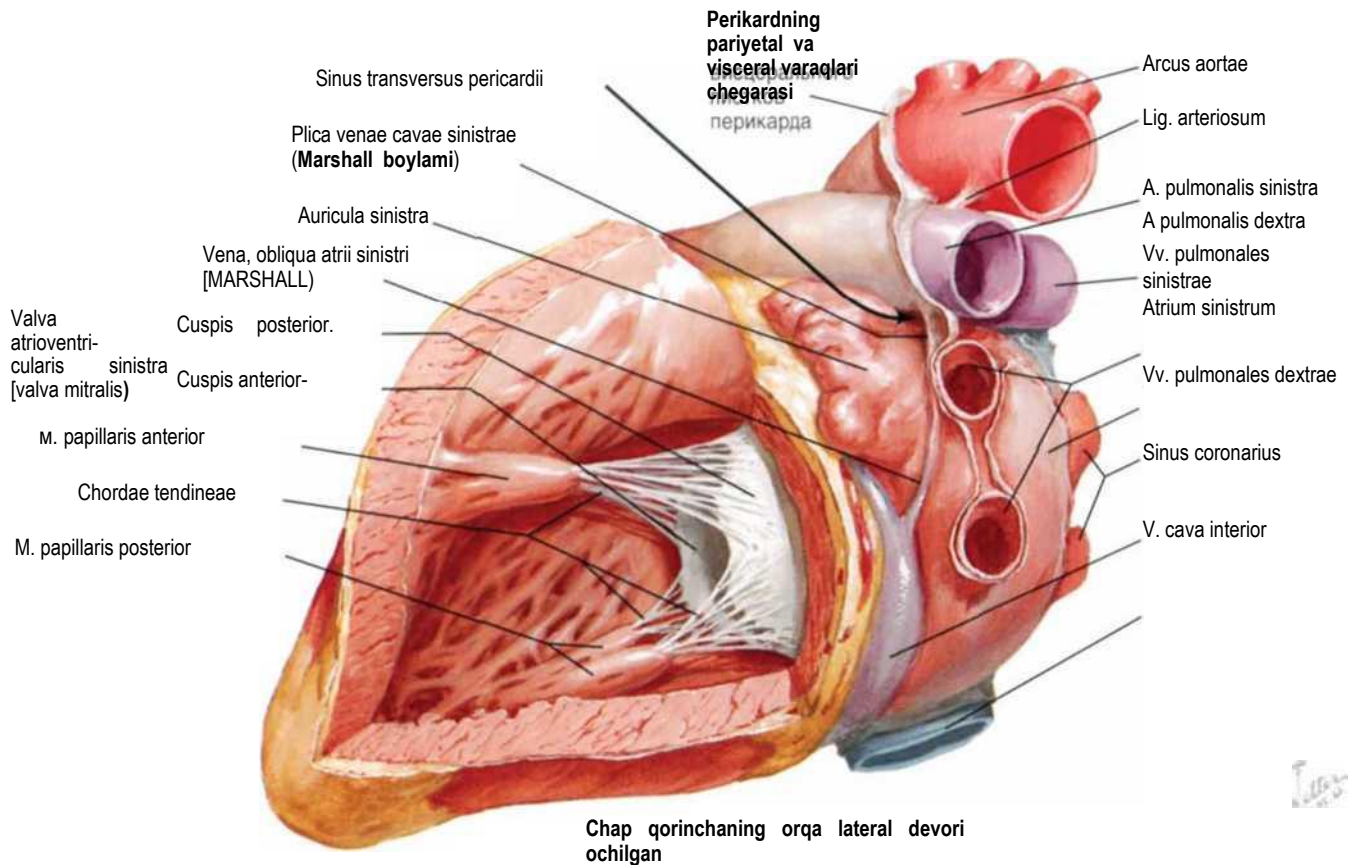
O'ng bo'lmacha va o'ng qorincha



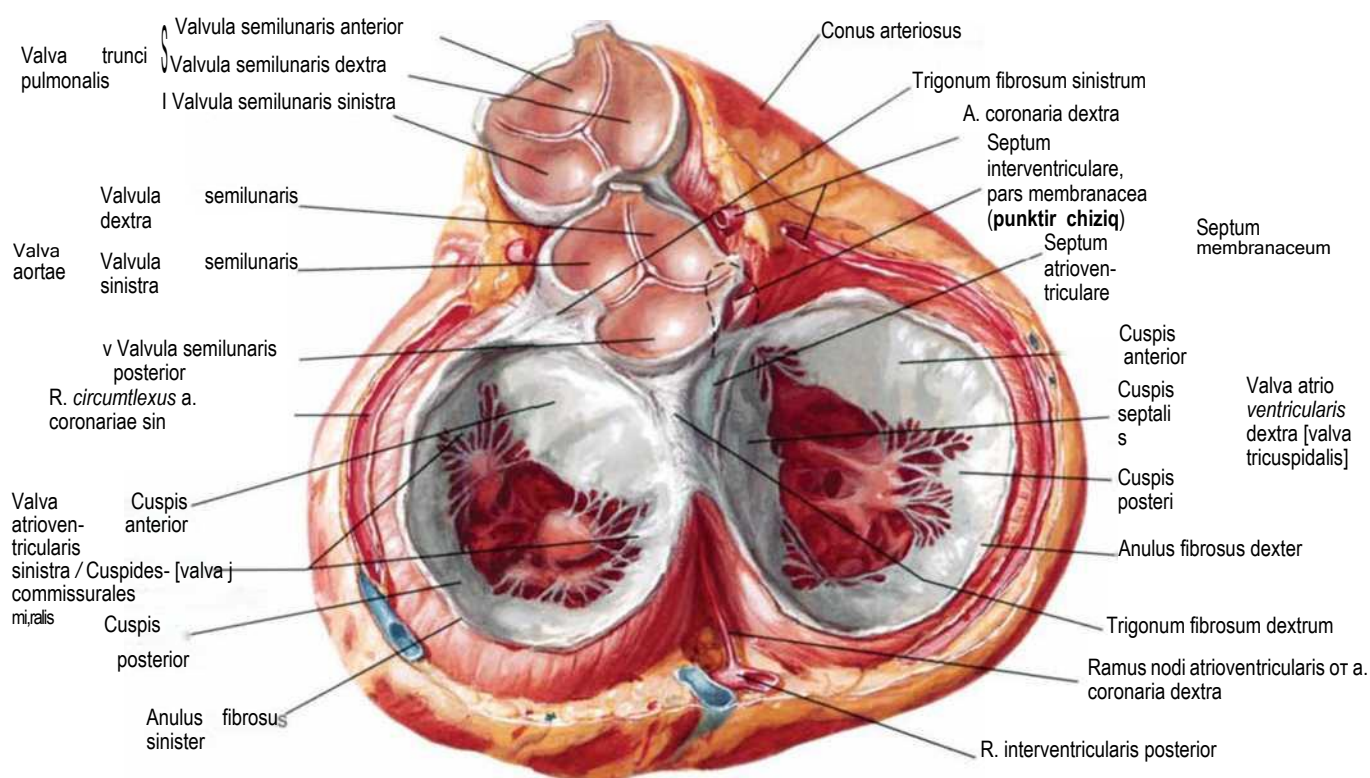
O'ng bo'lmacha ochilgan: o'ng tomondan ko'rinishi



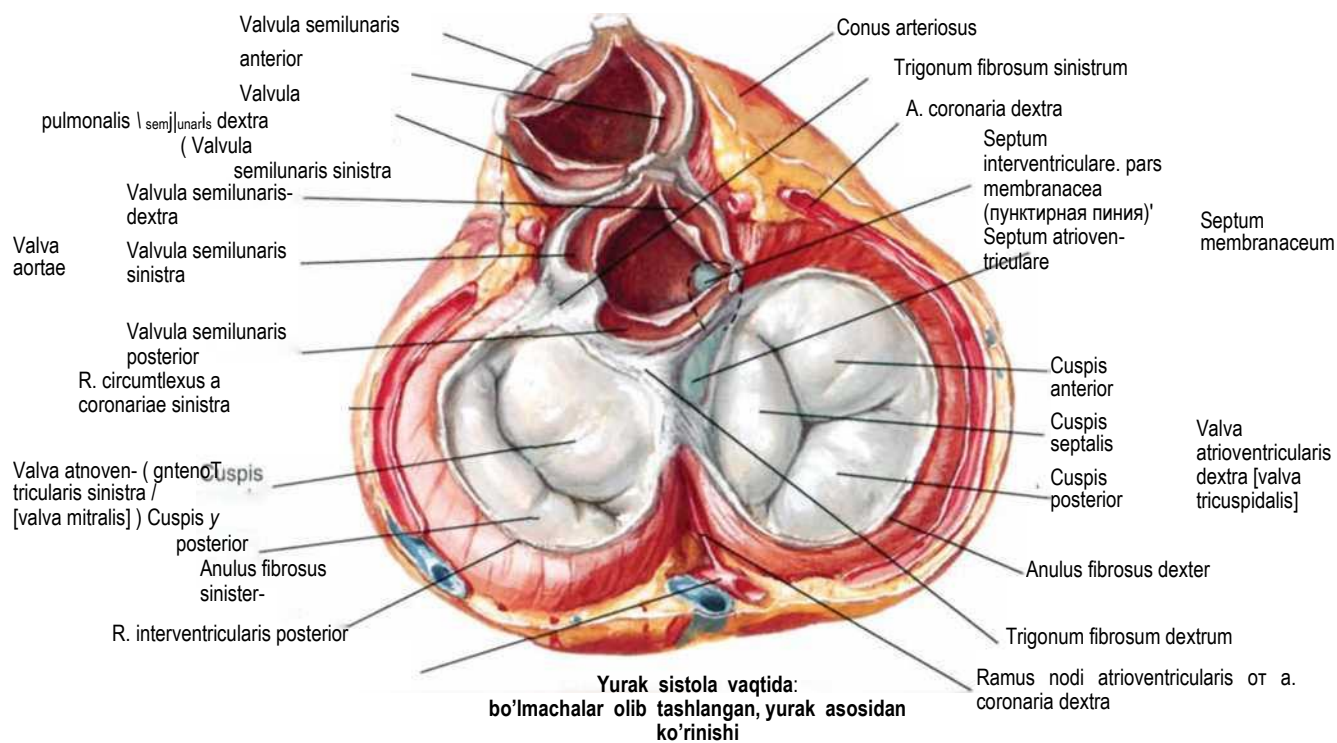
Chap bo'lmacha va chap qorincha



Klapanlar (valvae) va yurakning fibroz skeleti

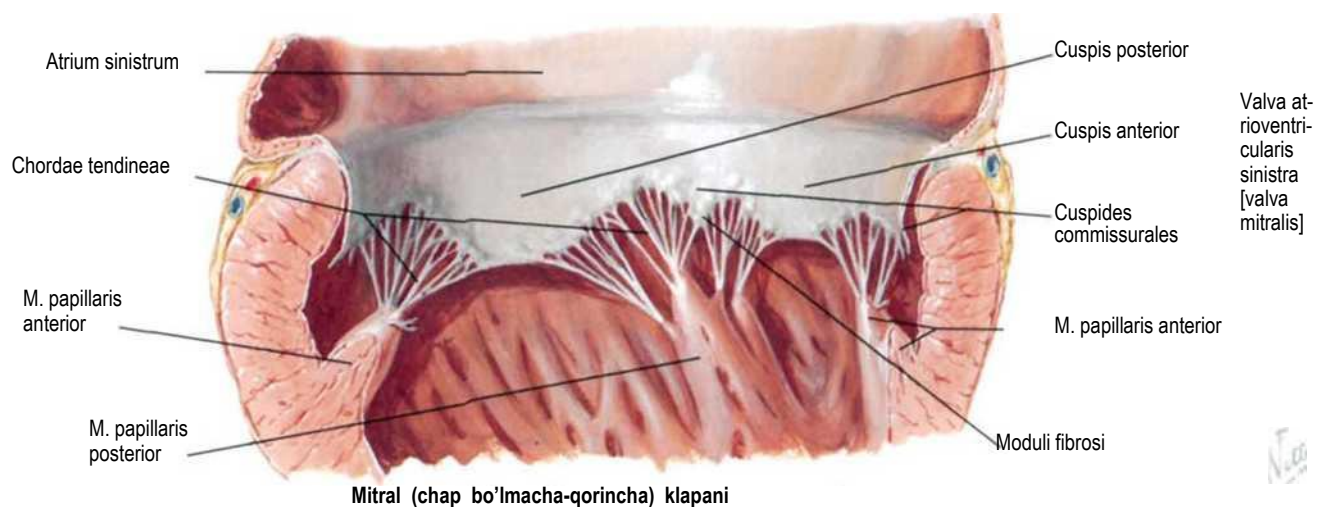
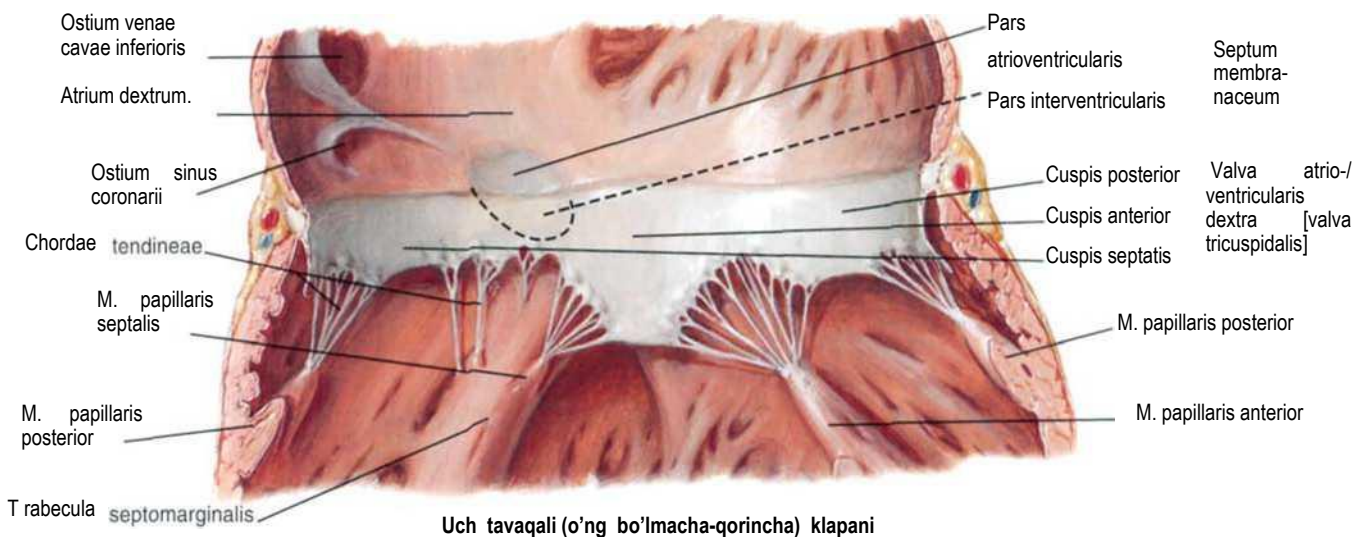
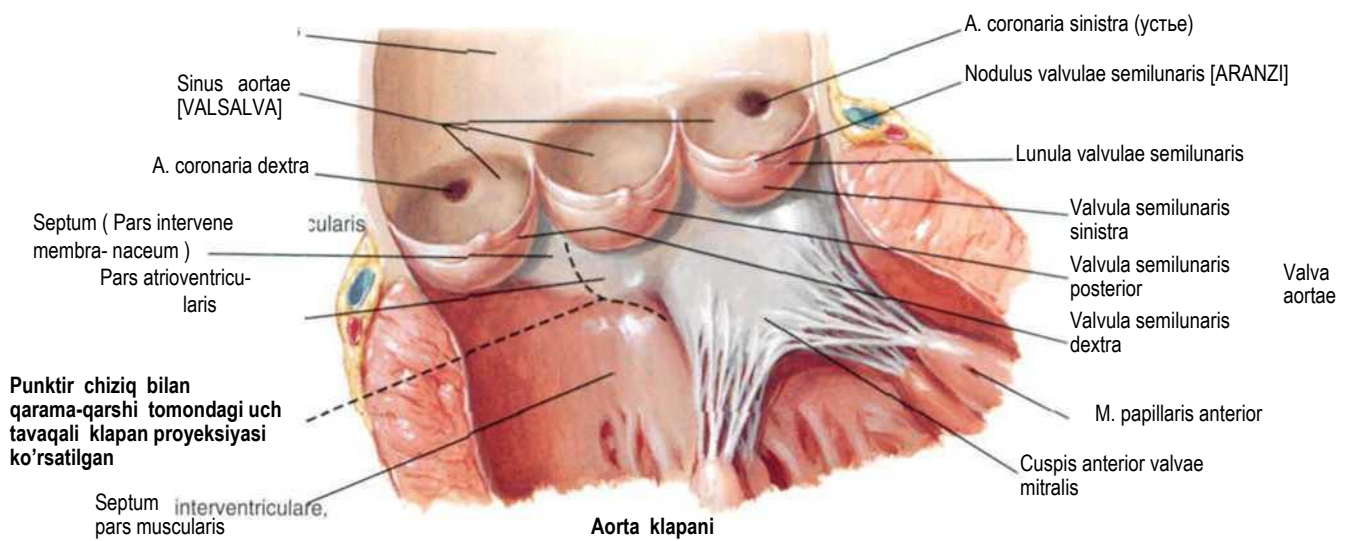


Yurak diastola vaqtida:
bo'lmachalar olib tashlangan, yurak asosidan ko'rinishi

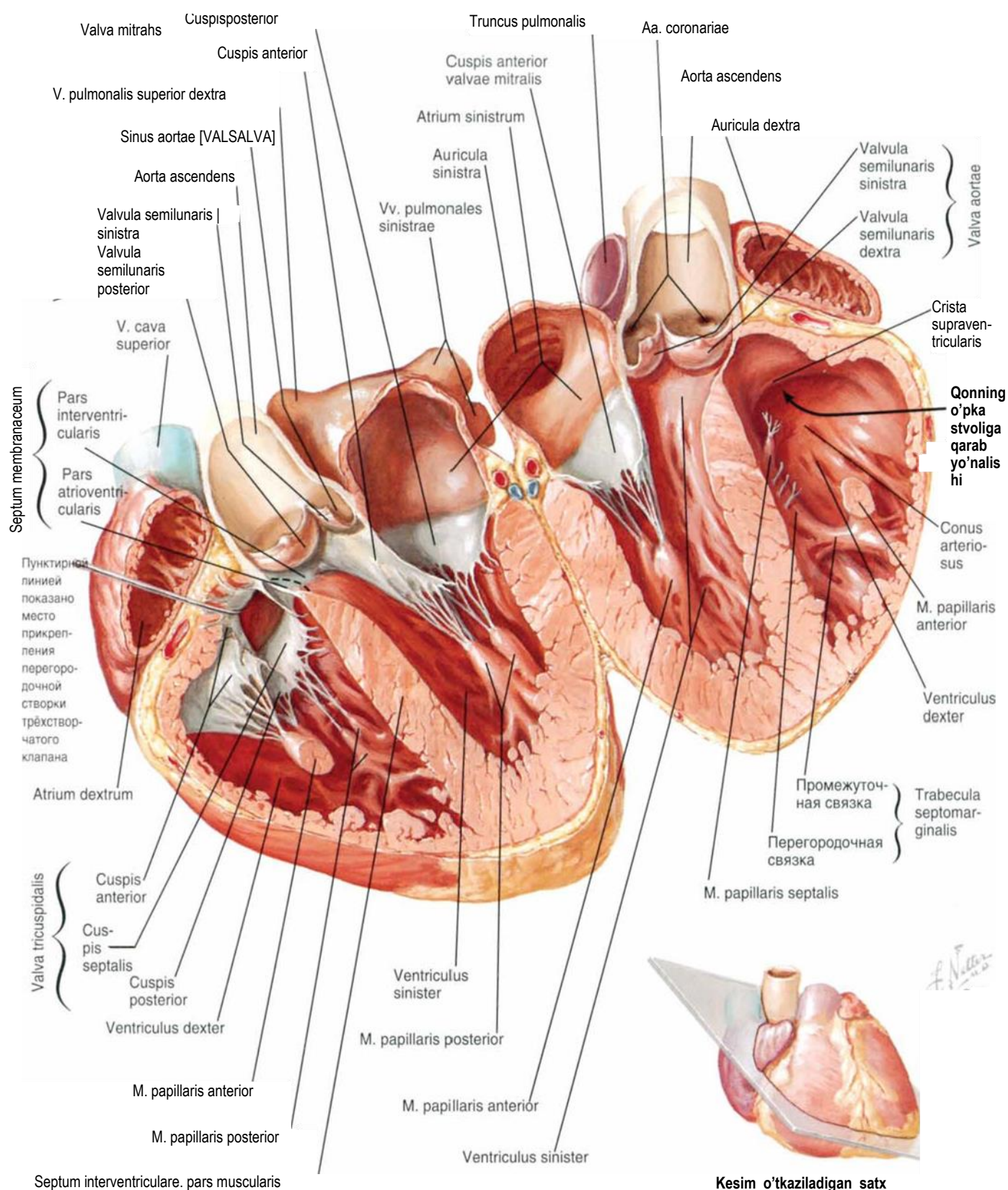


Yurak sistola vaqtida:
bo'lmachalar olib tashlangan, yurak asosidan ko'rinishi

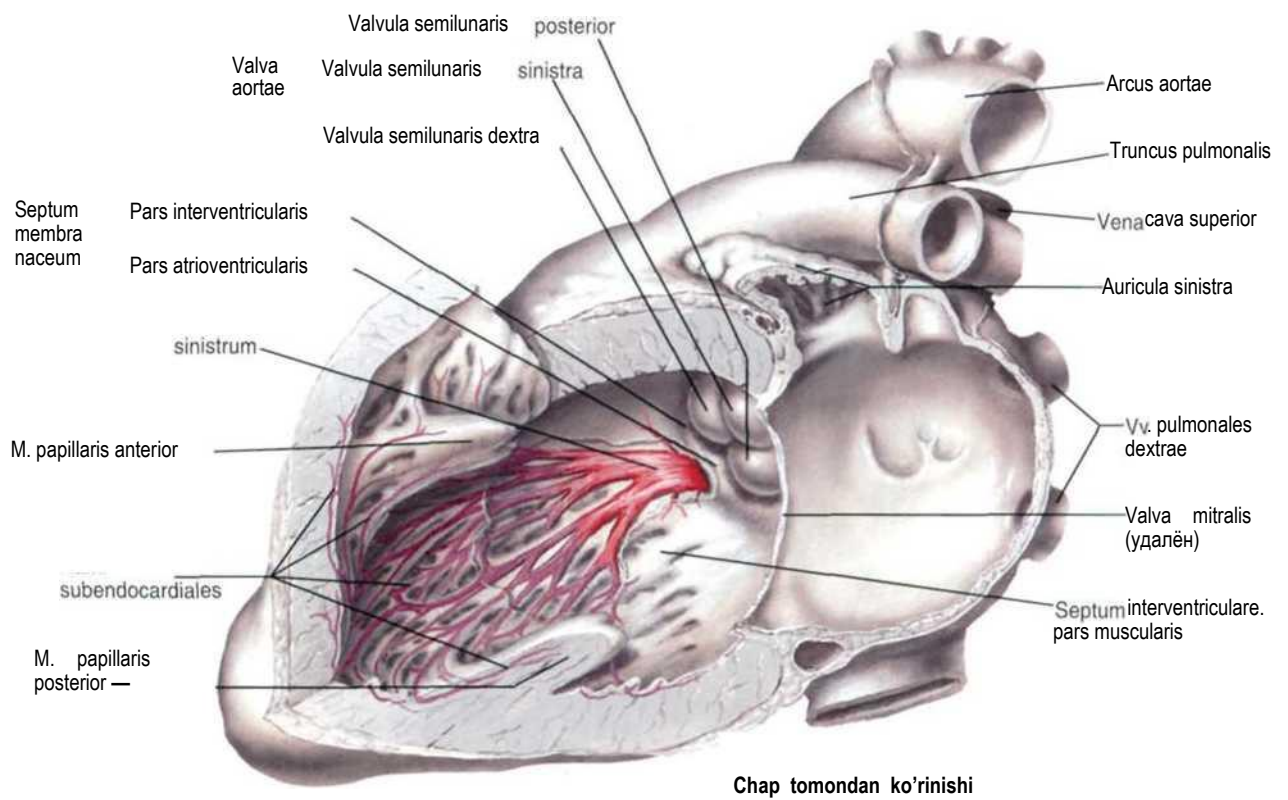
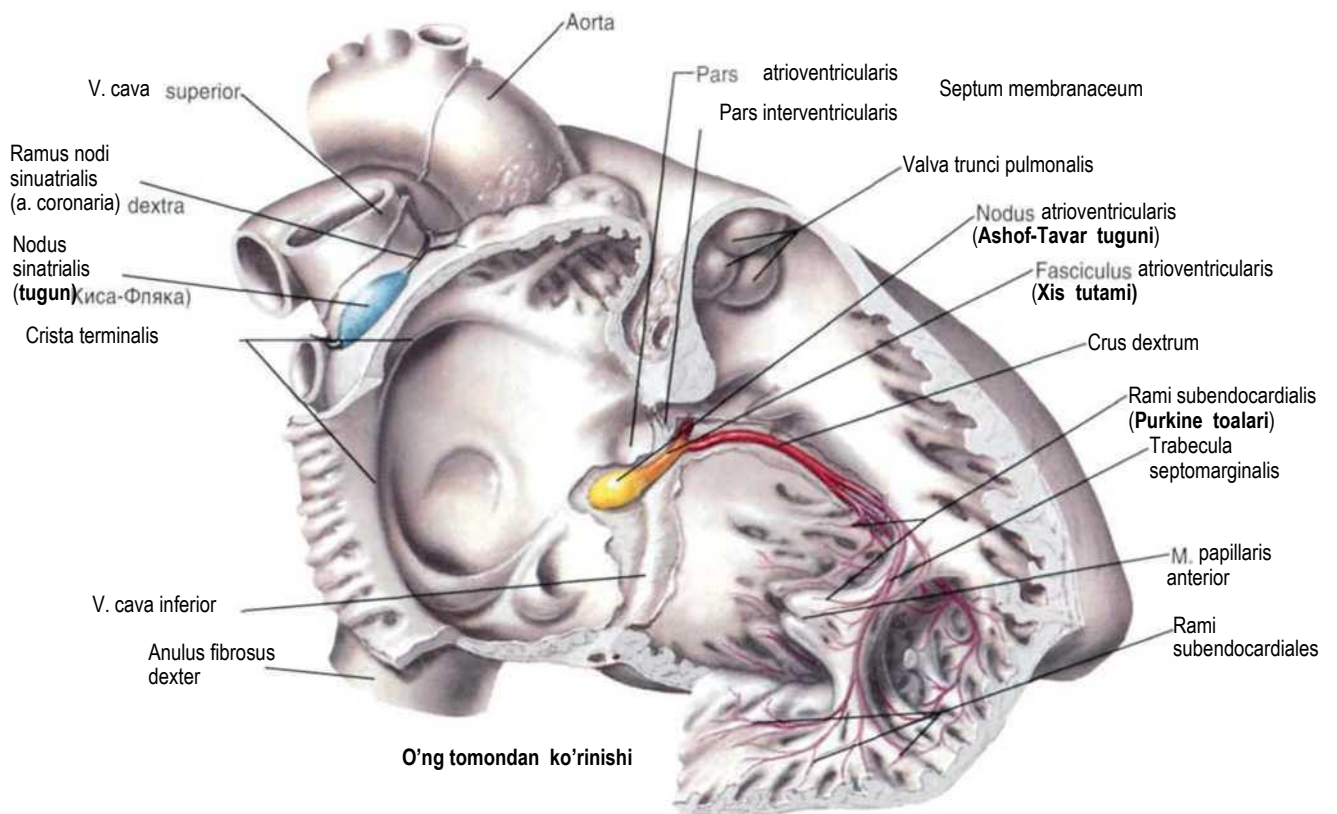
Klapanlar (valvae) va yurakning fibroz skeleti (davomi)



Bo'lmachalar, qorinchalar va qorinchalararo to'siq

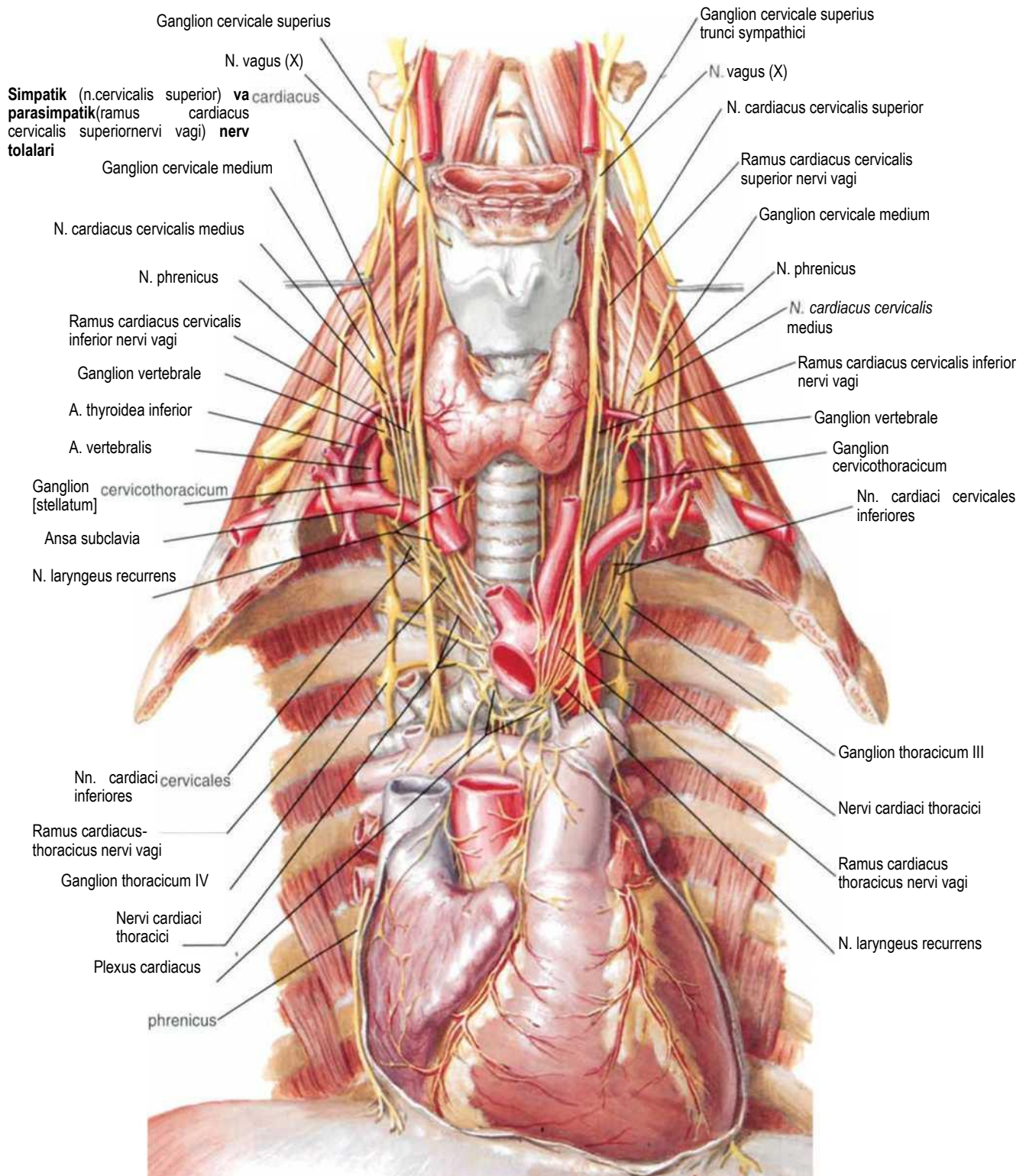


Yurakning o'tkazuvchi tizimi



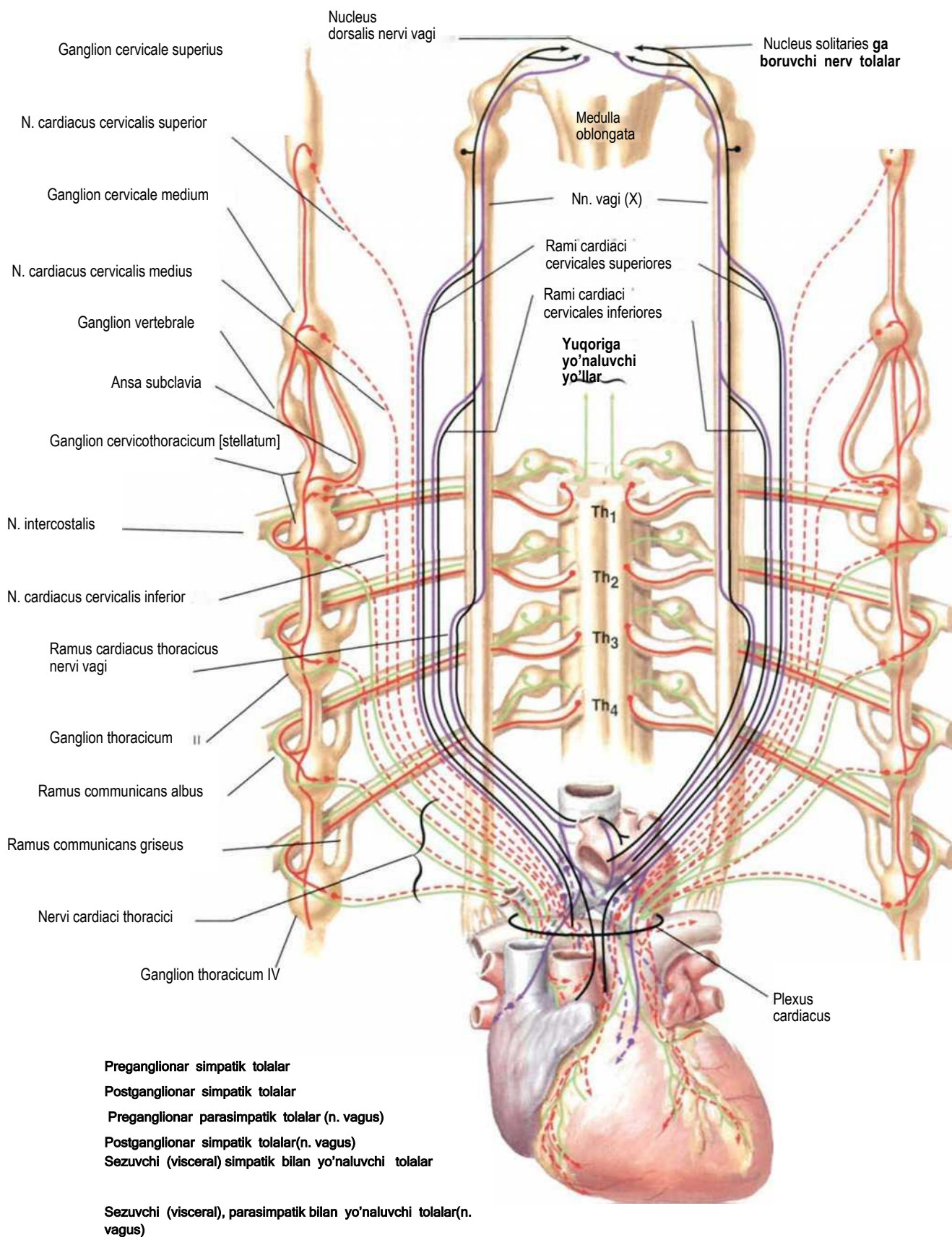
Yurak innervatsiyasi

124, 152. 198-rasmlar.



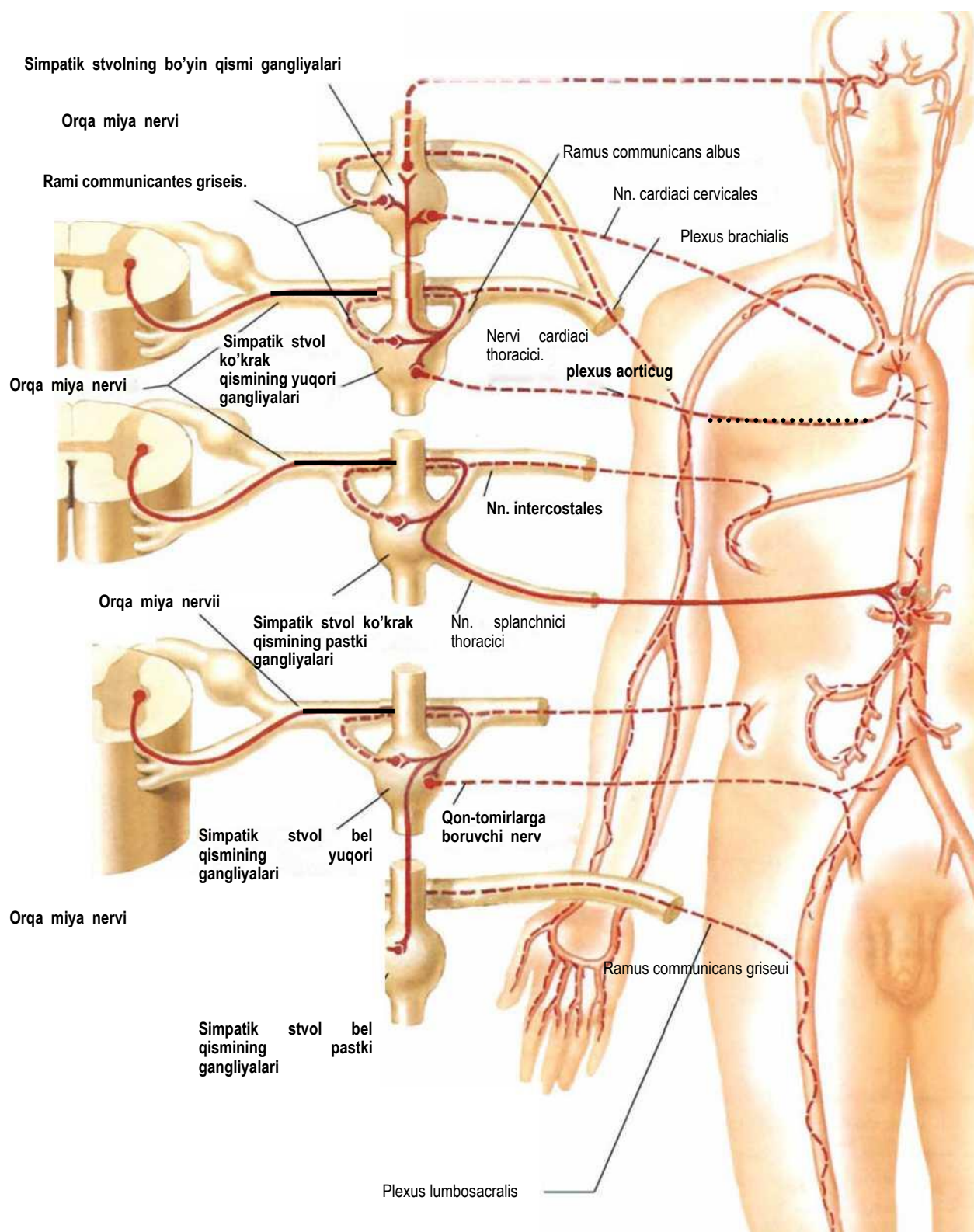
Yurak innervatsiyasi

120, 153-rasmlar.



Qon-tomirlar innervatsiyasi : sxemasi

153-rasm.



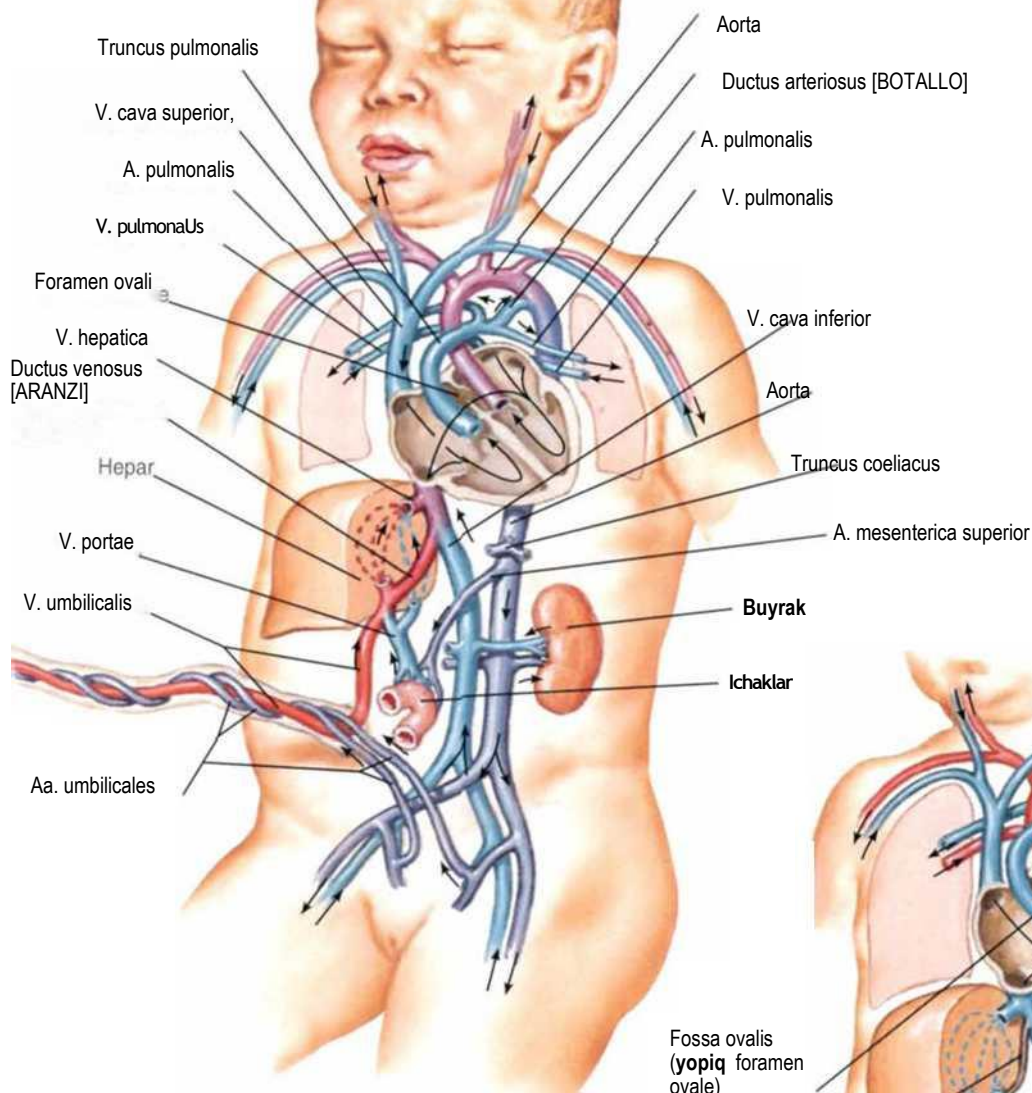
216-rasm

KO'KRAK QAFASI

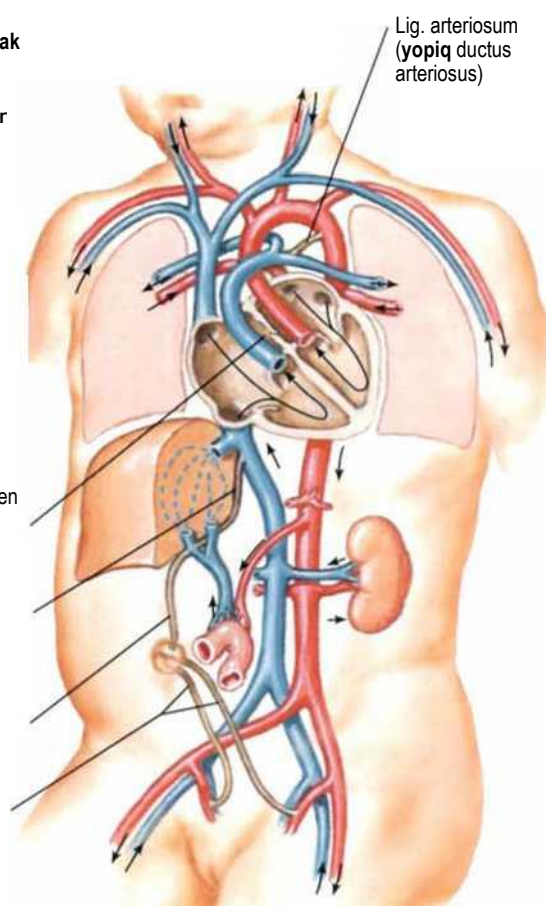
Prenatal va postnatal qon aylanishi

236-rasm .

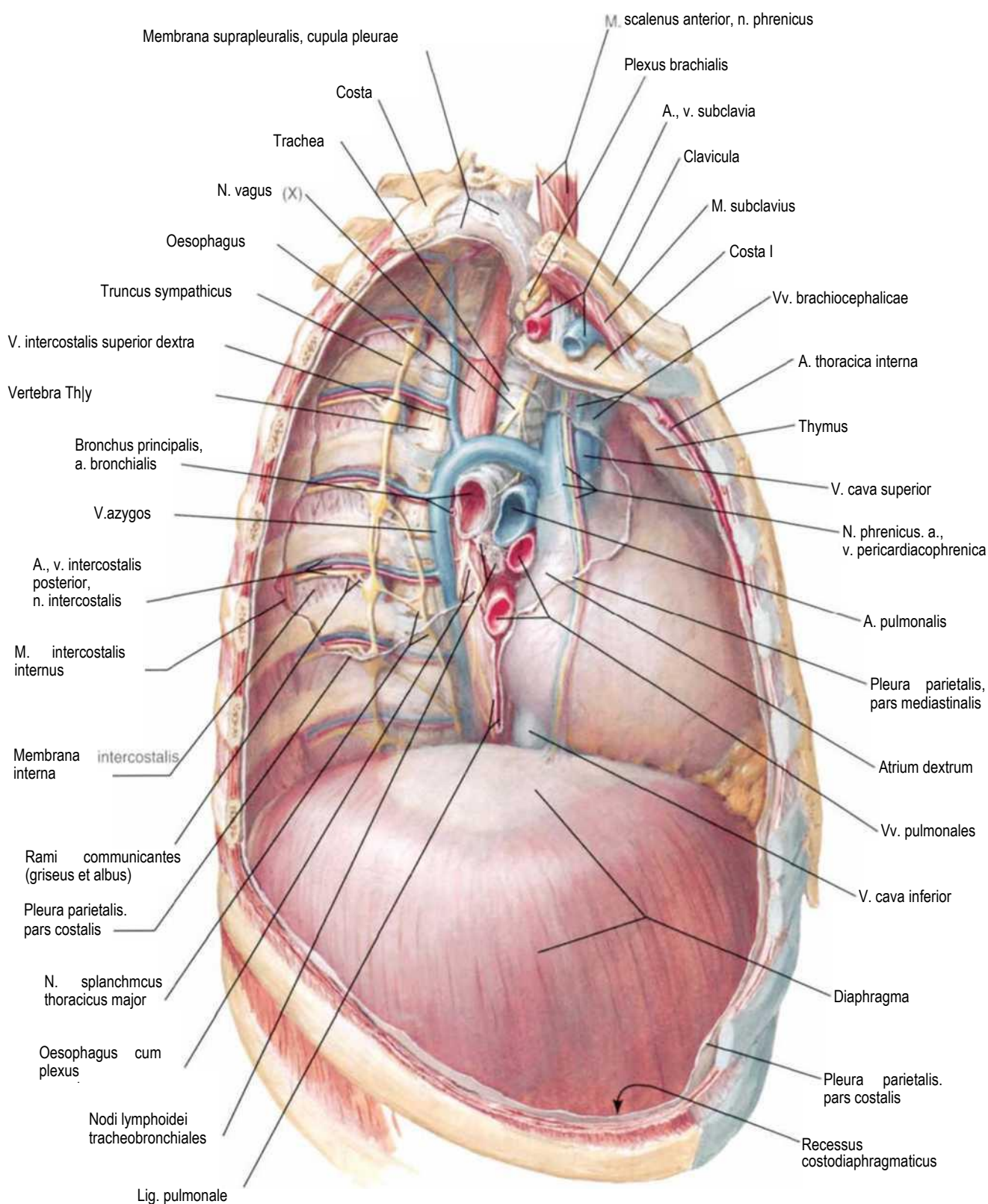
Prenatal sirkulyasiya



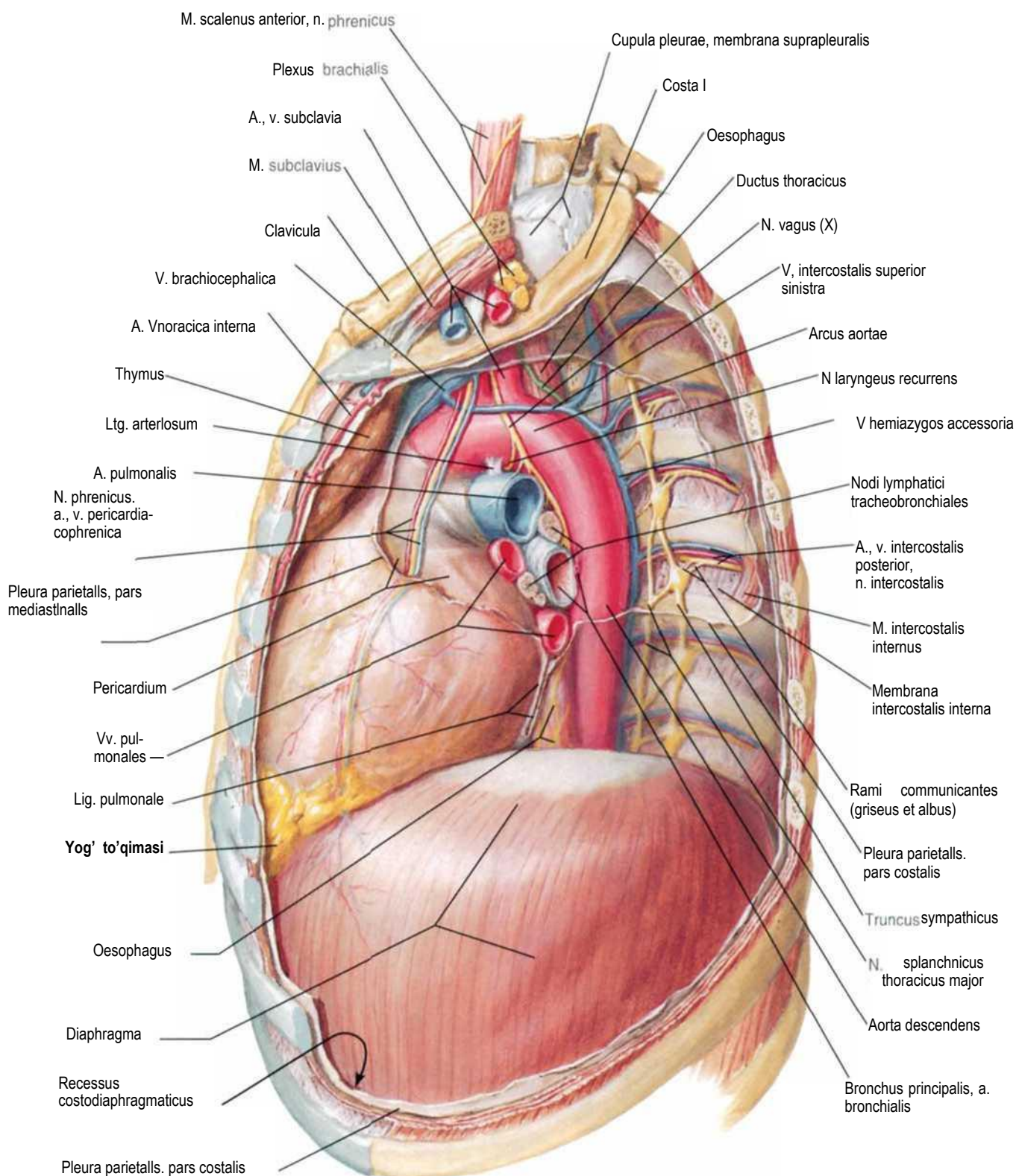
Postnatal sirkulyasiya



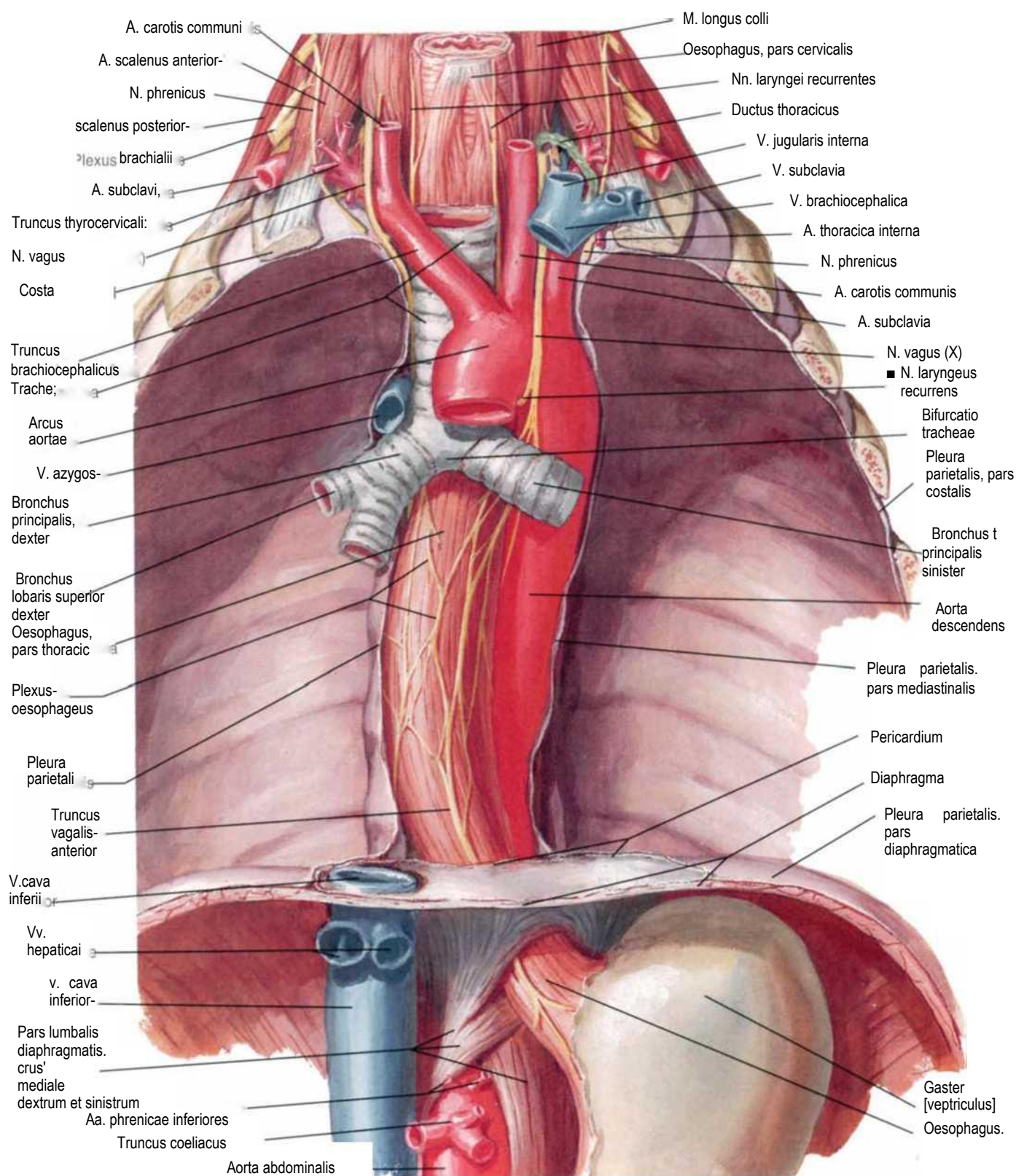
Ko'ks oralig'i (mediastinum), o'g yonboshdan ko'rinishi



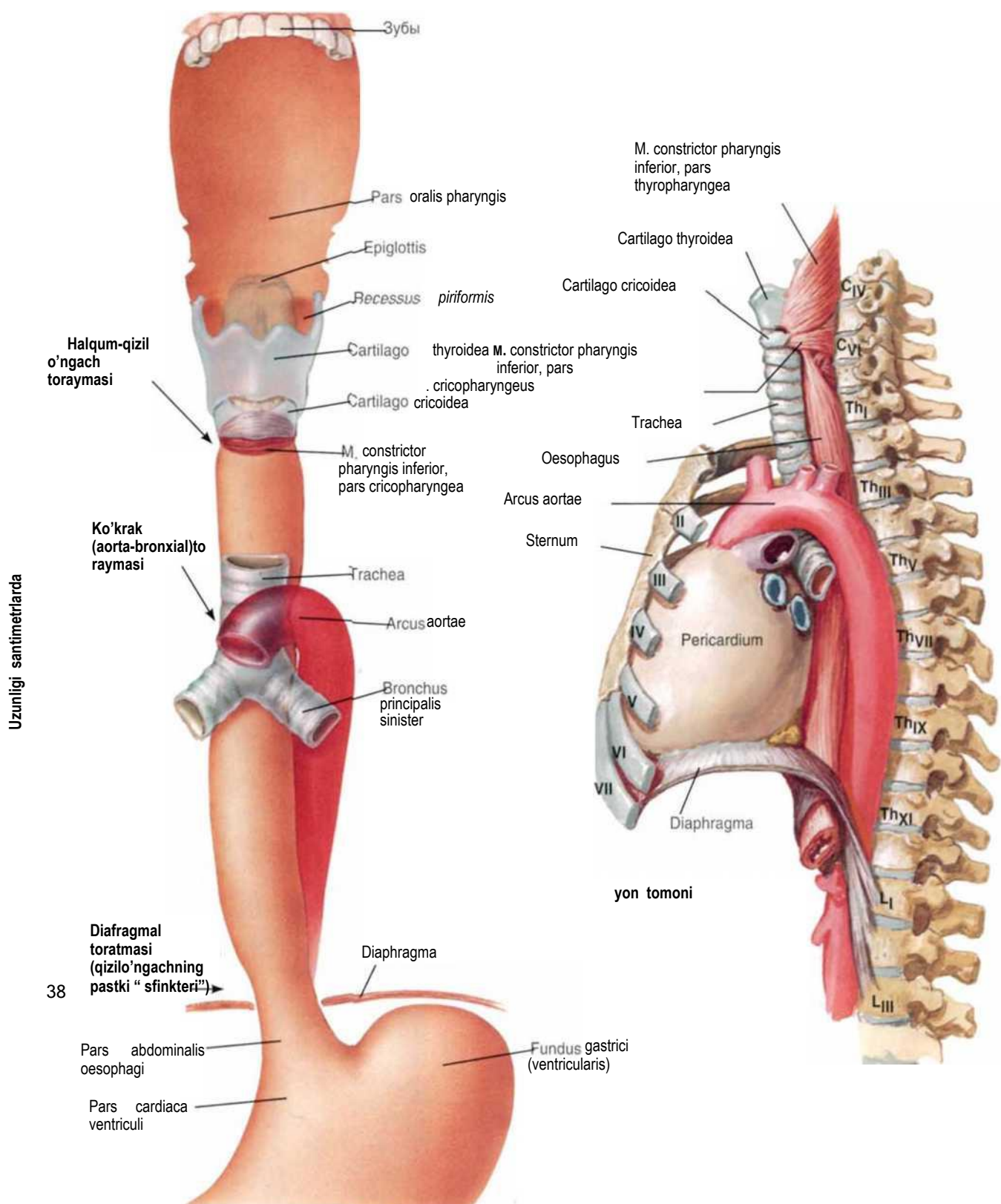
Ko'ks oralig'i (mediastinum), chap yonboshdan ko'rinishi



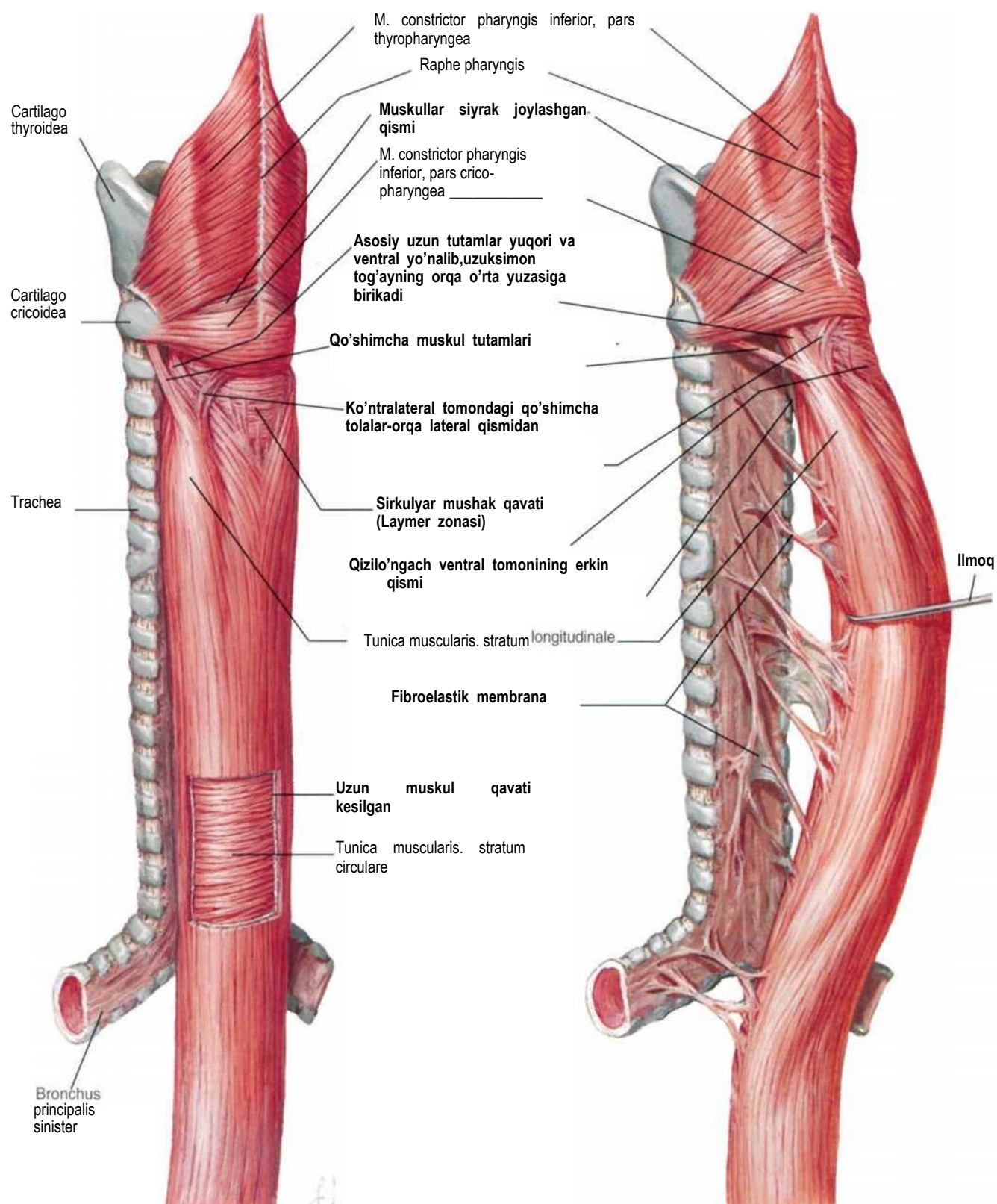
Qizilo'ngach (oesophagus): topografiyasi



Qizilo'ngach topografiyasi va toraymalari

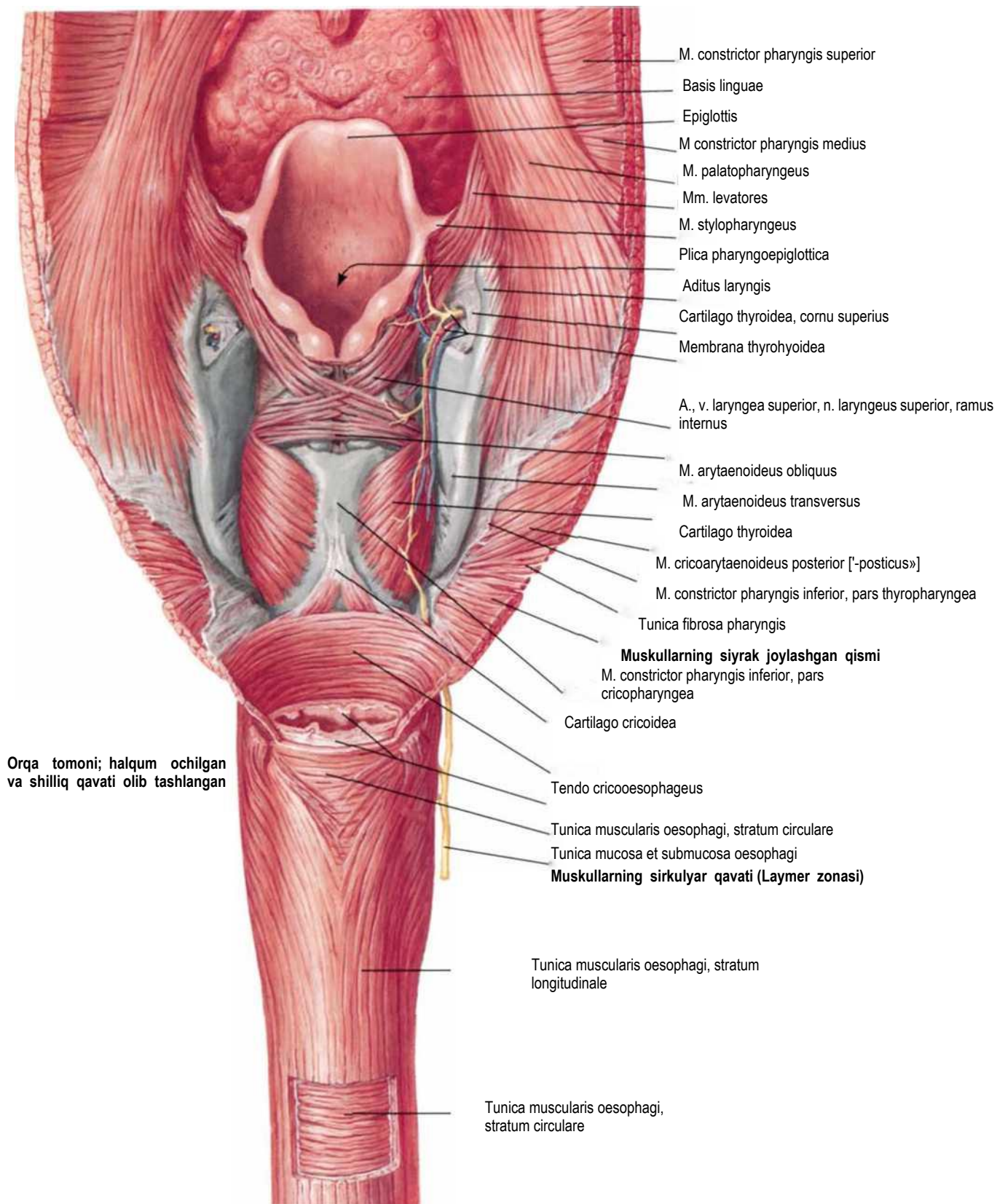


Qizilo'gach muskullari

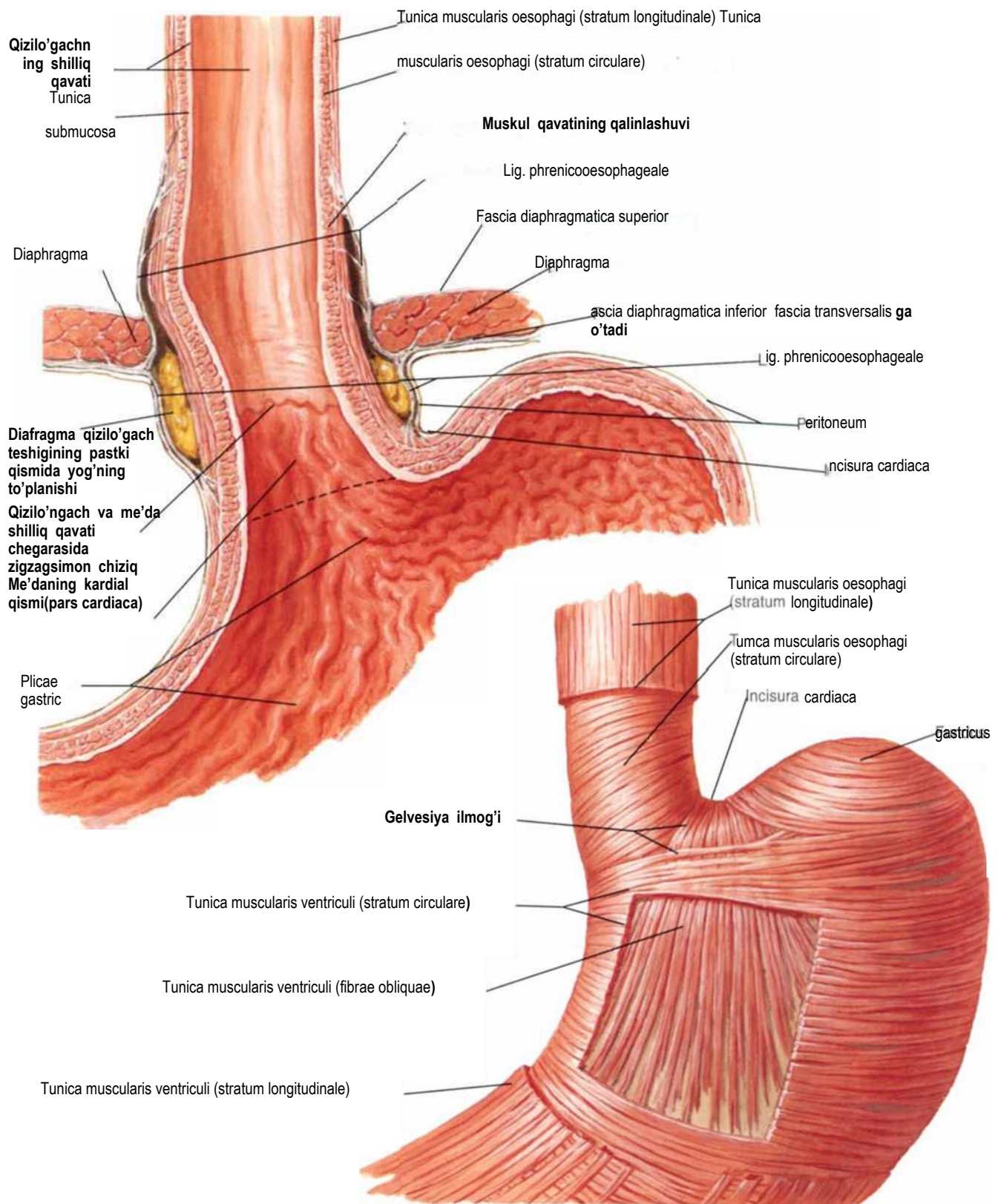


Halqumning qizilo'gachga o'tish qismi

61-rasm.

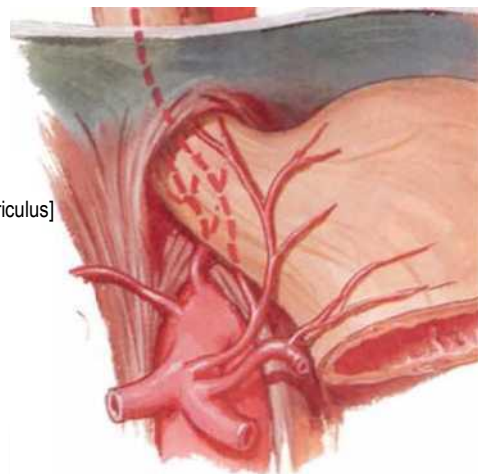
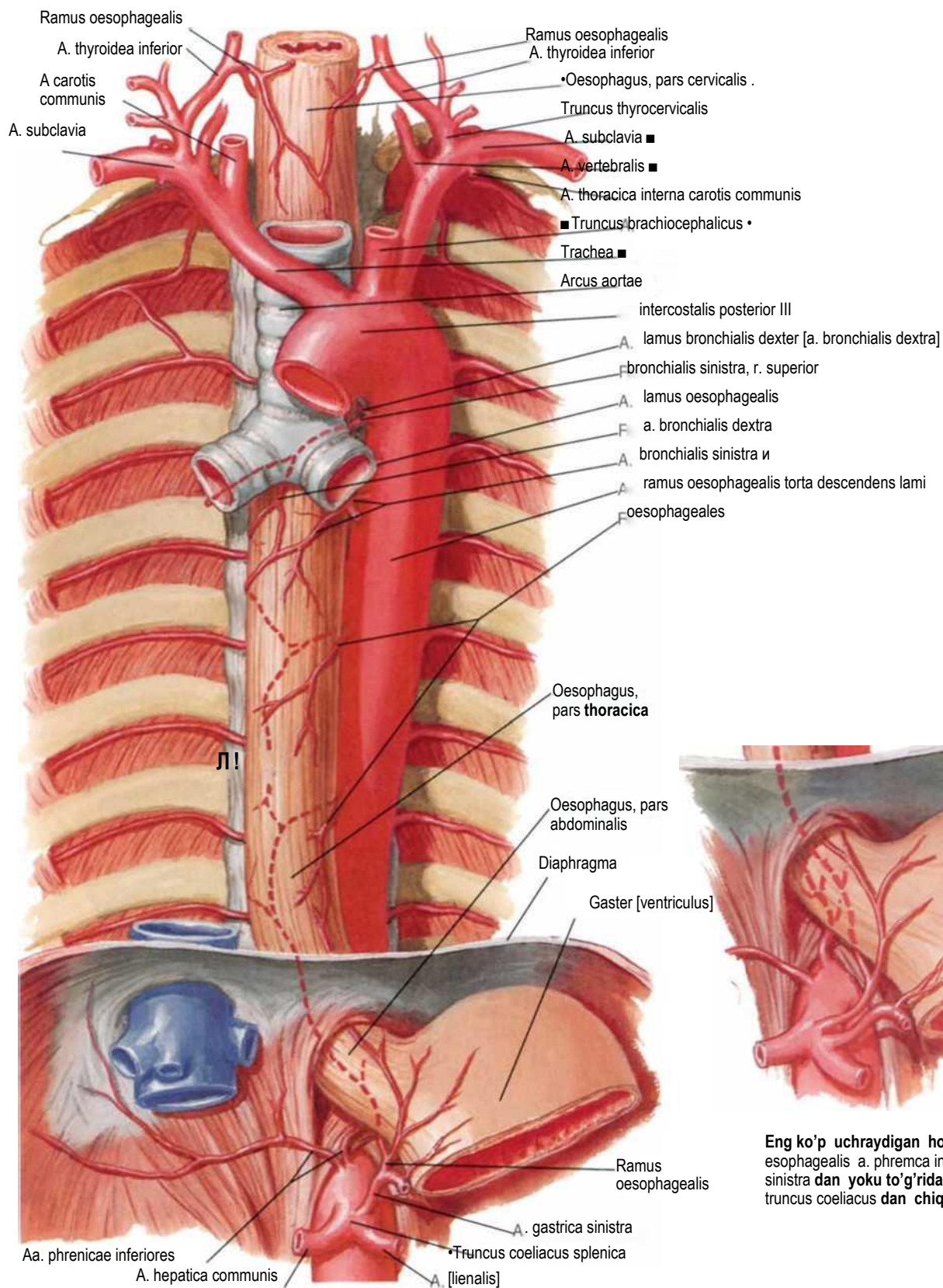


Qizilo'ngachdan me'daga o'tish qismi



Артерии пищевода

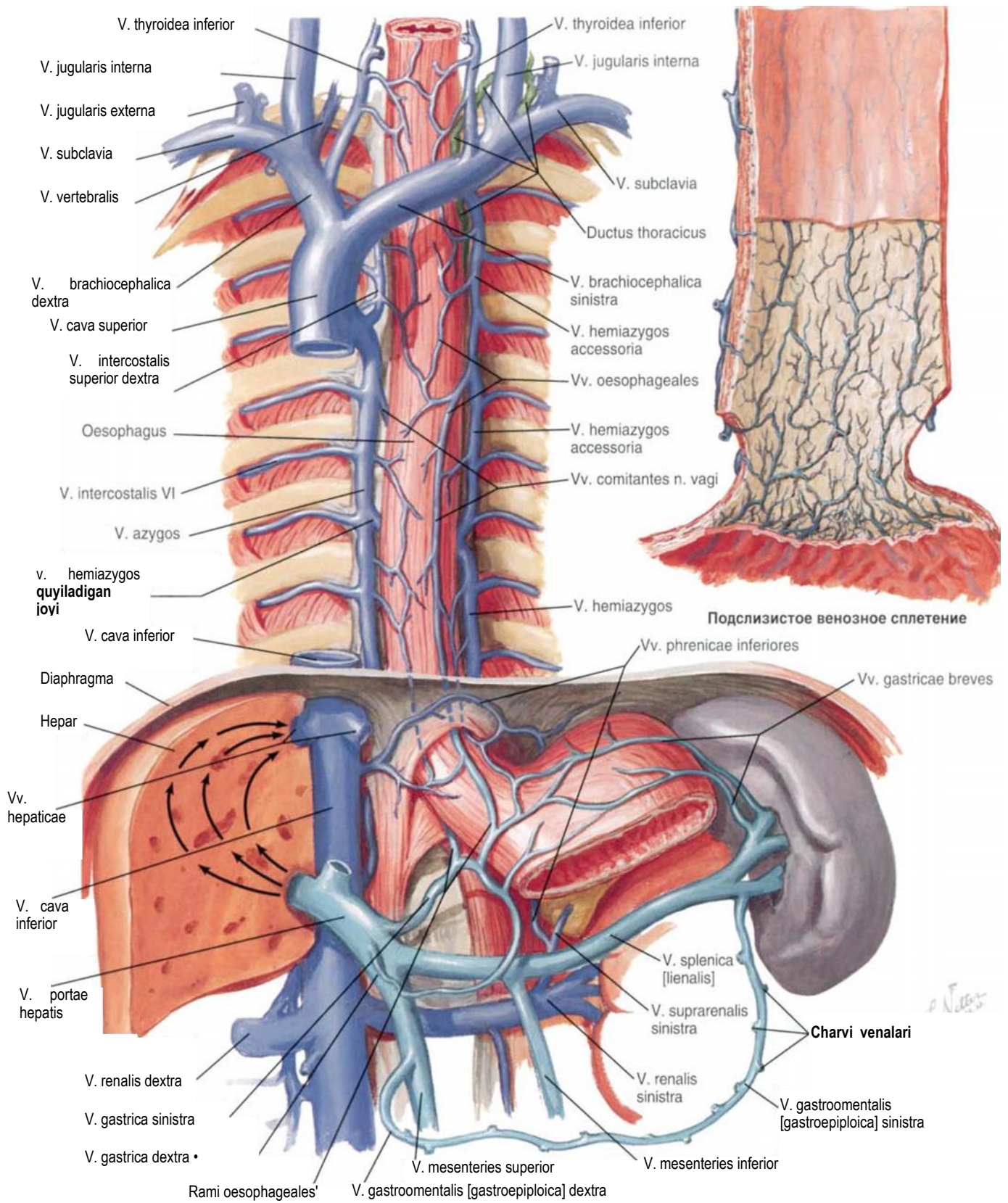
282. 283-rasmlar.



Eng ko'p uchraydigan holatlar: rami esophagealis a. phrenica inferior sinistra dan yoku to'g'ridan-to'g'ri truncus coeliacus dan chiqadi

Qizilo'ngach venalari

293-rasm.

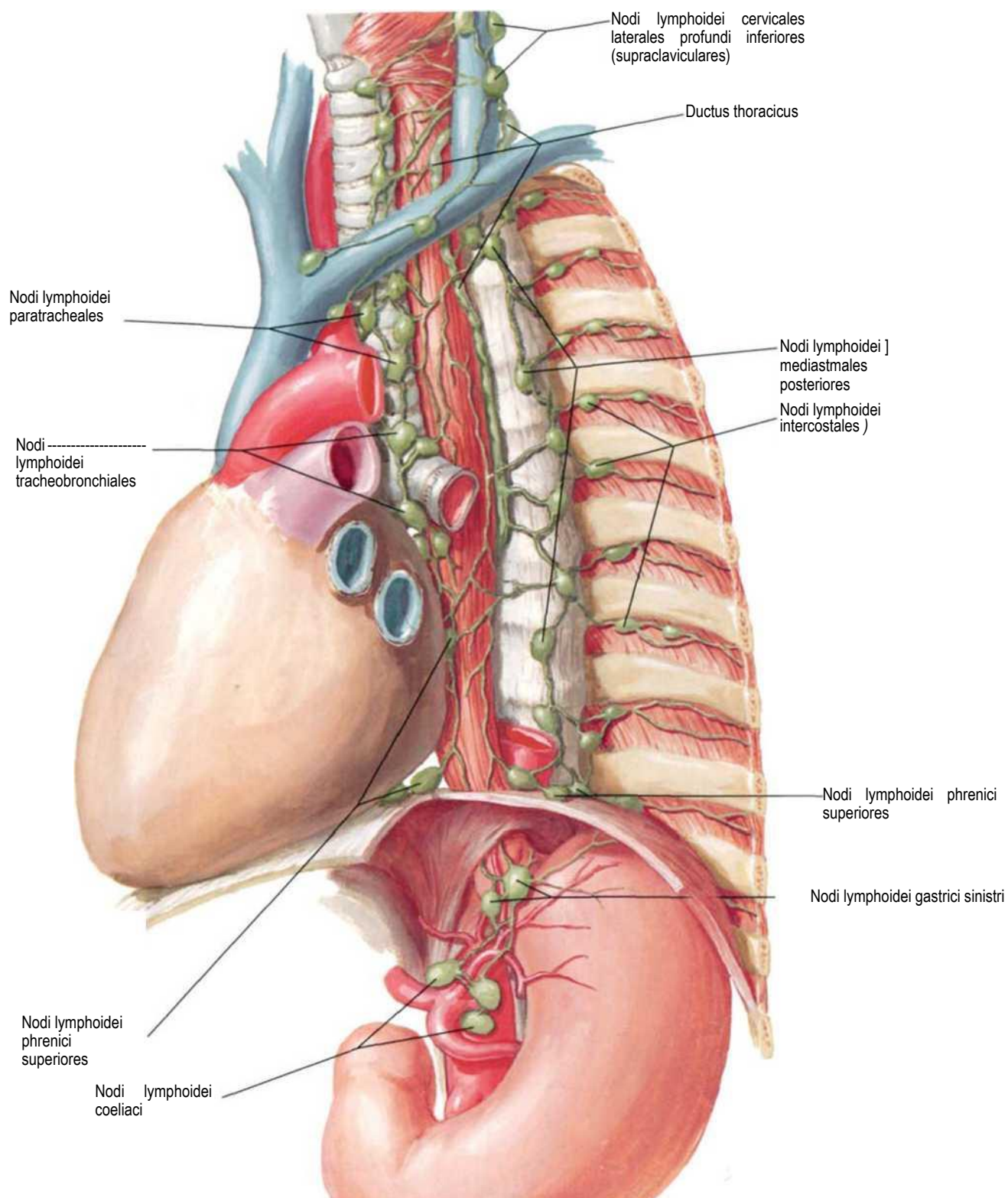


226-rasm

KO'KRAK QAFASI

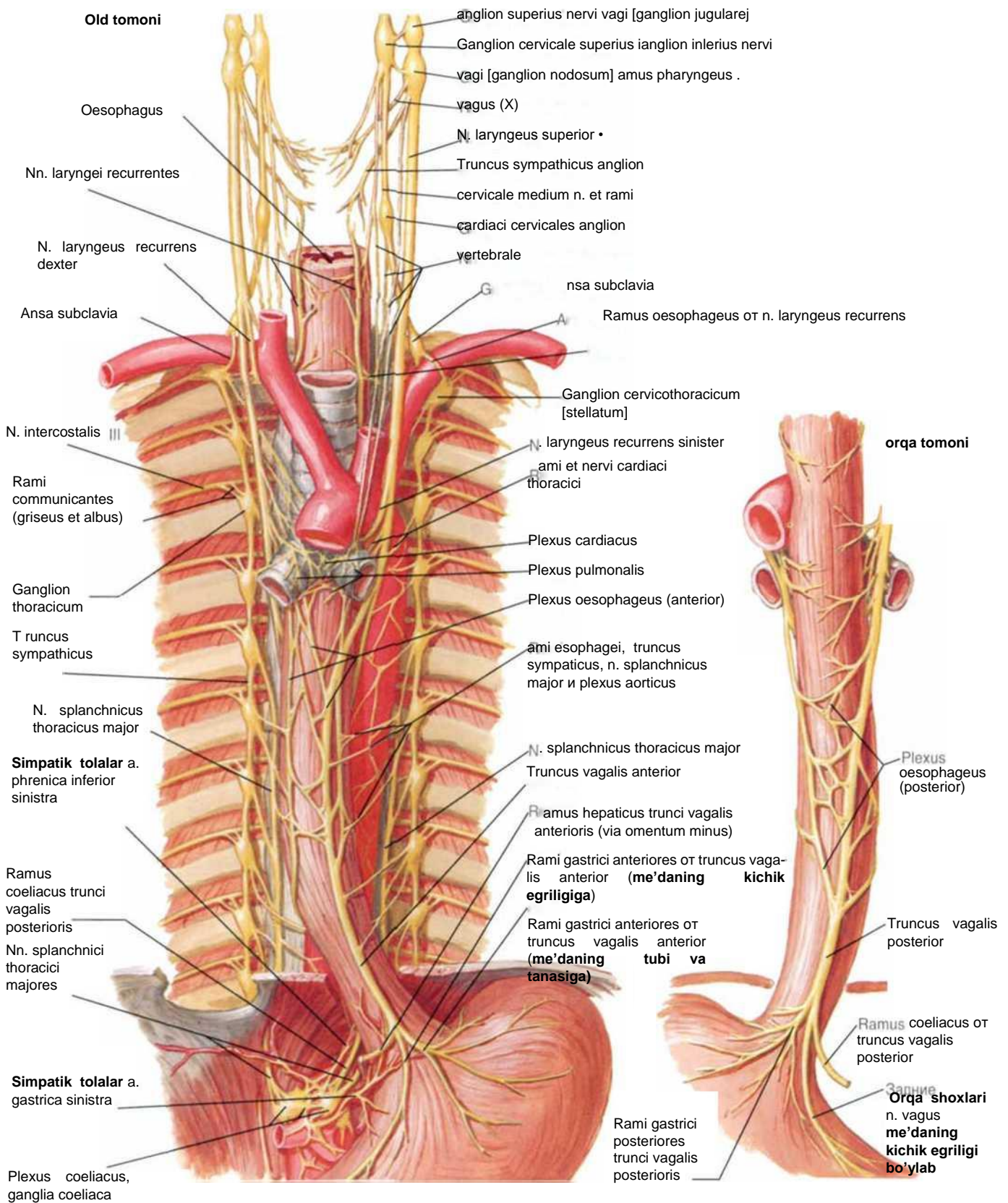
Qizilo'gachning limfatik tomirlari va tugunlari

197. 249-rasmlar.



Qizilo'ngach innervatsiyasi

152. 198-rasmlar.

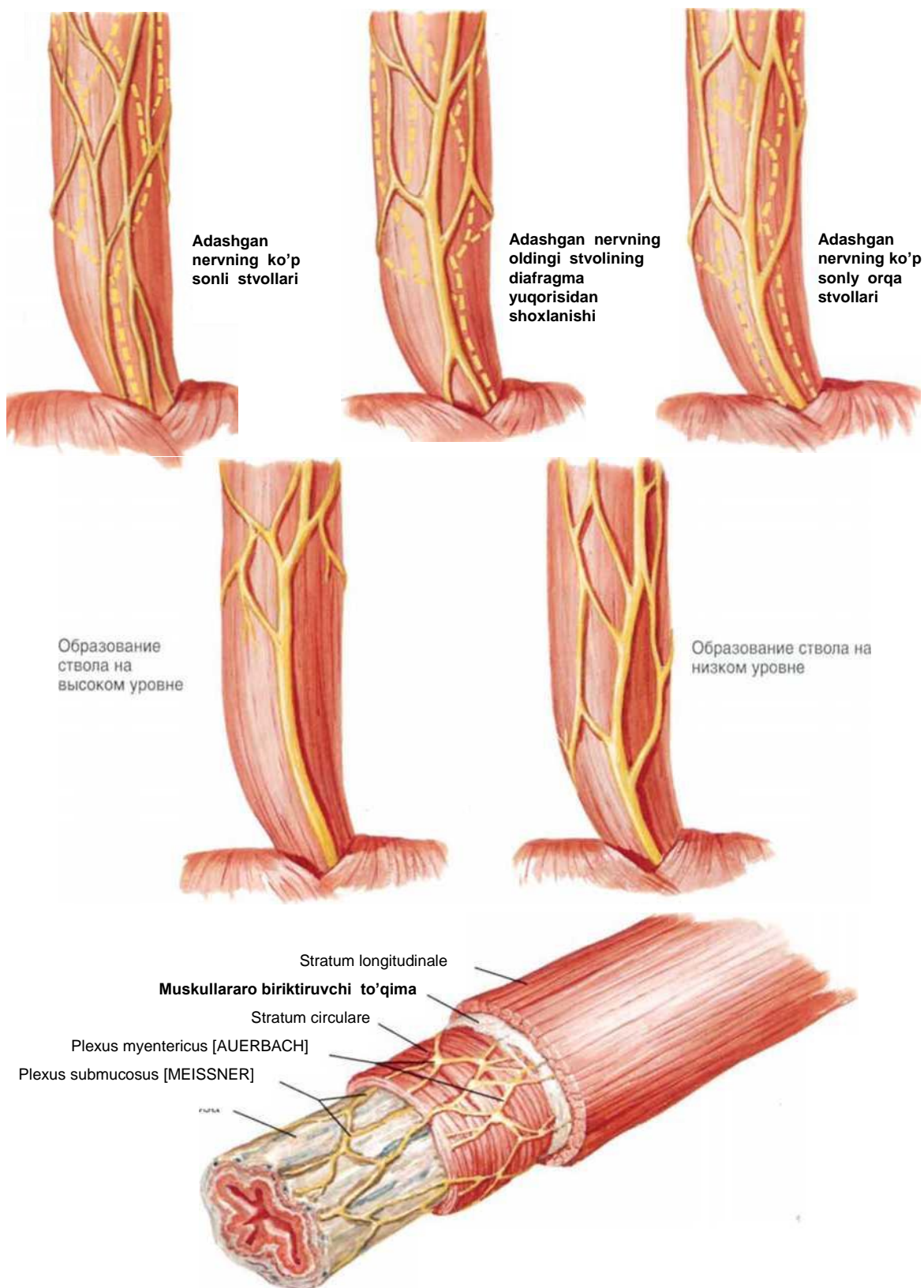


228-rasm

KO'KRAK QAFASI

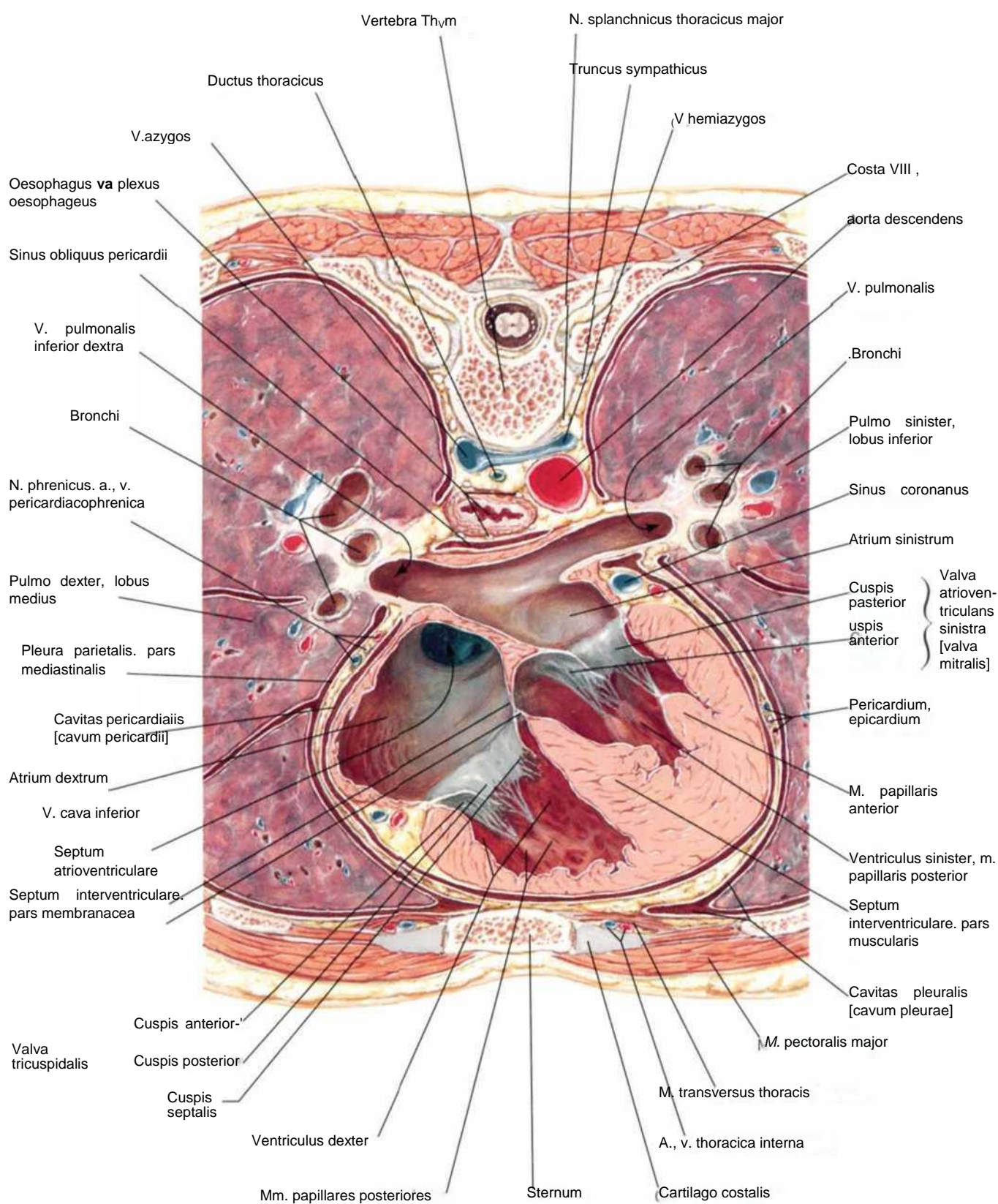
Qizilo'ngachning ichki nervlari va ularning turlari

Turlari



Ko'ks oralig'i (mediastinum), gorizontal kesim (yuqoridan ko'rinishi)

516-rasm.



230-rasm

KO'KRAK QAFASI

IV-bo'lim

QORIN

TANA

DEVORLARI

231-250rasm

- 231. Gavda suyaklari
- 232. Qorin oldingi devori: yuza qavati
- 233. Qorin oldingi devori: oraliq qavatlar
- 234. Qorin oldingi devori: chuqur qavatlar
- 235. Qorin to'g'ri muskulining qini: ko'ndalang kesimlar
- 236. Qorin oldingi devori: ichki tomoni
- 237. Qorin bo'shlig'ining yonbosh devori
- 238. Qorin oldingi devori arteriyalari
- 239. Qorin oldingi devori venalari
- 240. Qorin oldingi devori innervatsiyasi
- 241. Gavda devorlarining innervatsiyasi
- 242. Chov sohasi
- 243. Chov sohasi (davomi)
- 244. Chov kanali (canalis inguinalis)
- 245. Chov kanali (canalis inguinalis) va urug' yo'llari (funiculus spermaticus)

- 246. Qorin orqa devori: ichki tomoni
- 247. Qorin orqa devori arteriyalari
- 248. Qorin orqa devori venalari
- 249. Qorin orqa devori limfa tomirlari va tugunlari
- 250. Qorin orqa devori nervlari

QORIN BO'SHLIG'I

251-257rasm

- 251. Qorin sohasi, regiones abdominales. (satxlar va chiziqlar)
- 252. Katta charvi (omentum majus) va qorin bo'shlig'i a'zolari
- 253. Ichak tutqichi
- 254. Ichak tutqichi (davomi)
- 255. Charvi cho'ntagi (bursa omentalis)
- 256. Charvi cho'ntagi (bursa omentalis), ko'ndalang kesim
- 257. Qorin orqa devorining qorin pardasi

ICHKI A''ZOLAR

258-268rasm

- 258. Me'da (gaster [ventriculus])
- 259. Me'daning shilliq qavati
- 260. Me'daning muskul qavati
- 261. O'n ikki barmoqli ichak(duodenum)
- 262. O'n ikki barmoqli ichak (duodenum): qavatlari
- 263. Ingichka ichak (intestinum tenue)
- 264. Ileosekal sohasi
- 265. Ileosekal sohasi(davomi)
- 266. Chuvalchangsimon o'simta (appendix vermiformis)
- 267. Yo'g'on ichak (intestinum crasum): muskul va shilliq qavati
- 268. Sigmasimon ichak (colon sigmoideum): joylashish turlari

QORIN BO'SHLIG'I A'ZOLARI

269-281rasm

- 269. Jigar (hepar): topografiyasi
- 270. Jigar (hepar): yuzalari
- 271. Jigar (hepar): shaklining turlari
- 272. Jigar bo'lagi va segmentlari: tomirlar va yo'llarning taqsimlanishi
- 273. Jigar ichi tomirlari va yo'llari
- 274. Jigarining tuzilishi: sxemasi
- 275. Jigar ichidagi o't suyuqligi ajratish tizimi: sxemasi
- 276. O't pufagi (vesica fellea [biliaris]) va jigardan tashqarida joylashgan o't yo'llari
- 277. O't pufagi va o't yo'llari tuzilishining turlari
- 278. Umumiy o't yo'lining o'n ikki barmoq ichak bilan birikishi (ductus choledochus)
- 279. Me'da osti bezi (pancreas)
- 280. Me'da osti bezi yo'llarining tuzilishi turlari
- 281. Taloq (splen [lien])

ICHKI A'ZOLARNING QON BILAN TA'MINLANISHI

282-299rasm

- 282. Me'da,jigar va taloq arteriyalari
- 283. Me'da,o'n ikki barmoq ichak,me'da osti bezi va taloq arteriyalari

- 284. Jigar, o'n ikki barmoq ichak,me'da osti bezi va taloq arteriyalari
- 285. Me'da osti bezi boshchasi va o'n ikki barmoq ichak arteriyasi
- 286. Ingichka ichak arteriyasi
- 287. Yo'g'on ichak arteriyasi
- 288. Jigar va o't pufagining kollateral qon bilan ta'minlanishi va arteriyalarining yo'llari
- 289. Chambar ichak arteriyasi (arteriae colicae)
- 290. Me'da, o'n ikki barmoq ichak,me'da osti bezi va taloq venalari
- 291. Ingichka ichak venalari
- 292. Yo'g'on ichak venalari
- 293. Darvoza venasi (vena portae) va porto-koval anastomozlar
- 294. Darvoza venasining hosil bo'lishi
- 295. Me'daning limfa tomirlari va tugunlari
- 296. Ingichka ichak limfa tomirlari va tugunlari
- 297. Yo'g'on ichak limfa tomirlari va tugunlari
- 298. Jigar limfa tomirlari va tugunlari
- 299. Me'da osti bezi limfa tomirlari va tugunlari

ICHKI A''ZOLAR INNERVATSIYASI

300-310rasm

- 300. Qorin bo'shlig'ining vegetativ nervlari va gangliylari
- 301. Me'da va o'n ikki barmoq ichak innervatsiyasi
- 302. Me'da va o'n ikki barmoq ichak innervatsiyasi (davomi)
- 303. Me'da va o'n ikki barmoq ichak innervatsiyasi (sxemasi)
- 304. Ingichka ichak innervatsiyasi
- 305. Yo'g'on ichak innervatsiyasi
- 306. Ingichka va yo'g'on ichak innervatsiyasi: sxemasi
- 307. Vegetativ reflektor yo'ylar: sxemasi
- 308. Ichaklar nerv chigallari: sxemasi
- 309. Jigar va o't yo'llari innervatsiyasi: sxemasi

310. Me'da osti bezi innervatsiyasi: sxemasi

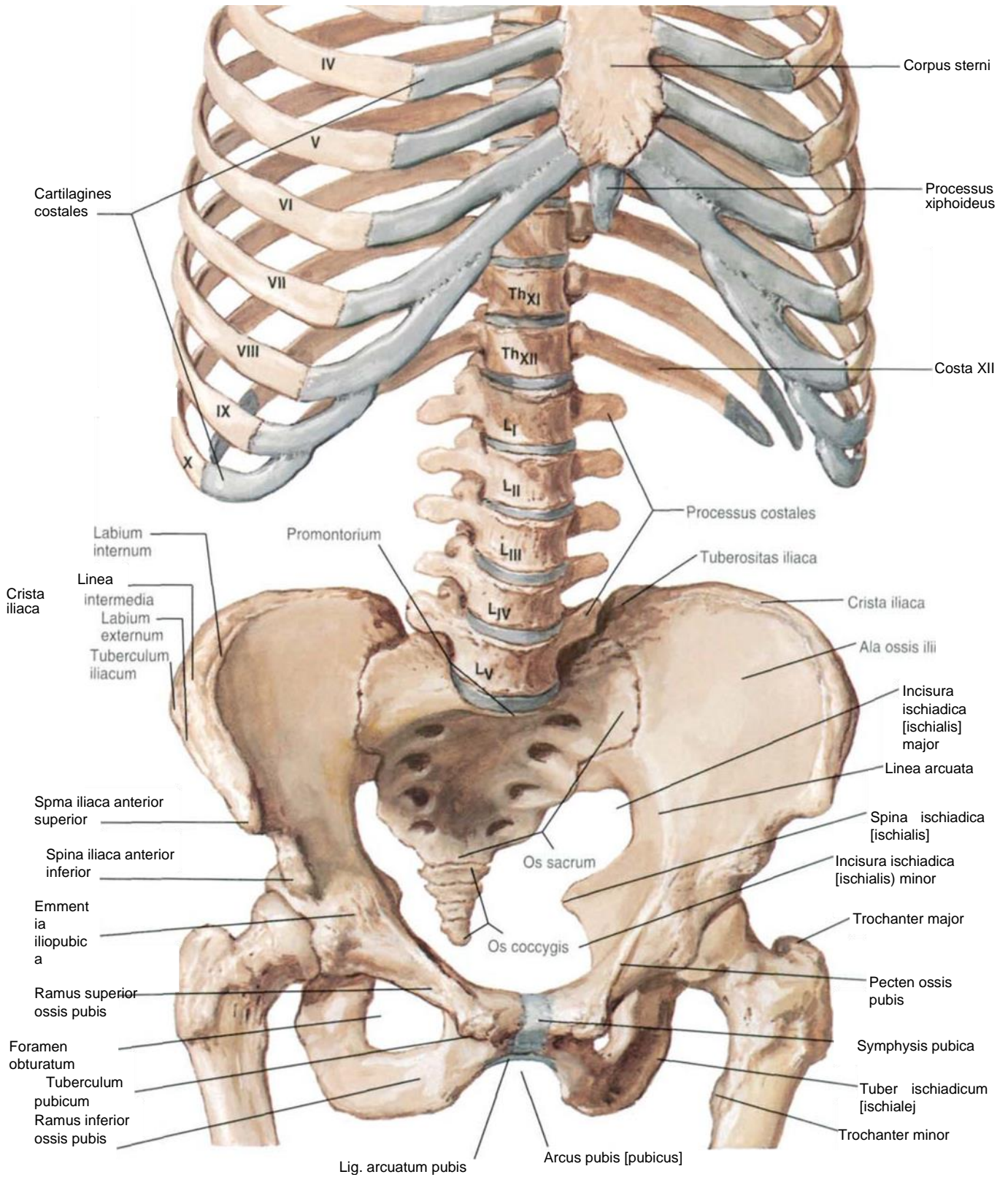
**BUYRAK VA BUYRAK USTI
BEZLARI**

311-329rasm

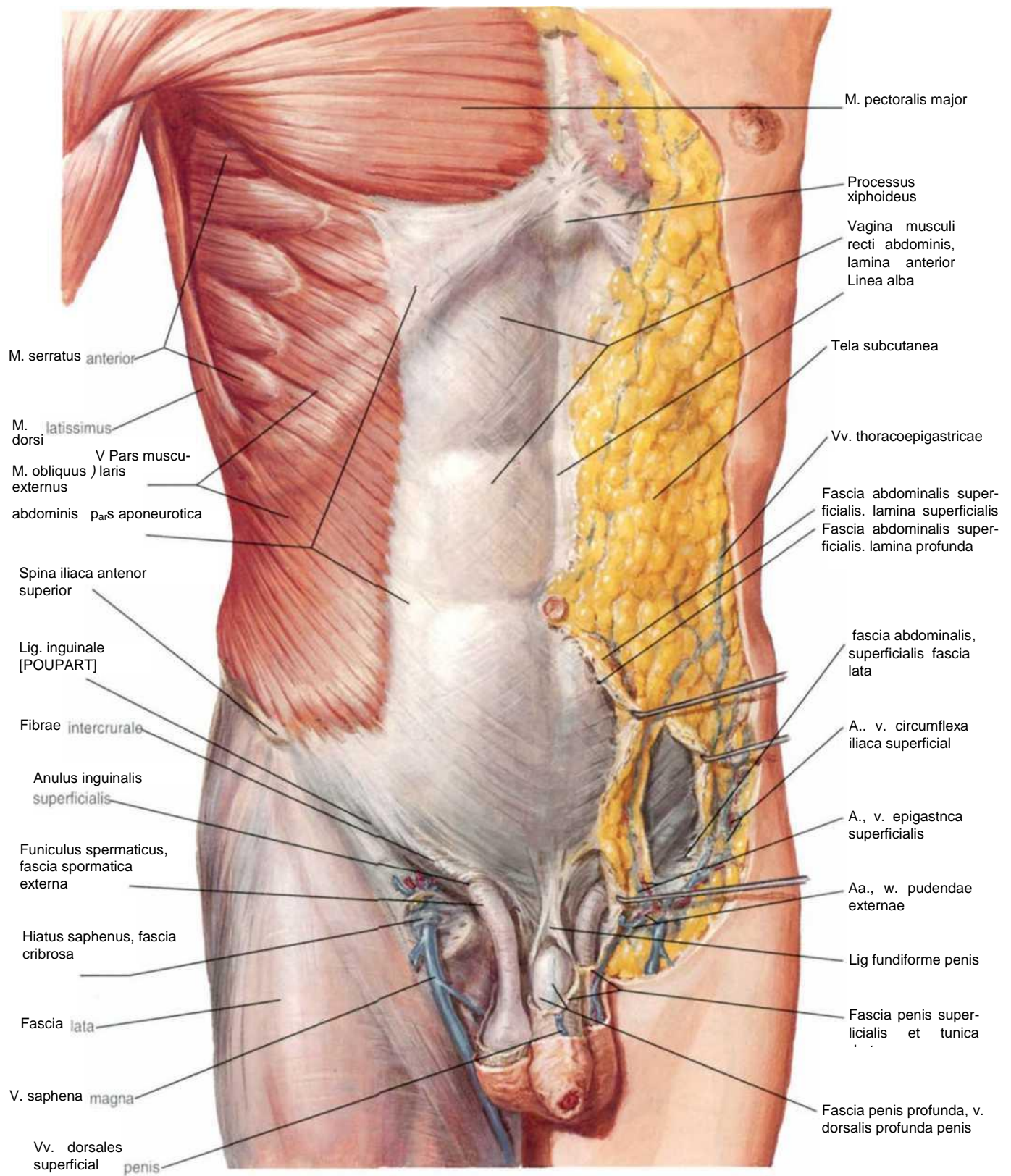
- 311. Buyraklar (ren): old tomondan ko'rinishi
- 312. Buyraklar (ren): orqa tomoni
- 313. Buyraklarning makrostrukturasi
- 314. Buyraklarning arteriya va venalari
- 315. Buyrakichi arteriyalari va segmentlari
- 316. Buyraklarning arteriya va vena turlari
- 317. Nefron va yig'uvchi naychalar:sxemasi
- 318. Buyrak parenximasi
qon-tomirlari:sxemasi

- 319. Siydik naylari (ureter)
- 320. Siydik nayi va siydik pufagi arteriyalari
- 321. Buyrak va siydik pufagining limfa
tomirlari va tugunlari
- 322. Buyraklar,siydik nayi va siydik
pufagining innervatsiyasi
- 323. Buyraklar innervatsiyasi: sxemasi
- 324. Buyraklar fassiyasi (fascia renalis)
- 325. Buyrak usti bezlarining arteriya va
venalari
- 326. Buyrak usti bezlarining innervatsiyasi
- 327. Qorin bo'shlig'ining ko'dalang kesimi
Thxii (yuqoridan ko'rinishi)
- 328. Qorin bo'shlig'ining ko'dalang kesimi
Lq Lqy (yuqoridan ko'rinishi)
- 329. Qorin bo'shlig'ining sagittal kesimi

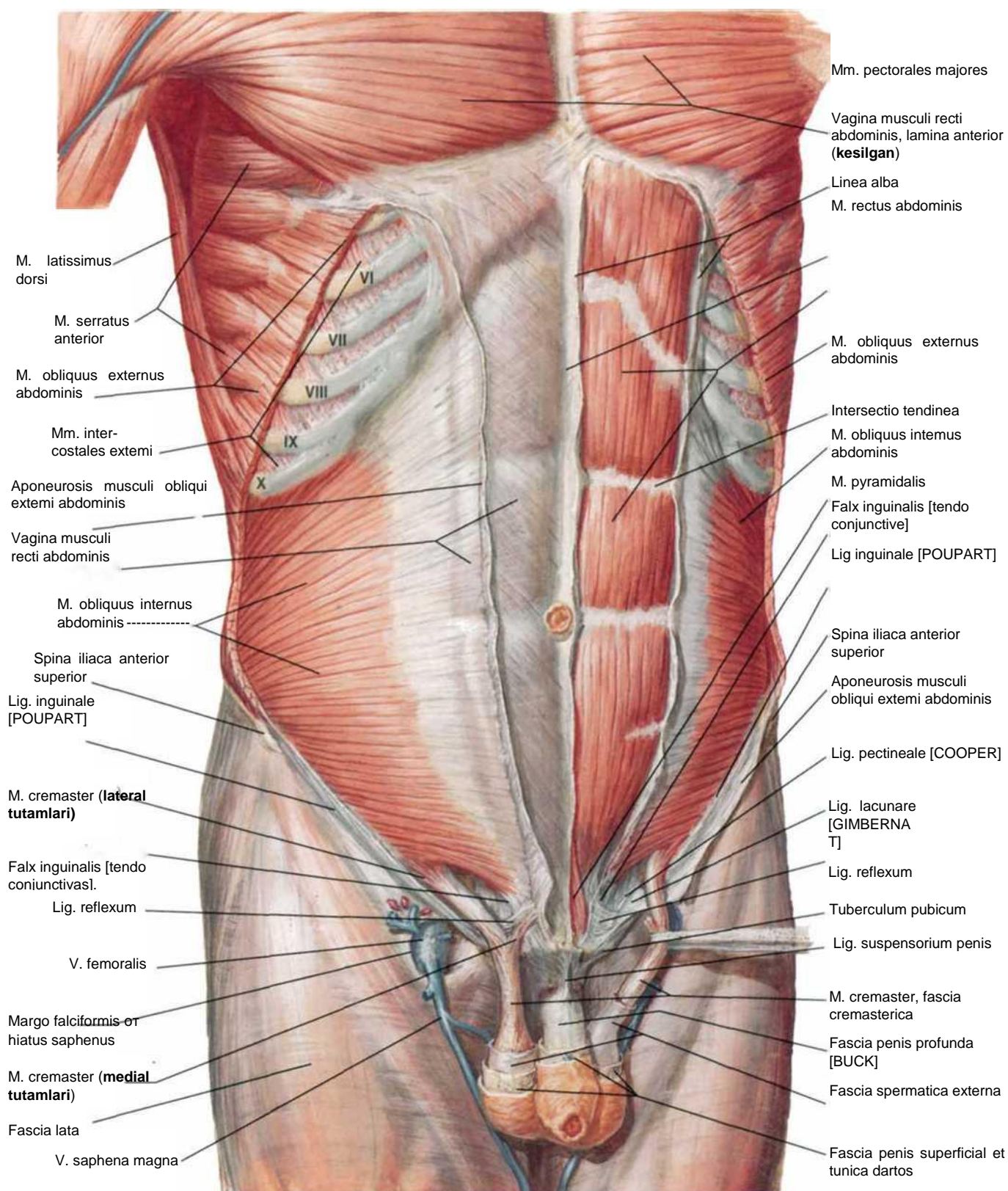
Gavda suyaklari



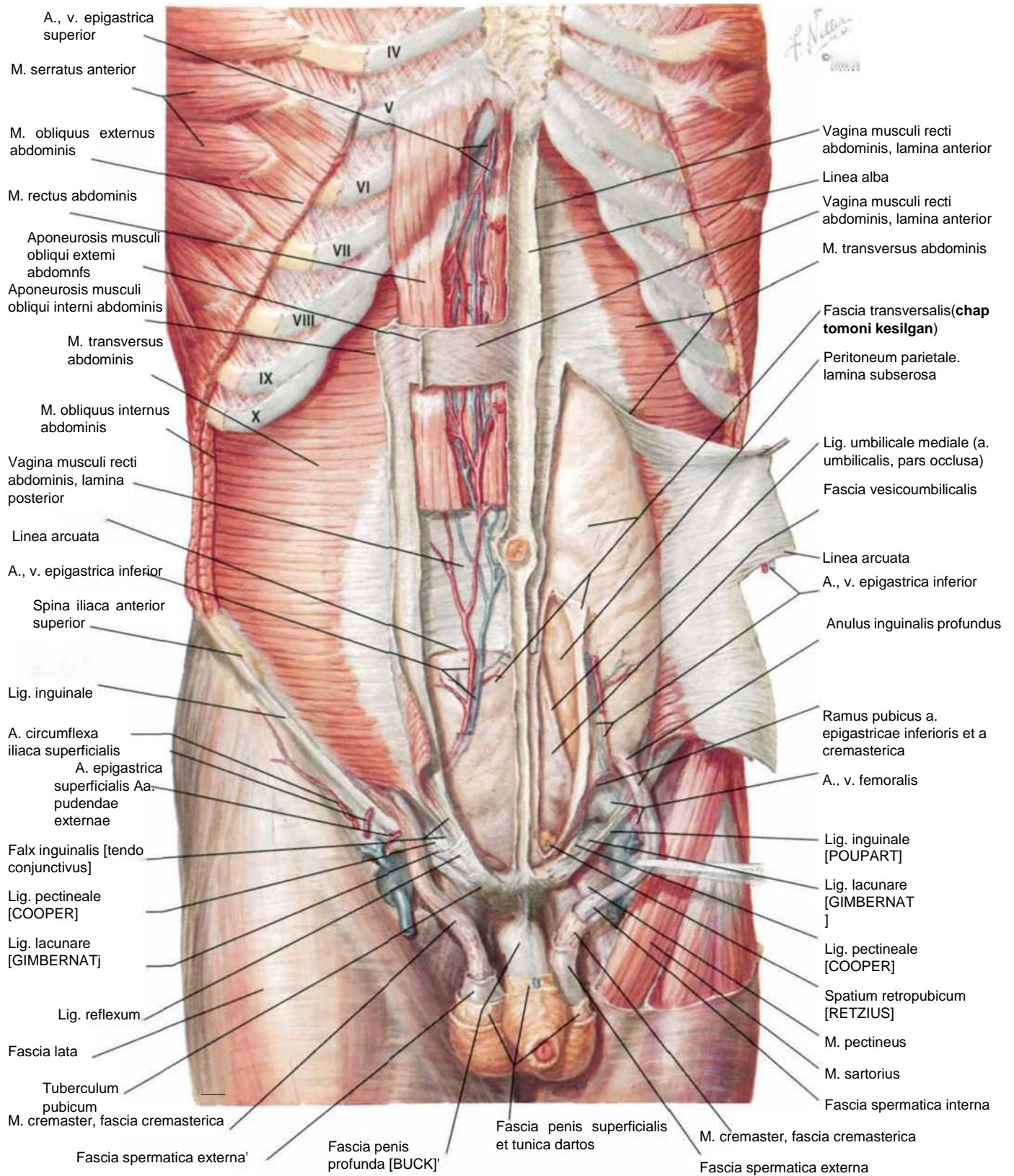
Oldingi qorin devori: yuza qavat



Oldingi qorin devori: oraliq qavati

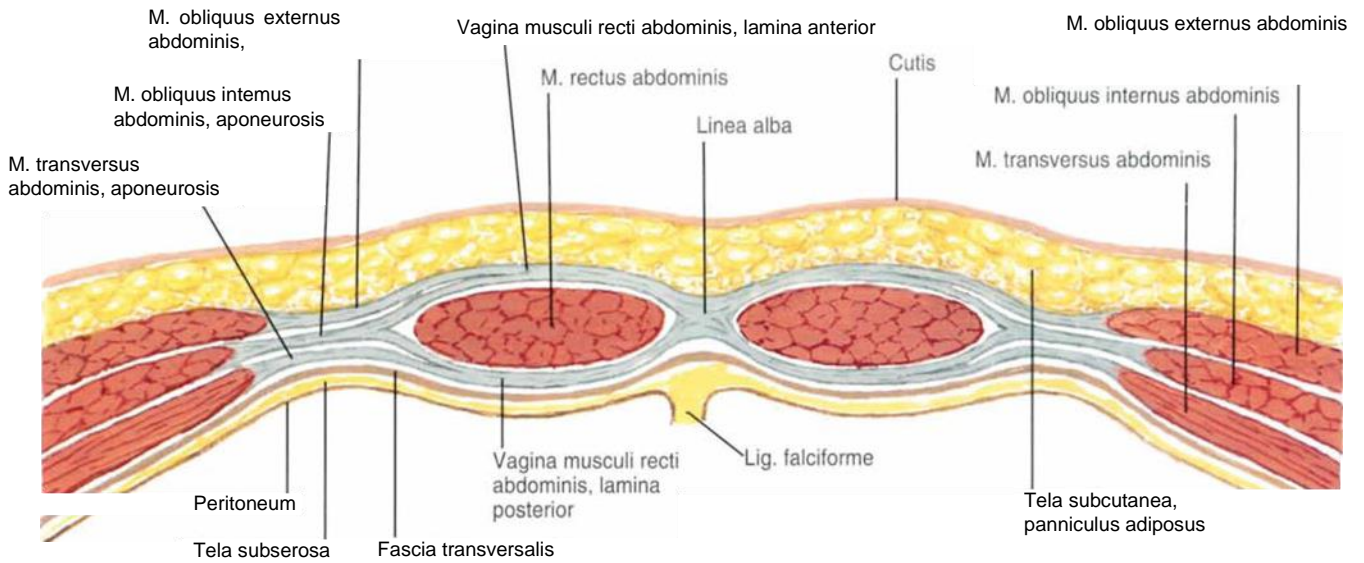


Oldingi qorin devori: chuqur qavati



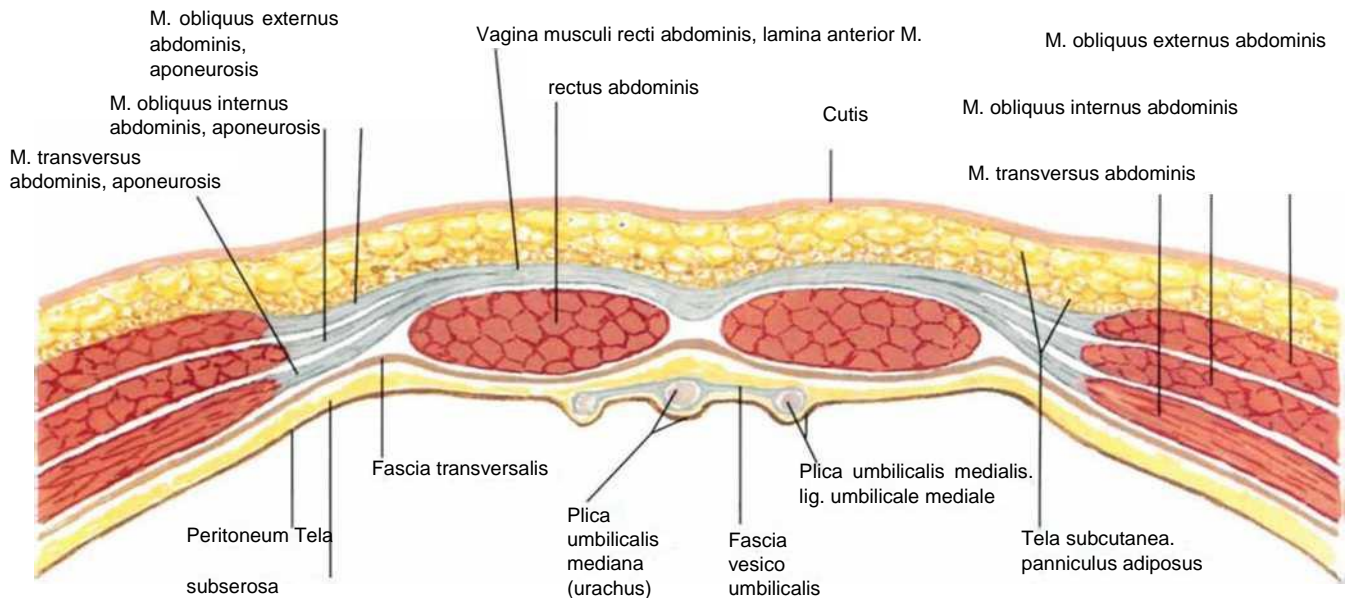
Qorin to'g'ri muskulining qini: ko'ndalang kesimi

Kesim linea arcuata dan yuqorida



Qorin qiyshiq muskulining aponevrozi 2ta plastinkaga ajraladi;ular qorin to'g'ri muskulini oldidan va orqasidan o'rab turadi.Shunday qilib,qorin to'g'ri muskuli qinining oldingi devorinitashqi qiyshiq muskul aponevrozi va ichki qiyshiq muskul aponevrozining oldingi qismi tashkil etadi,orqa devorini esa ichki qiyshiq muskulning aponevrozining orqa plastinkasi va qorinning ko'ndalang muskuli aponevrozi tashkil etadi. Ana shu hamma aponevrozlarning birikish chizig'i esa linea alba ni hosil qiladi.

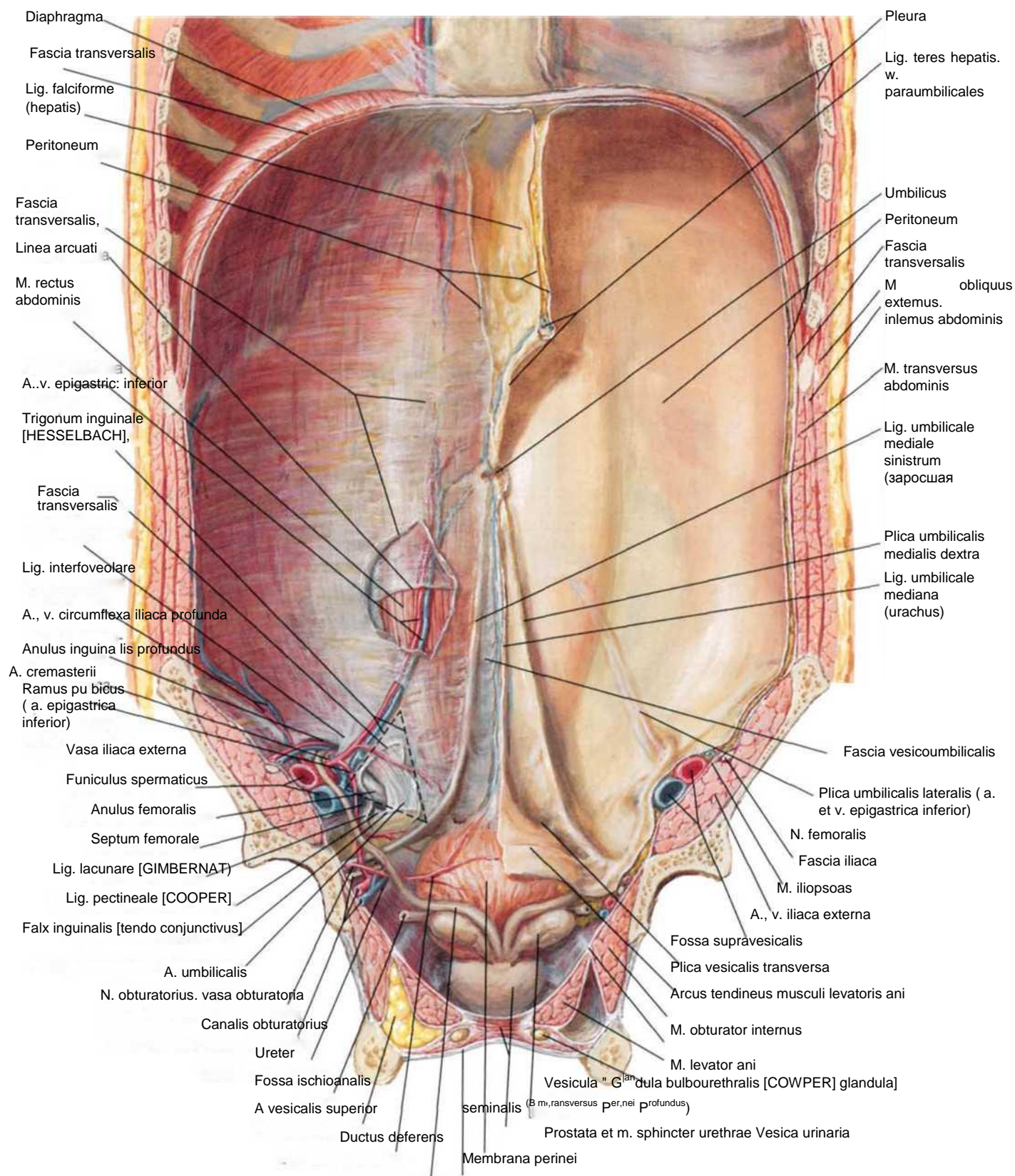
linea arcuata dan pastdagi kesim



linea arcuata dan pastda qorin tashqi va ichki qiyshiq muskullarining aponevrozlari ko'ndalang muskul aponevrozi bilan birgalikda qorin to'g'ri muskuli qinining oldingi devorini hosil qiladi. Qin orqa devorini esa faqat ko'dalang fassiya hosil qiladi.

Qorin bo'shlig'ining oldingi devori: ichki tomoni

217-rasm.

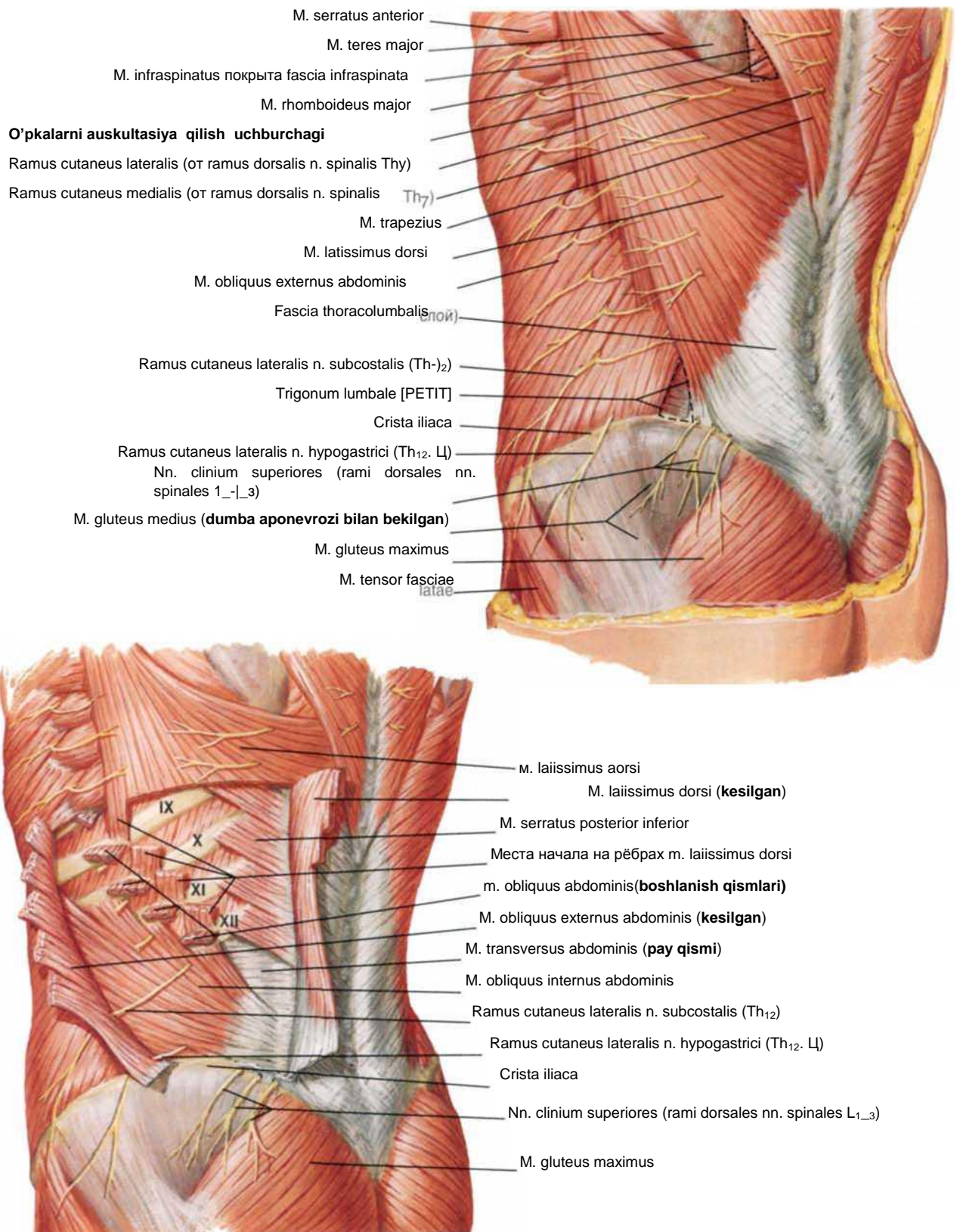


236-rasm

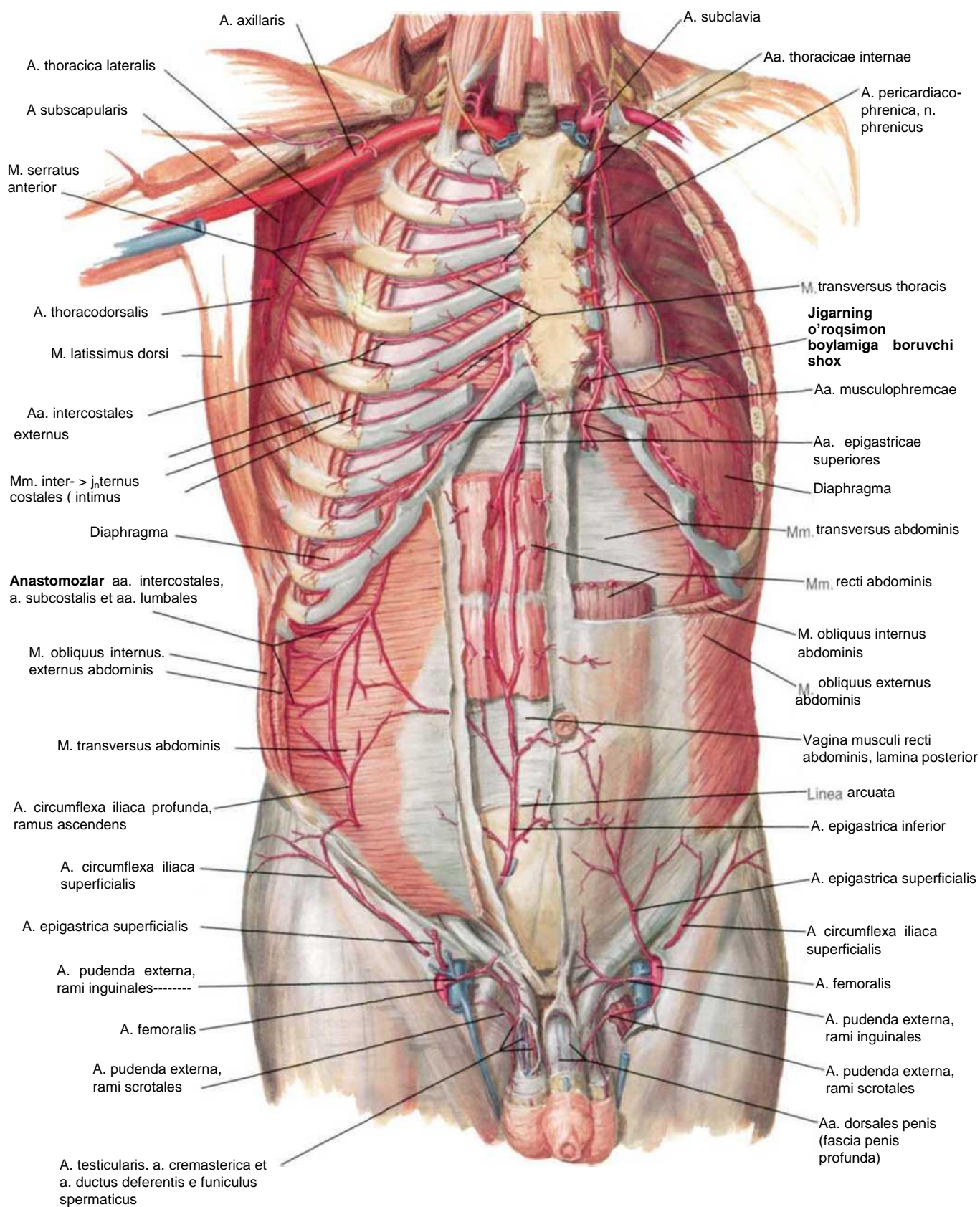
QORIN

Qorin bo'shlig'ining yonbosh devori

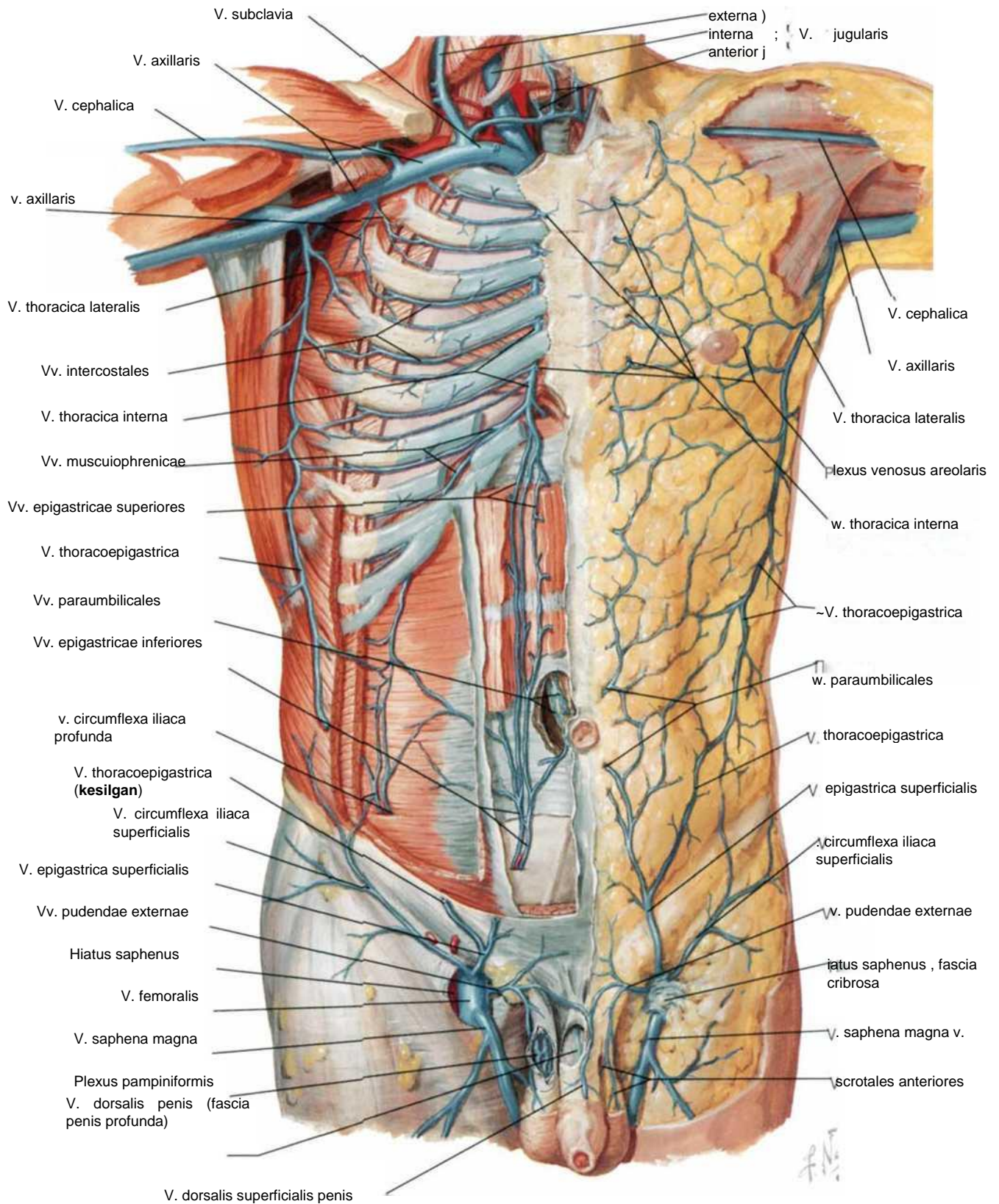
160. 163. 165. 166. 241-rasm.



Oldingi qorin devori arteriyalari

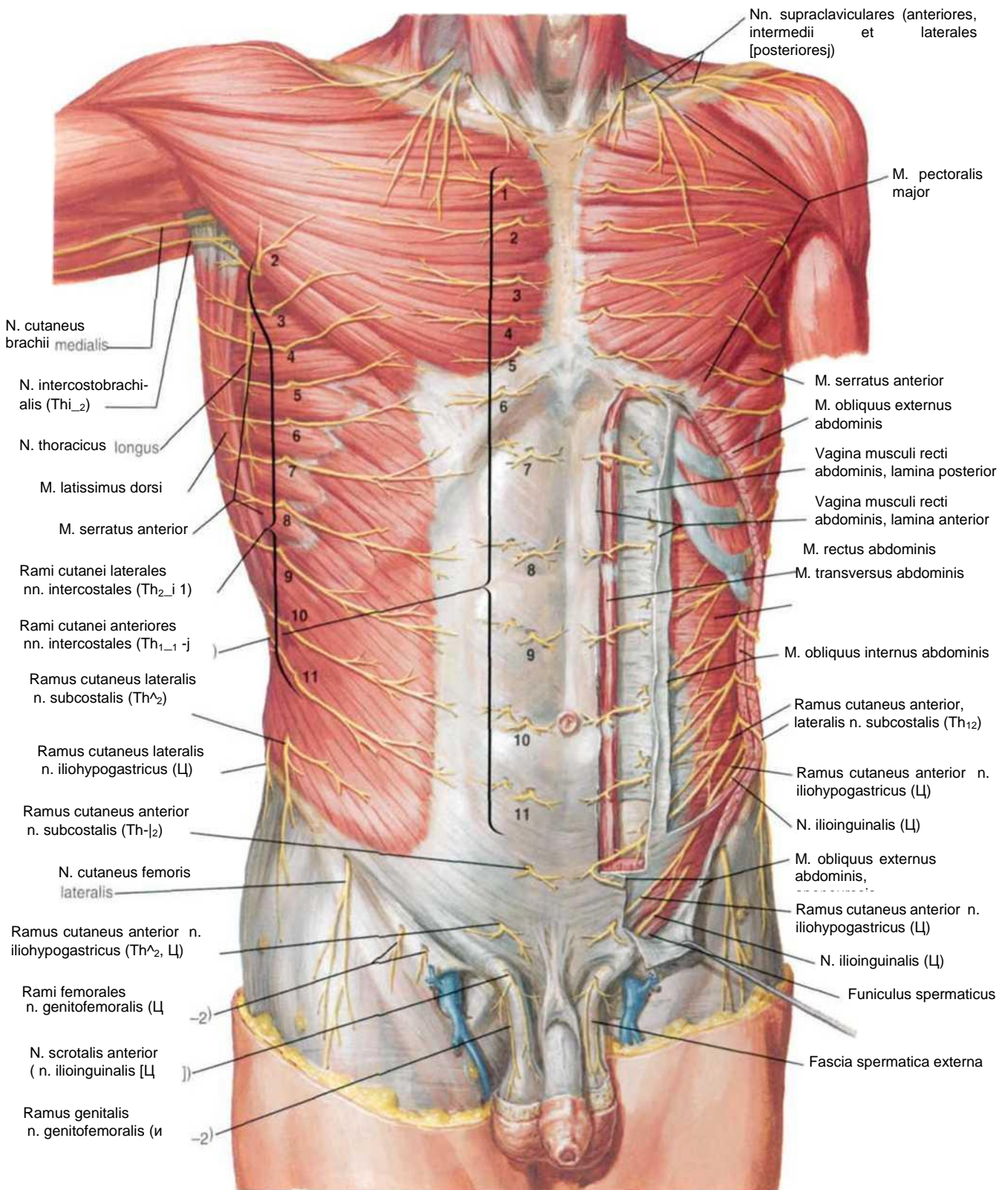


Qorin oldingi devori venalari



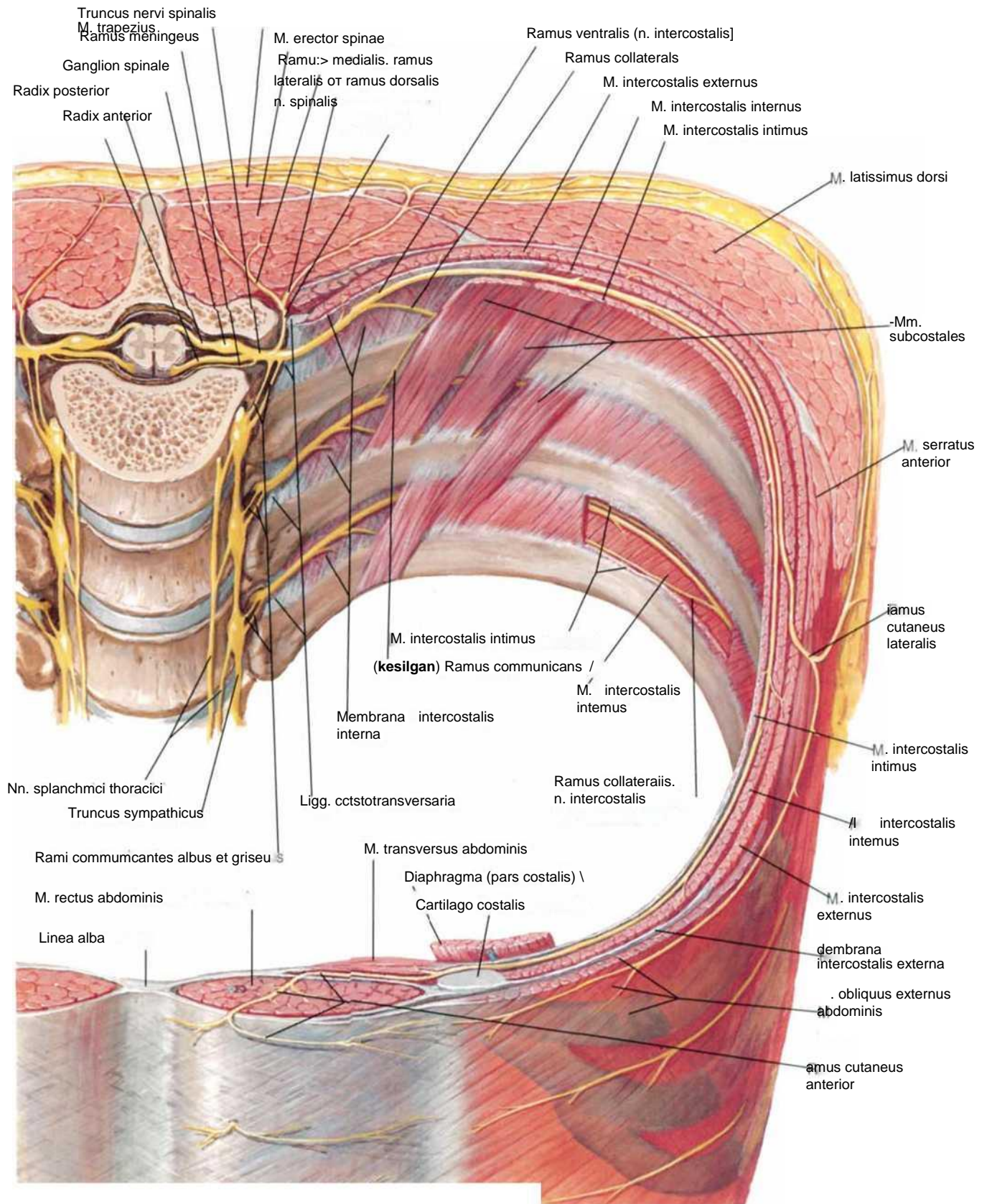
Oldingi qorin devori innervatsiyasi

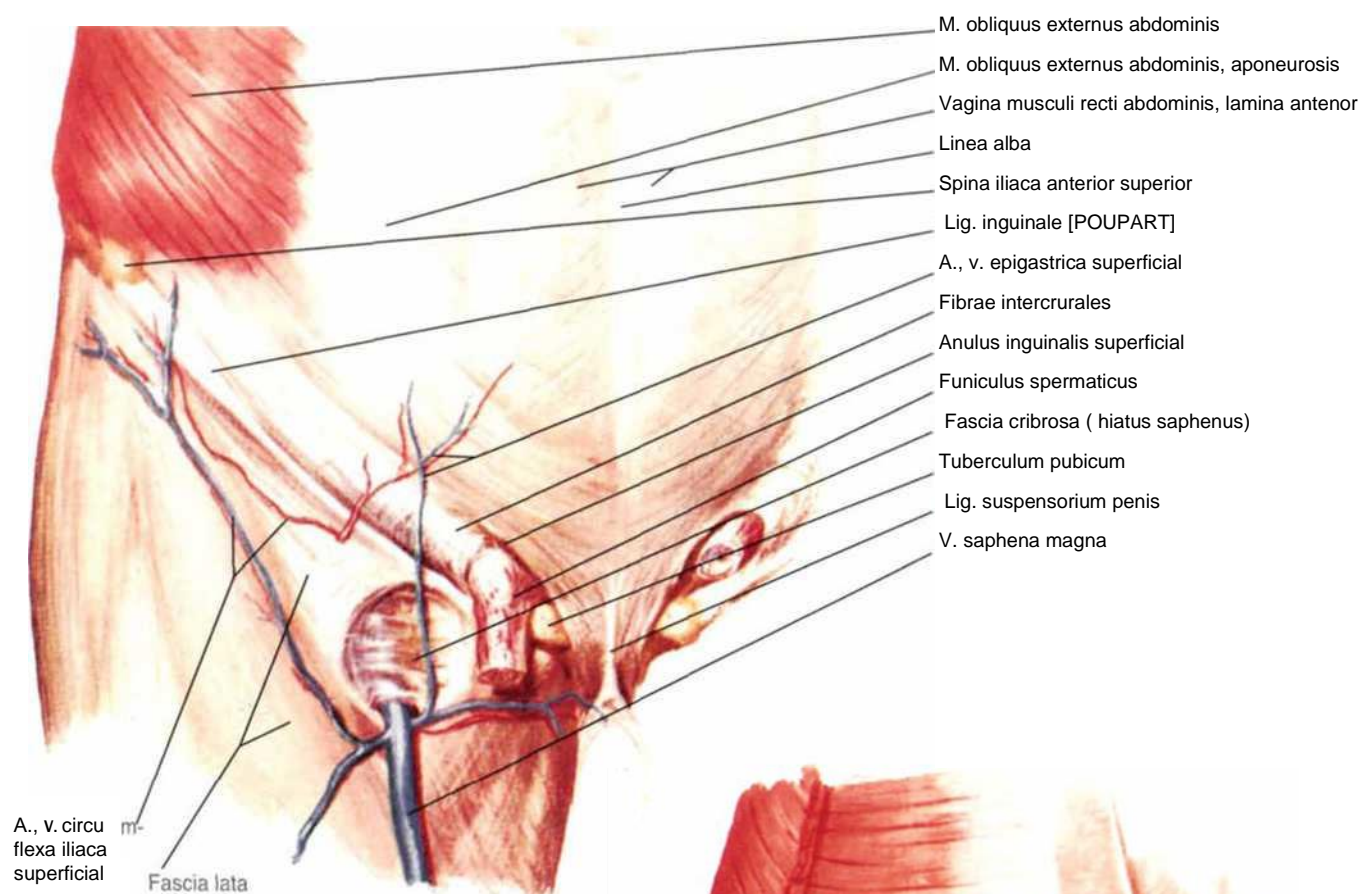
163. 237. 250. 464-rasmlar.



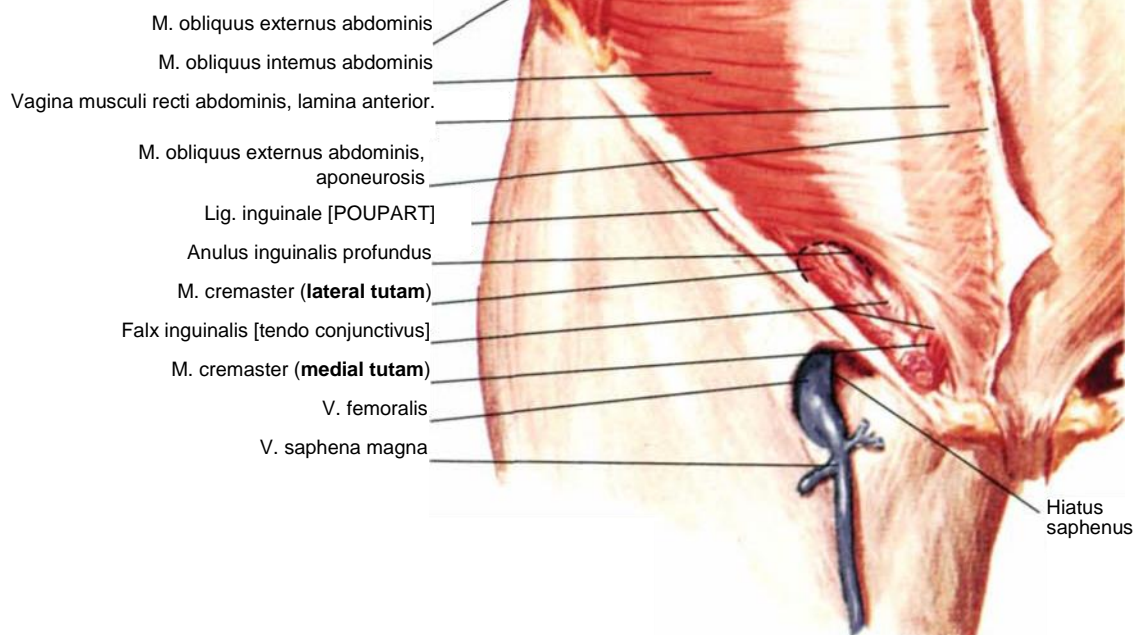
Tana devorlari innervatsiyasi

166. 179-rasmlar.

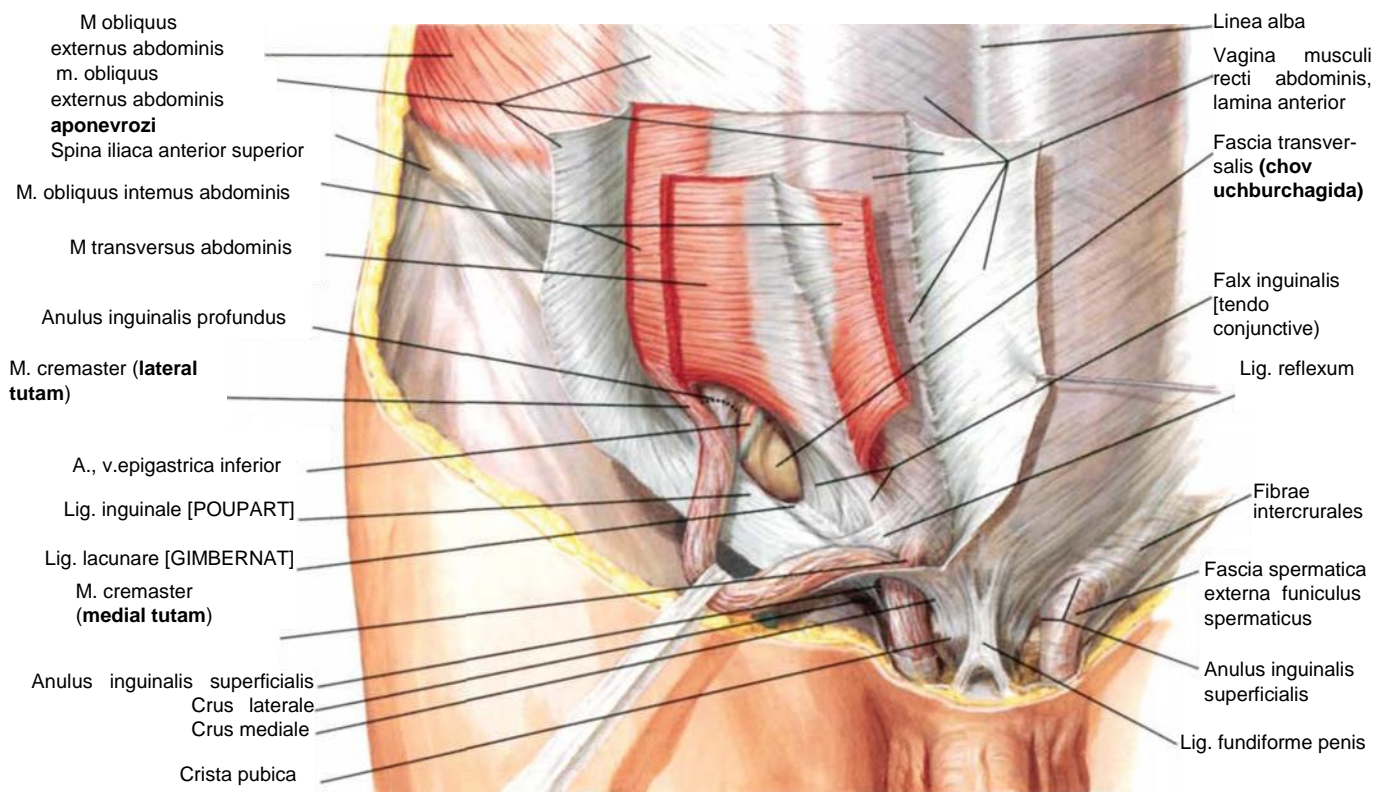




Teri va teri osti yog' qavati olingan

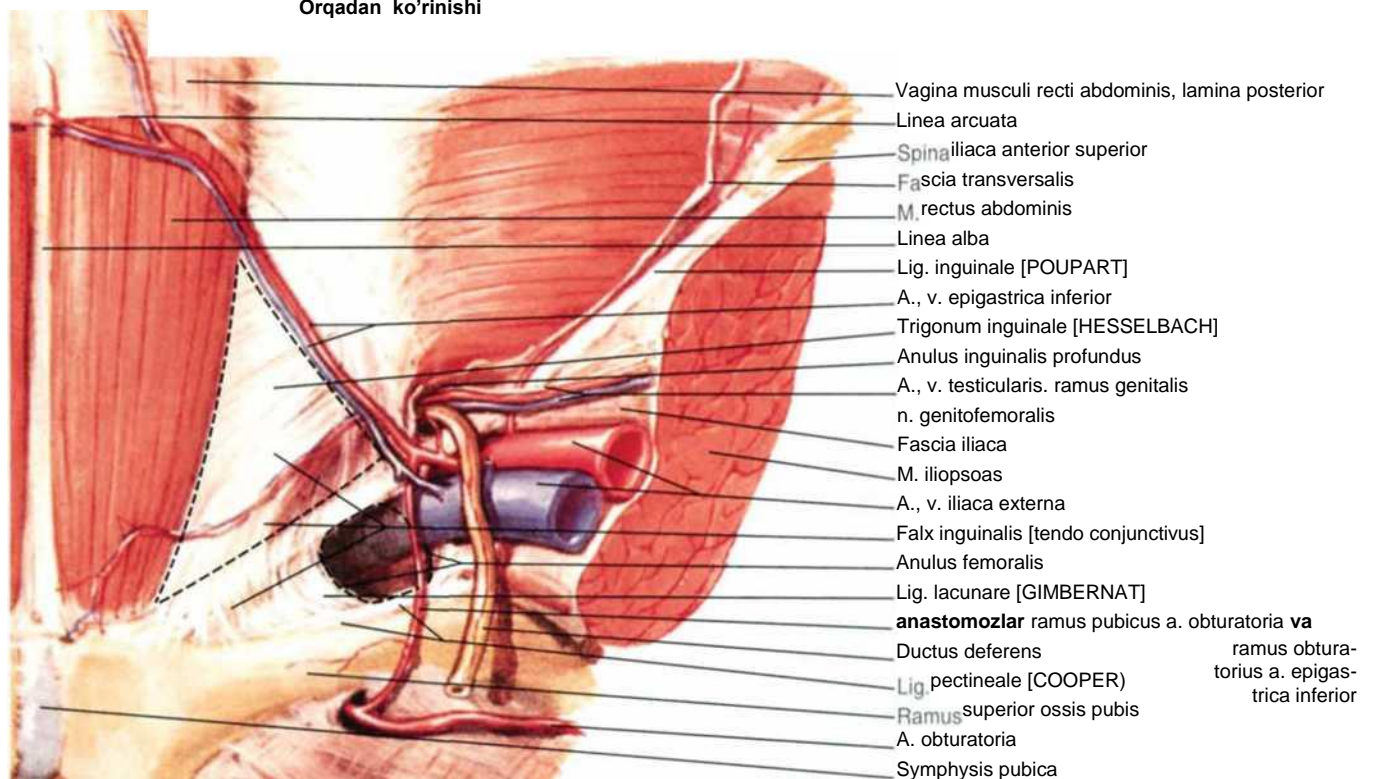


Chov sohasi (davomi)

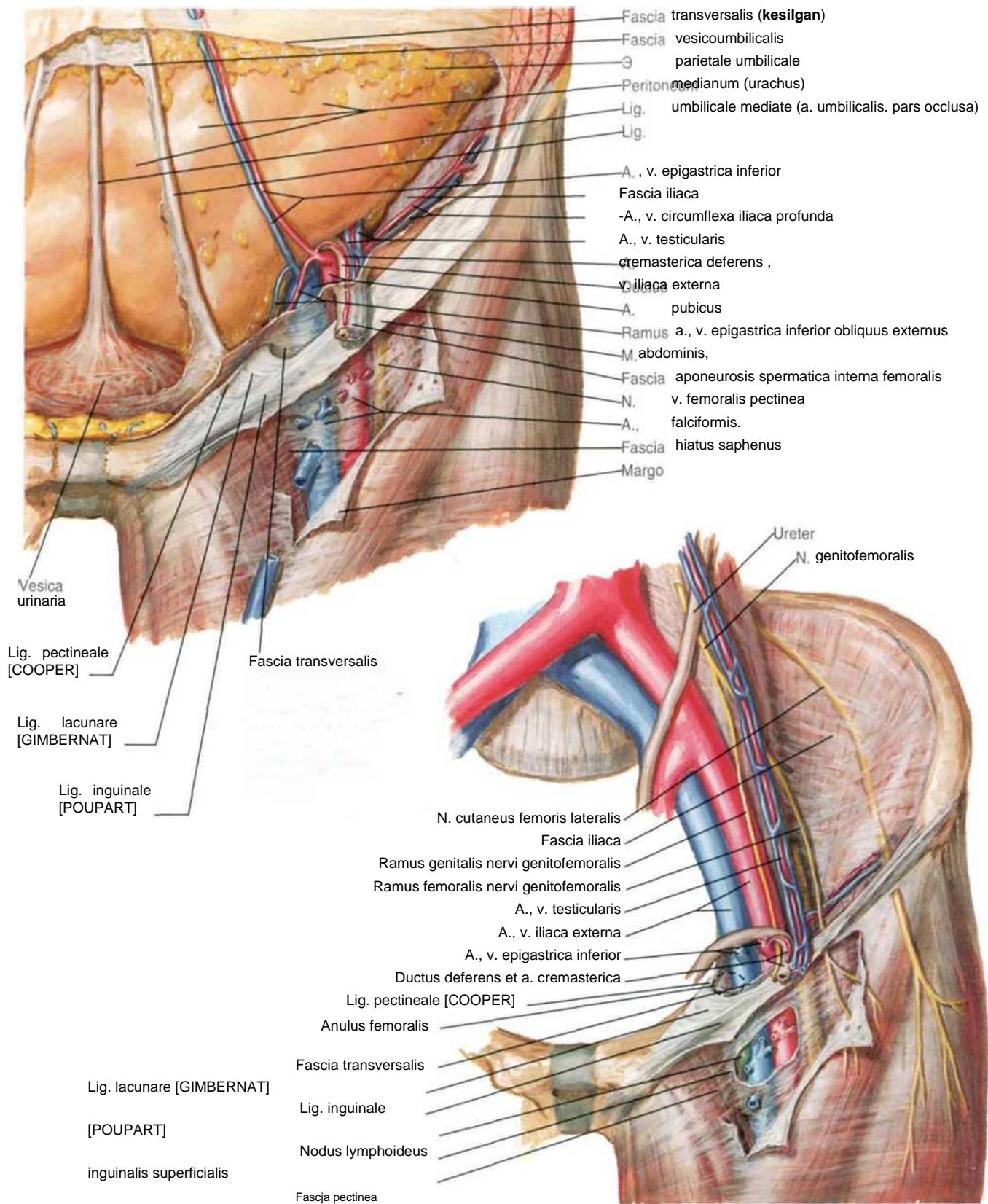


Old tomoni

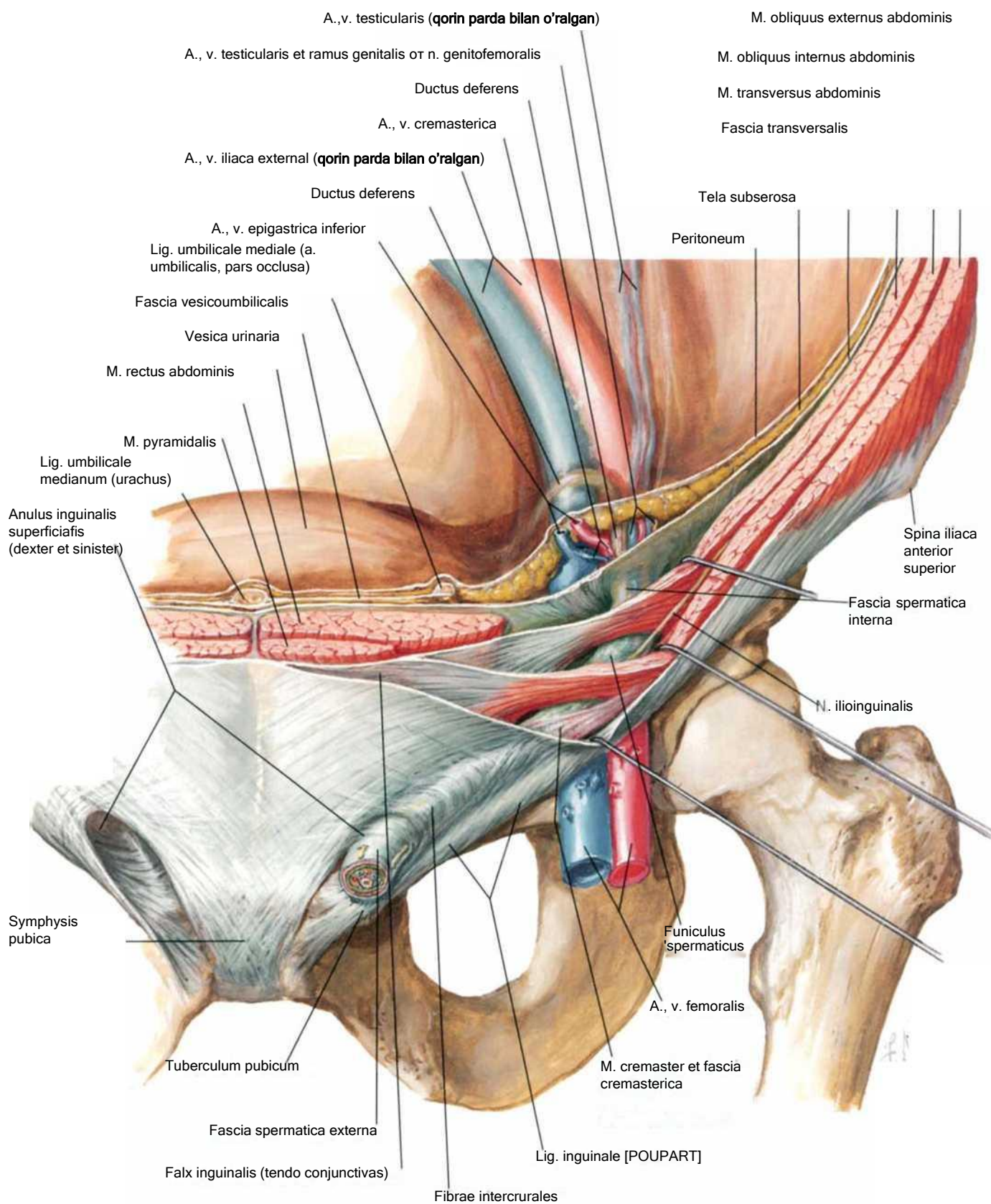
Orqadan ko'rinishi



Chov kanali (canalis inguinalis)

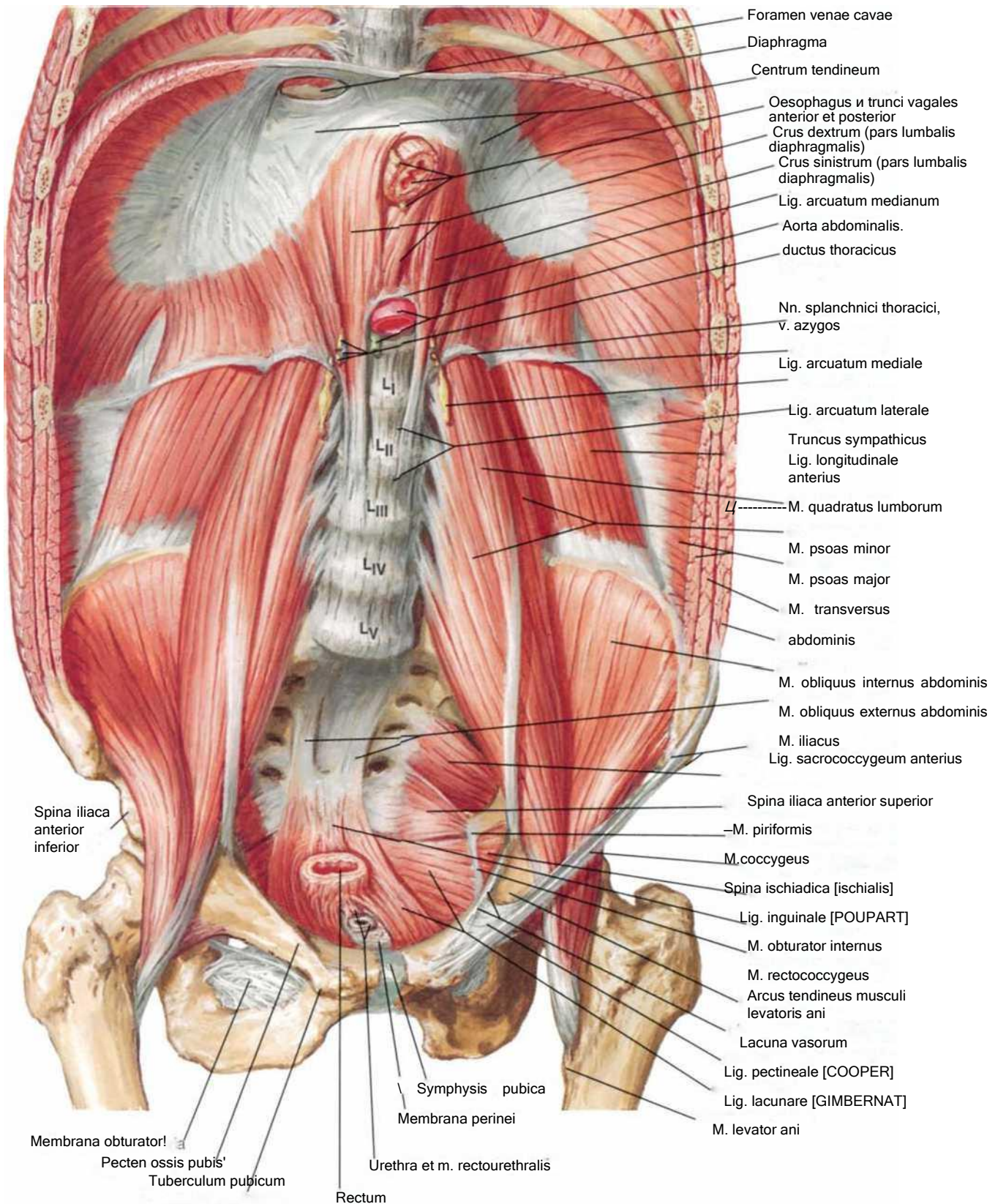


Chov kanali va urug' yo'llari



Qorin bo'shlig'ining orqa devori: ichki tomoni

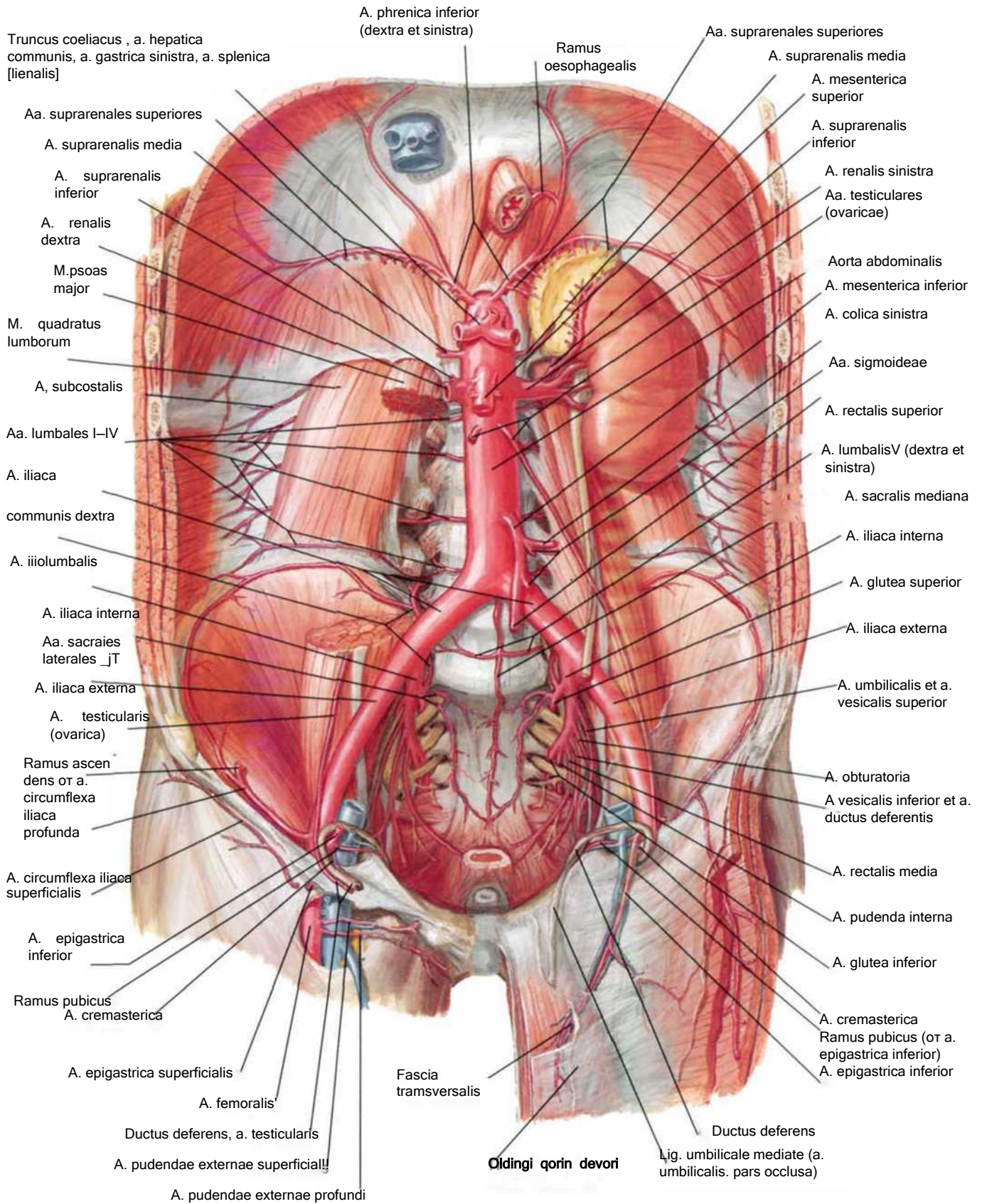
181-rasm.



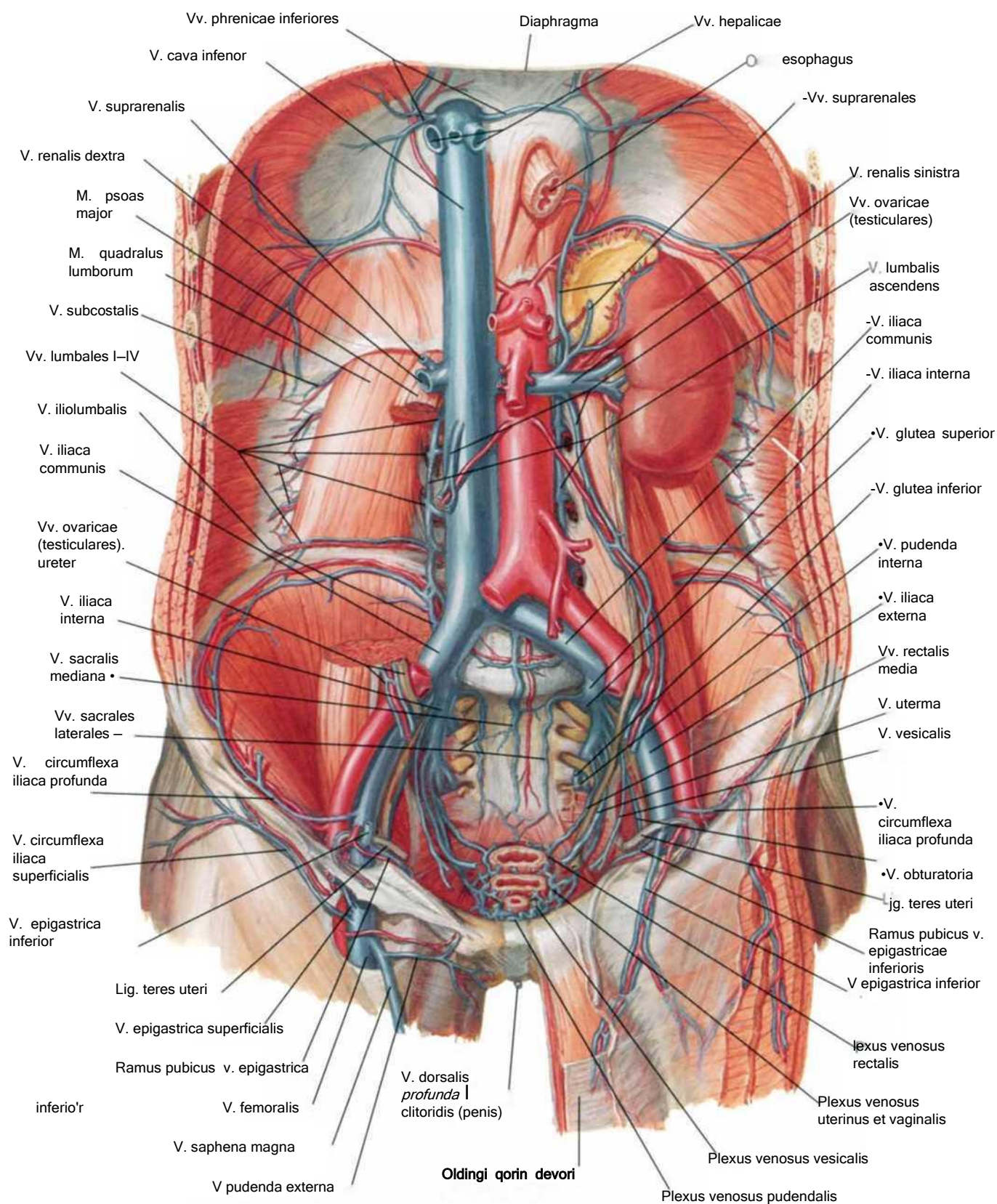
246-rasm

QORIN

Qorin bo'shlig'i orqa devori arteriyalari

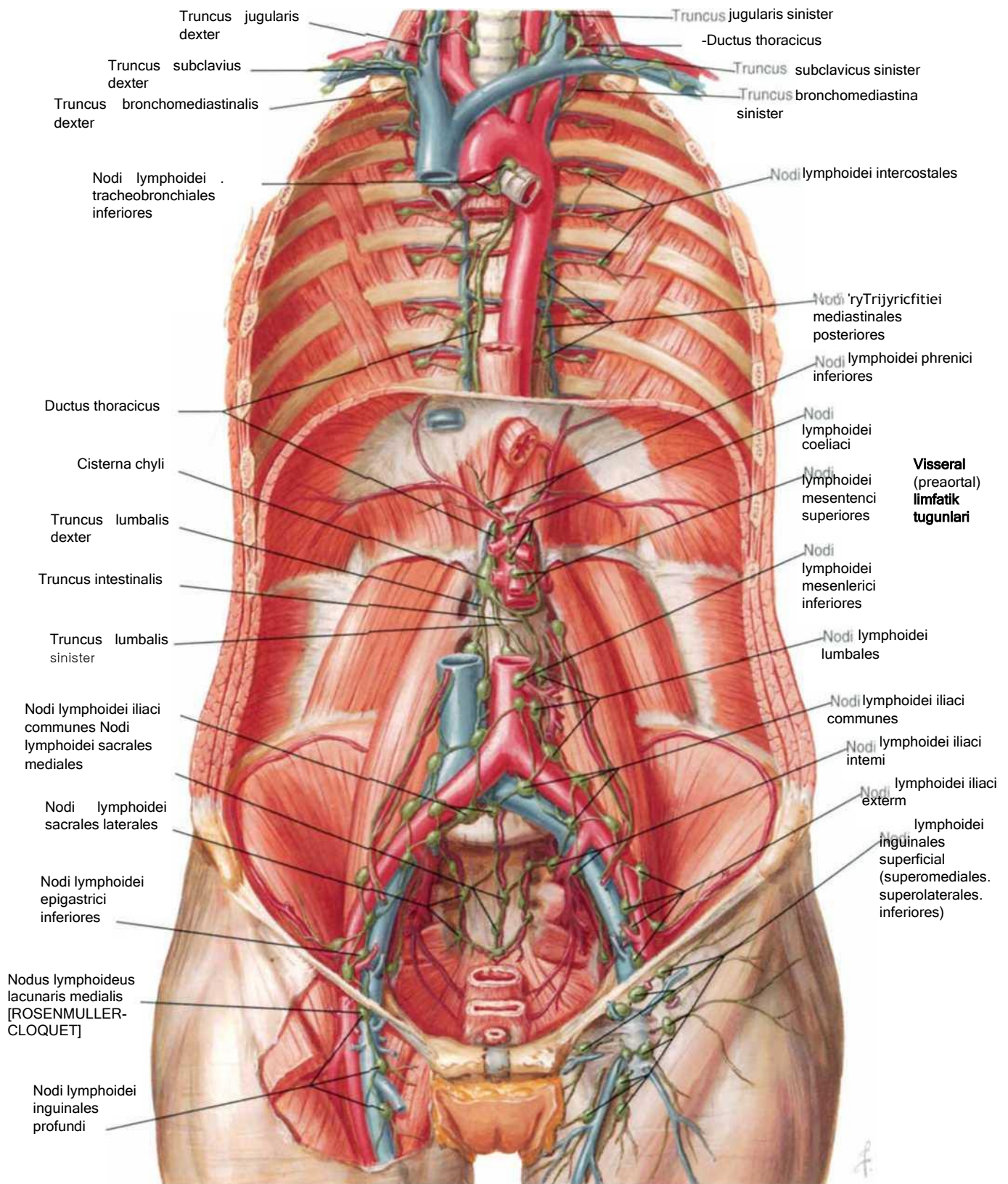


Qorin bo'shlig' orqa devorining venalari



Qorin bo'shlig'i orqa devorining limfa tomirlari va tugunlari

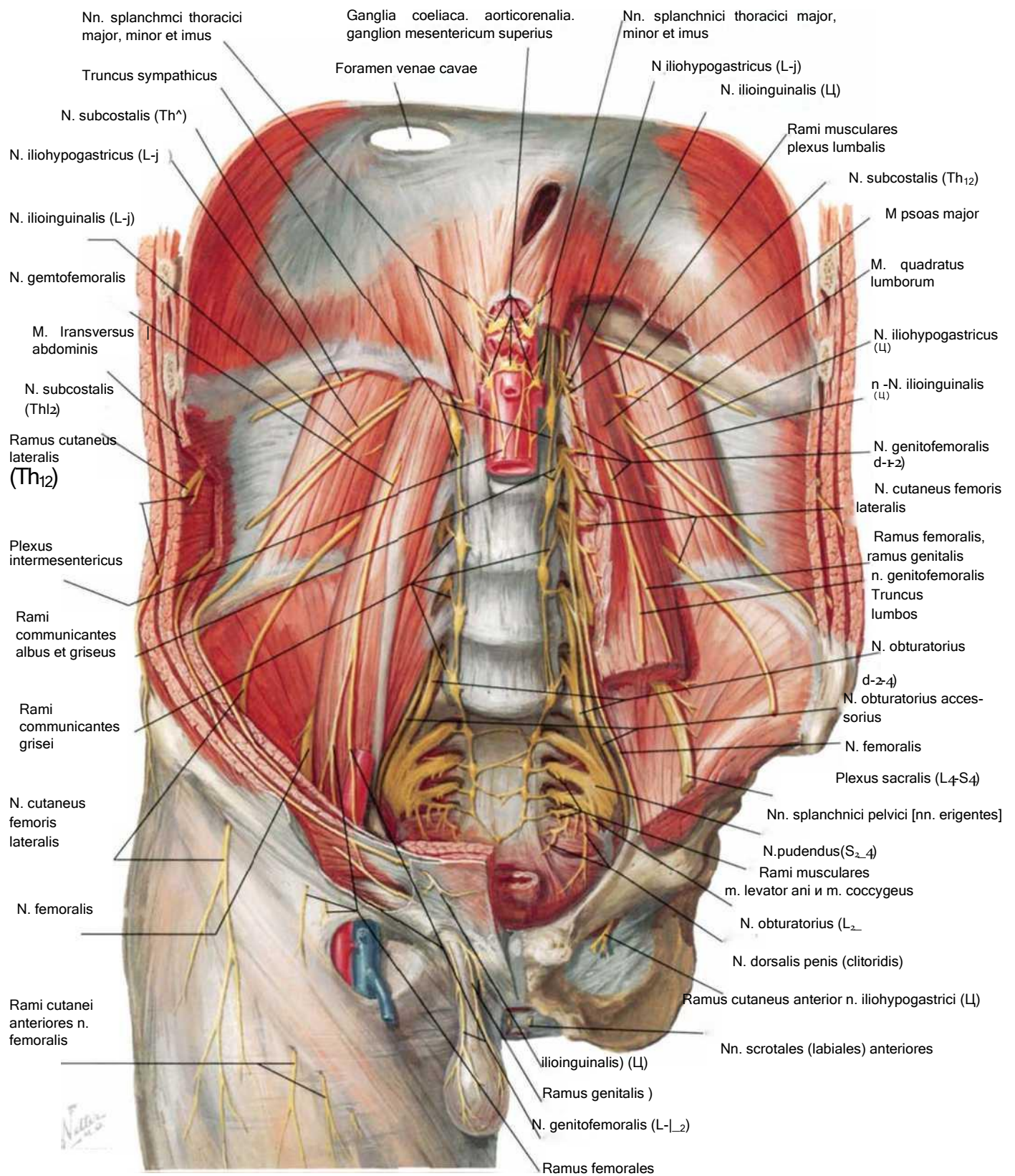
378-rasm.



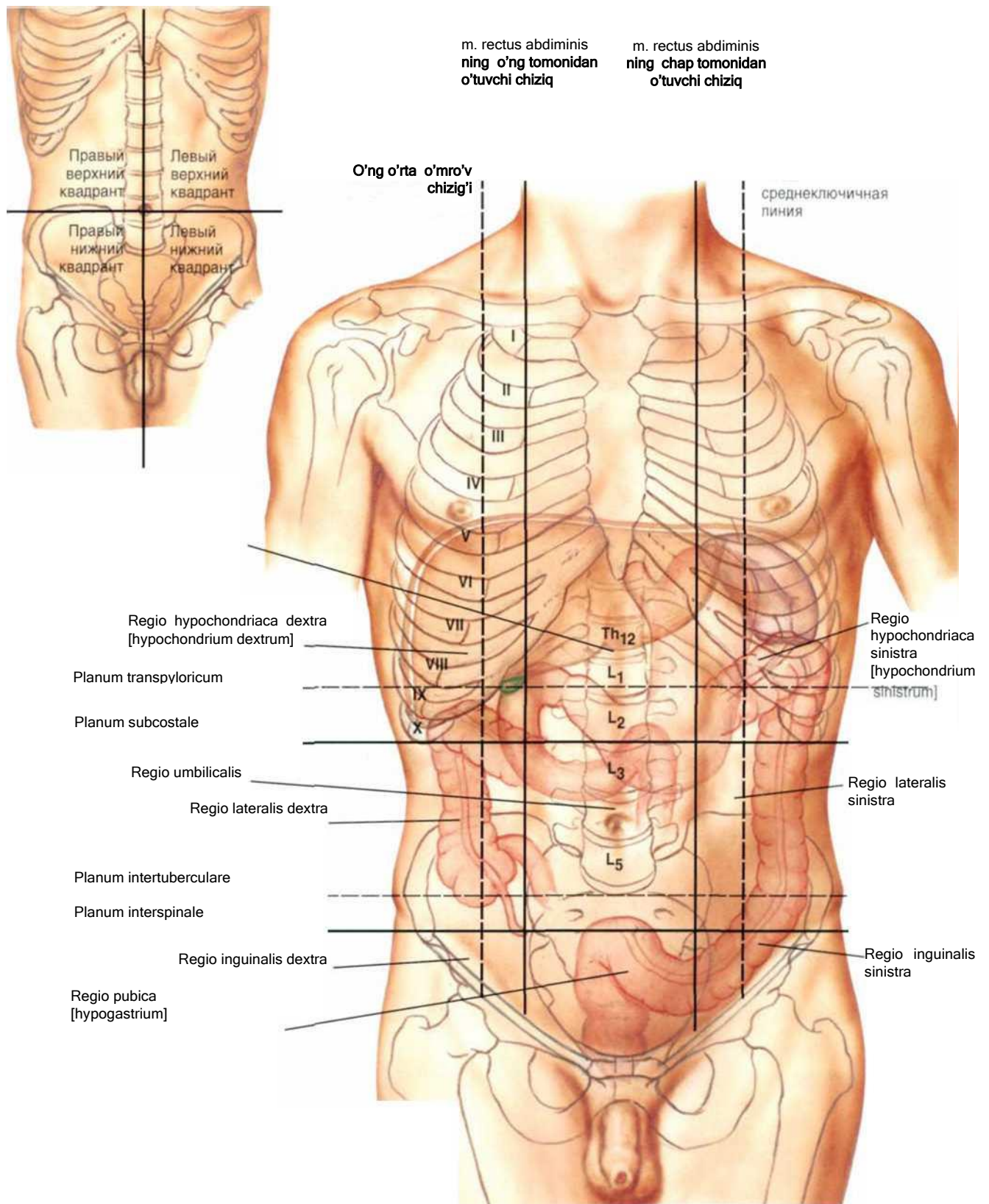
TANA DEVORLARI

249-rasm

Qorin bo'shlig'i orqa devorining nervlari

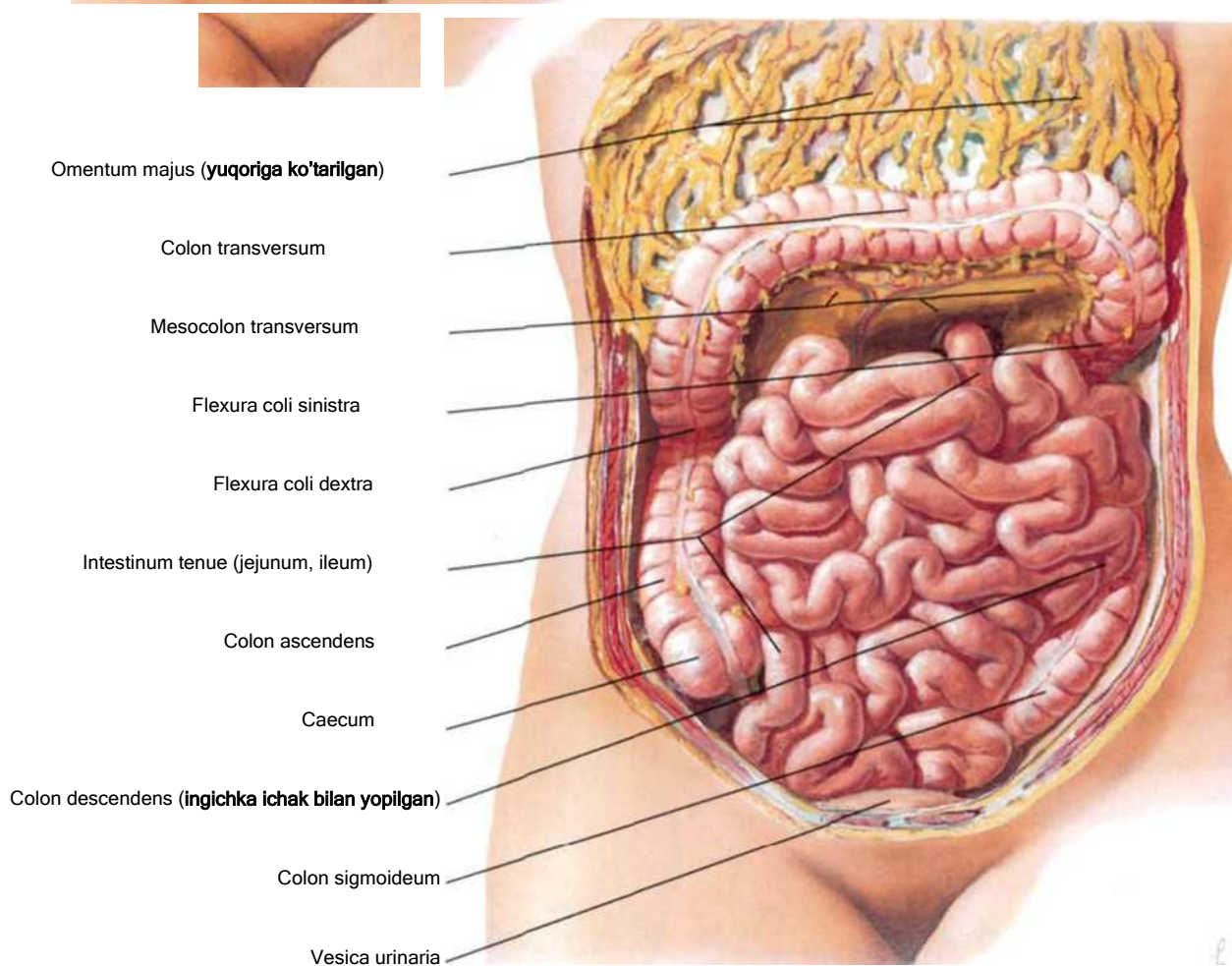
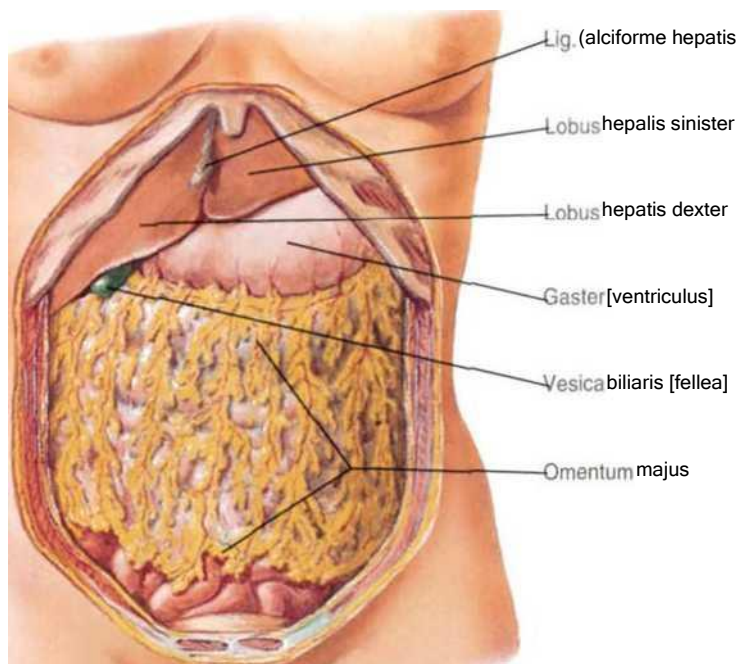


Qorin sohasi, regiones abdominales, (chiziqlar va satxlar)



Katta charvi (omentum majus) va qorin bo'shlig'i a'zolari

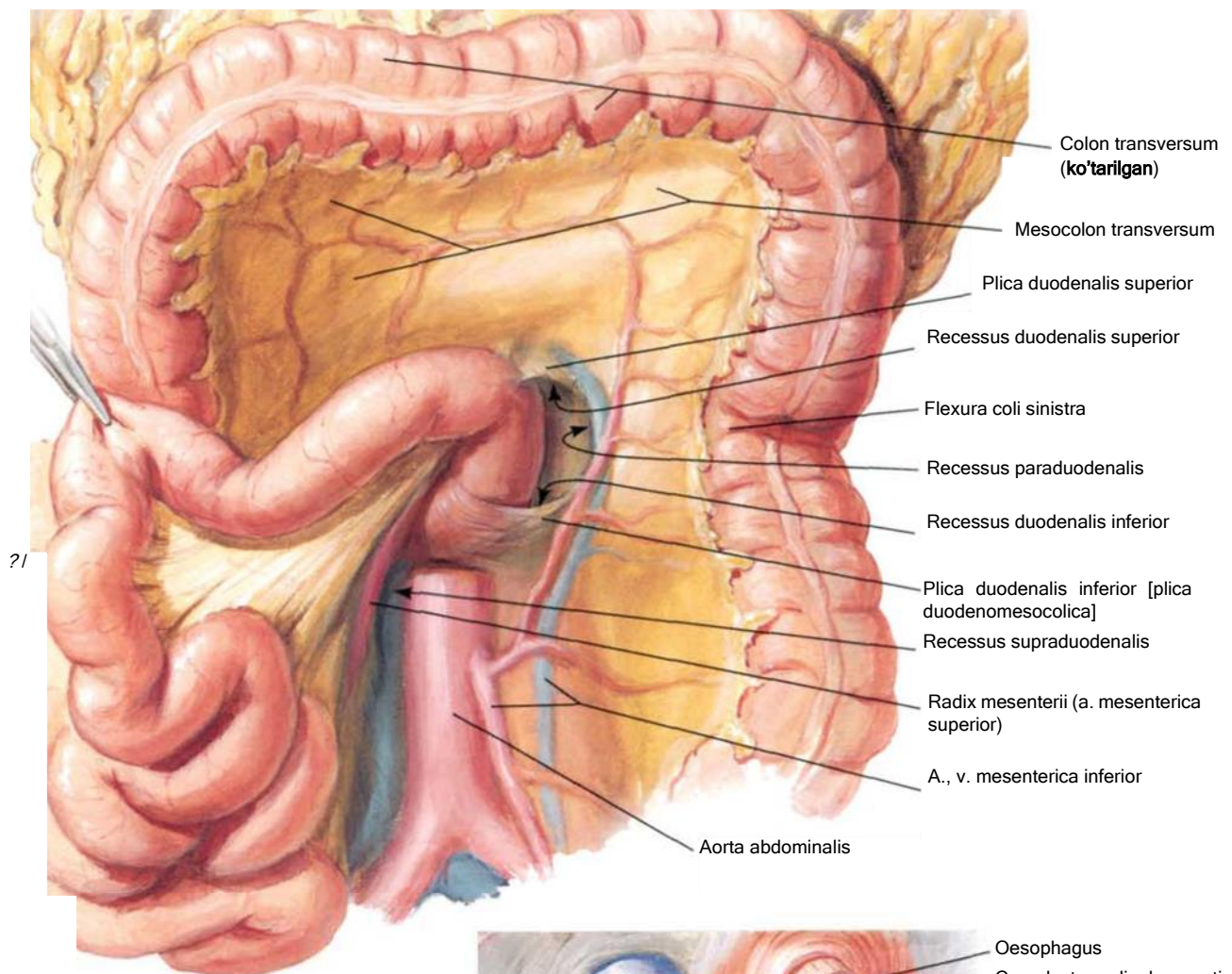
258. 328. 329-rasmlar.



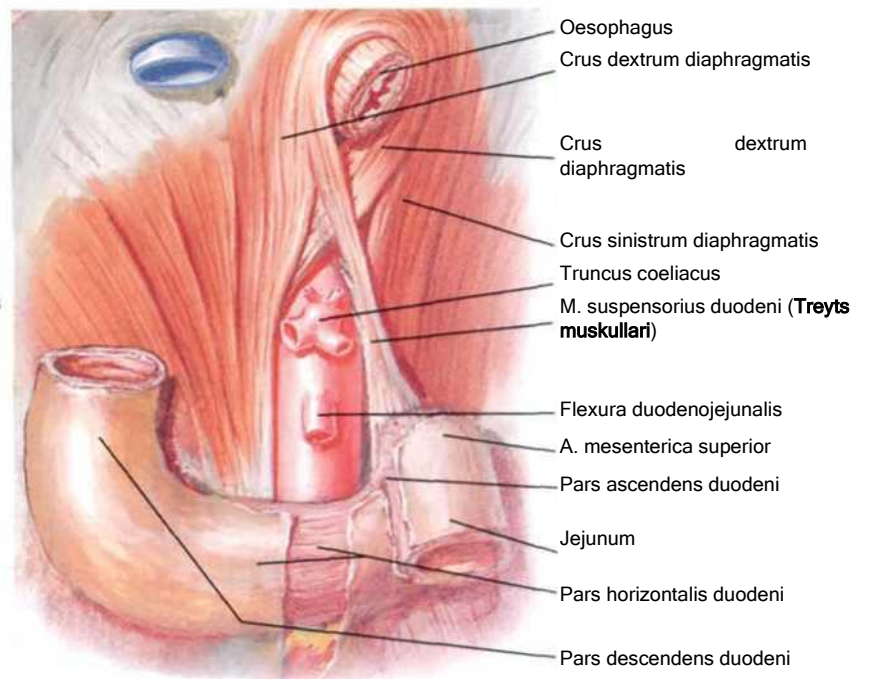
252-rasm

QORIN

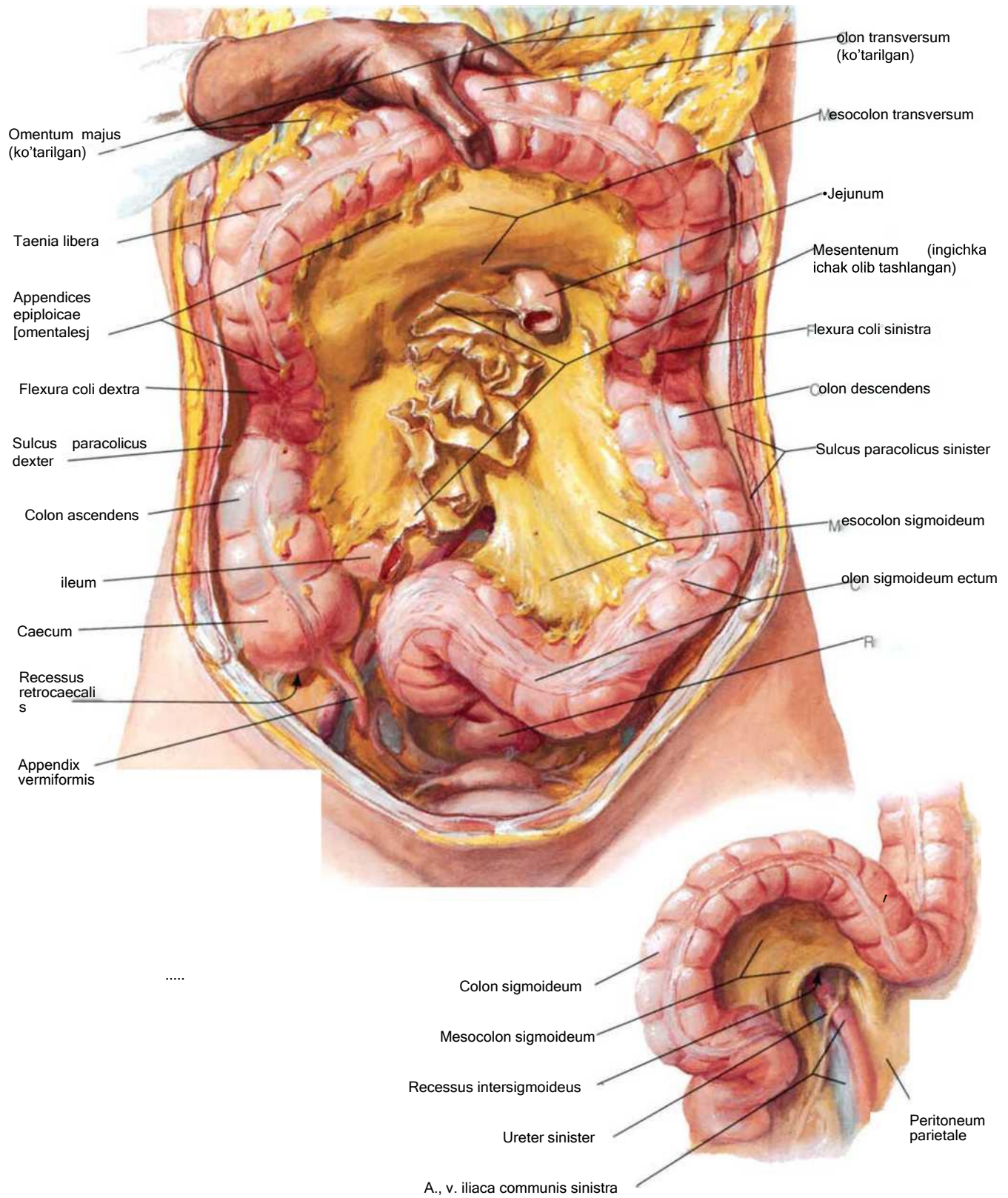
Ichak tutqichlari



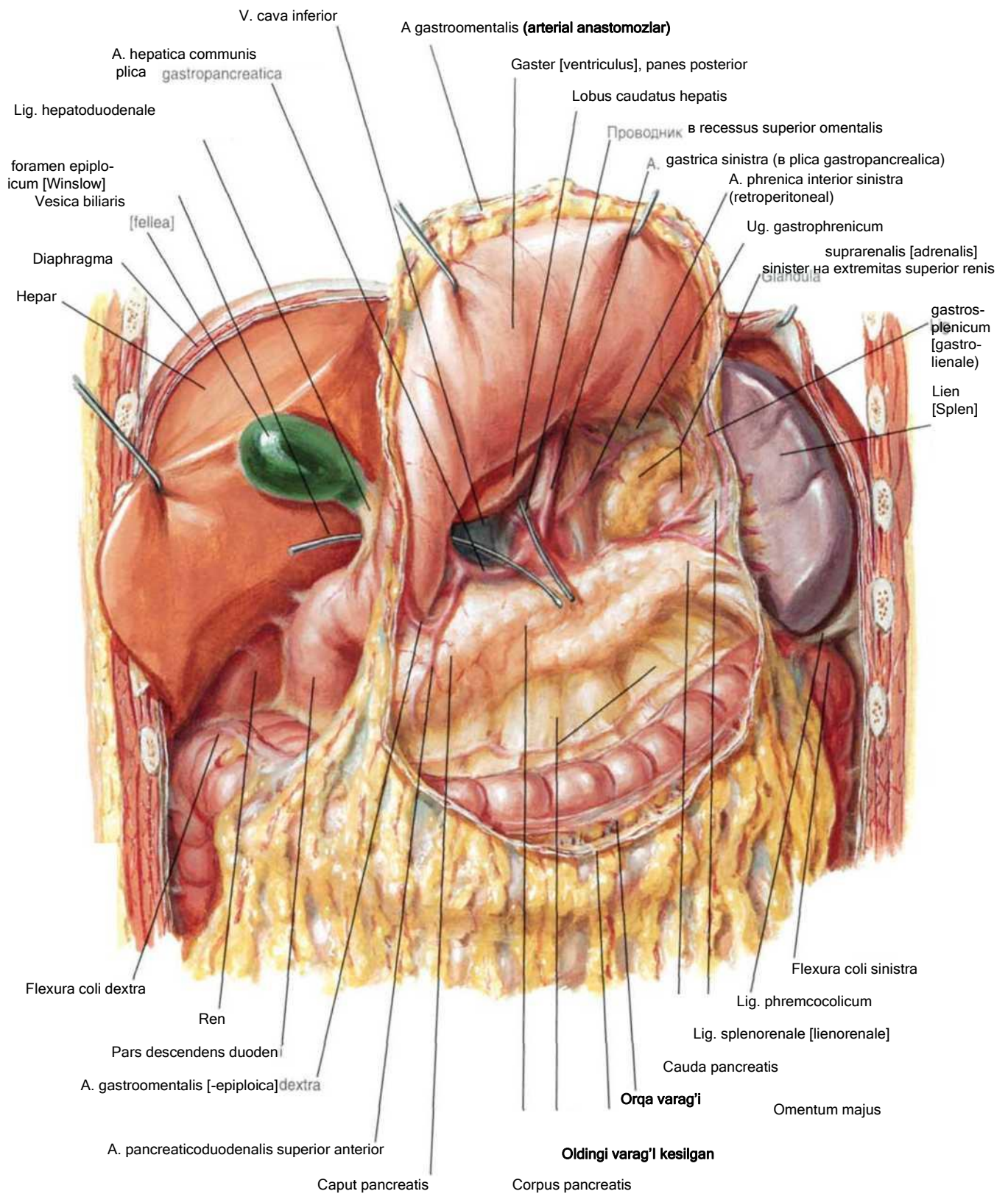
Топография m. suspensorius duodeni (мышцы Трейтца)



Ichak tutqichlari (davomi)

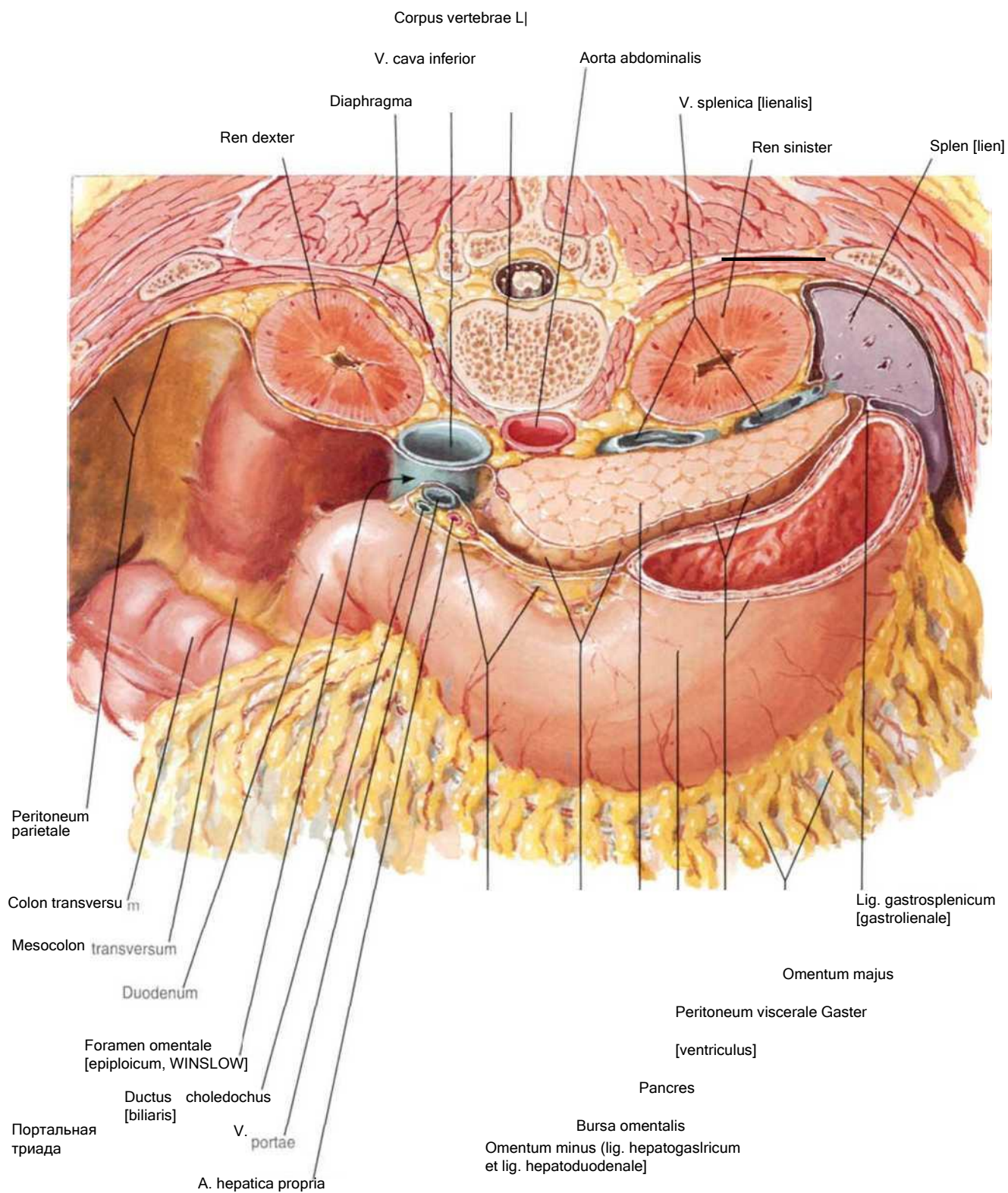


Charvi xaltasi (bursa omentalis)



Charvi xaltasi (bursa omentalis), ko'ndalang kesimi

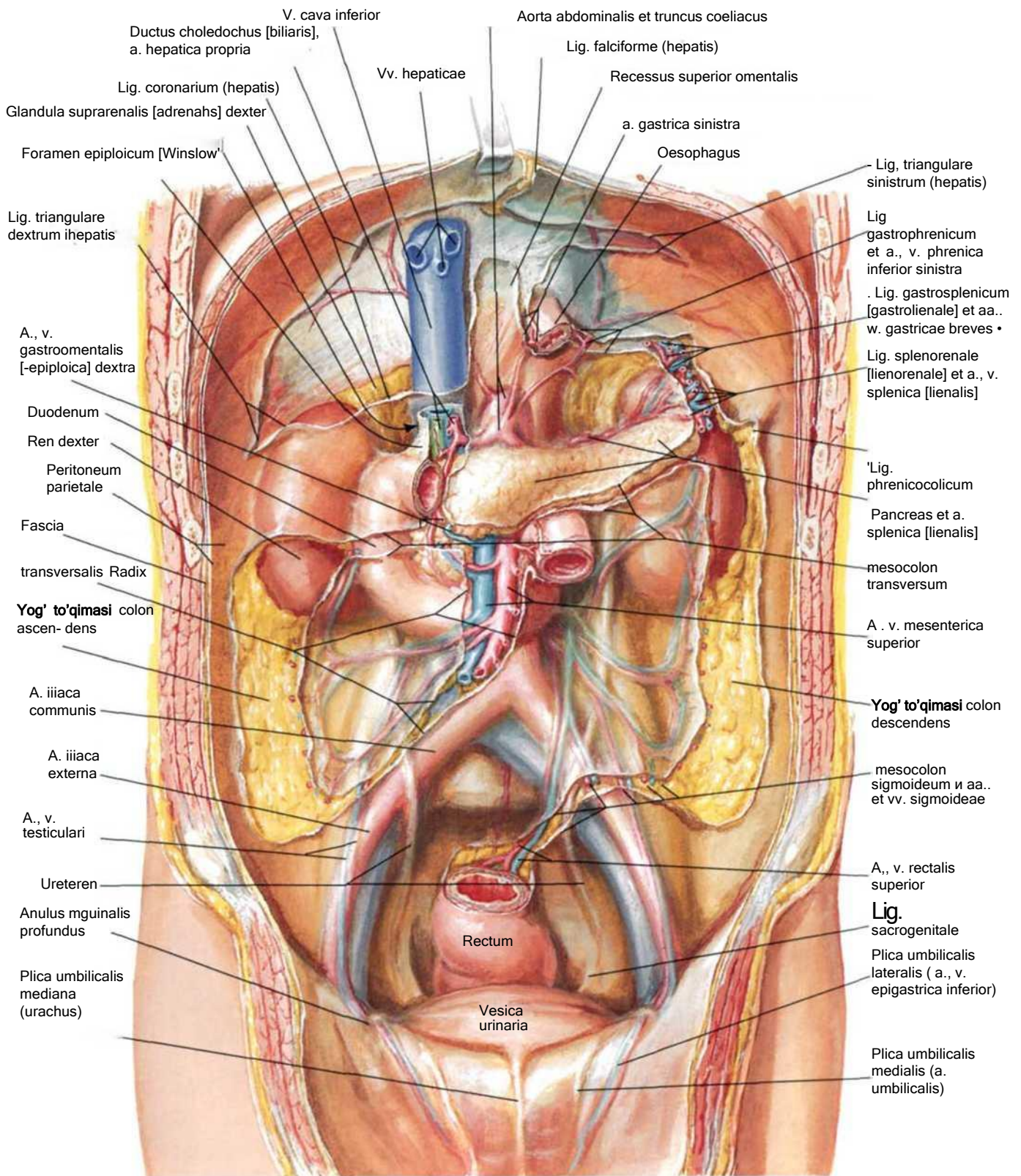
327-rasm.



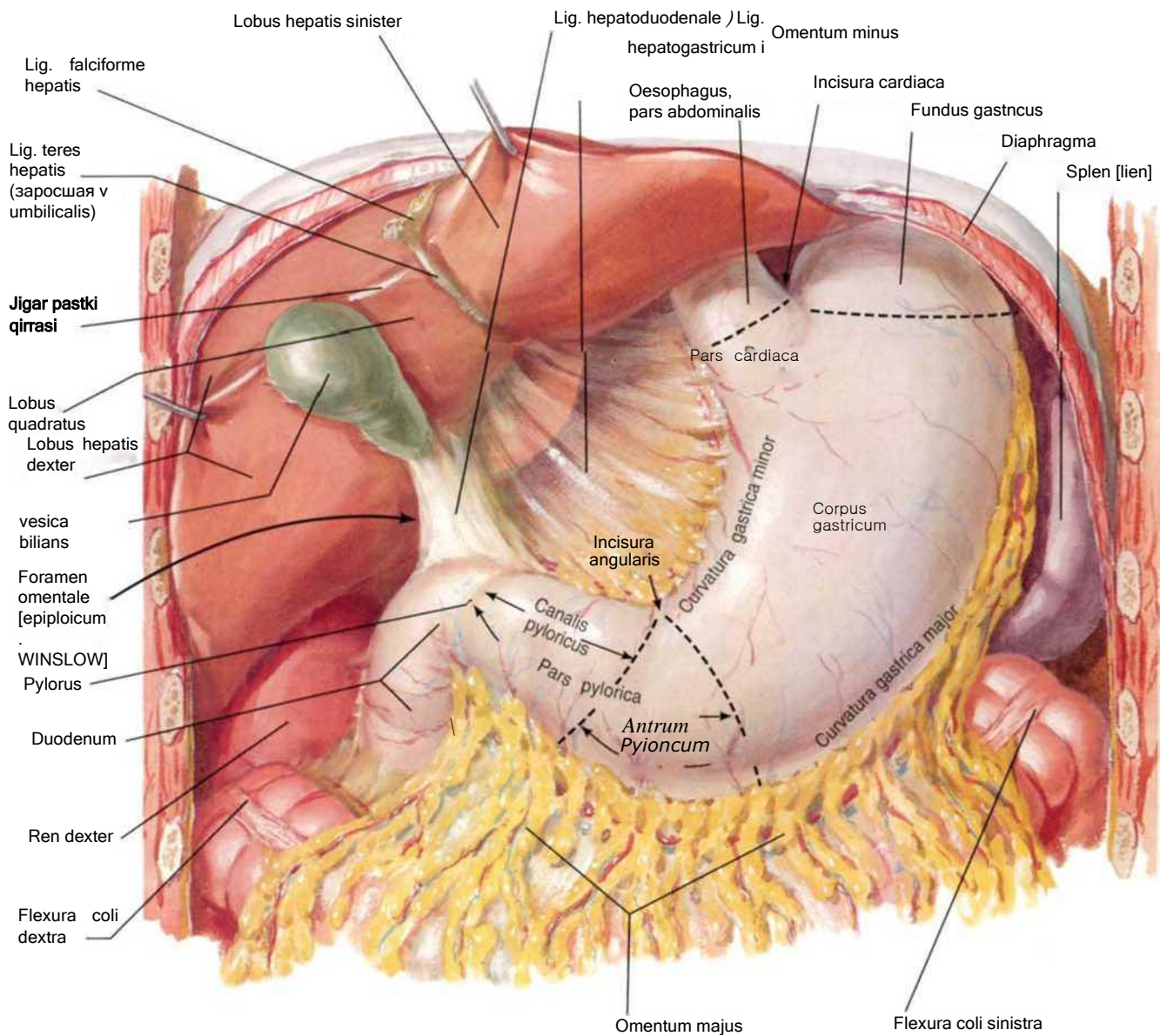
256-rasm

QORIN BO'SHLIG'I

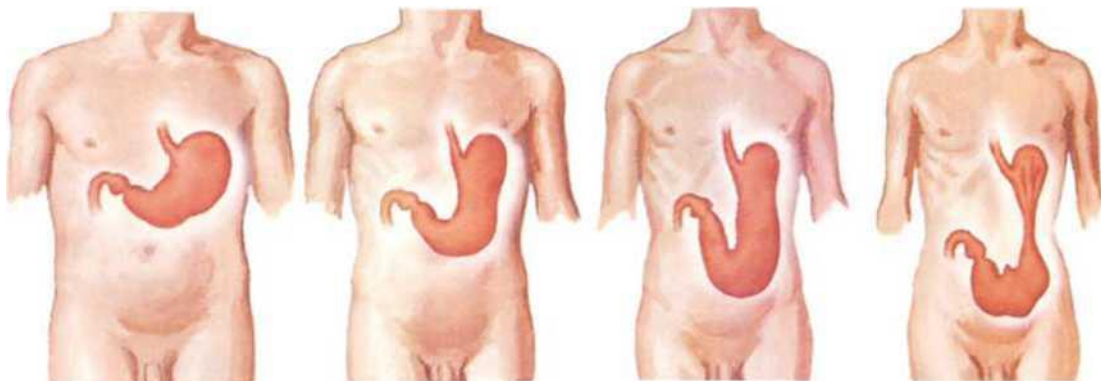
Qorin bo'shlig'i orqa devorining qorin pardasi



Me'da (gaster [ventriculus])



Odam konstitutsiyasiga qarab me'daning qorin bo'shlig'ida joylashuvi



Gipertonik me'da

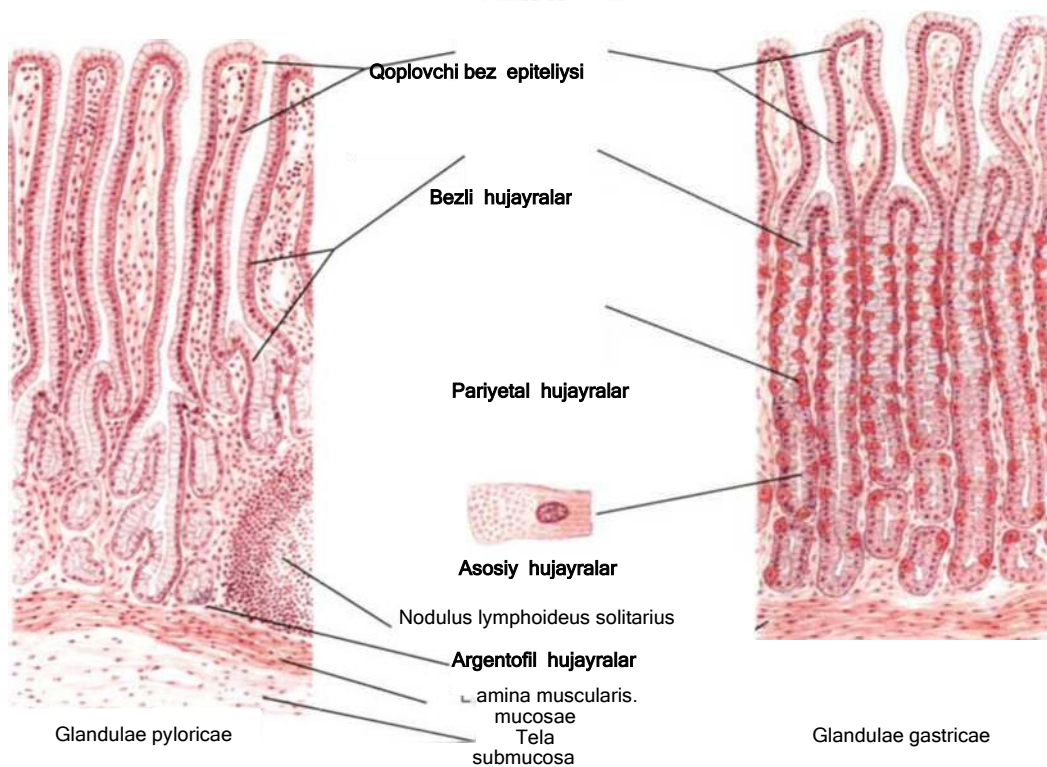
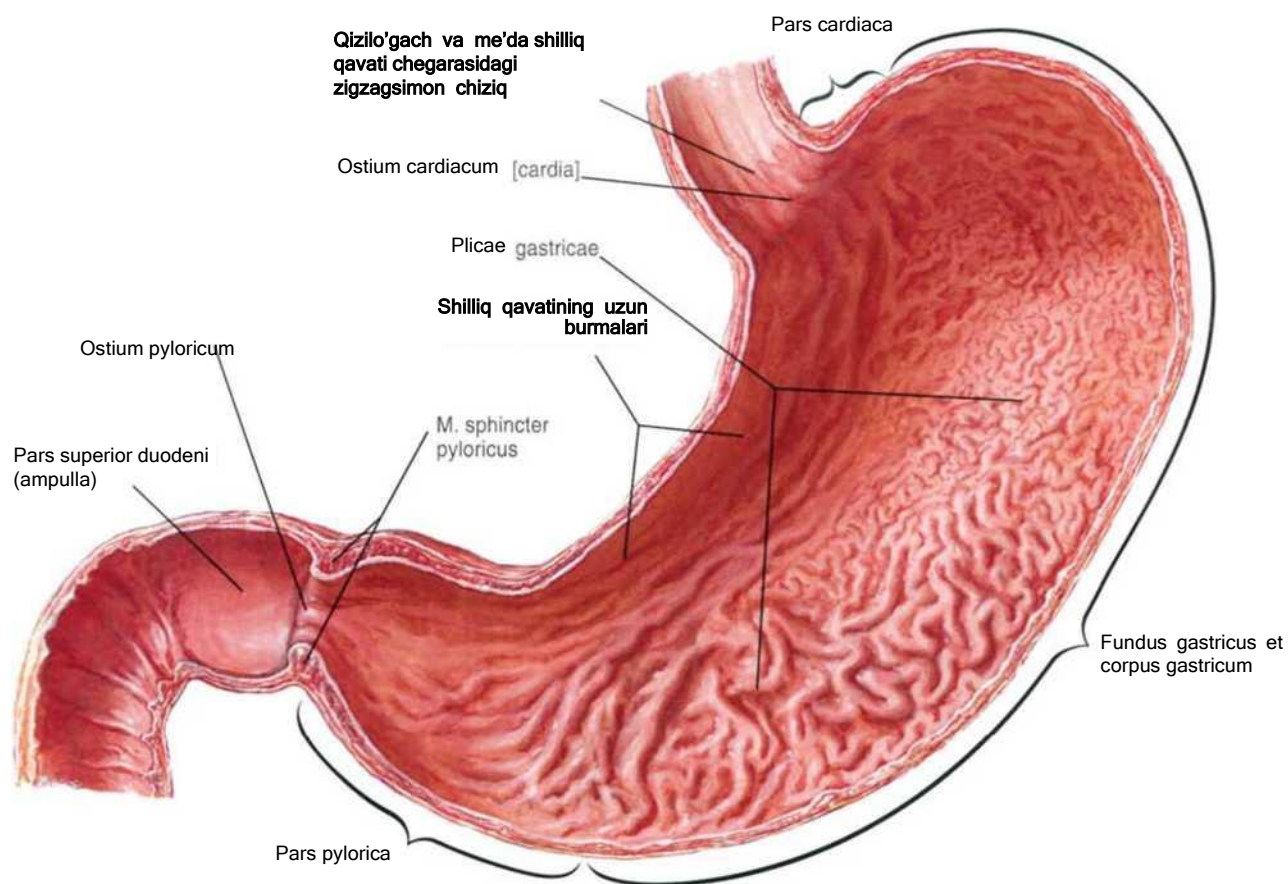
Ortotonik me'da

Gipotonik me'da

Atonik me'da

Me'daning shilliq qavati

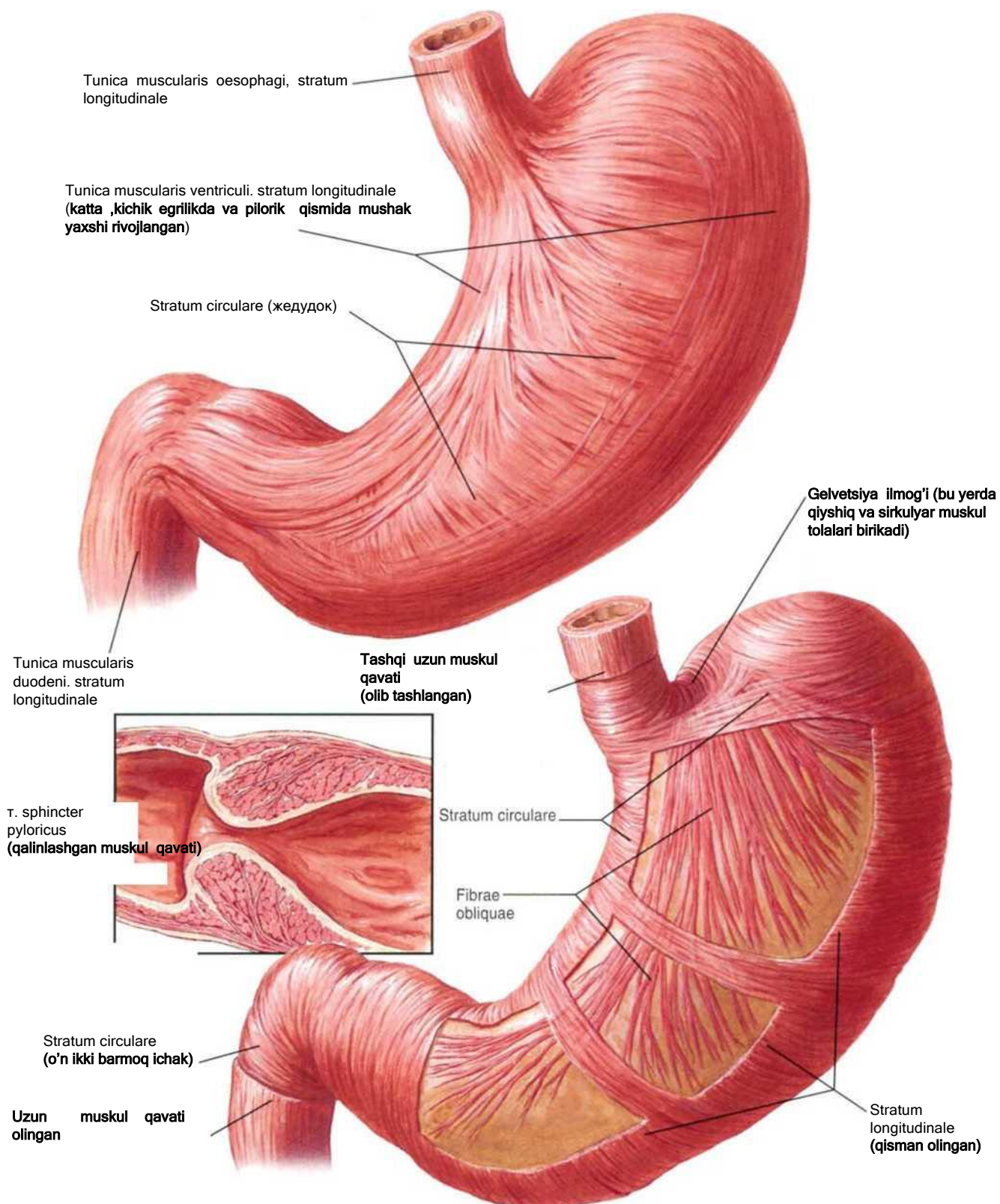
224-rasm.



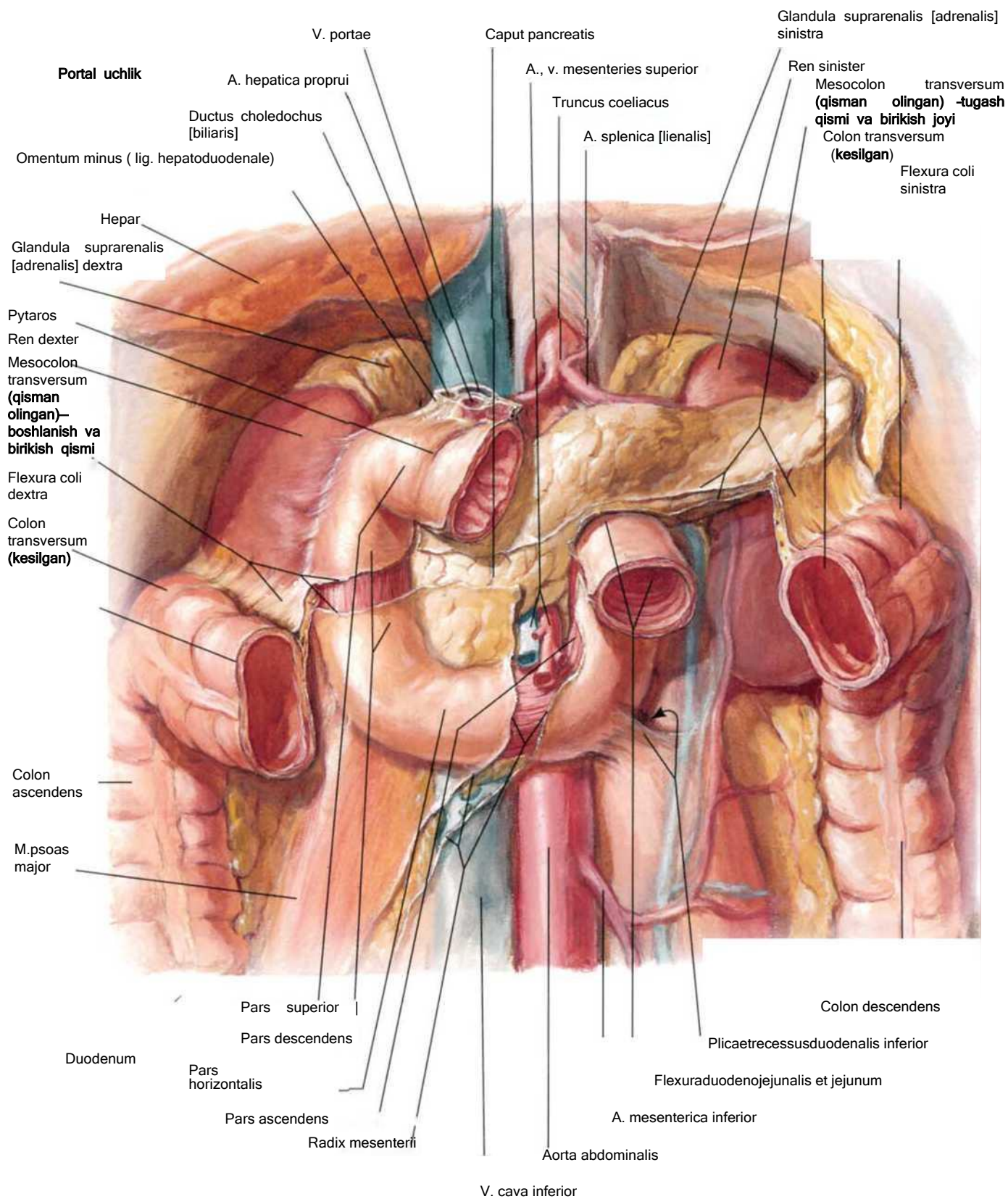
QORIN BO'SHLIG'I

259-rasm

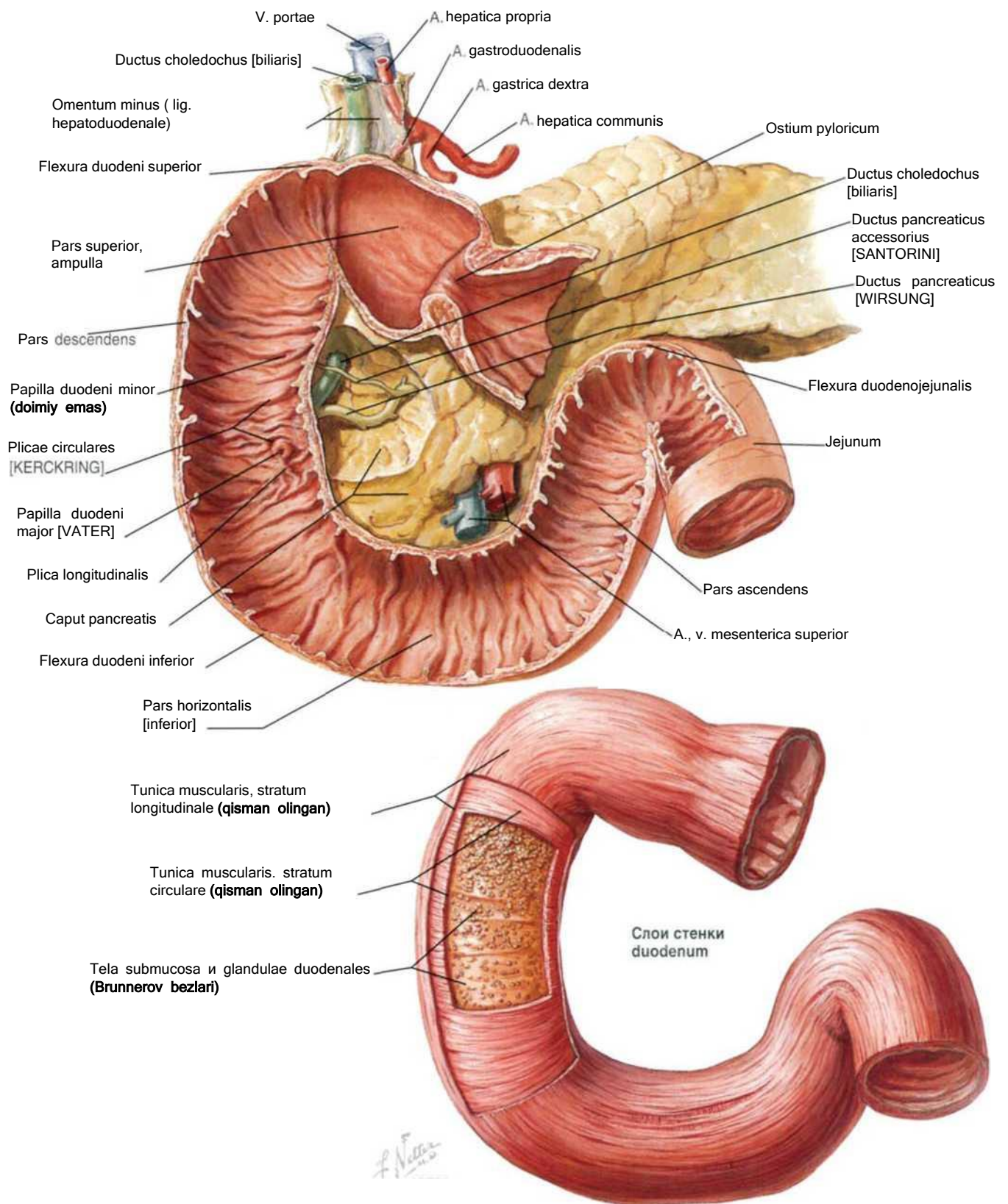
Me'daning muskul qavati



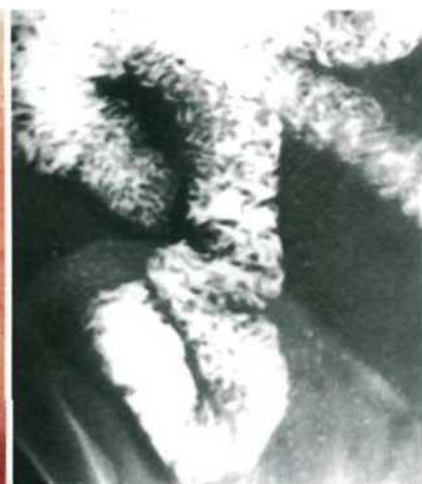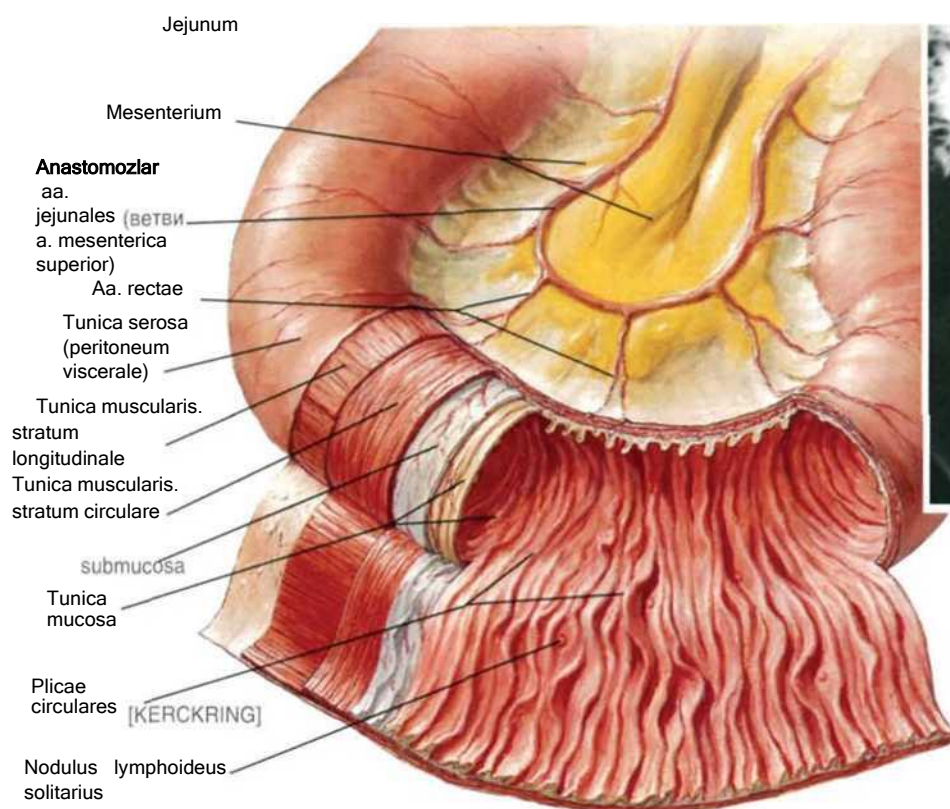
O'n ikki barmoq ichak (duodenum)



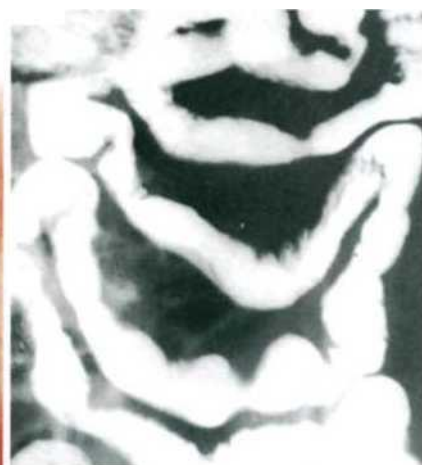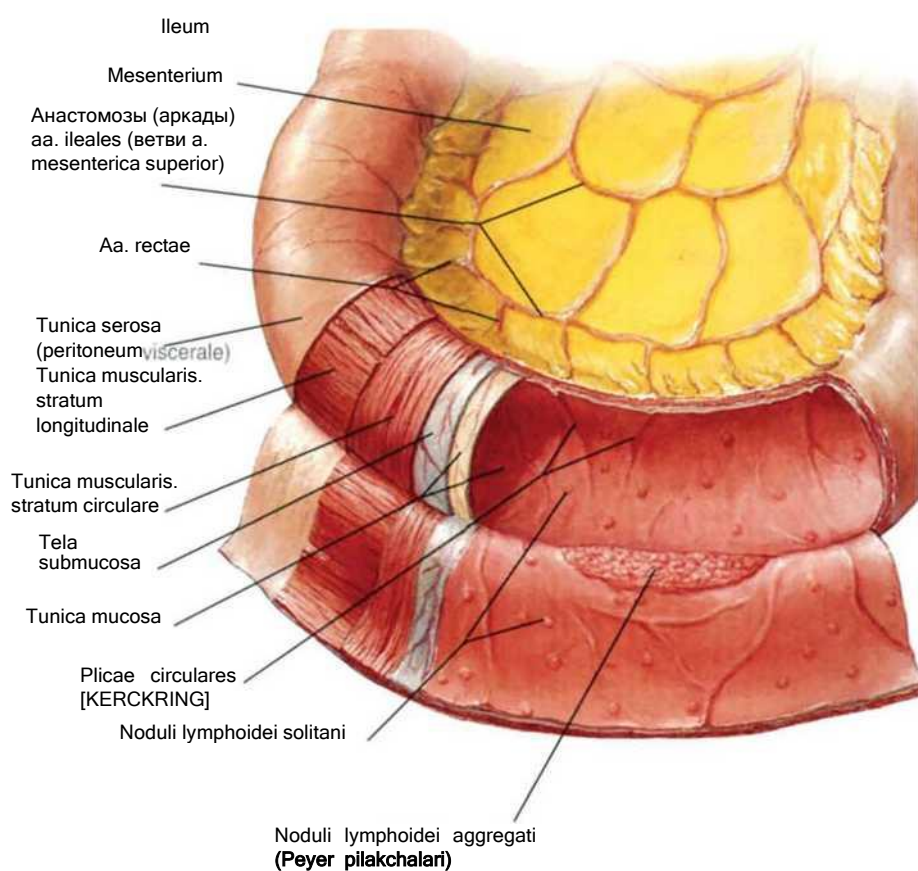
O'n ikki barmoq ichak (duodenum):qavatlari



Ingichka ichak (intestinum tenue)

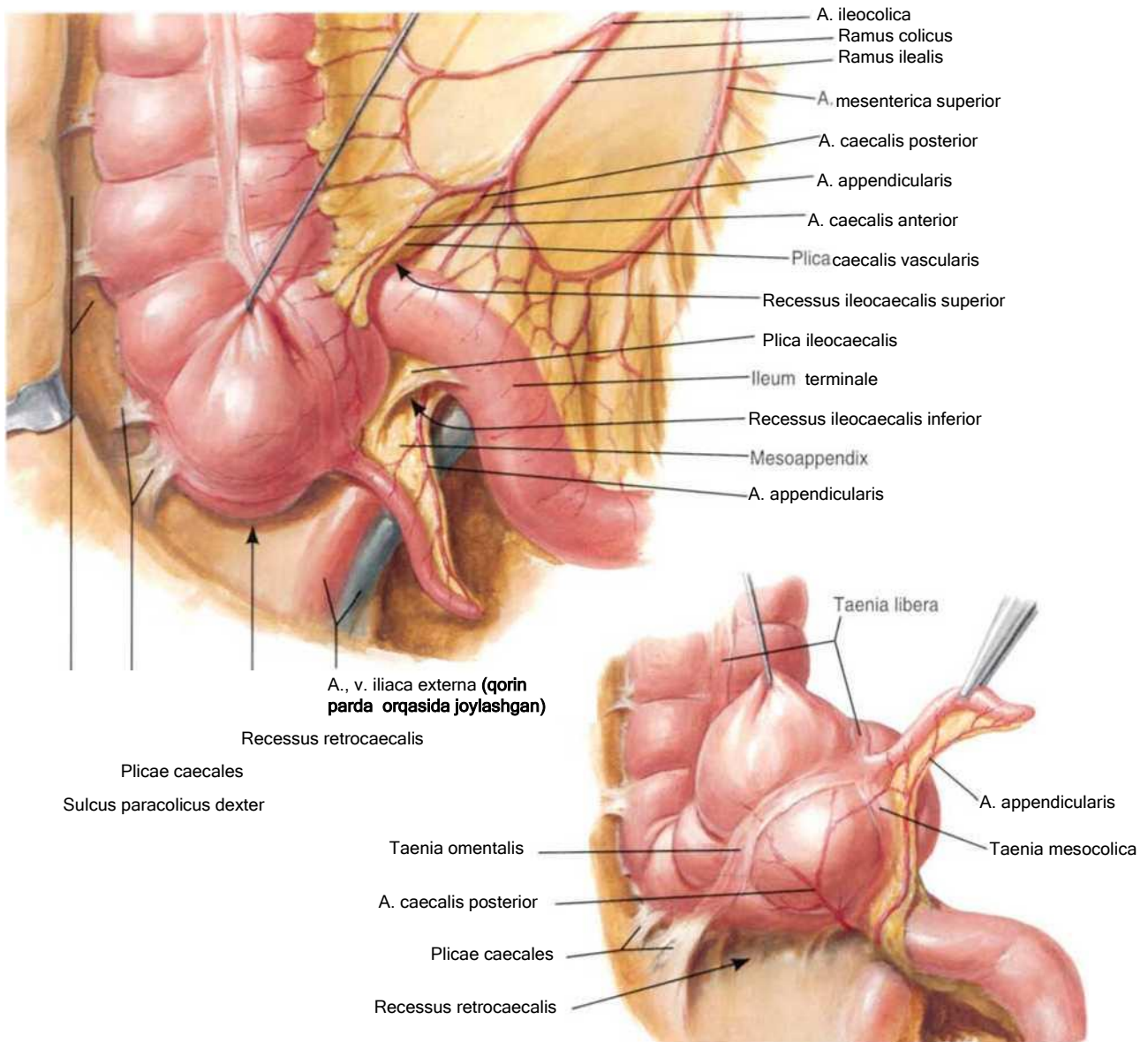


Och ichakda bariyning
taqsimlanishi (rentgenogrammasi)

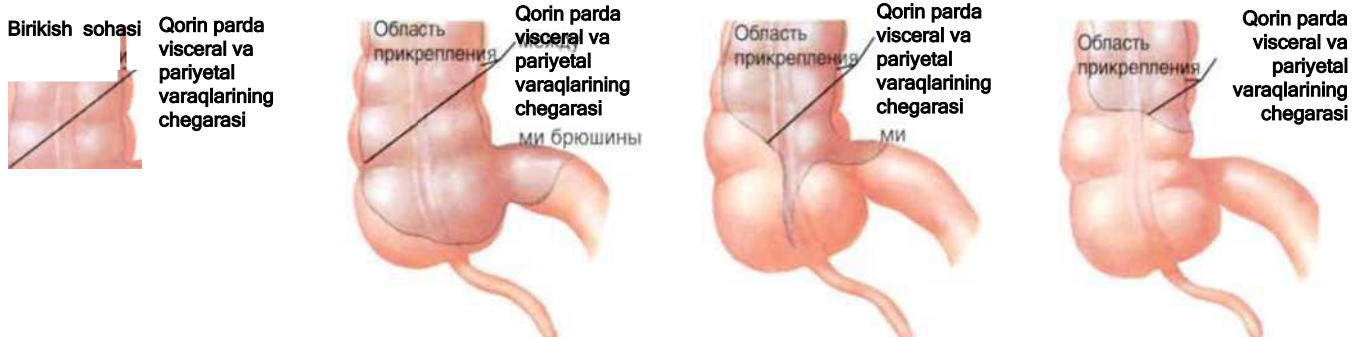

Yonbosh ichakda bariyning
taqsimlanishi (rentgenogrammasi)

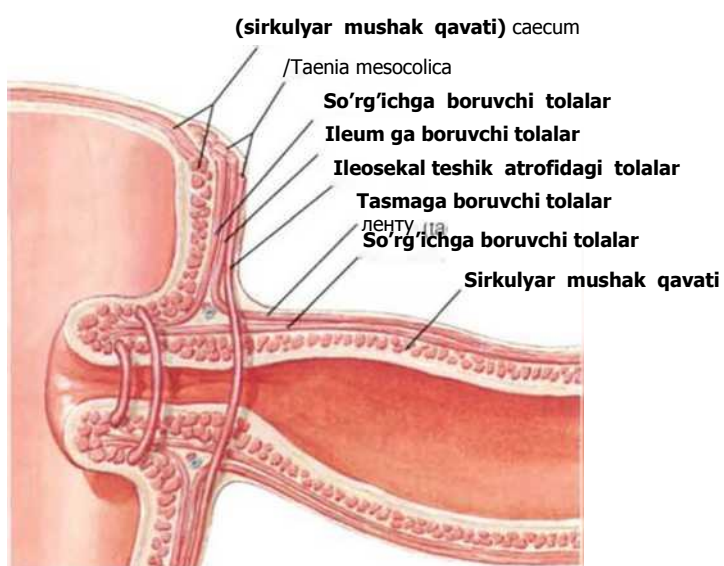
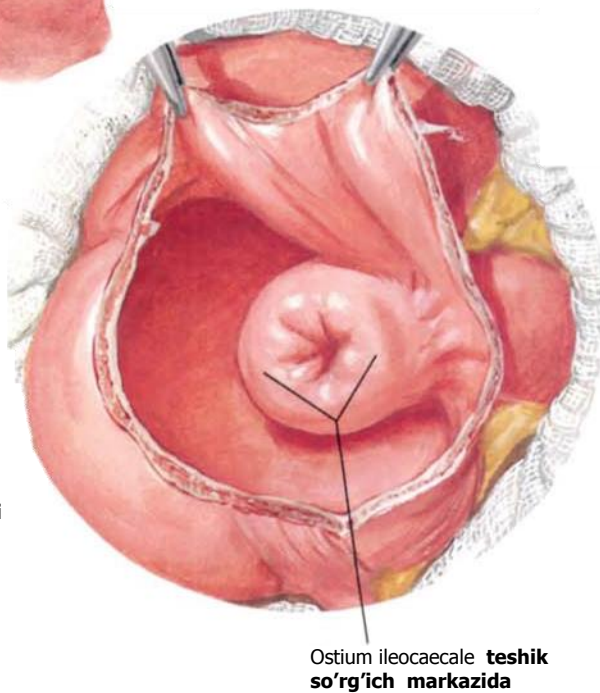
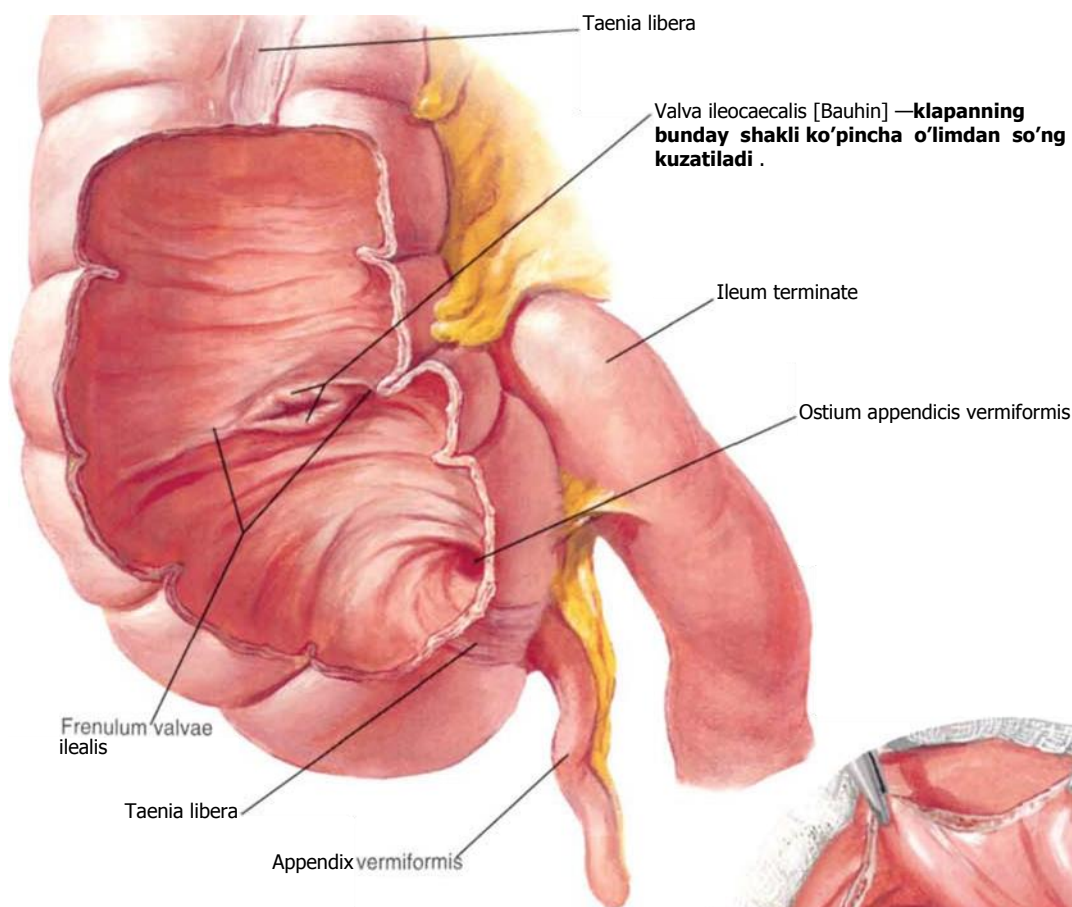
Ileosekal sohasi



Qorin orqa devoriga ko'richakning birkish turlari

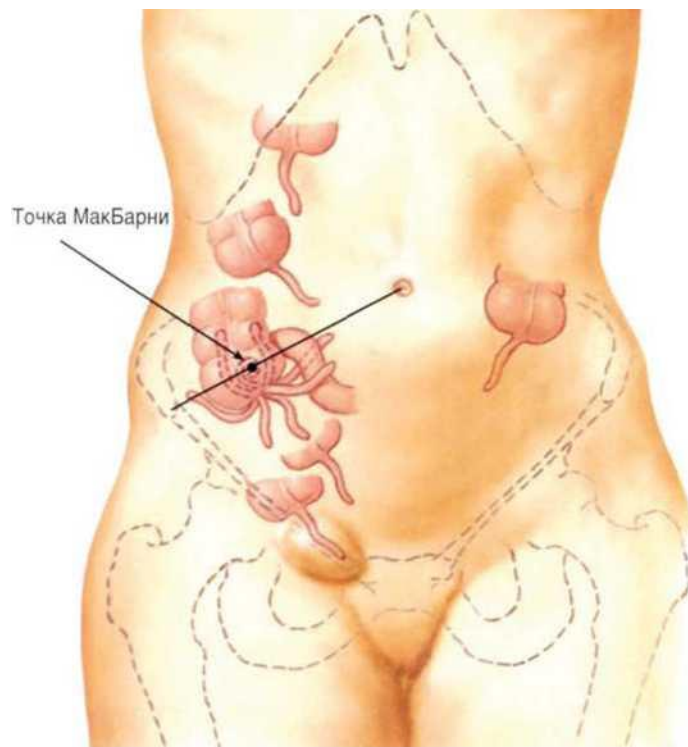


Ileosekal sohasi (davomi)

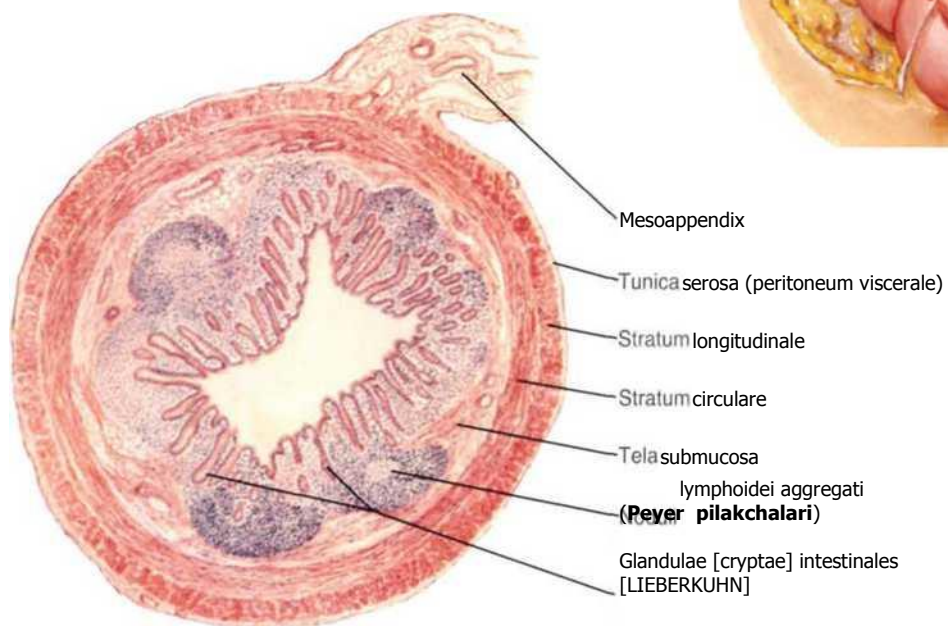
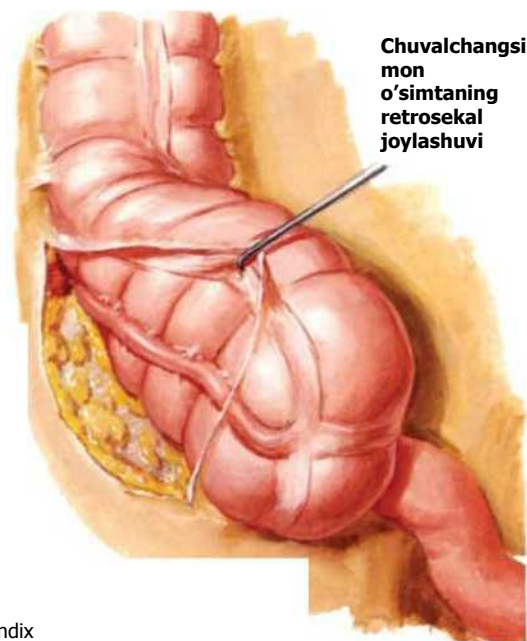


Yonbosh ichakni ko'richakka o'tish qismidagi muskullar qavati (sxemasi)

Chuvalchangsimon o'simta (appendix vermiformis)

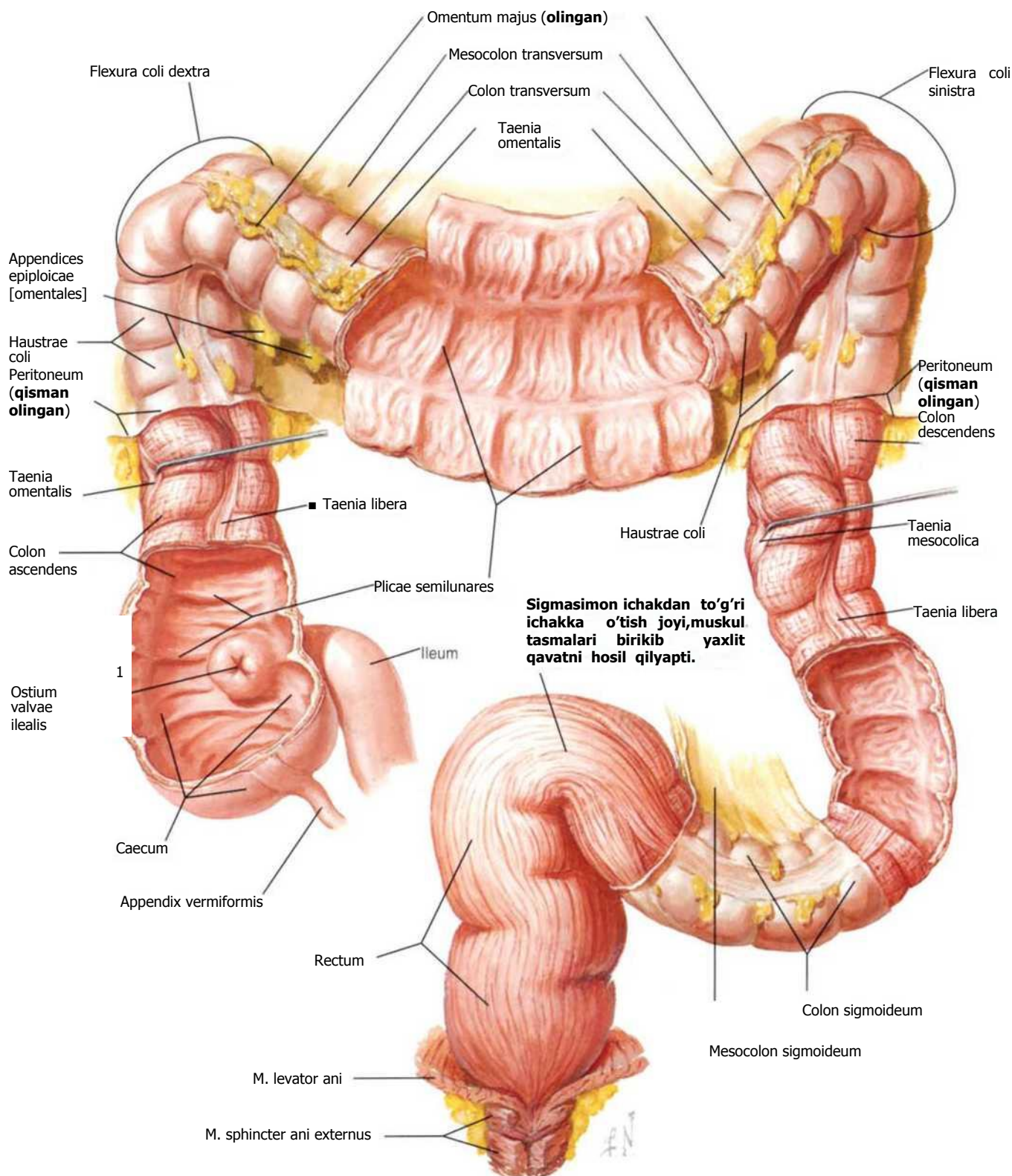


Chuvalchangsimon o'simtaning joylashish turlari



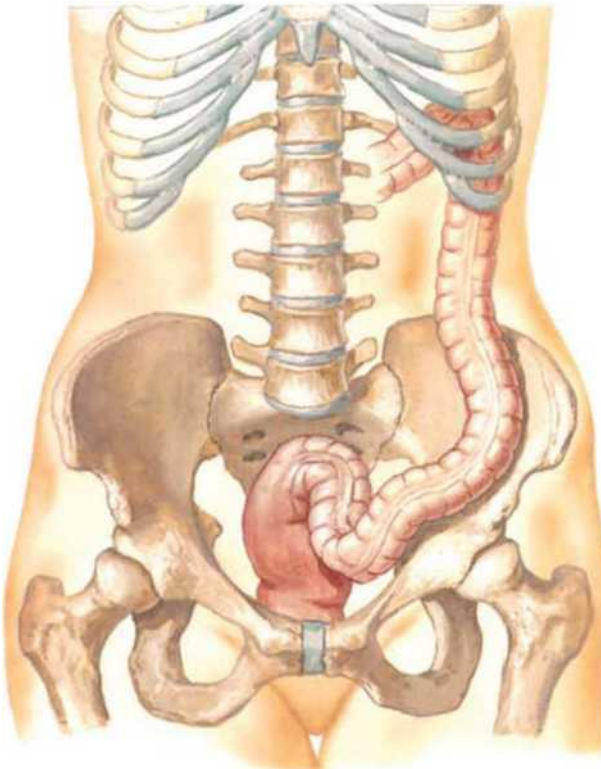
Yo'g'on ichak (*intestinum crasum*): shilliq va muskul qavatlari

363-368-rasmlar.

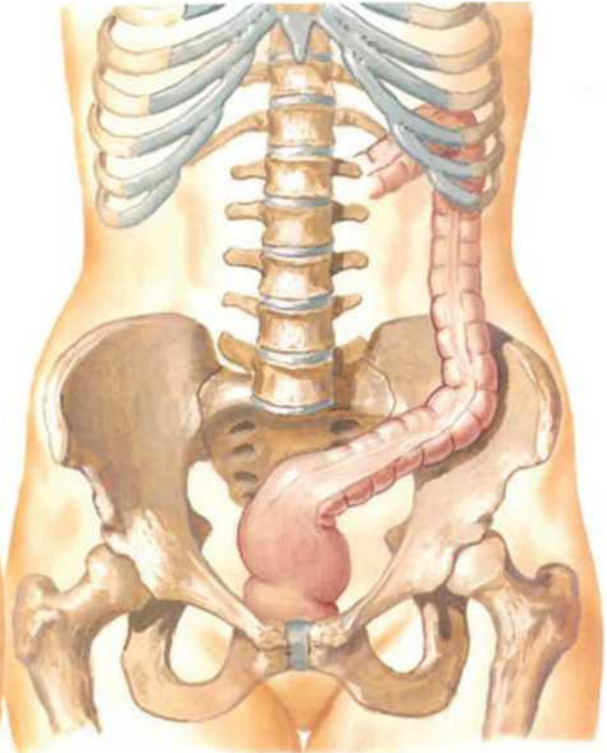


Sigmasimon ichak (colon sigmoideum): joylashish turlari

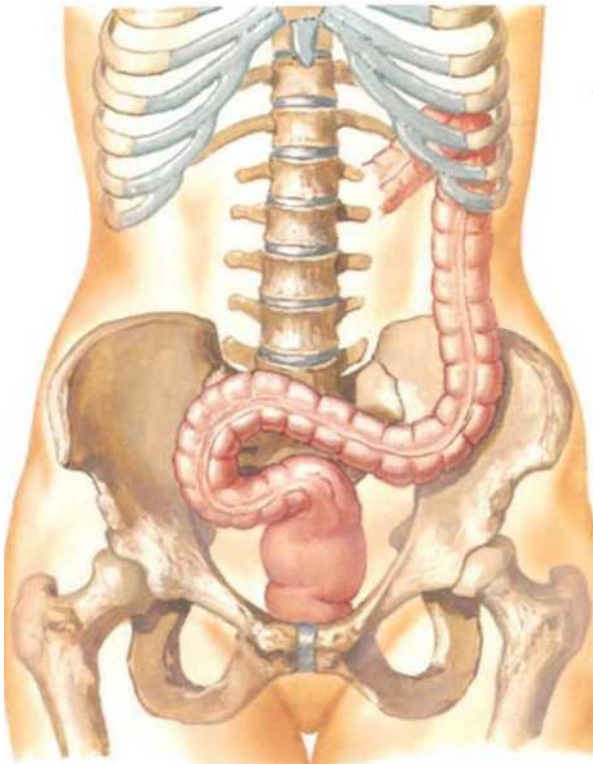
337. 338. 363-366-rasmlar.



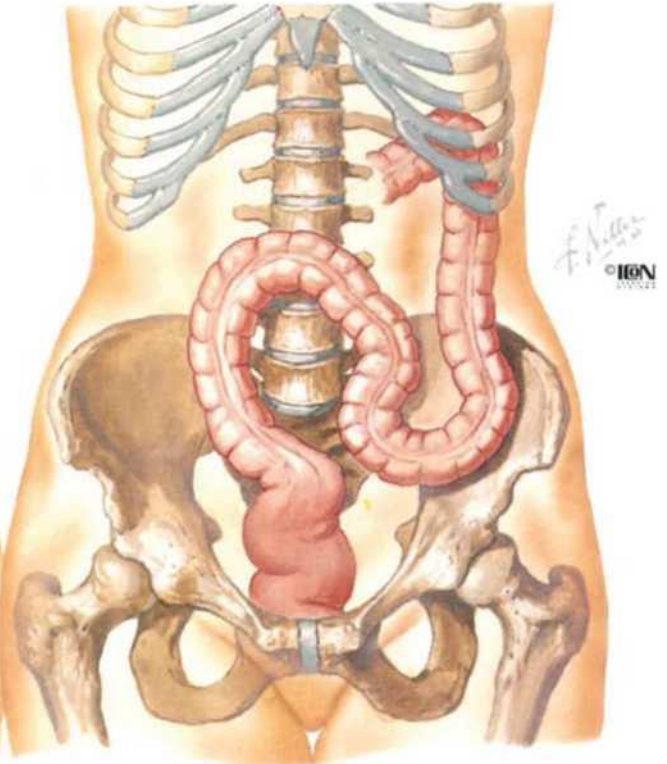
Tipik holat



Kalta, chanoq bo'shlig'ida qiyshiq joylashadi

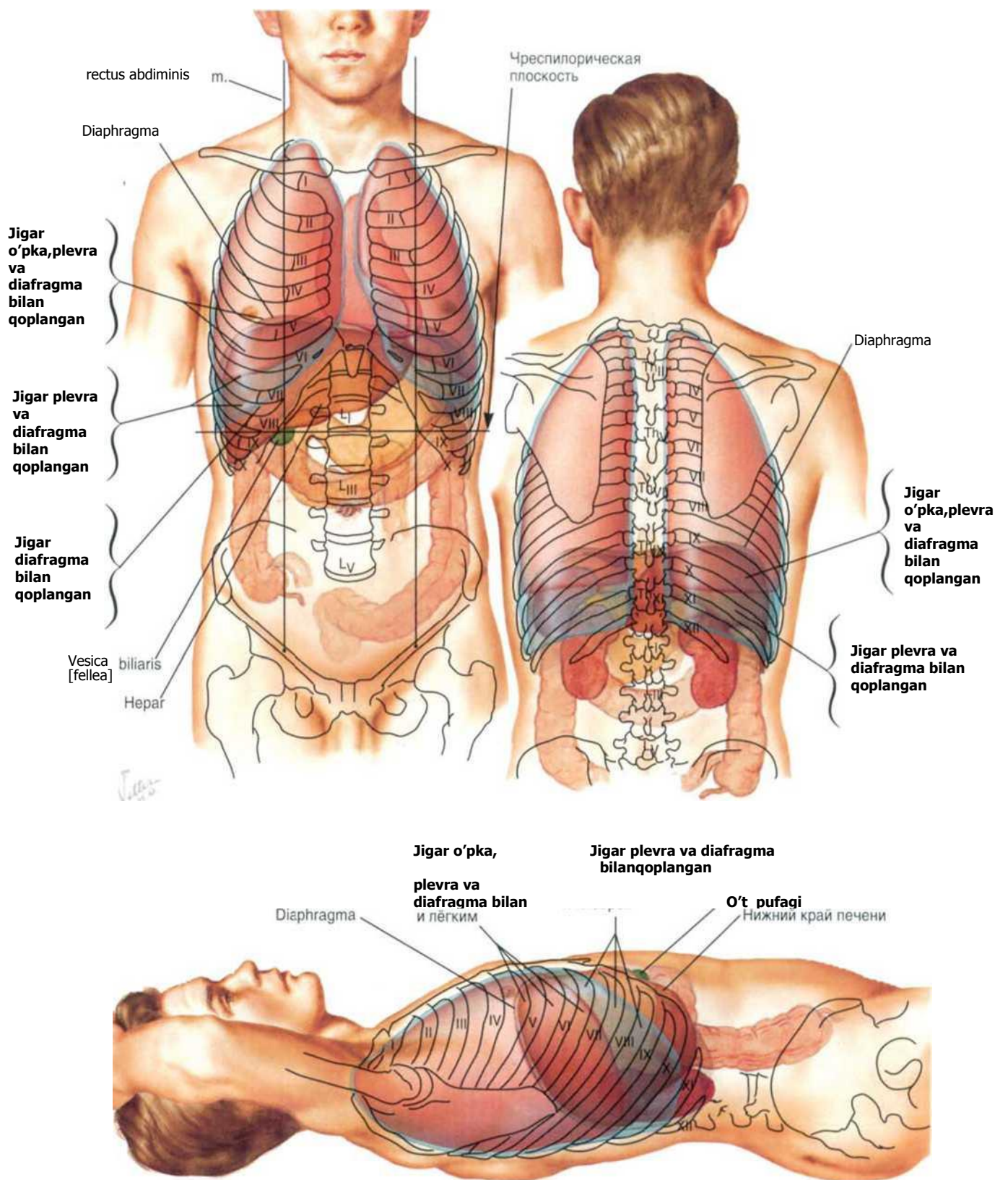


Ilmoq ko'rinishida o'ng tomonga surilgan

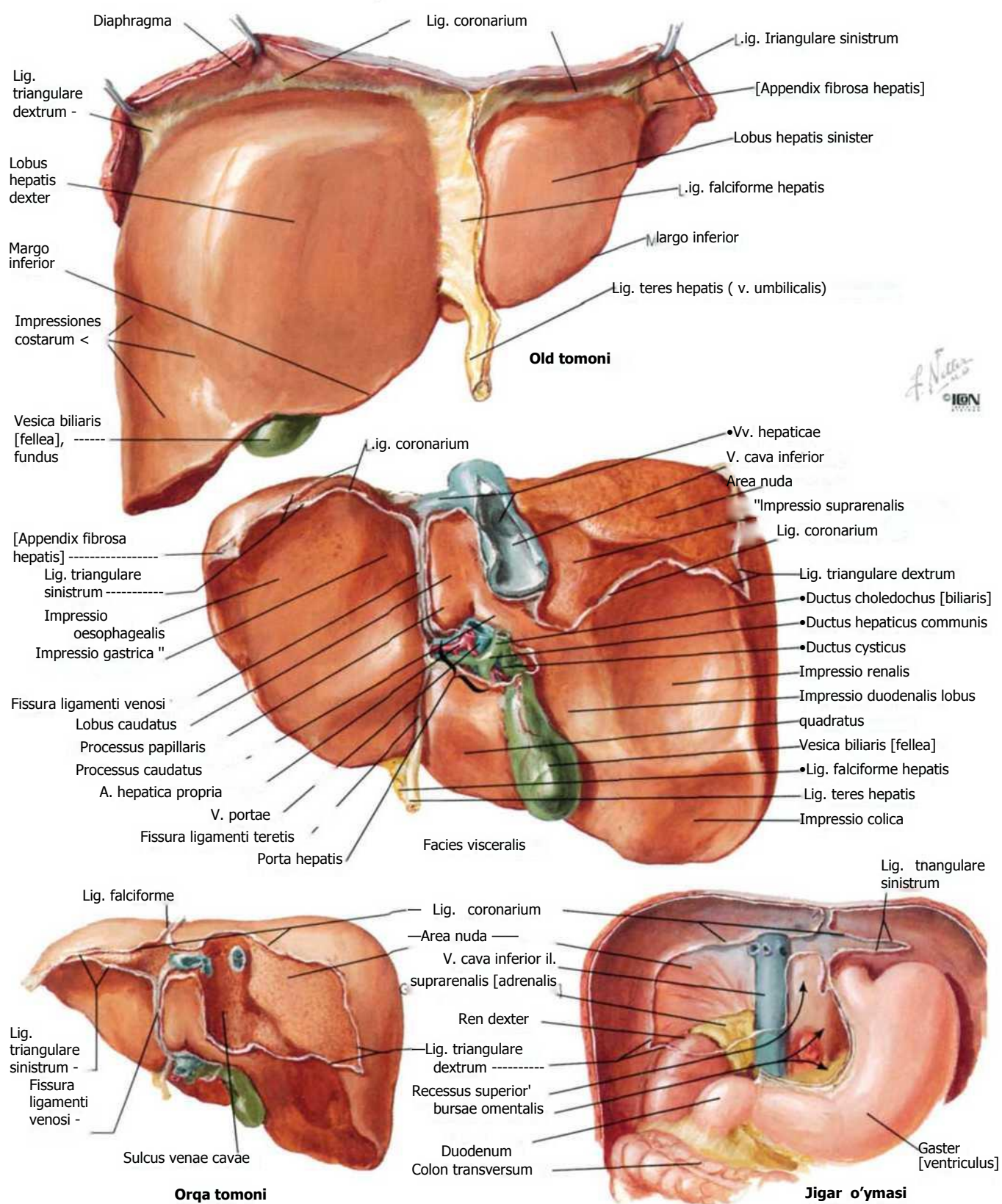


Yuqoriga, qorin bo'shlig'iga ko'tarilgan holati

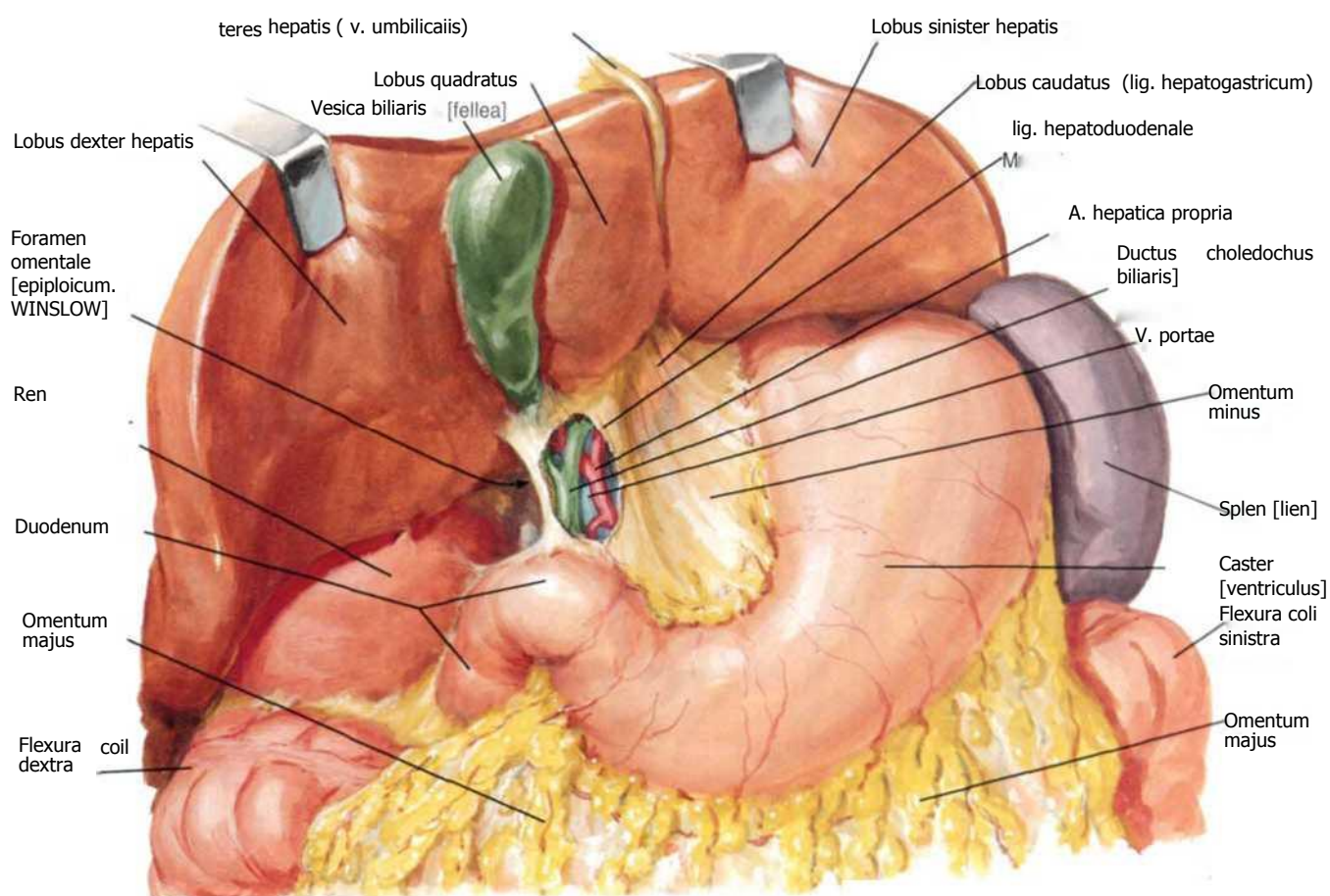
Jigar (hepat): topografiya



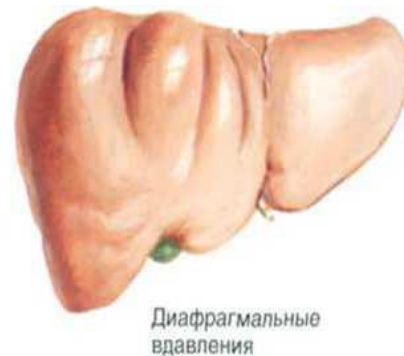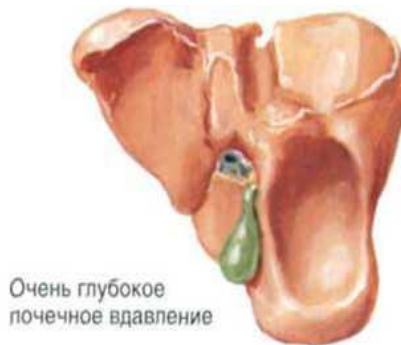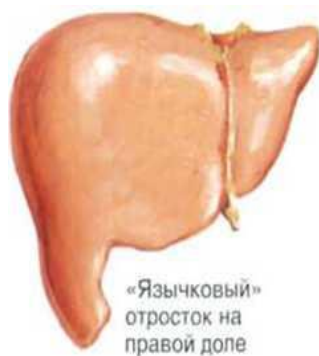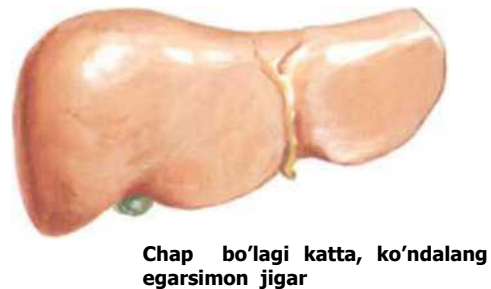
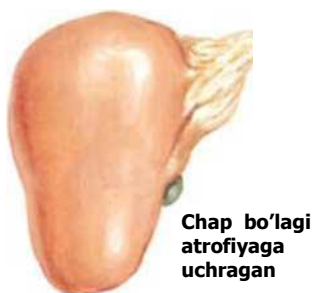
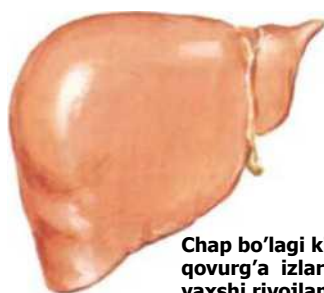Jigar (hepat): yuzalari



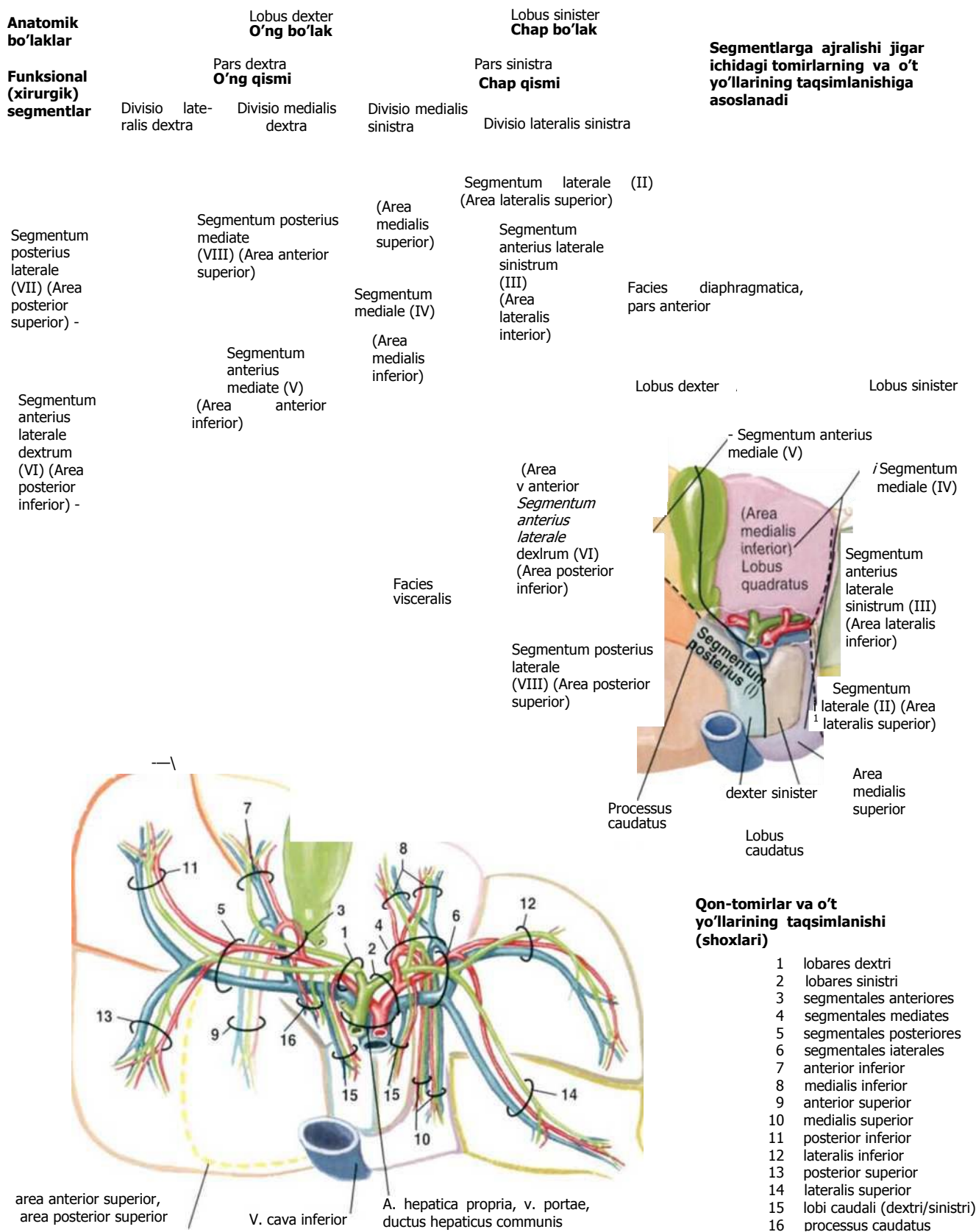
Jigar (hepar): shakllari



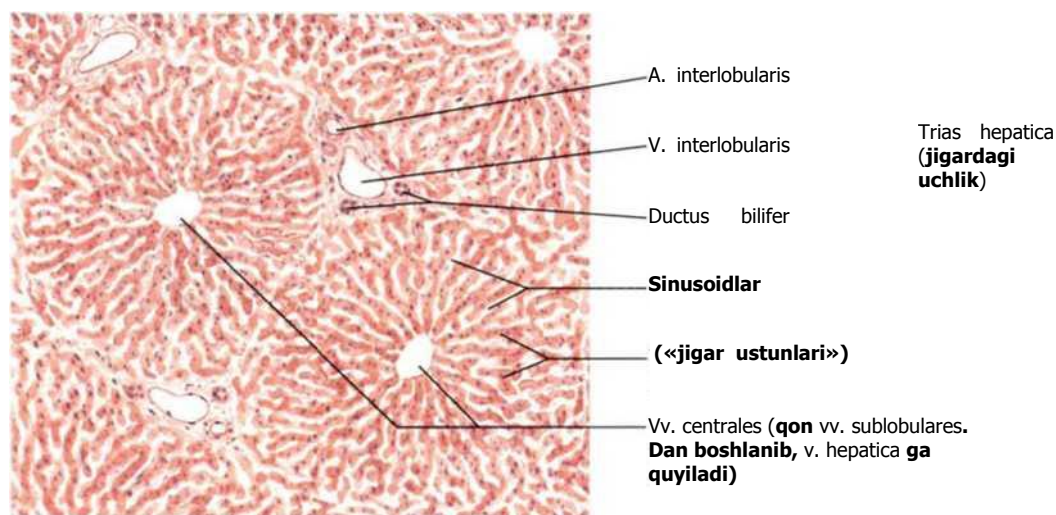
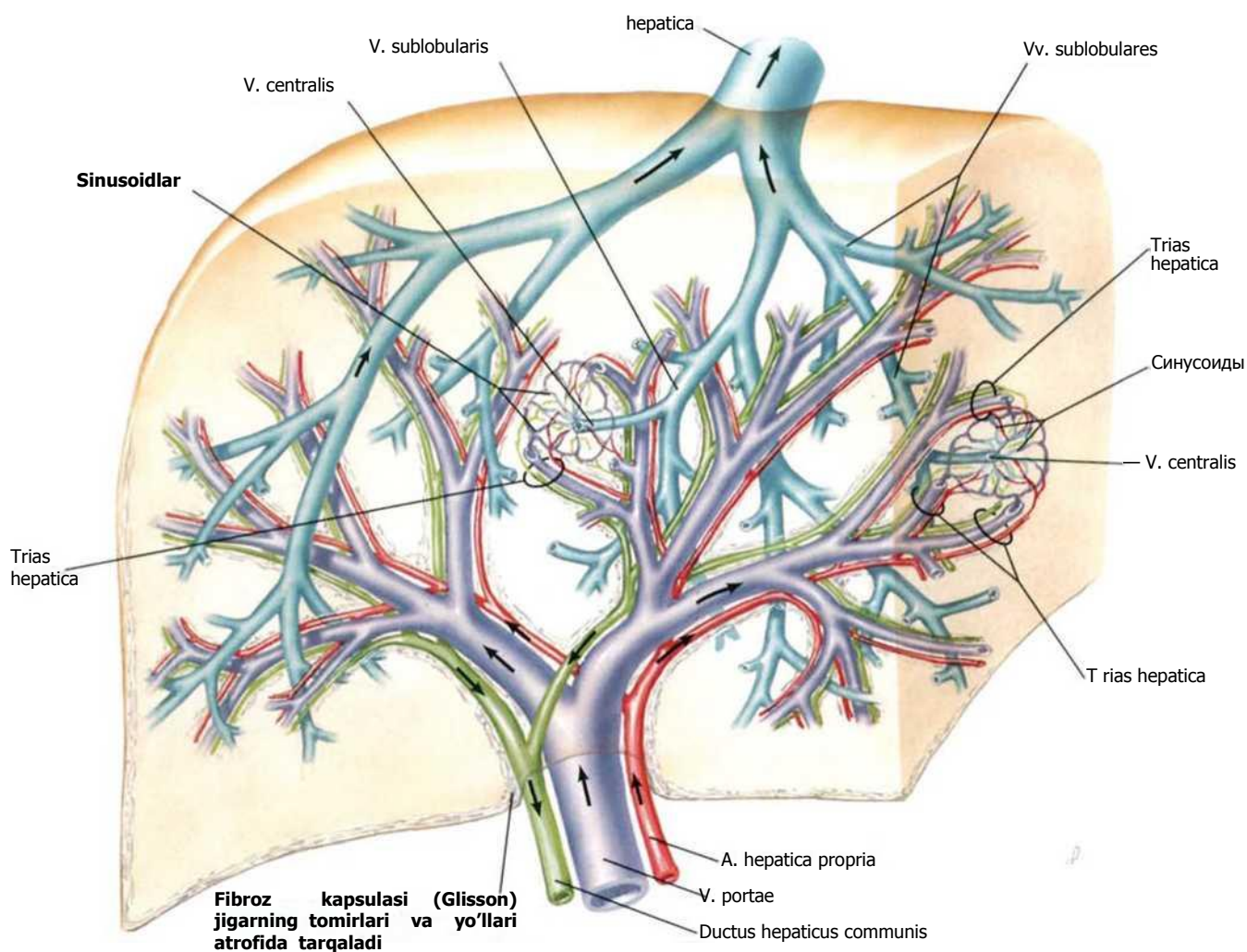
Jigar shakllarining turlari



Jigar segmentlari va bo'laklari: tomir va o't yo'llarining taqsimlanishi

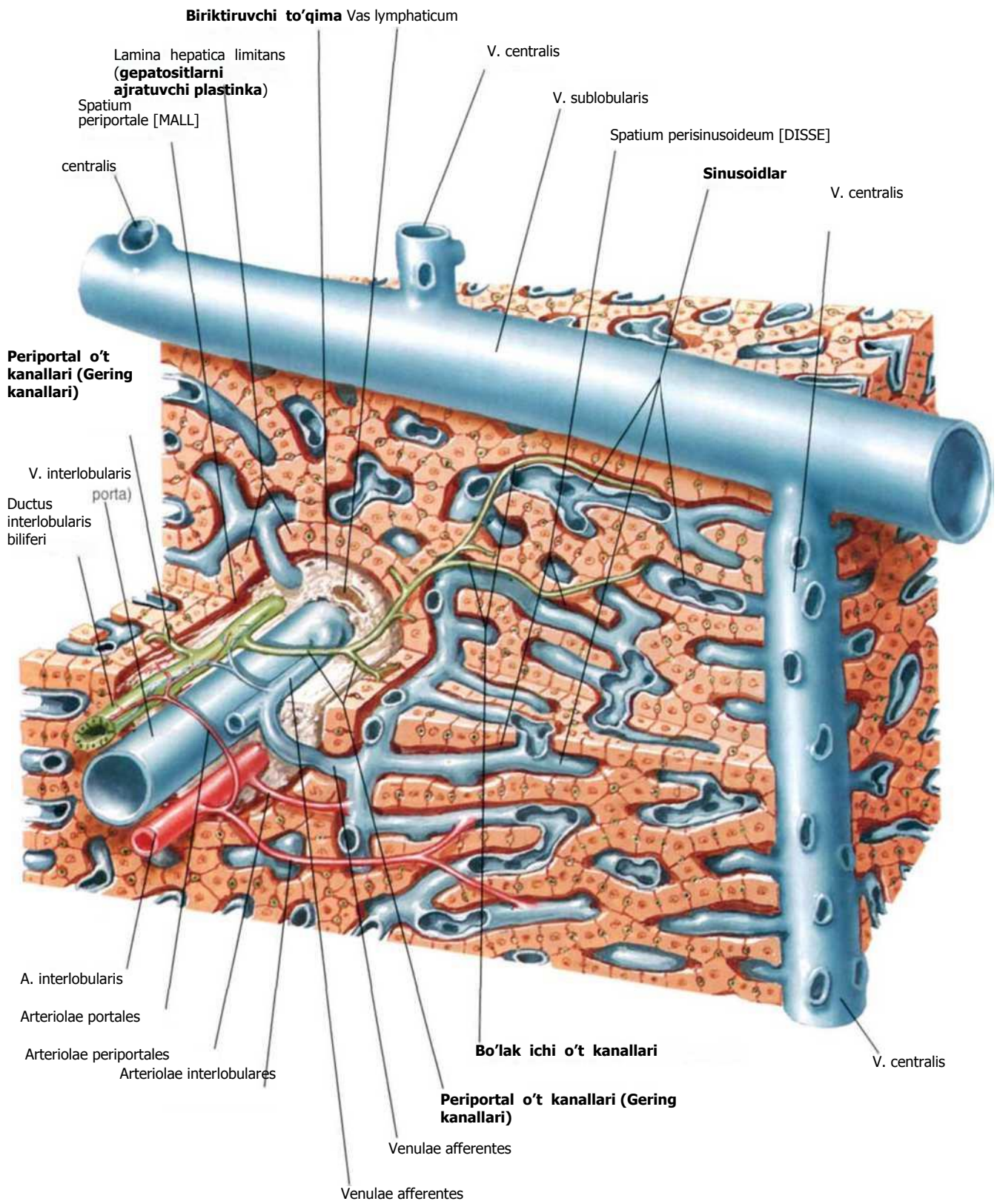


Jigar ichi tomirlari va o't yo'llari

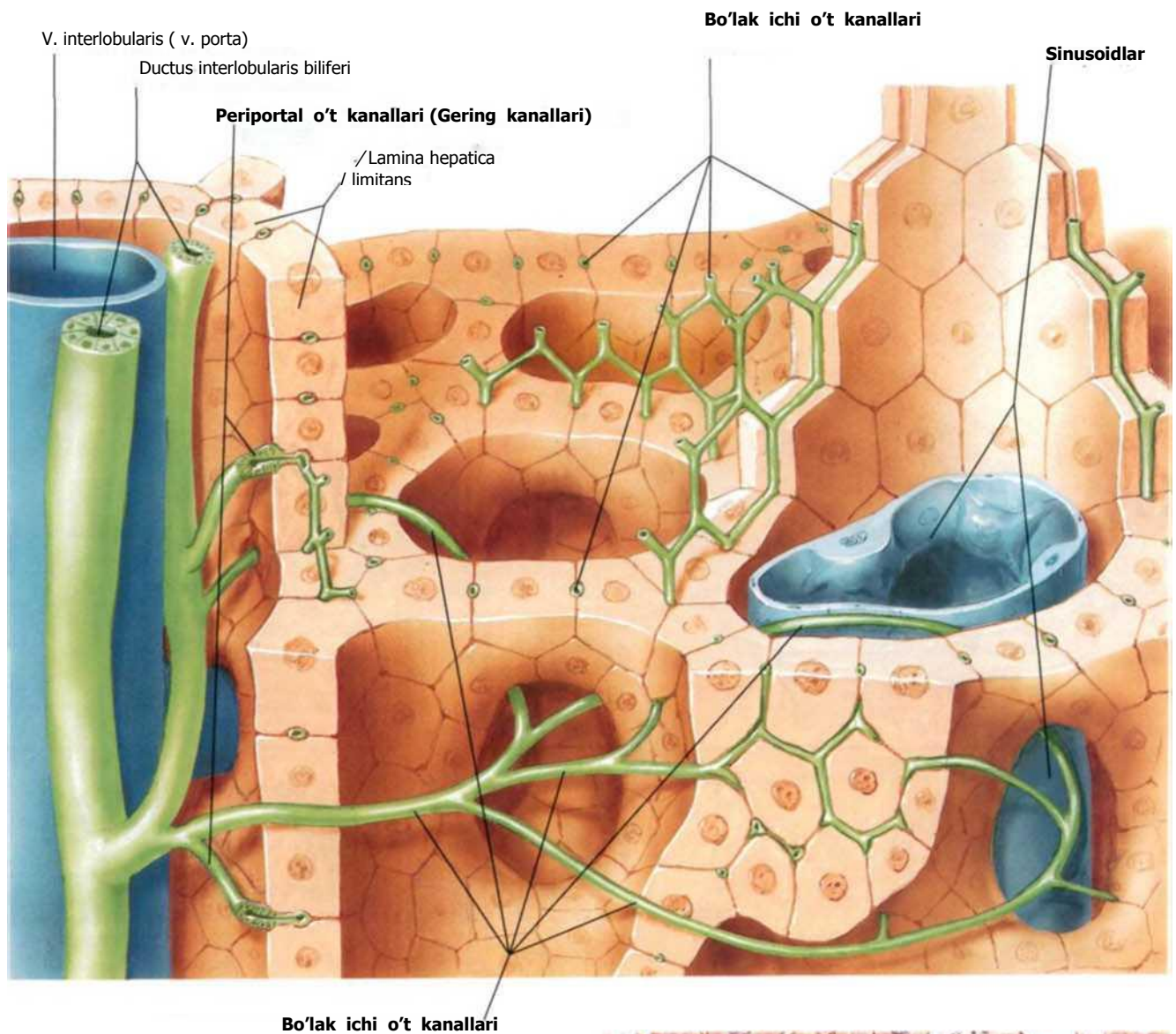


Jigar bo'lakchalarining tuzilishi

Jigarning tuzilishi : sxemasi

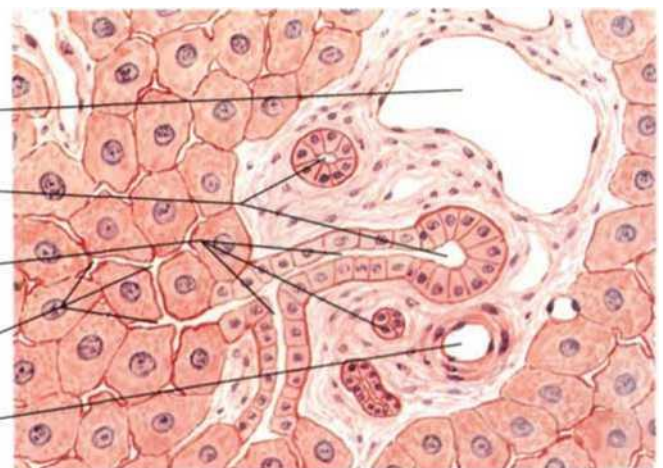


Jigar ichidagi o't hosil bolish tizimi: sxemasi



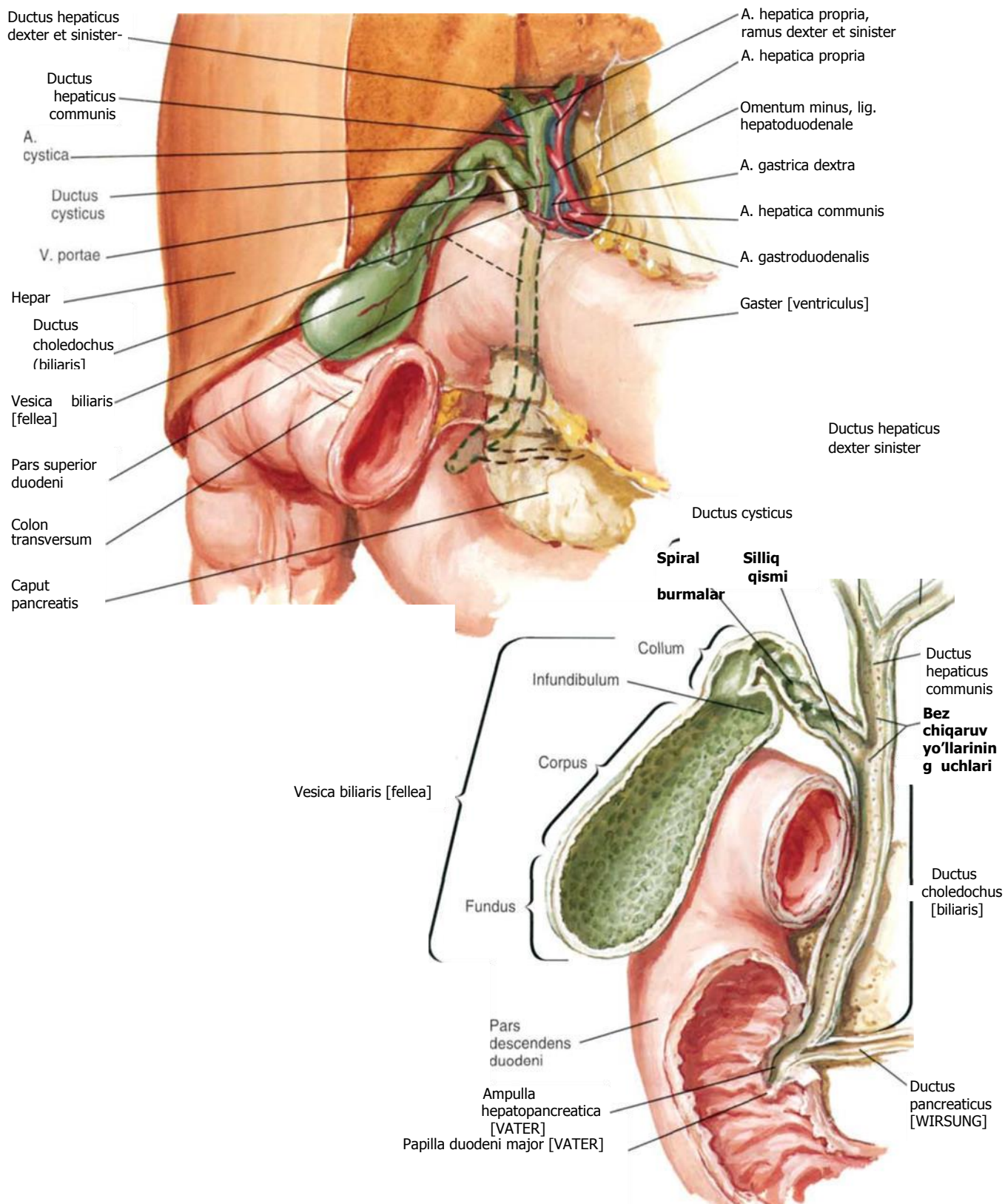
Sxemada o't kanalchalari xususiyl devorga ega bo'lgan naylar ko'rinishida bo'lib, kanalchalarning to'rlari gepatosit o't yo'llarining qutblari birikishidan hosil bo'ladi. Yani kanalchalarning devorini gepatositlarning plazmatik membranasi tashkil qiladi

V. interlobularis
v. porta)
Ductus
interlobulares biliferi
Periportal o't
kanallari (Gering
kanallari)
Bo'lak ichi o't
kanallari
A. interlobularis



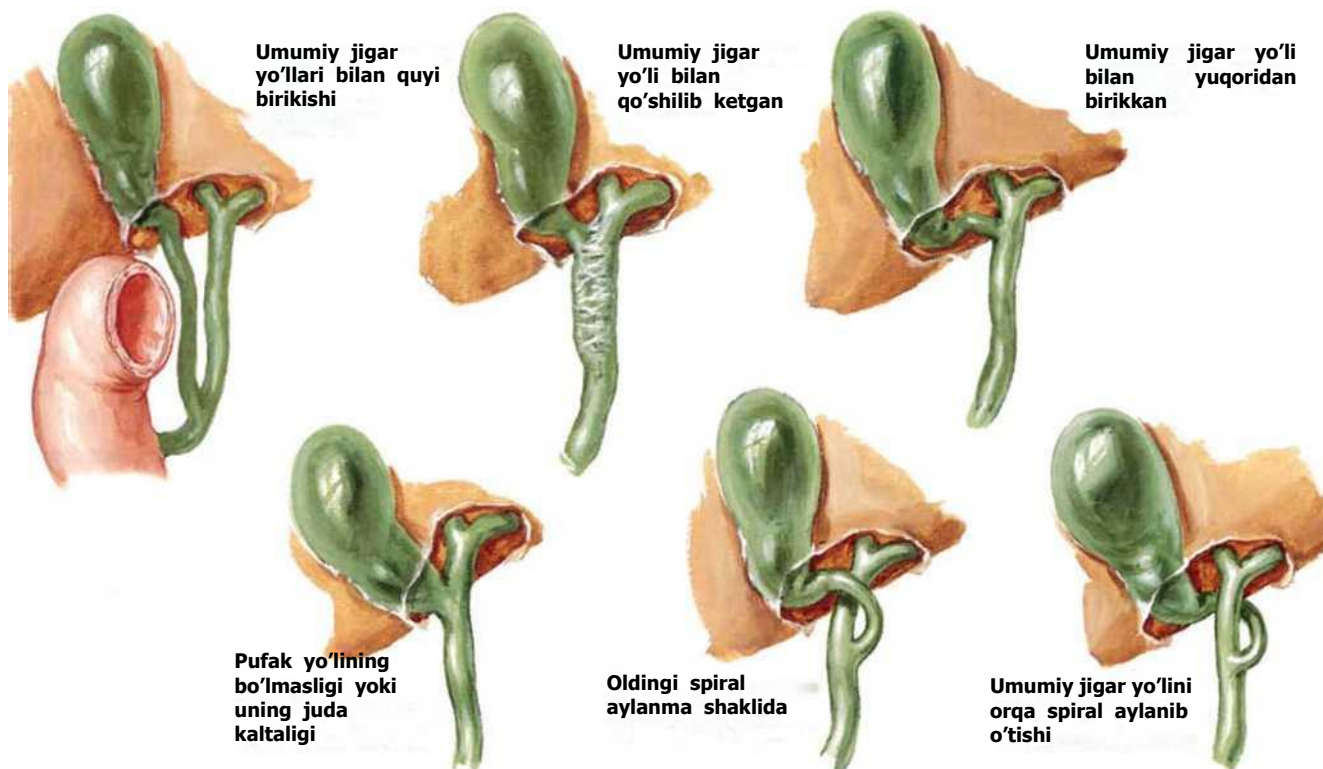
Jigarning mikroskopik ko'ronishi

O't pufagi va jigardan tashqari o't yo'llari

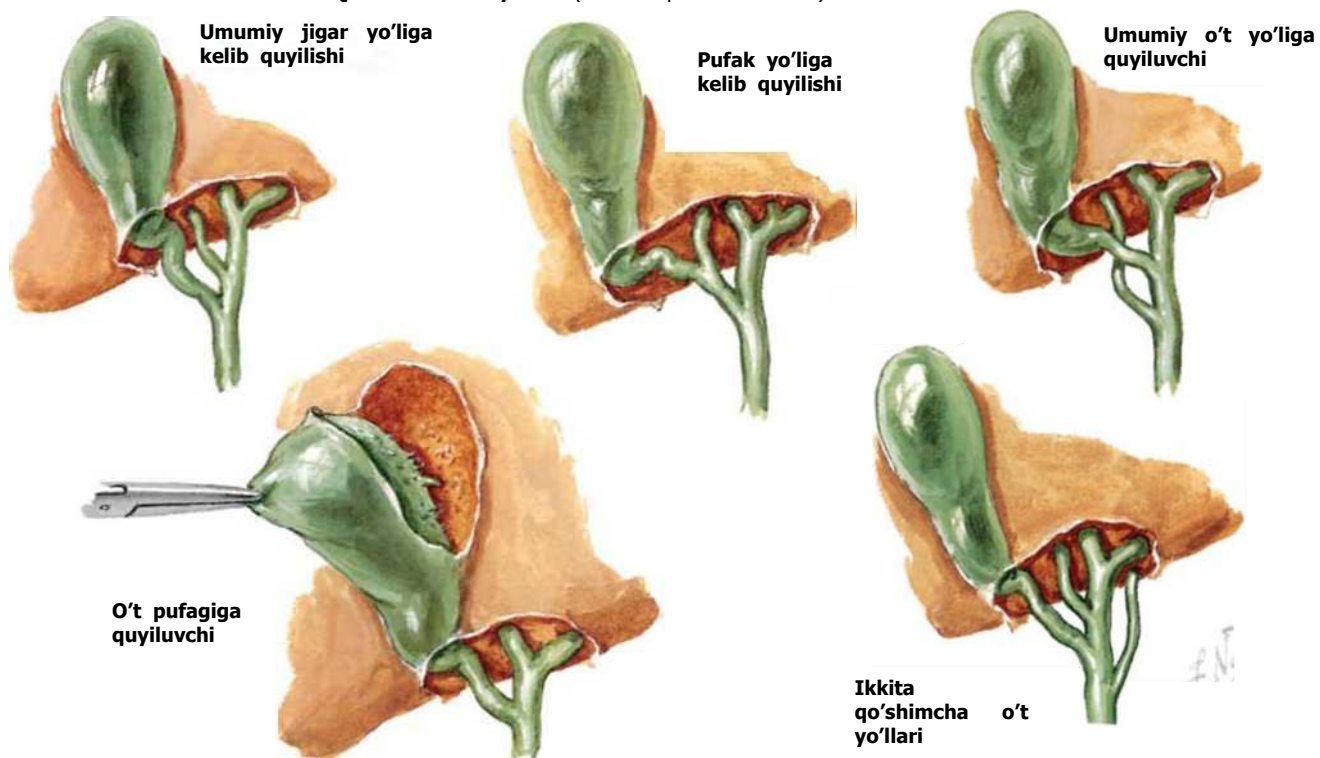


O't pufagi va o't yo'llarining turlari

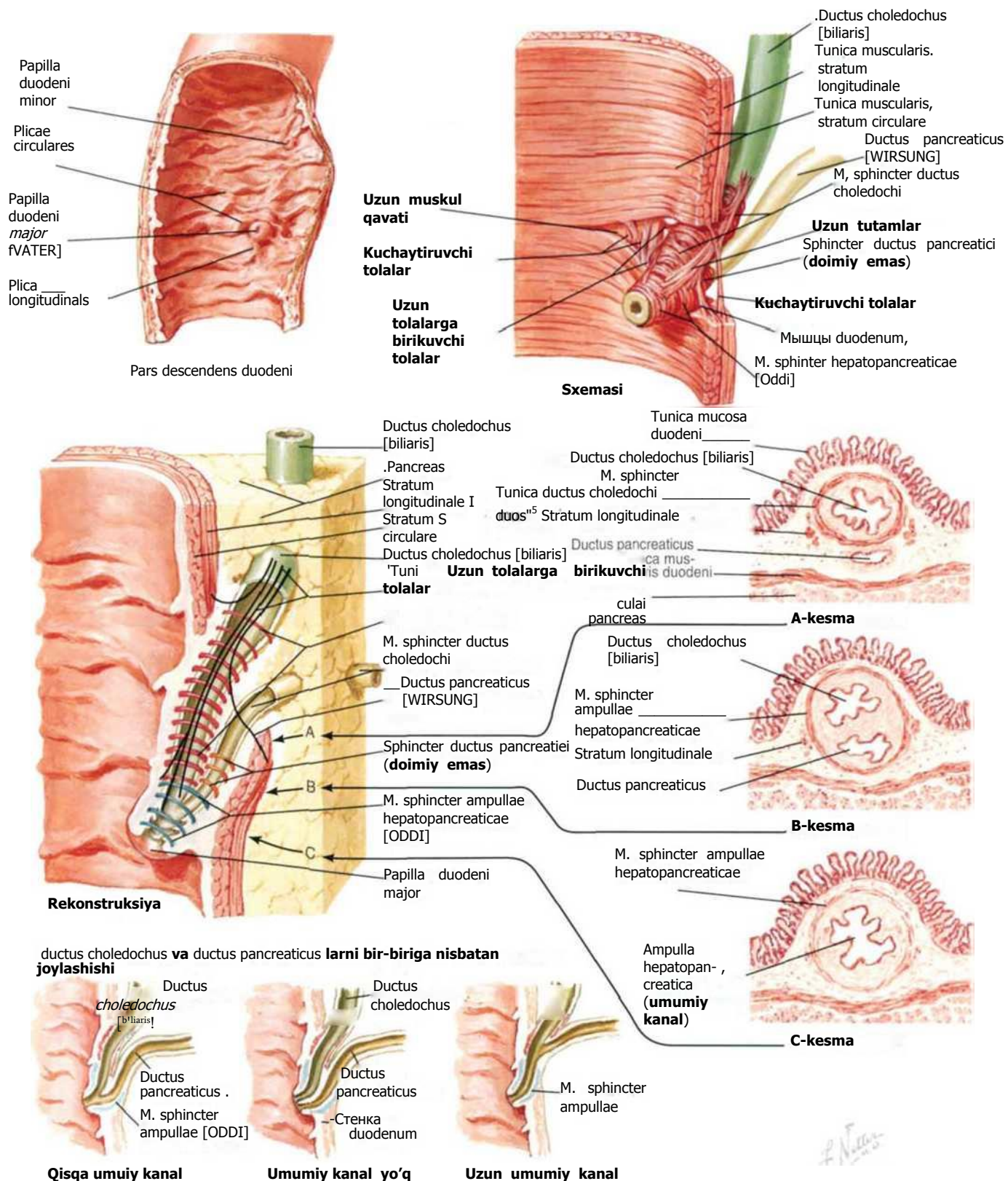
Pufak yo'llarining tuzilishi va uning turlari



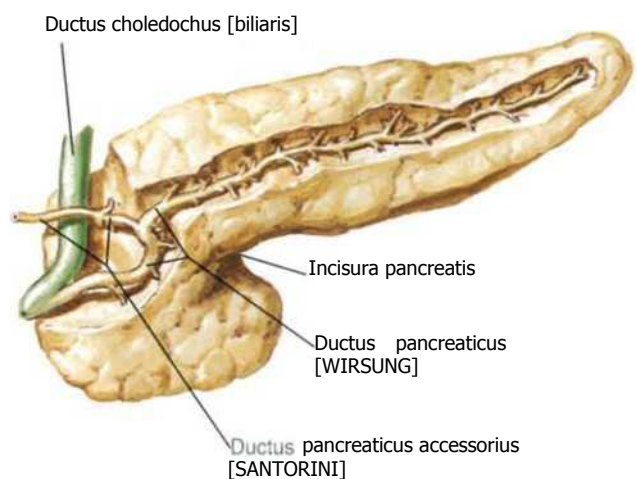
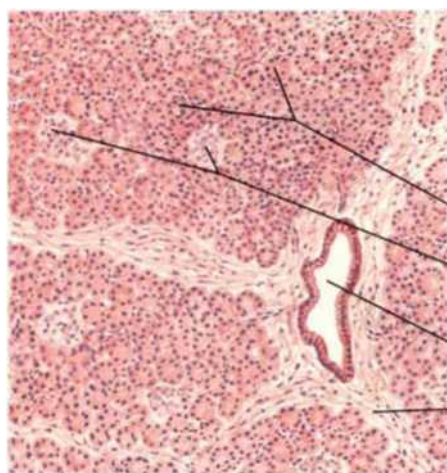
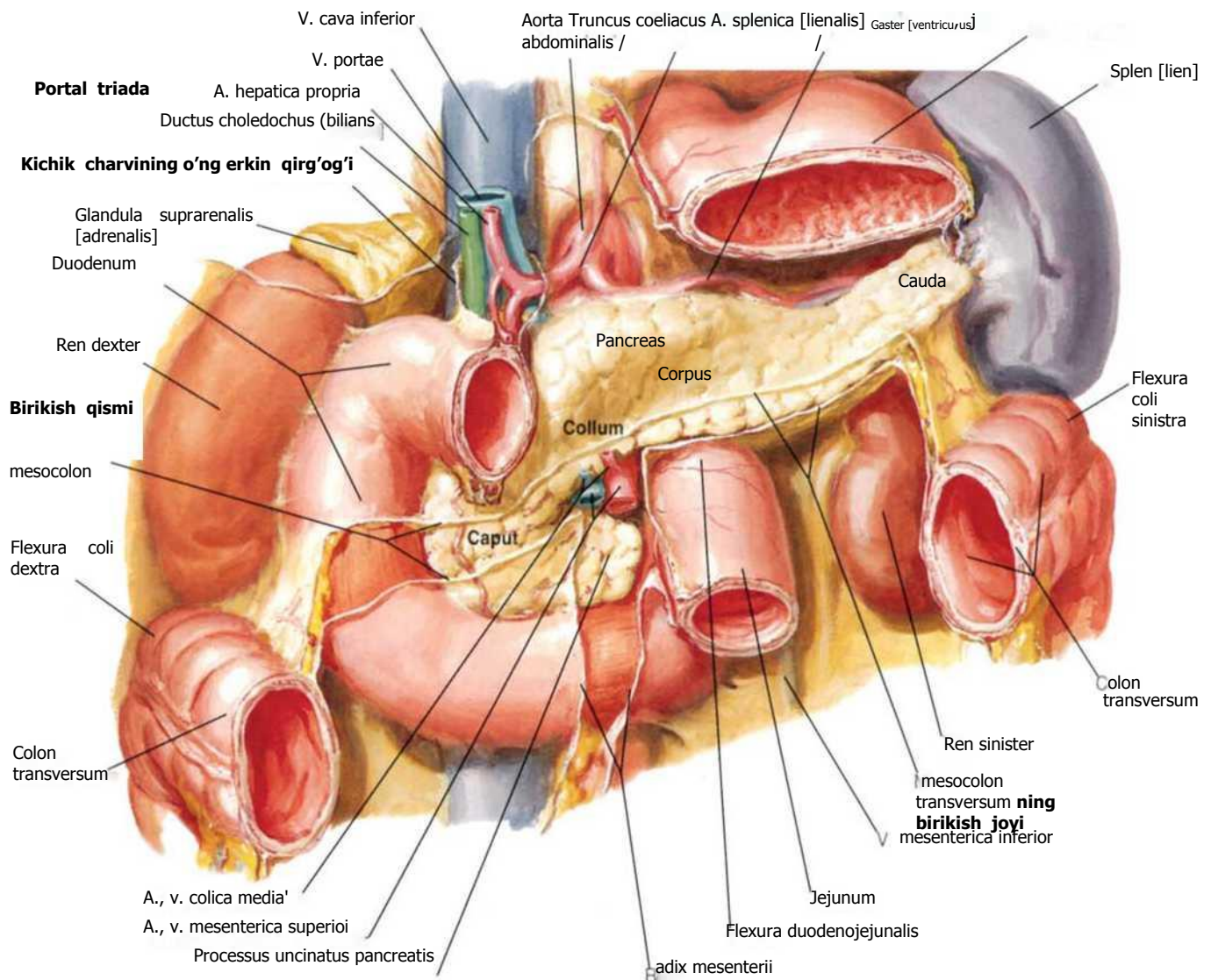
Qo'shimcha o't yo'llari (ductus hepatici abberantes)



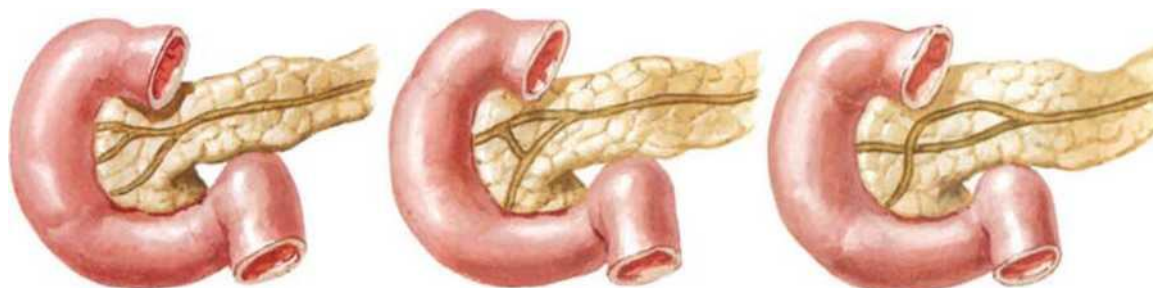
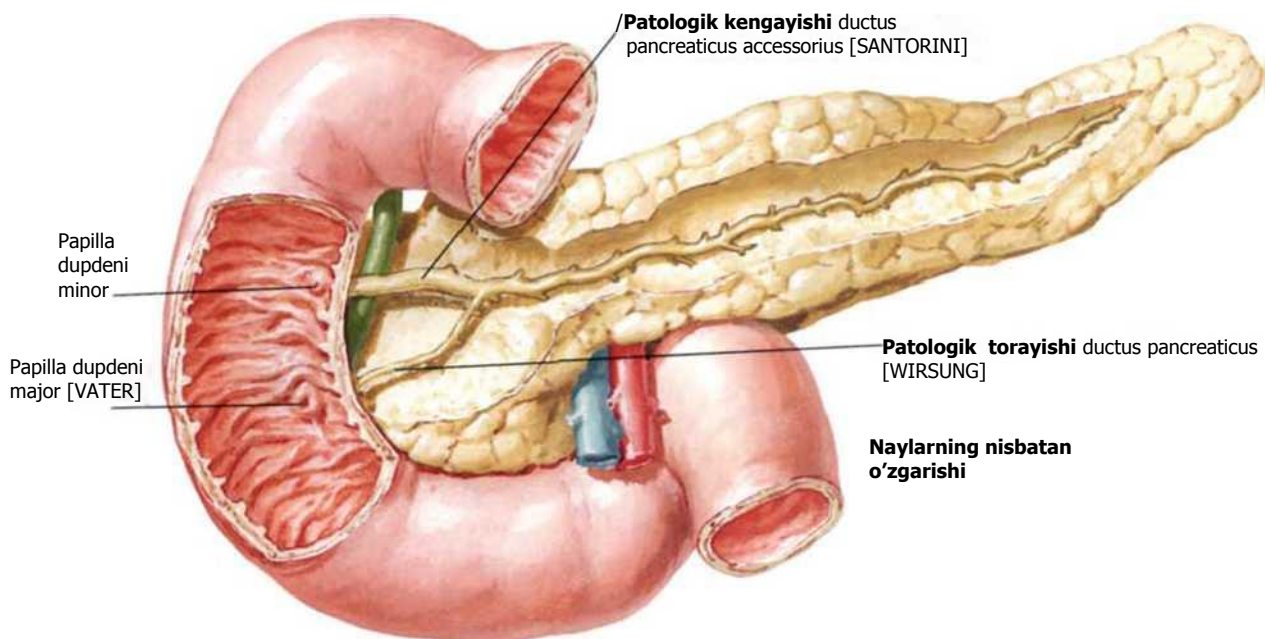
Umumiy o't yo'lini o'n ikki barmoq ichak bilan birikishi



Me'da osti bezi (pancreas)



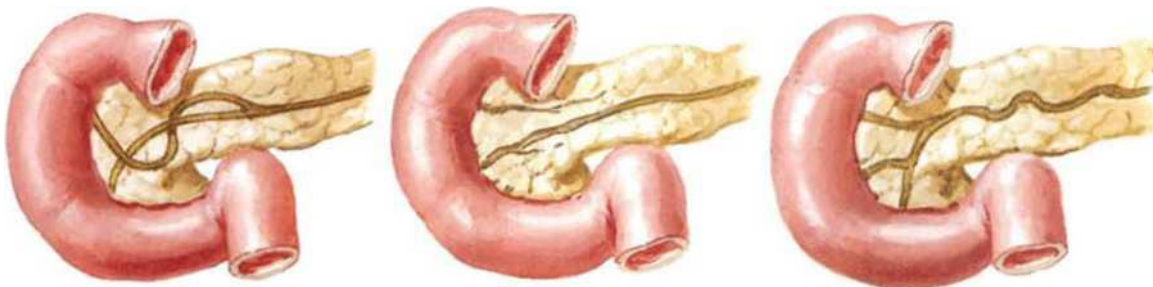Me'da osti bezi yo'llarining tuzilish turlari



ductus pancreaticus **ning** ikkilanishi accessorius [SANTORINI]

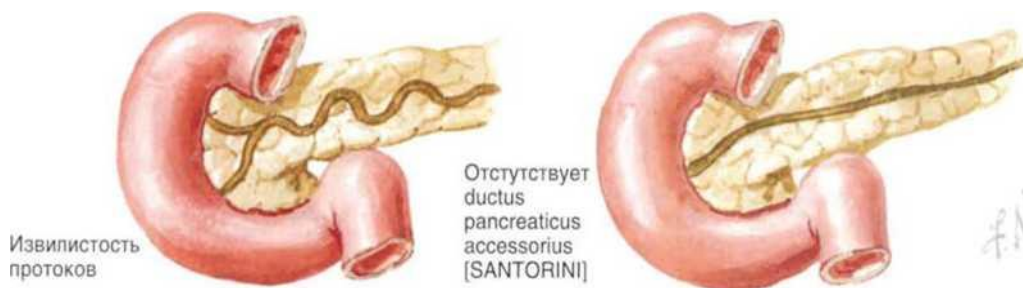
Naylararo anastomoz

Naylarning kesishuvi

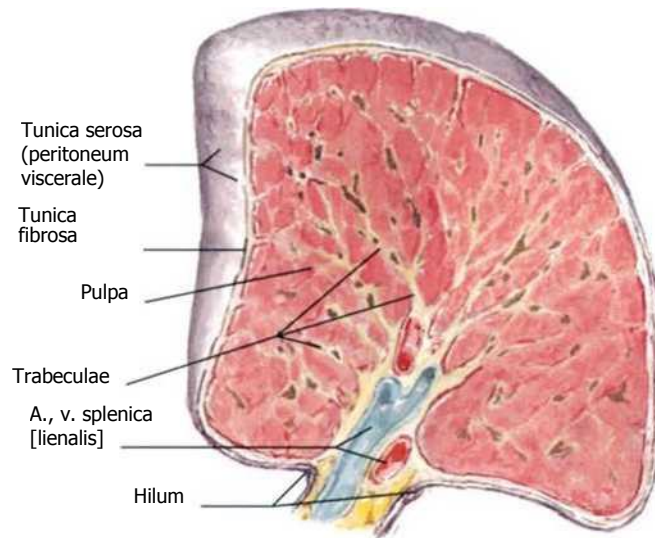
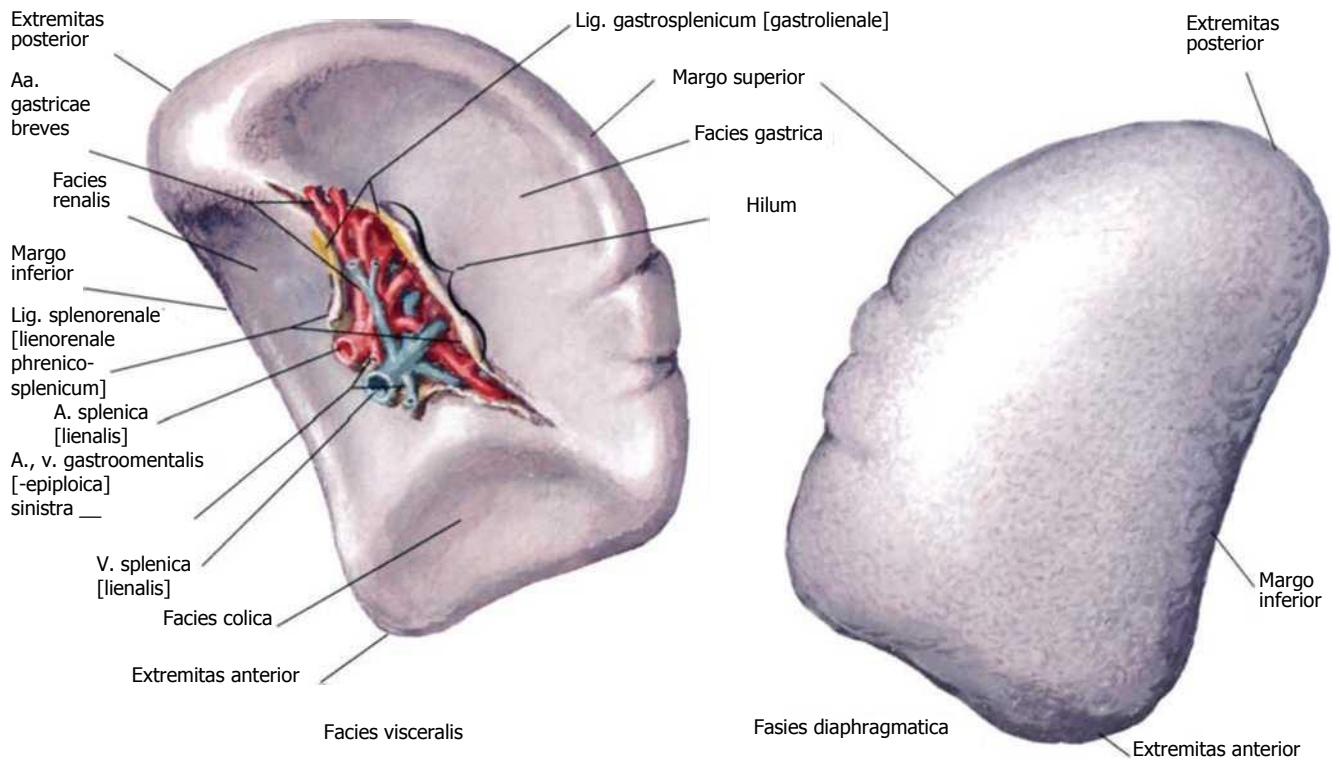


Naylarning ikkilangan kesishuvi

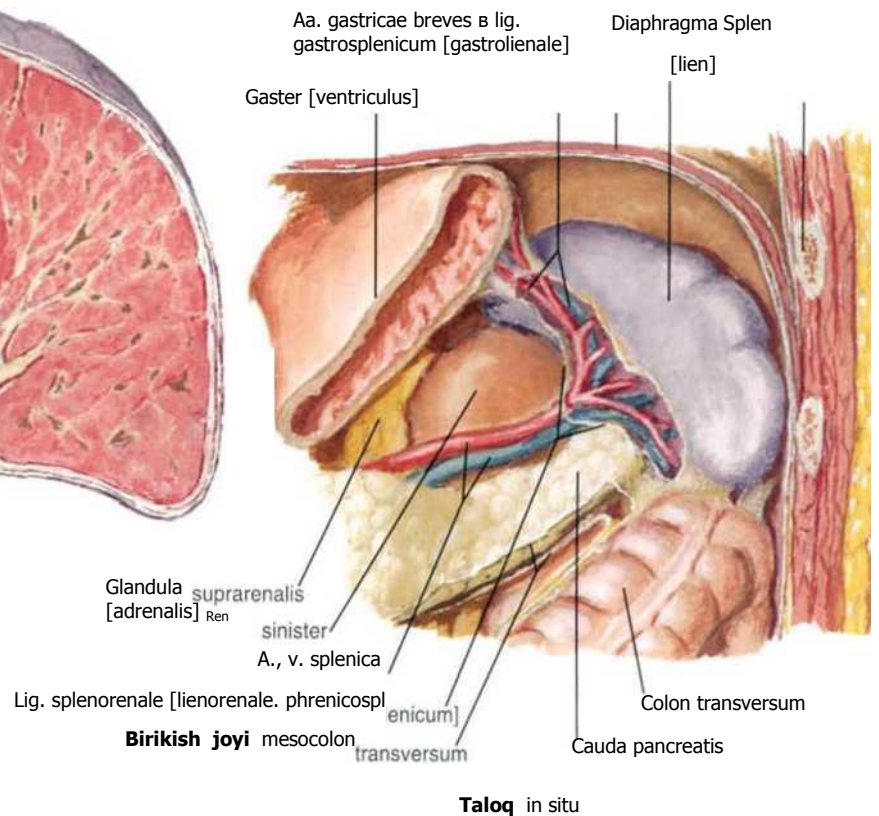
Me'a osti bezi yo'llarining orasida tutashuvni Ikkilanganductuspancreaticus yo'qligi[WIRSUNG]



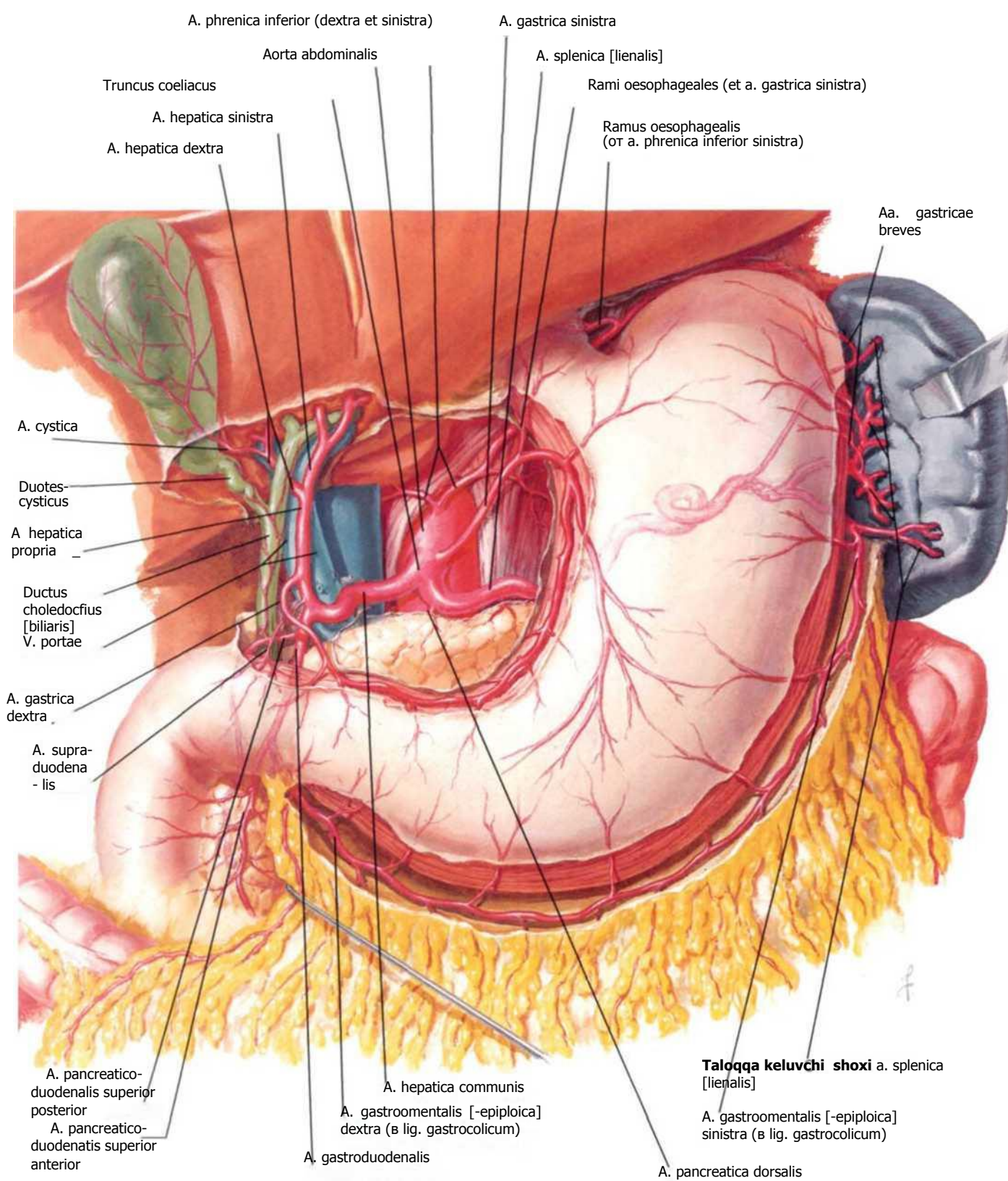
Taloq (splen [lien])



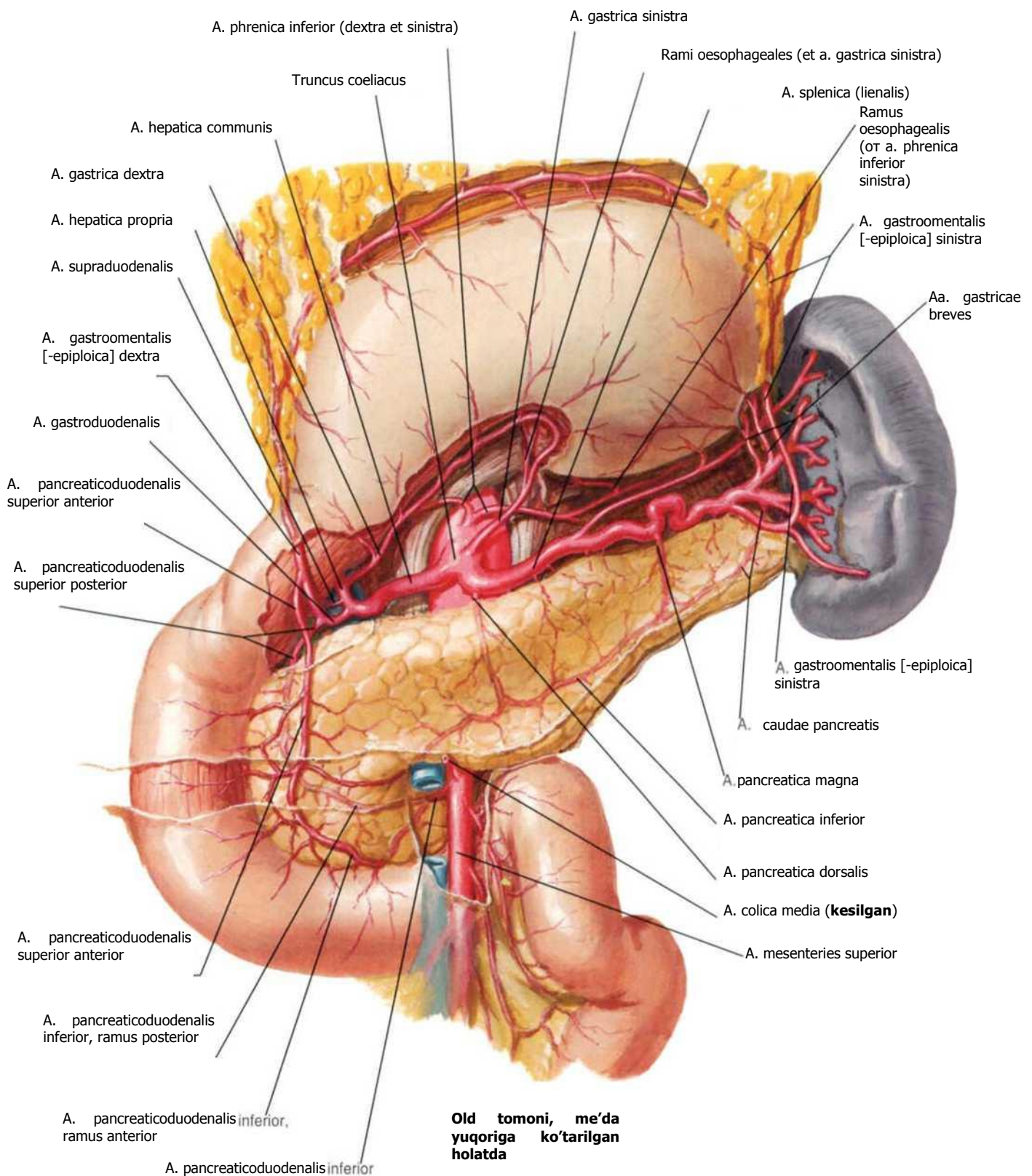
Ko'ndalang kesim



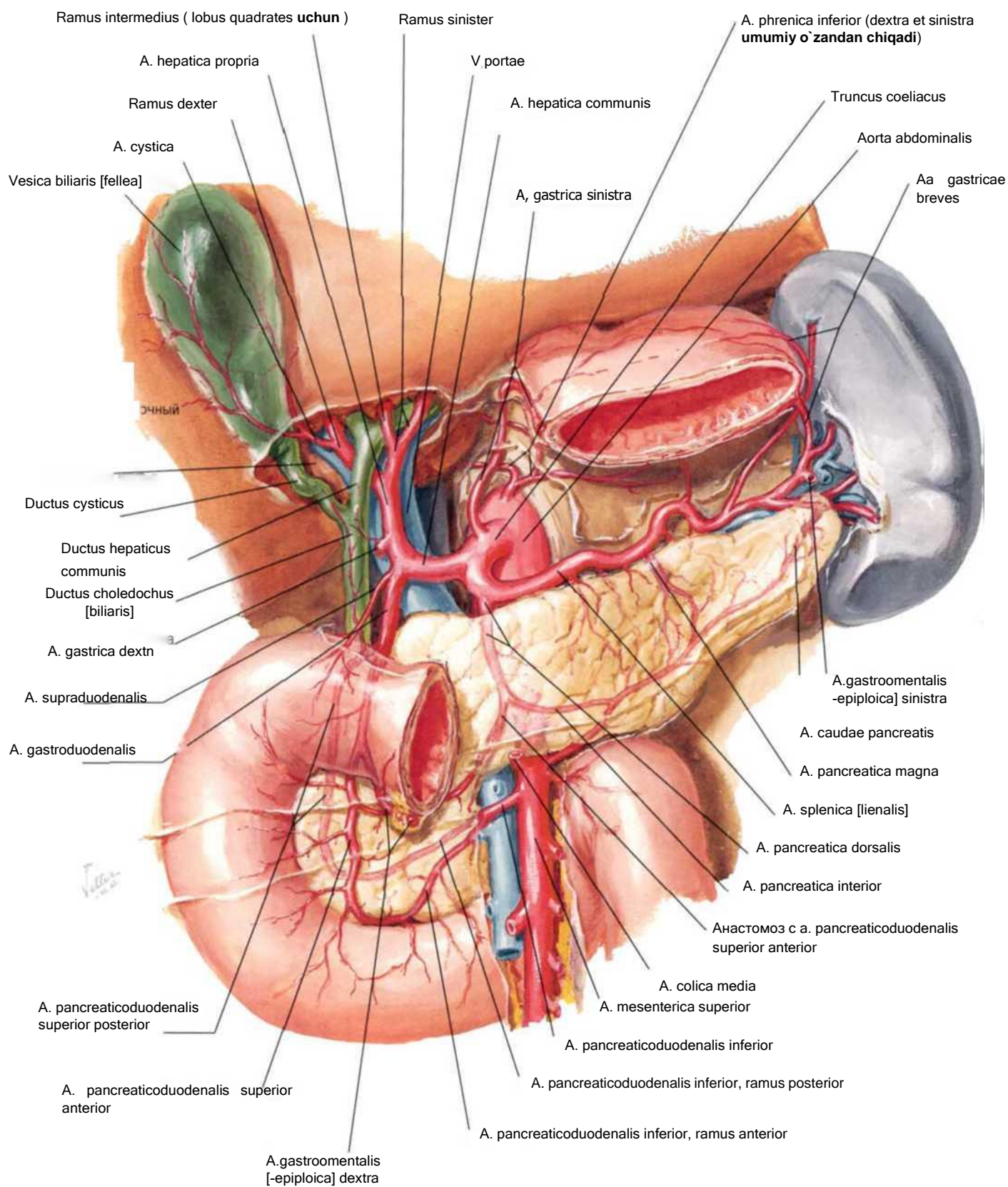
Me'da ,jigar va taloq arteriyalari



Me'da, o'n ikki barmoq ichak, me'da osti bezi va taloqning arteriyalari

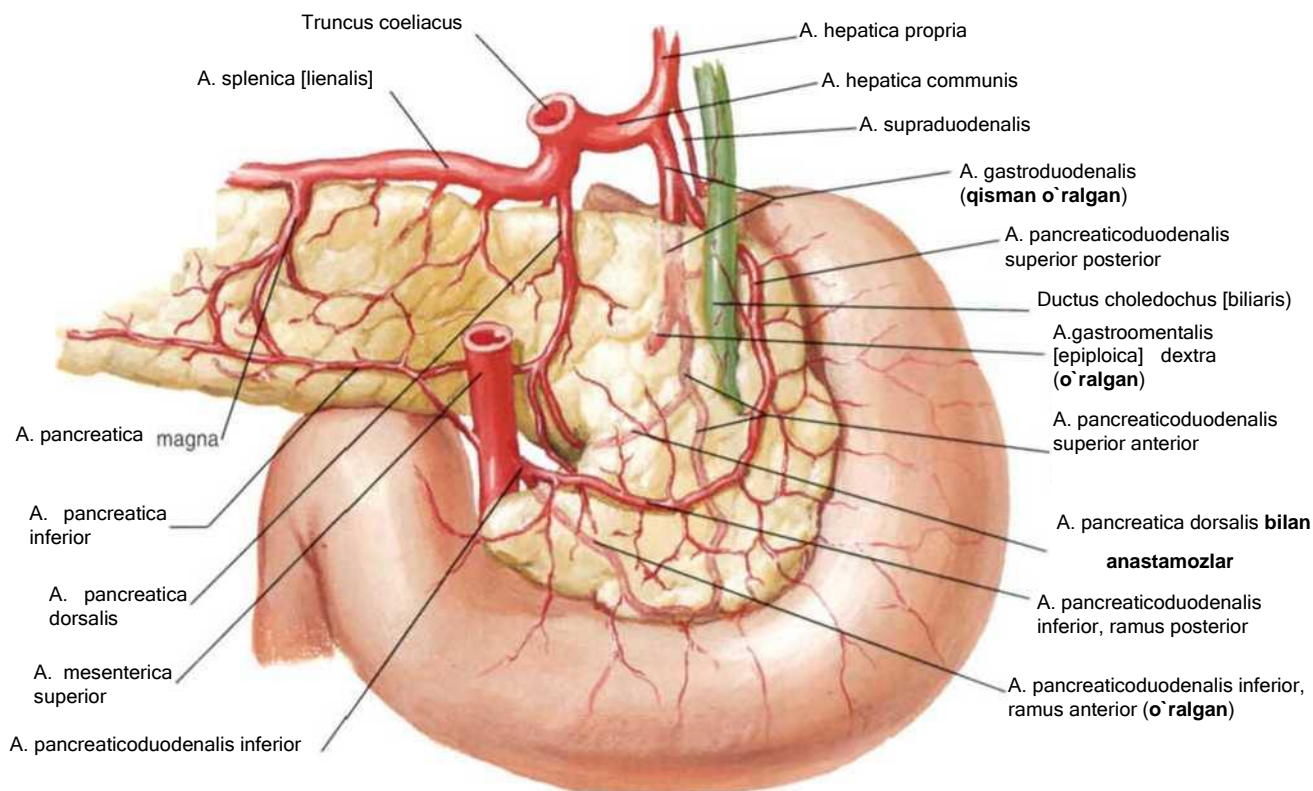
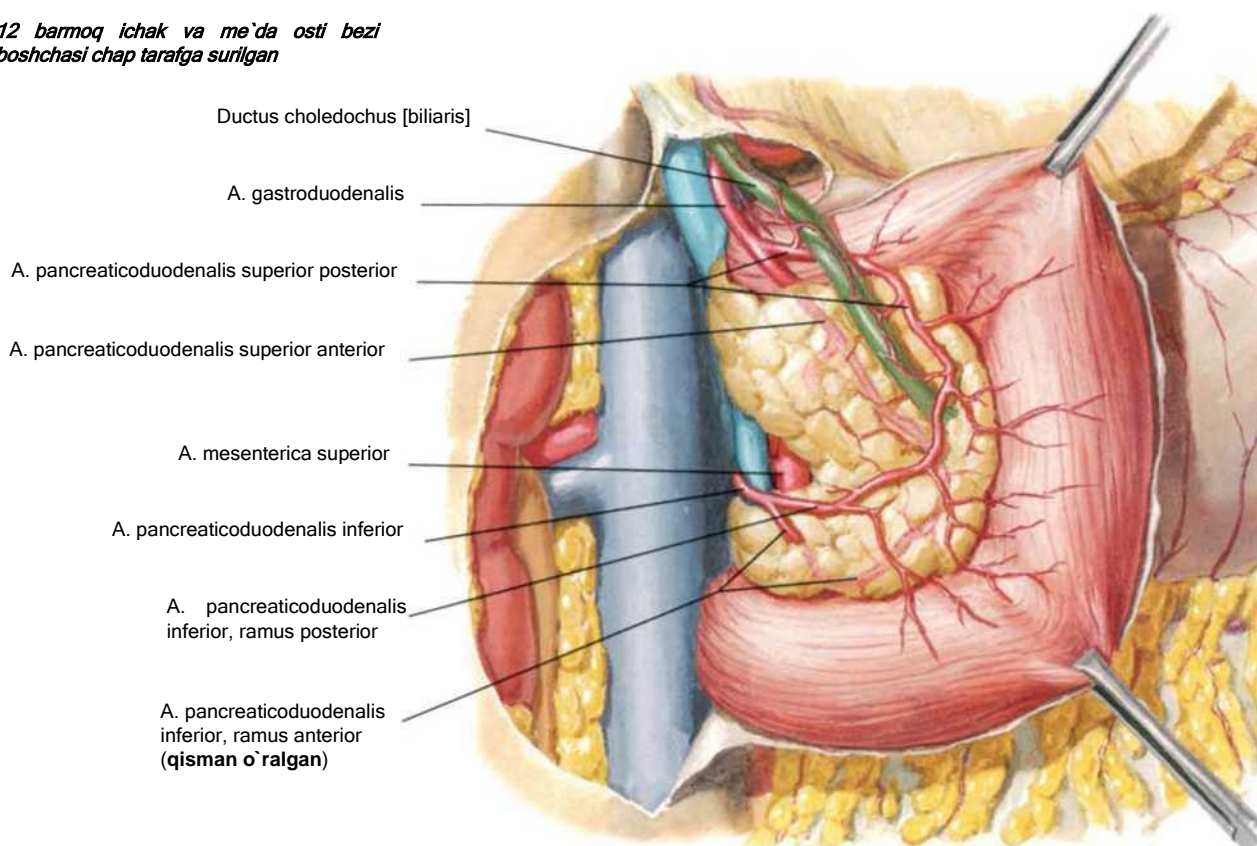


Jigar, 12 barmoq ichak, me`da osti bezi va taloq arteriyalari

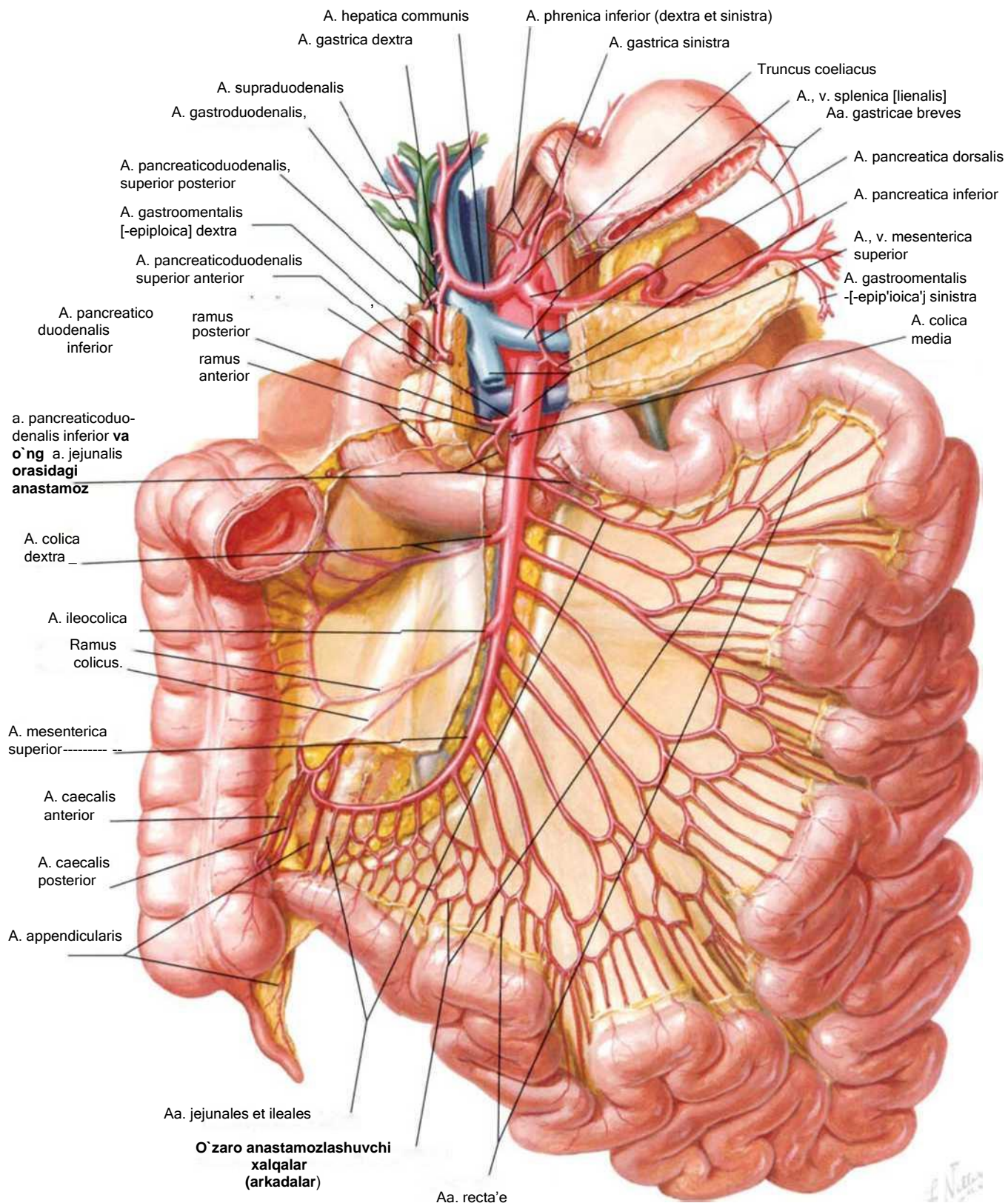


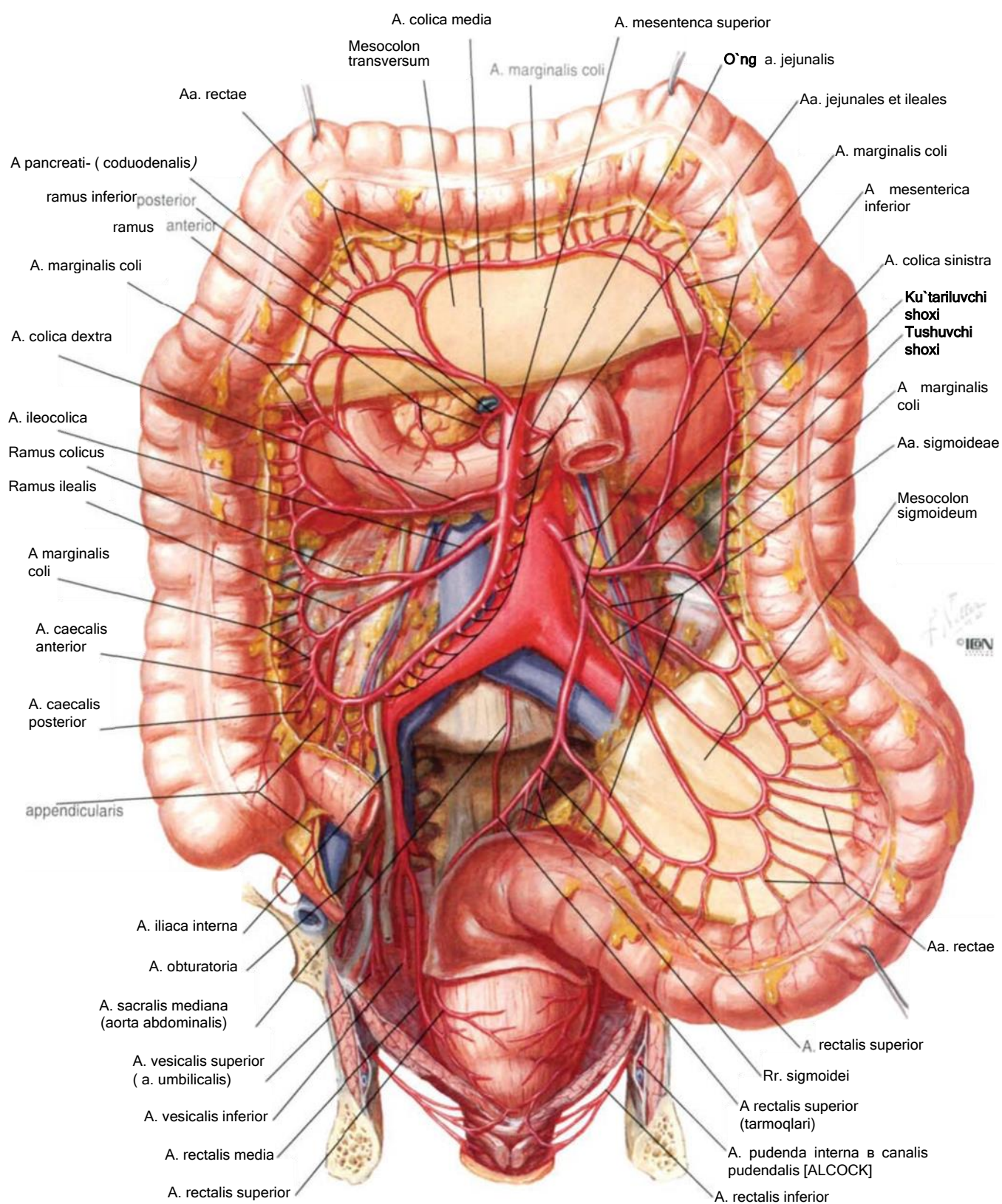
Me`da osti bezining boshchasi va 12 barmoq ichak arteriyalari

12 barmoq ichak va me`da osti bezi
boshchasi chap tarafga surilgan

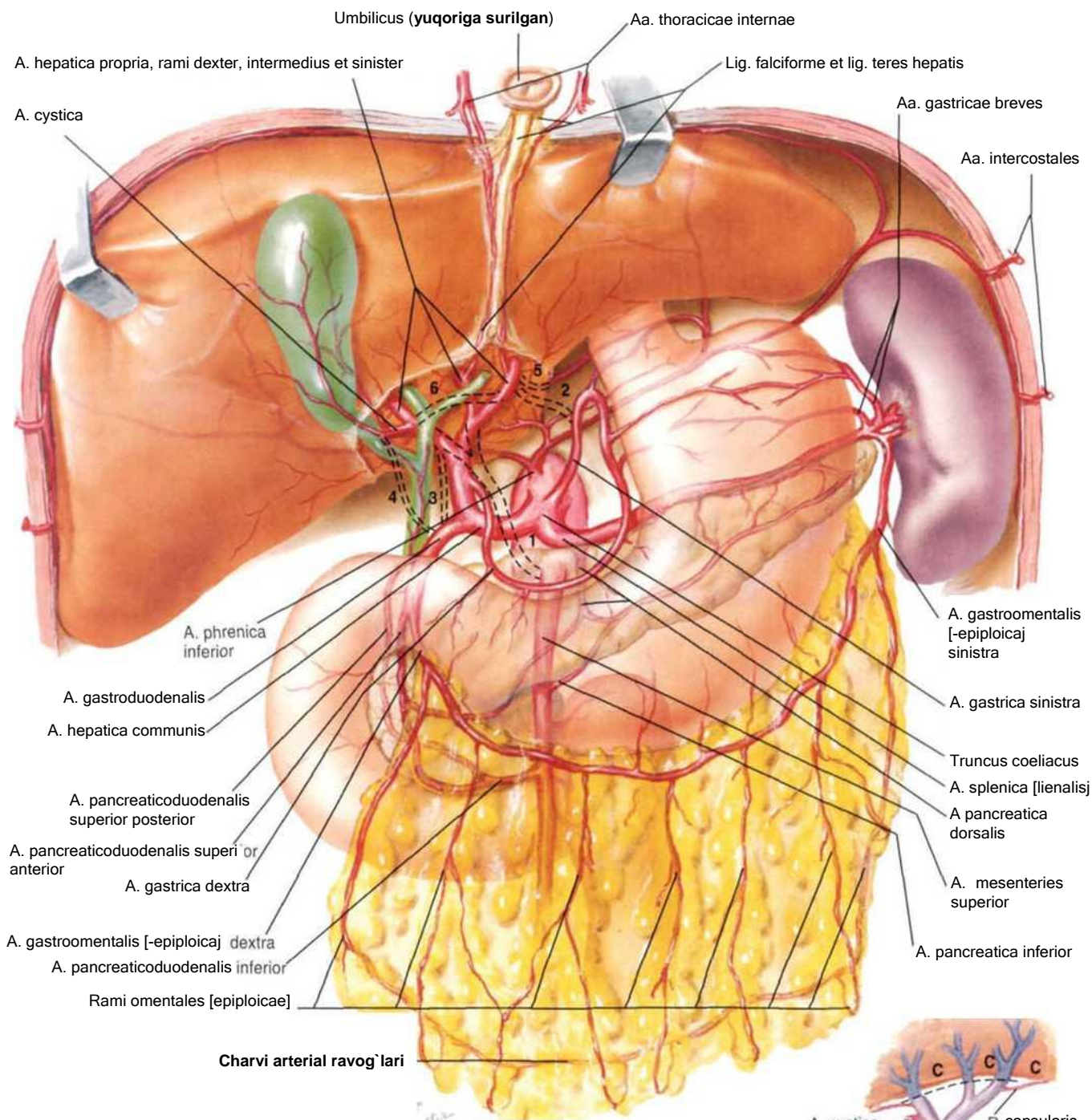


Orqadan ko`rinishi





Jigar va o't qopining arteriya va kollateralarining variantlari

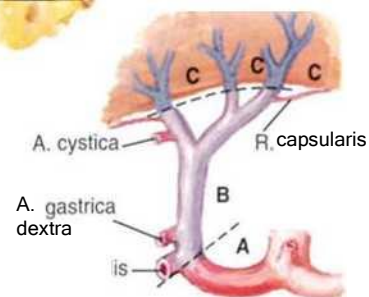


Arteriyalarning tarmoqlanish variantlari

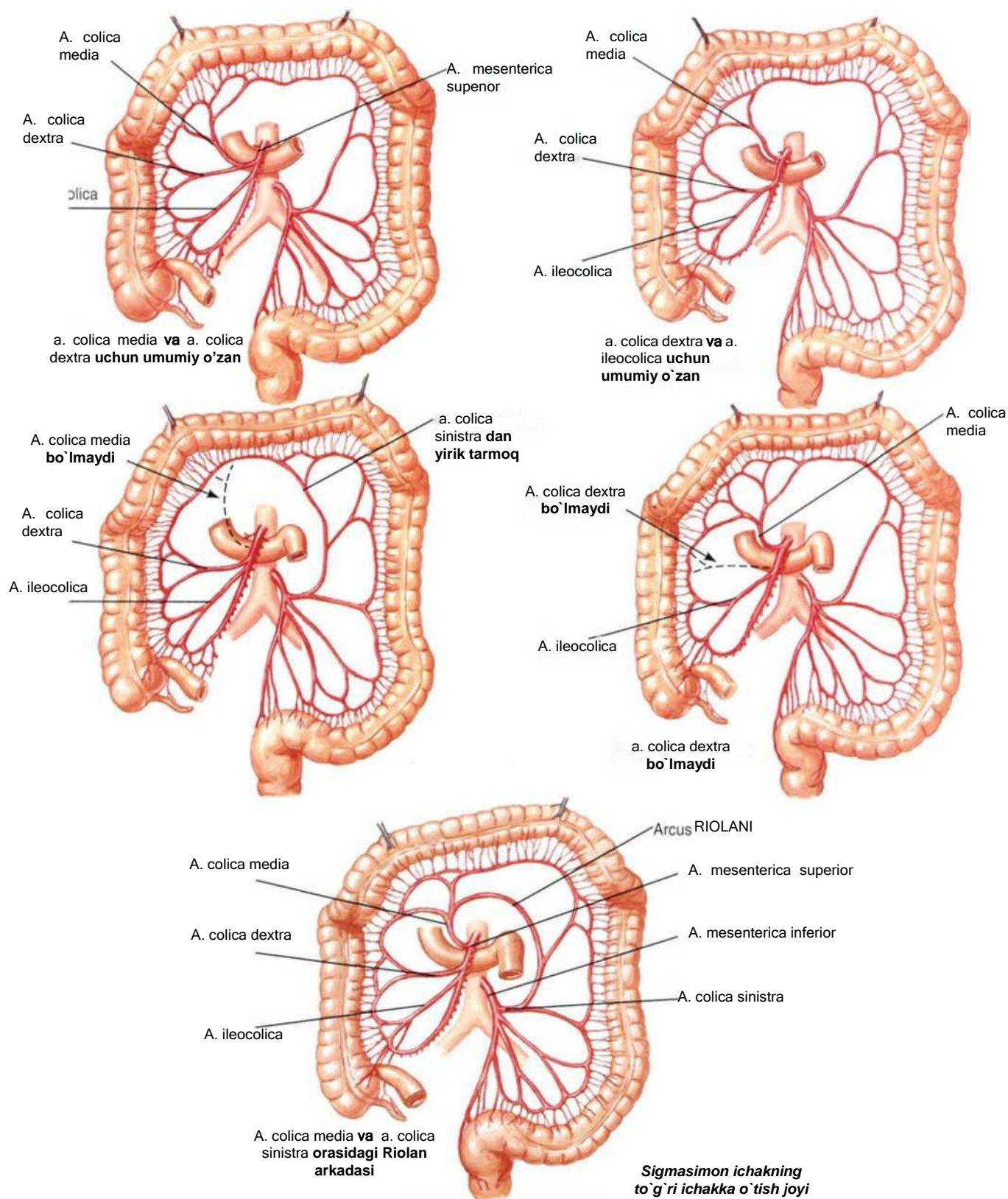
1. A. hepatica communis **yoki** propria a. mesenteries superior **dan**
2. A. hepatica propria, ramus sinister a. gastrica sinistra **dan**
3. A. hepatica propria, ramus dexter a. gastroduodenalis **dan**
4. A. cystica a. gastroduodenalis **dan**

Anastamozlar

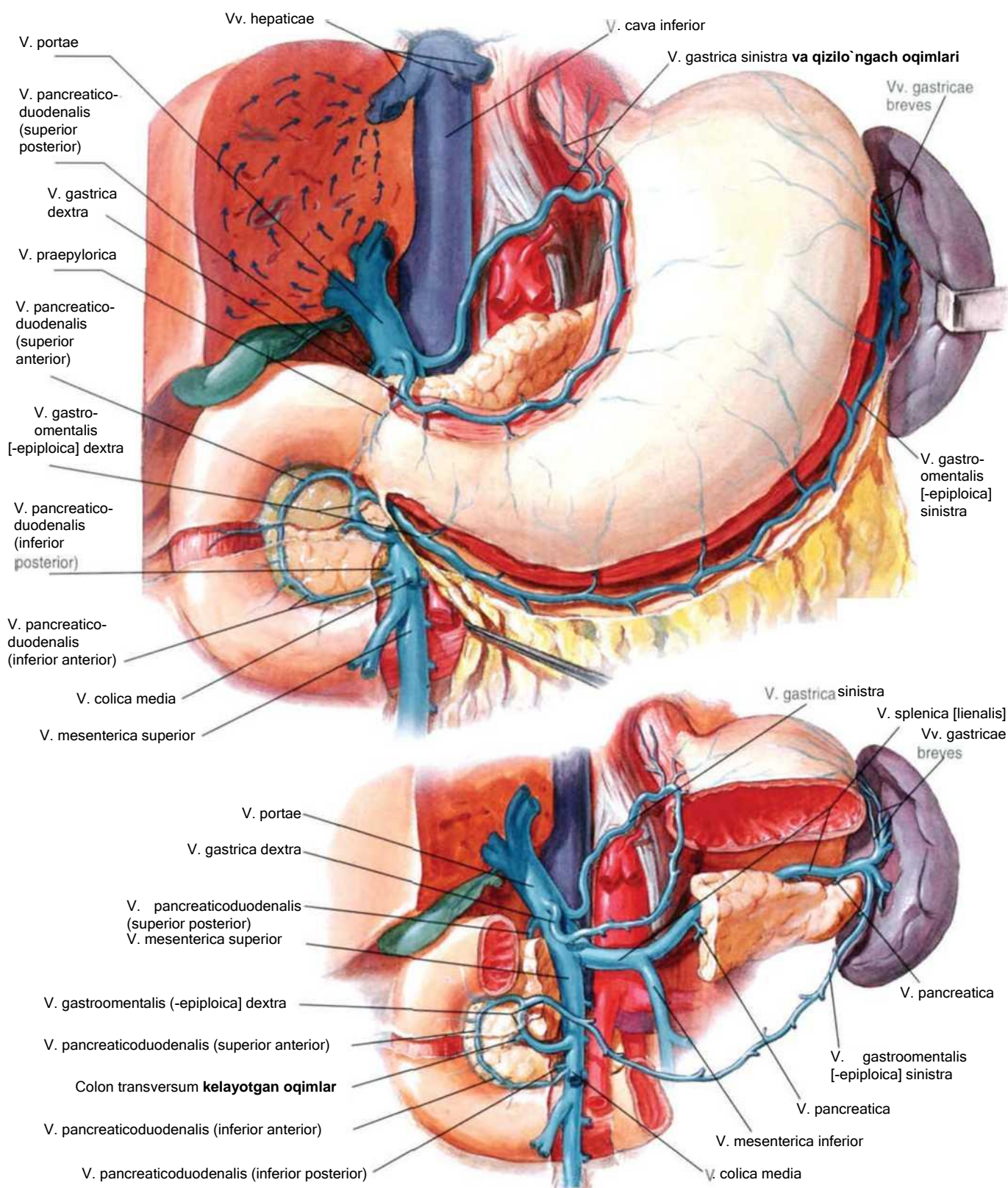
5. A. phrenica inferior / a. gastrica sinistra <---> a. hepatica propria, ramus sinister
6. A. hepatica propria, ramus dexter <---> a. hepatica propria.

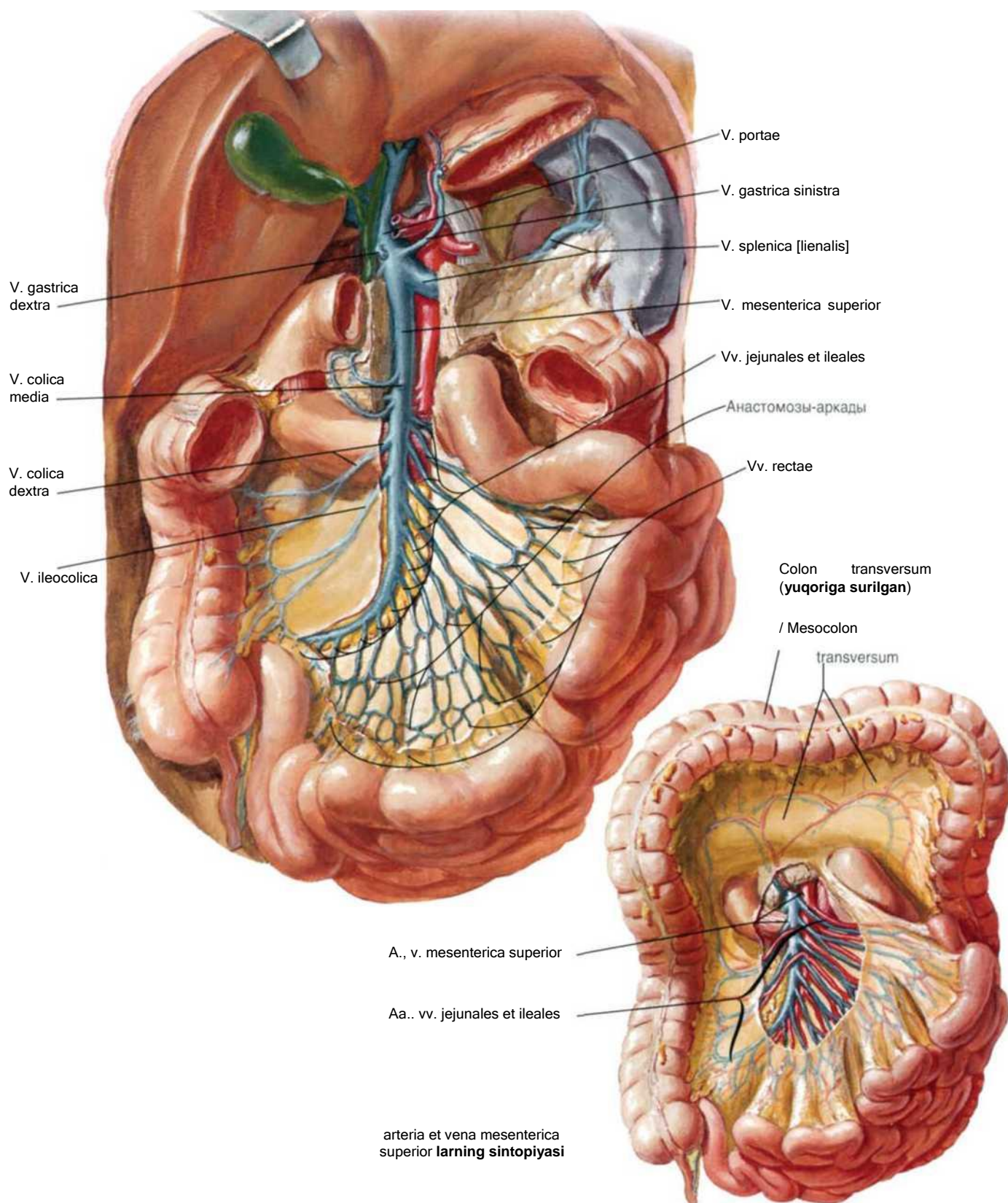


Chambar arteriyalarining variantlari (arteriae colicae)

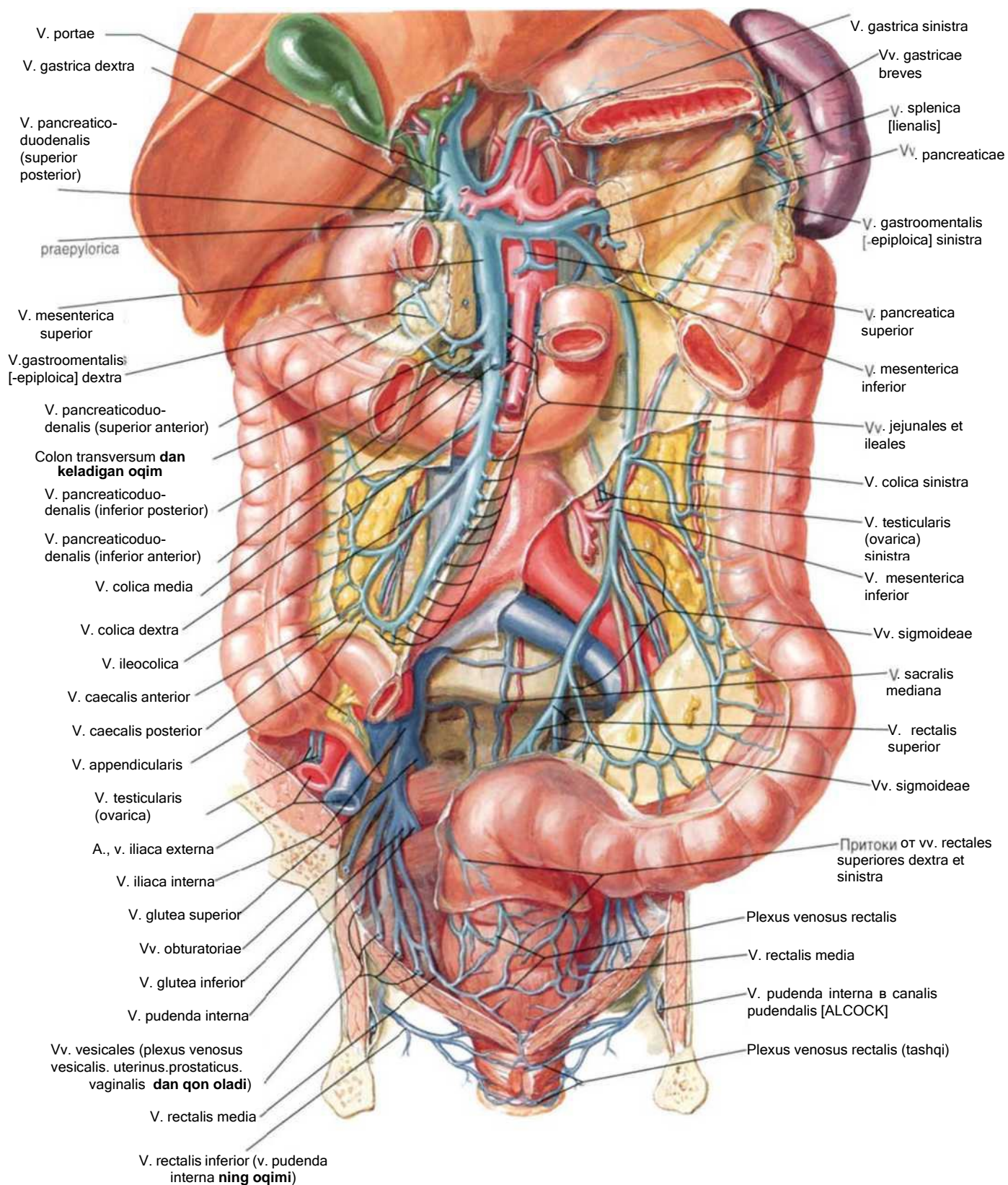


Me`da, 12 barmoq ichak, me`da osti bezi va taloq venalari

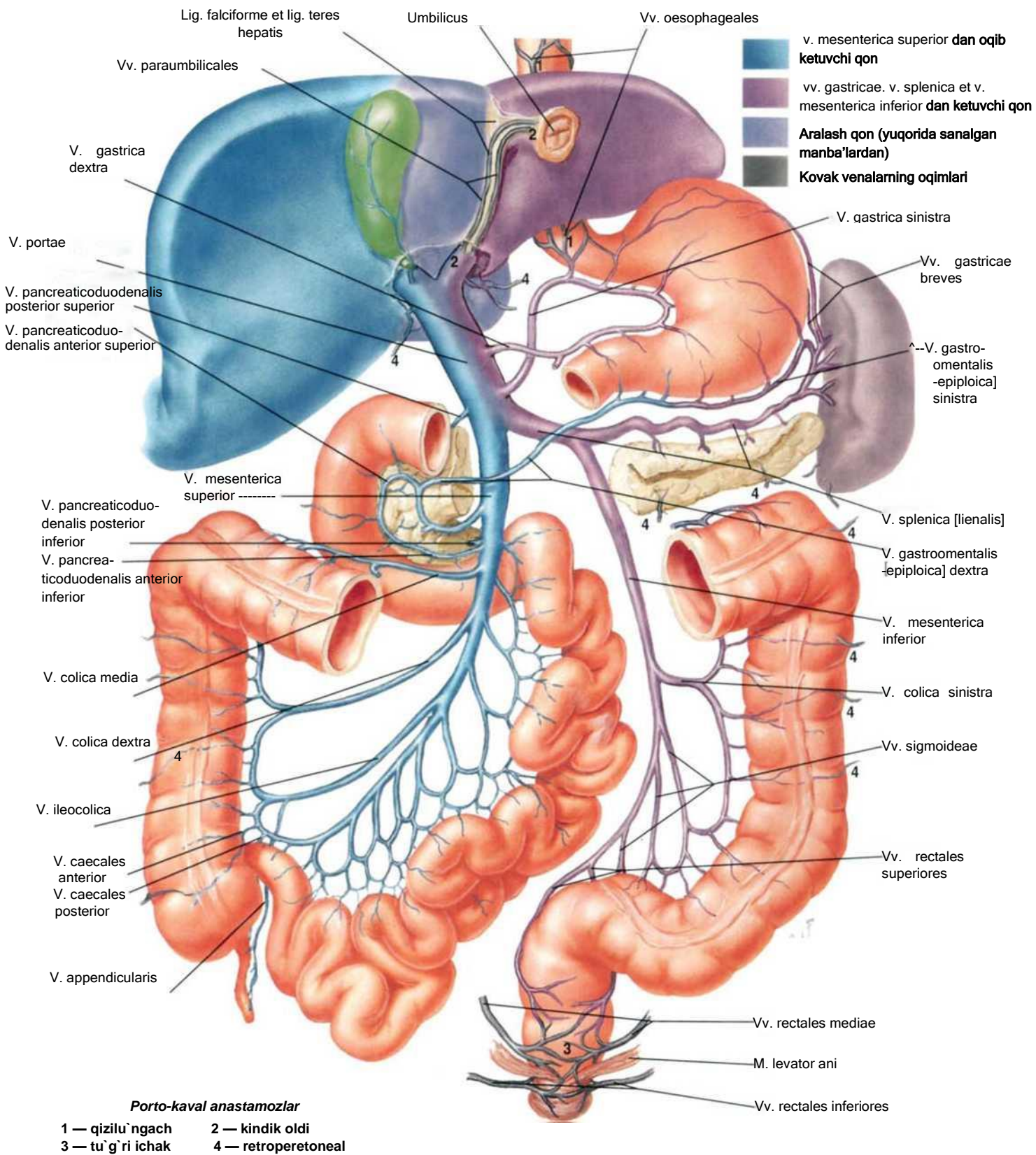




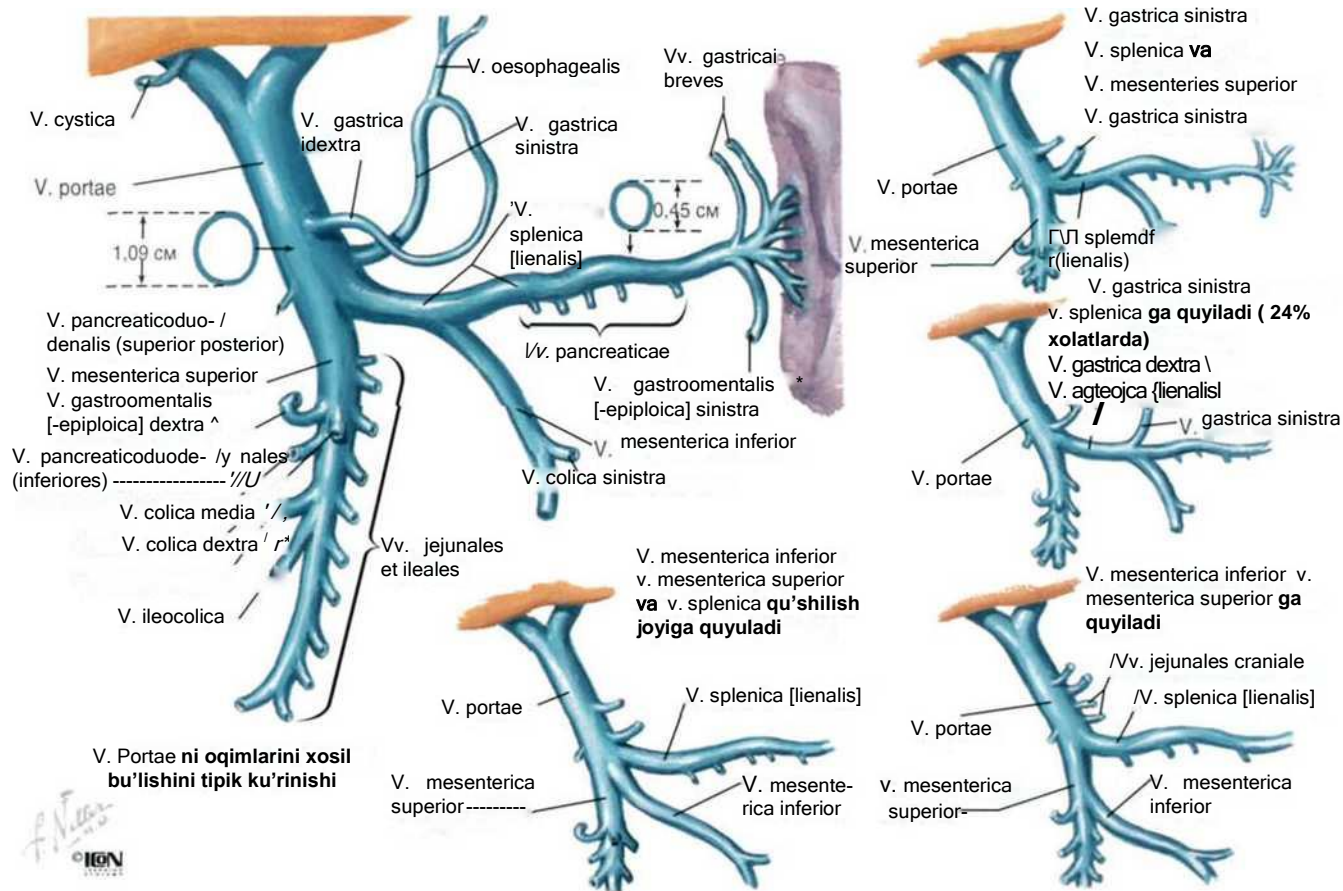
YO'G'ON ICHAK VENALARI



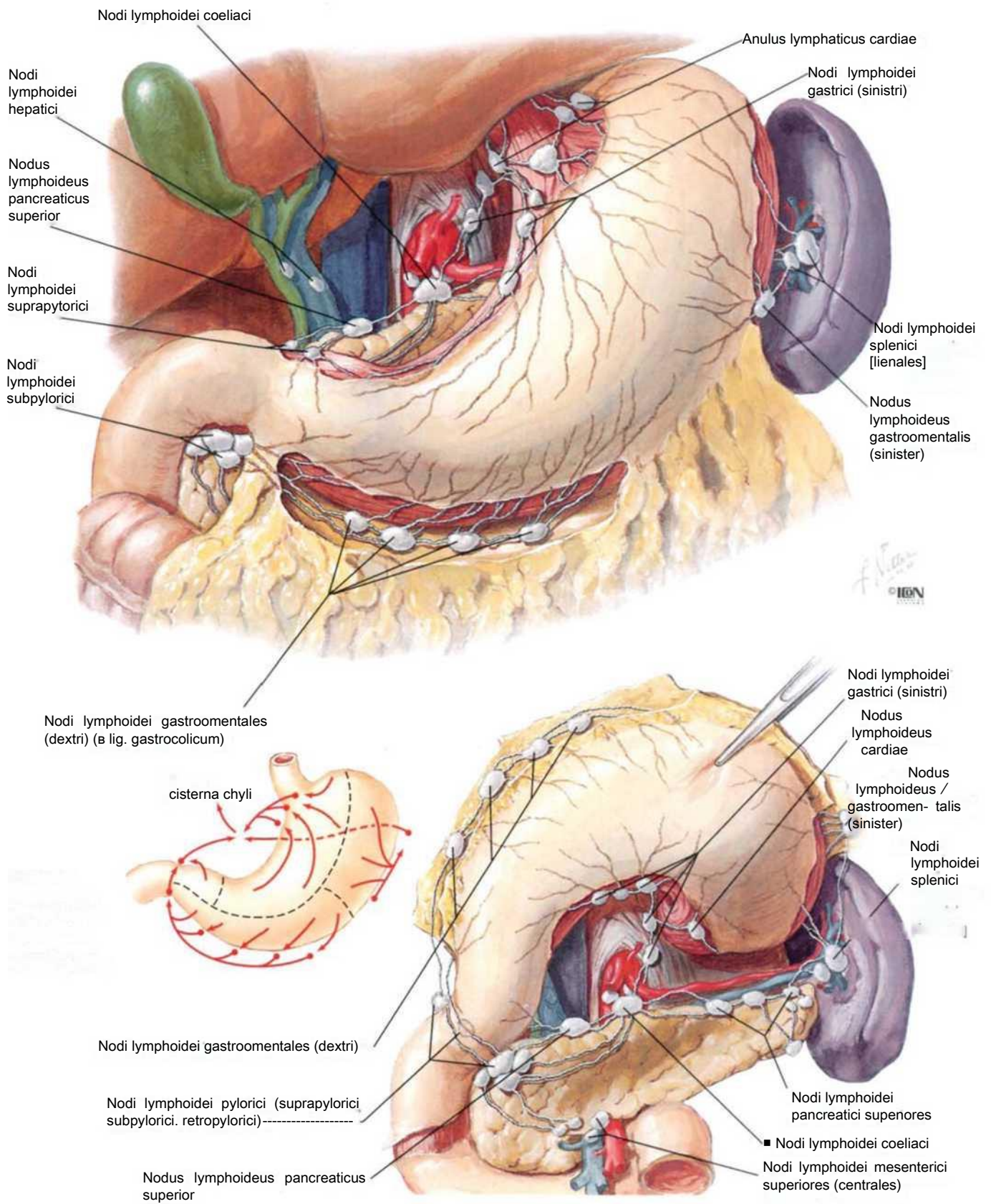
Darvoza venasinig oqimlari va porto-kaval anastamozlar



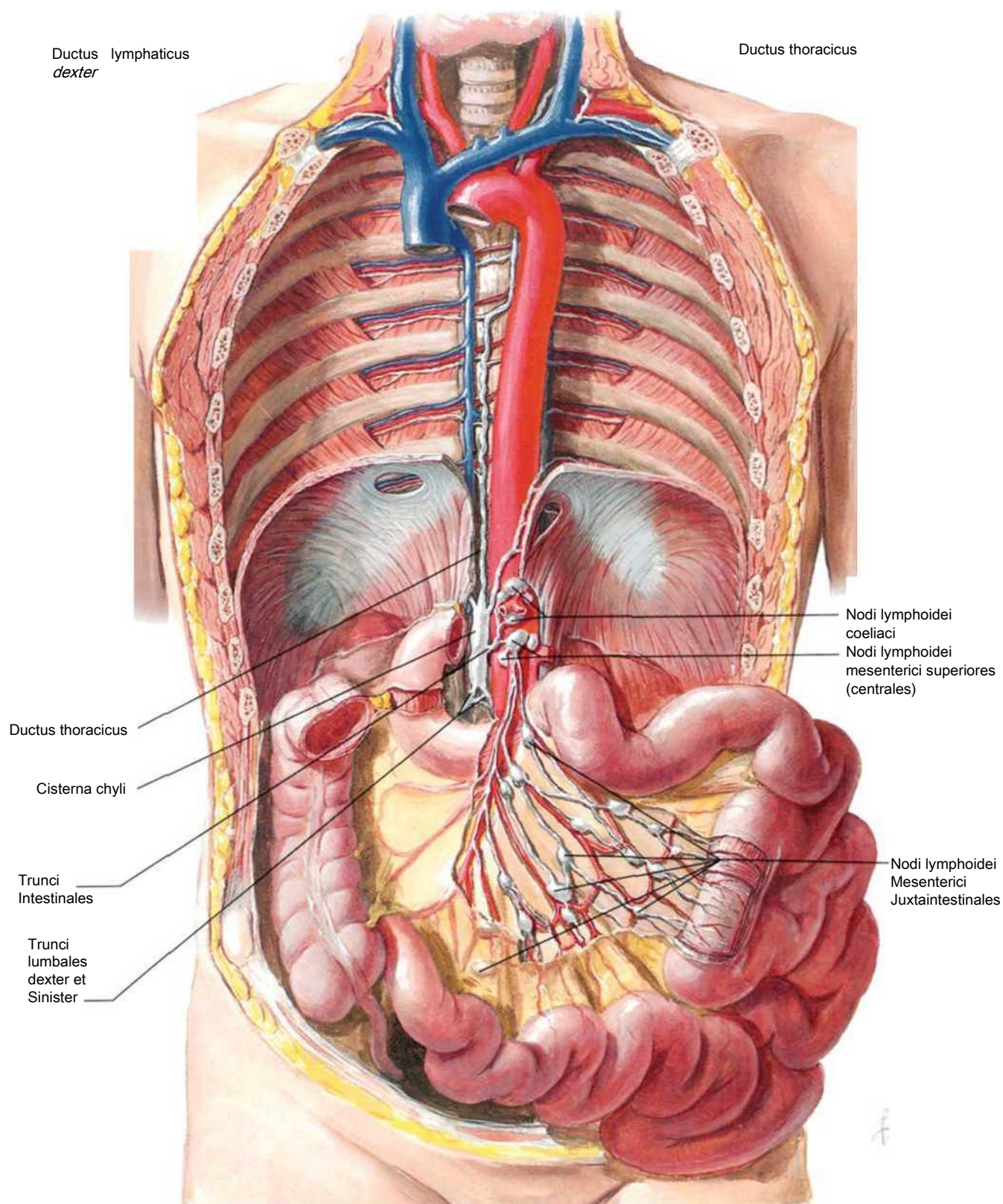
Darvoza venasi oqimlar



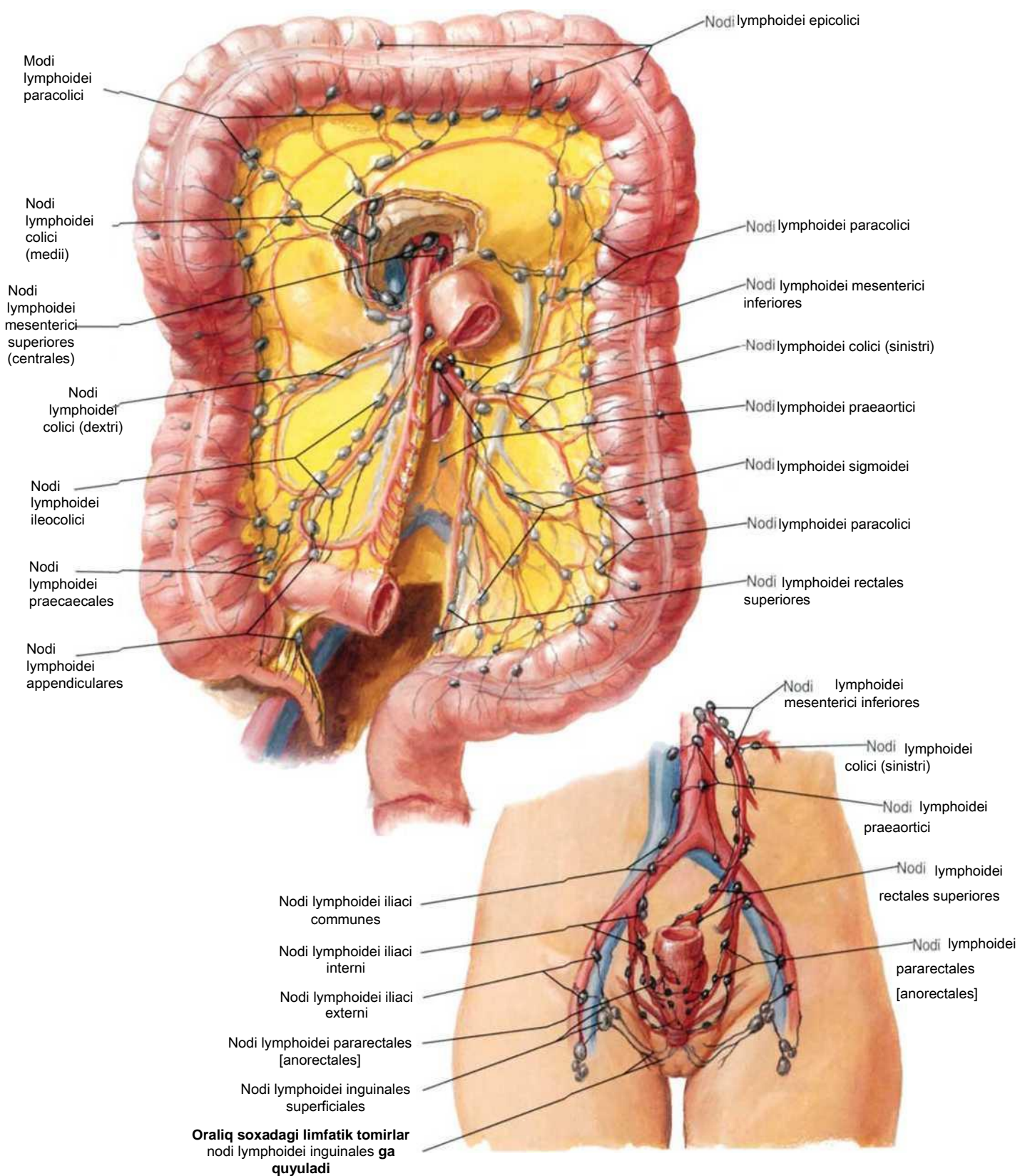
Me`daning limfatik tomirlari va tugunlari



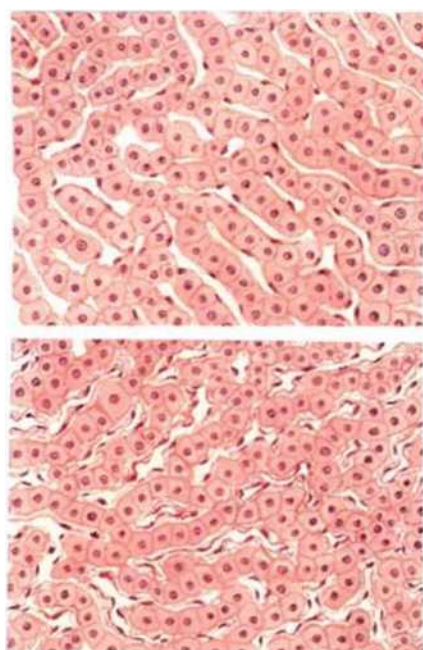
Ingichka ichakning limfa tomirlari va tugunlari



Yo'gon ichakning limfa tomirlari va tugunlari



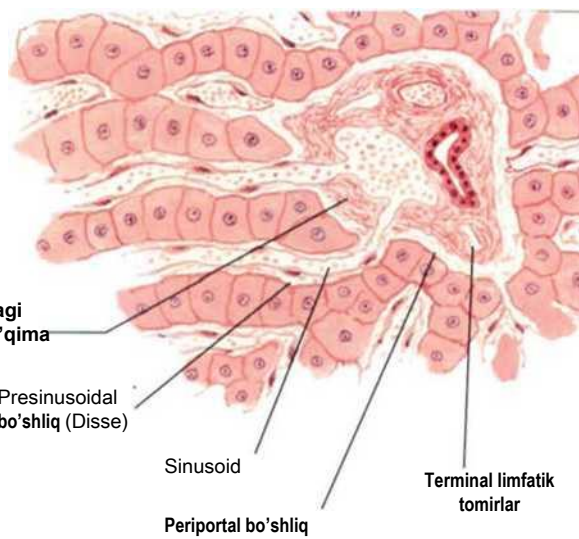
Jigarning limfatik tomirlari va tugunlari



Jigarning mikroskopik kesma ko'rinishi

Toraygan yoki berkilgan (Disse) presinusoidal bo'shlig'i

Presinusoidal bo'shliqlar sezilarli darajada kengaygan



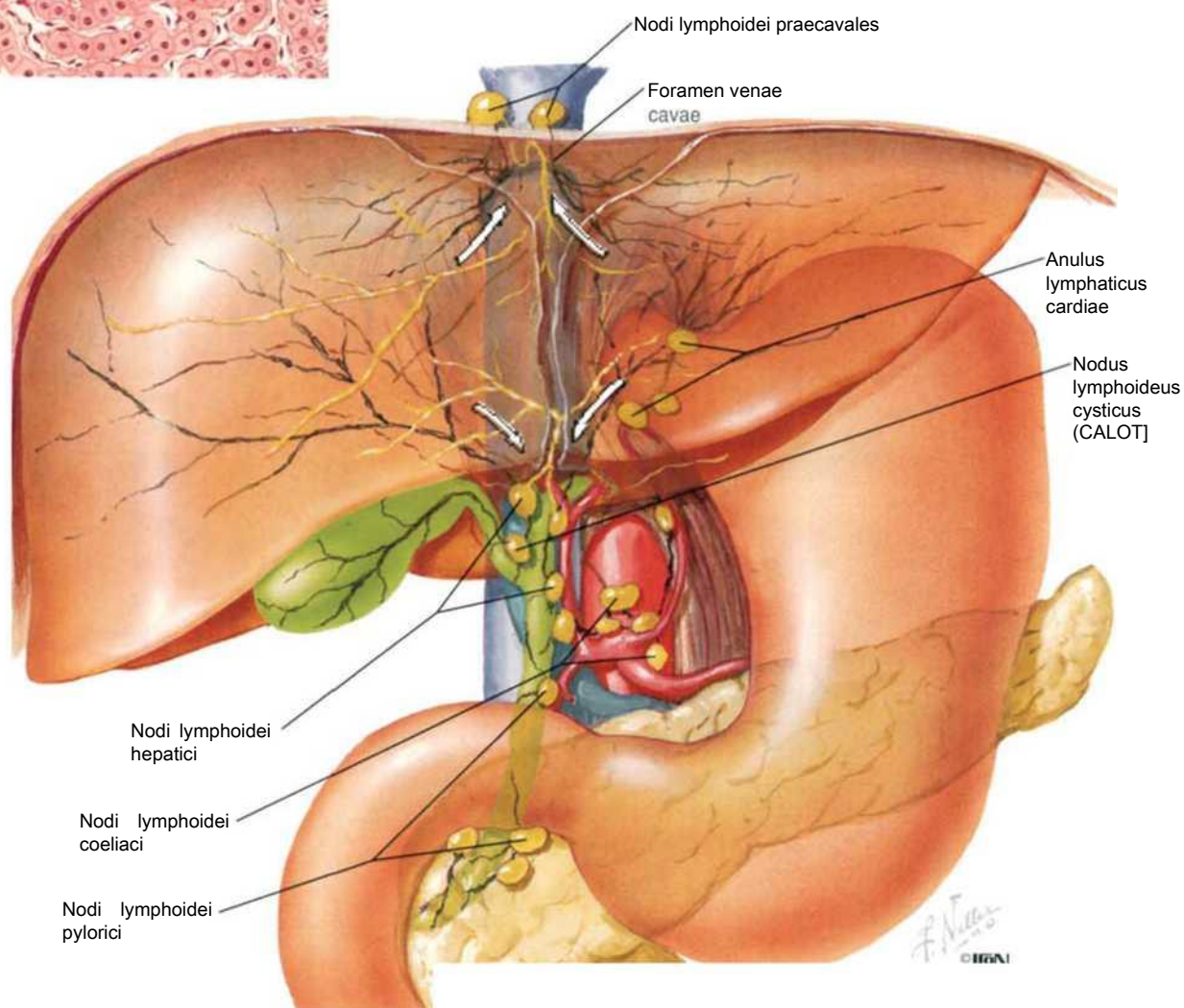
Portal triadadagi brikiruvchi to'qima

Presinusoidal bo'shliq (Disse)

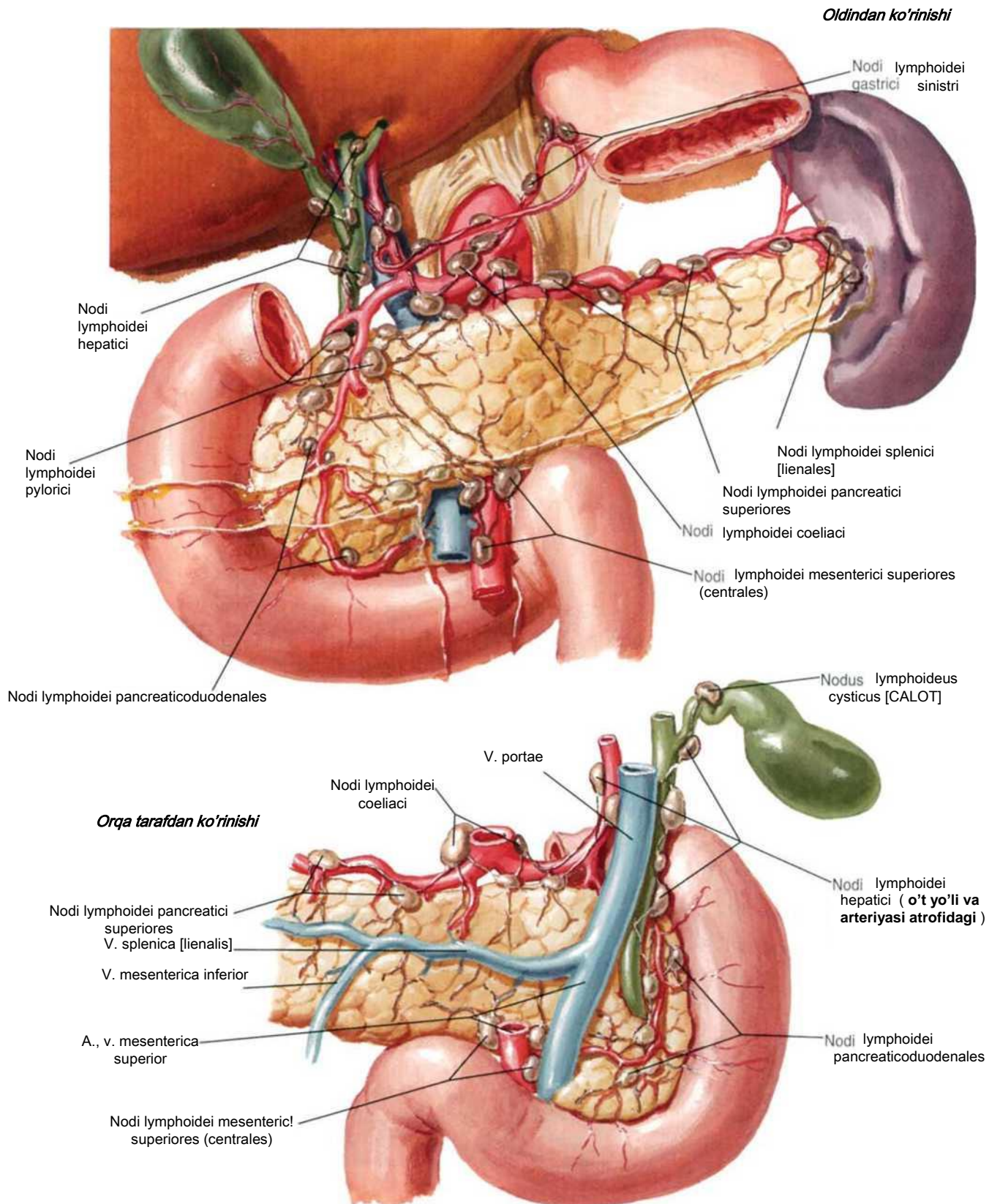
Sinusoid

Periportal bo'shliq

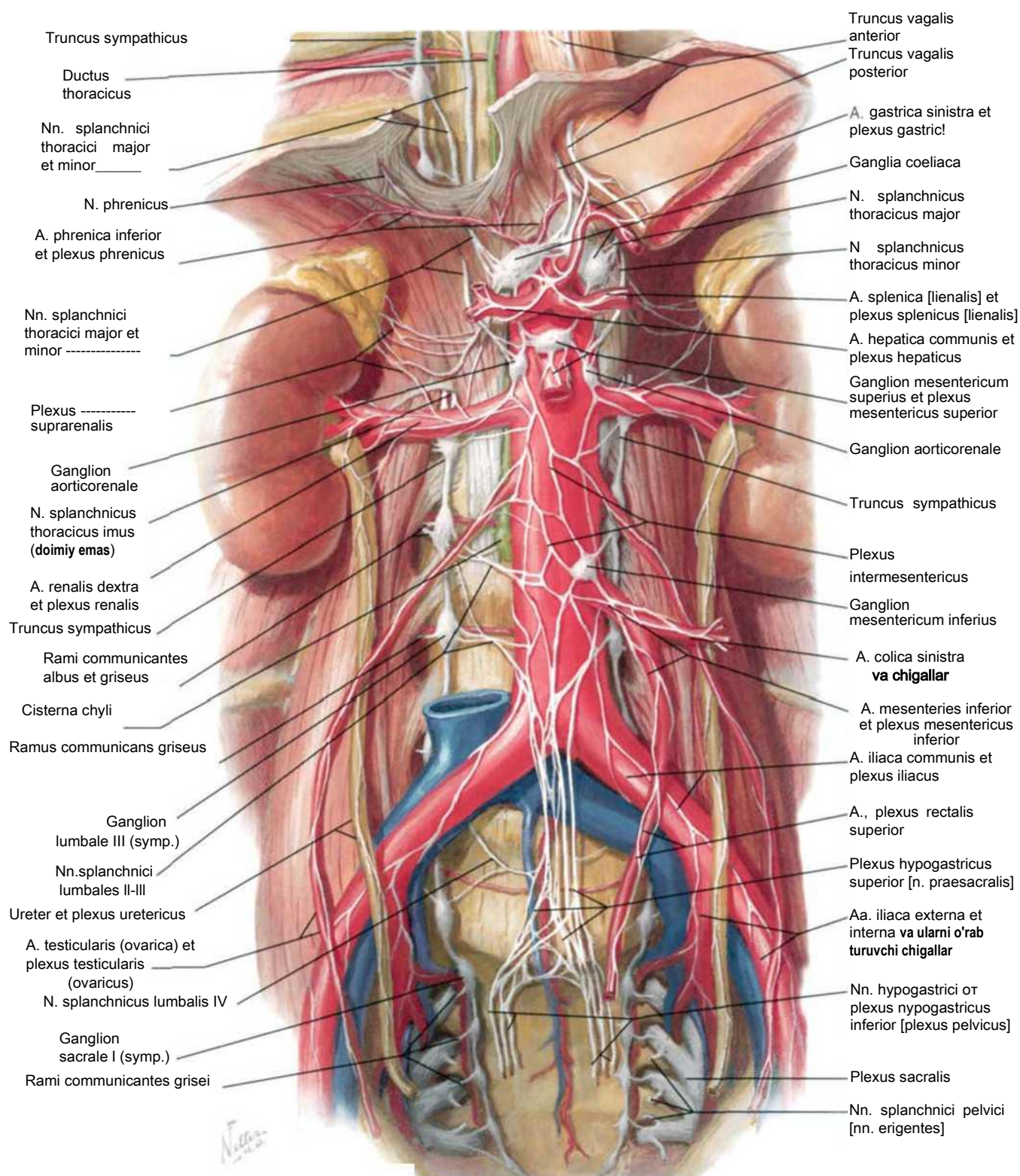
Terminal limfatik tomirlar



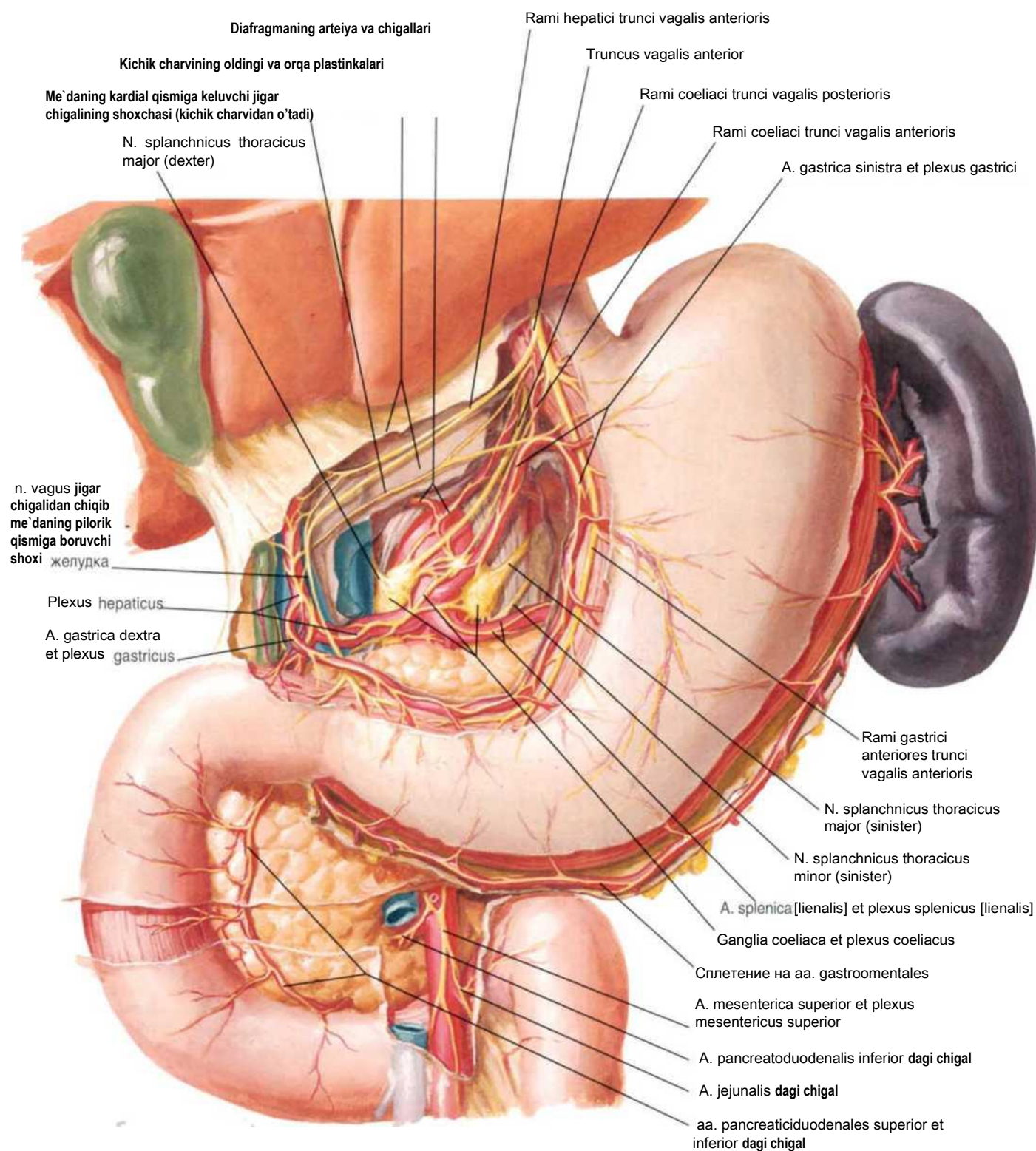
Me`da osti bezining limfatik tomirlari va tugunlari



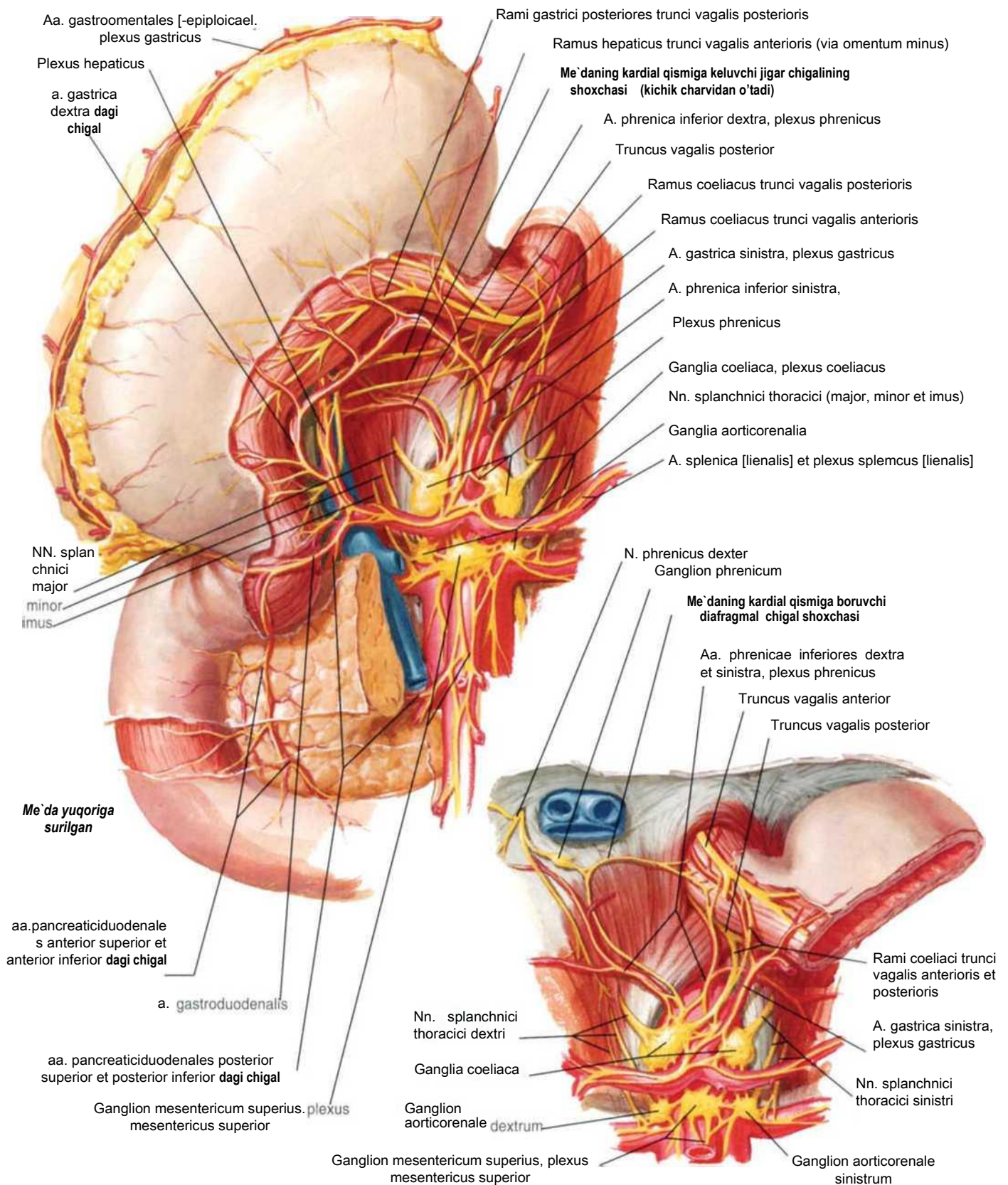
Qorin bo'shligining vegetativ nerv va gangliylari



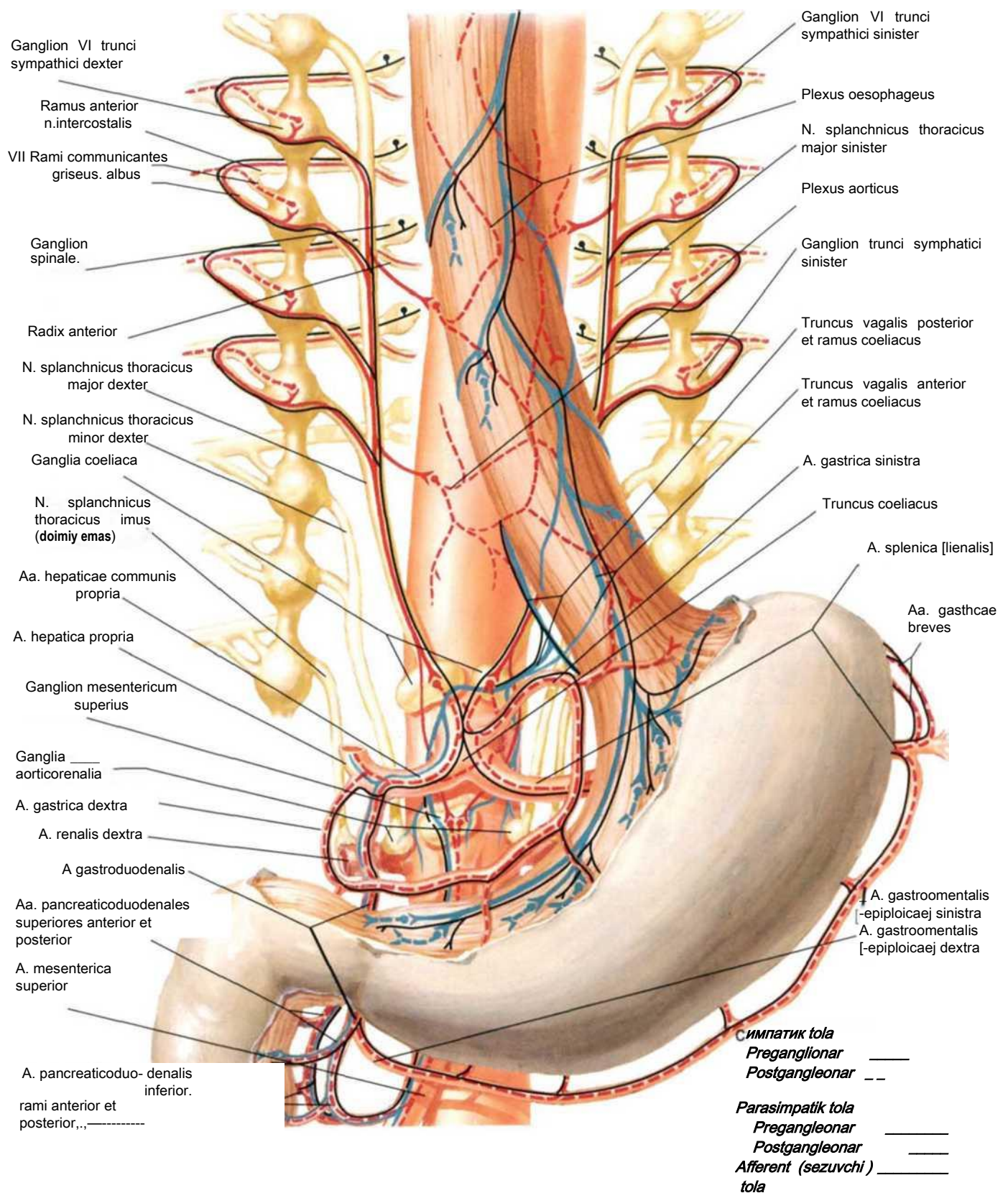
Me`da va 12 barmoq ichak innervatsiyasi



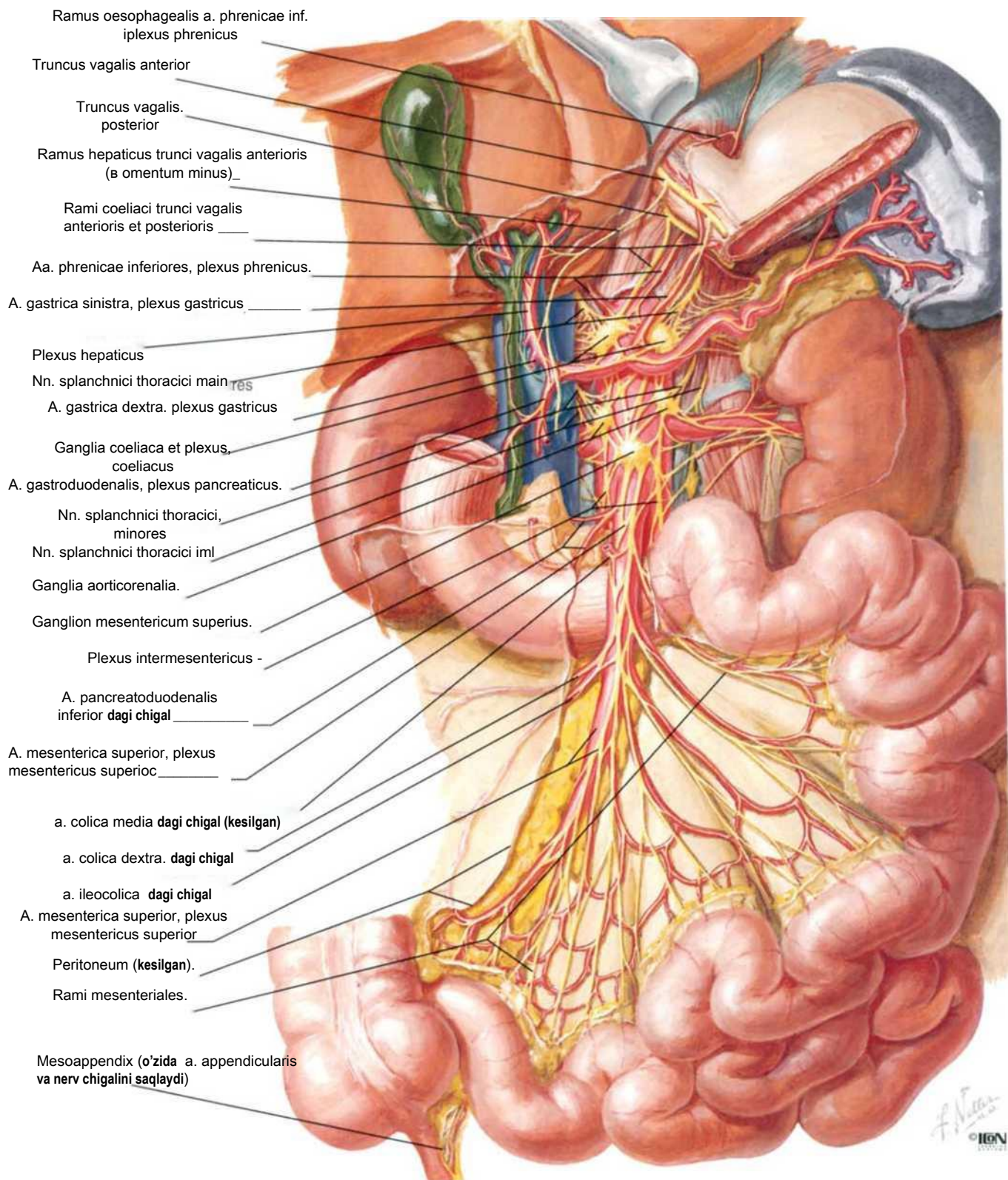
Me`da va 12 barmoq ichak innervatsiyasi (davomi)



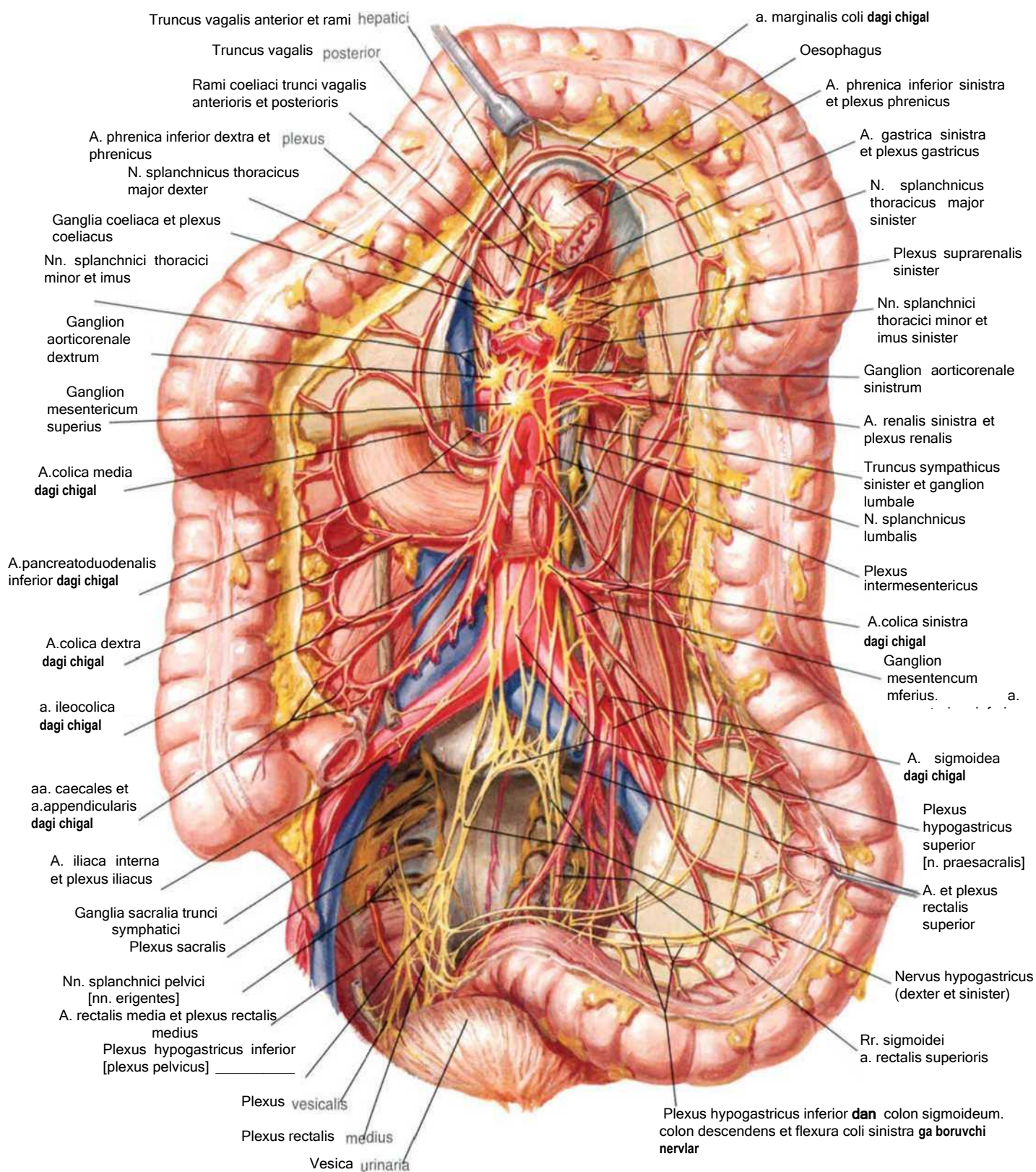
Me`da va 12 barmoq ichak innervatsiyasi (sxema)



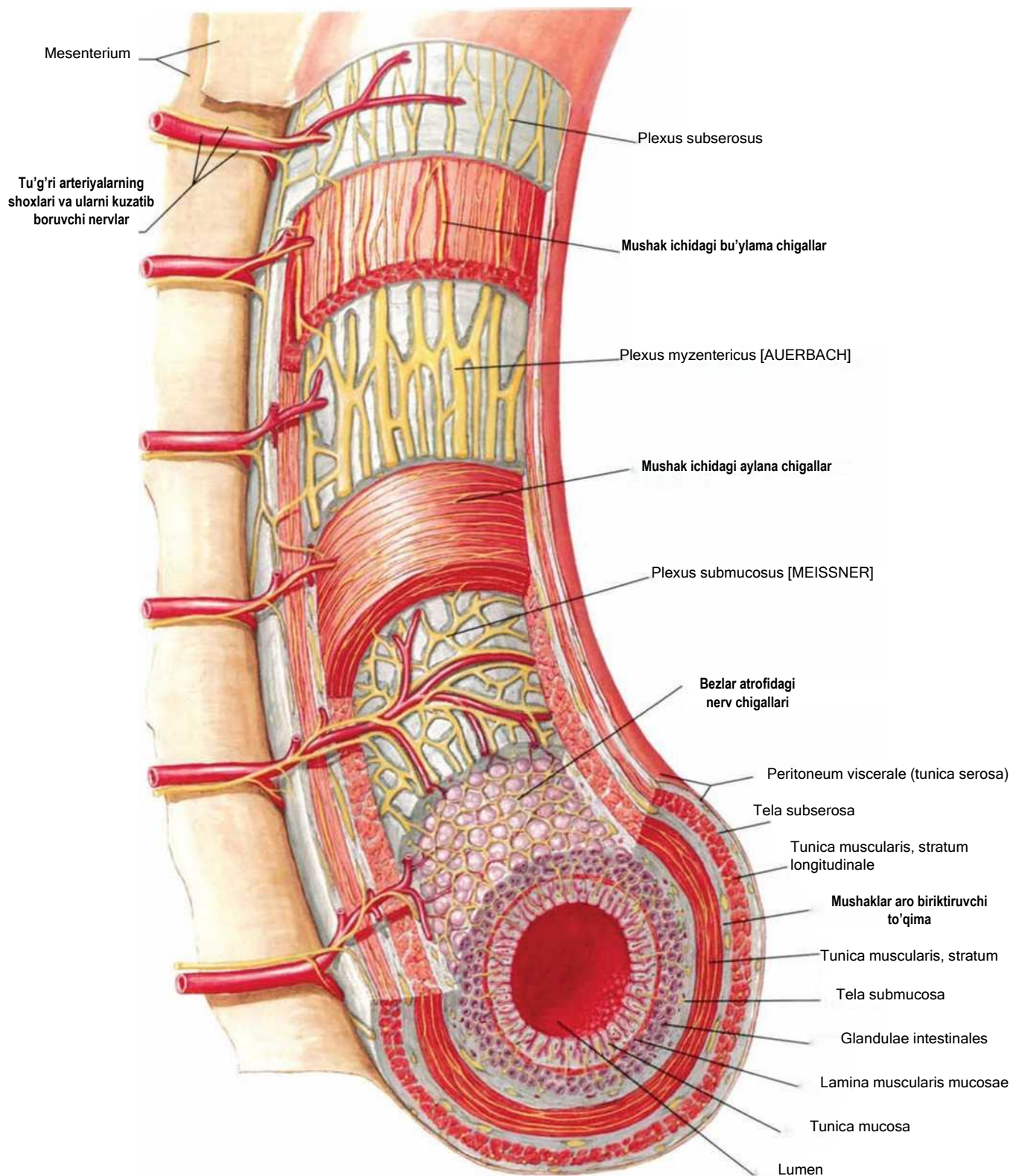
Ingichka ichak innervatsiyasi



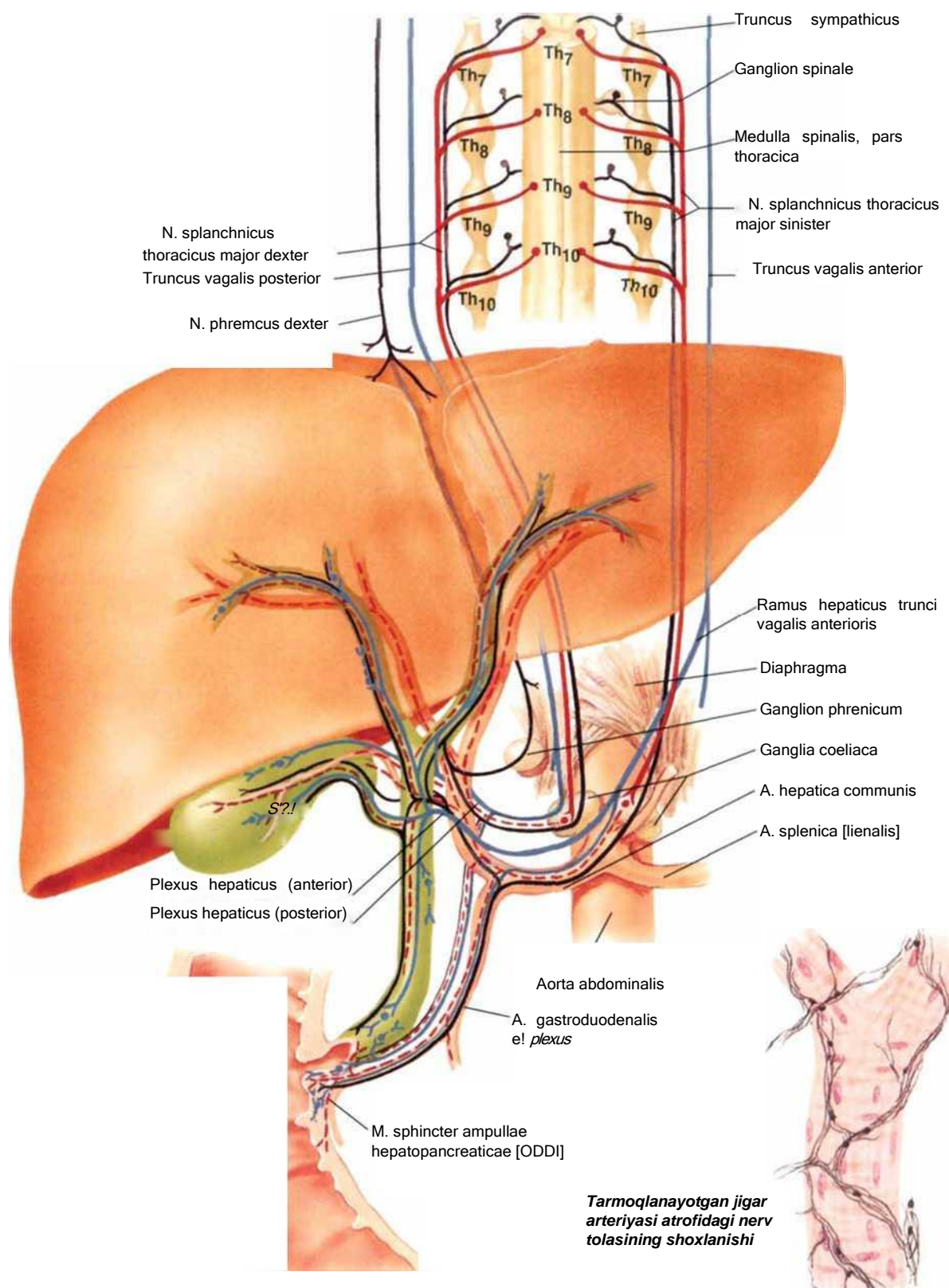
Yo'g'on ichak innervatsiyasi



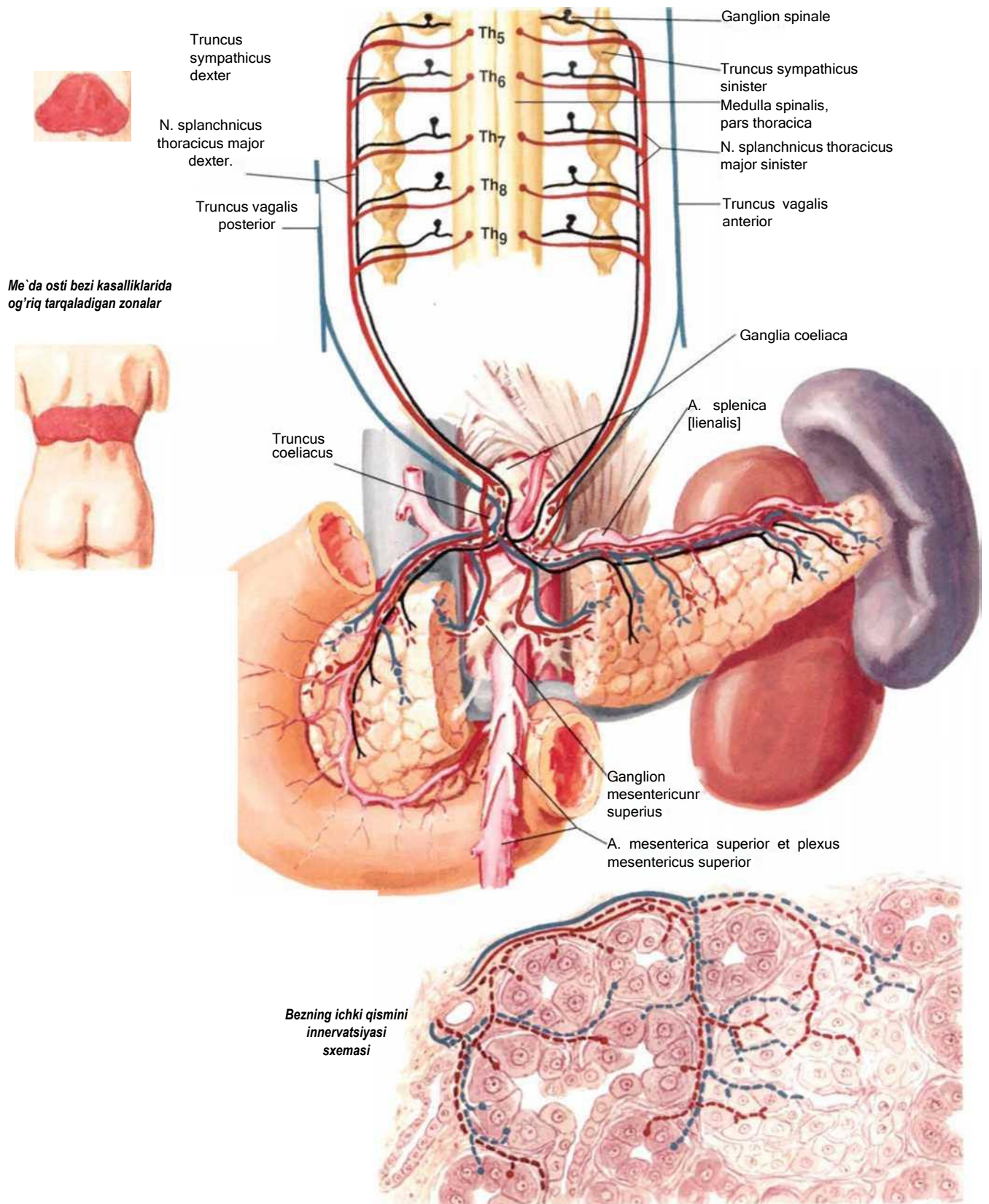
Ichakning nerv chigallari : sxemasi



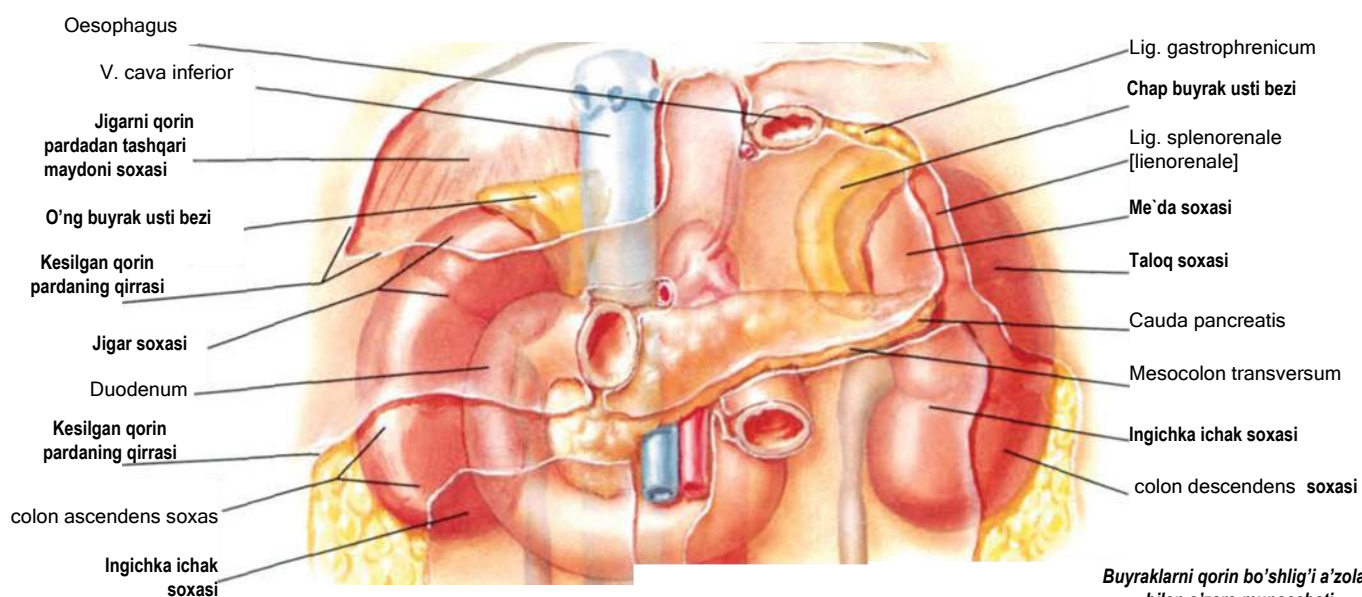
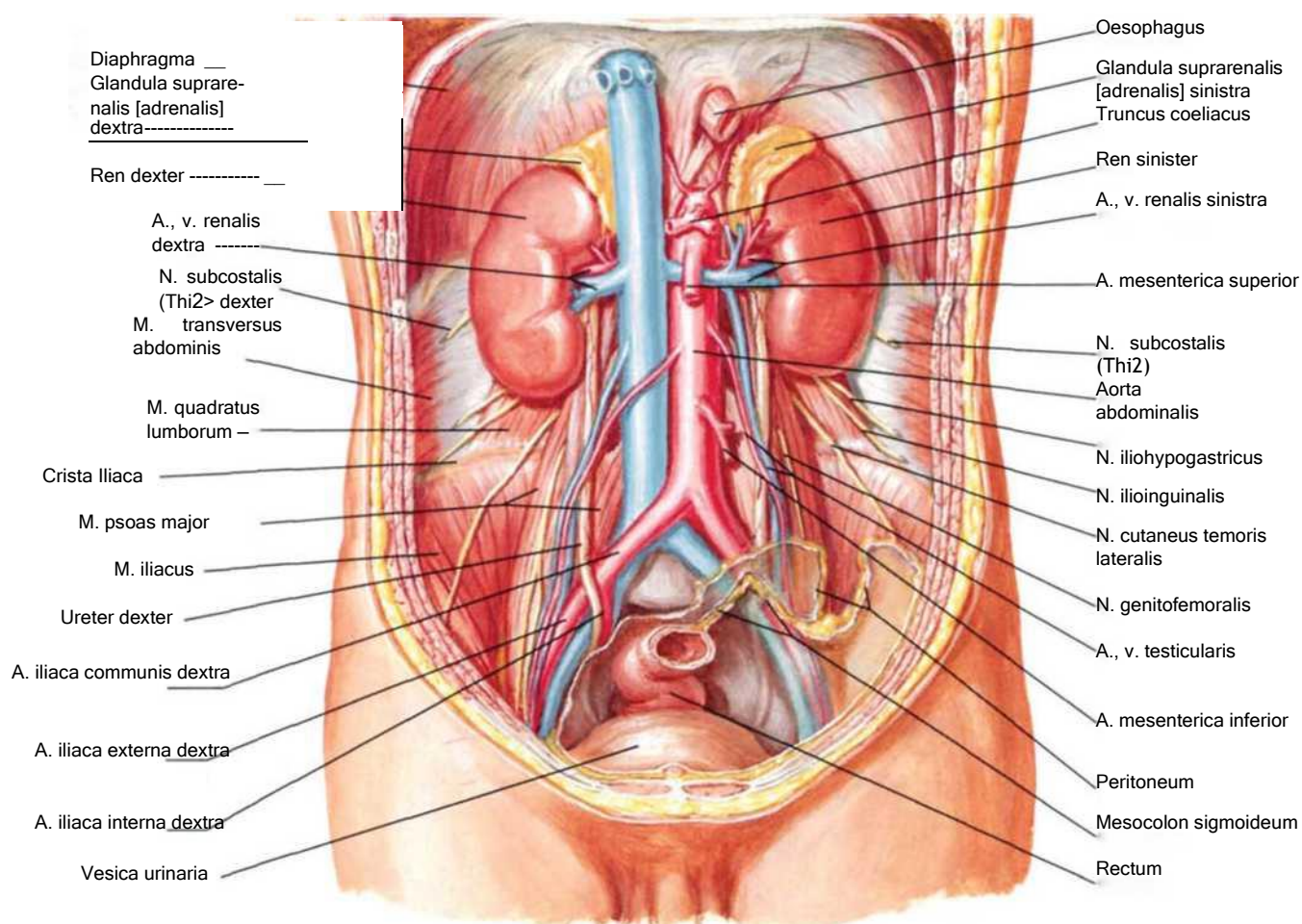
Jigar va o't yo'llari innervatsiyasi: sxemasi



Me`da osti bezining innervatsiyasi : sxema

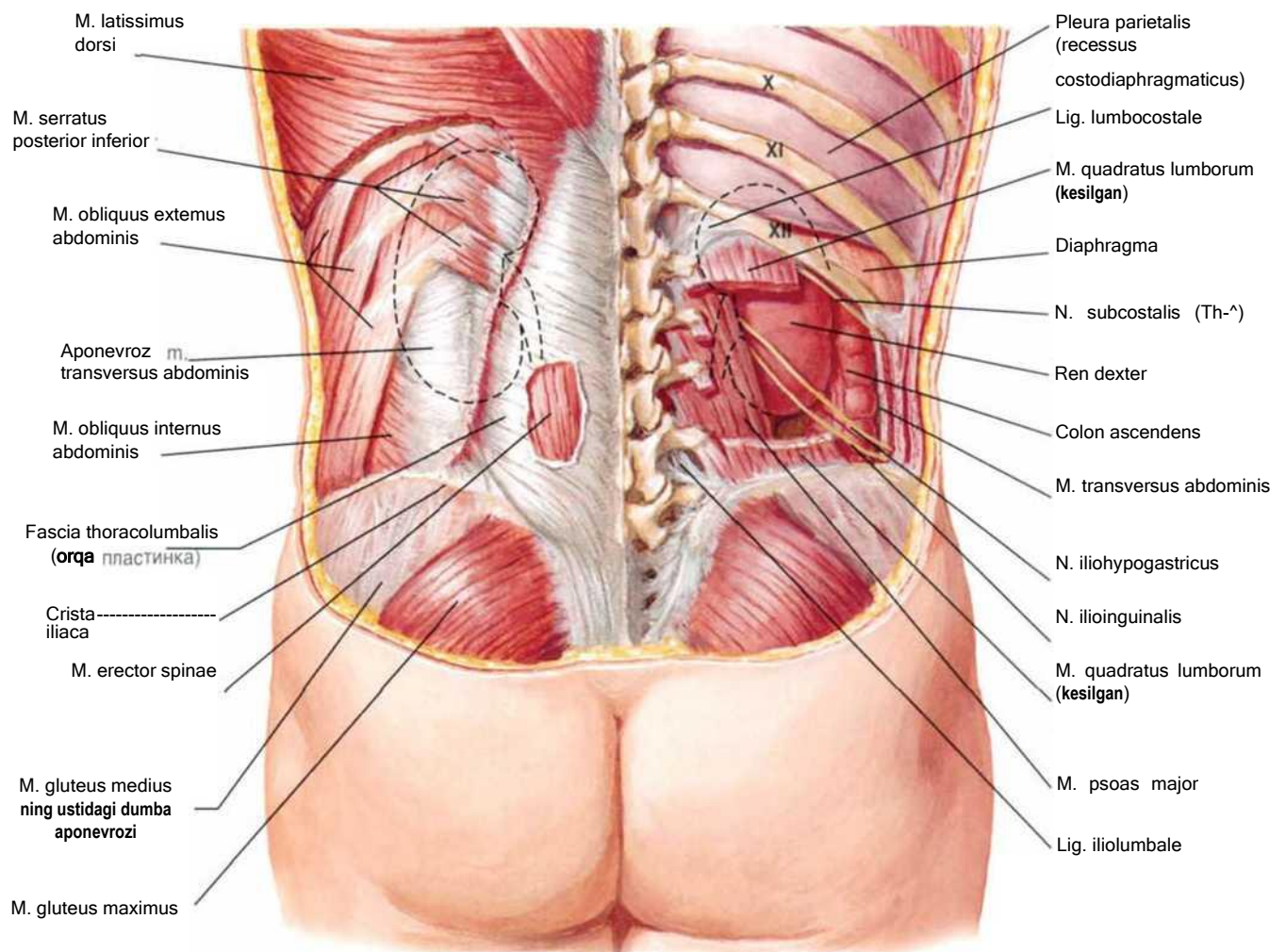


Buyraklar (ren): oldindan ko'rinishi

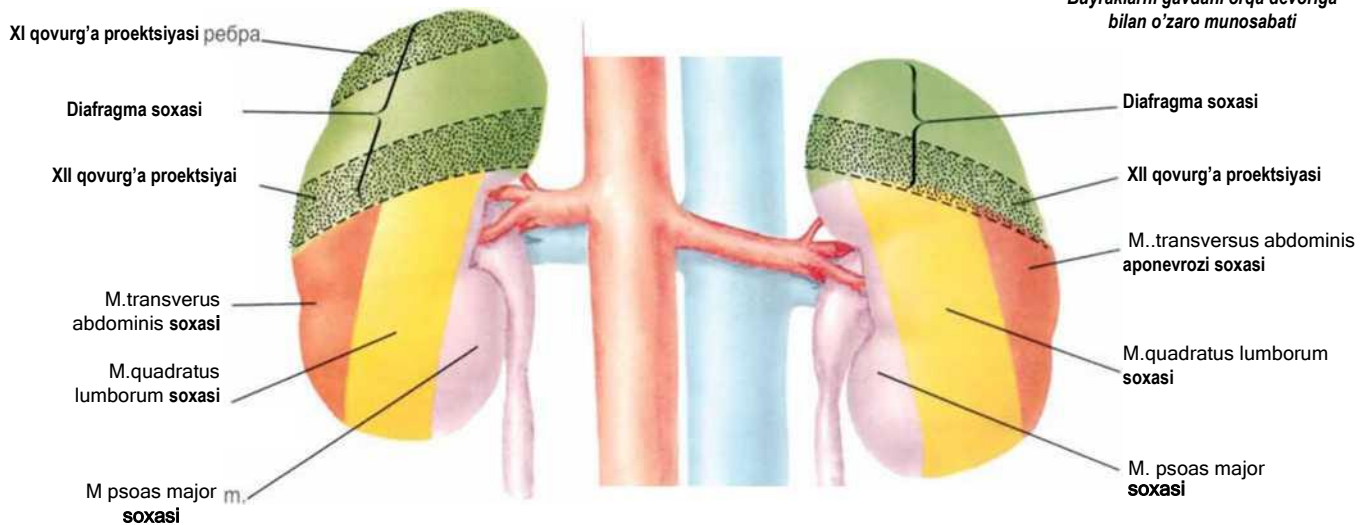


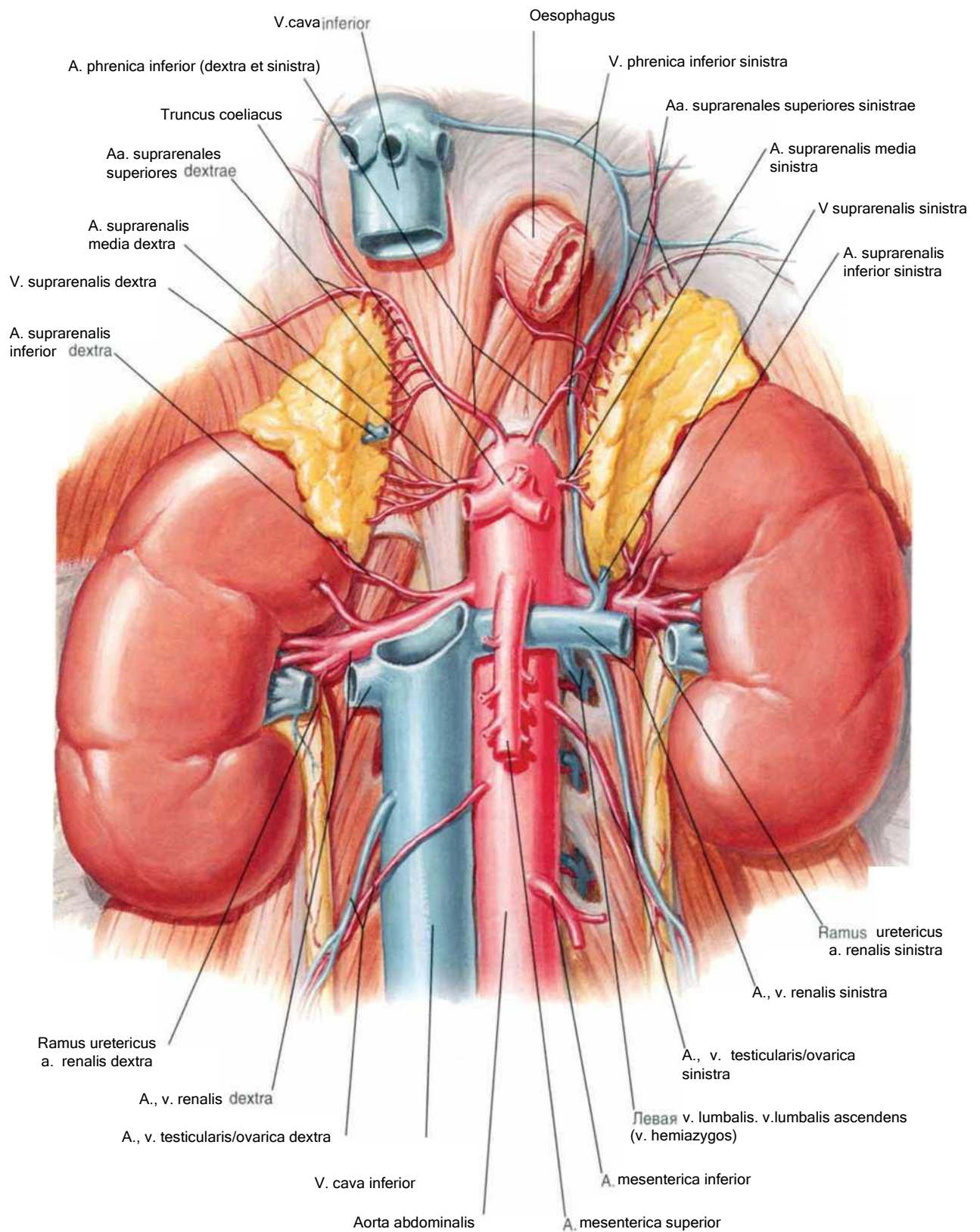
Buyraklarni qorin bo'shlig'i a'zolari bilan o'zaro munosabati

Buyraklar (ren): orqadan ko'rinishi

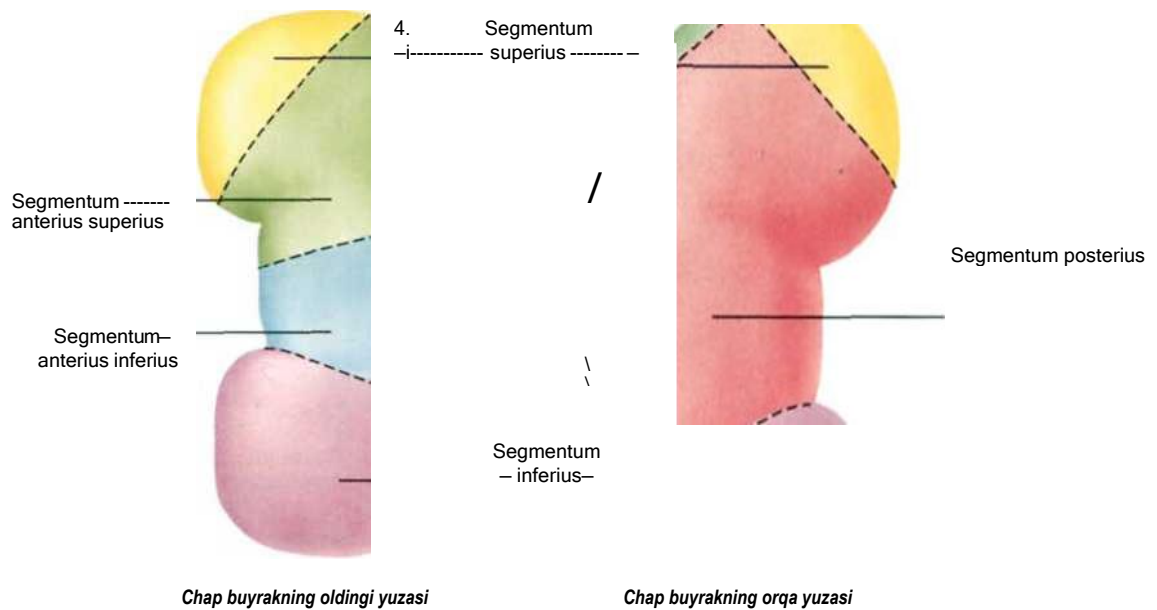
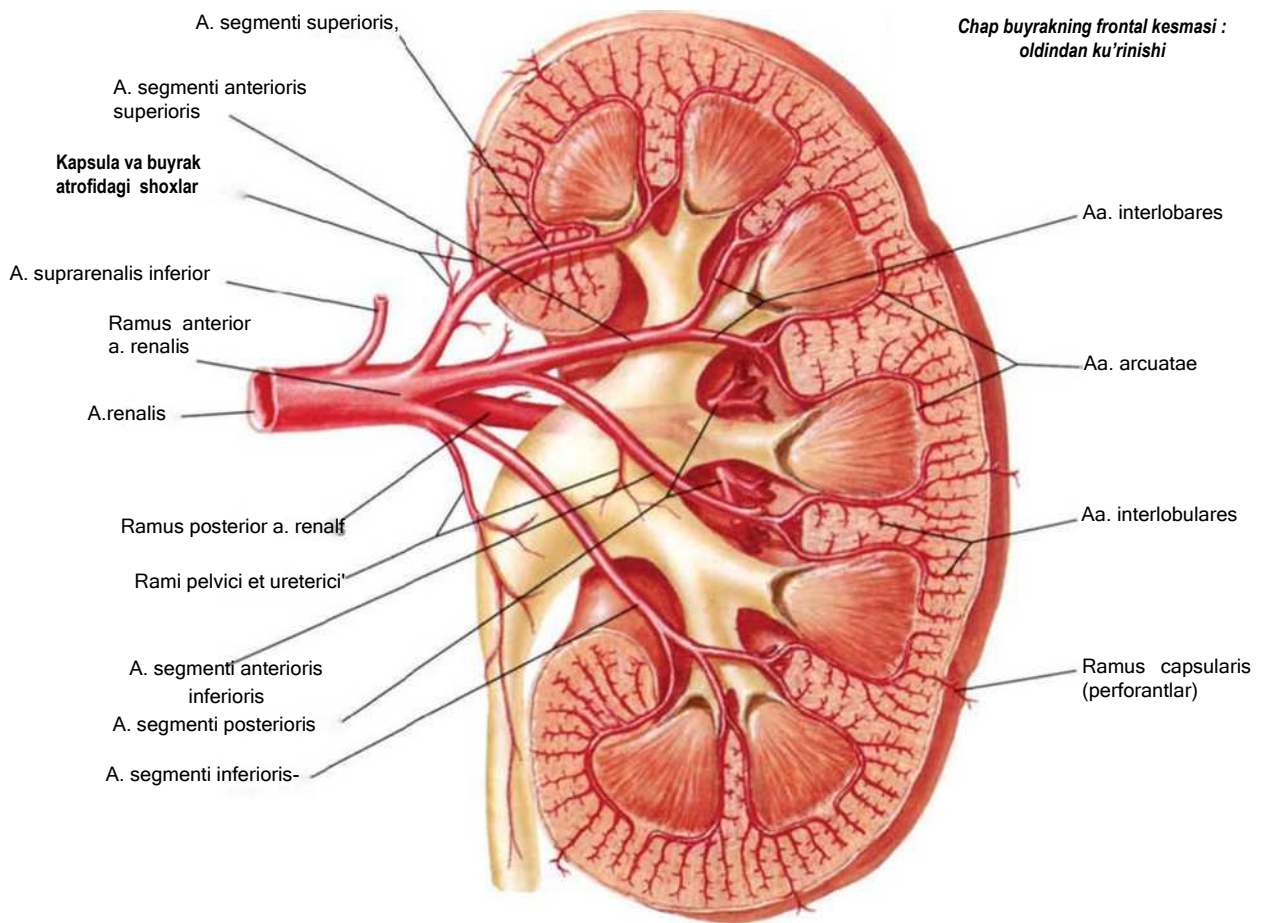


Aorta abdominalis V. cava inferior

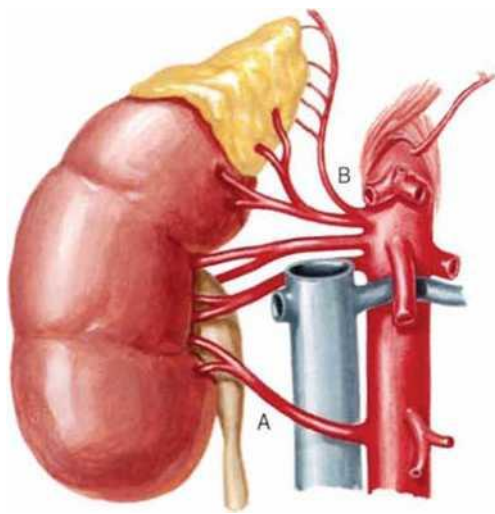




Buyrak segmentlari va buyrak ichki arteriyalari

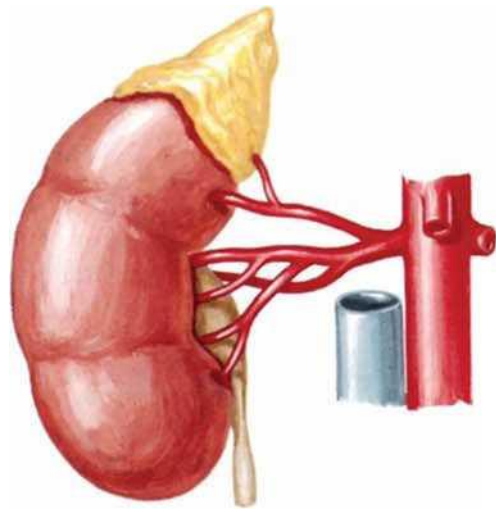


Buyrak arteriya va venalarining variantlari

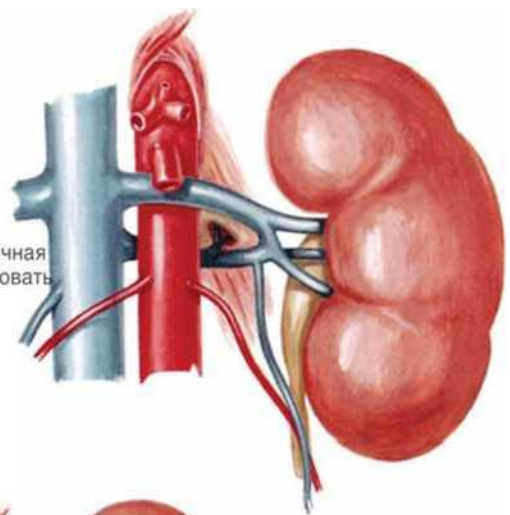


A - O'ng pastki qo'shimcha arteriya
v. cava inferior ning orqasidan emas,
oldi tarafidan o'tadi

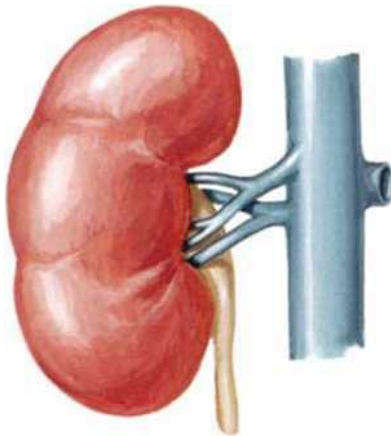
B - Pastki diafragmal arteriya va yuqorigi buyrak
usti arteriyalari buyrak arteriyasidan chiqadi (o'rta
buyrak usti arteriyasi bo'lmaydi)



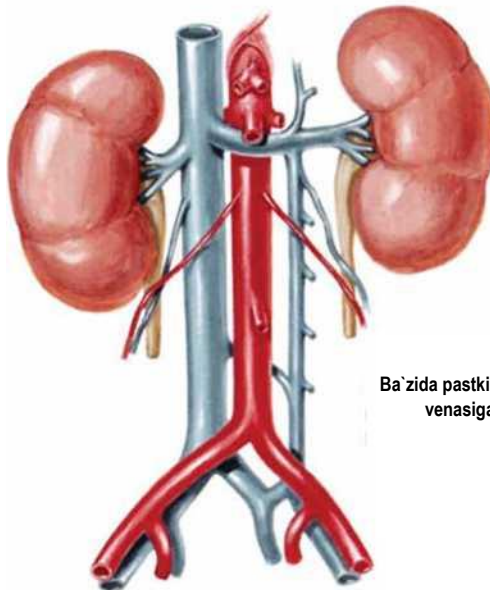
Buyrak
arteriyasining
proksimal bo'linishi



почечная
формировать
Ikkilangan chap buyrak venasi
aortani atrofini xalqa kabi
o'rashi mumkin

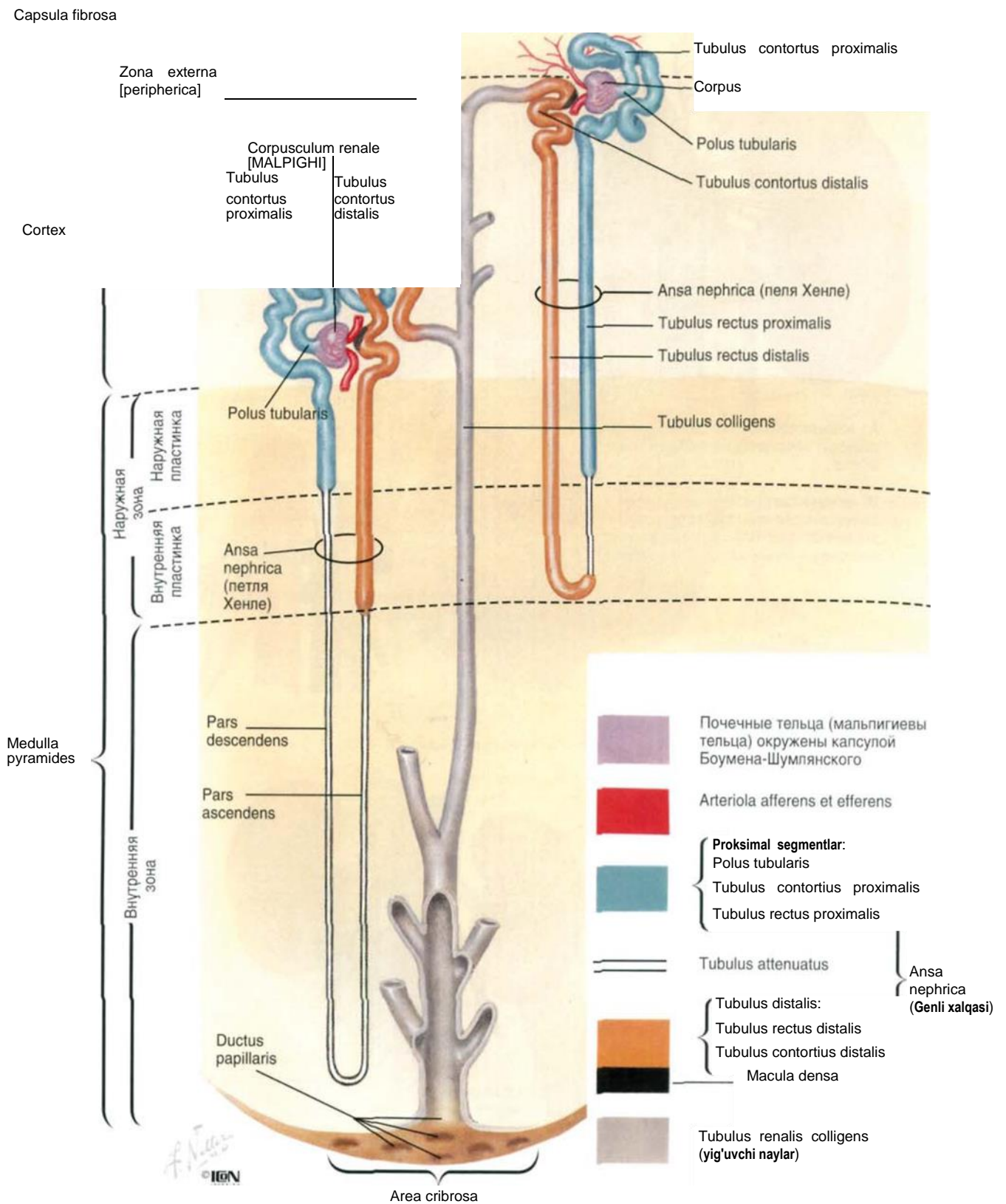


Ko'p sonli buyrak venalariga ega

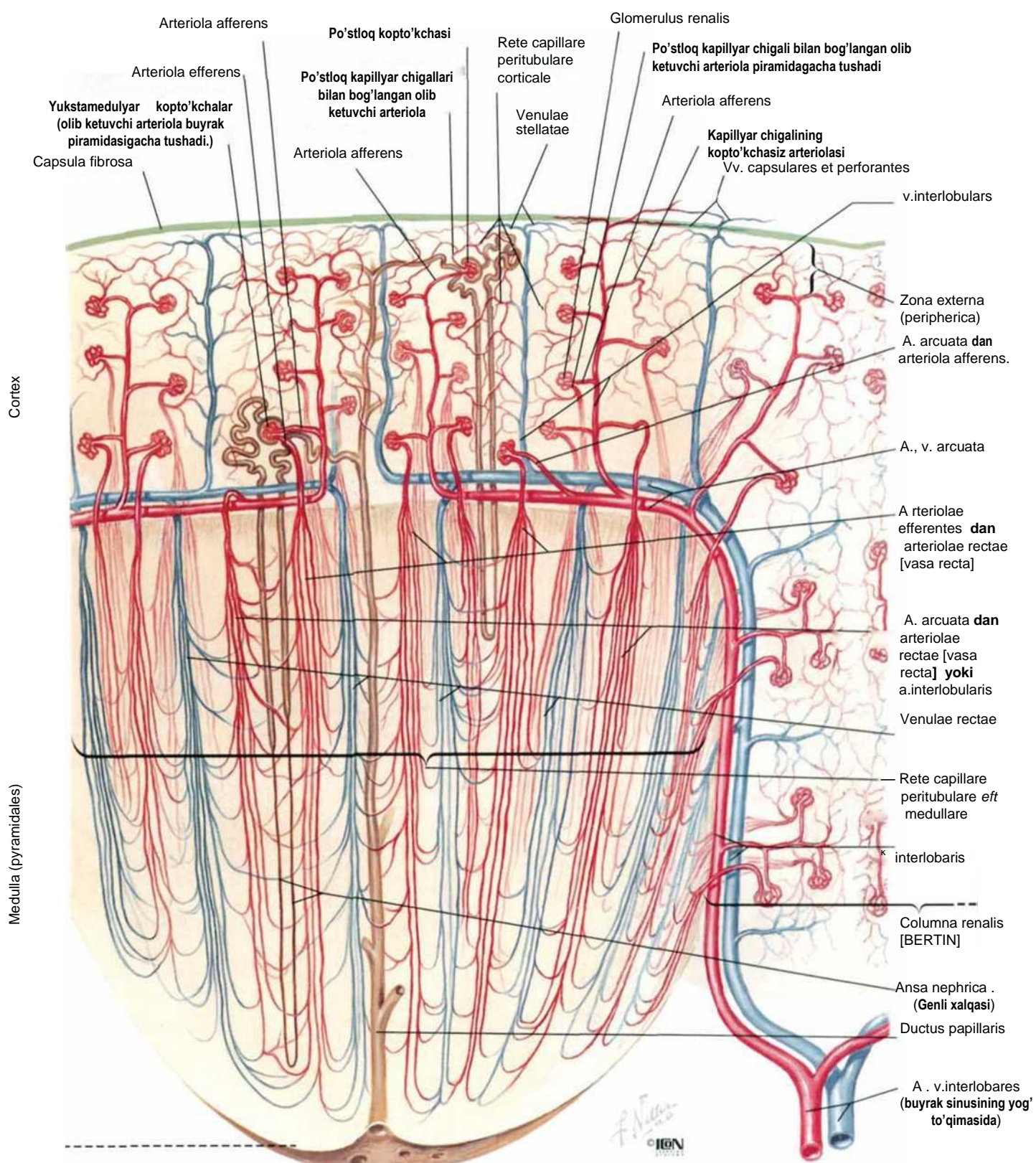


Ba'zida pastki kovak vena chap buyrak
venasiga quyulishi mumkin

Nefron va yig'uvchi naylar: sxemasi

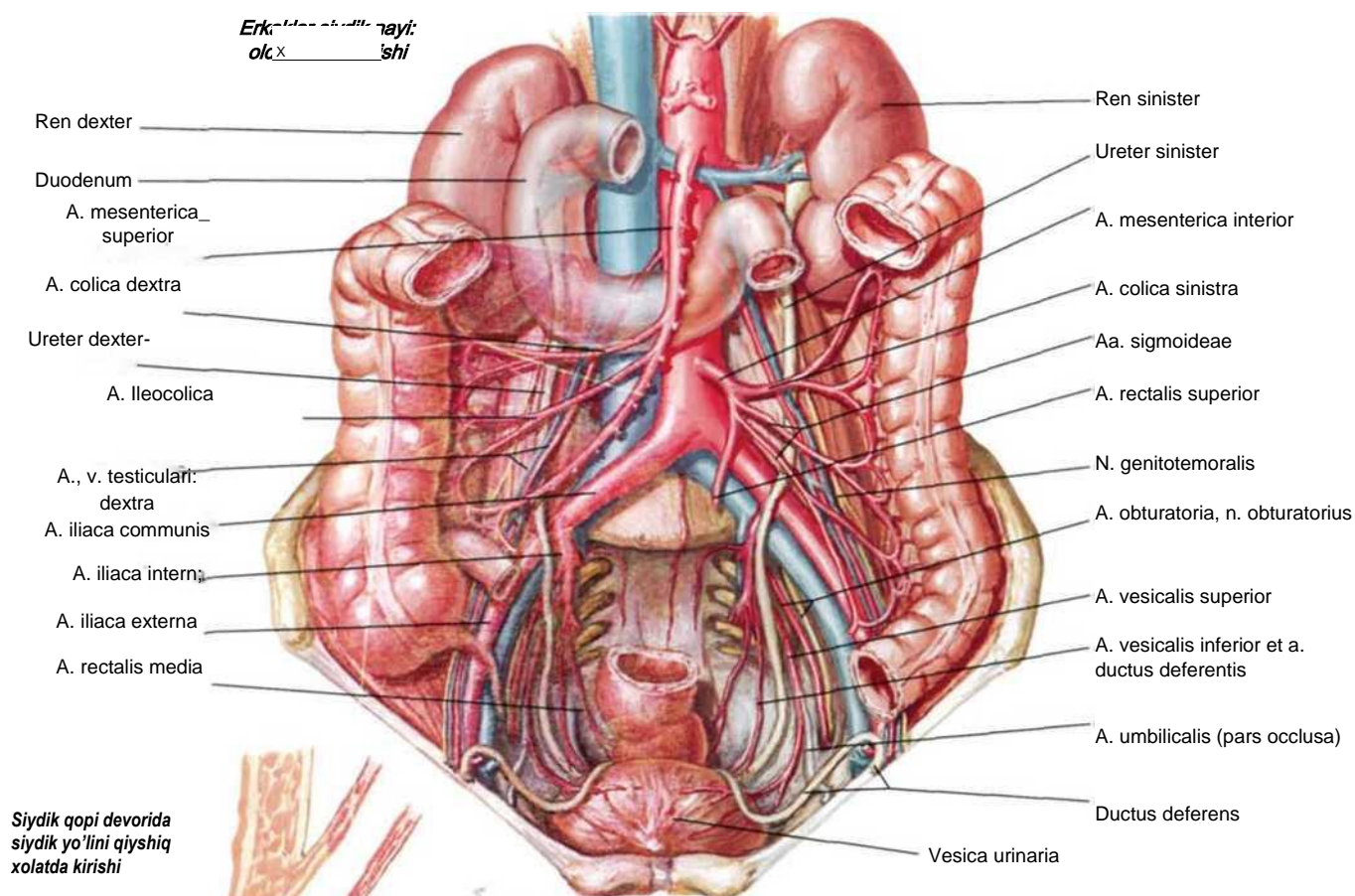


Buyrak parenximasi qon tomirlari: sxemasi

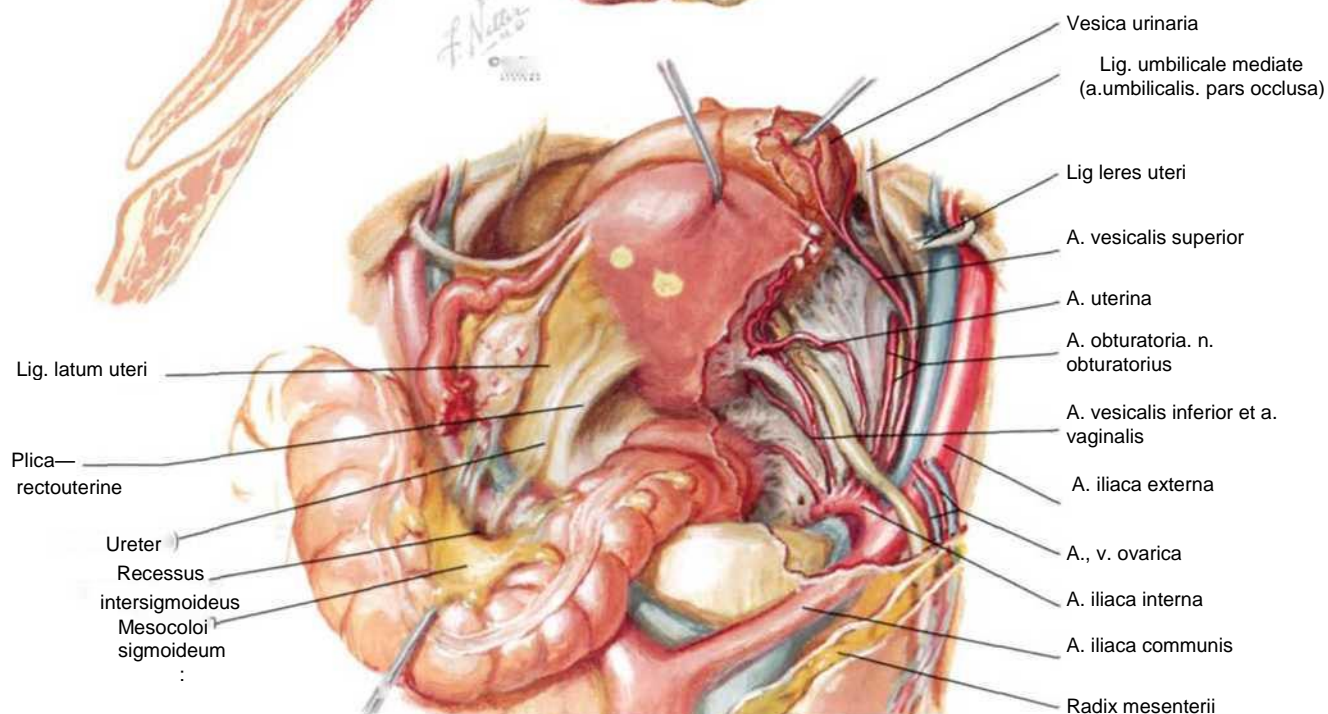


Siydik nayi (ureter)

Erk... nayi:
olk... shi

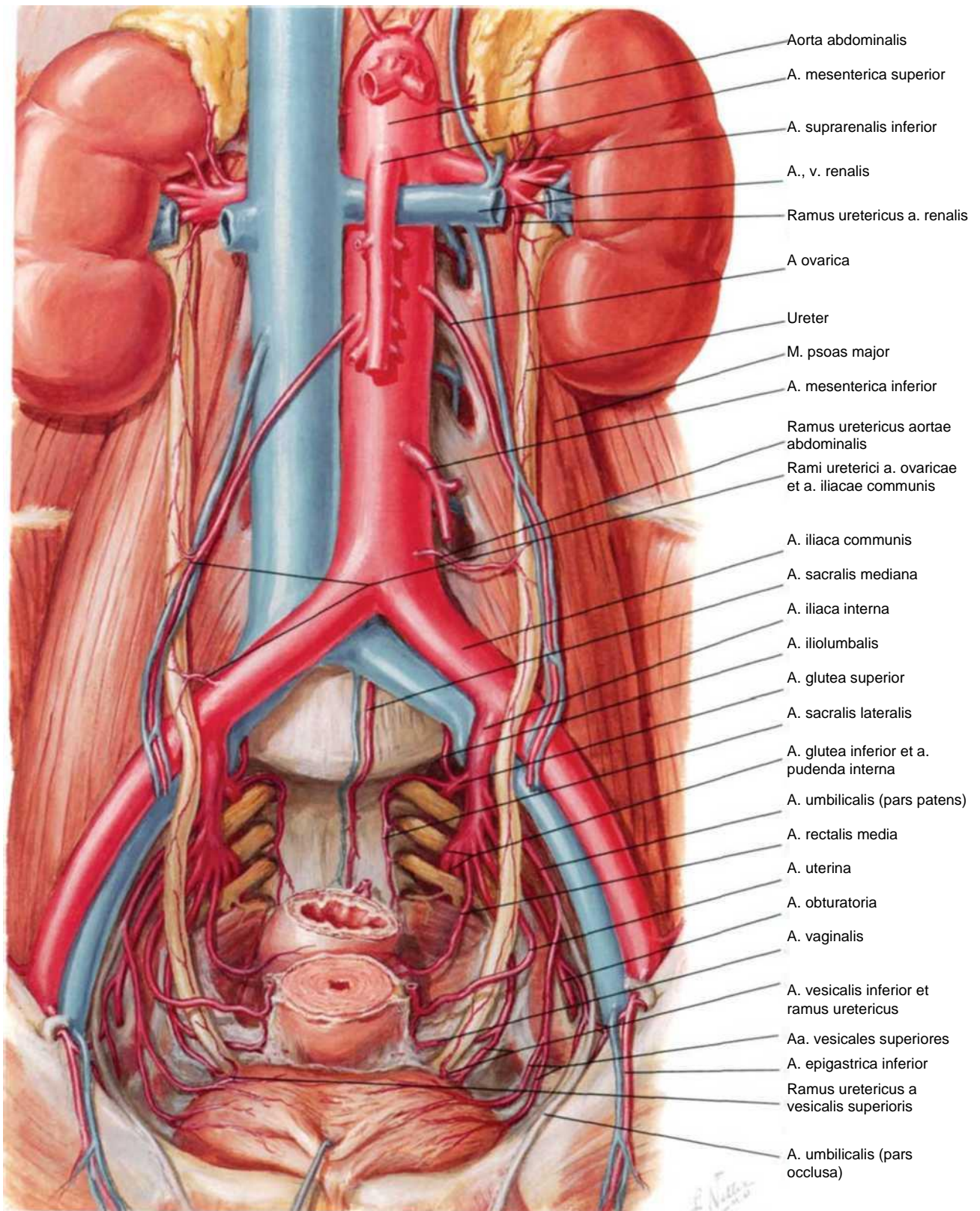


Siydik qopi devorida
siydik yo'lini qiyshiq
xolatda kirishi

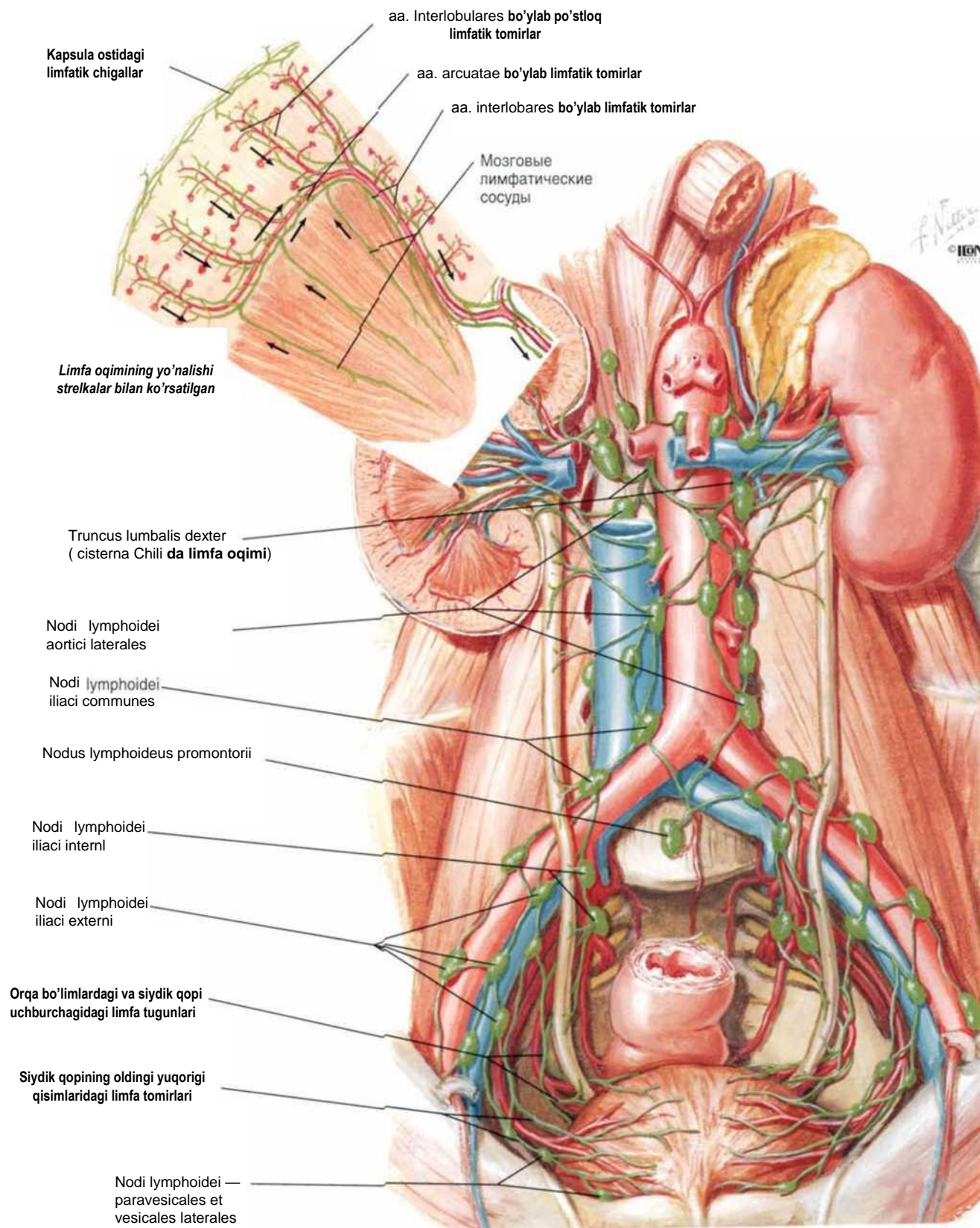


Oldindan ko'rinishi

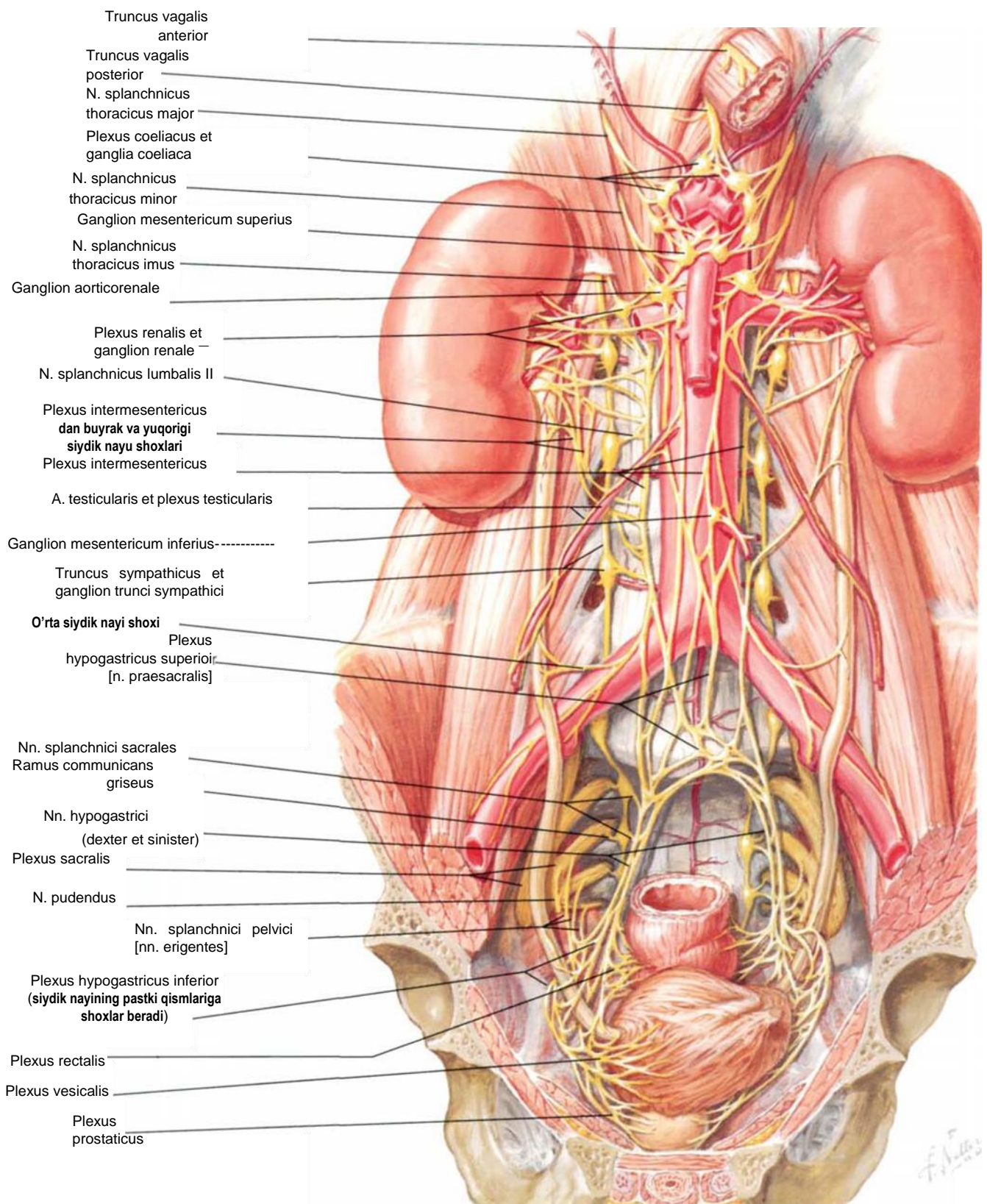
Siydik nayi va siydik qopi arteriyalari



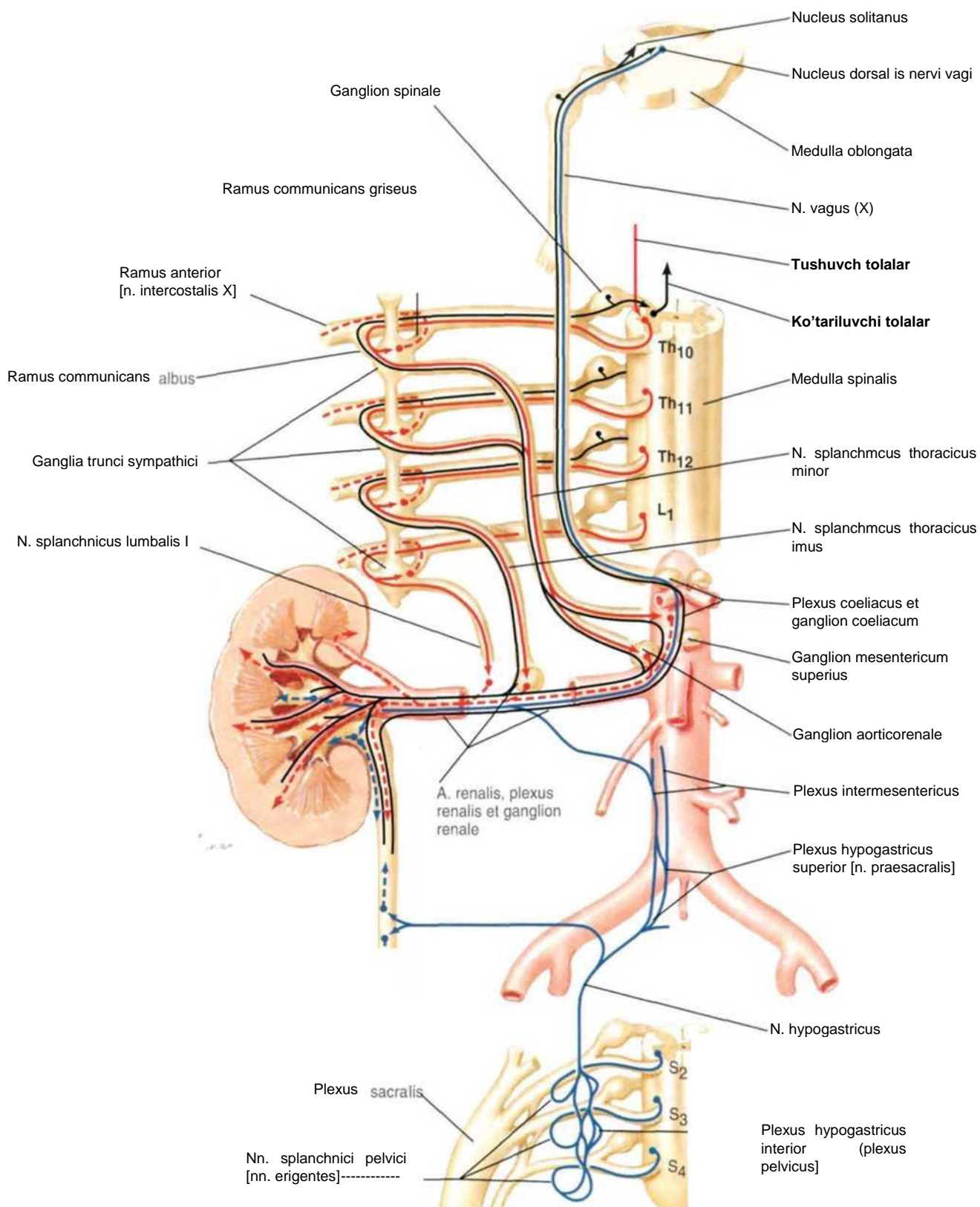
Buyrak va siydik qopi limfa tomirlari va tugunlari



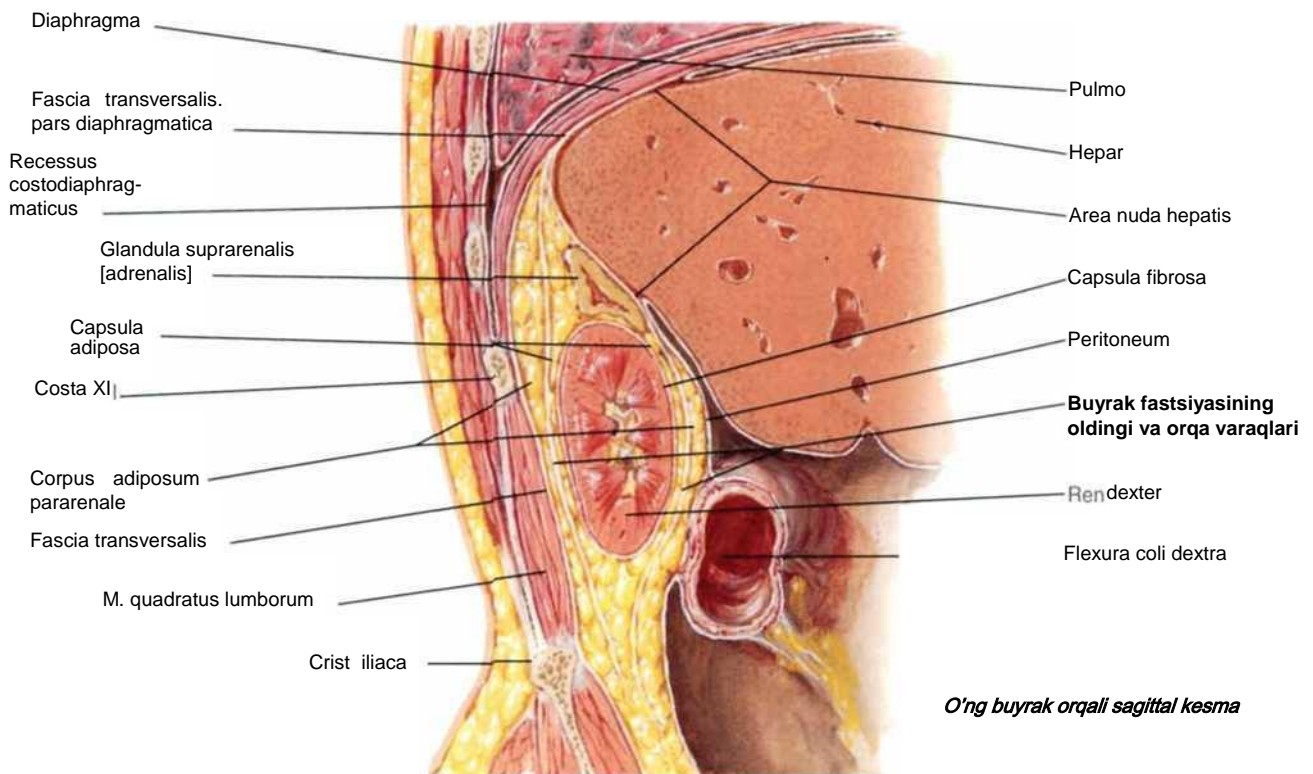
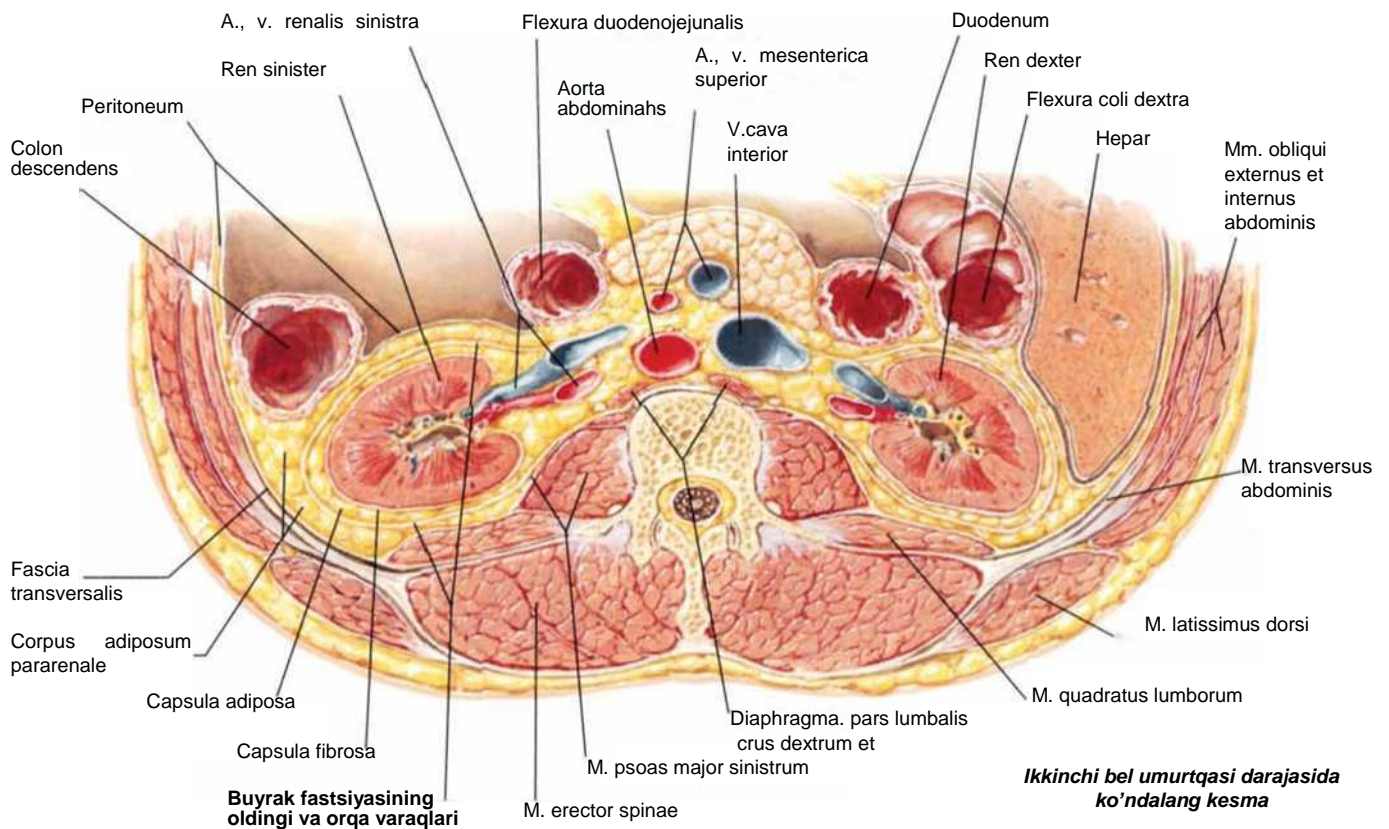
Buyrak, siydik nayi va siydik qopining innervatsiyasi



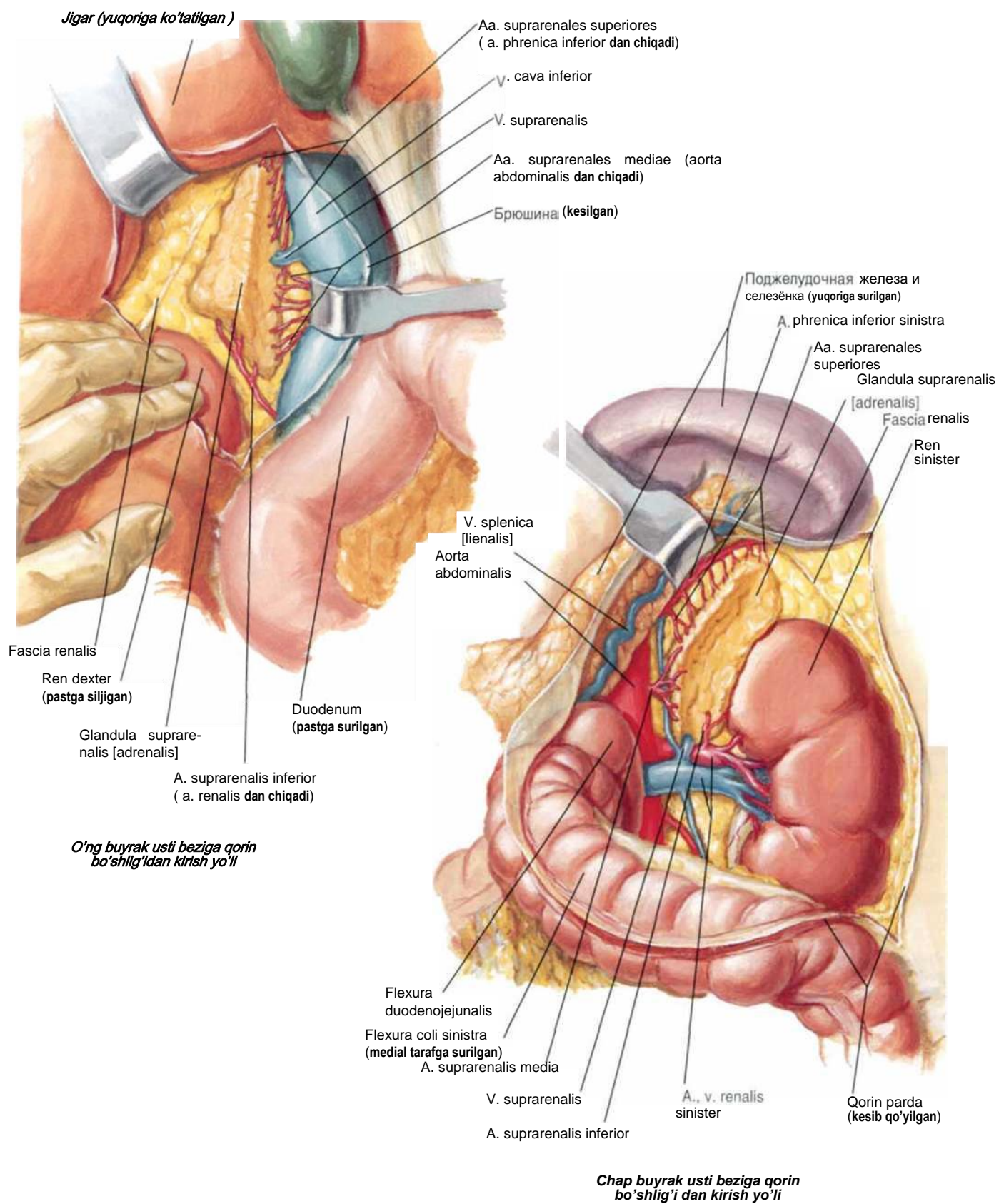
Buyraklar innervatsiyasi: sxemas

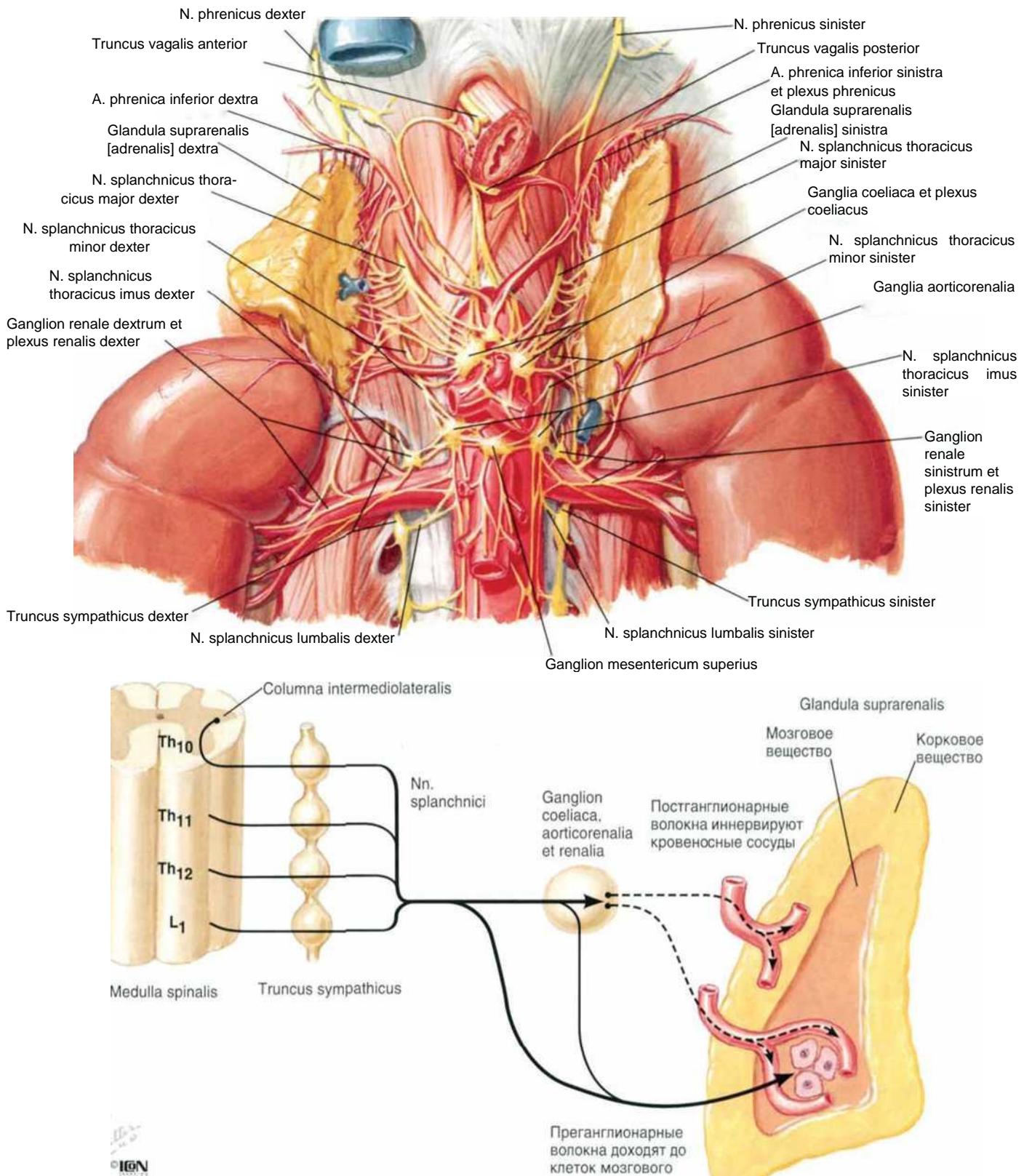


Buyrak fastsiyasi (fascia renalis)

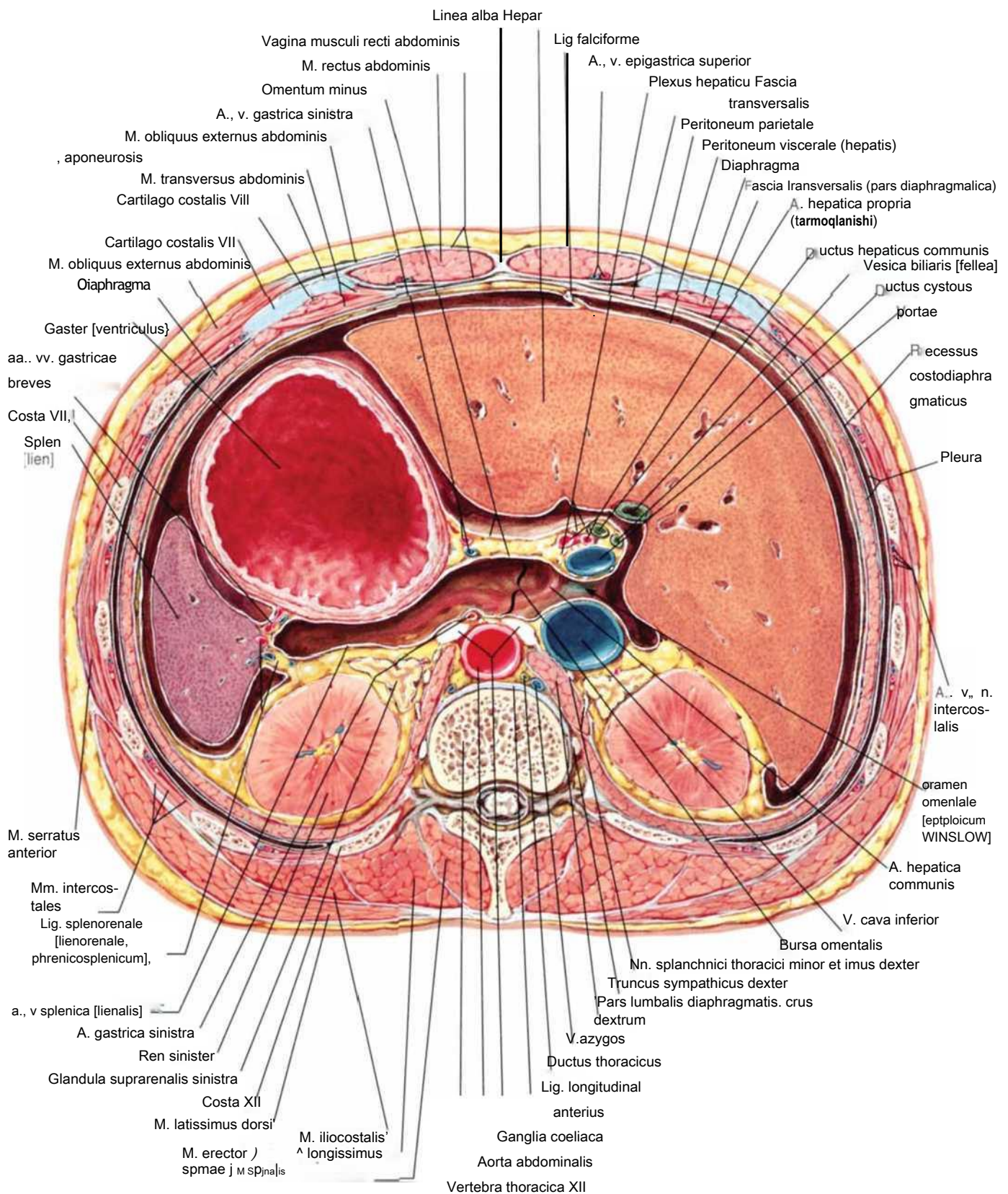


Buyrak usti bezining arteriyalari va venalar

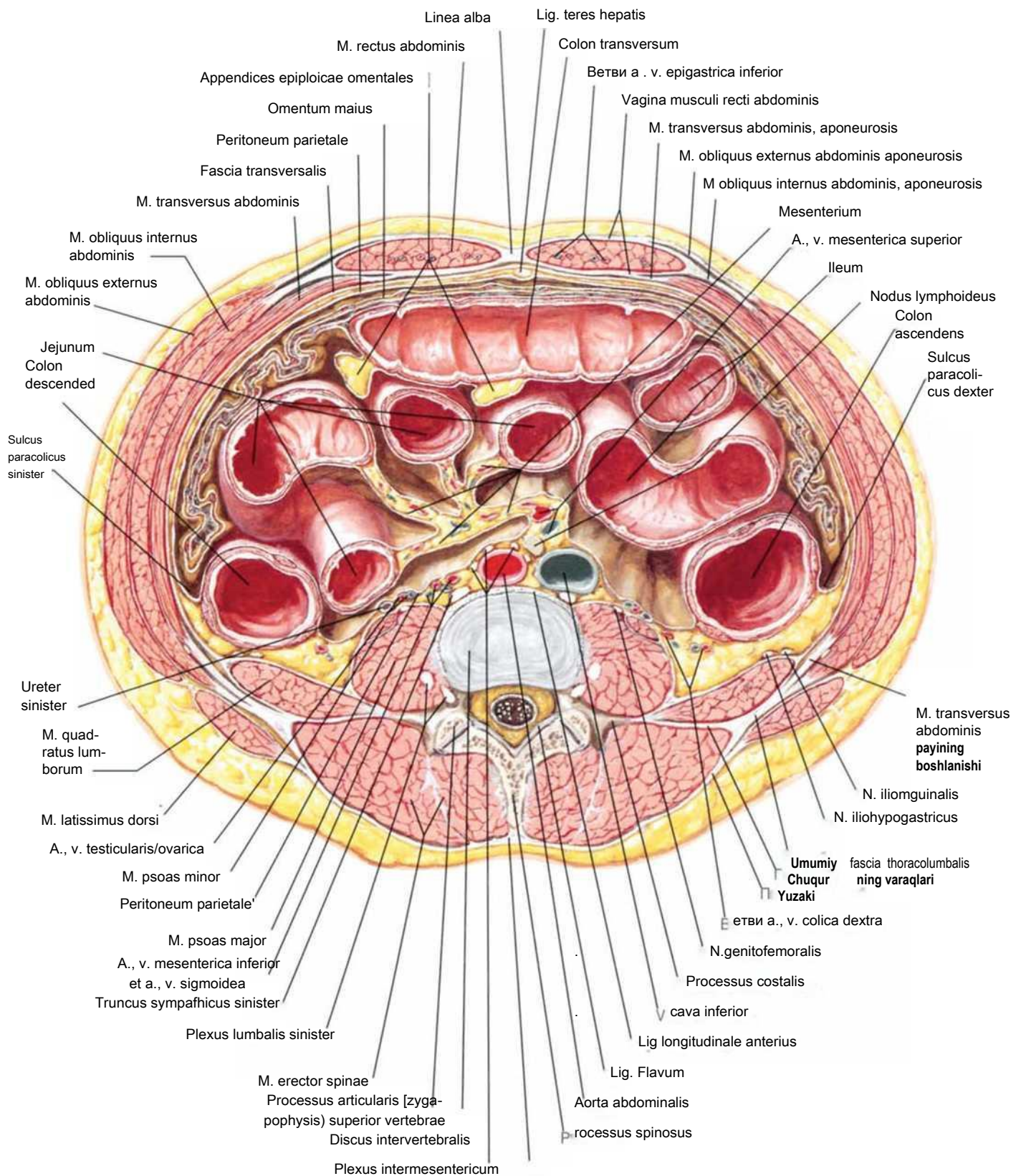




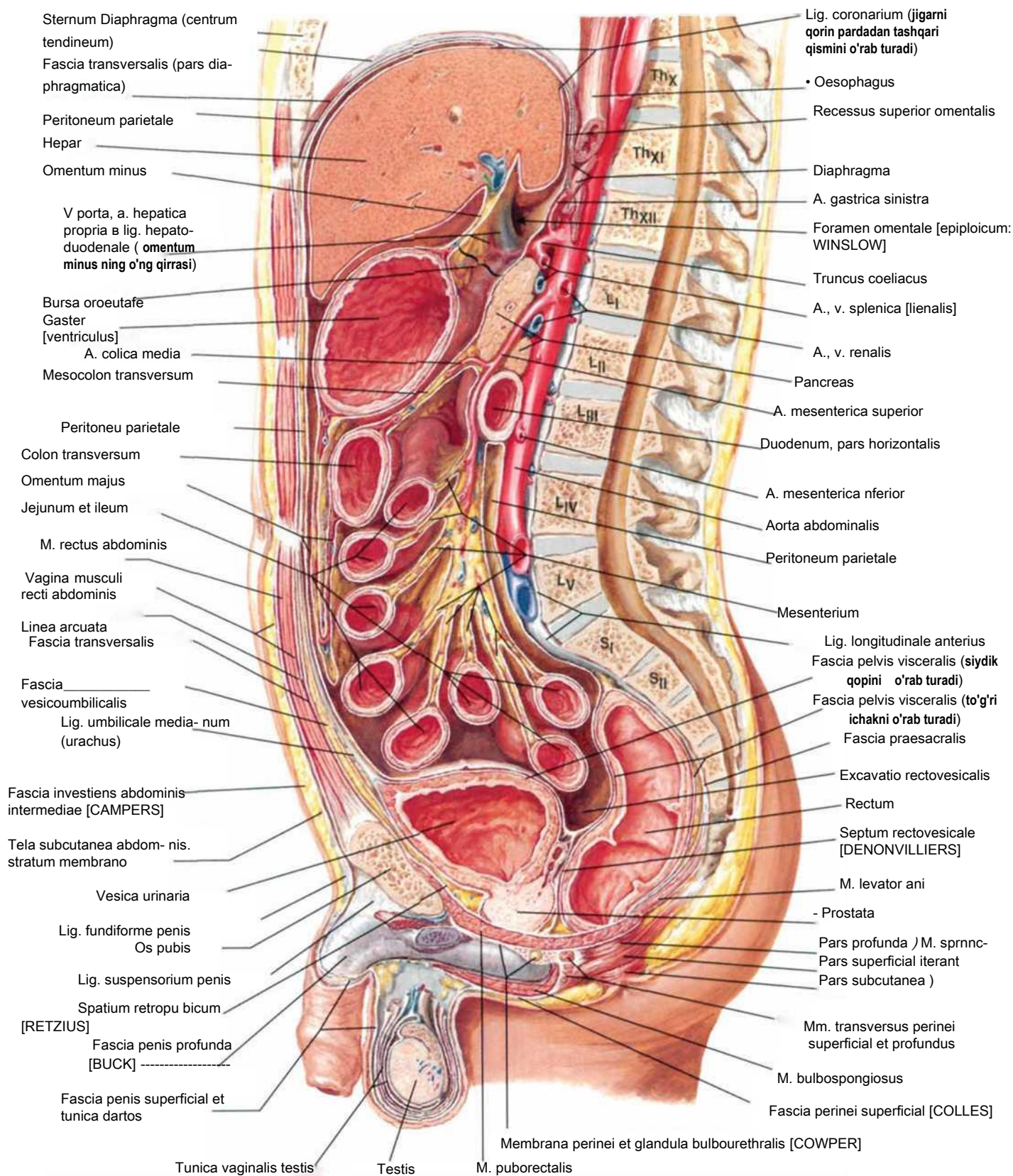
XII ko'krak umurtqasi darajasida qorin bo'shlig'ini ko'ndalang kesmasi (yuqoridan ko'rinishi)



*Birinchi bel umurtqasi darajasida qorin bo'shlig'ini
ko'ndalang kesmasi*



Qorin bo'shlig'ini sagittal kesmas



V-Bolim

TOS VA ORALIQ

SOXASI

SUYAKLAR BA BOYLAMLAR

330-332 Rasm

- 330. *Tosning suyak va boylamlari*
- 331. *Tosning suyak va boylamlari (davomi)*
- 332. *Tos suyaklaridagi jinsiy tafovud va ularning o'lchamlarini aniqlash*

TOS BO'SHLIGINING TUBI

333-343 Rasm

- 333. *Tos diafragmasi: ayollarniki*
- 334. *Tos diafragmasi: ayollarniki (davomi)*
- 335. *Tos diafragmasi: erkaklarniki*
- 336. *Tos diafragmasi: erkaklarniki (davomi)*
- 337. *Ayollar tosi va oraliq soxasi a'zolari*
- 338. *Erkaklar tosi va oraliq soxasi a'zolari*
- 339. *Ayollar tos a'zolari*
- 340. *Erkaklar tos a'zolari*
- 341. *Tos fastsiyalari*
- 342. *Siydik qopi (vesica urinaria): topografiyasi*
- 343. *Ayollar va erkaklar siydik qopi*

AYOLLAR TOS BO'SHLIG'I

344-353 Rasm

- 344. *Ayollar tos a'zolari*
- 345. *Bachadon (uterus), qin (vagina) va ularni o'rab turuvchi a'zolar*
- 346. *Tuxumdon (ovarium) va bachadon naylari (tuba uterina [salpinx])*
- 347. *Bachadon: yoshga xos o'zgarishlar va miometriyning tuzulishi*
- 348. *Bachadon: joylashish variantlari*
- 349. *Tuxumdon, tuxum xujayralari va falikulalar*
- 350. *Oraliq soxasi (perineum) va ayollar tashqi jinsiy a'zolari*
- 351. *Oraliq soxasi: yuzaki tuzulmalari*
- 352. *Oraliq soxasi: chuqur tuzulmalari*
- 353. *Ayollar uretrasi (urethra feminina)*

ERKAKLAR TOS BO'SHLIG'I

354-362 Rasm

- 354. *Erkaklar oraliq soxasi va tashqi jinsiy a'zolari : yuzaki tuzulmalari*
- 355. *Erkaklar oraliq soxasi va tashqi jinsiy a'zolari : chuqur tuzulmalari*
- 356. *Jinsiy olat (penis)*

- 357. *Oraliq soxasi: chuqur tuzulmalari*
- 358. *Prostata bezi (prostata) va urug' puffakchalari (glandulae vesiculosae)*
- 359. *Erkaklar siydik chiqaruv kanali (urethra masculina)*
- 360. *Urug'donlarni pastga tushishi*
- 361. *Yorg'oq (scrotum)*
- 362. *Urug'don (testis [orchis]), urug'don ortig' (epididymis) va urug' yo'li (ductus deferens)*

TO'G'RI ICHAK

363-368 Rasm

- 363. *To'g'ri ichak (rectum)*
- 364. *Quymich-to'g'ri ichak chuqurchasi (fossa ischioanal)*
- 365. *To'g'ri ichak (rectum) va anal kanali (canalis analis)*
- 366. *To'g'ri ichak va anal kanali muskullari*
- 367. *Tosning tubi va oraliq soxasi: pastdan ko'rinishi*
- 368. *Tos va oraliq soxasi bo'shliqlari*

QON BILAN

TA'MINLANISHI

369-379 Rasm

- 369. *To'g'ri ichak va anal kanali arteriyalari*
- 370. *To'g'ri ichak va anal kanali venalari*
- 371. *Ayollar tos a`zolari arteriya va venalari*
- 372. *Urug'don arteriyalari va venalari*

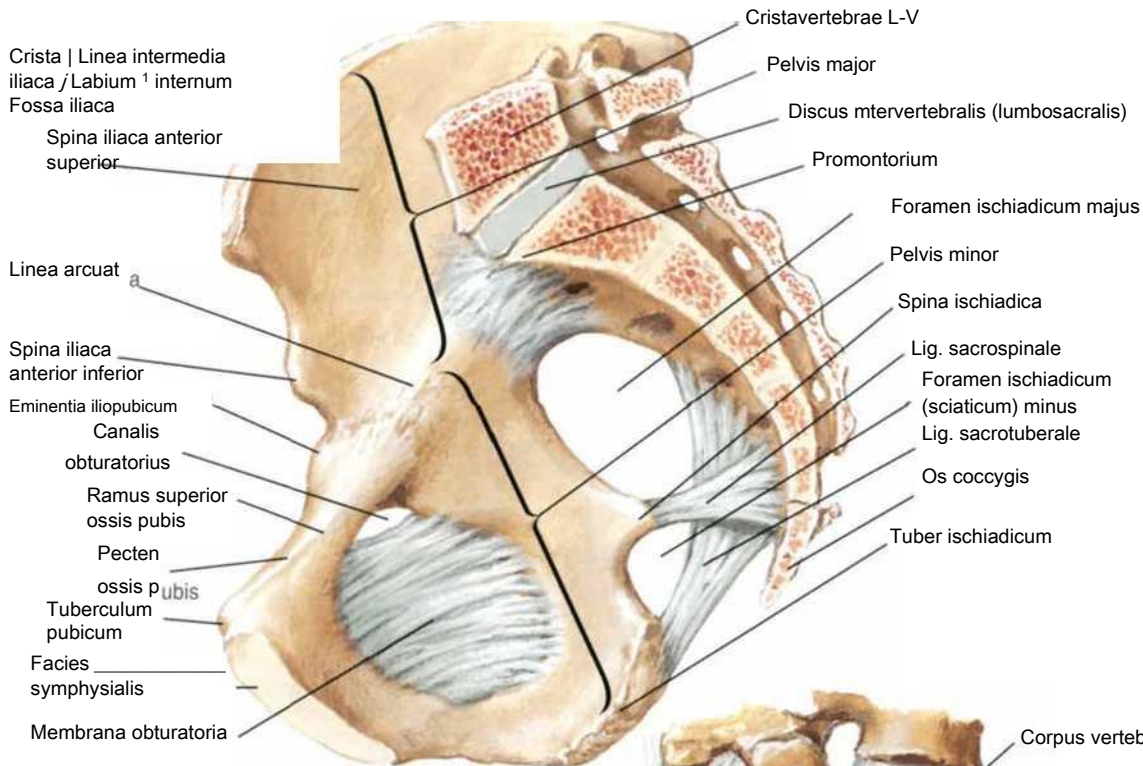
- 373. *Ayollar tosining arteriya va venalari*
- 374. *Erkaklar tosining arteriya va venalari*
- 375. *Oraliq soxasi va bachadon arteriya va venalari*
- 376. *Erkaklar oraliq soxasi arteriya va venalari*
- 377. *Ayollar tosi va jinsiy a`zolari limfa tomirlari va tugunlari*
- 378. *Ayollar oraliq soxasi limfa tomirlari va tugunlari*
- 379. *Erkaklar tosi va jinsiy a`zolari limfa tomirlari va tugunlari*

INNervatsiya

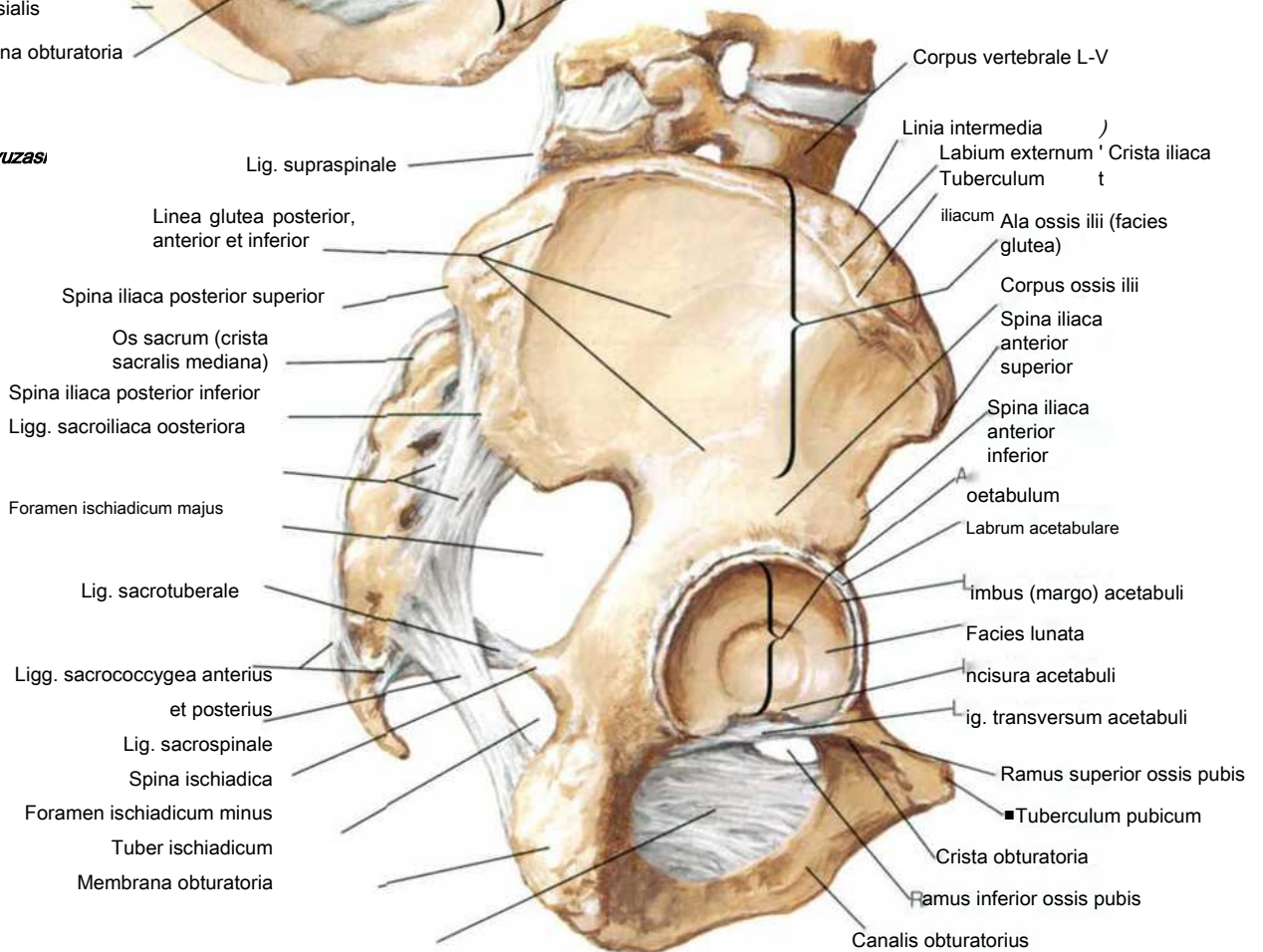
380-390 Rasm

- 380. *Erkaklar tashqi jinsiy a`zolari innervatsiyasi*
- 381. *Erkaklar tos a`zolari innervatsiyasi*
- 382. *Erkaklar oraliq soxasi innervatsiyasi*
- 383. *Ayollar tos a`zolari innervatsiyasi*
- 384. *Ayollar oraliq soxasi va tashqi jinsiy a`zolari innervatsiyasi*
- 385. *Tug'ruq jarayonida impuls o'tkazishda ishtirok etuvchi nervlar*
- 386. *Ayollar jinsiy a`zolari innervatsiyasi: sxemasi*
- 387. *Erkaklar jinsiy a`zolari innervatsiyasi: sxema*
- 388. *Siydik qopi va siydik nayining innervatsiyasi: sxema*
- 389. *Tashqi jinsiy a`zolarining gomologik tuzulmalari*
- 390. *Ichki jinsiy a`zolarining gomologik tuzulmalari*

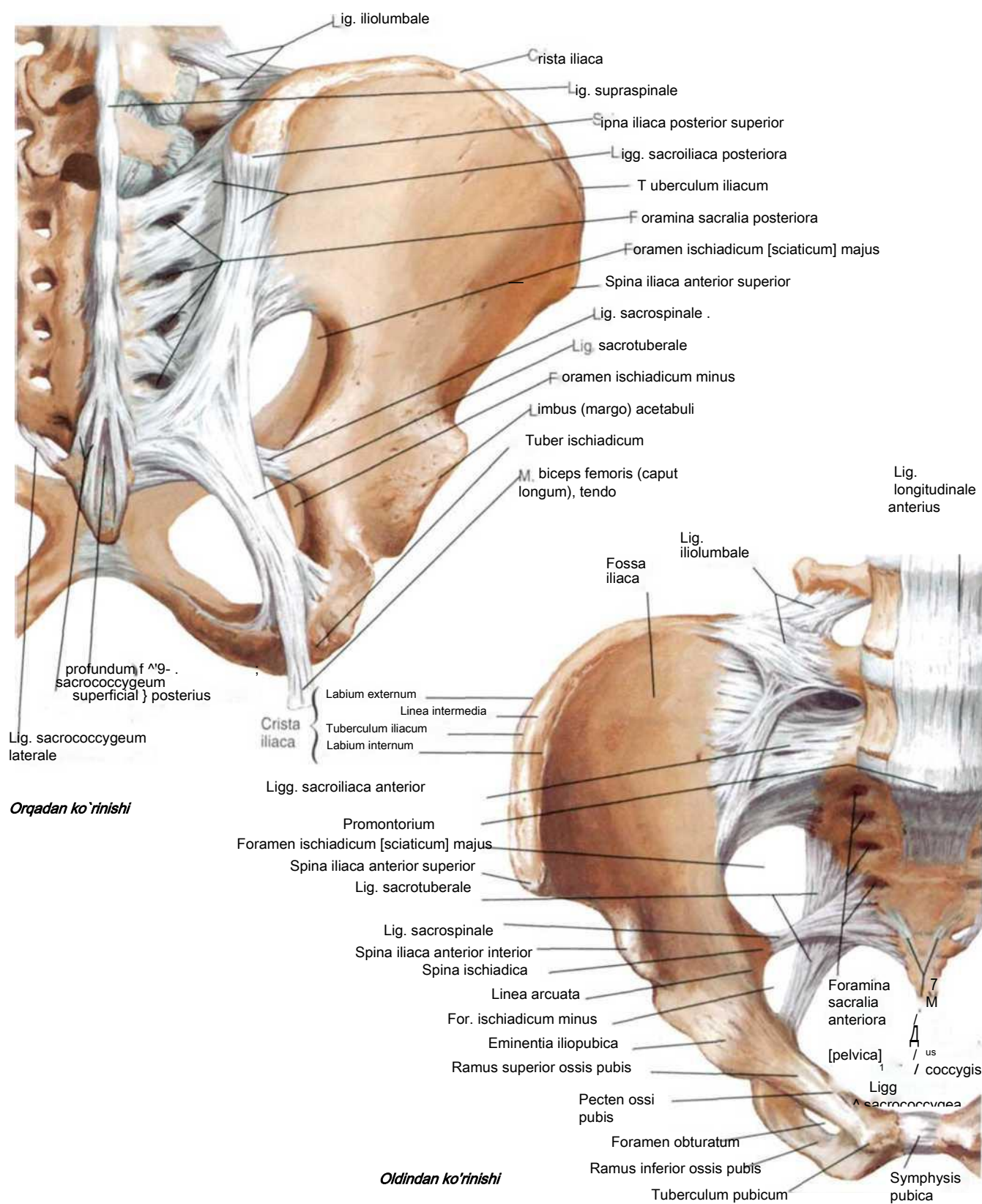
Medial yuzasi (sagittal kesma)



Lateral yuzasi

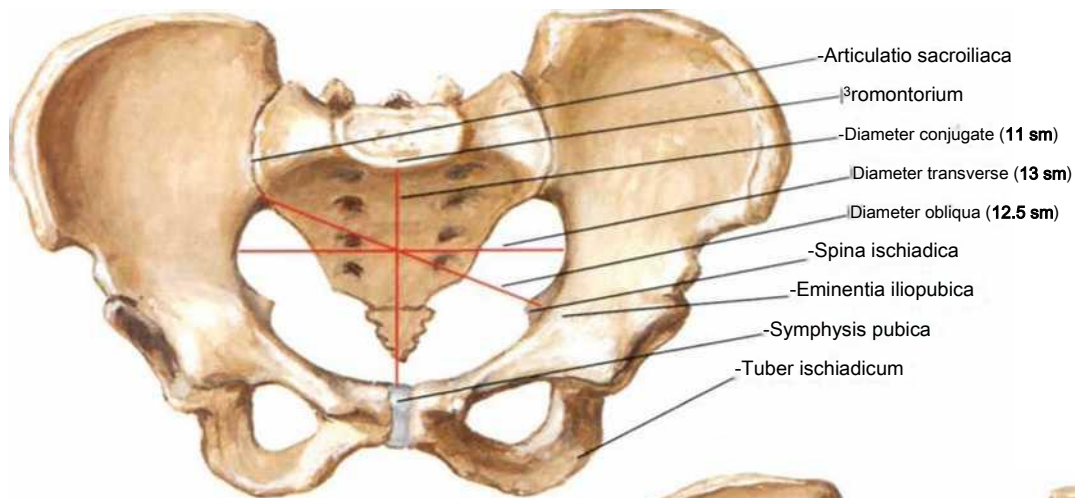


Tosning suyak va boylamlari (davomi)



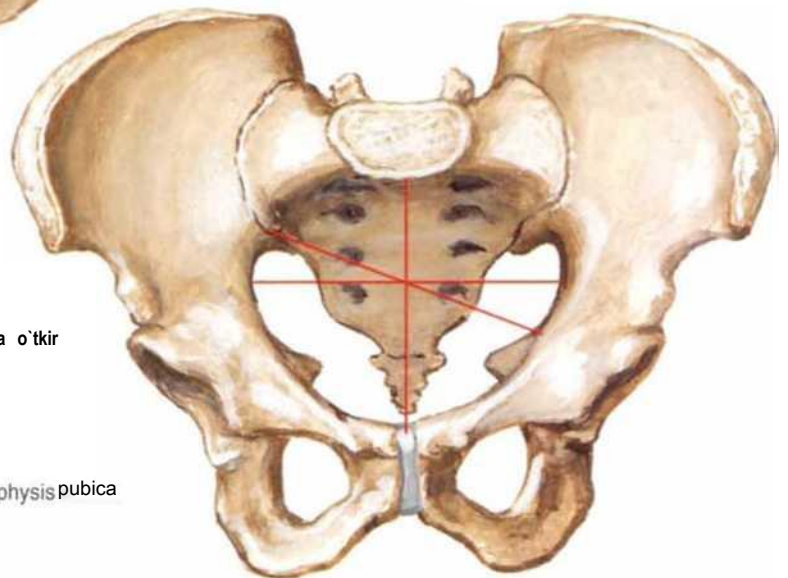
Tos suyaklaridagi jinsiy tafavud va uning o'lchamlarini aniqlash

Ayollar tosi: oldindan ko'rinishi



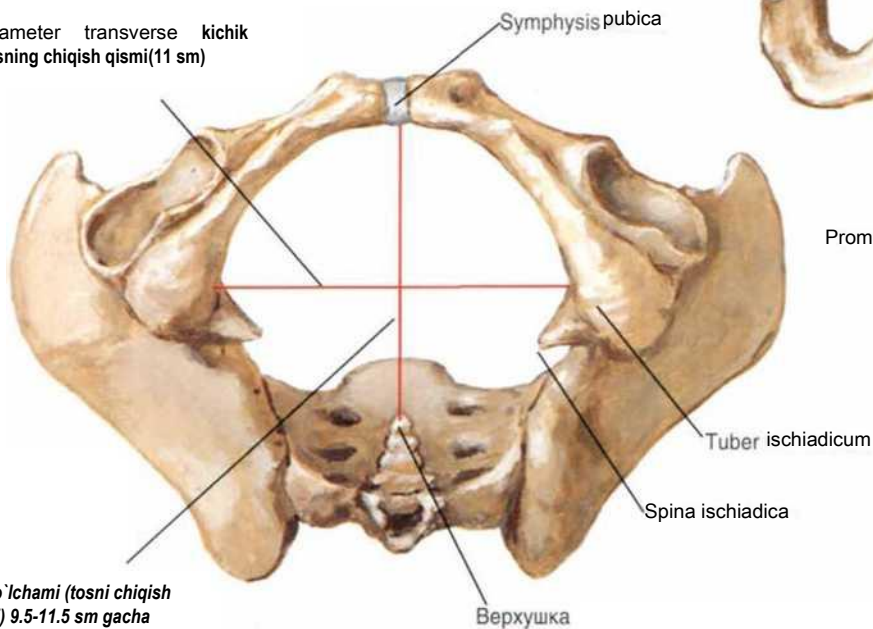
Kichik tosnig kirish qismni diametrlari

Erkaklar tosi: oldindan ko'rinishi



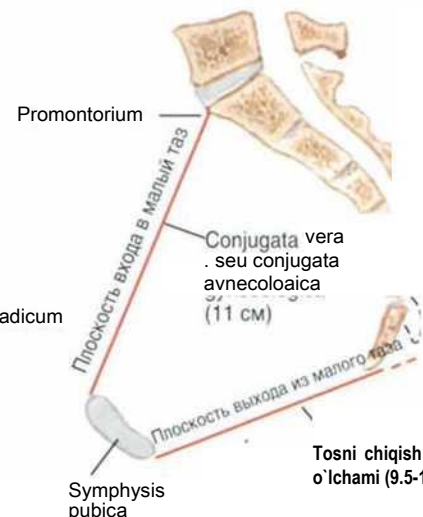
Barcha o'lchamlari (diametrlar) ayollarnikiga nisbatan kichik
Kichik tosnig kirish qismi ayollarda ovalsimon bo'lsa, erkaklarda esa "Qartadagi yurak" shaklini eslatadi
Qov simfizi chuqurroq va uzunroq
Qov suyaklarini ajralish qismi ayollarnikiga qaraganda o'tkir burchak hosil qiladi
Quymuch do'ngliklari orasidagi masofa kichik bo'ladi
Yonbosh suygi qanotl nisbatan vertikal holatda yozilgan

Diameter transverse kichik tosnig chiqish qismi (11 sm)



To'g'ri o'lchami (tosni chiqish qismi) 9.5-11.5 sm gacha o'zgarib turadi

Ayollar tosi: pastdan ko'rinishi

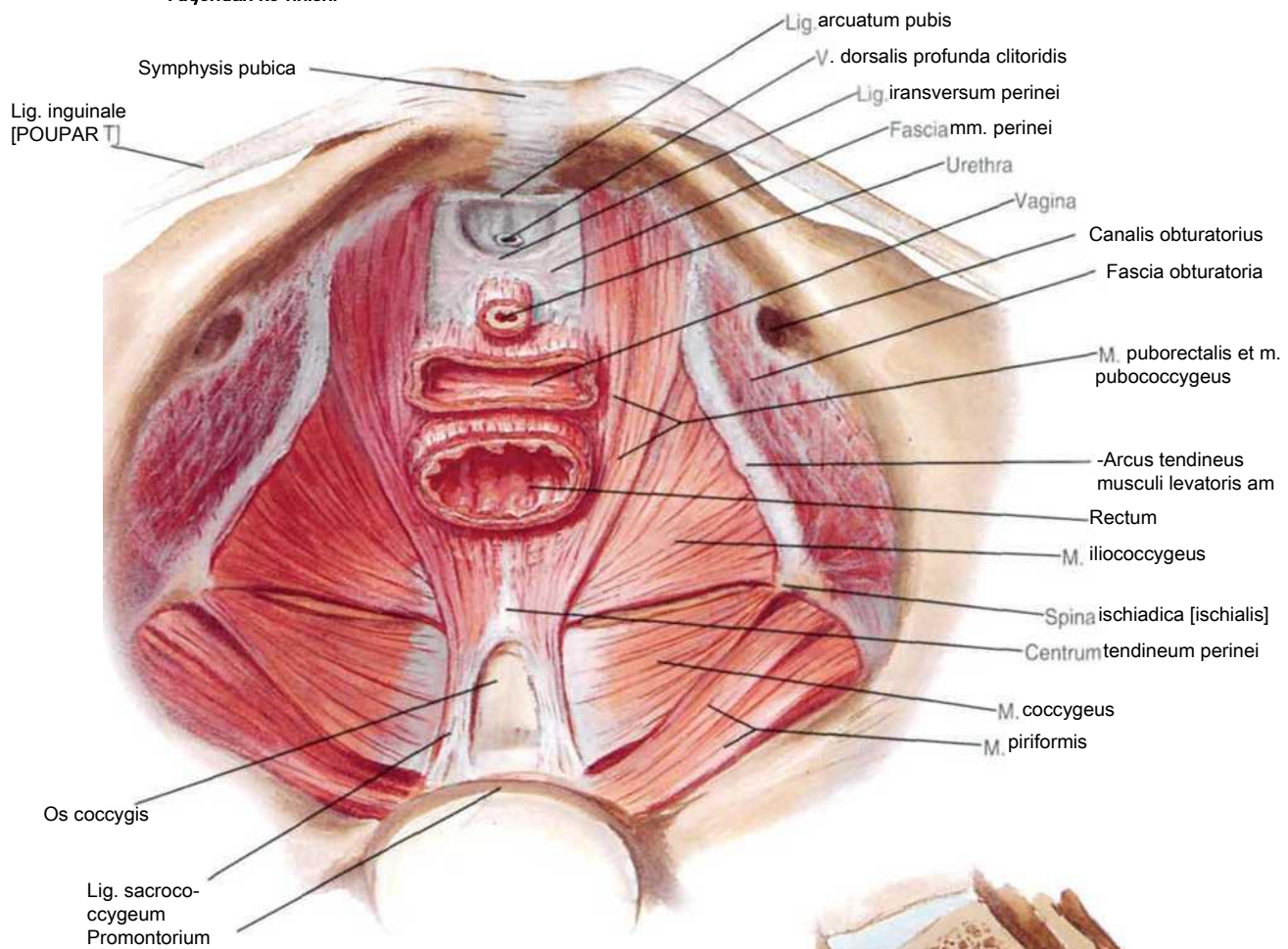


Tosni chiqish qismi to'g'ri o'lchami (9.5-11.5 sm)

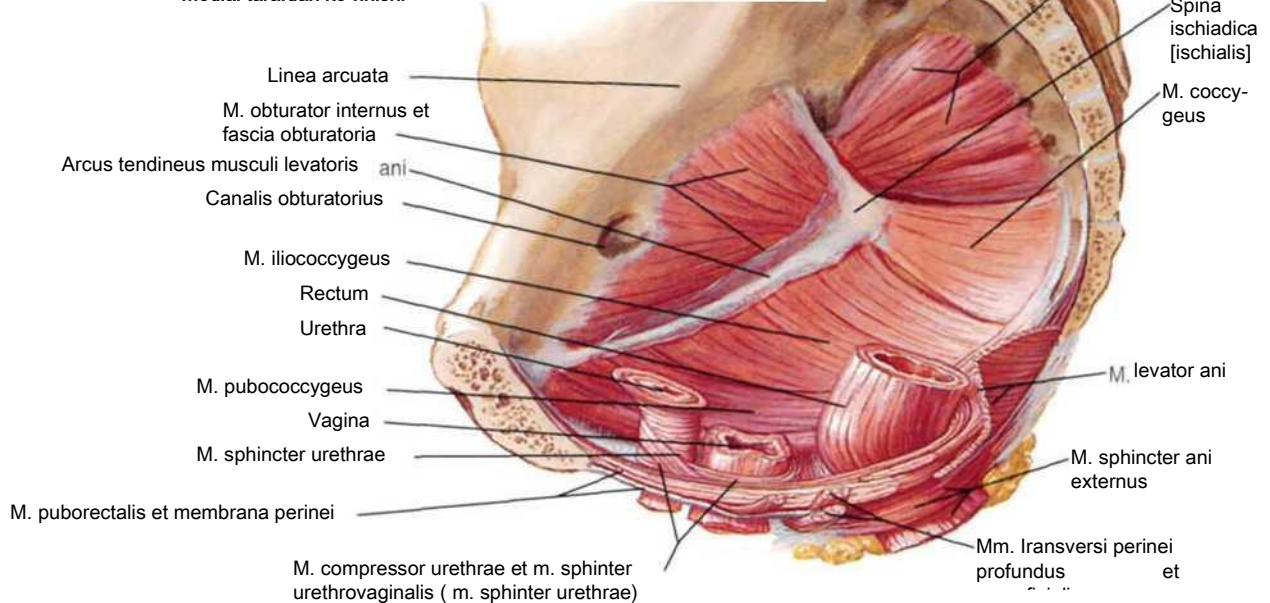
Ayollar tosi: sagittal kesmasi

Tos diafragmasi: ayollarniki

Yuqoridan ko'rinishi

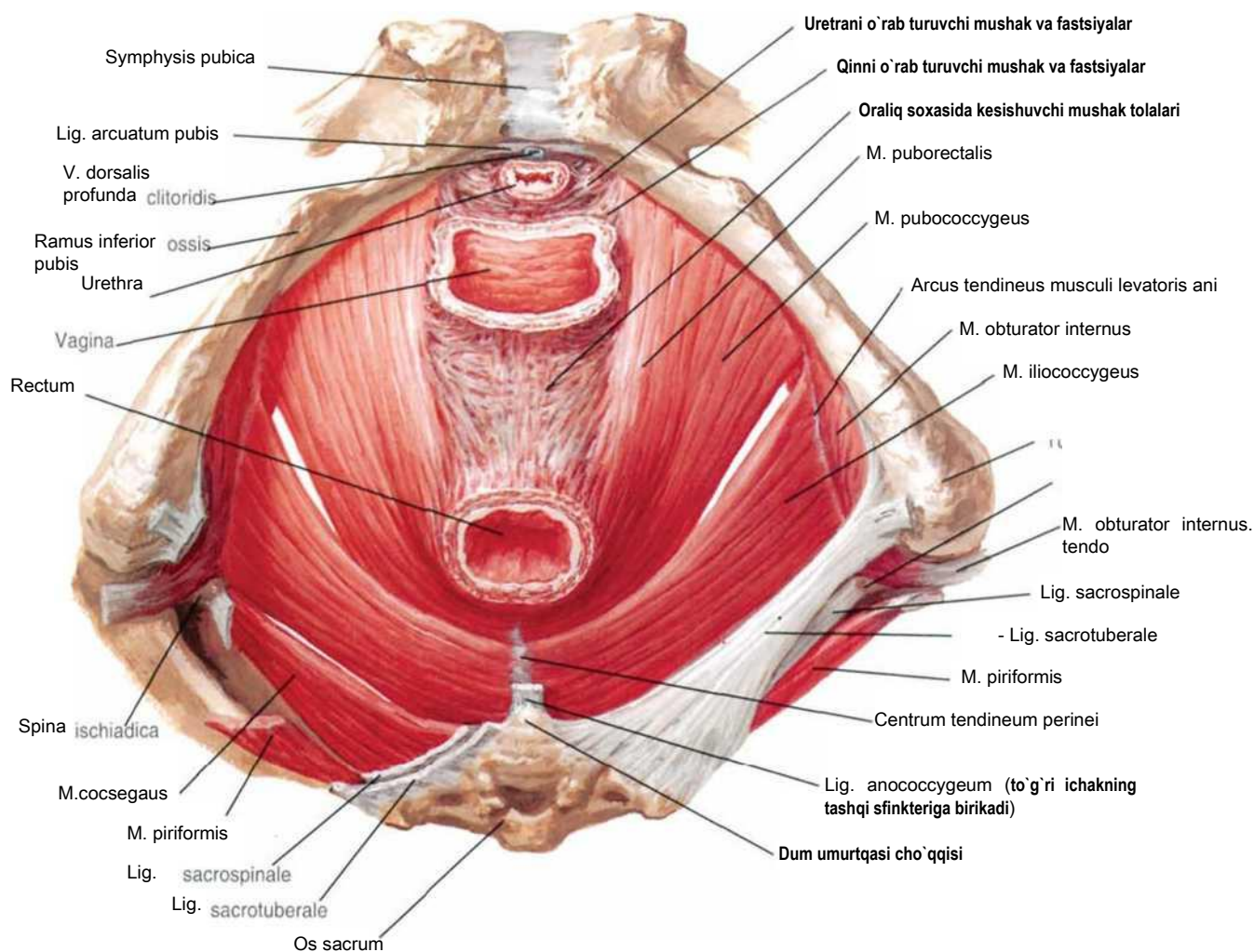


Medial tarafdin ko'rinishi

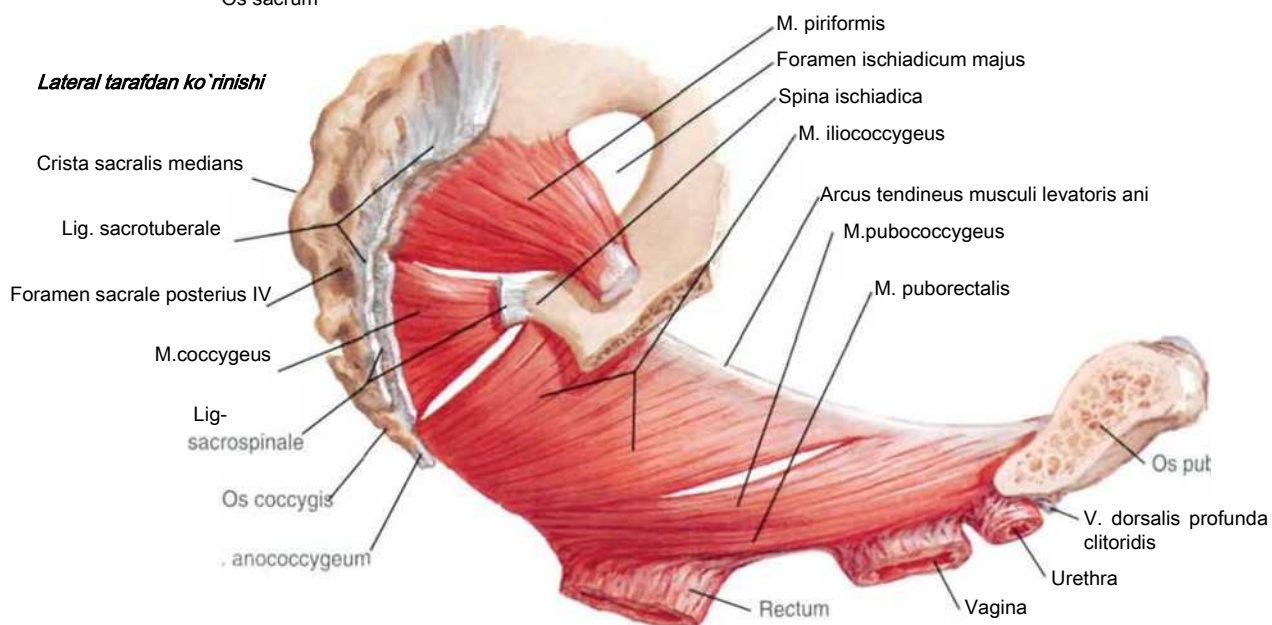


Tos diafragmasi: ayollarniki (davomi)

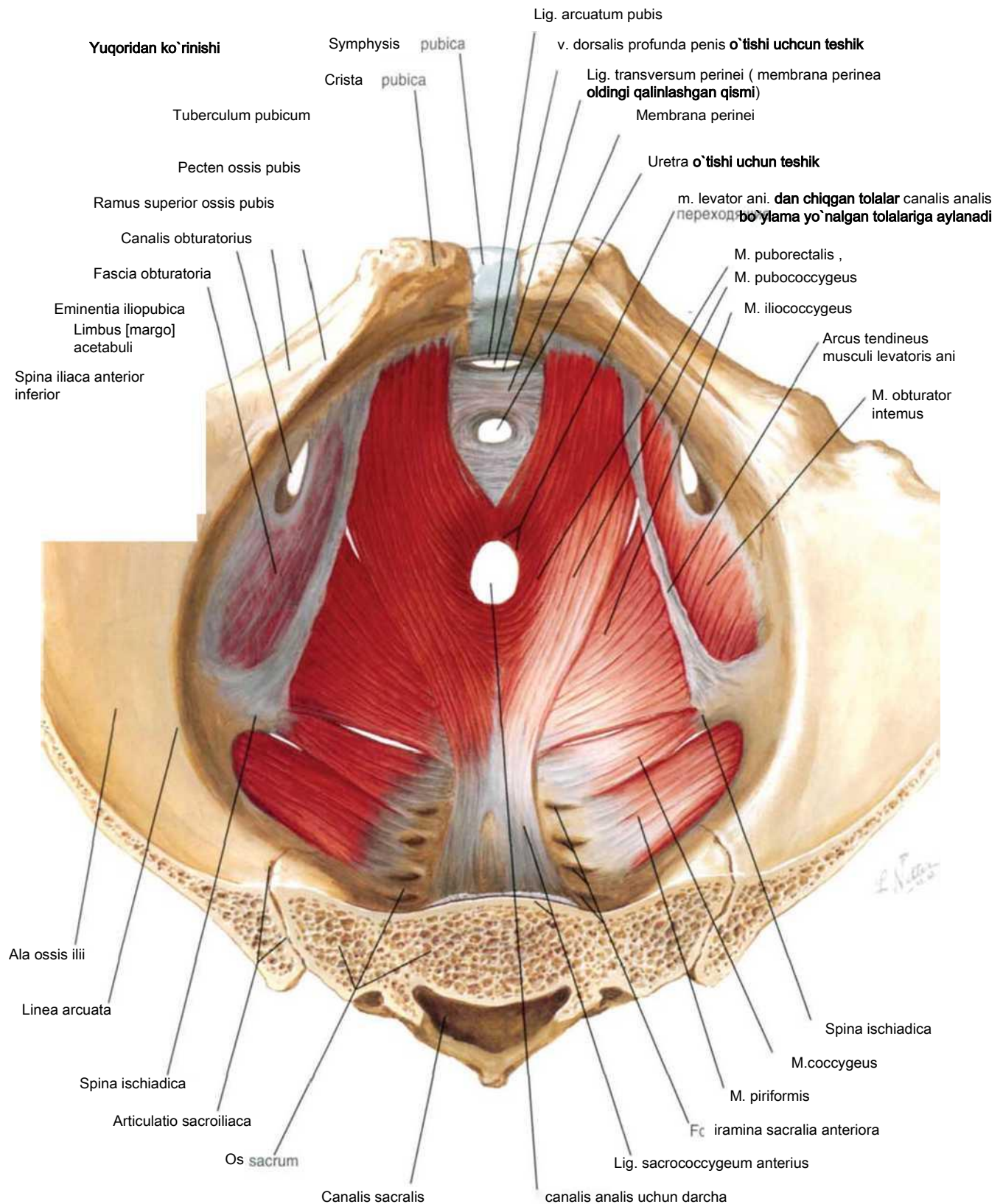
Pastdan ko'rinishi



Lateral tarafdin ko'rinishi

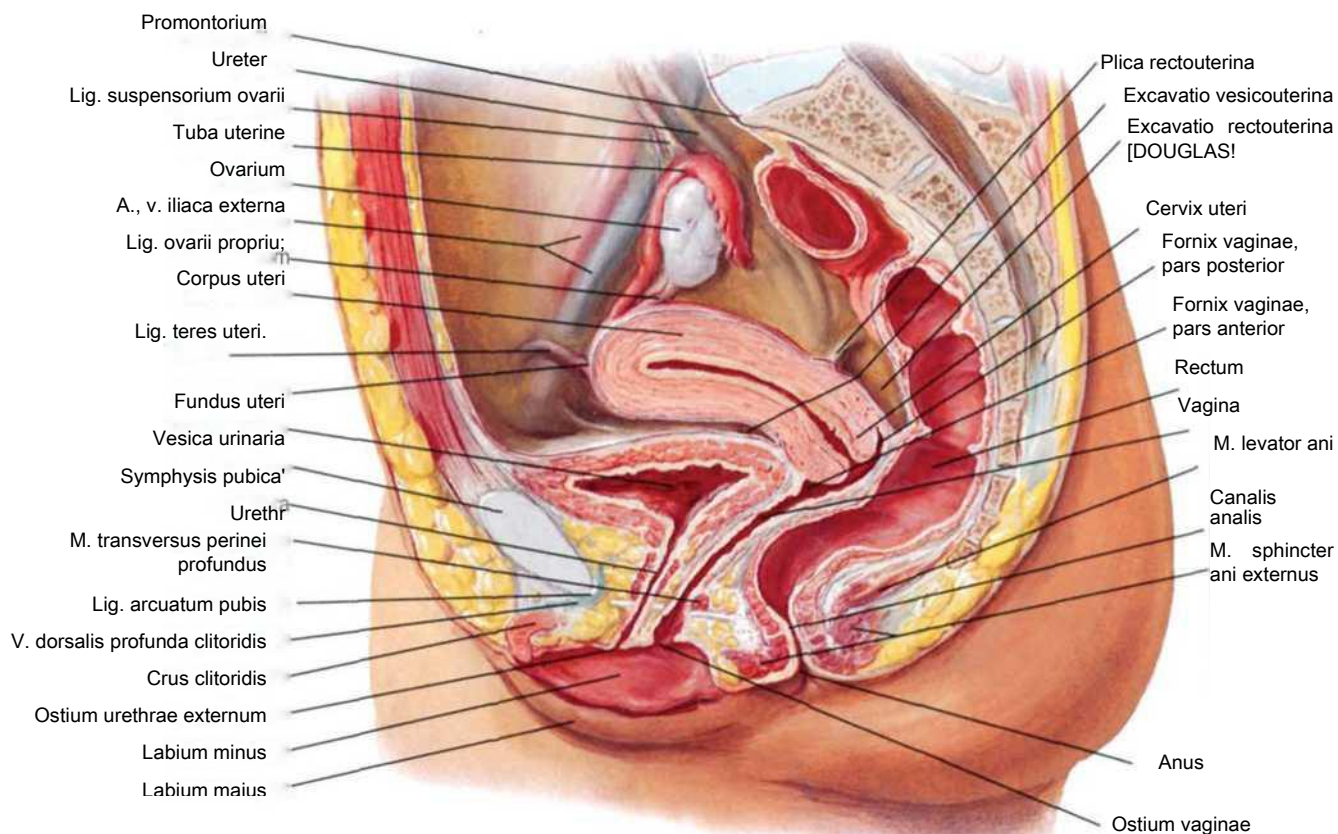


Tos diafragmasi: erkaklarniki

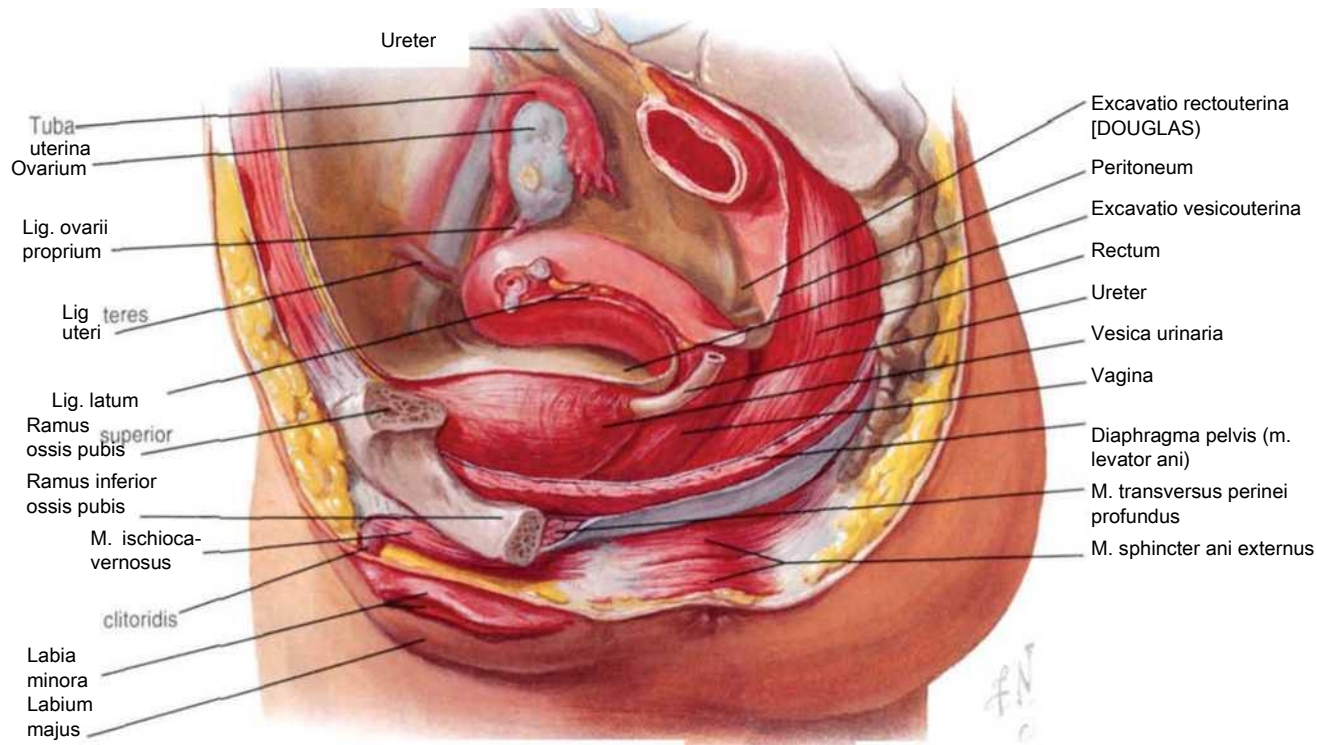


Ayollar tos va oraliq a'zolari

O'rta sagittal kesma

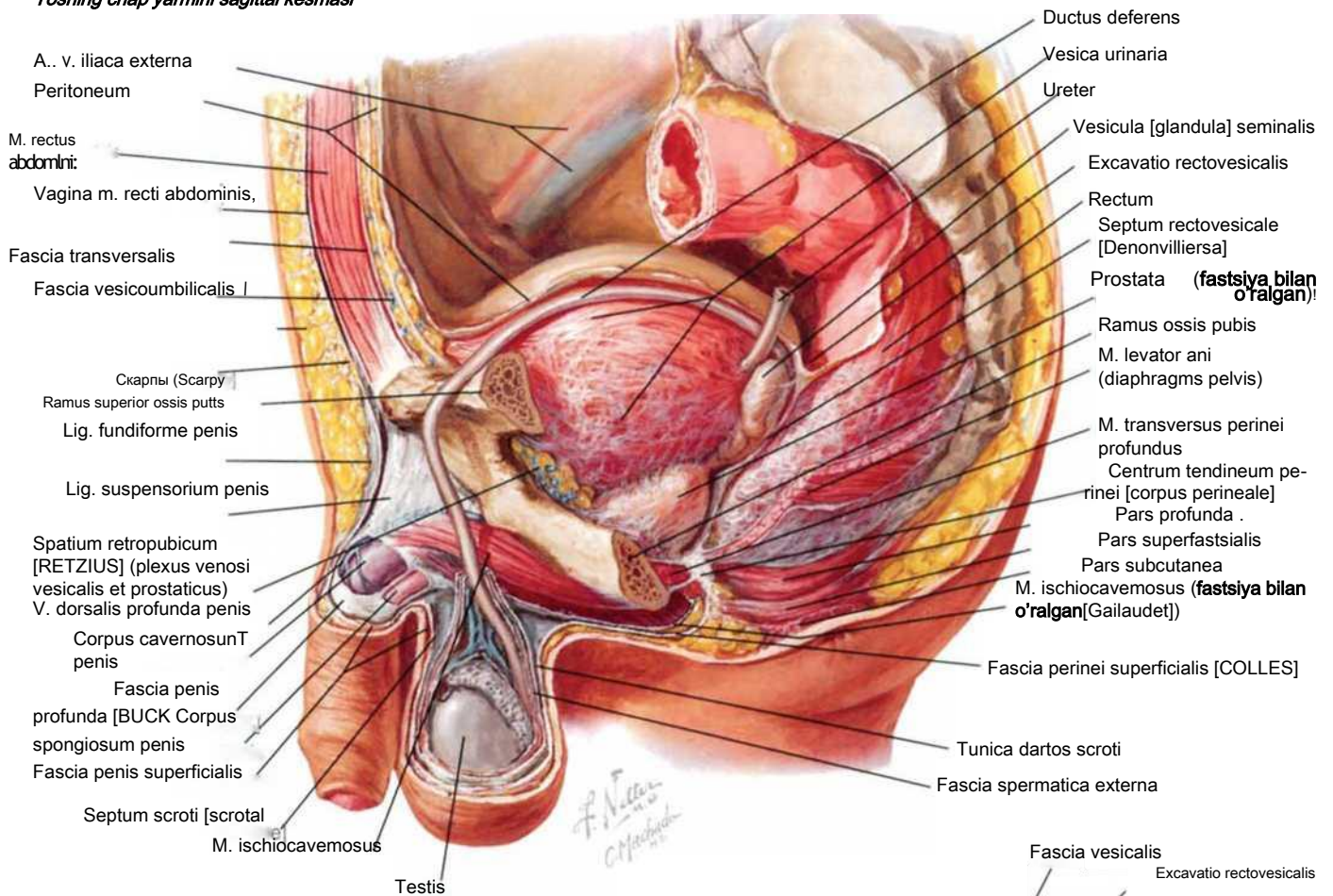


Tosning chap yarmini sagittal kesmasi

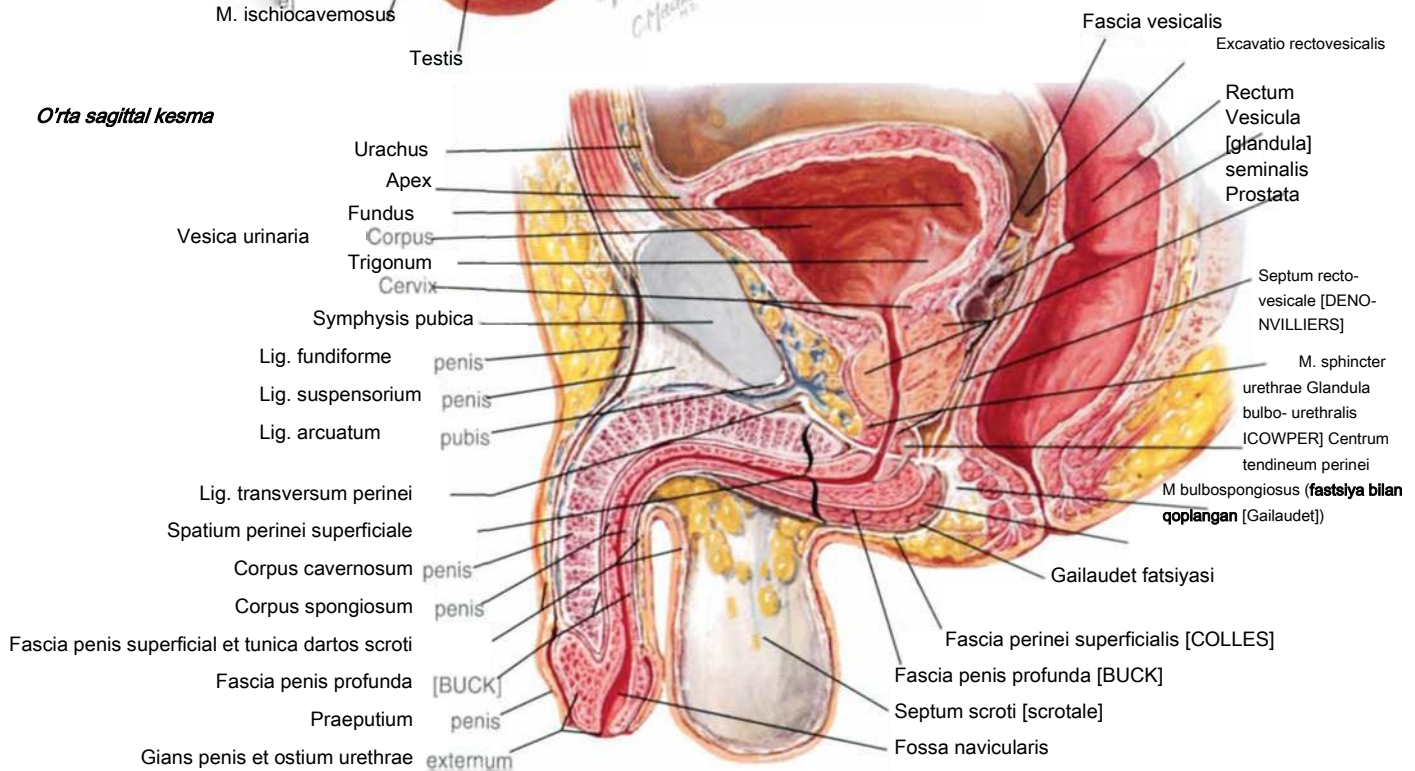


Erkaklar tos va oraliq soxa a'zolari

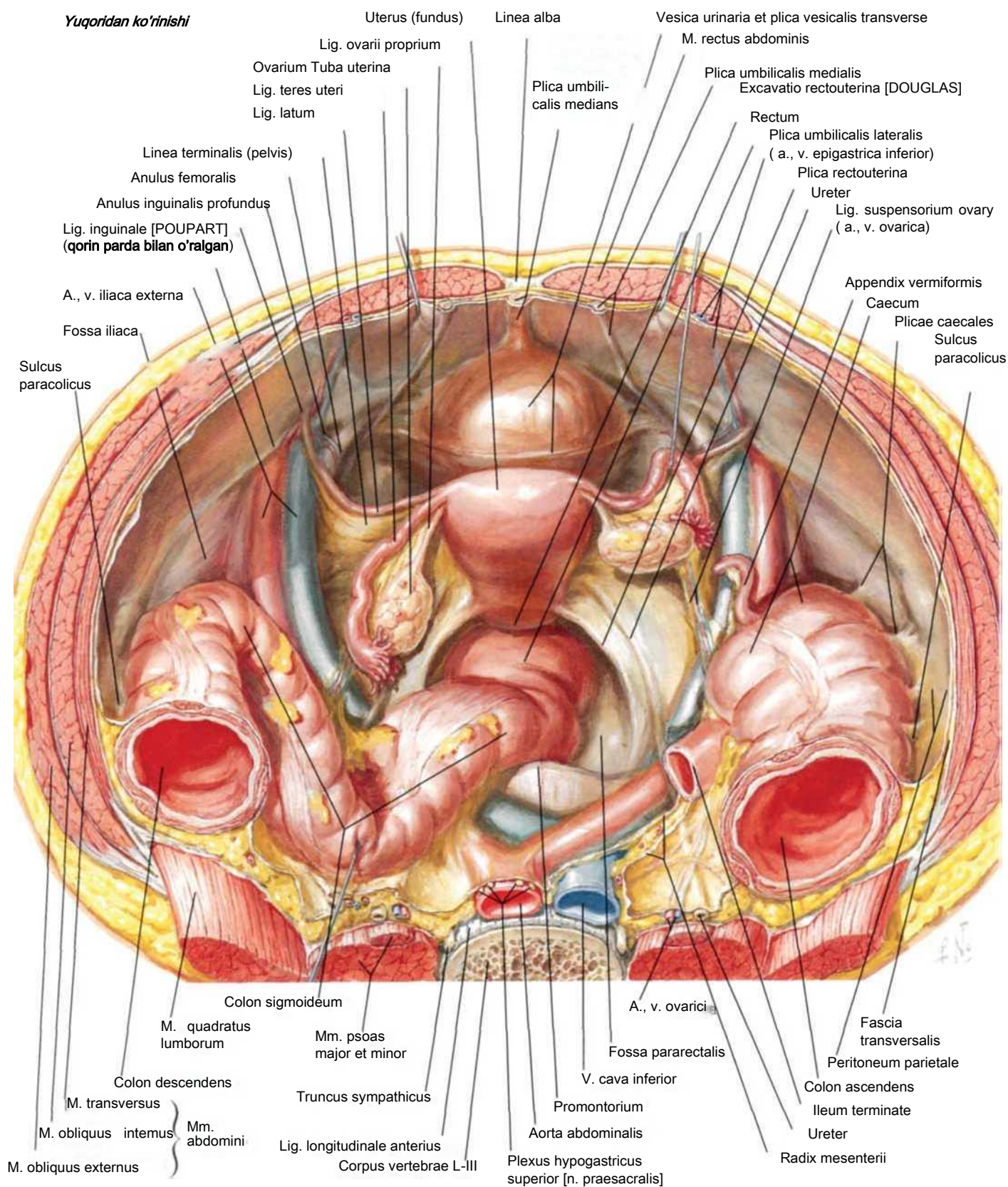
Tosning chap yarmini sagittal kesmasi



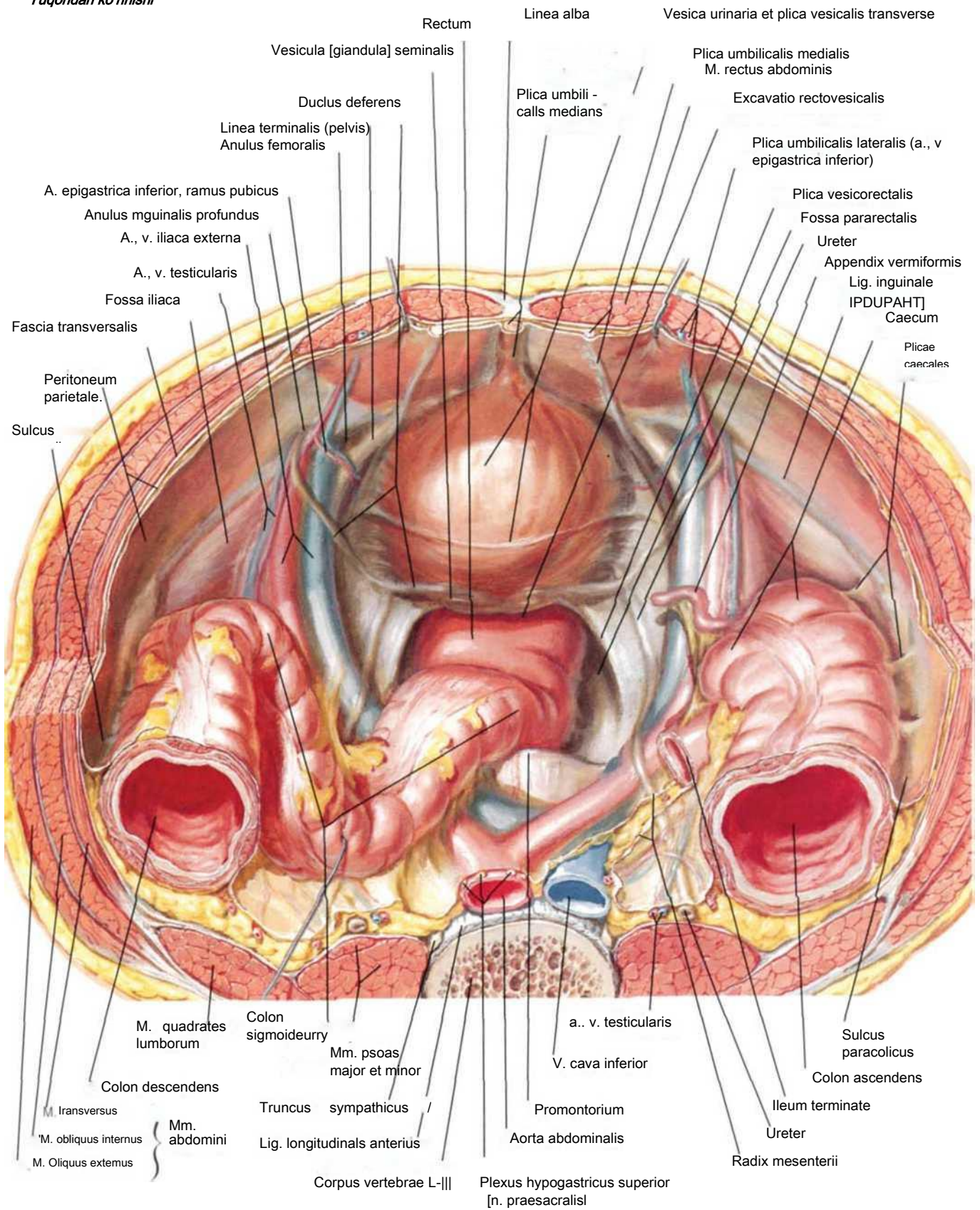
O'rtta sagittal kesma



Ayollar to's a'zolari

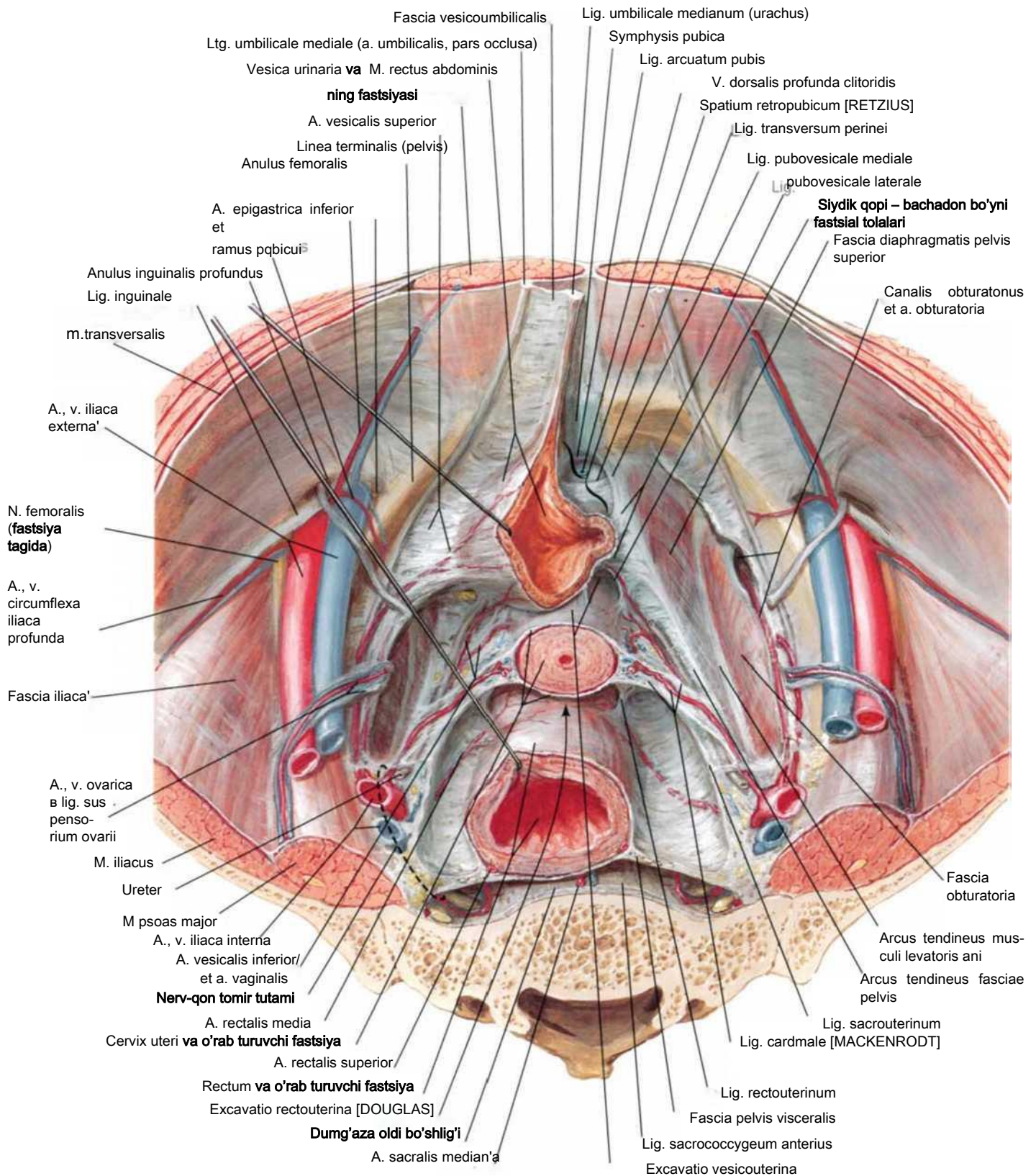


Yuqoridan ko'rinishi



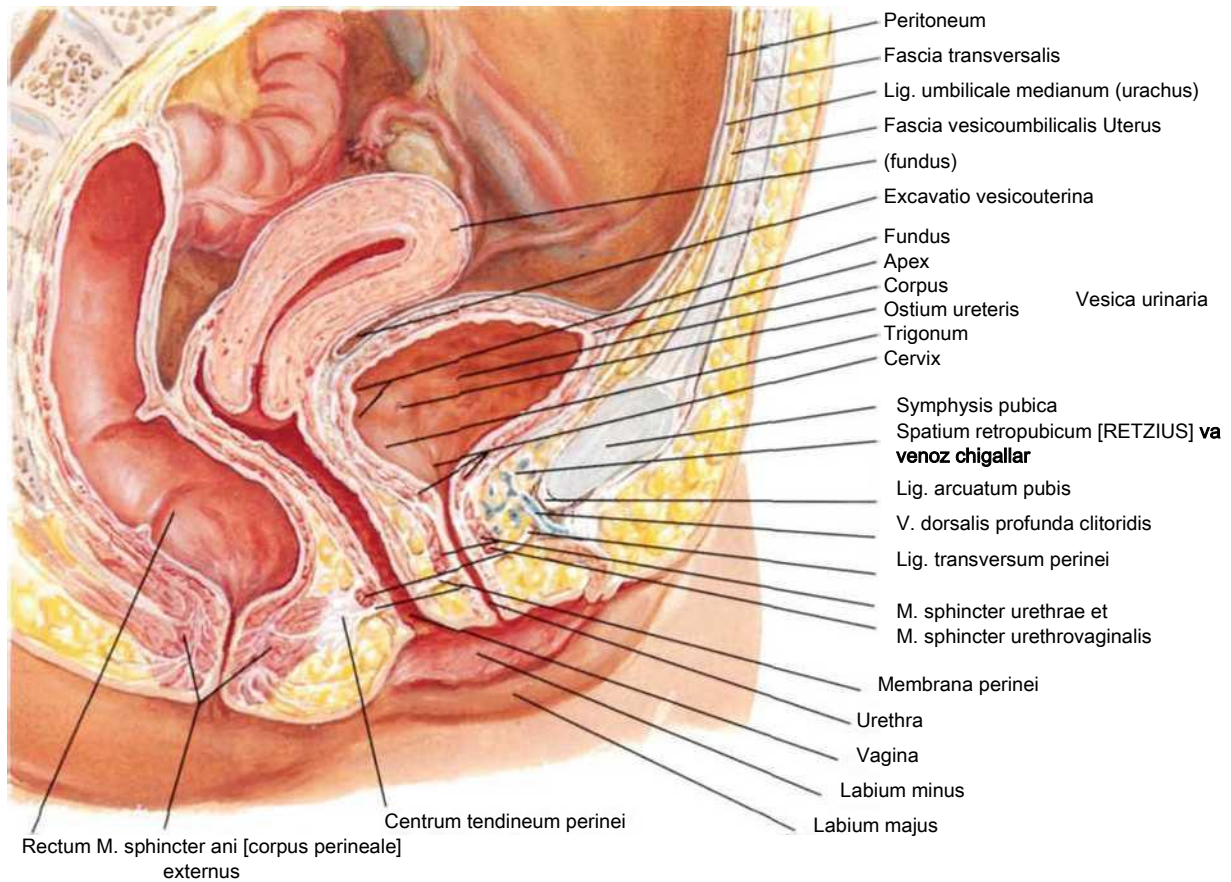
Tos fastsiyalari

Ayollar tosi; qorin parda va siyrak klechatka olib tashlangan

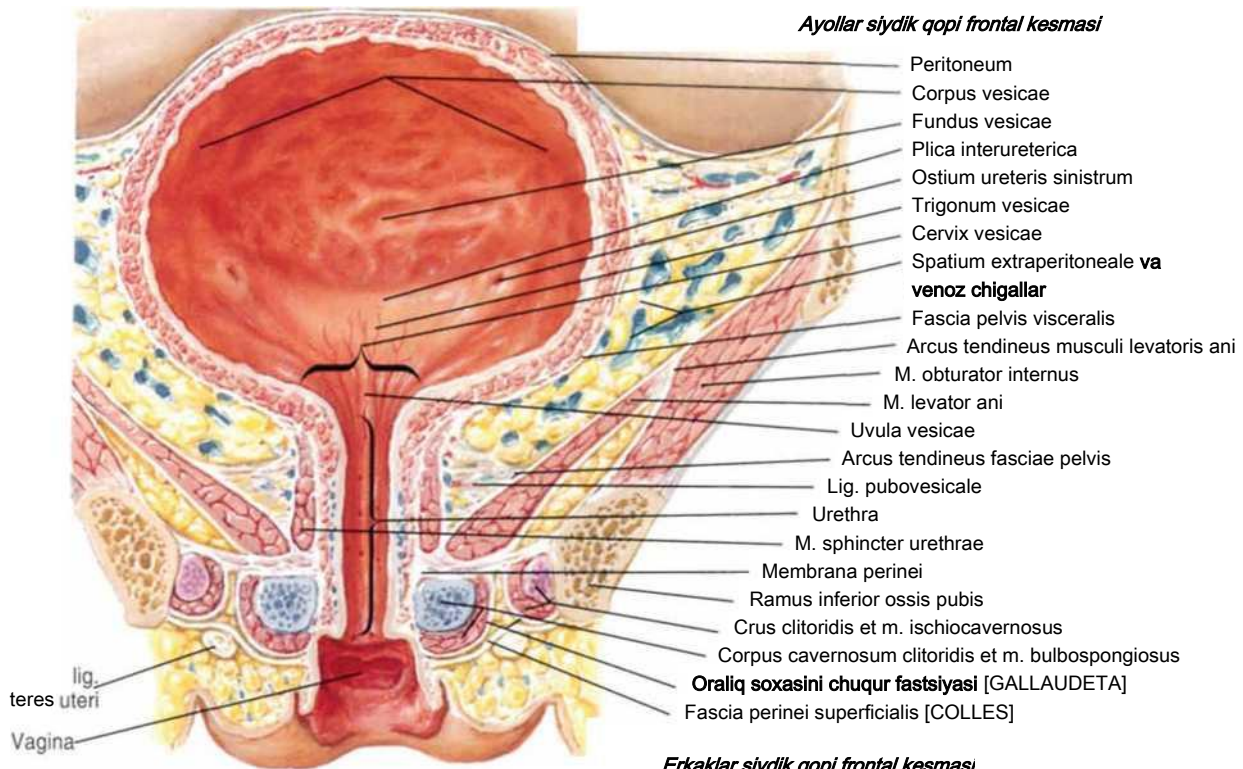


Siydik qopi (vesica urinaria): topografiyasi

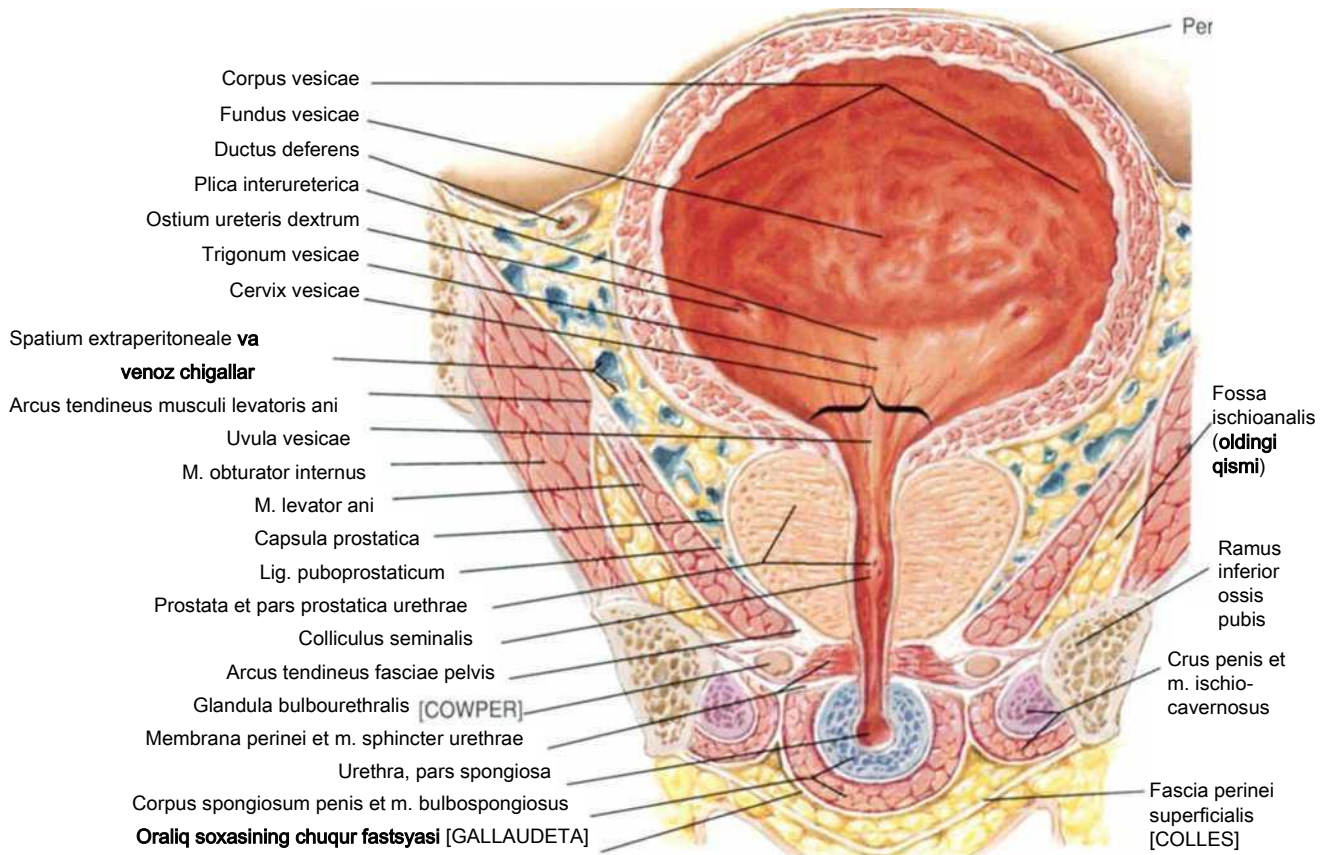
Ayollar tosining o'rtta sgittal kesmasi



Ayollar va erkaklar siydik qopi

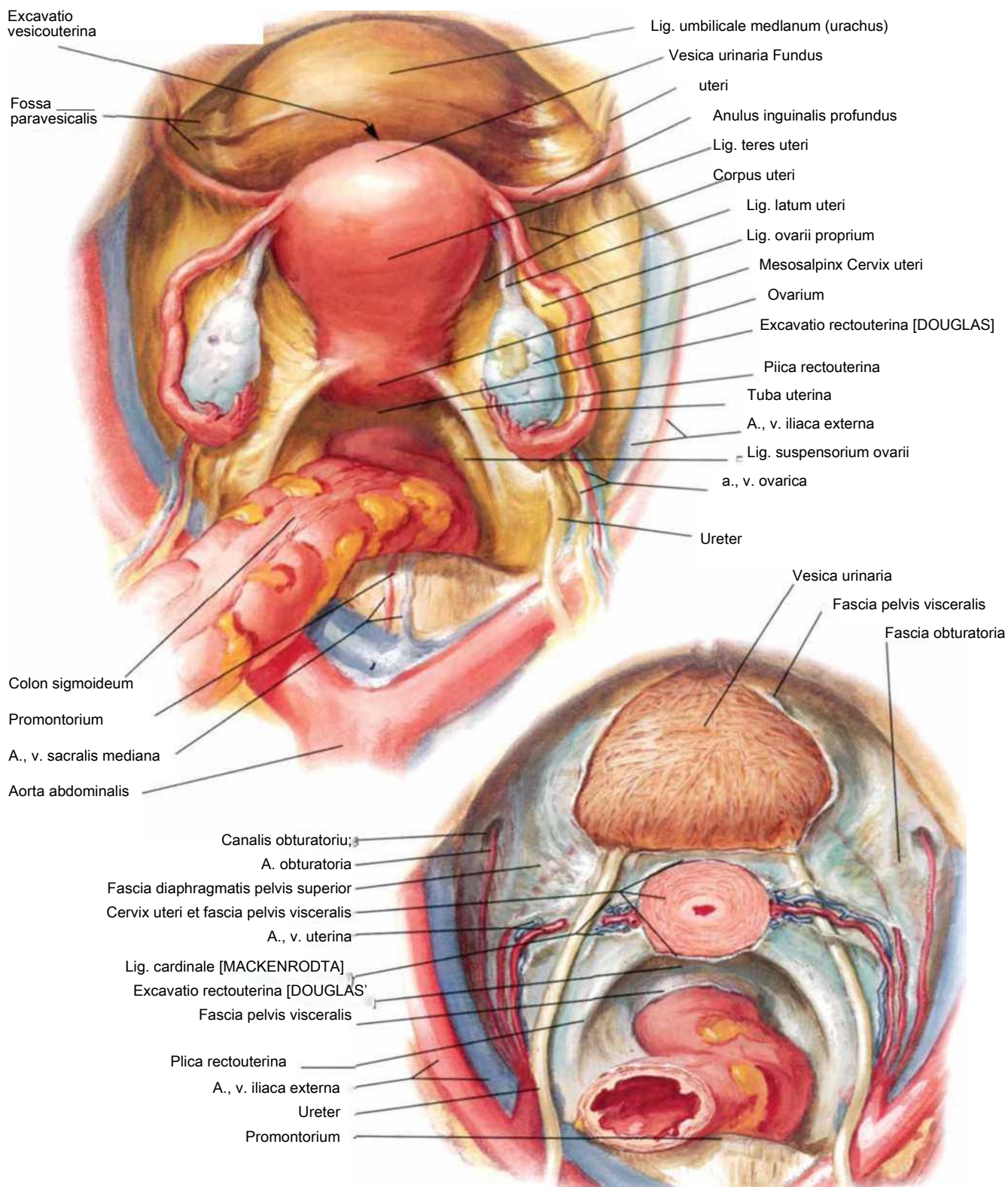


Erkaklar siydik qopi frontal kesmasi



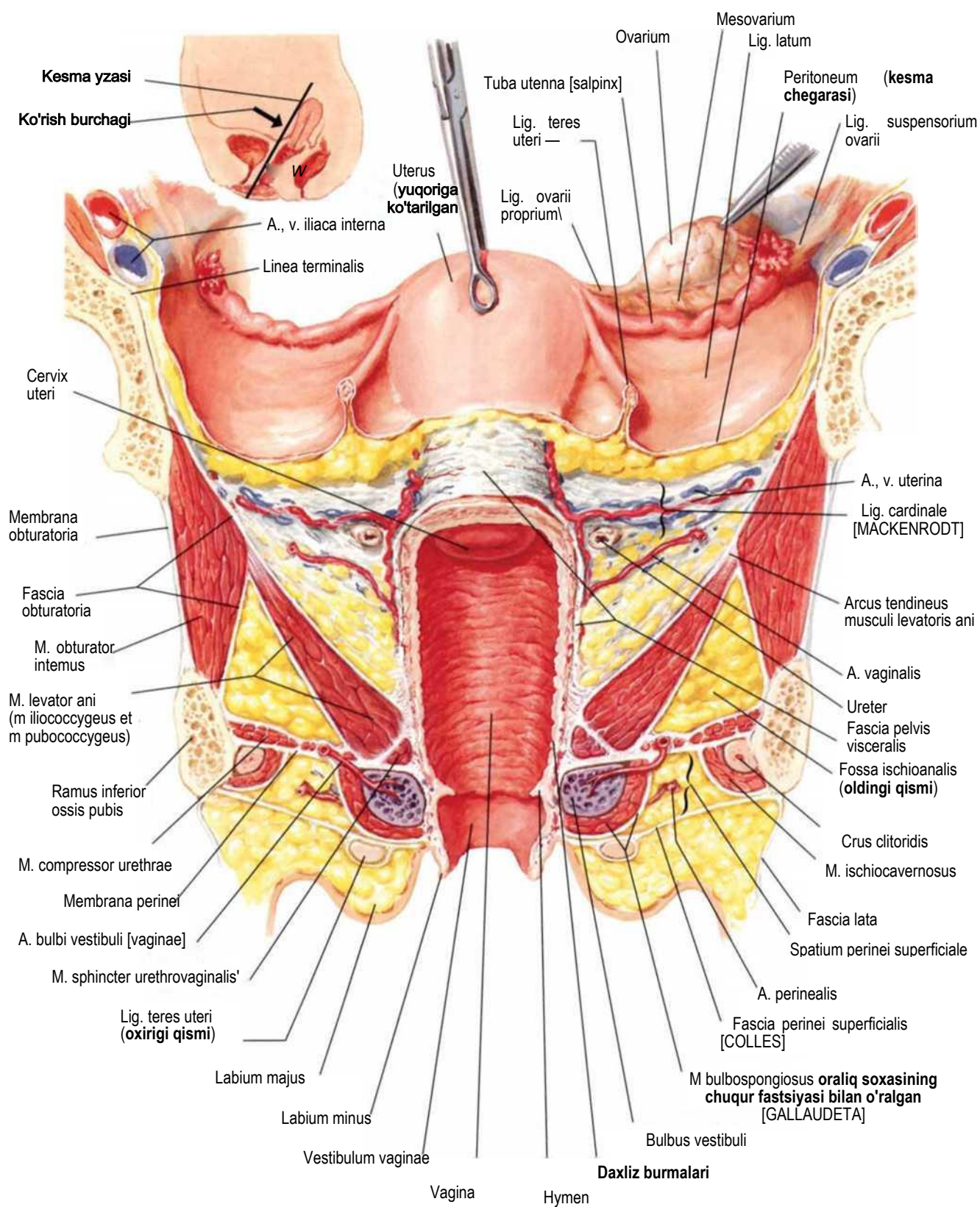
Ayollar to's soxasi a'zolari

Yuqoridan ko'rinishi

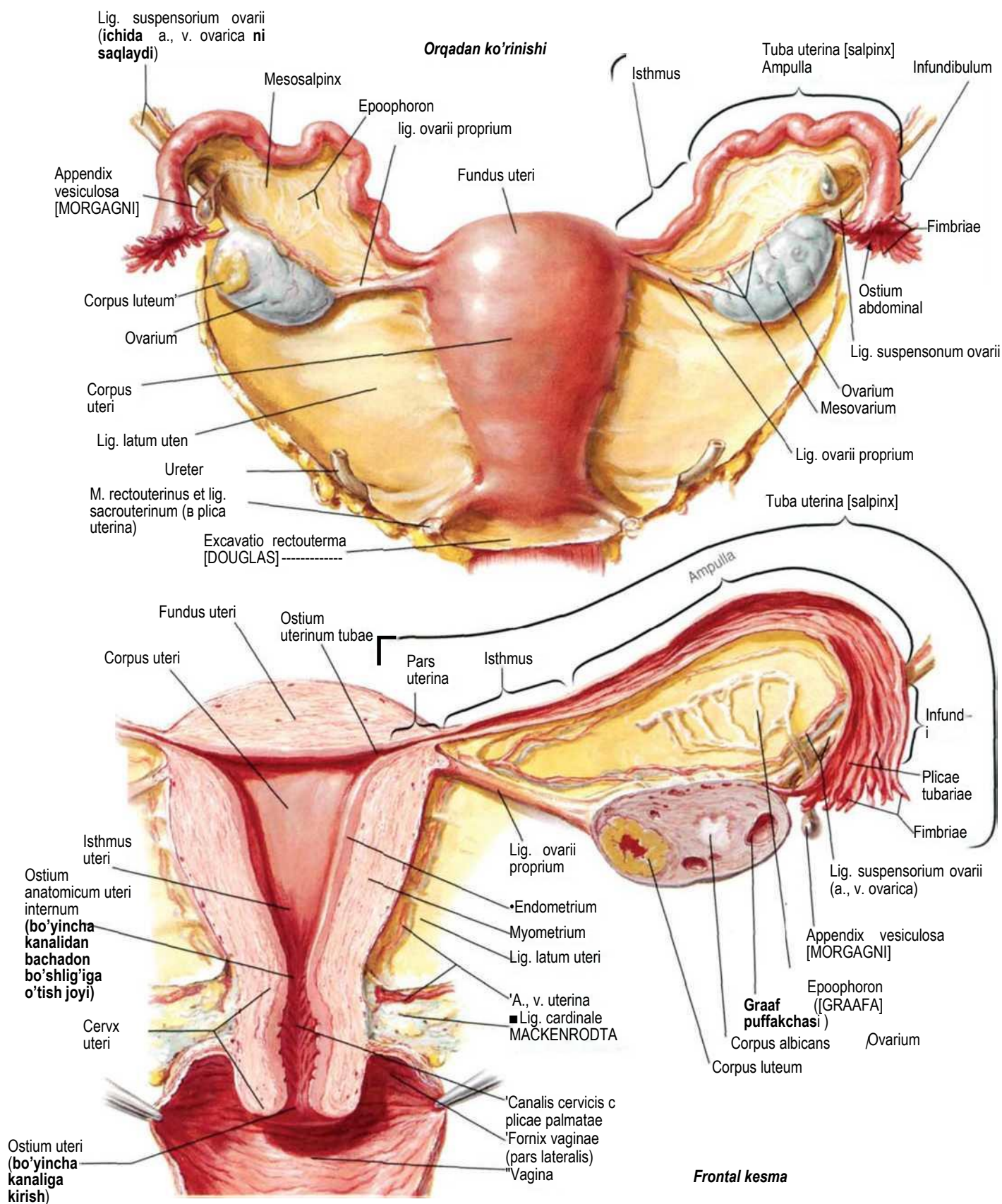


Yuqoridan ko'rinishi: qorin parda va bachadon olib tashlangan

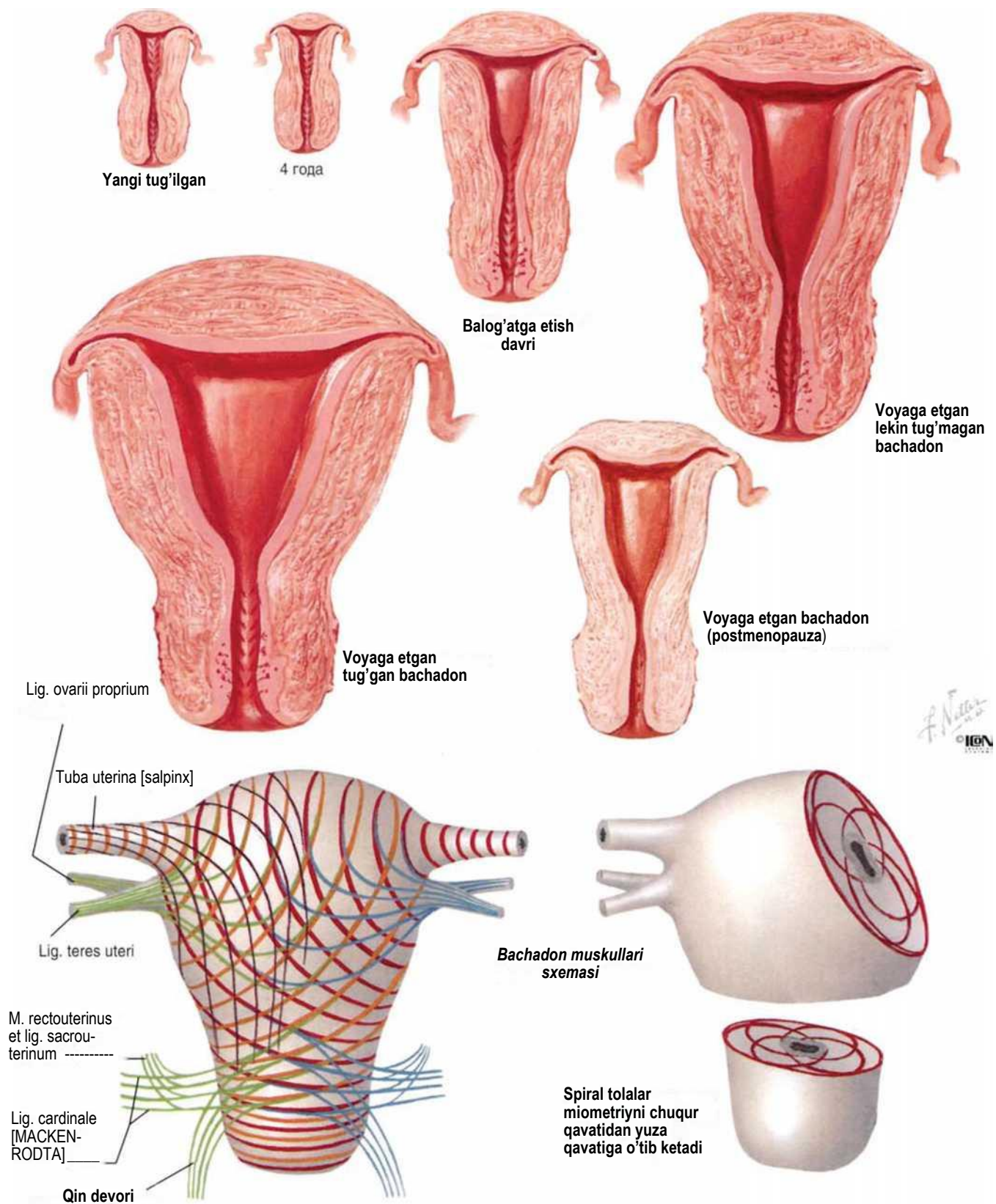
Bachadon (uterus), qin (vagina) va ularni atrofidagi a'zolar



Tuxumdon (ovarium) va bachadon naylari (tuba uterina [salpinx])

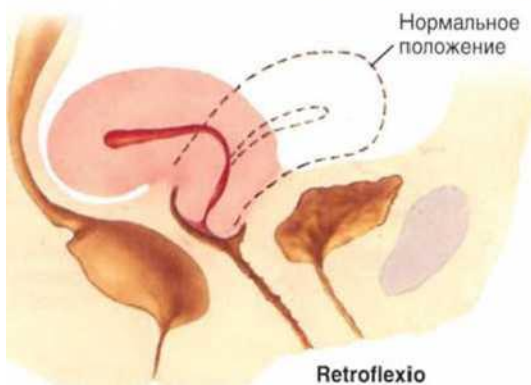
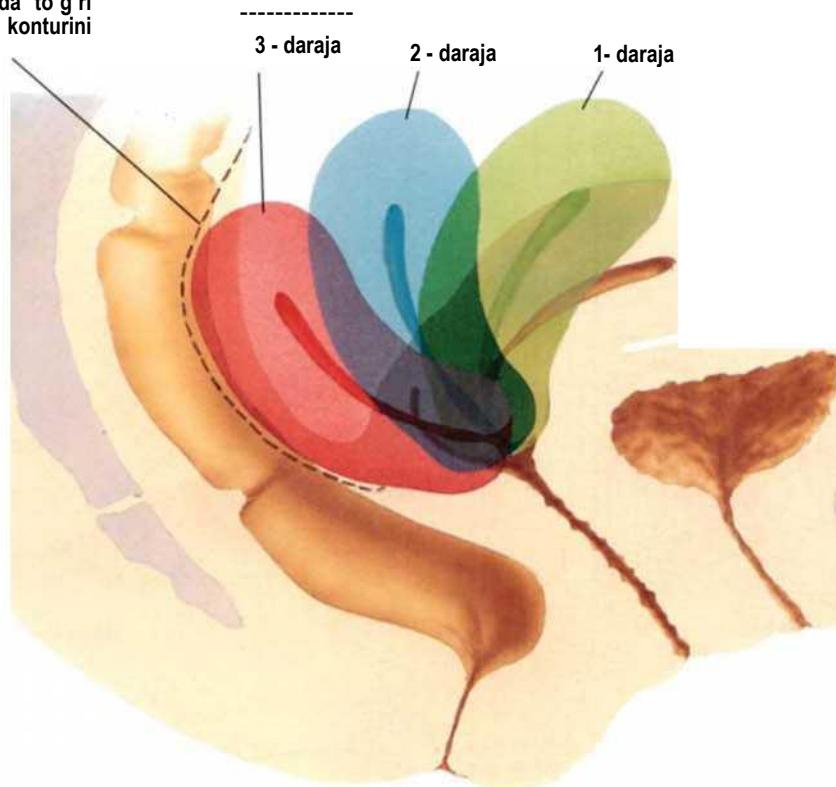


Bachadon: yoshga xos o'zgarishlar va tuzulishi

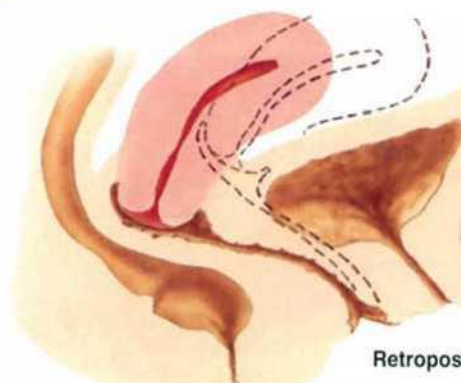


Retroversiya darajasi (retroversio)

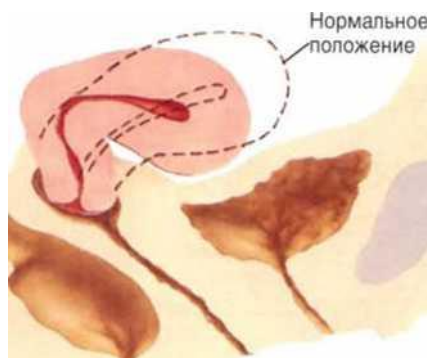
3 - darajasida to'g'ri
ichakning
o'zgarishi konturini



Retroflexio

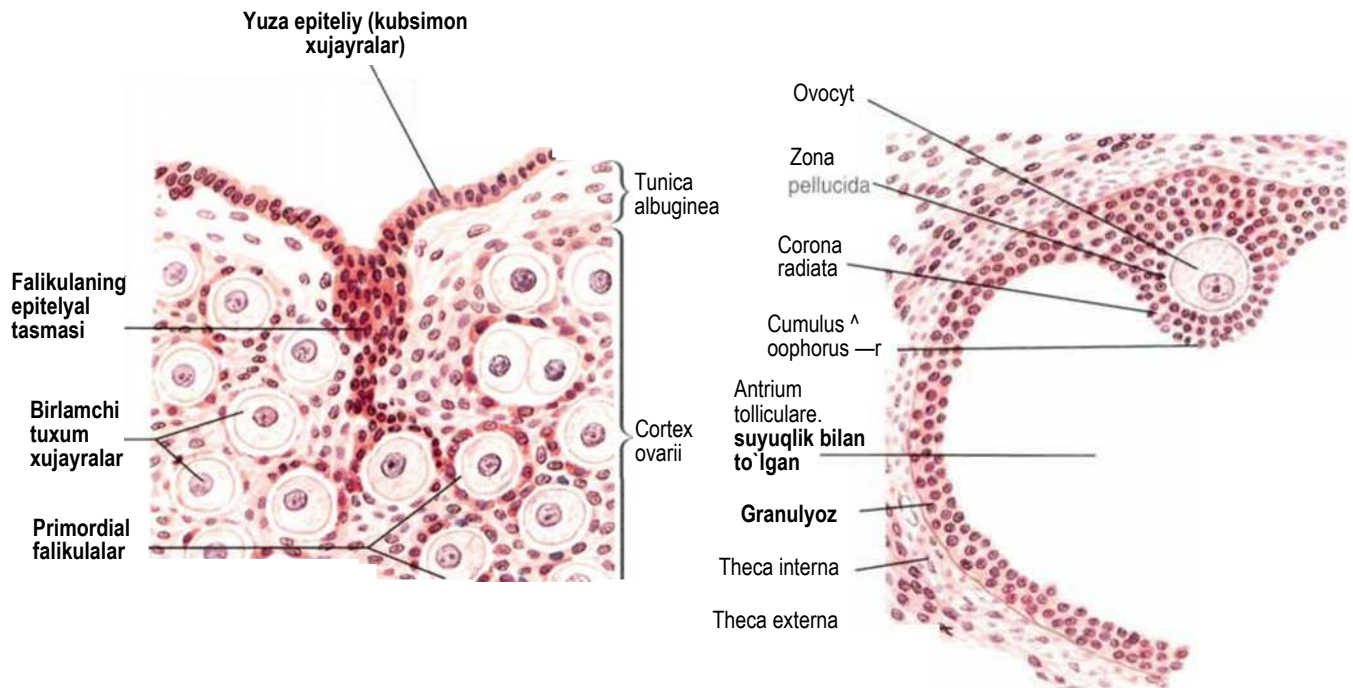


Retroposi



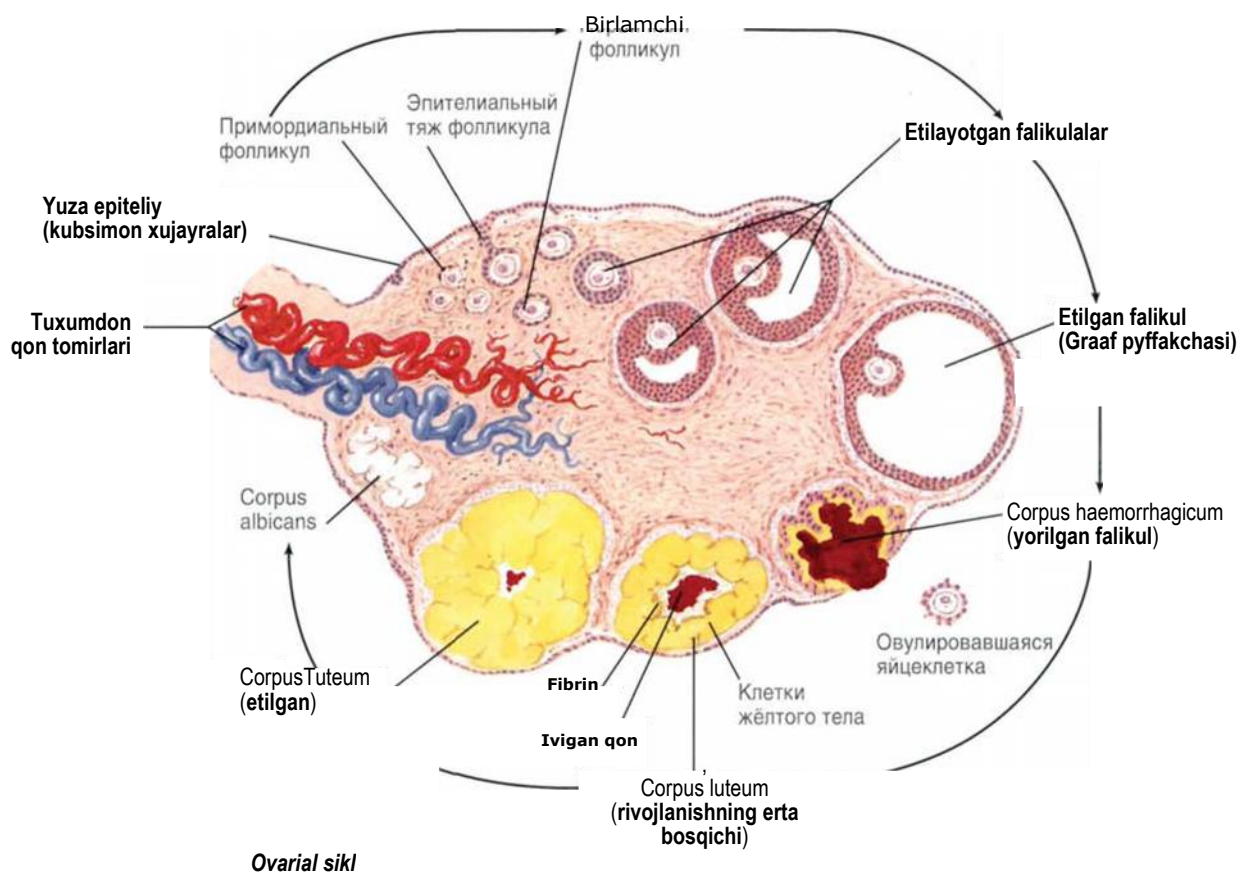
Antelexio (normal va og'ir darajasi)

Tuxumdon, tuxum xujayralari va falikulalar

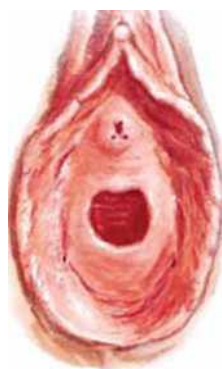
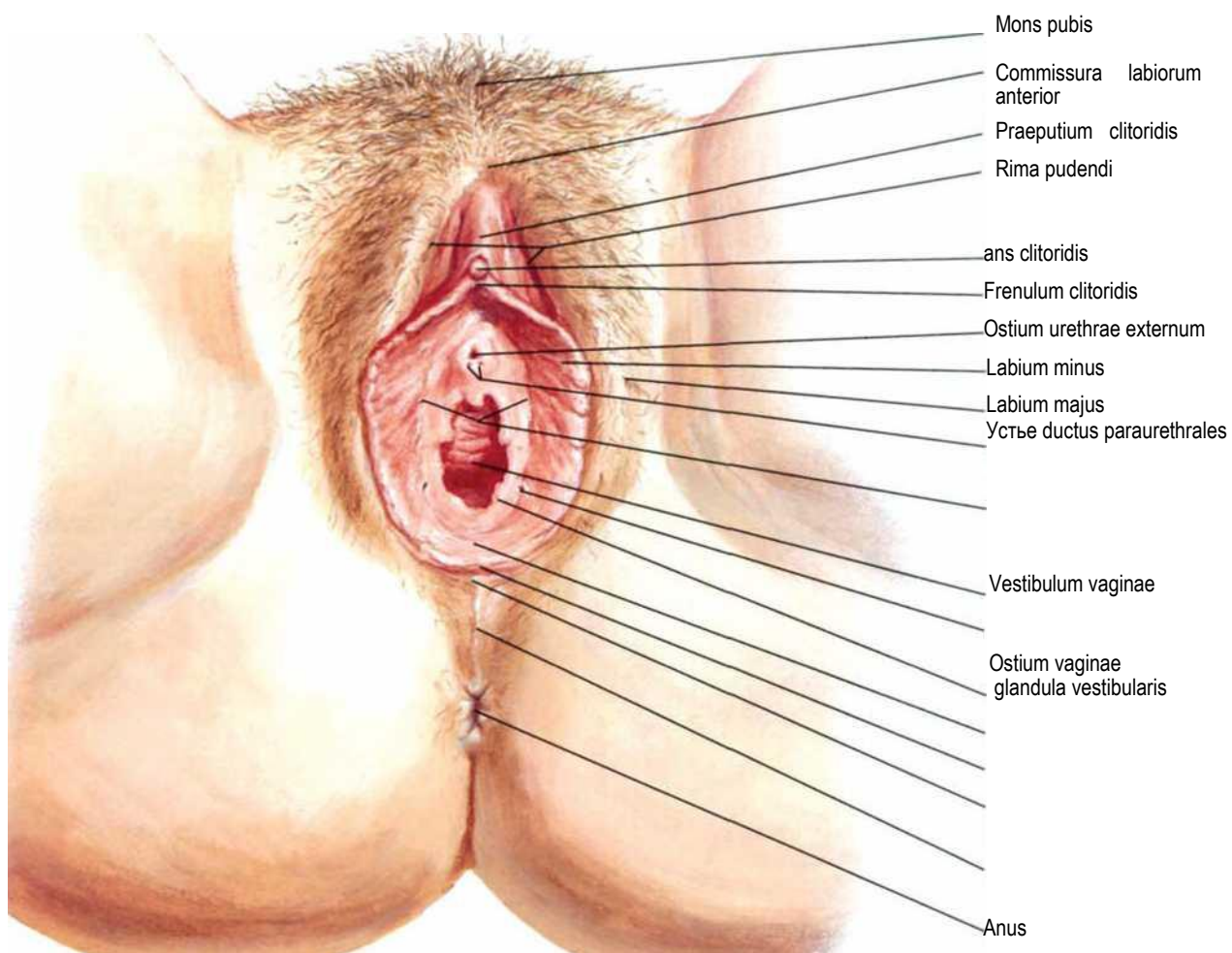


Yangi tug'ilgan chaqaloq tuxumdoni

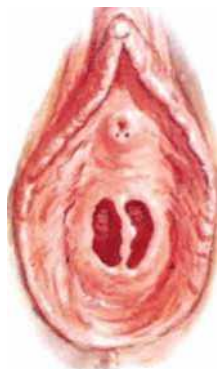Etilgan falikula



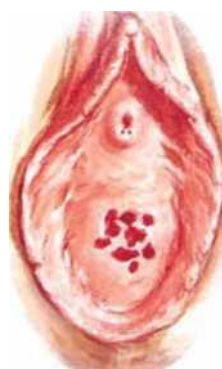Oraliq soxasi (perineum) va ayollar tashqi jinsiy a'zolari



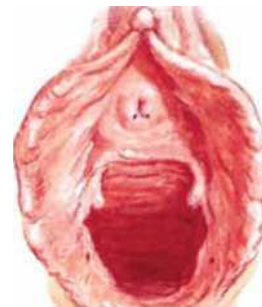
Hymen anularis



Hymen septus

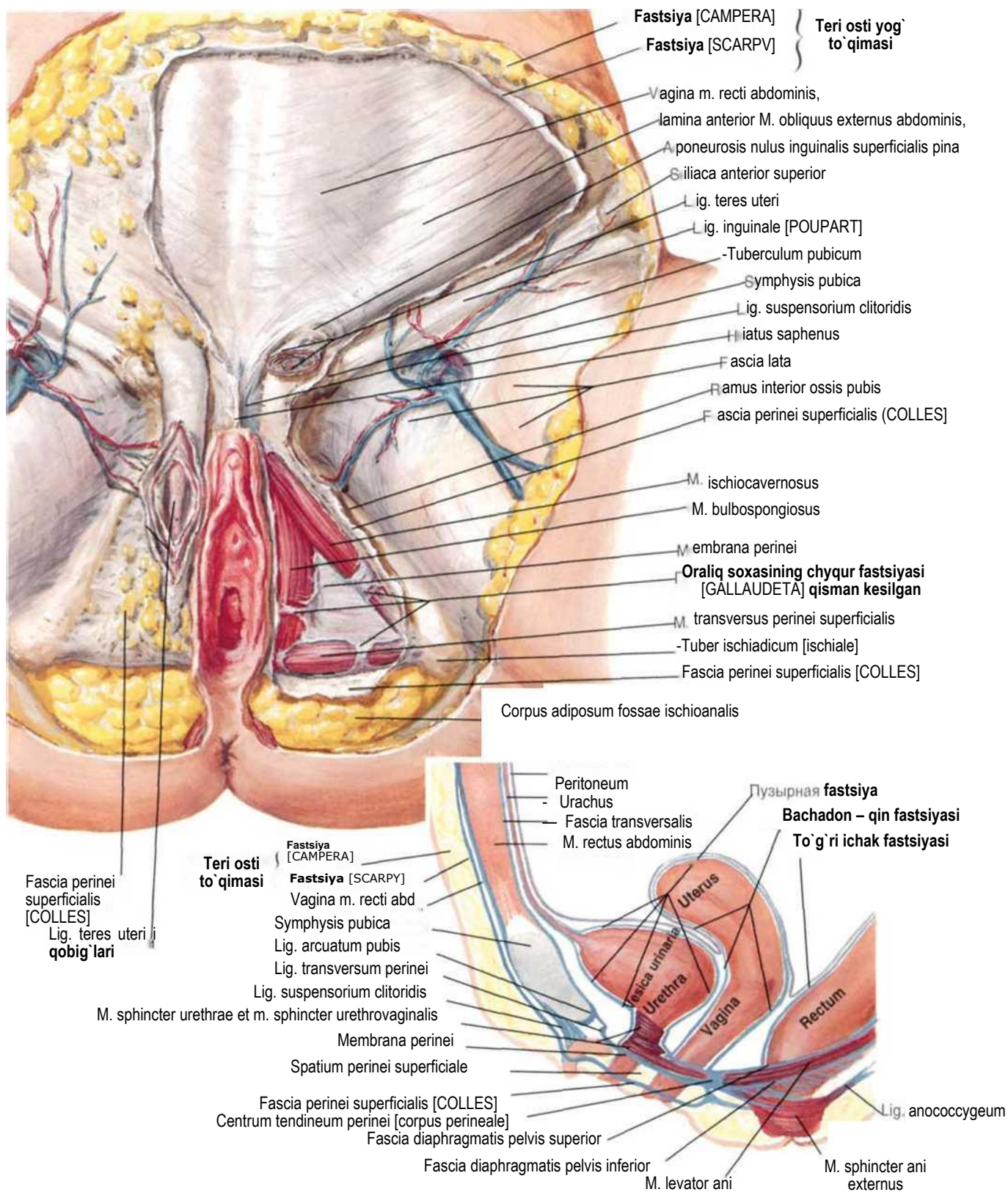


Hymen cribriformis

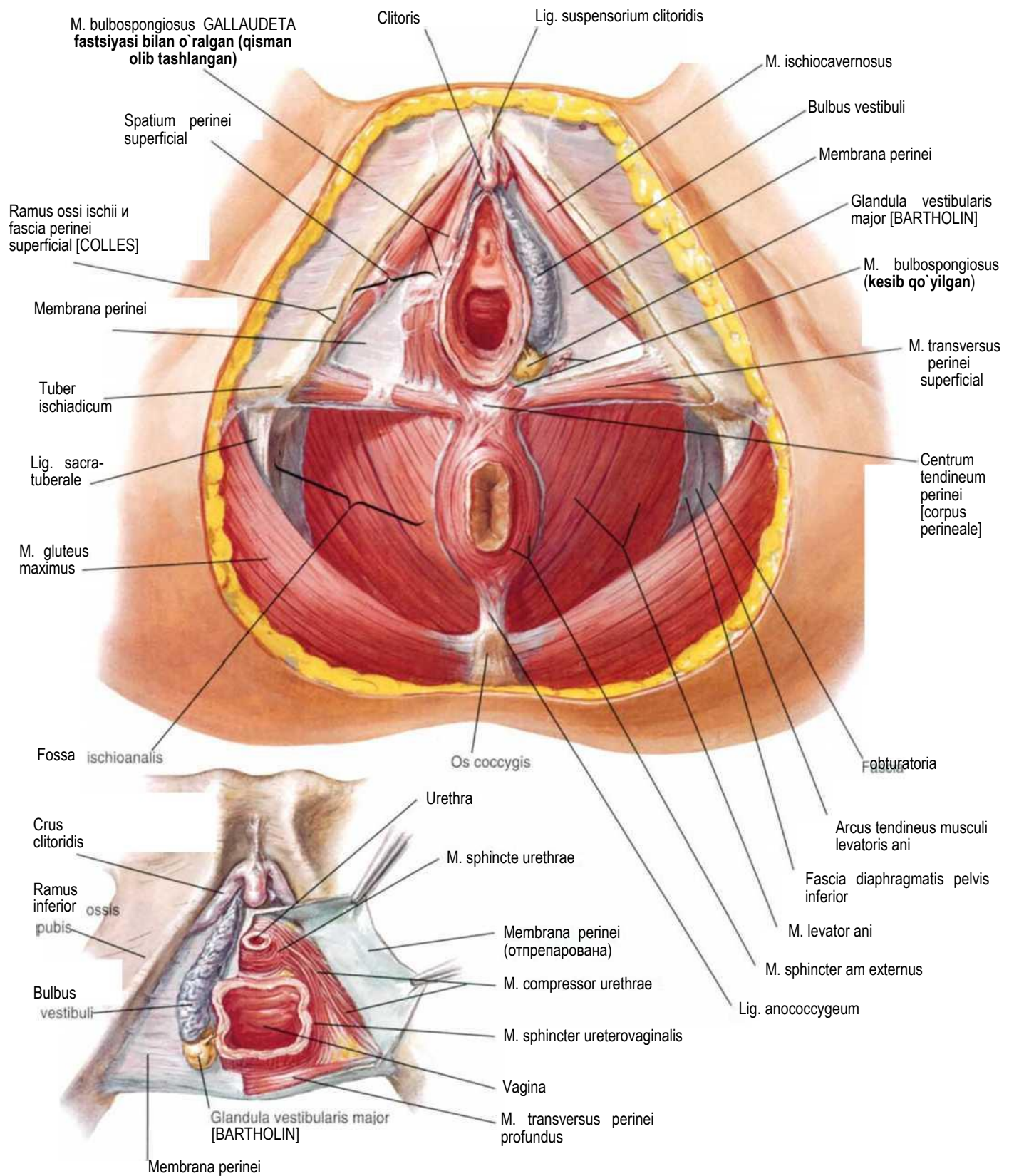


Ostium vaginae (porus introitus)

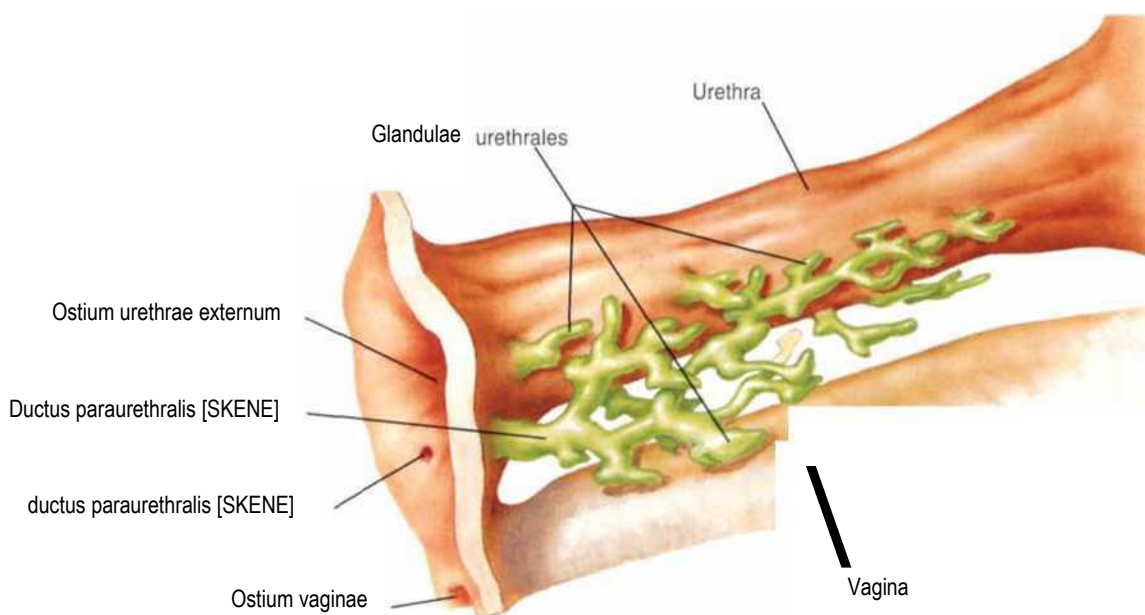
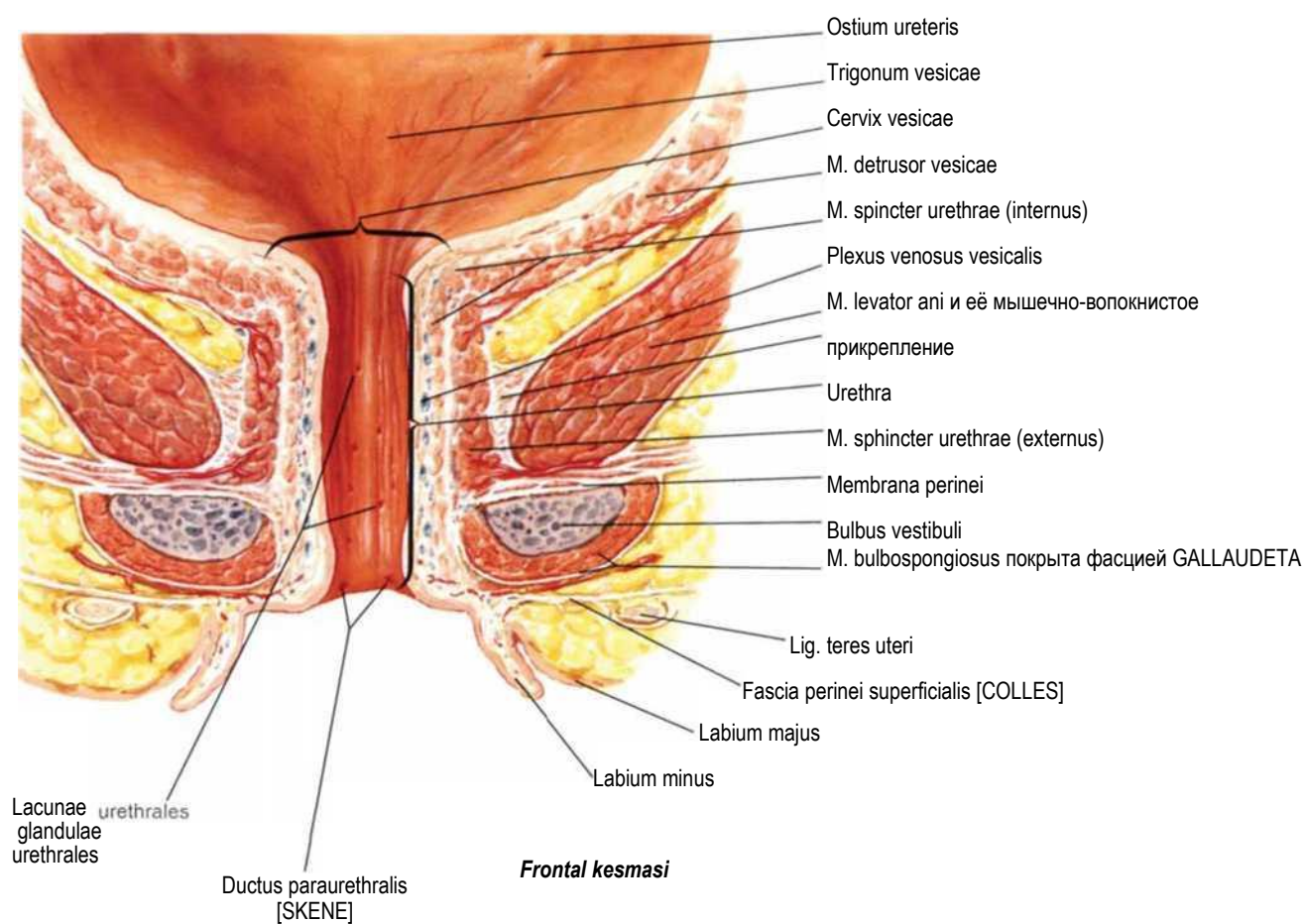
Oraliq soxasi: yuzaki tuzilmalari



Oraliq soxasi: chuqur tuzulmalari

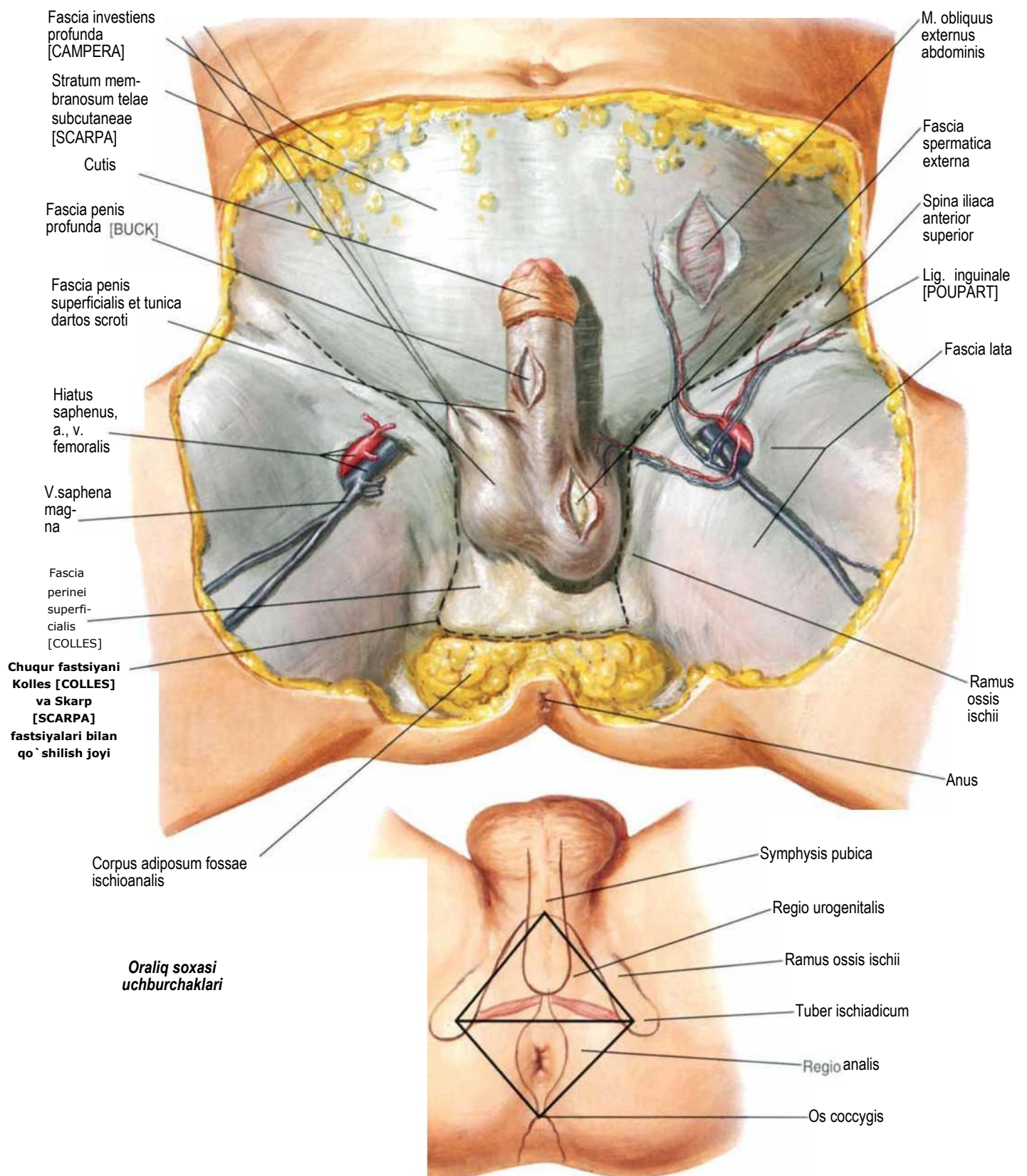


Ayollar uretrasi (urethra feminina)

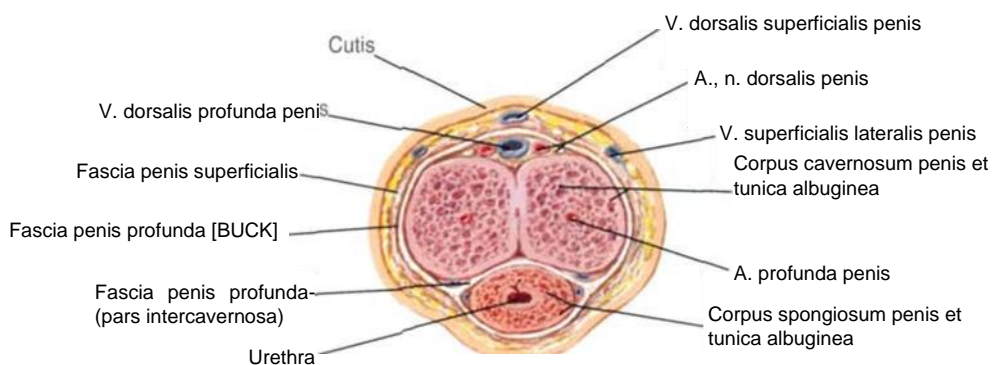
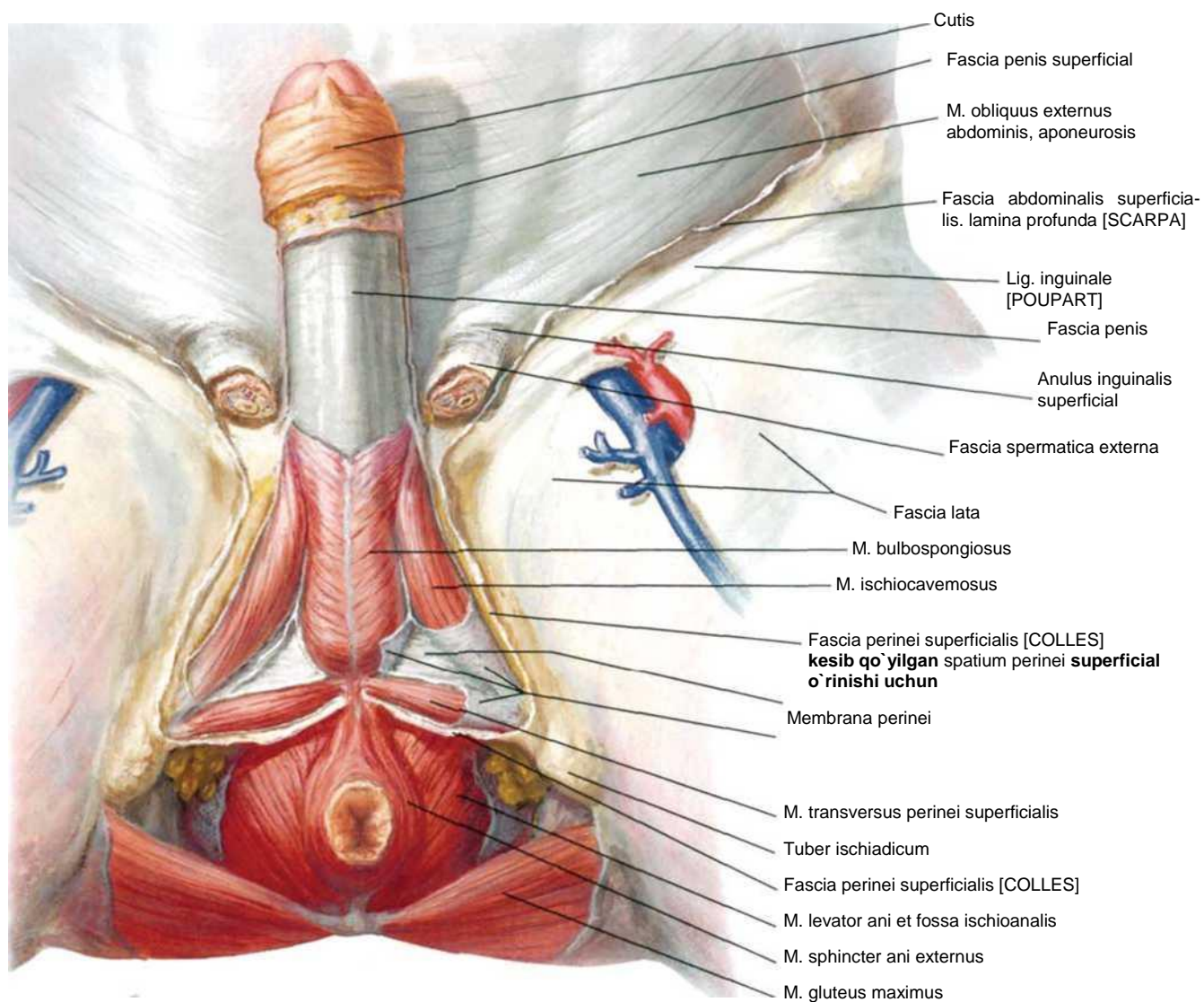


Sxematik tuzulishi

Erkaklar tashqi jinsiy a'zolari: yuzaki tuzilmalari

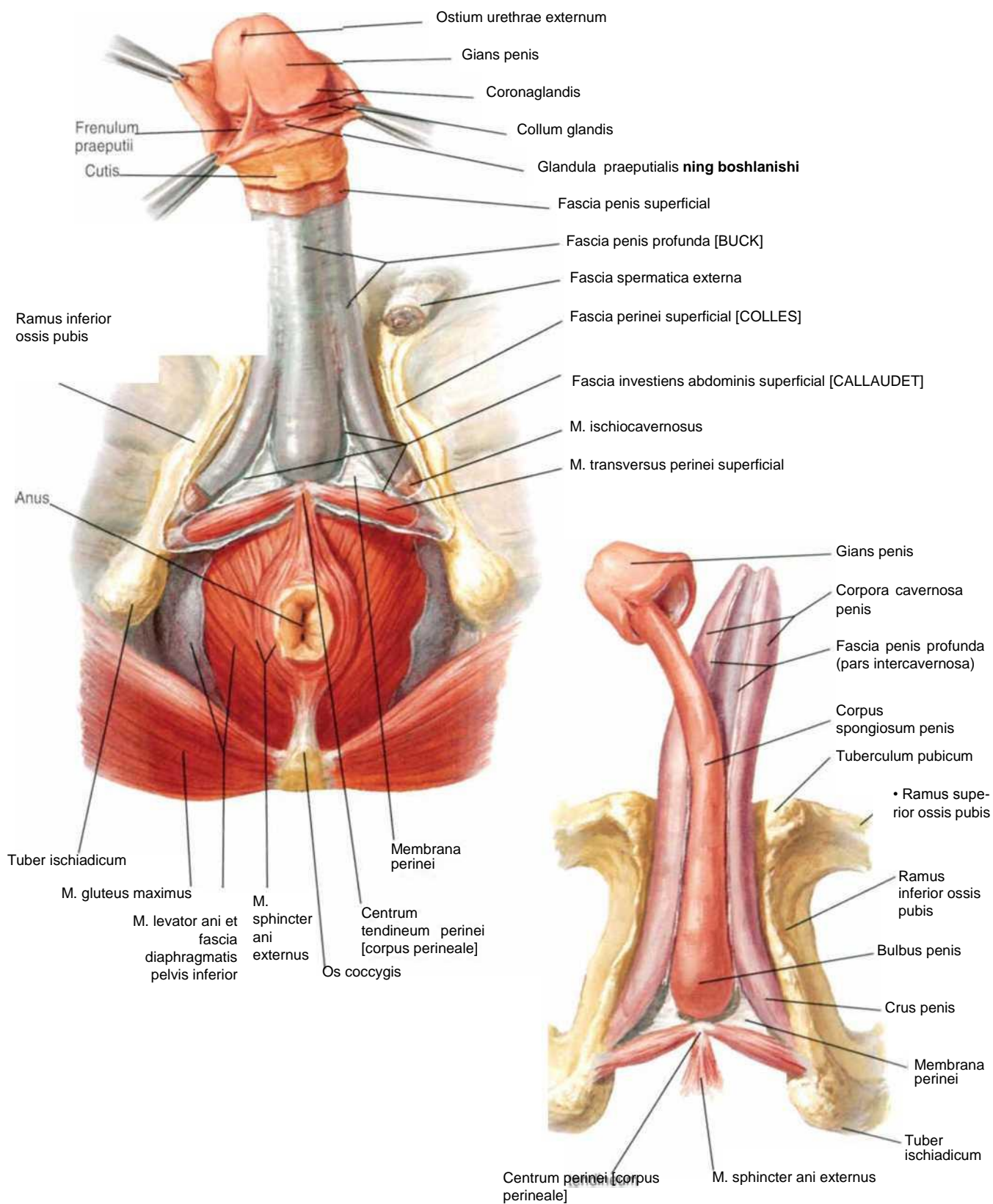


Erkaklar tashqi jinsiy a'zolari: chuqur joylashgan tuzulmalar

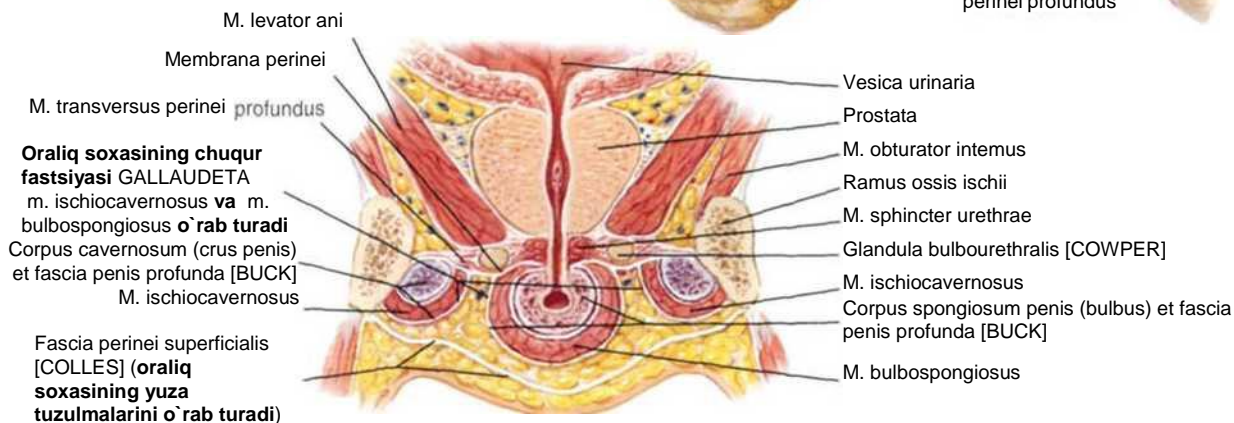
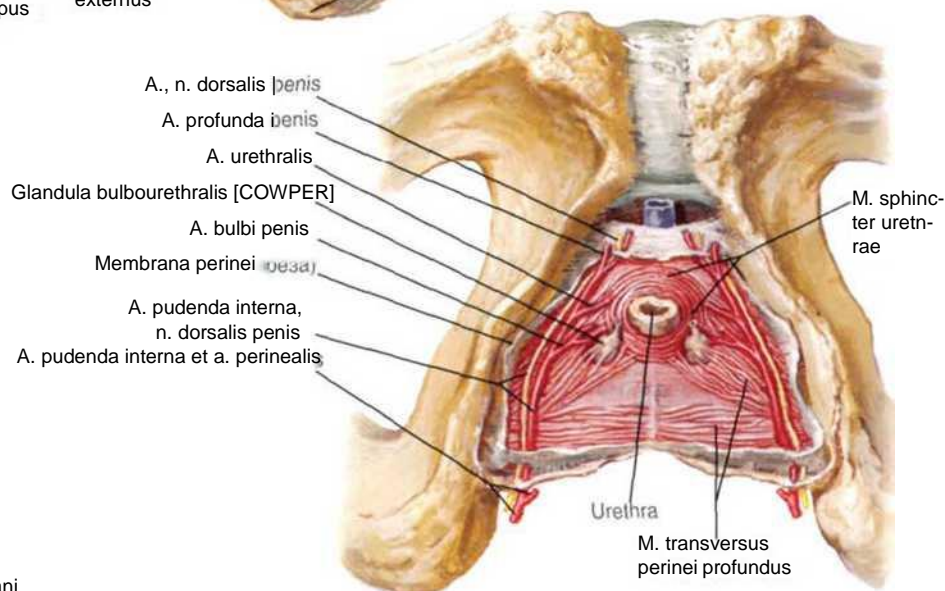
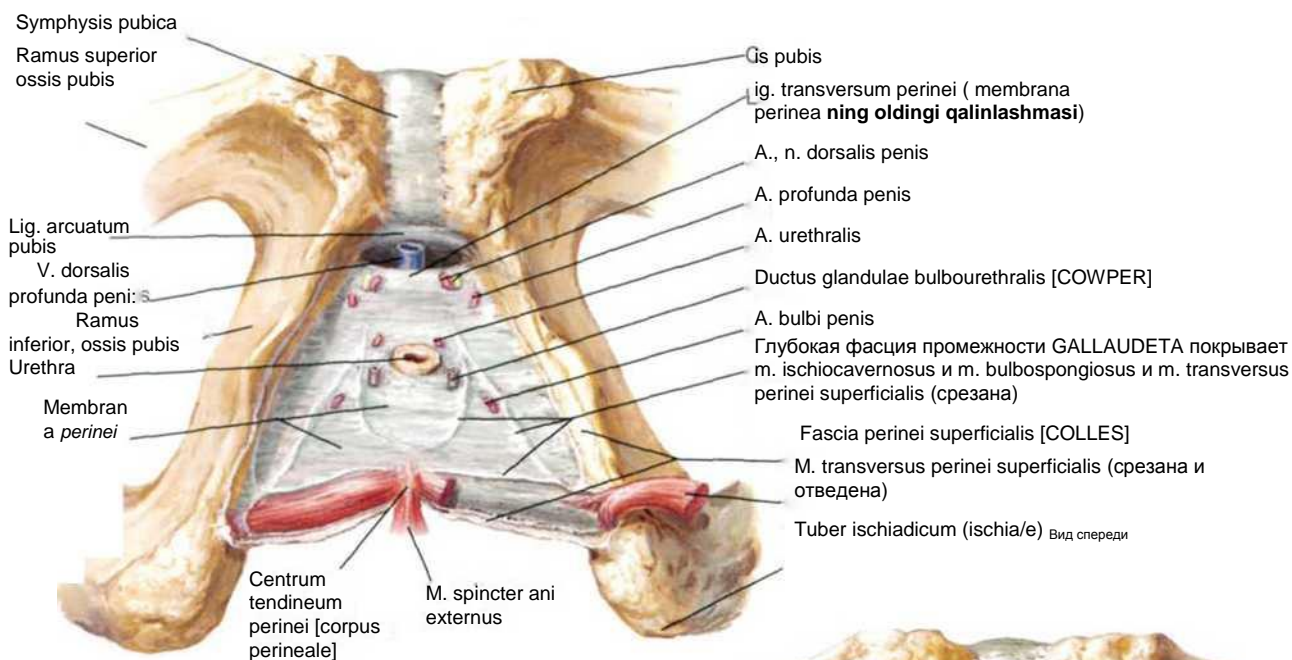


Jinsiy olat tanasining ko'ndalang kesmasi

Jinsiy olat (penis)

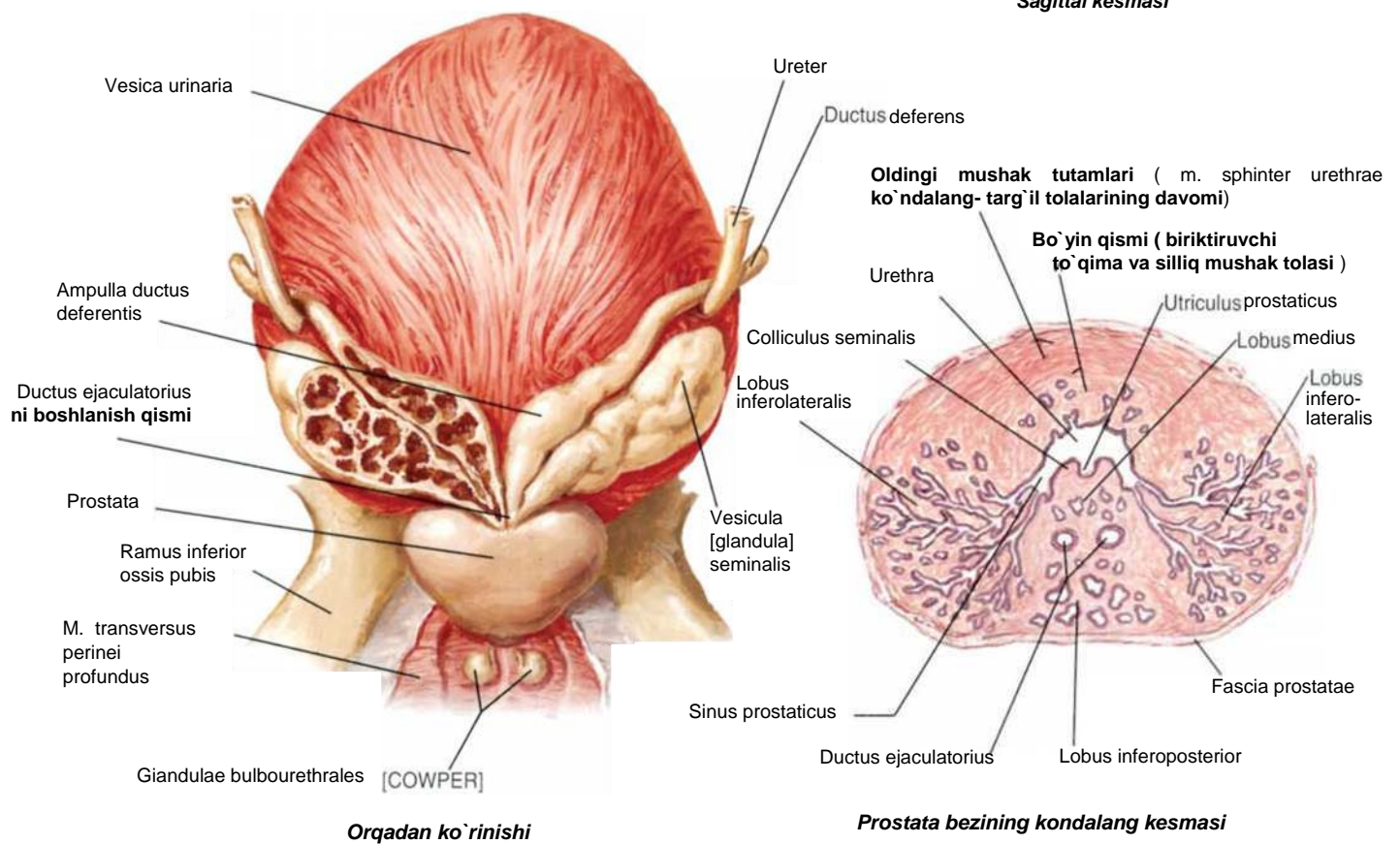
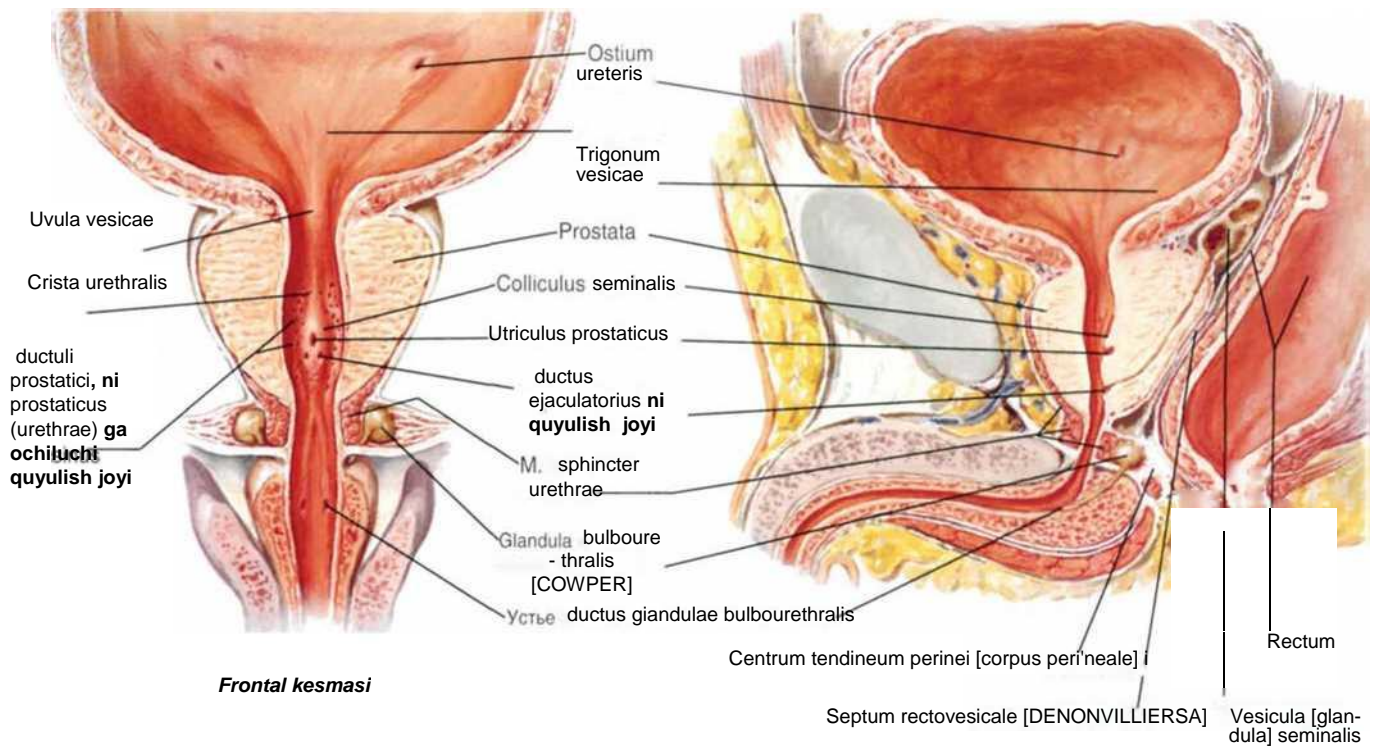


Oraliq soxasi: chuqur tuzulmalar

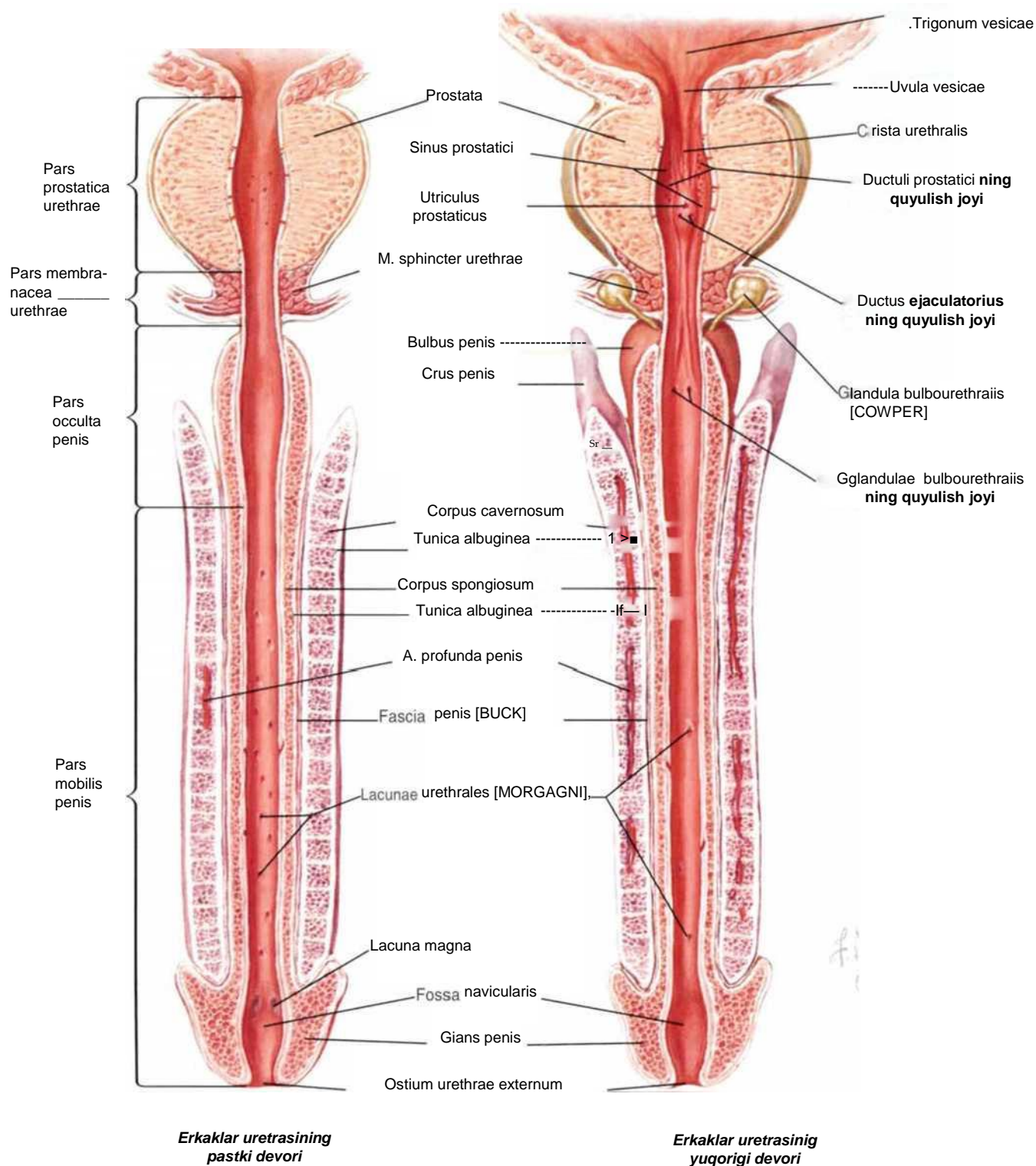


Erkaklar oraliq soxasini uretra orqali frontal kesmasi

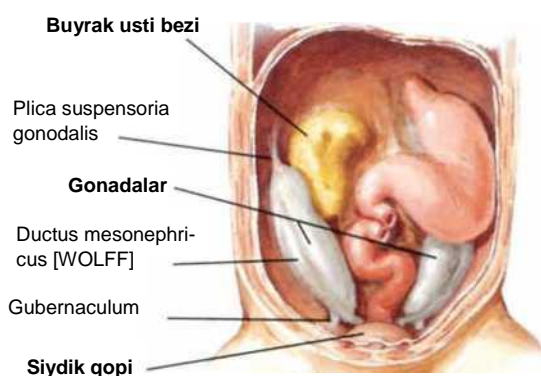
Prostata bezi va urug` puffakchalari



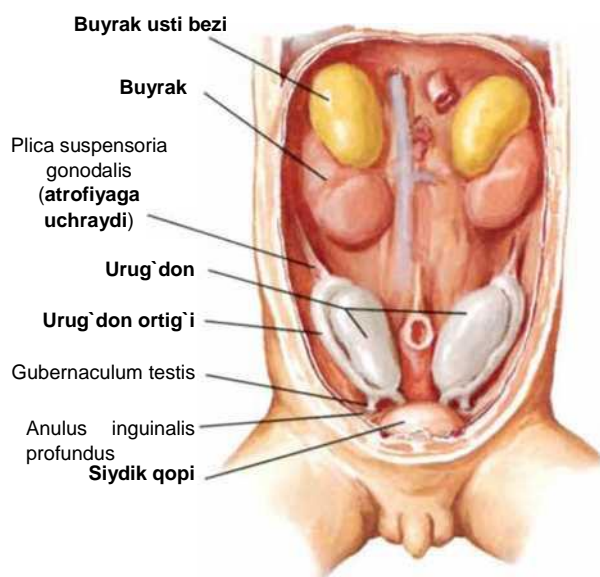
Erkaklar siydik chiqaruv kanali (urethra masculina)



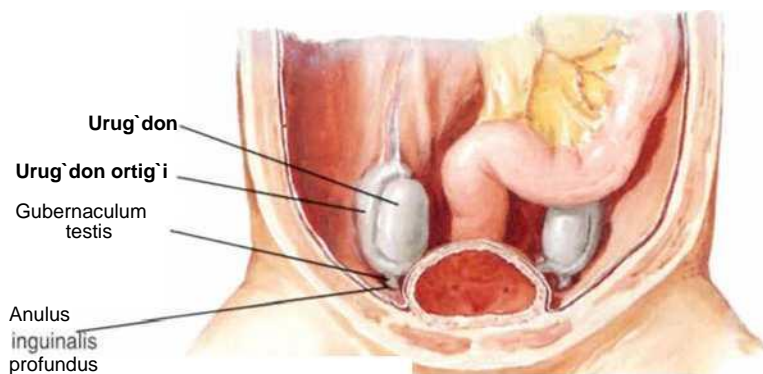
Urug'donlarni pastga tushishi



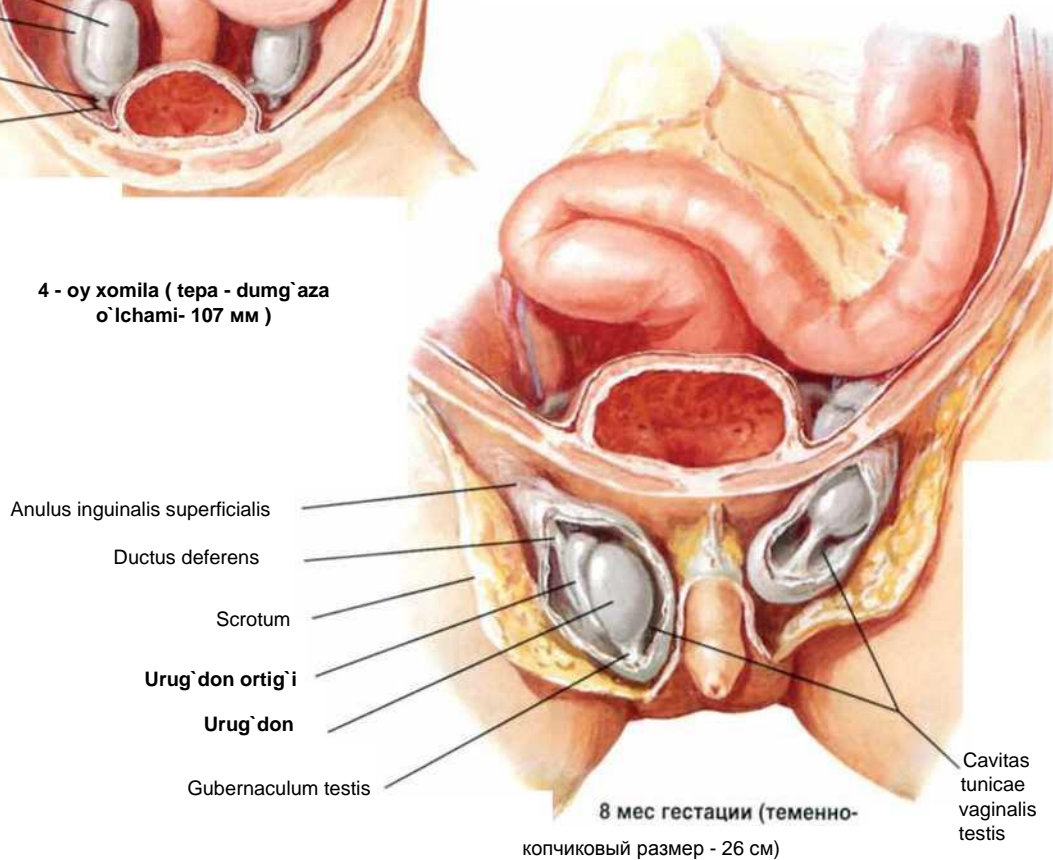
8 - hafta (tepa - dumg'aza o'lchami- 22,5 mm)



11 - hafta (tepa - dumg'aza o'lchami- 43 mm)

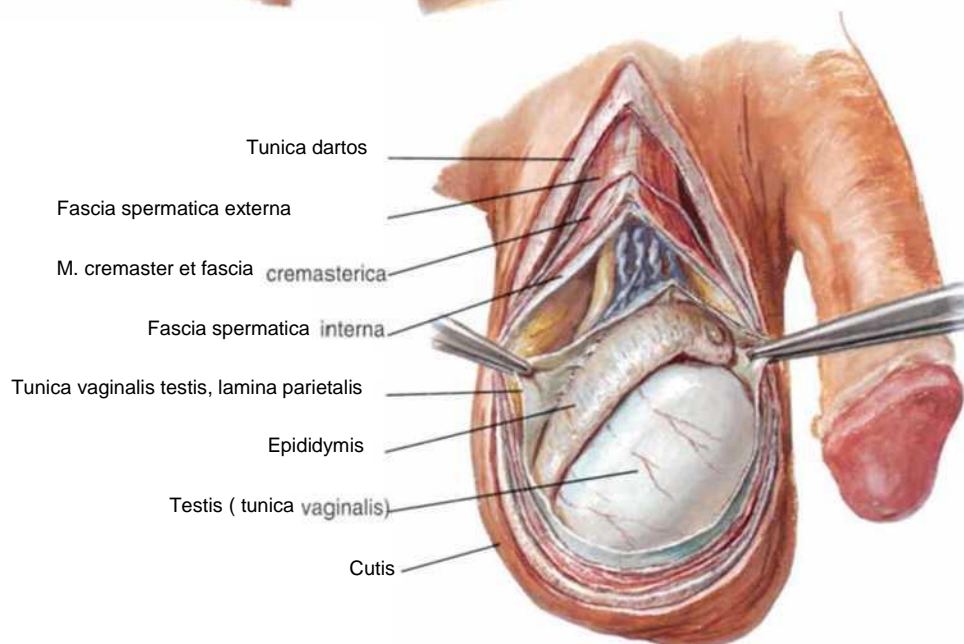
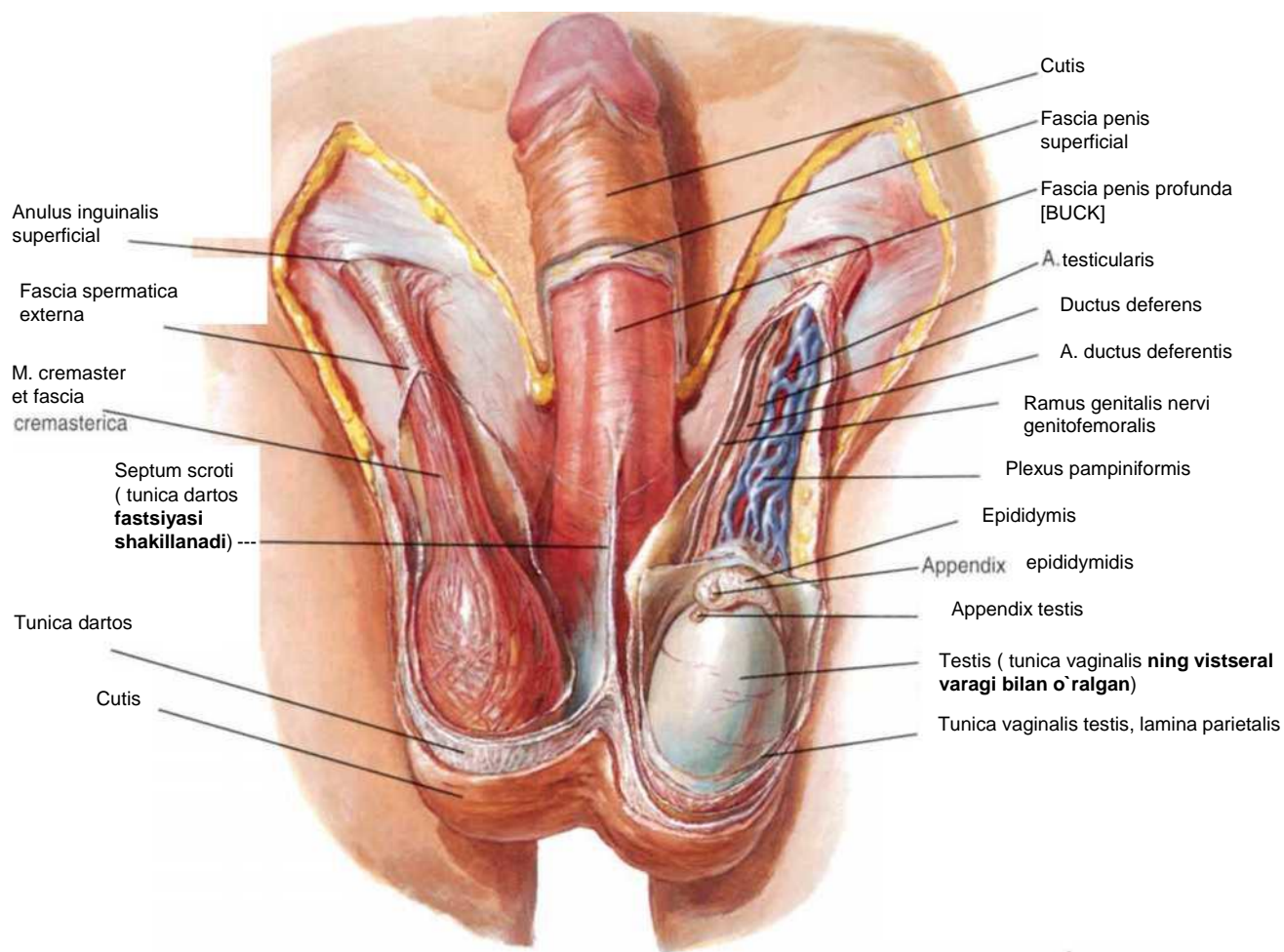


4 - oy xomila (tepa - dumg'aza o'lchami- 107 mm)

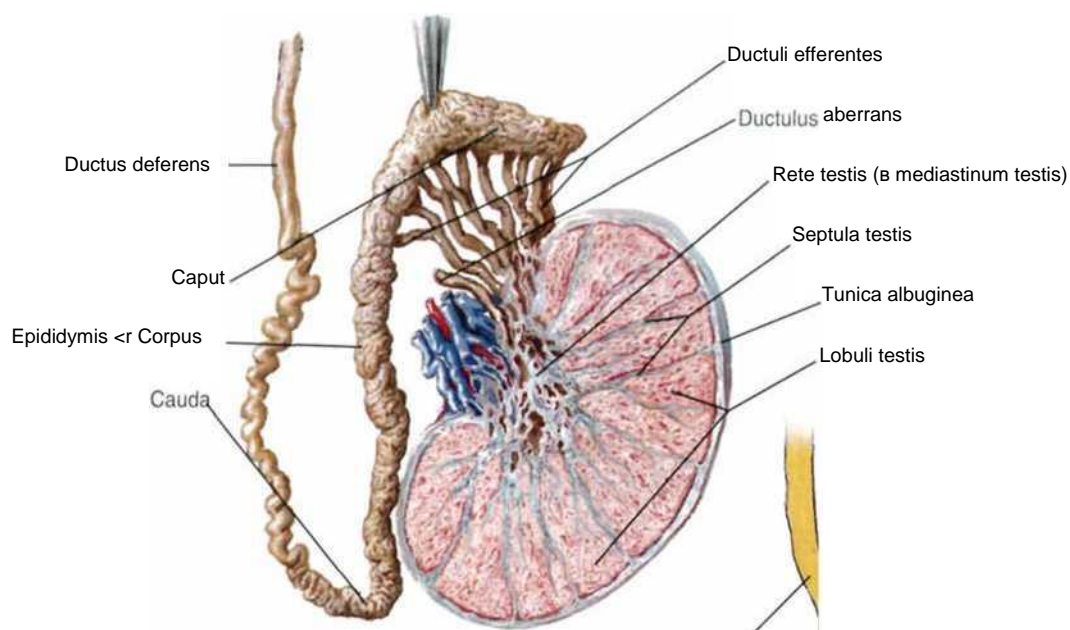


8 мес гестации (теменно- копчиковый размер - 26 см)

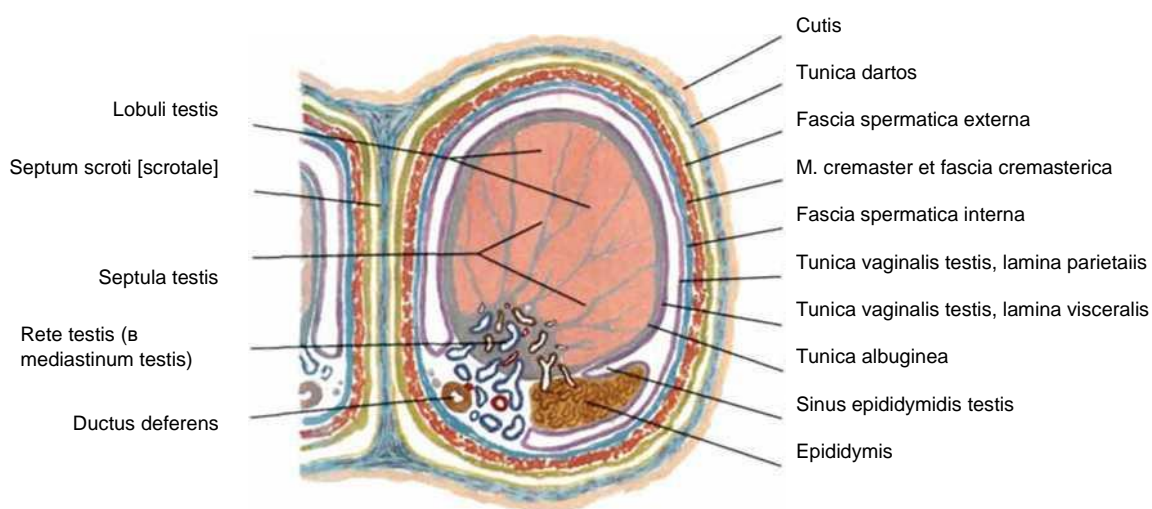
Yorg'oq (scrotum)



Urug'don, urug'don ortig'i va urug' yo'li



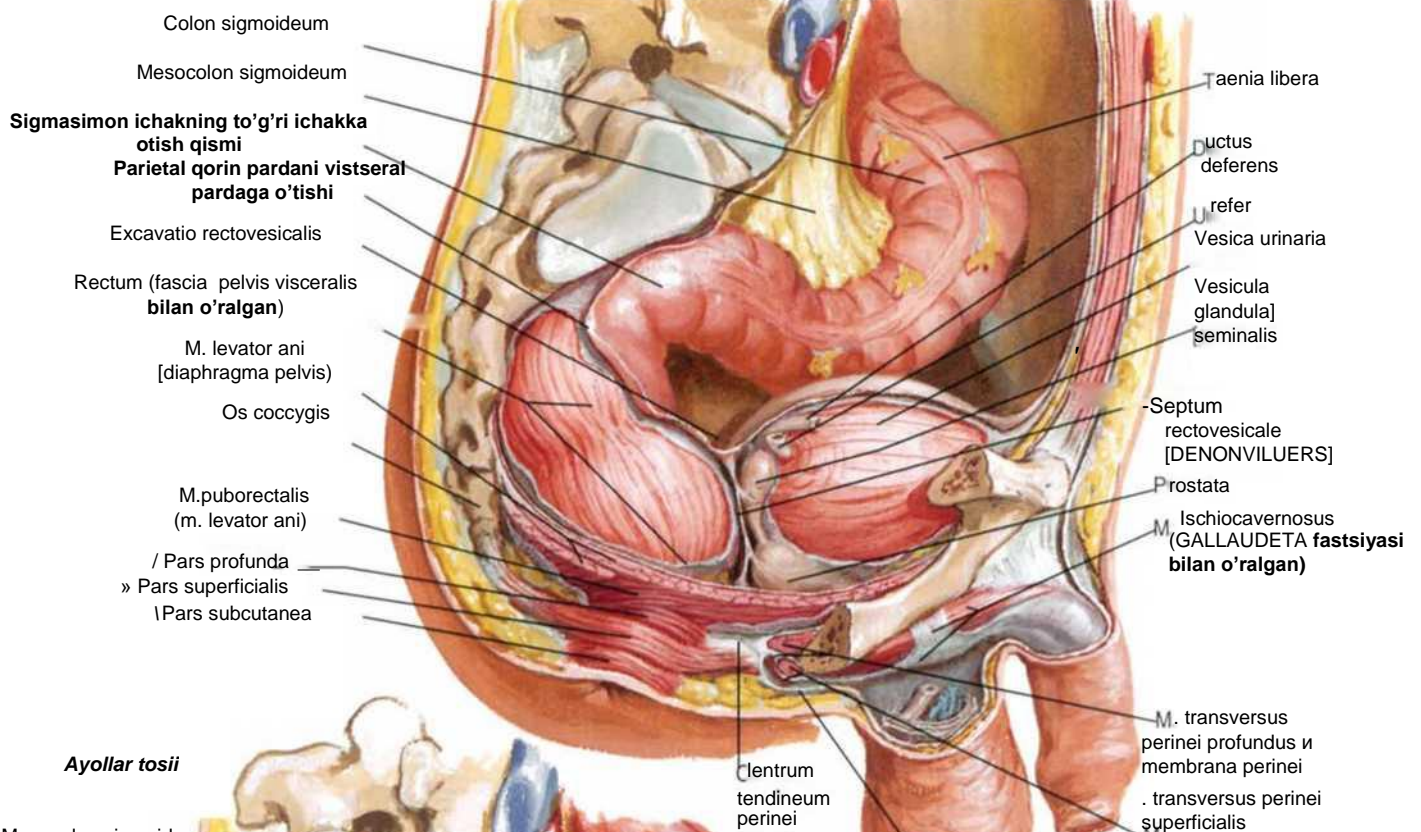
Frontal kesmasi



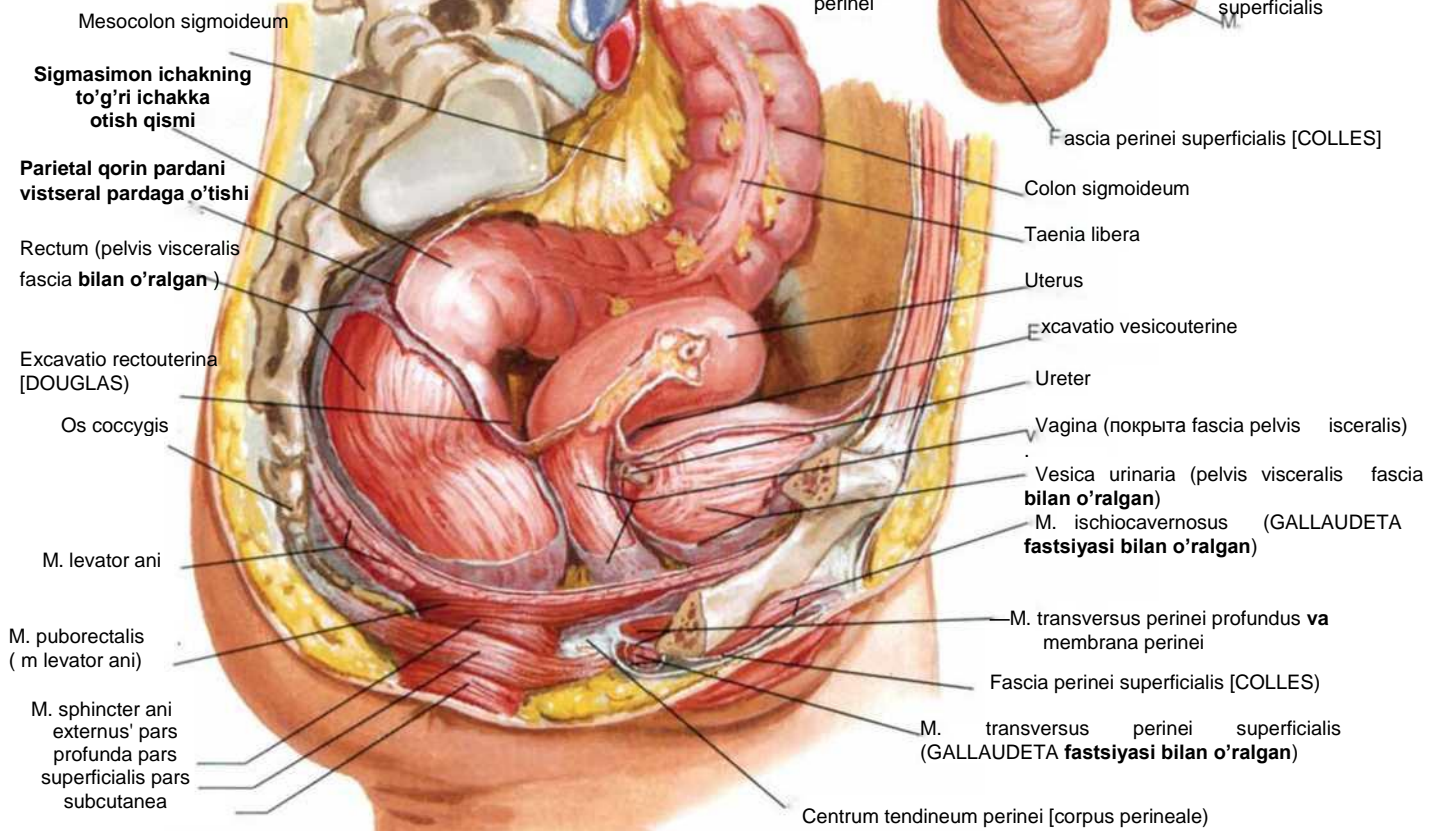
Yorg'oqni urug'don orqali ko'ndalang kesmasii

To'g'ri ichak (rectum)

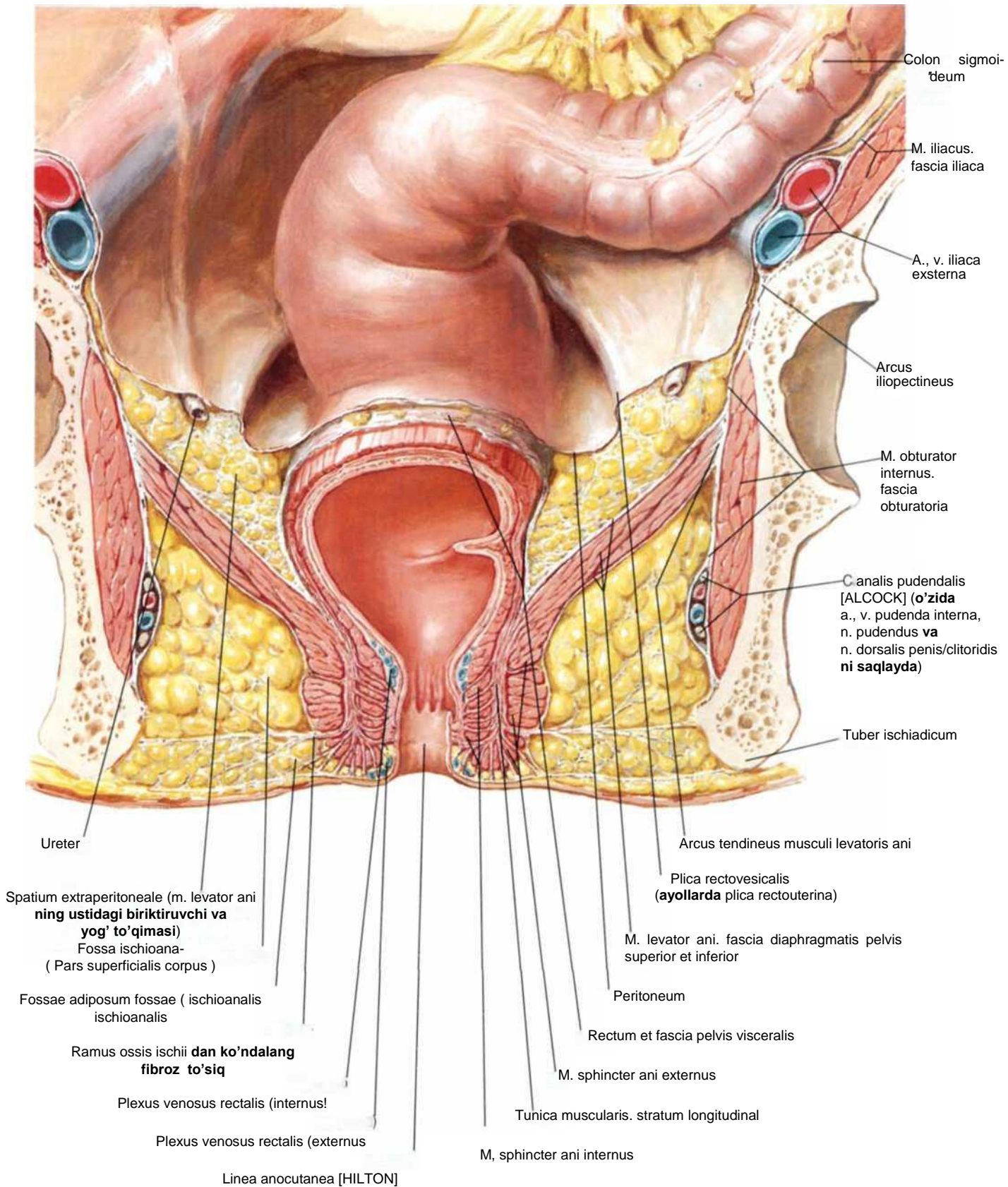
Erkaklar tosi



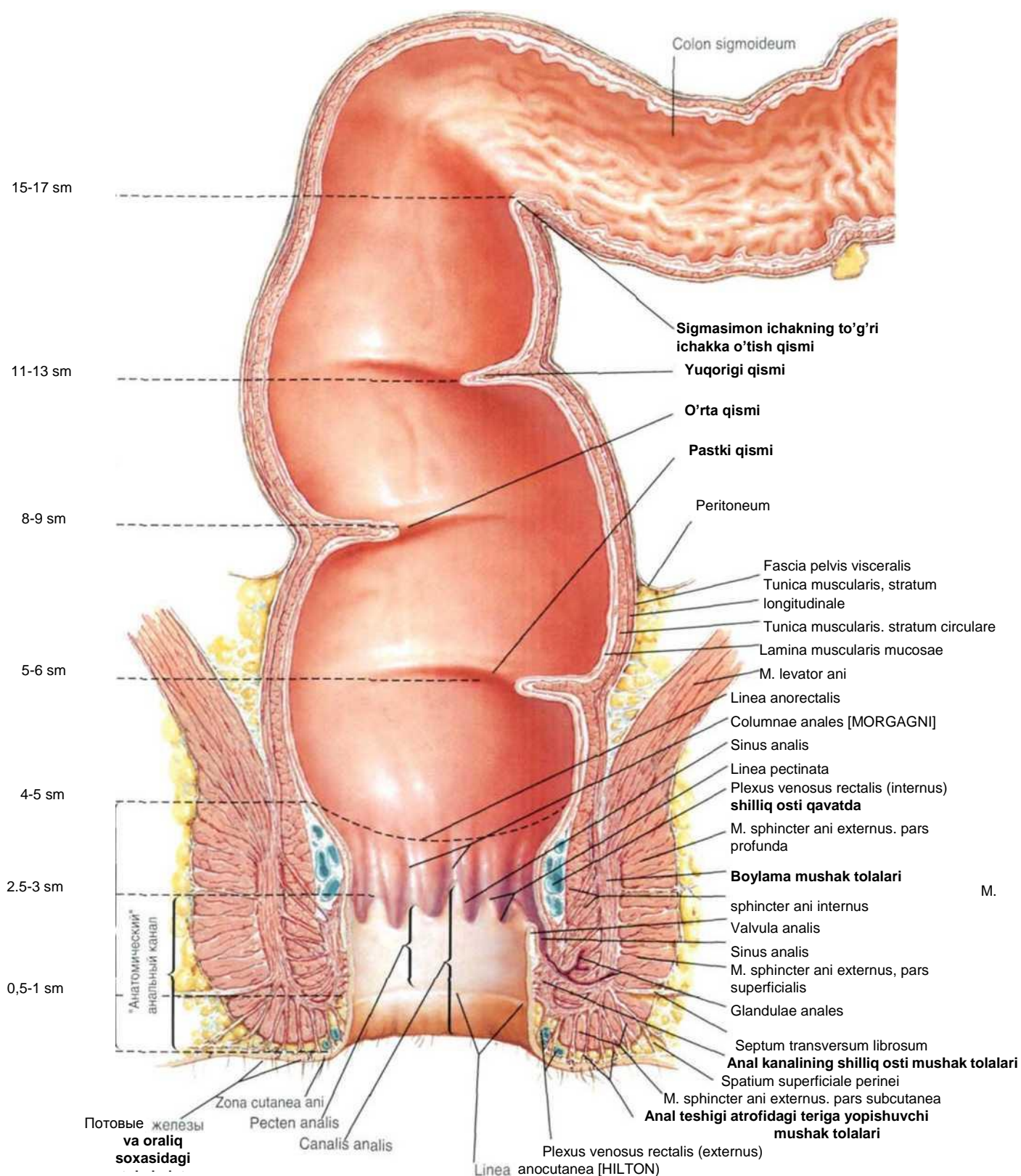
Ayollar tosi



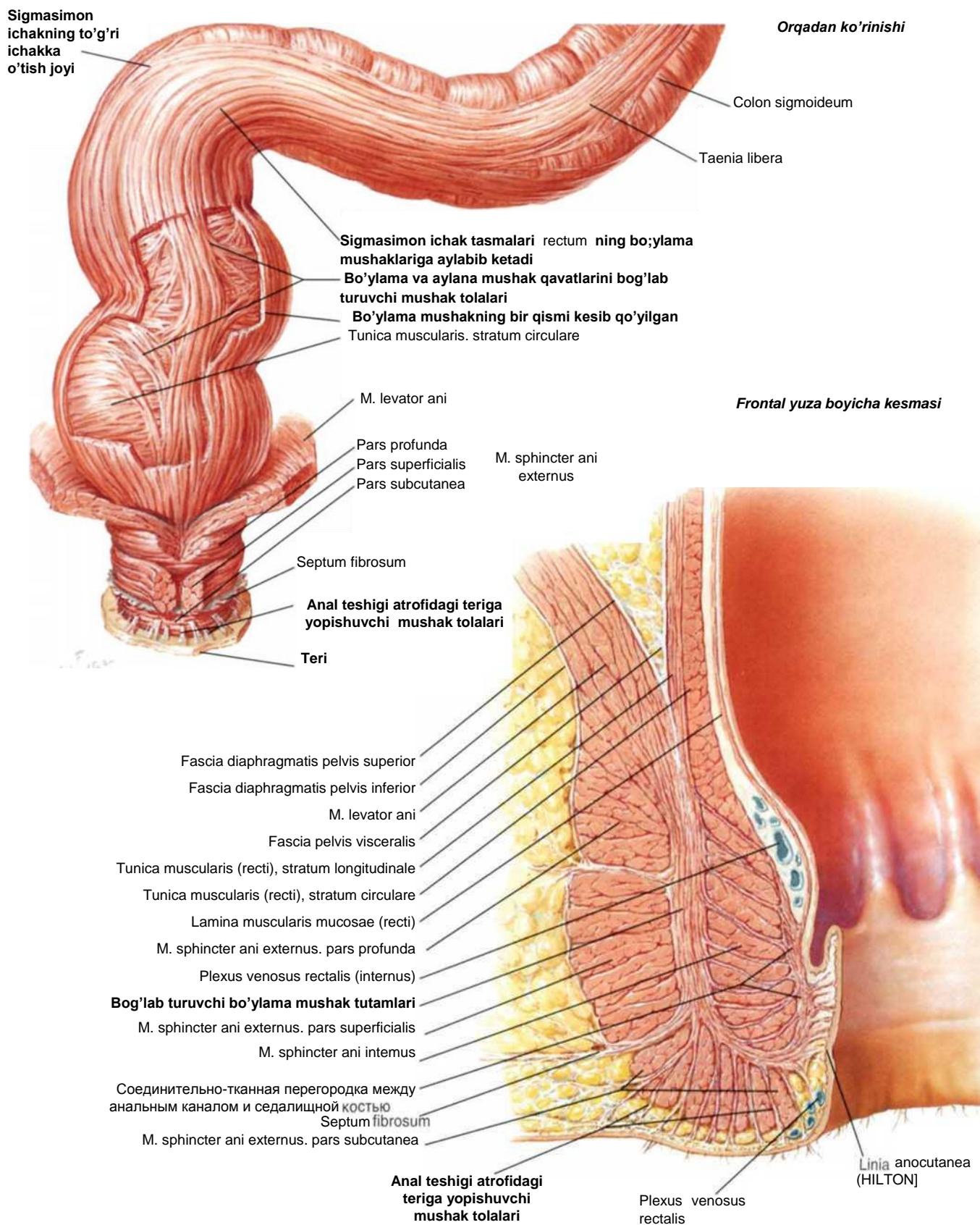
Quymich - to'g'ri ichak chuqurchasi (fossa ischioanalis)



To'g'ri ichak (rectum) va anal kanali (canalis analis)

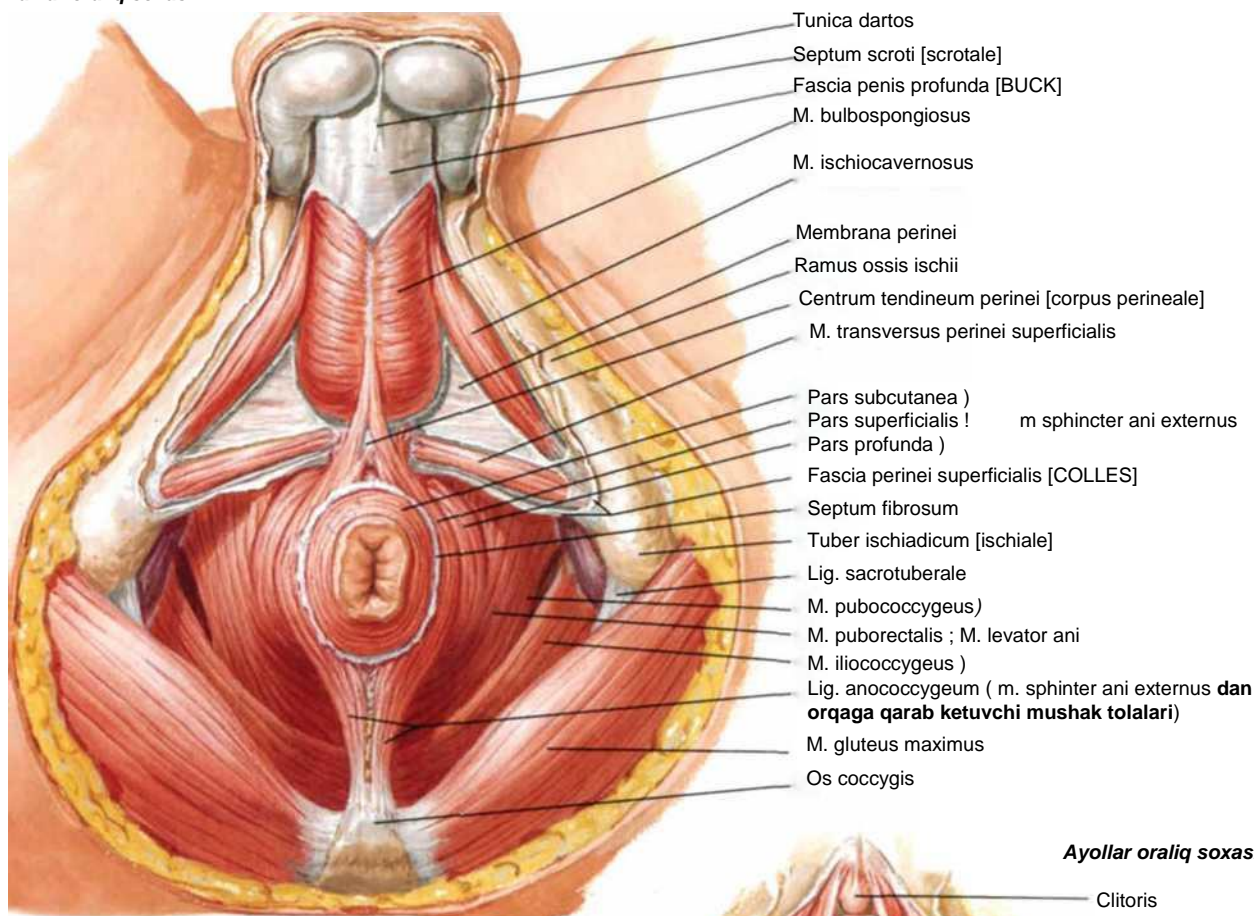


To'g'ri ichak va anal kanali mushaklari

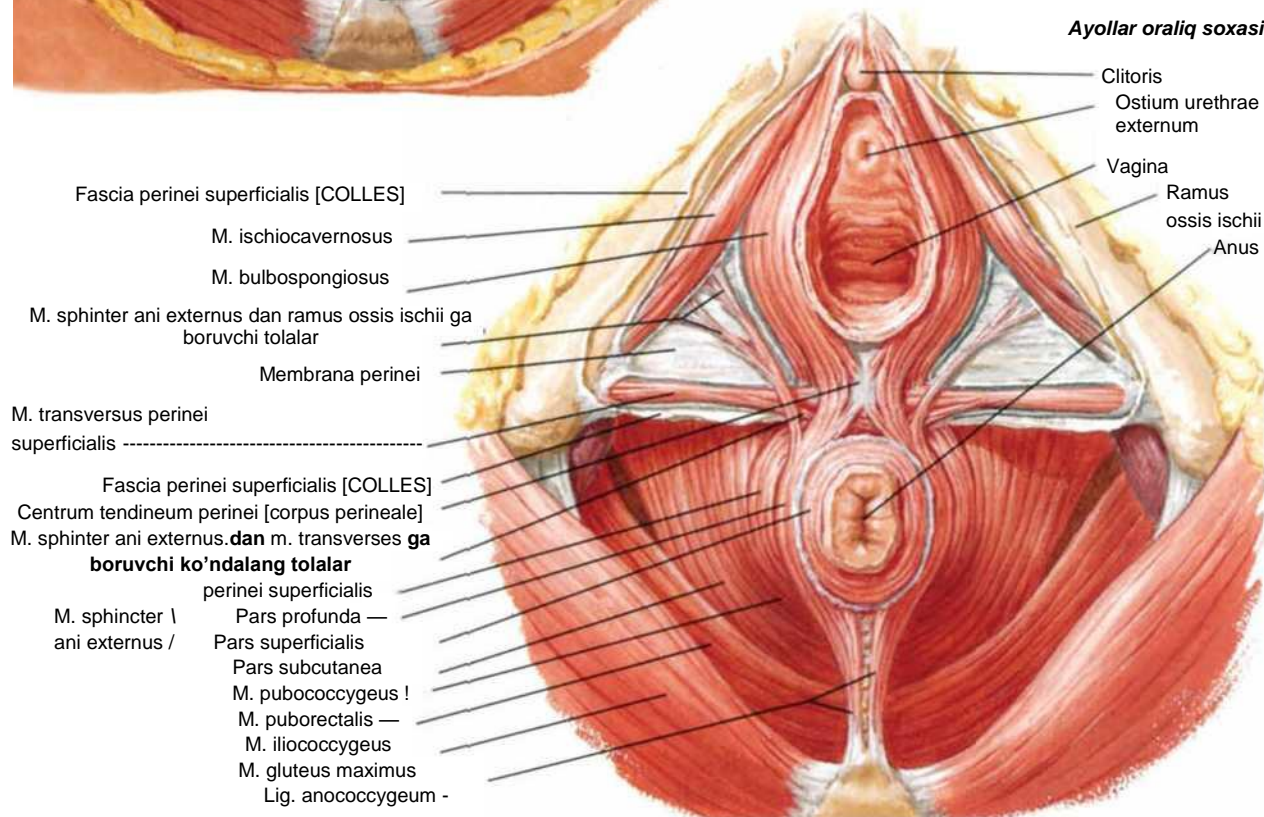


Tosning tubi va oraliq soxasi: pastdan ko'rinishi

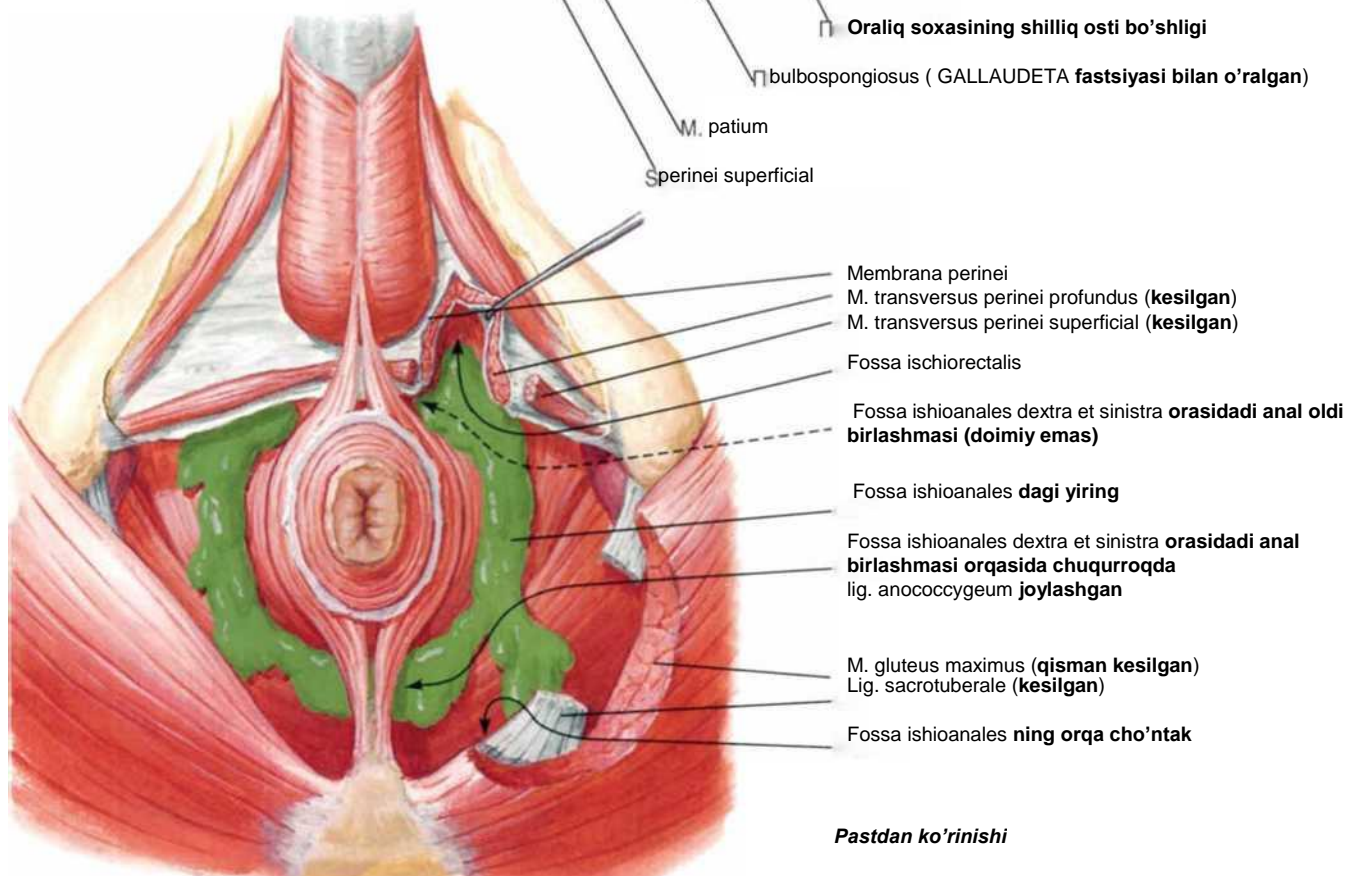
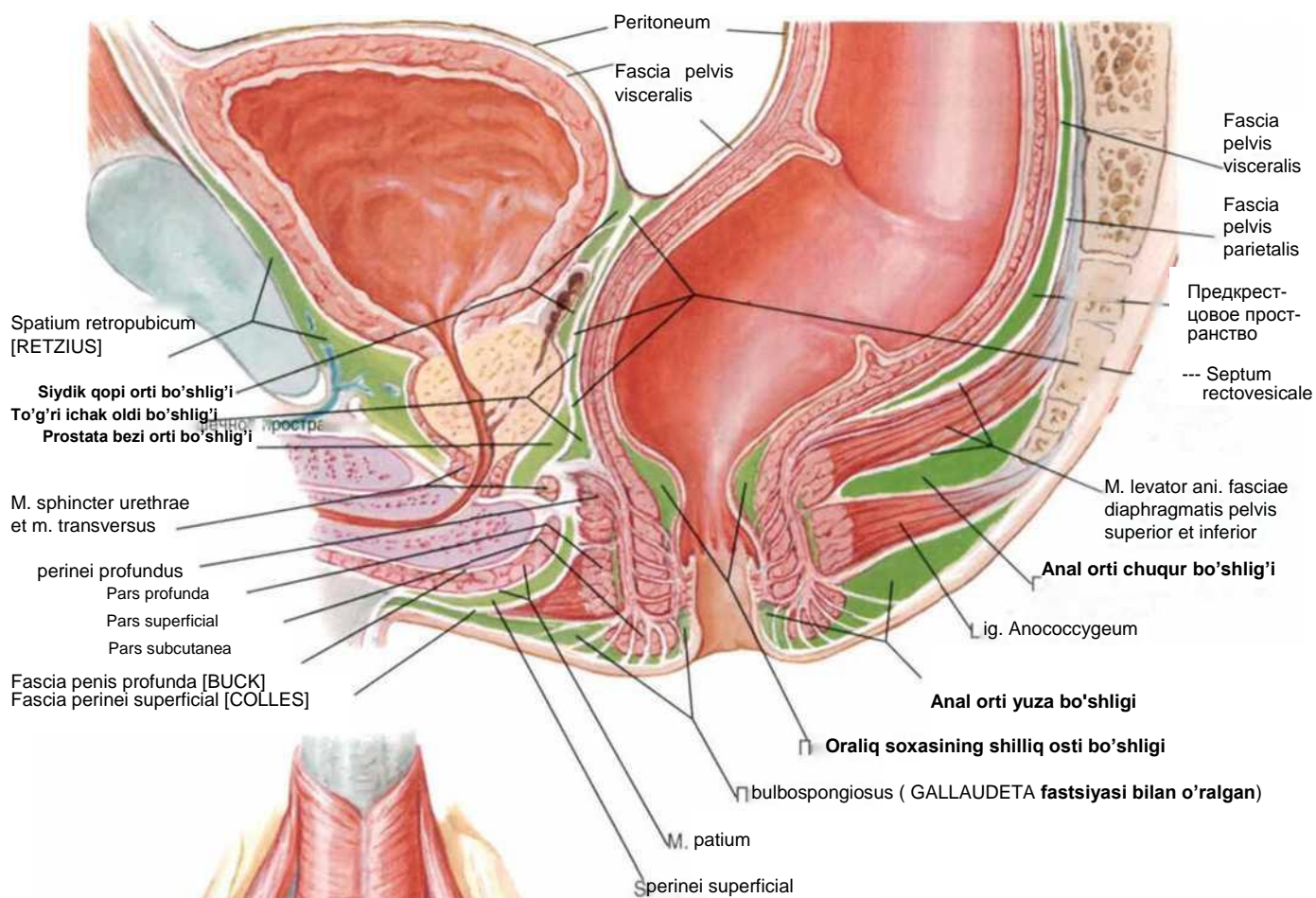
Erkaklar oraliq soxasi



Ayollar oraliq soxasi



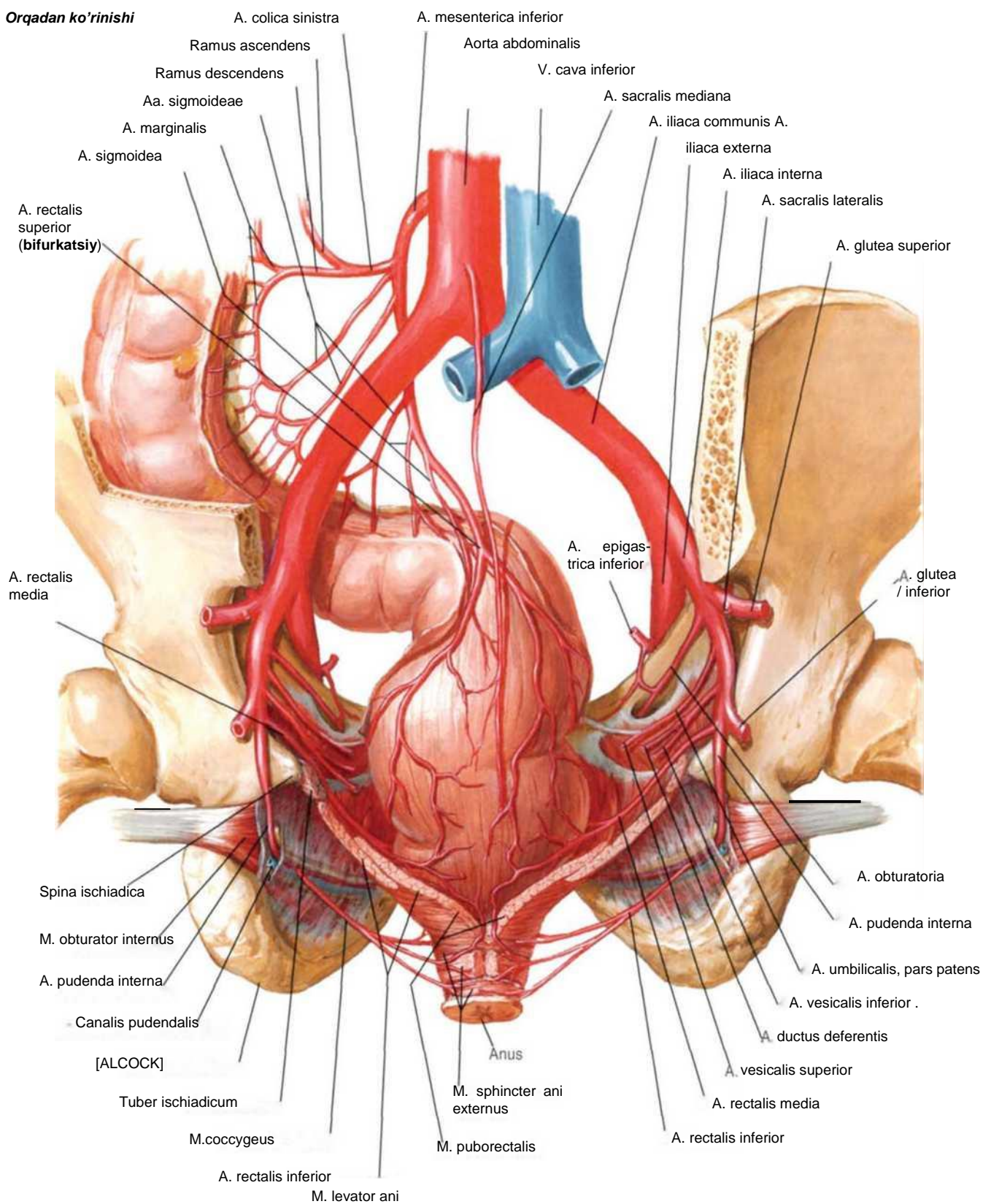
Sagittal kesma



Oraliq soxasida abtsesni tarqalishi

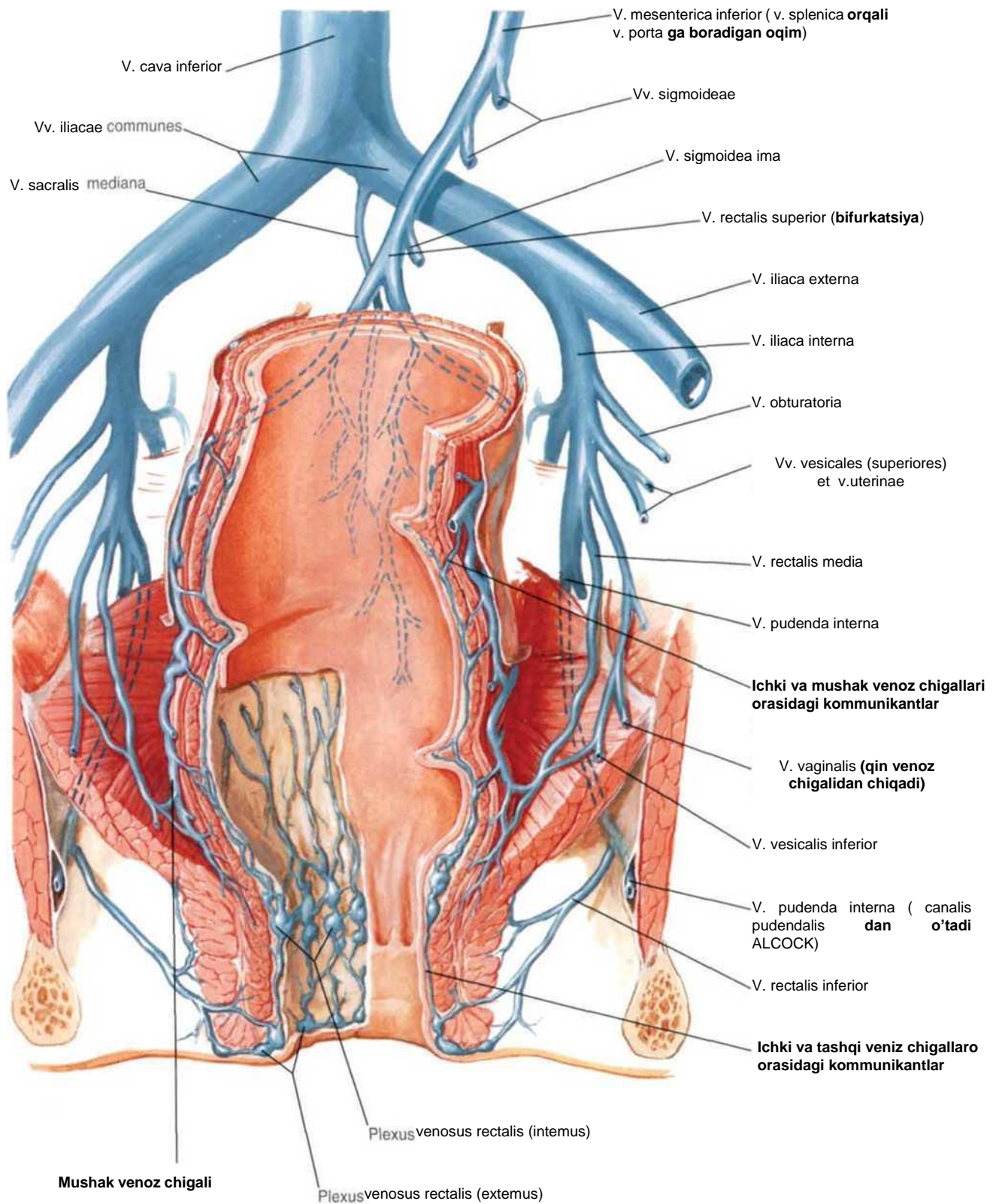
To'g'ri ichak va anal kanali arteriyalari

Orqadan ko'rinishi



To'g'ri ichak va anal kanali venalari

Oldindan ko'rinishi

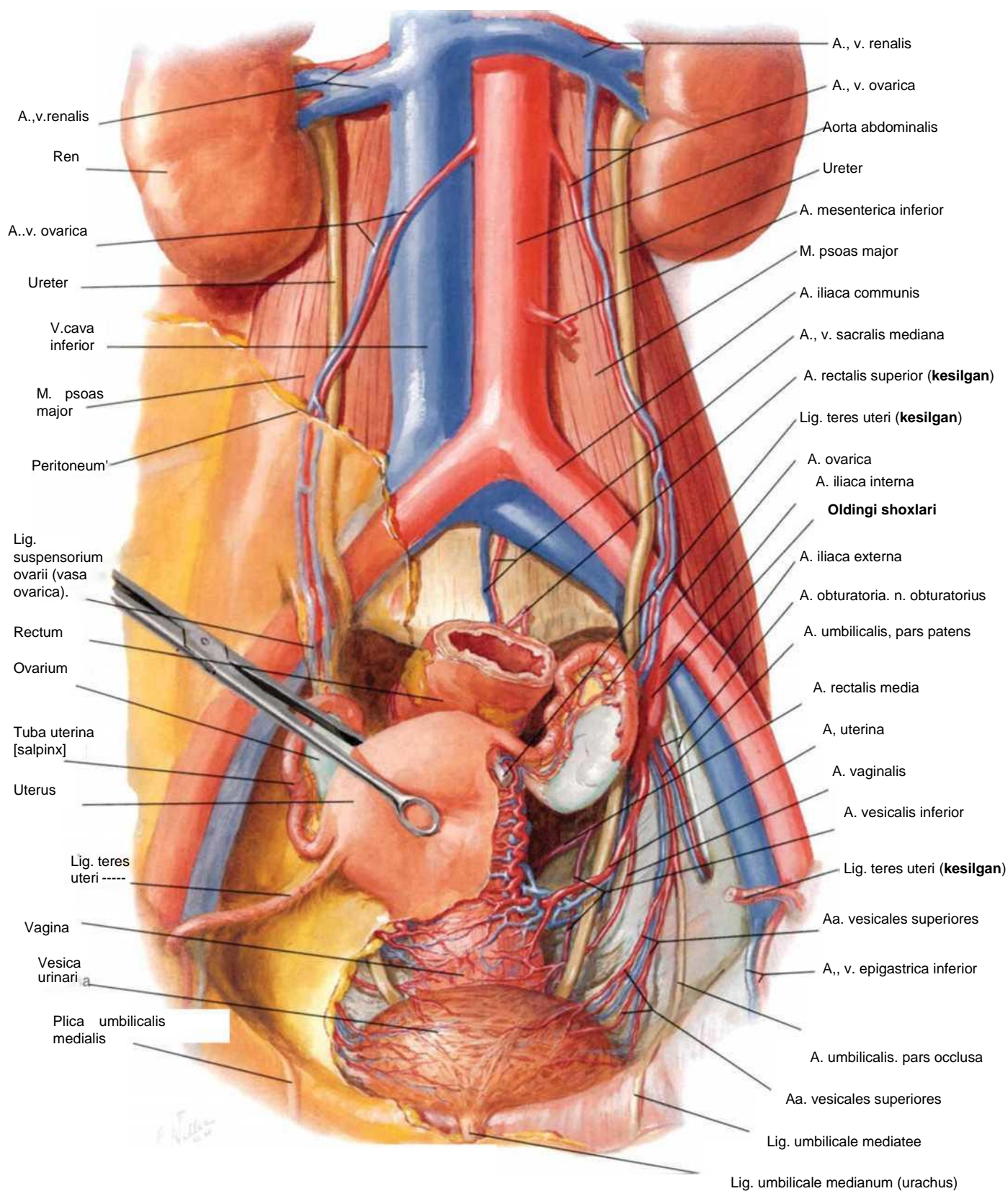


QON BILAN TA'MINLANISHI

370 - Rasm

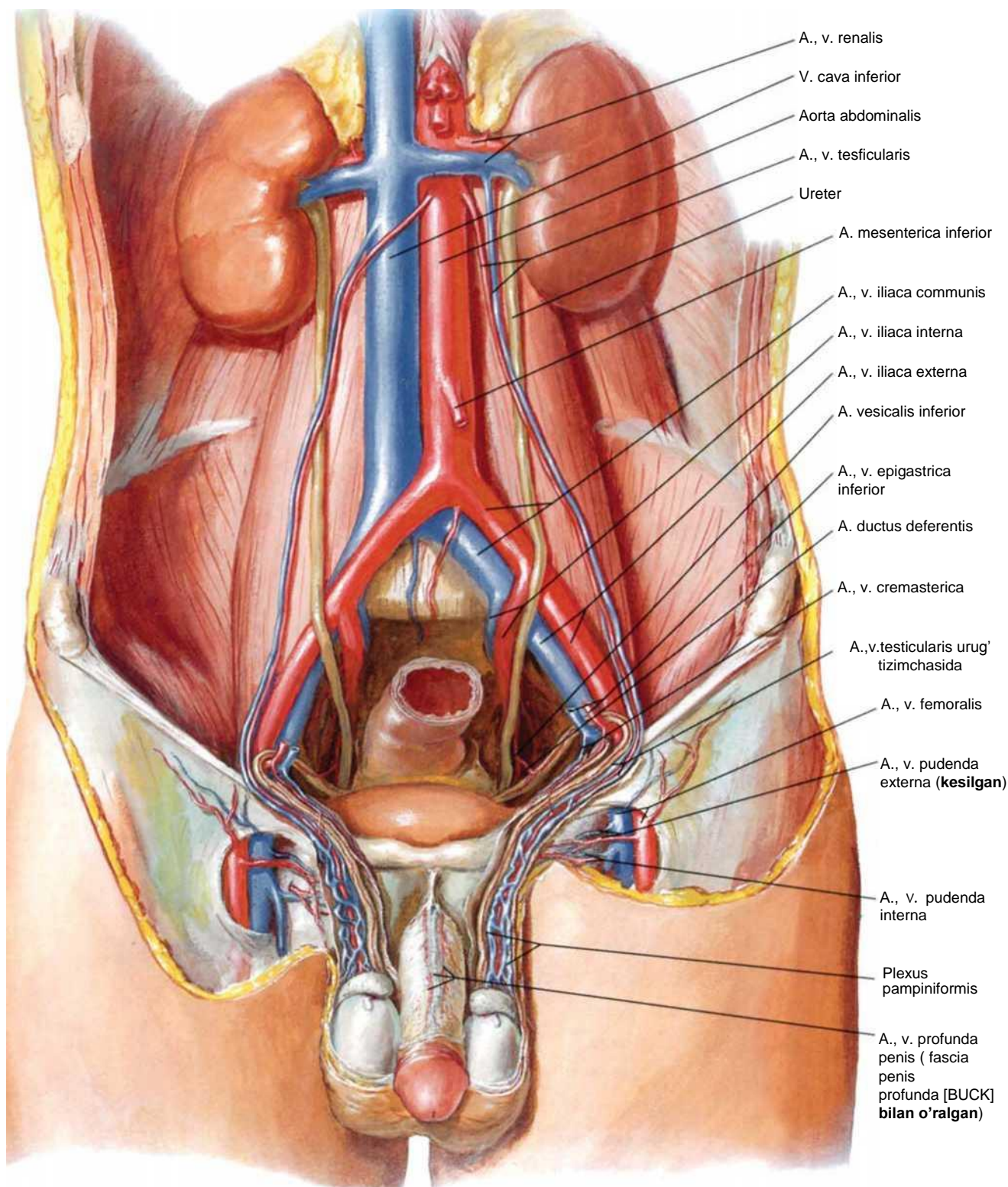
Ayollar to's a'zolarining arteriya va venalari

Oldindan ko'rinishi

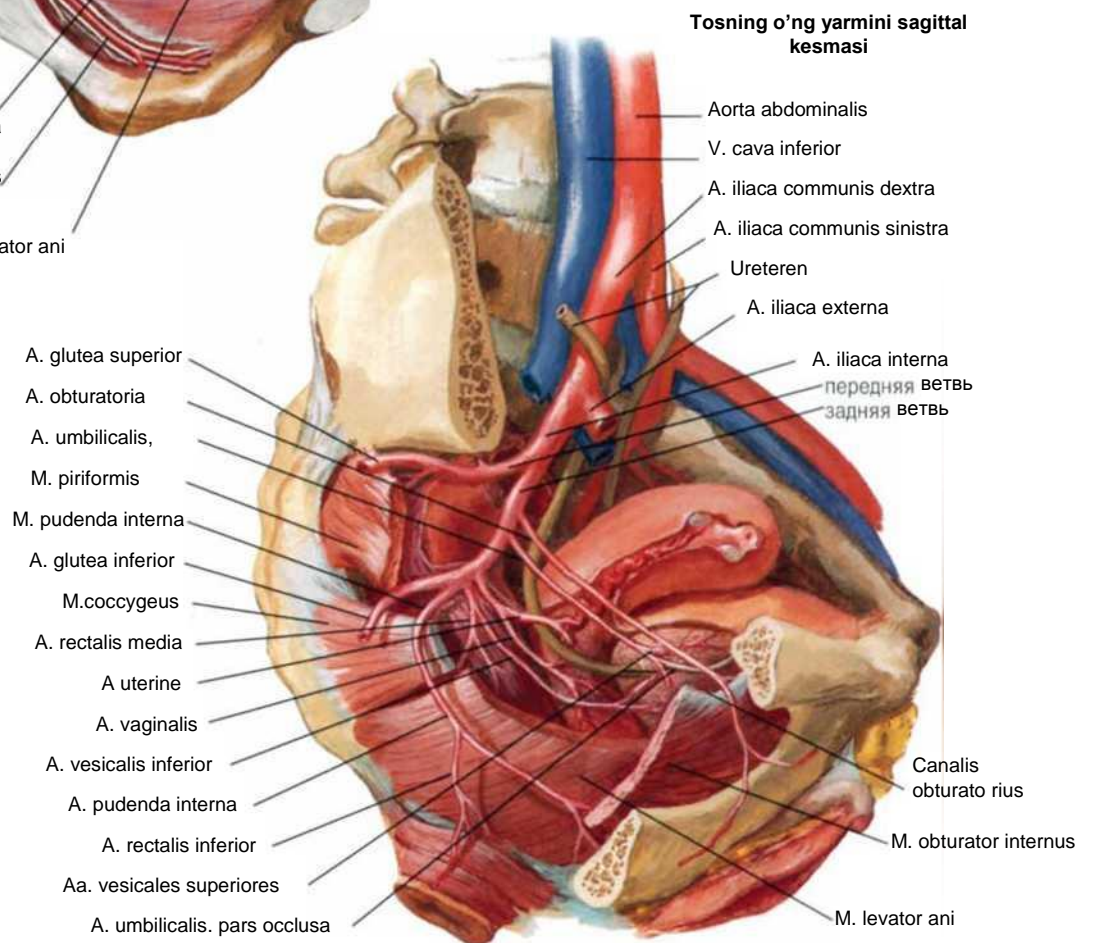
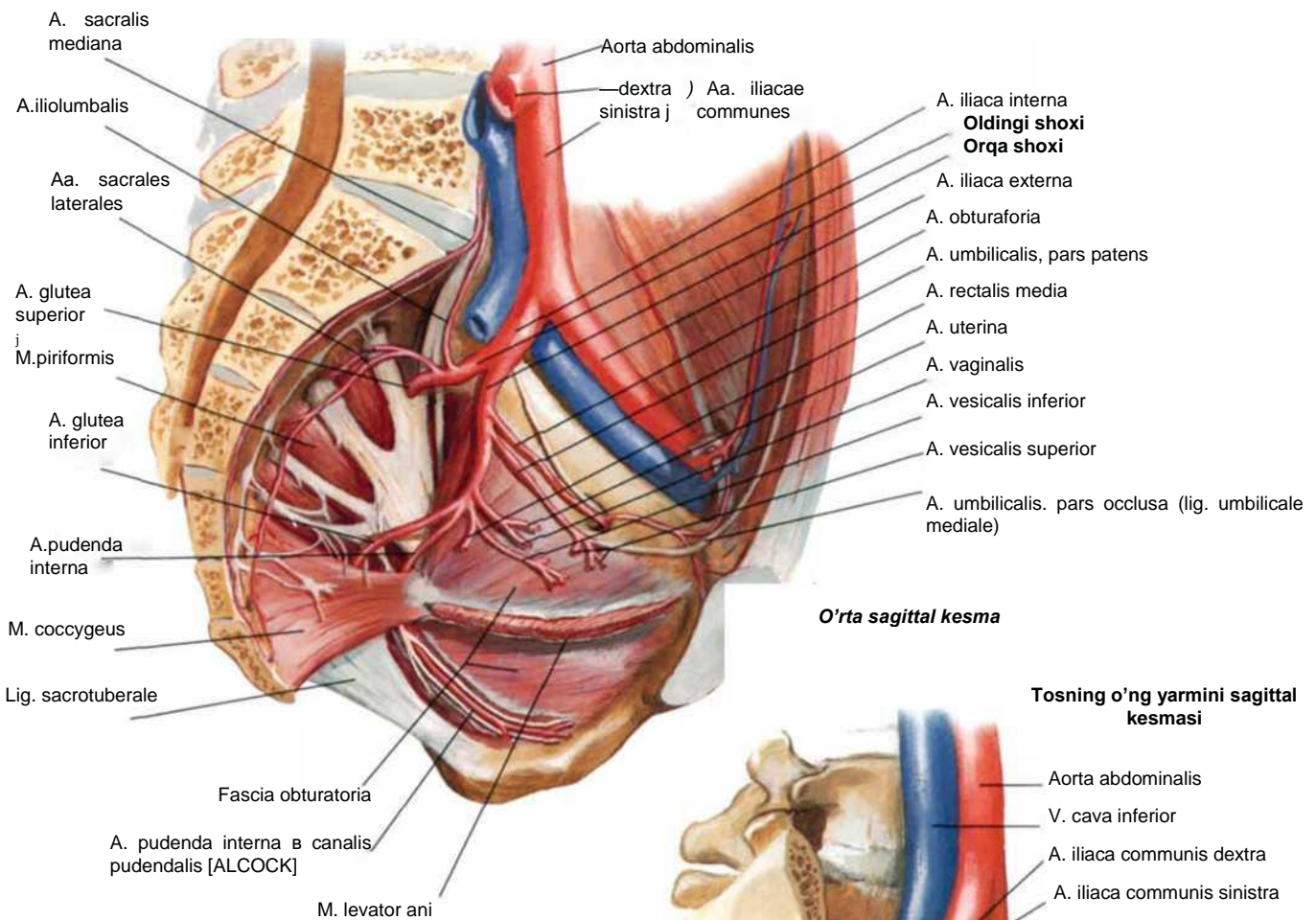


Urug'don arteriya va venalari

Oldindan ko'rinishi

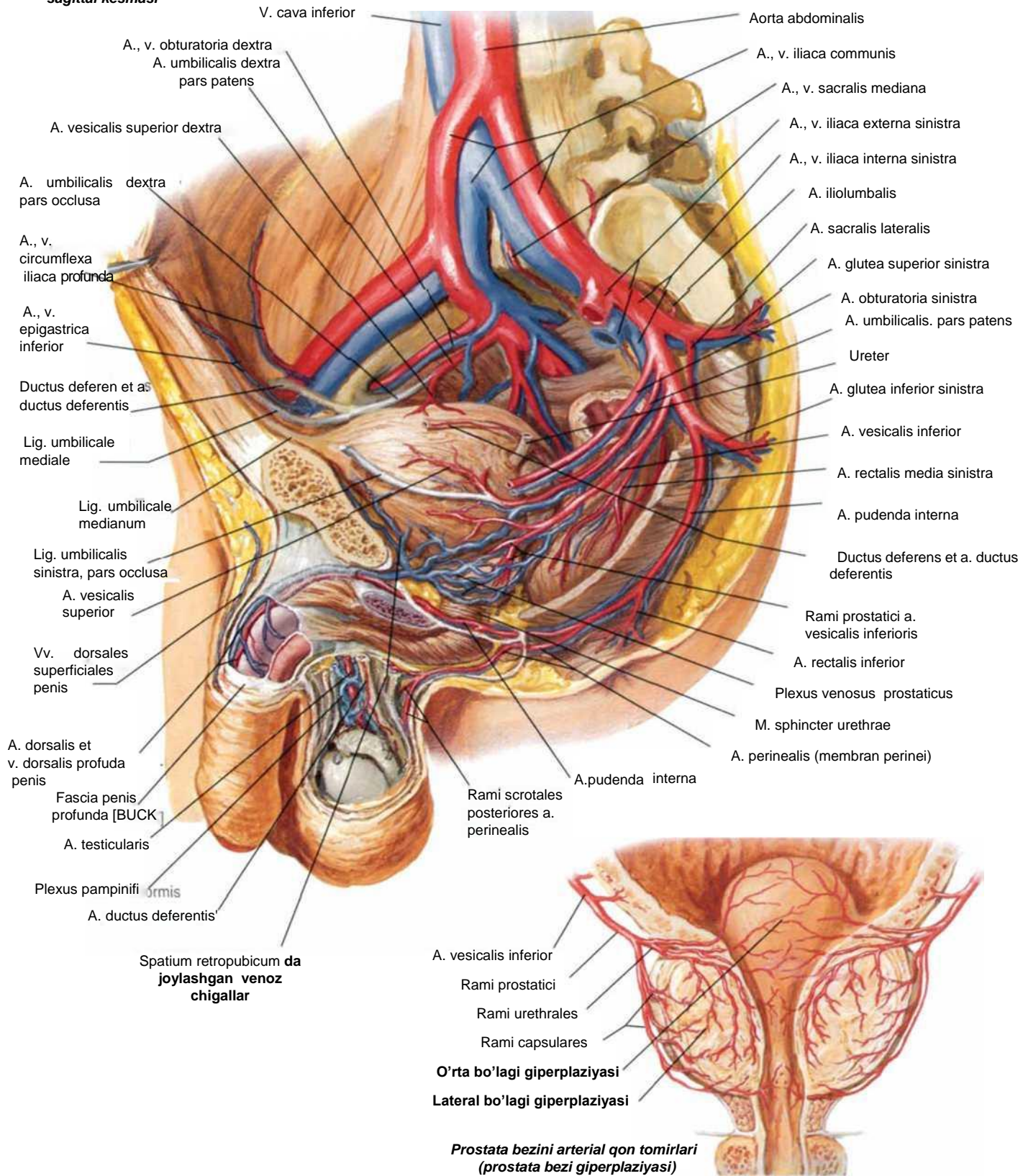


Ayollar tos soxasi arteriya va venalari

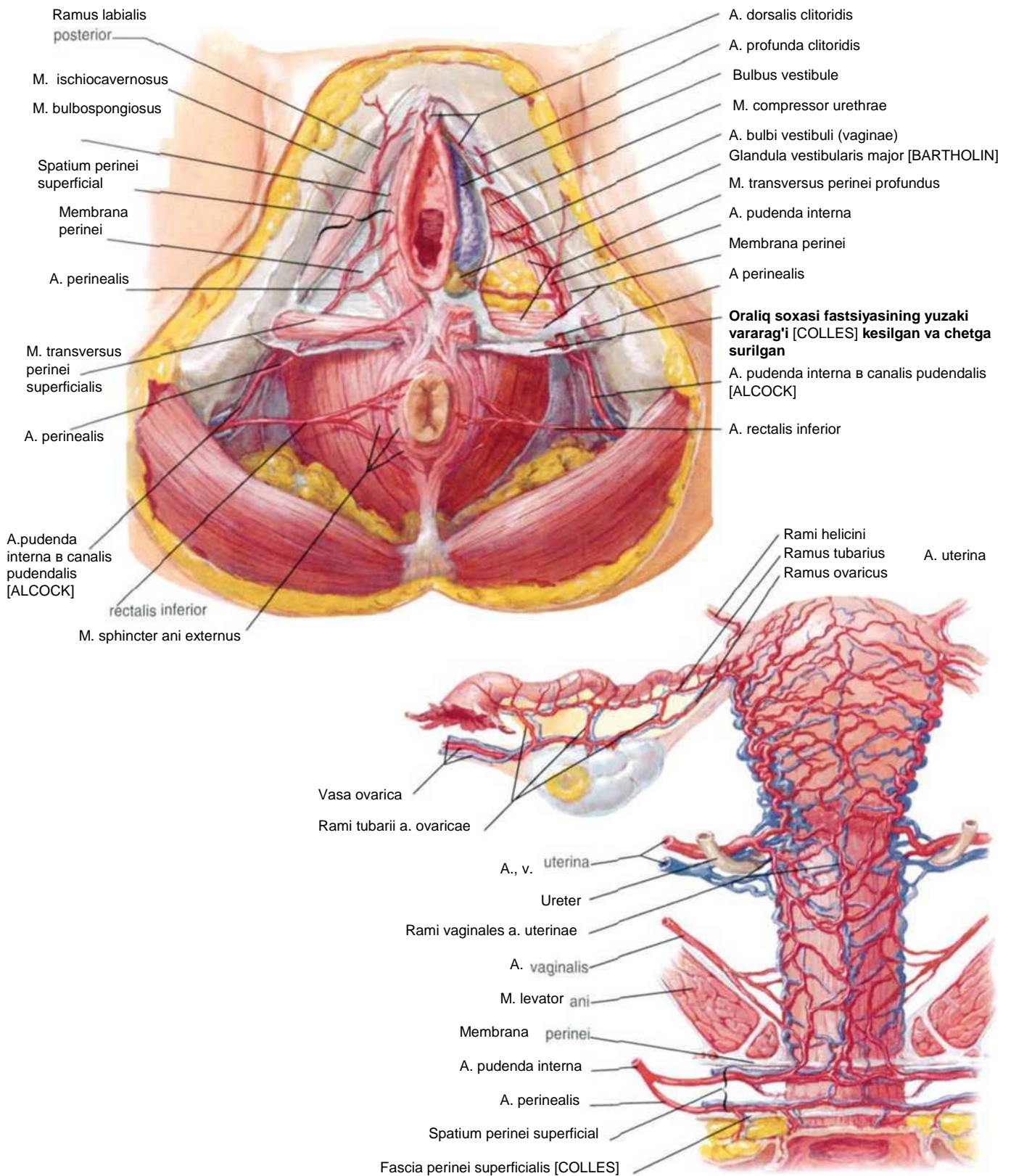


Erkaklar tos soxasi arteriya va venalari

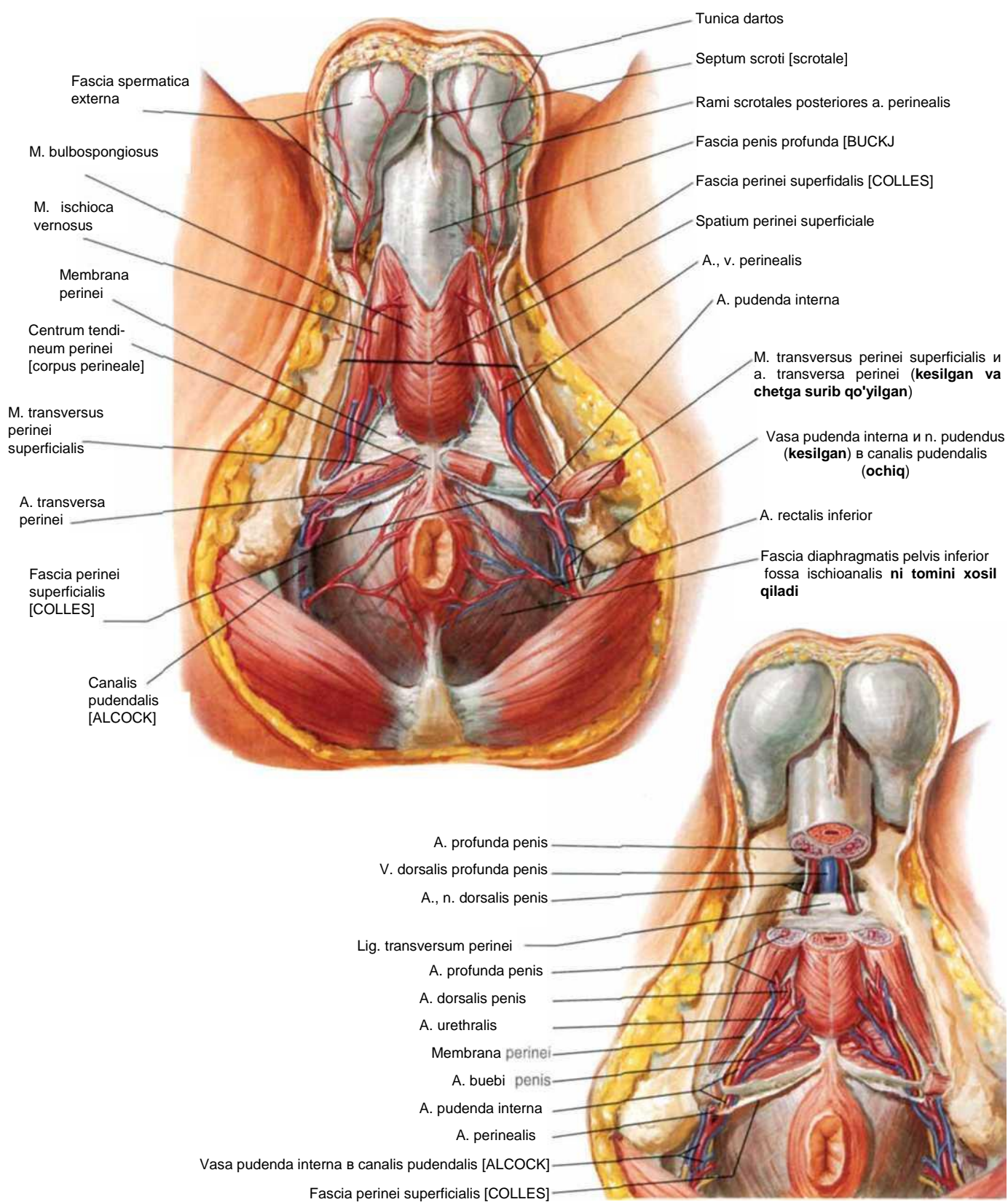
Tosning chap yarmini sagittal kesmasi

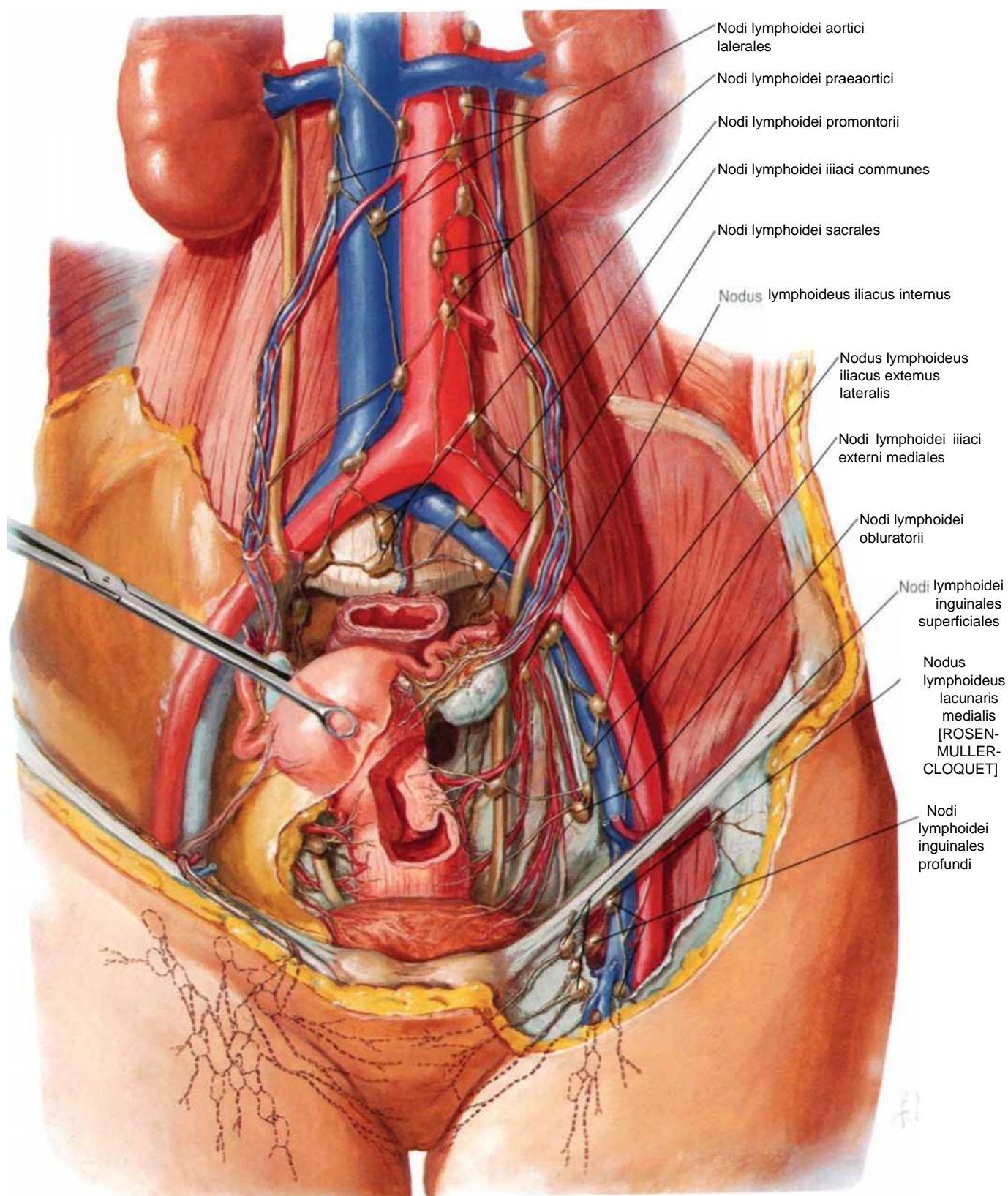


Oraliq soxasi va bachadon arteriya va venalari

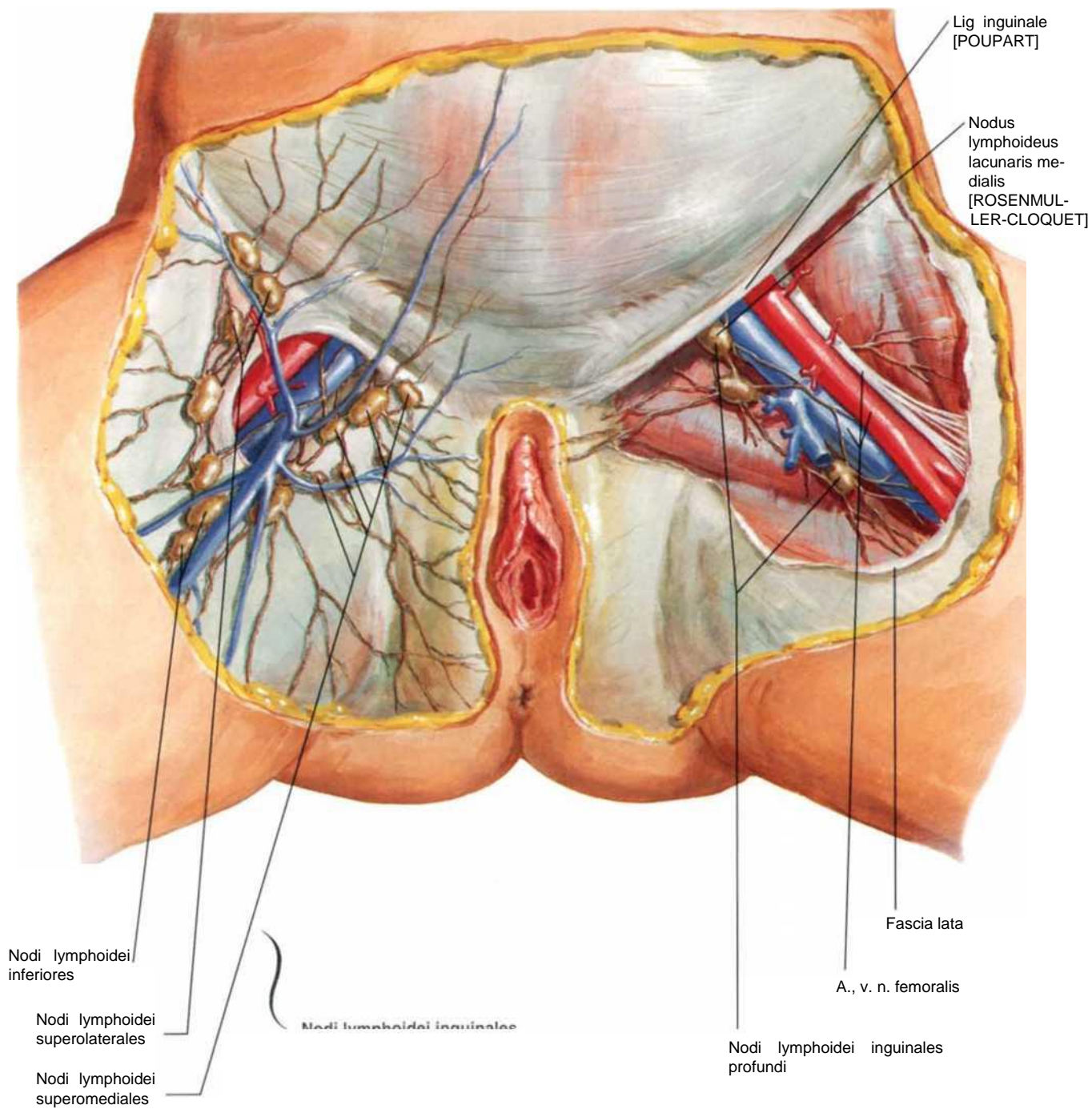


Erkaklar oraliq soxasi arteriya va venalari

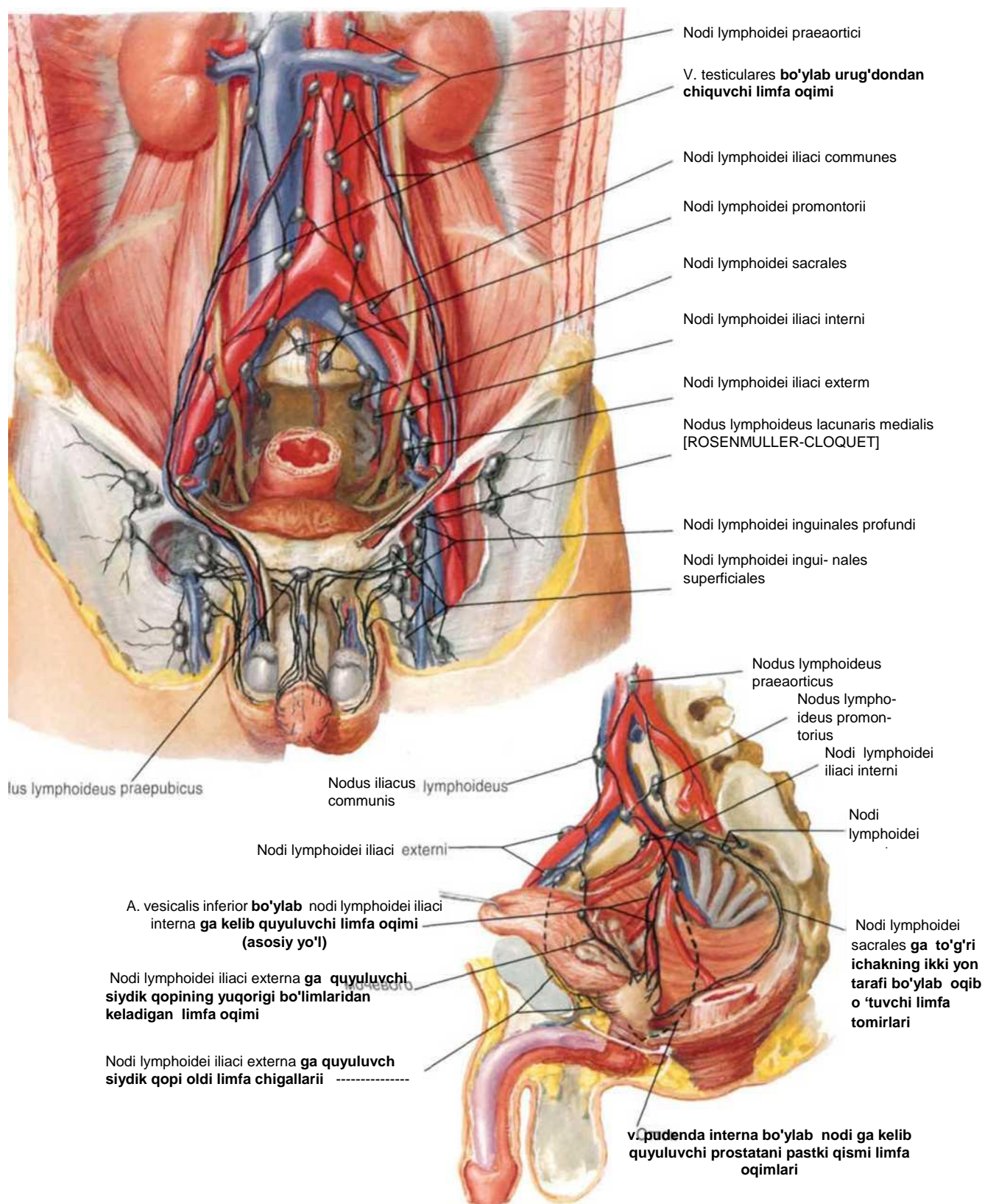




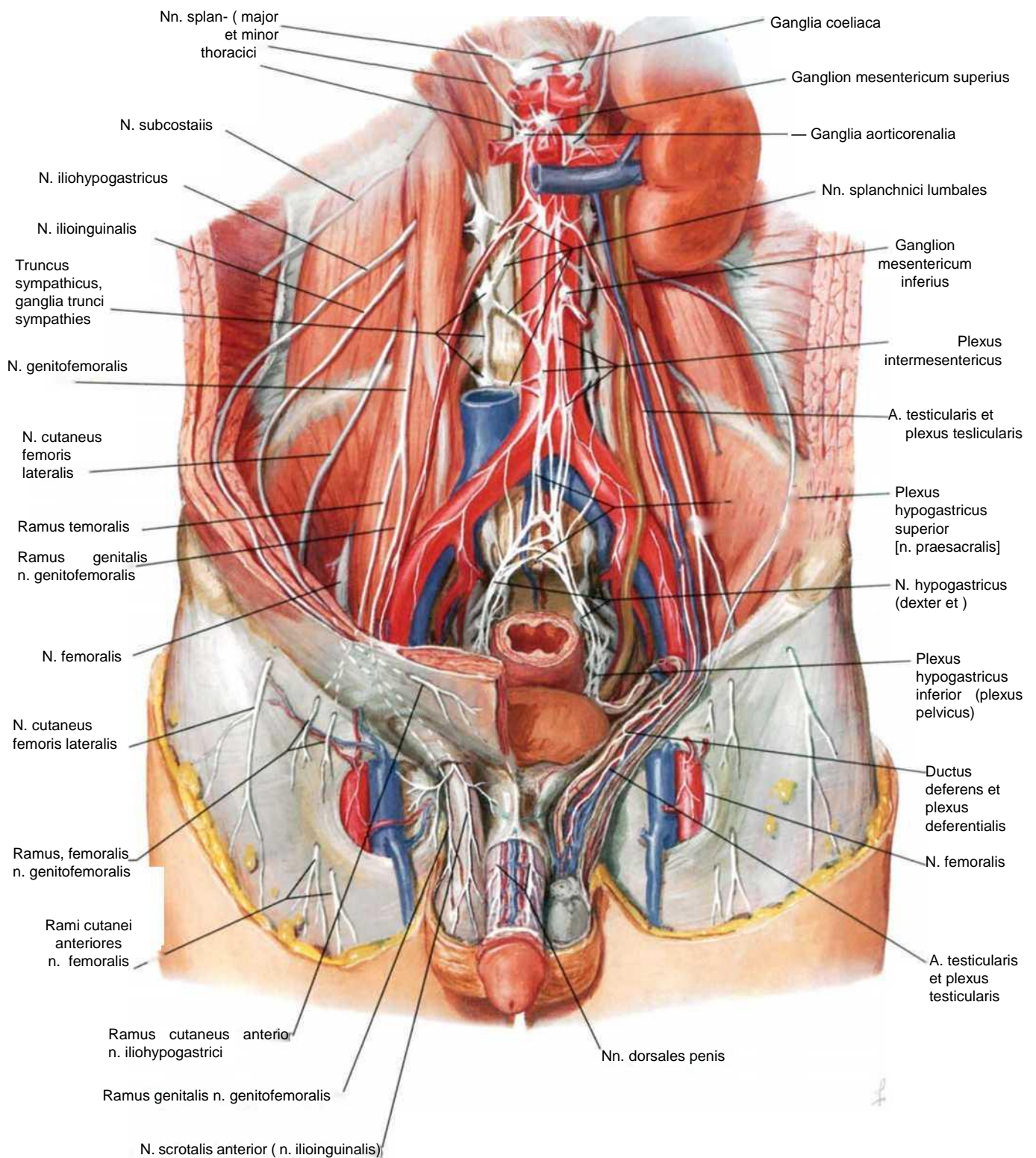
Ayollar oraliq soxasini limfatik tomirlari va tugunlari



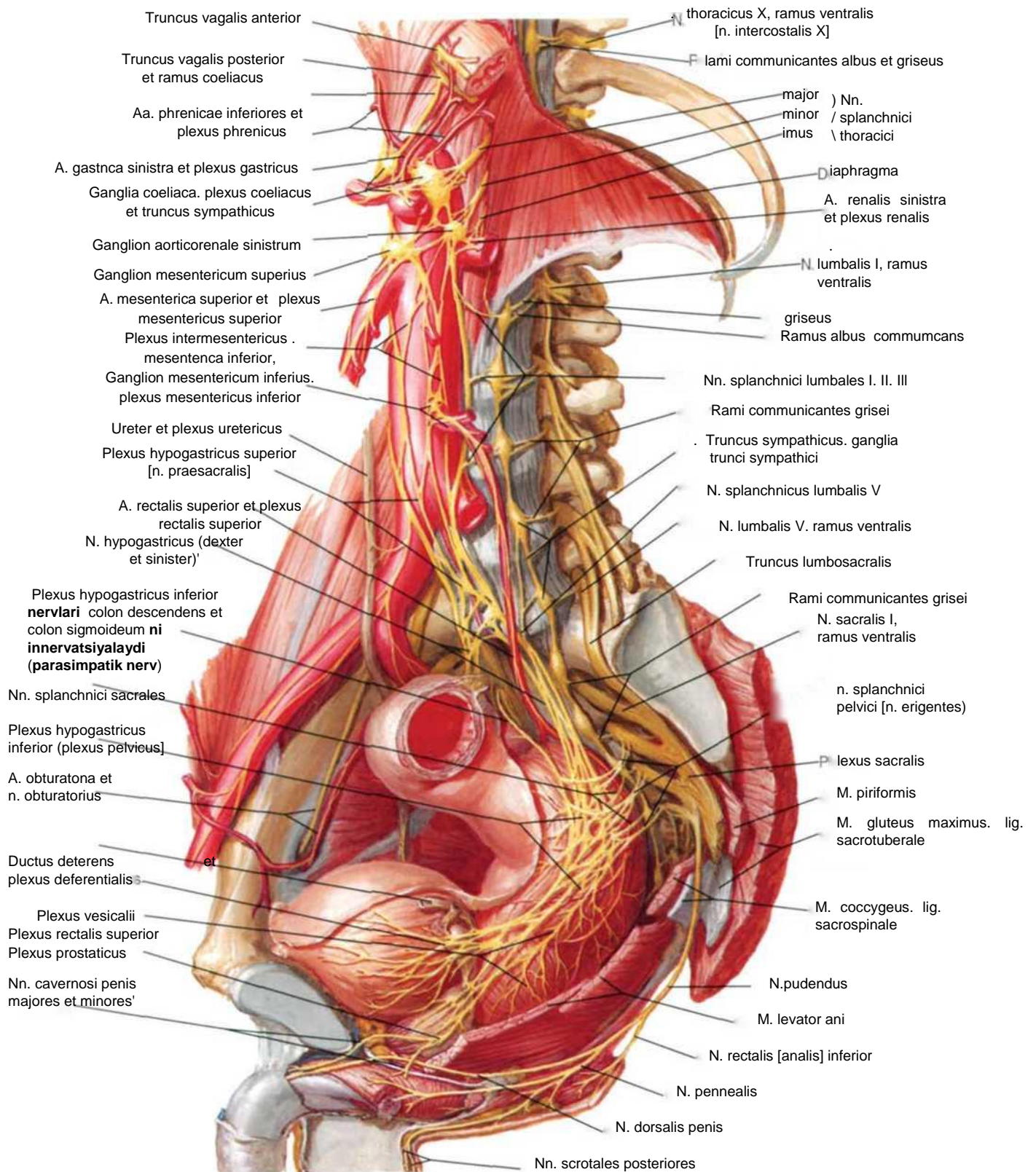
Erkakalar tos soxasi va jinsiy a'zolari limfatik tomirlari va tugunlari



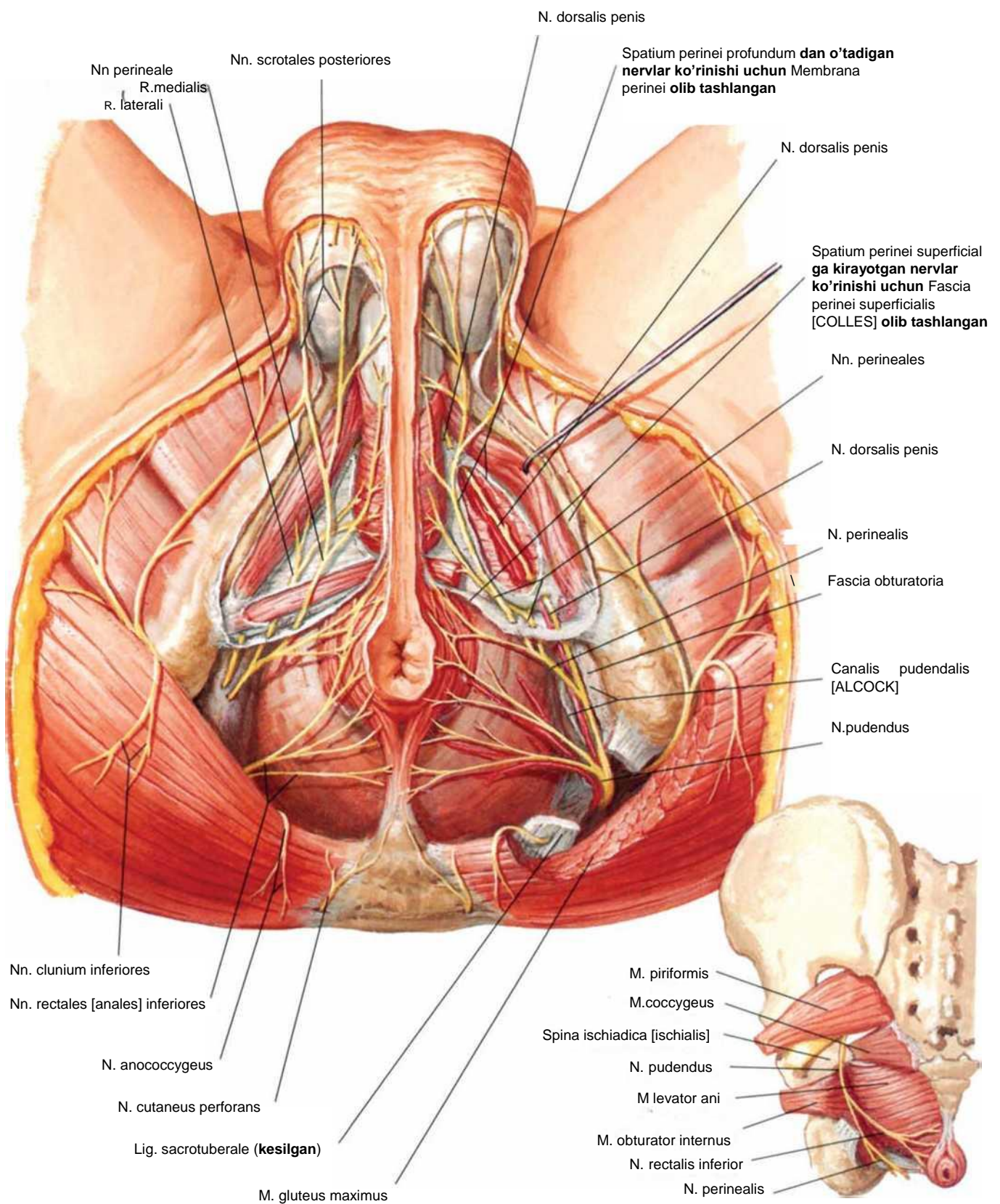
Erkaklar tashqi jinsiy a'zolari innervatsiyasi



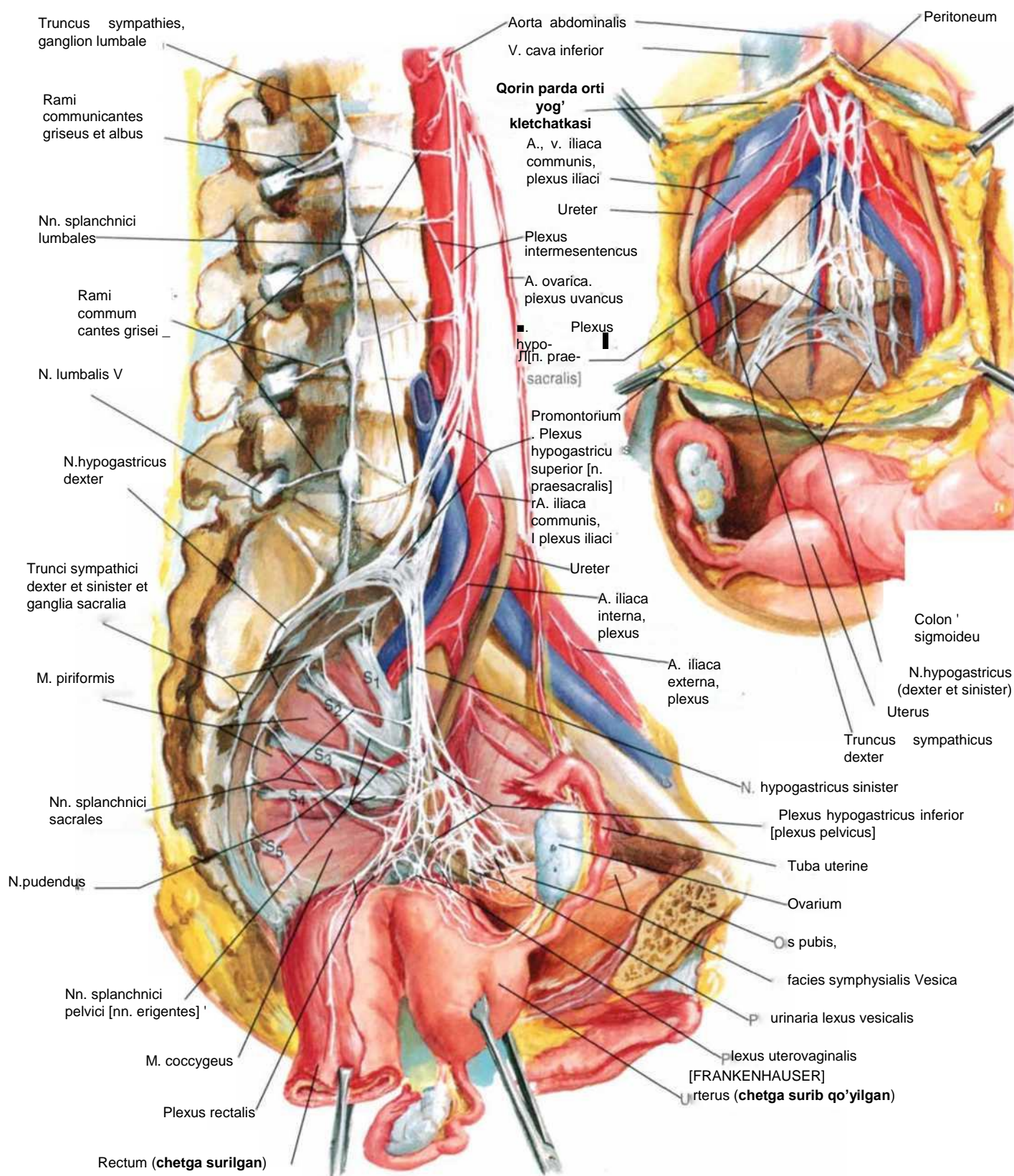
Erkaklar tos soxasi a`zolari innervatsiyasi



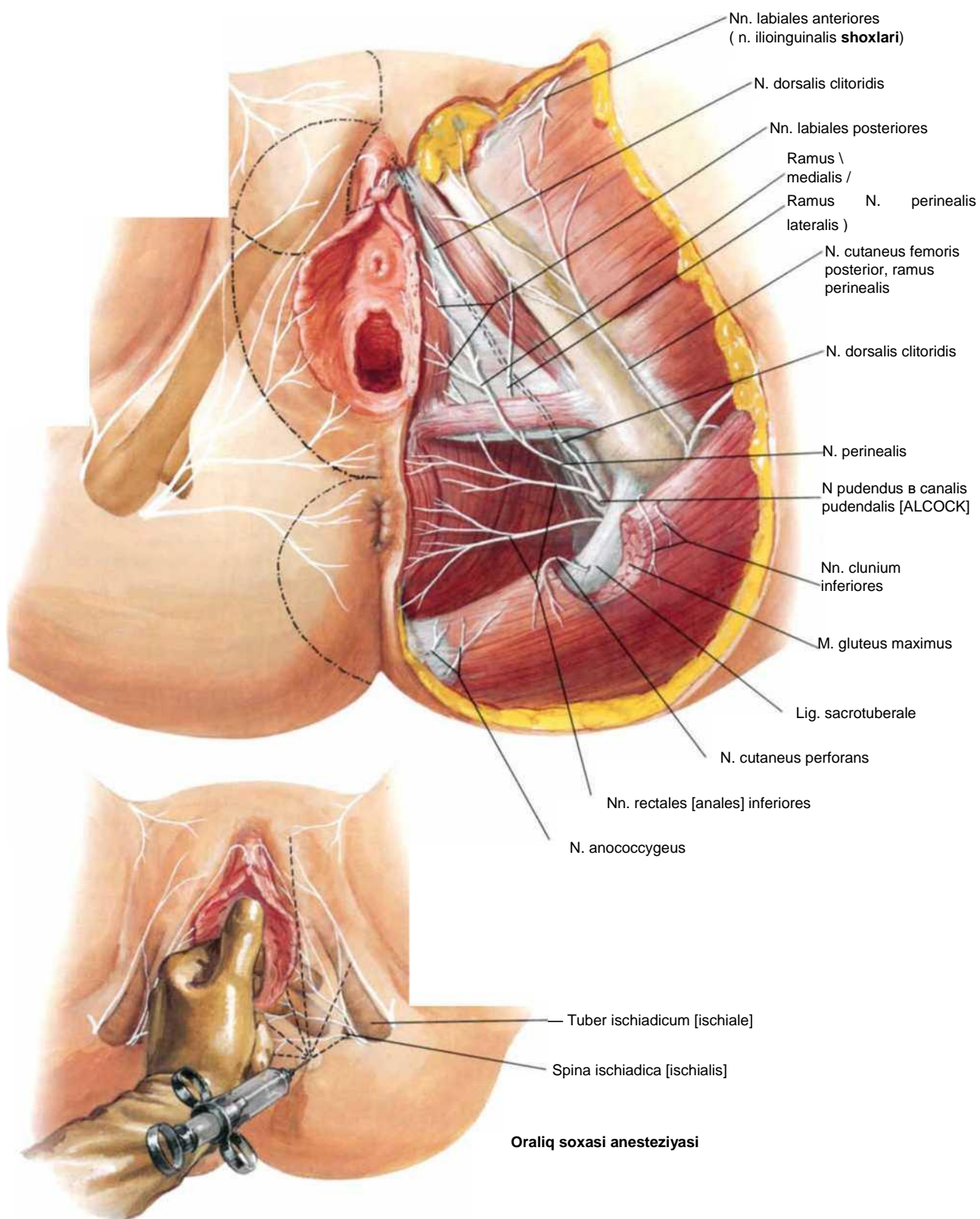
Erkaklar oraliq soxasi innervatsiyasi



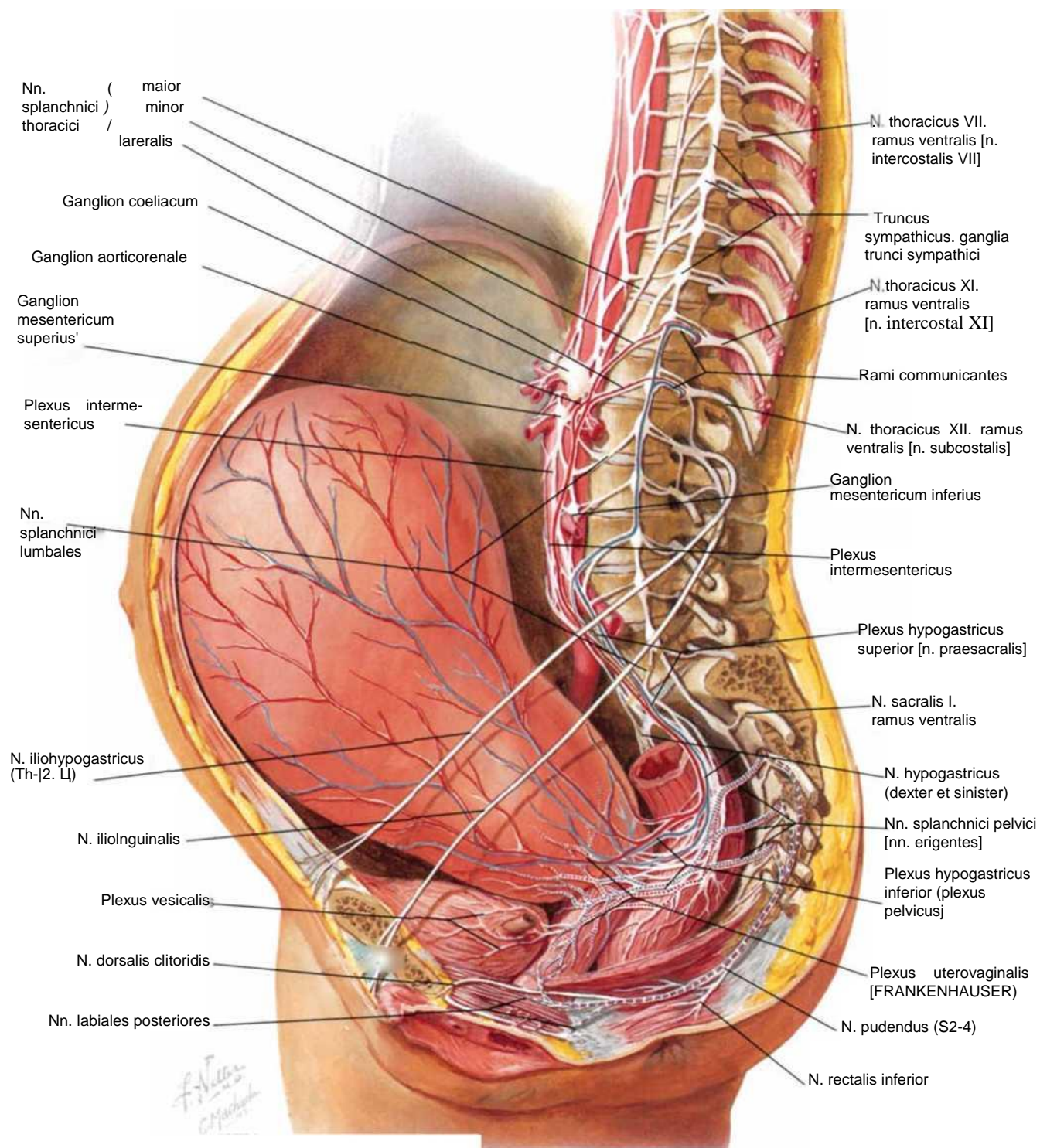
Ayolla to's soxasi a'zolari innervatsiyasi



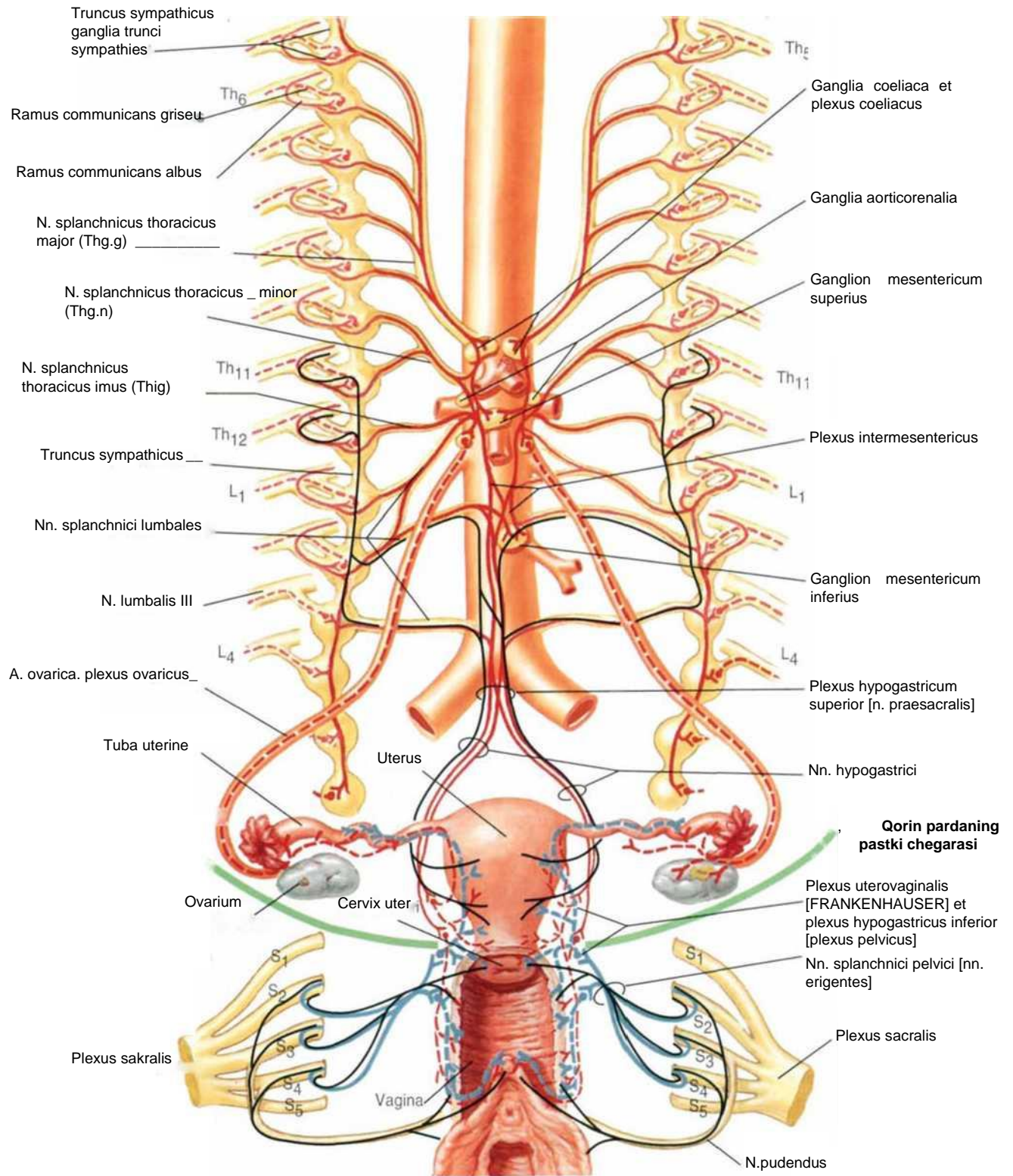
Ayollar tashqi jinsiy a'zolari innervatsiyasi



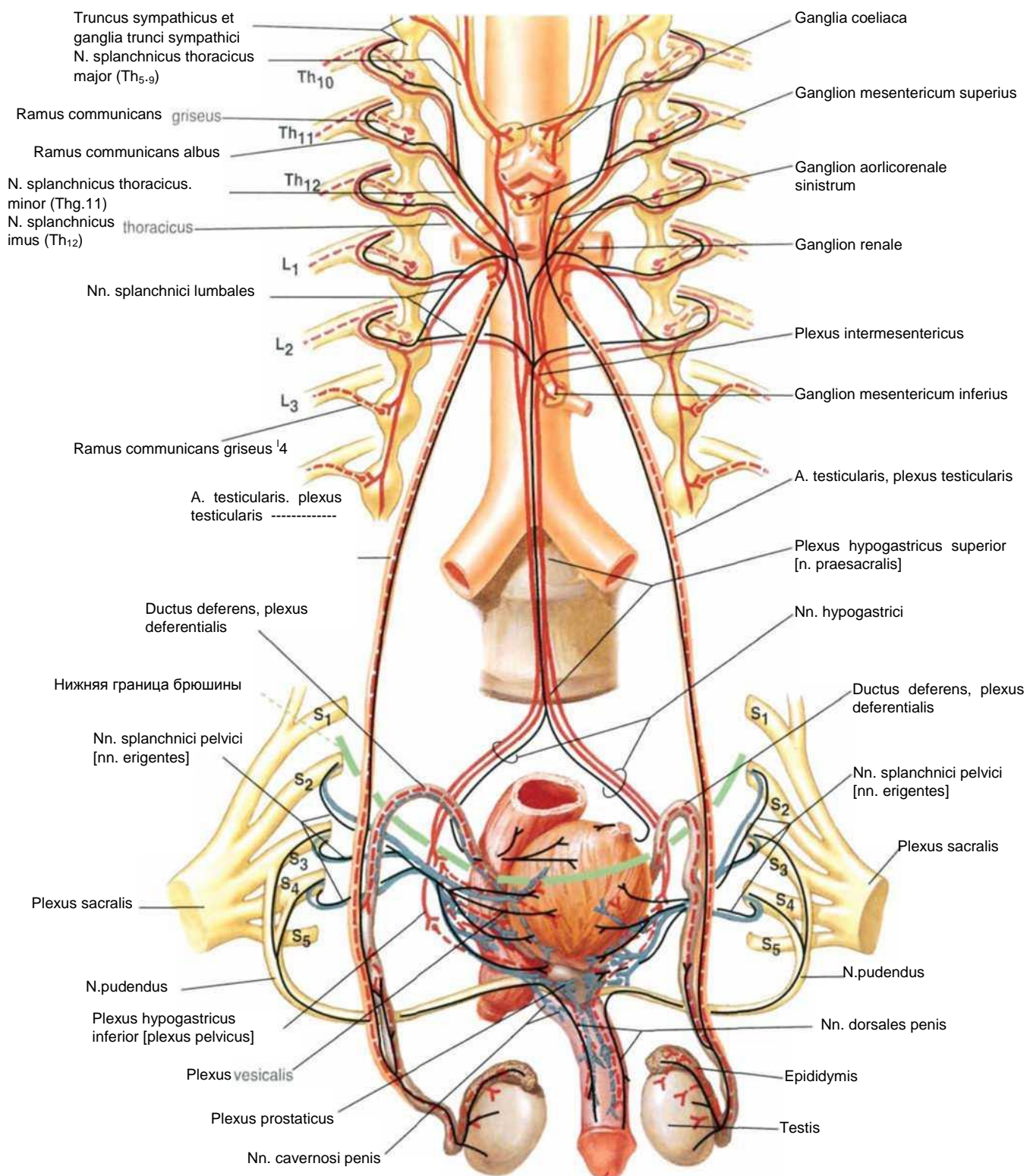
Tug'ruq jarayonida impuls o'tkazishda ishtirok etuvchi nervlar



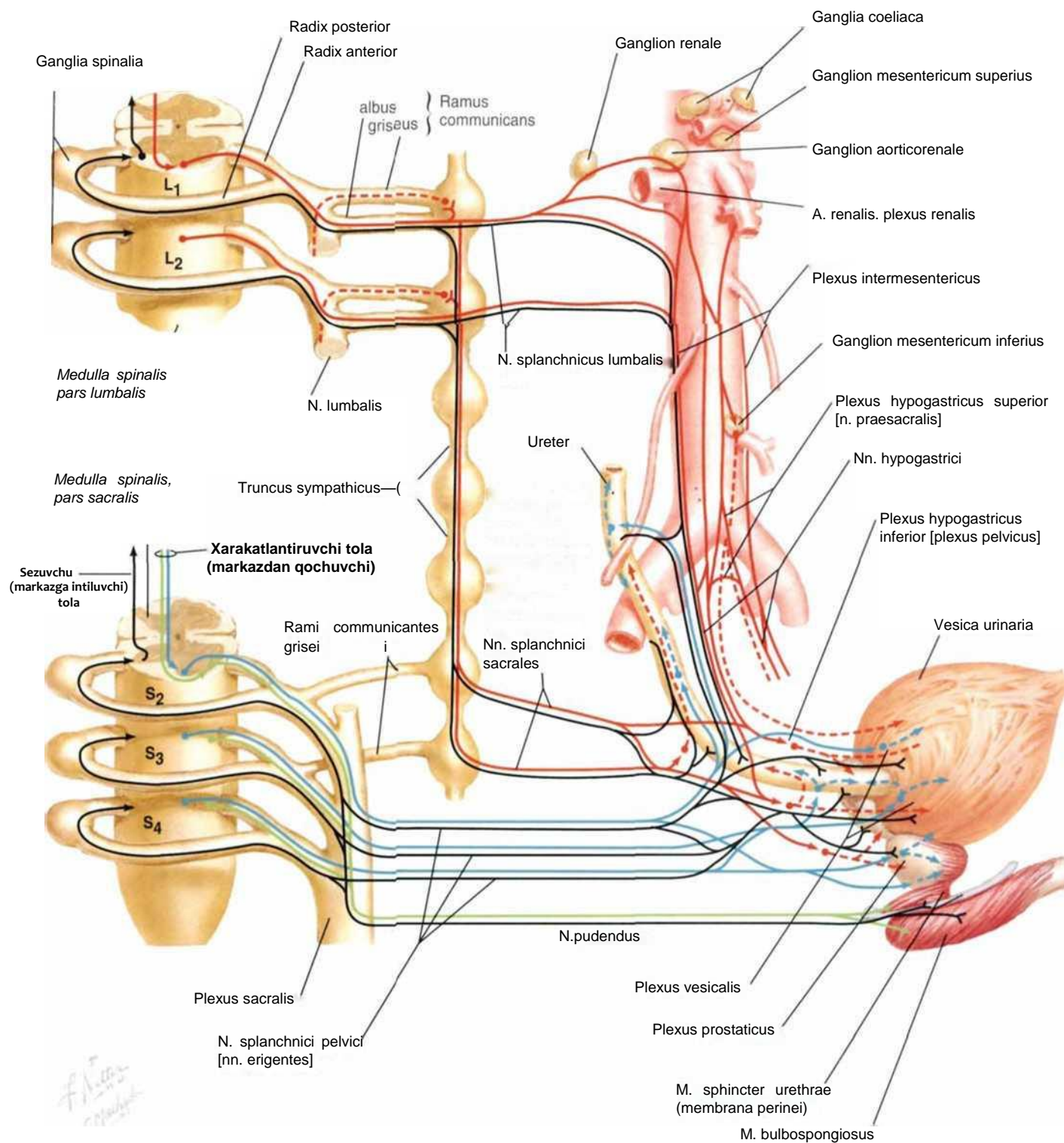
Ayollar jinsiy aʼzolari innervatsiyasi: sxemasi



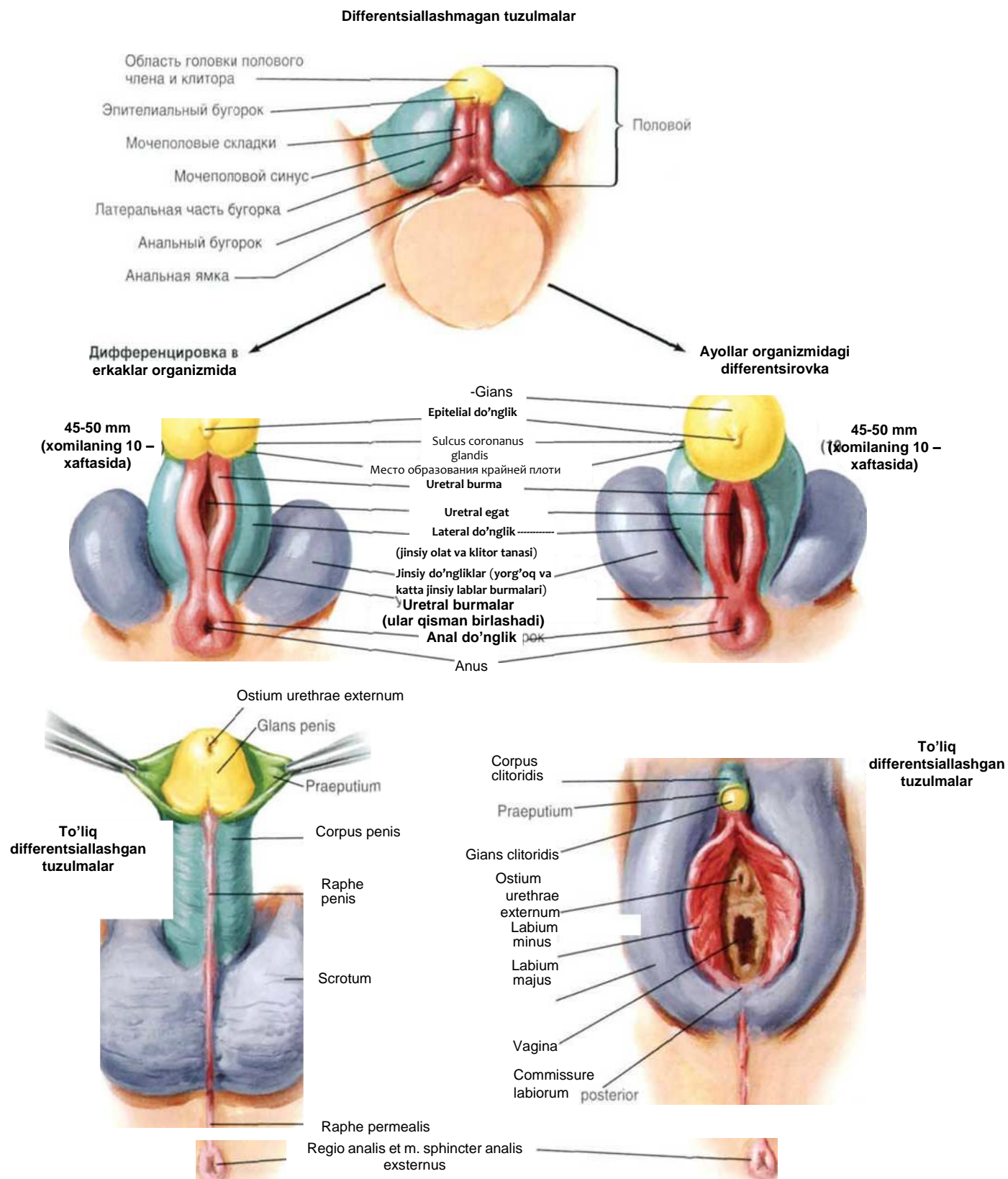
Erkadklar jinsiy a'zolari innervatsiyasi: sxemasi



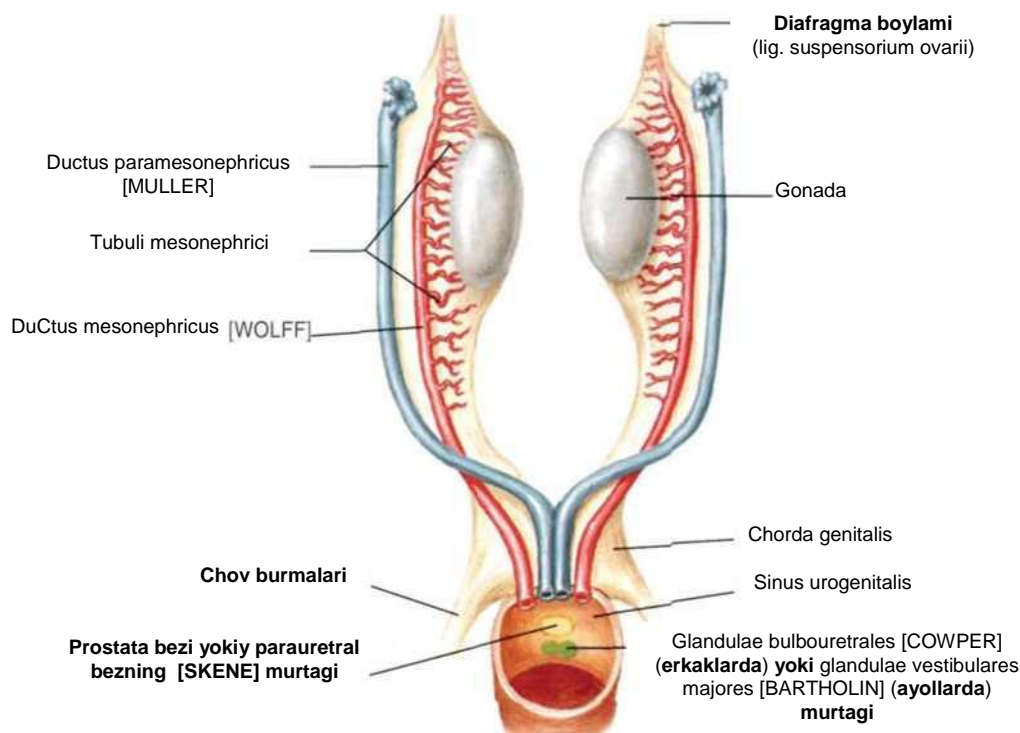
Siydik yo'li va qovuqni innervatsiyasi: sxemasi



Tashqi jinsiy a'zolarning gomologik tuzulmalari



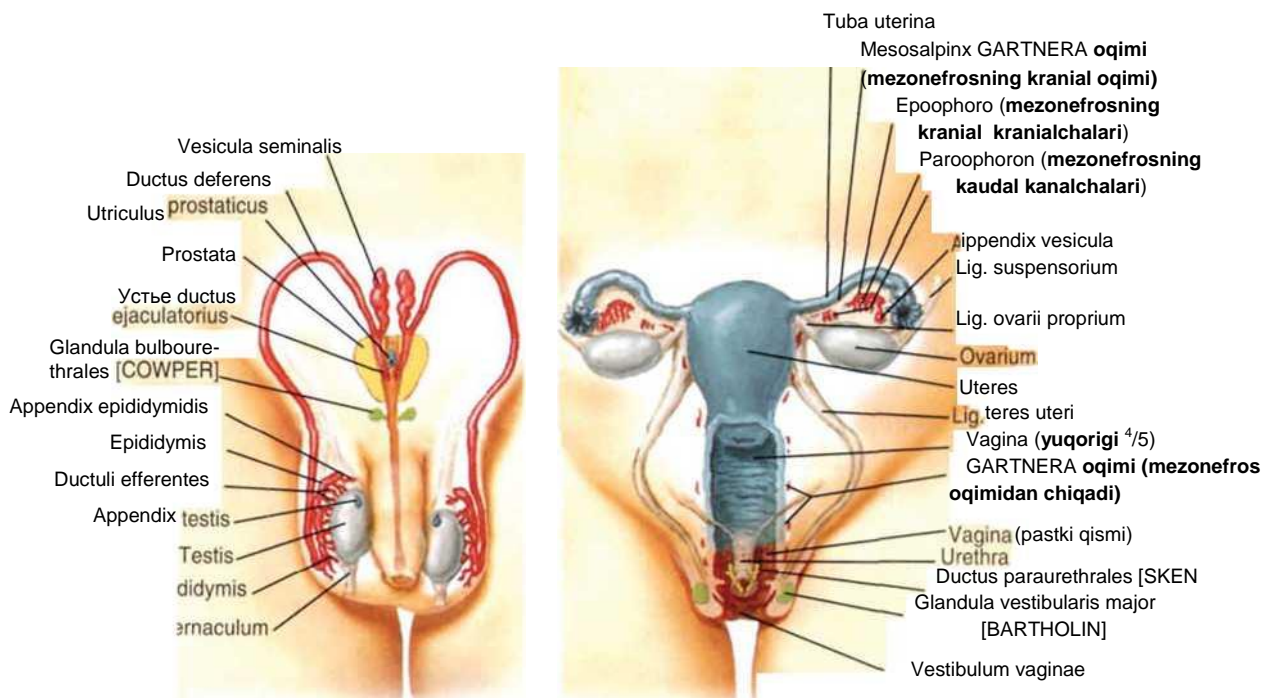
Ichki jinsiy a'zolarining gomologik tuzilmalari



Differentsiallashmagan tuzilmalar

Erkaklar organizmida differentsiallanishi

Ayollar organizmida differentsiallanishi



VI- Bo'lim

QO'L SOXASI

ANATOMIYASI

ELKA KAMARI

391-401 Rasm

391. *O'mrov (clavicula) va to'sh- o'mrov bo'gimi (art. sternoclavicularis)*
392. *Kurak (scapula) va elka suyagi (humerus): oldindan ko'rinishi*
393. *Kurak (scapula) va elka suyagi (humerus): orqadan ko'rinishi*
394. *Elka bo'g'imi (articulatio humeri)*
395. *Elka kamari muskullari*
396. *Elkani aylantiruvchi muskullar*
397. *Elka bo'g'imi muskul va boylamlari*
398. *Arteria axillaris va kurak atrofida anastamozlar*
399. *Ko'krak fastsiyasi (fascia pectoralis), to'sh-o'mrov fastsiyasi (fascia clavipectoralis) va qo'ltiq osti fastsiyasi (fascia axillaris)*
400. *Axilla: oldindan ko'rinishi*
401. *Elka chigali (plexus brachialis): sxemasi*

ELKA

402-406 Rasm

402. *Elka muskullari: oldindan ko'rinishi*
403. *Elka muskullari: orqadan ko'rinishi*
404. *Elka arteriyasi (arteria brachialis)*

405. *Elka arteriyasi (a. brachialis) va tirsak bo'g'imi atrofida anastamozlar*
406. *Elka: turli darajalarda ko'ndalang kesmasi*

BILAK SOXASI VA TIRSAK BOG'IMI

407-421 Rasm

407. *Tirsak bo'g'imi (articulatio cubiti)*
408. *Tirsak bo'gimi boylamlari*
409. *Bilak soxasi suyaklari*
410. *Bilak soxasining aloxida muskullari: bilak suyagini bruvchilar*
411. *Bilak soxasining aloxida muskullari: panja va barmoqlarni yozuvchilar*
412. *Bilak soxasining aloxida muskullari: kaft oldinini bukuvchilar*
413. *Bilak soxasining aloxida muskullari: barmoqlarni bukuvchilar*
414. *Bilak soxasi muskullari (yuza qavat): orqadan ko'rinishi*
415. *Bilak soxasi muskullari (chuqur qavat): orqadan ko'rinishi*
416. *Bilak soxasi muskullari (yuza qavat): oldindan ko'rinishi*
417. *Bilak soxasi muskullari (o'rta qavat): oldindan ko'rinishi*

418. *Bilak soxasi muskullari (chuqur qavat): oldindan ko'rinishi*
419. *Bilak soxasi: turli darajalarda ko'ndalang kesmasi*
420. *Bilak soxasi muskullarini boshlanishi va birikishi: oldindan ko'rinishi*
421. *Bilak soxasi muskullari birikishi: orqadan ko'rinishi*

PANJA

422-440 Rasm

422. *Kaft oldi suyaklari (ossa carpi)*
423. *Kaft oldini xarakati*
424. *Kaft oldini boylamlari*
425. *Kaft oldibi boylamlari (davomi)*
426. *Panja suyaklari*
427. *Kaft va falangalararo boylamlar*
428. *Kaftni ichki yuzasi: yuza qavatlarni ko'rinishi*
429. *Kaftni ichki yuzasi: chuqur tuzulmalari*
430. *Panjaning bukuvchi muskullari paylari, arteriyalari va nervlari*
431. *Sinovial qin (vagina synoviales) va panja paylari*
432. *Chuvalchangsimon muskul (musculi lumbricales), bo'shliq va sinovial qin: sxema*
433. *Barmoqlarni bukuvchilari va yozuvchilarining paylari*

434. *Kaftning chuqur muskullari*
435. *Panjaning arteriya va nervlar: ichki yuzasi*
436. *Panja: bilak tarafi*
437. *Panja: orqa tarafi*
438. *Panja: chuqur tuzulmalari*
439. *Panjaning orqa tarafidagi yozuvchilarning paylari*
440. *Barmoqlar (digiti)*

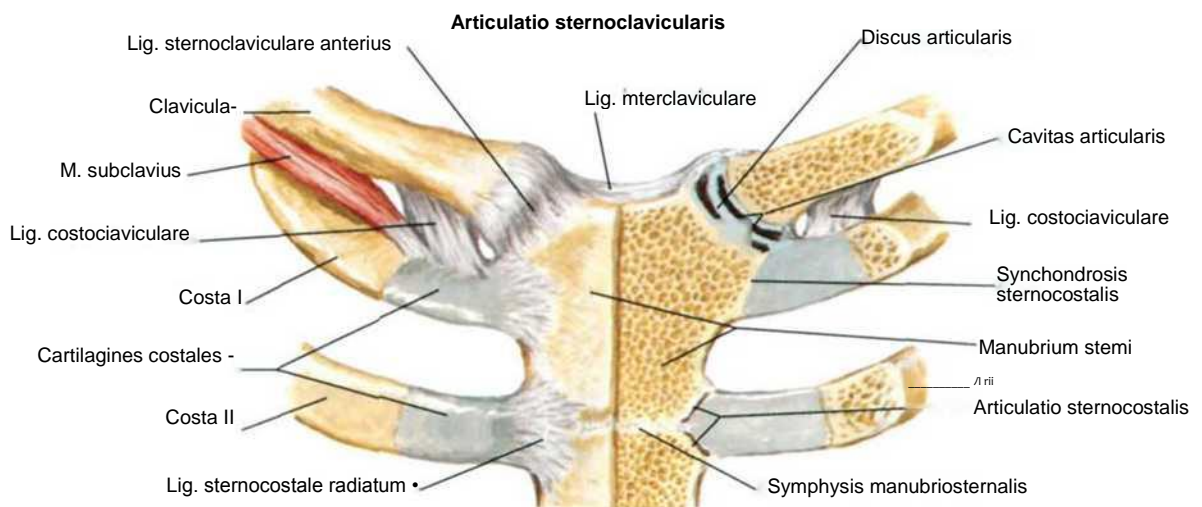
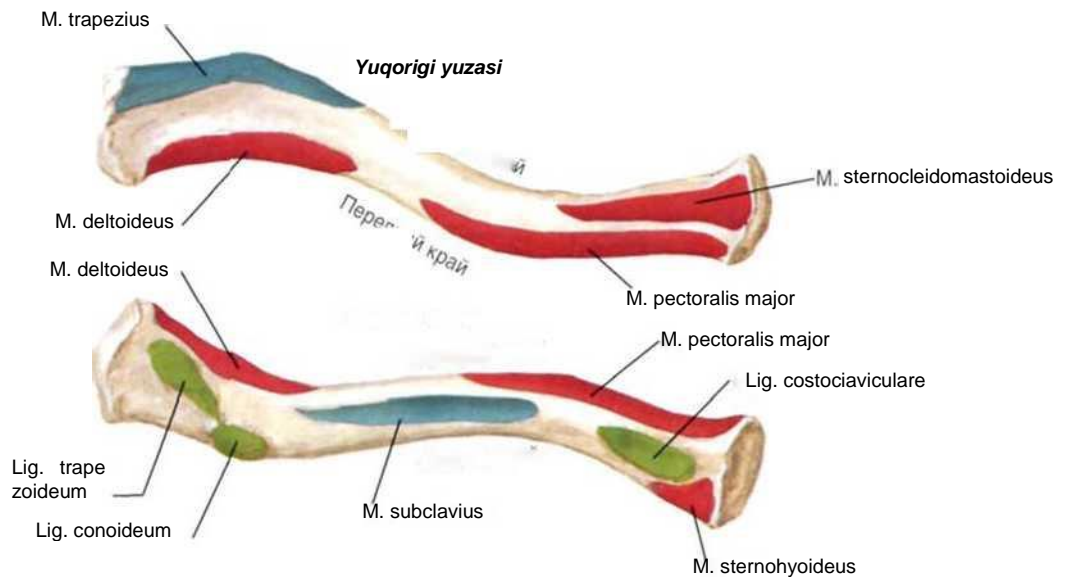
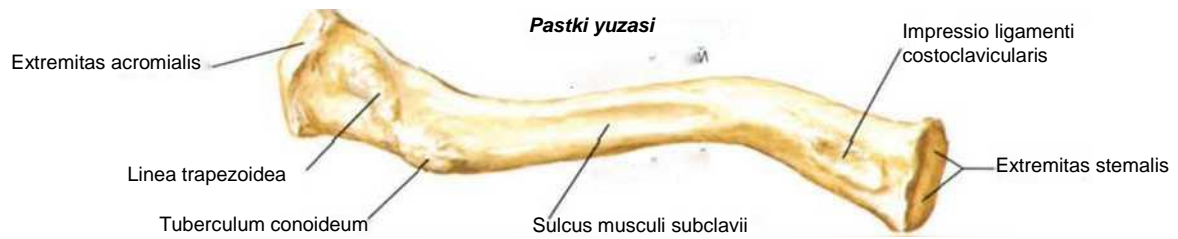
QON BILAN TA`MINLANISHI VA INNERVATSIYASI

441-452 Rasm

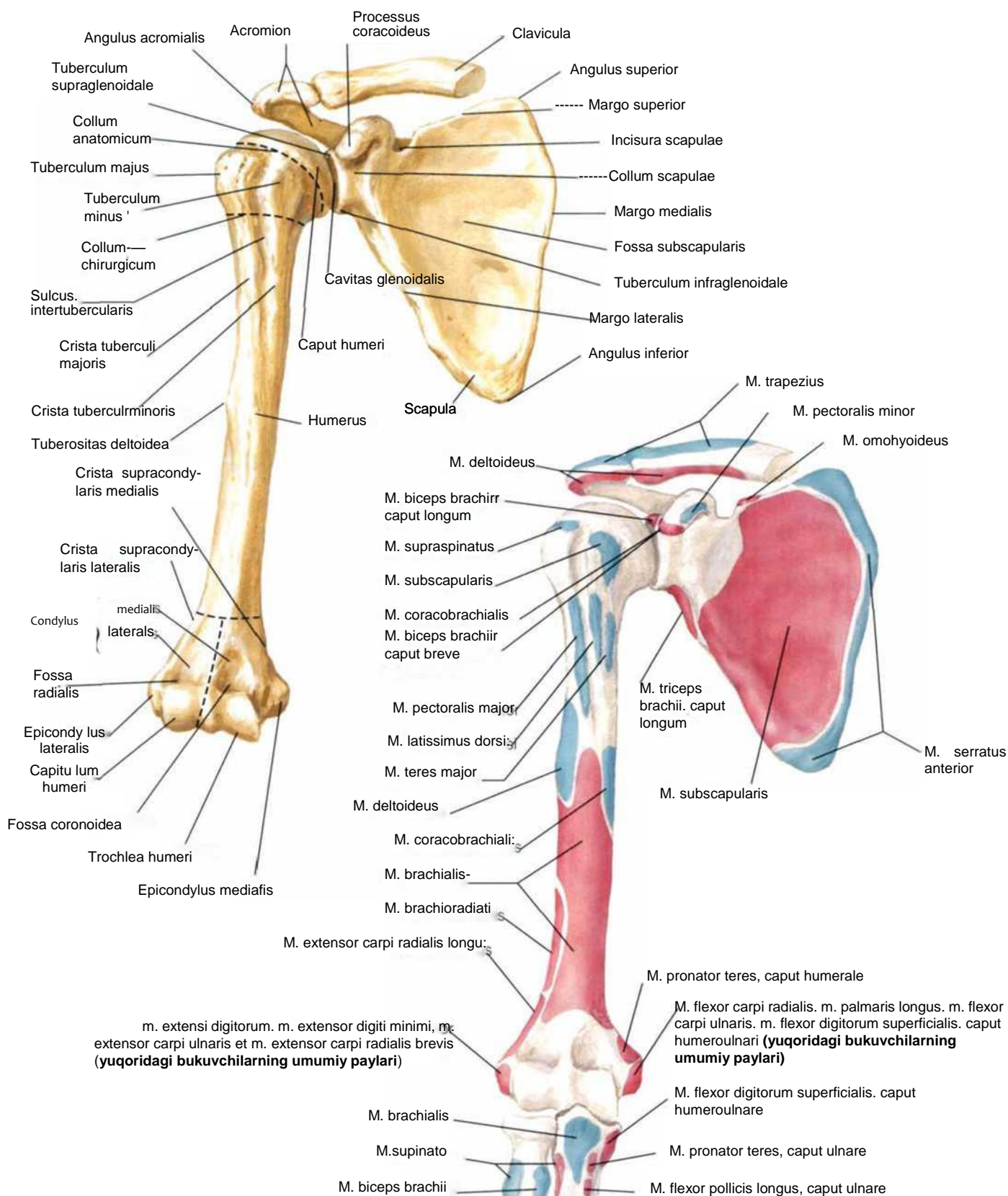
441. *Panja terisi innervatsiyasi*
442. *Qo'l soxasi arteriya va venalari*
443. *Muscul- teri nervi (n. musculocu- taneus)*
444. *O'rta nerv (n. medianus)*
445. *Tirsak nervi (n. ulnaris)*
446. *Elka kamari va elkaning orqa guruhi muskullari innervatsiyasi*
447. *Bilak nervi (n. radialis): panja va bilak soxasi innervatsiyasi*
448. *Elkaning teri nervlari va teri osti venalari*
449. *Bilak soxasi va panjaning teri nervlari va teri osti venalari*
450. *Qo'l soxasi terisining innervatsiyasi*
451. *Qo'l soxasining dermatomlari*
452. *Qo'l soxasining limfatik tomirlari va tugunlari*

O'mrov va to'sh-o'mrov bo'g'imi

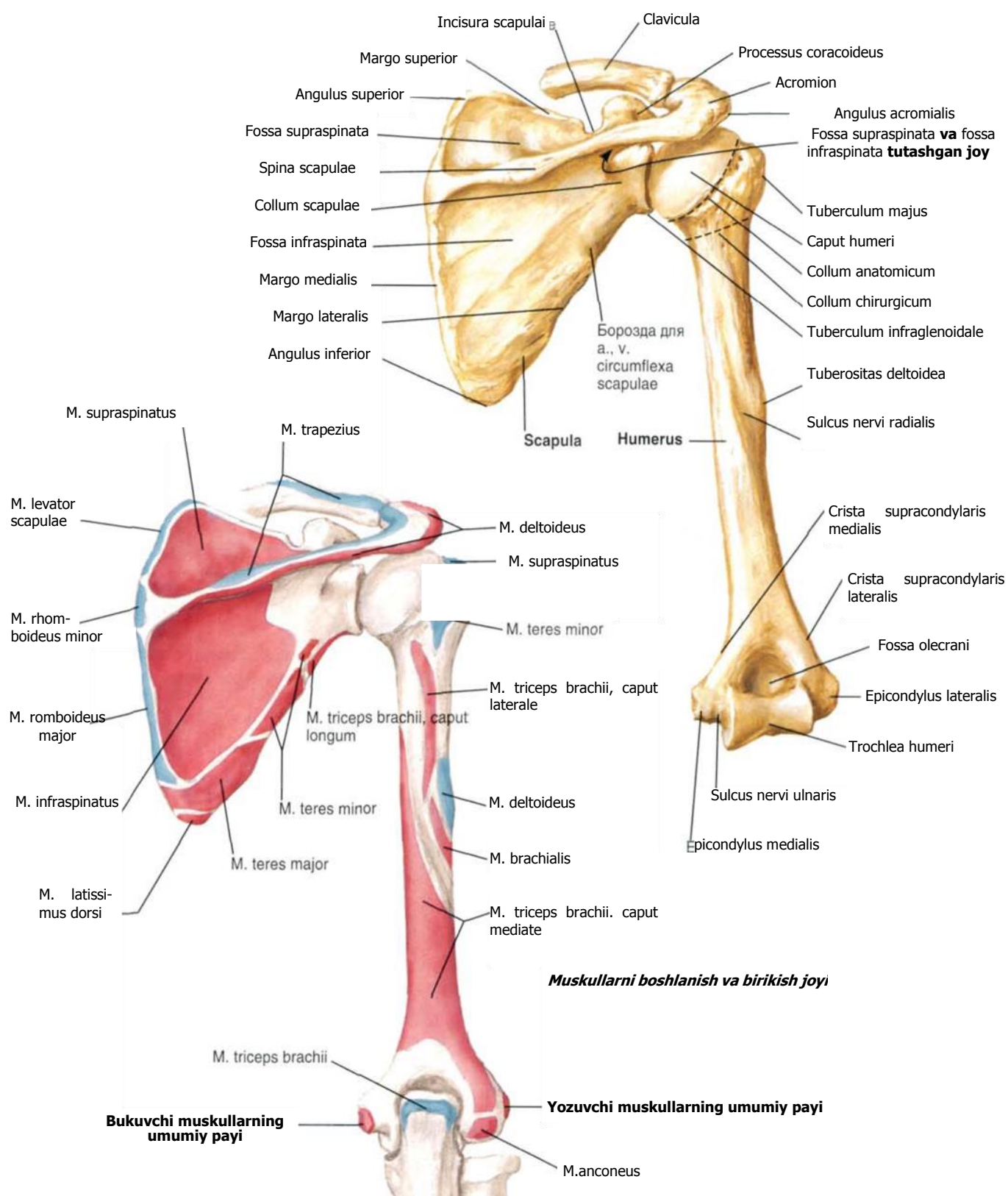
O'ng omrov



Kurak (scapula) va elka suyagi (humerus): oldindan ko'rinishi

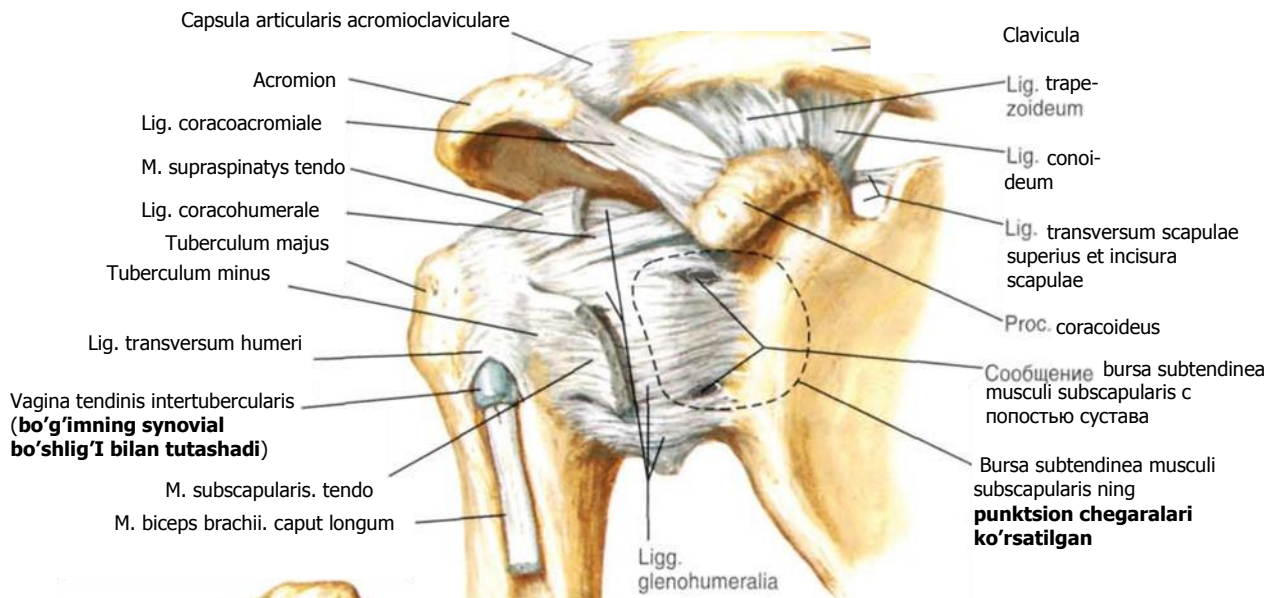


Kurak (scapula) va elka suyagi (humerus): orqadan ko'rinishi

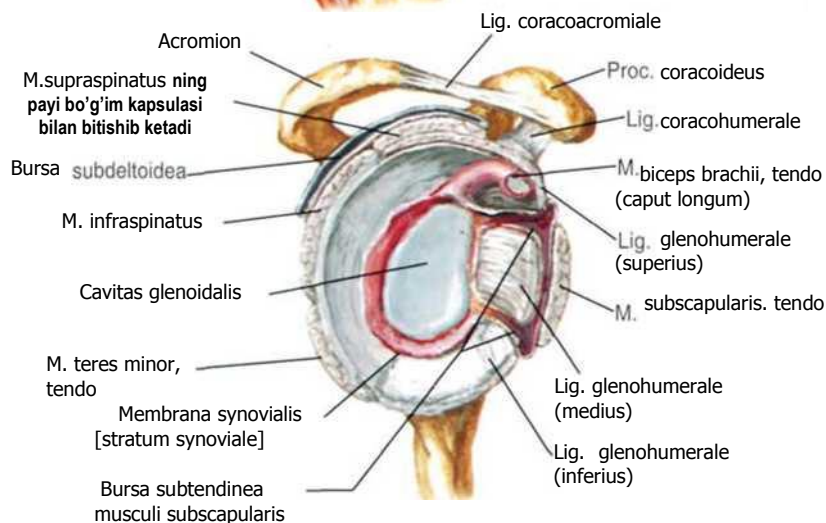
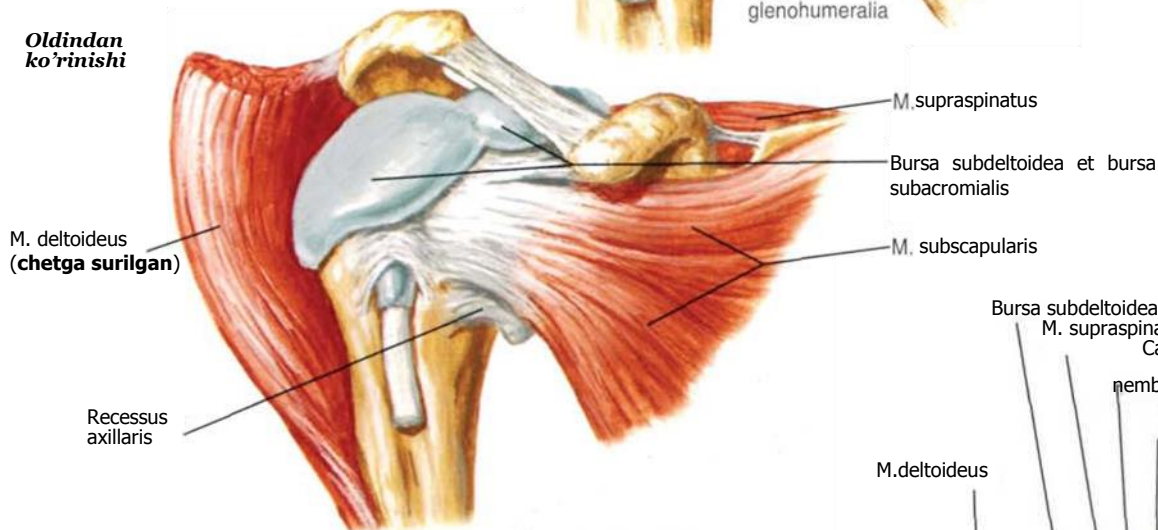


Elka bo'g'imi (articulatio humeri)

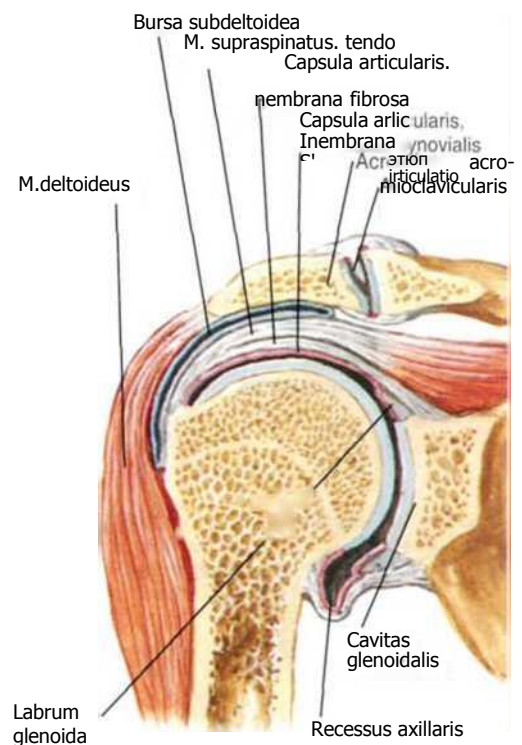
Oldindan ko'rinishi



Oldindan ko'rinishi



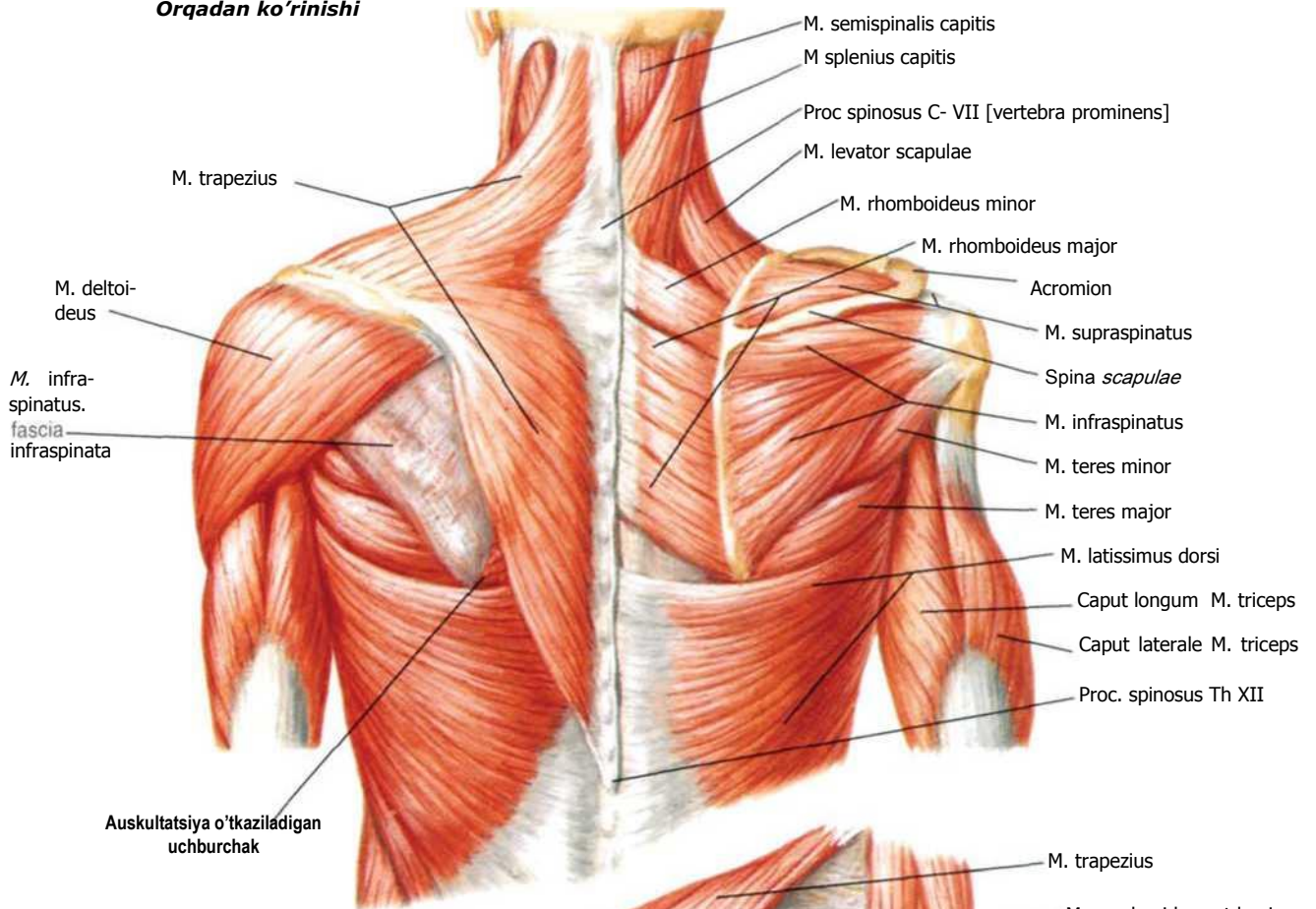
Bo'g'im ochilgan, yon tarafdin ko'rinishi



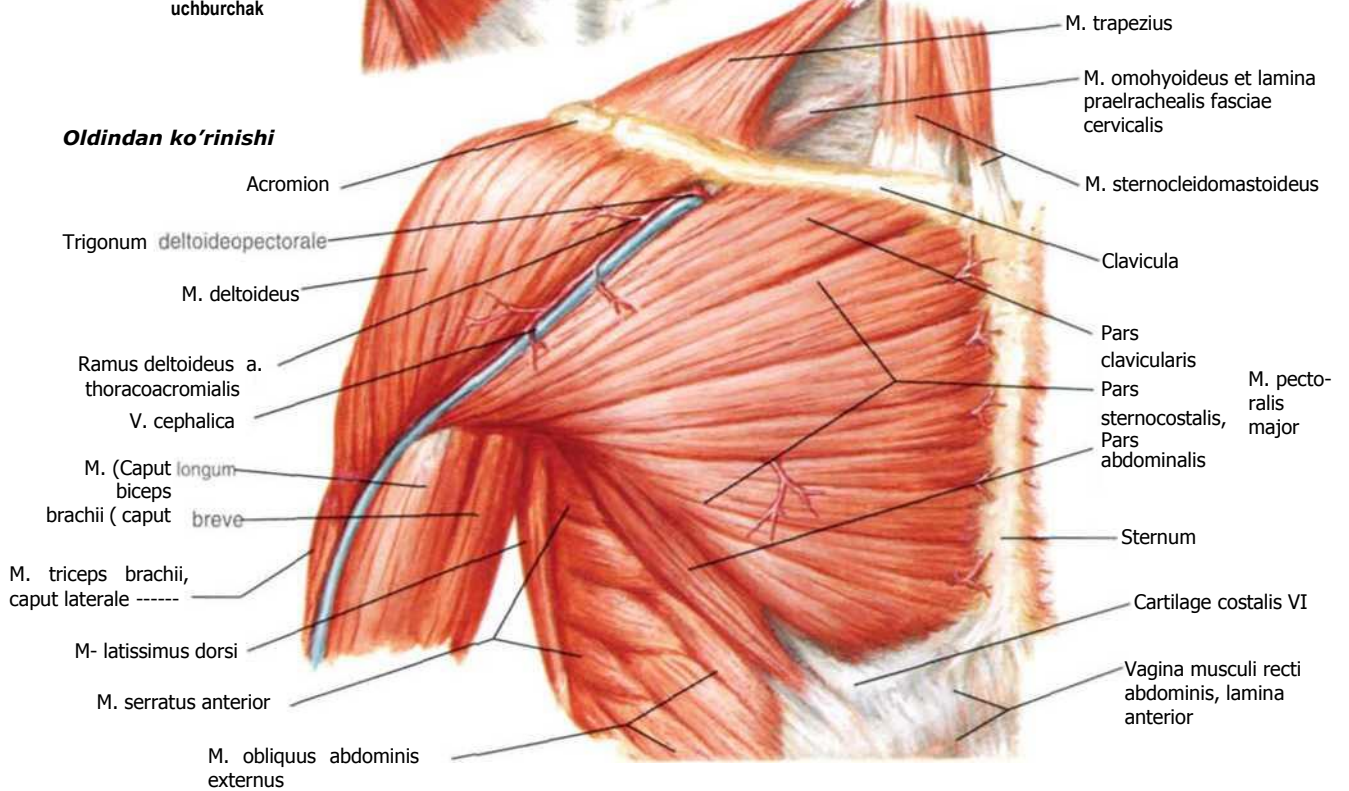
Frontal yuza bo'ylab o'tgan kesma

Elka kamari muskullari

Orqadan ko'rinishi

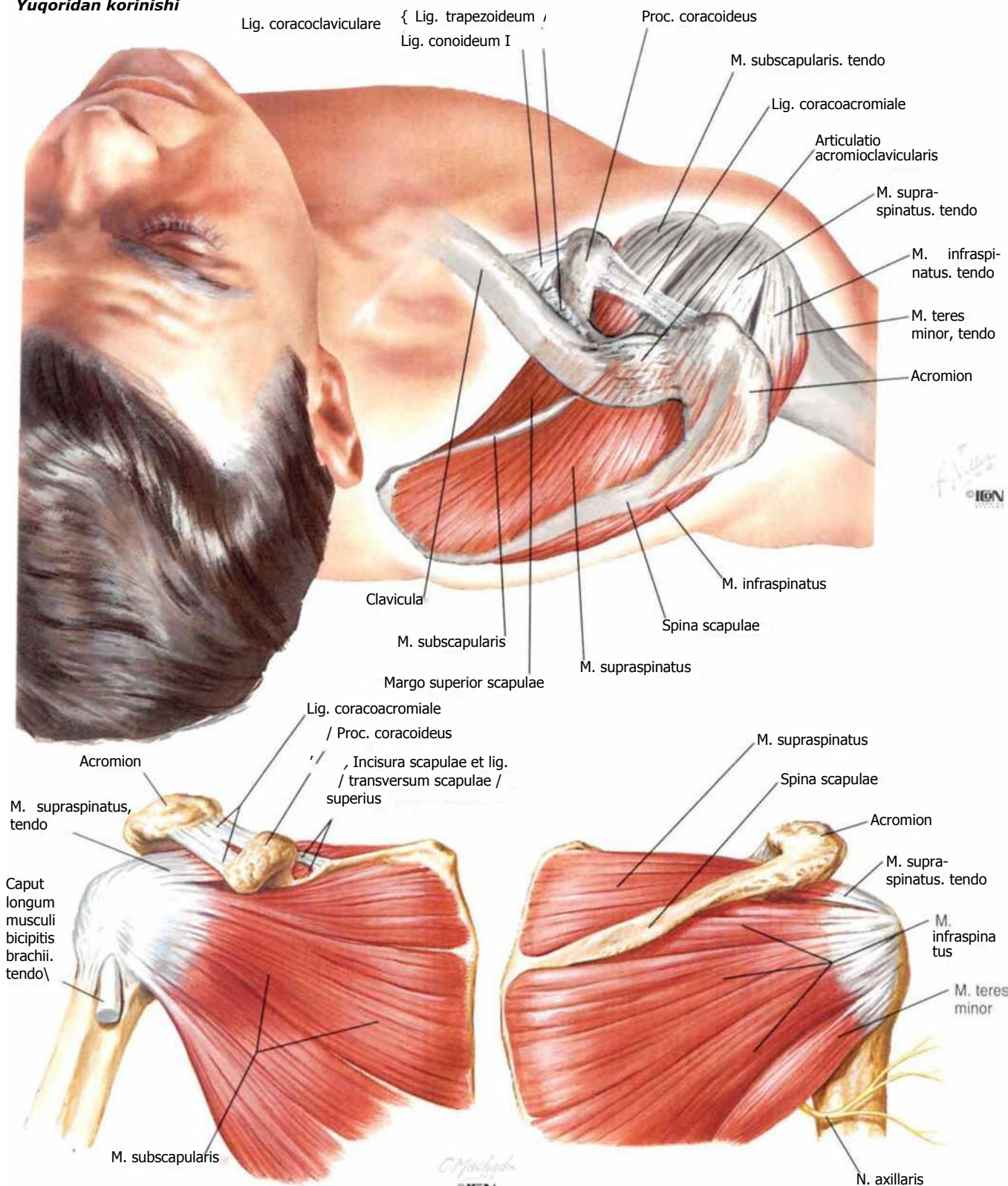


Oldindan ko'rinishi



Elkaning buruvchi muskullari

Yuqoridan korinishi

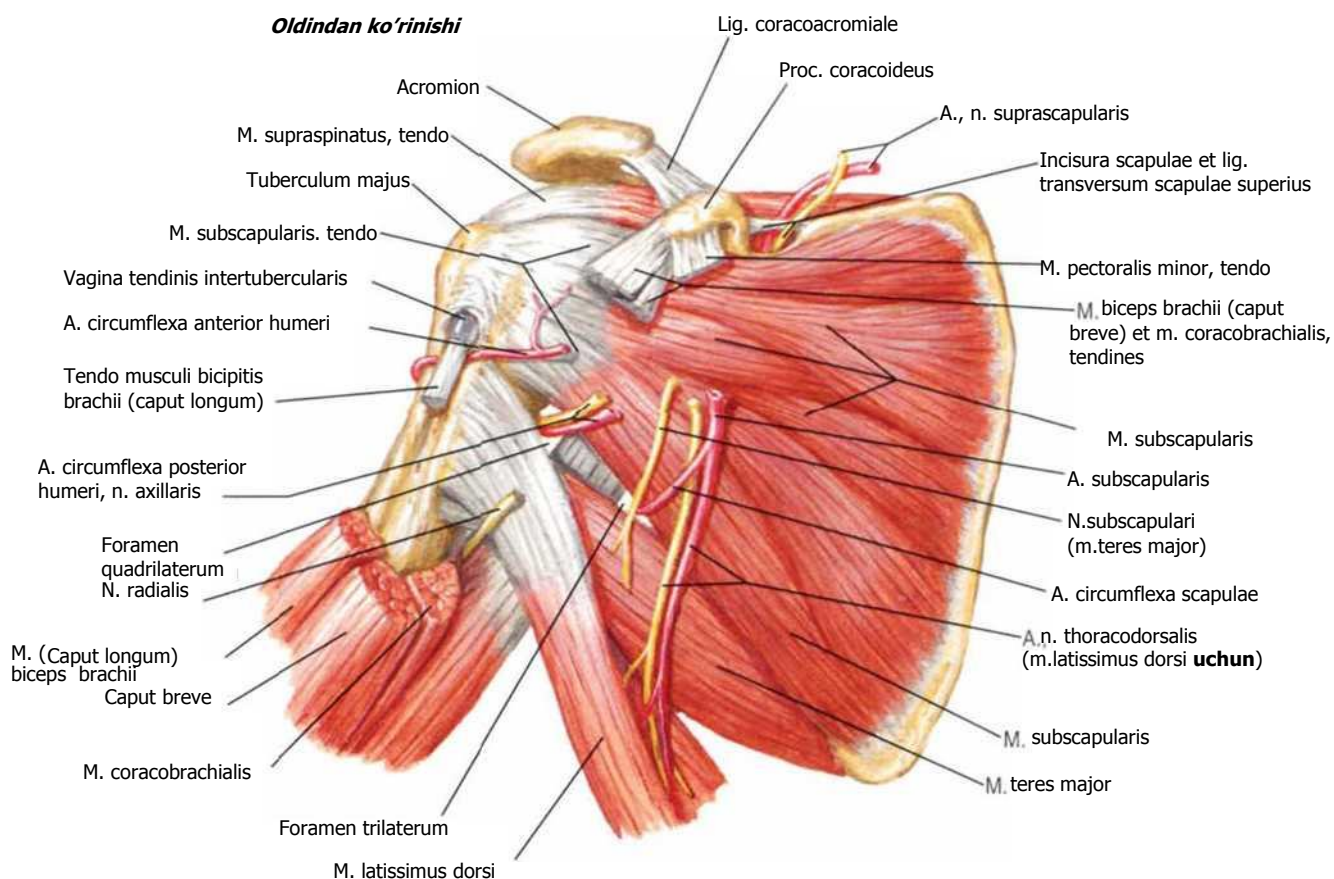


Oldindan ko'rinishi

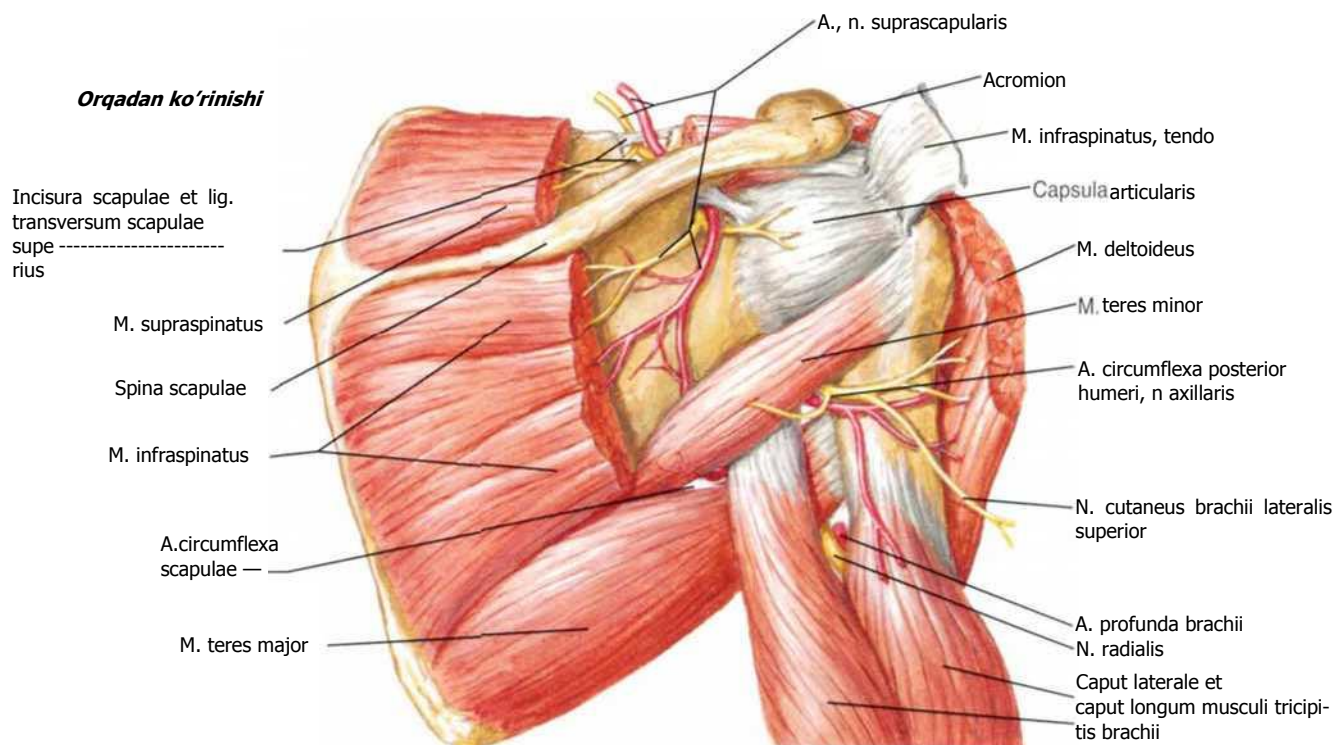
Orqadan ko'rinishi

Elka bo'g'mining mushak va boylamlari

Oldindan ko'rinishi

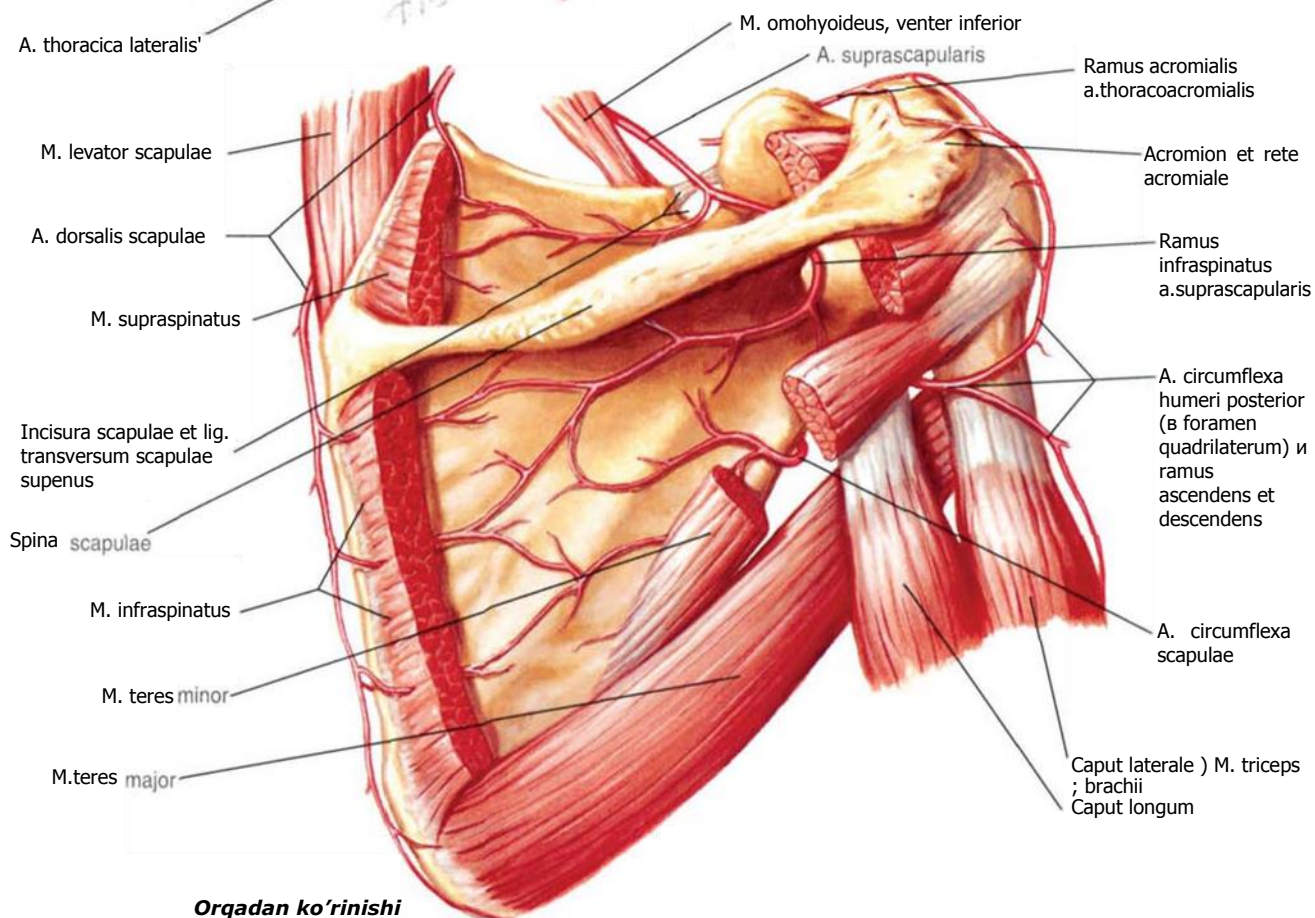
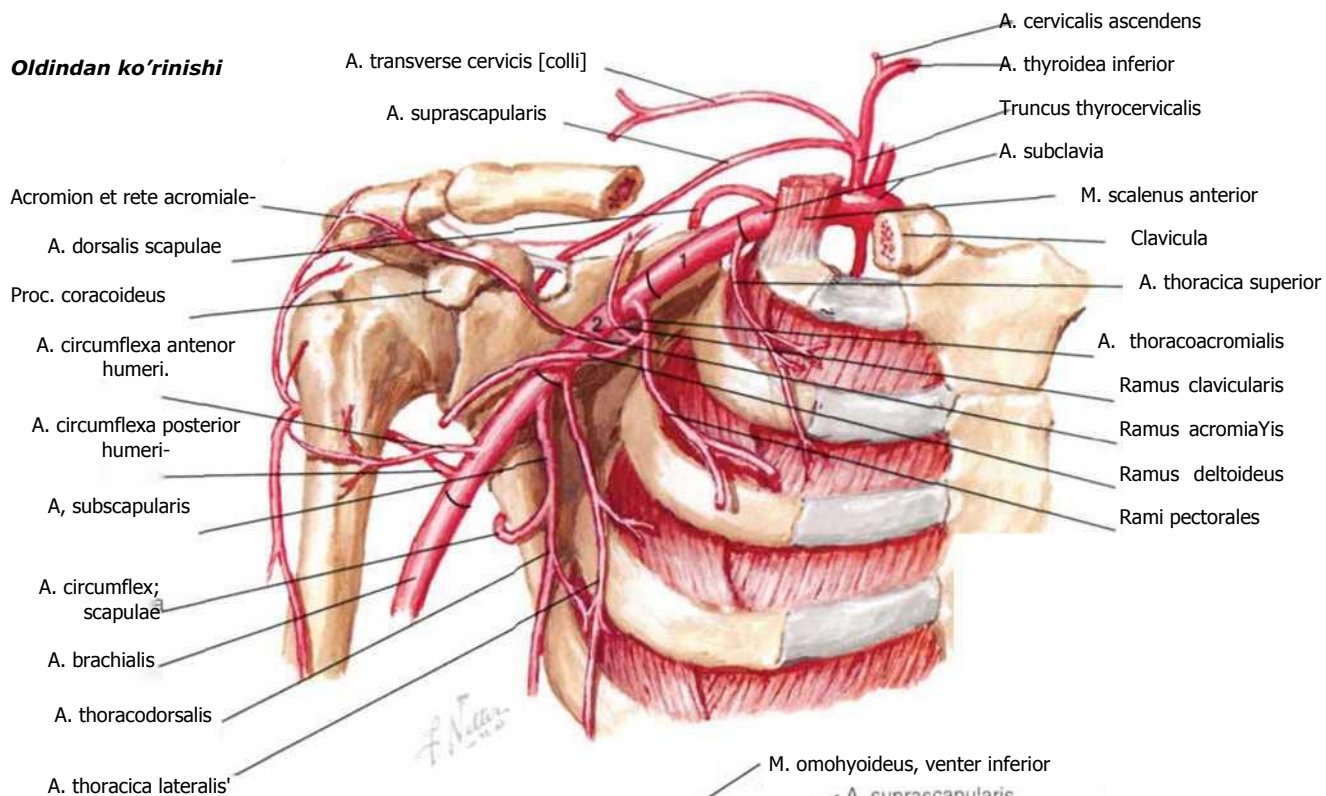


Orqadan ko'rinishi



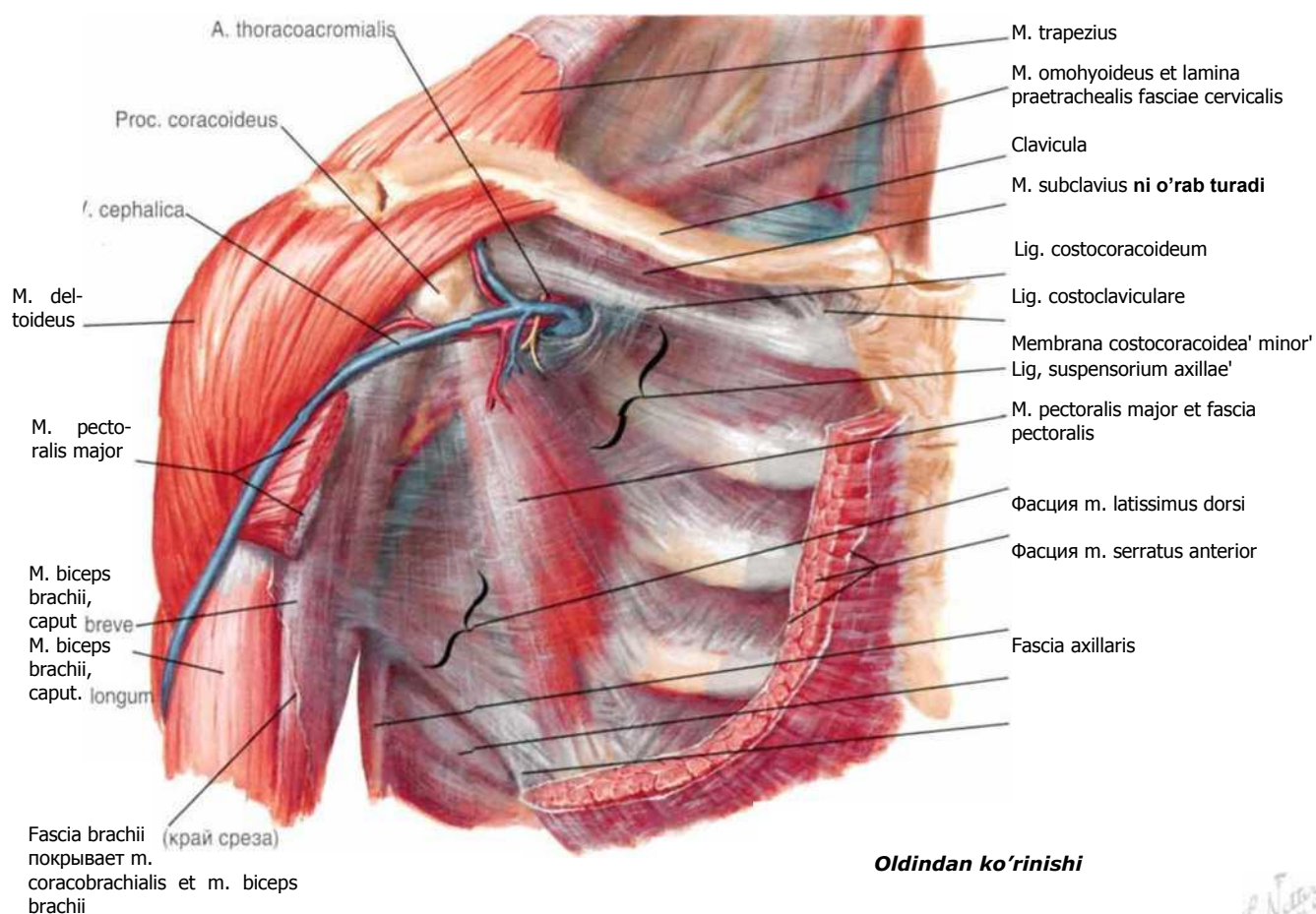
Arteria axillaris va kurak atrofidagi anastamozlar

Oldindan ko'rinishi

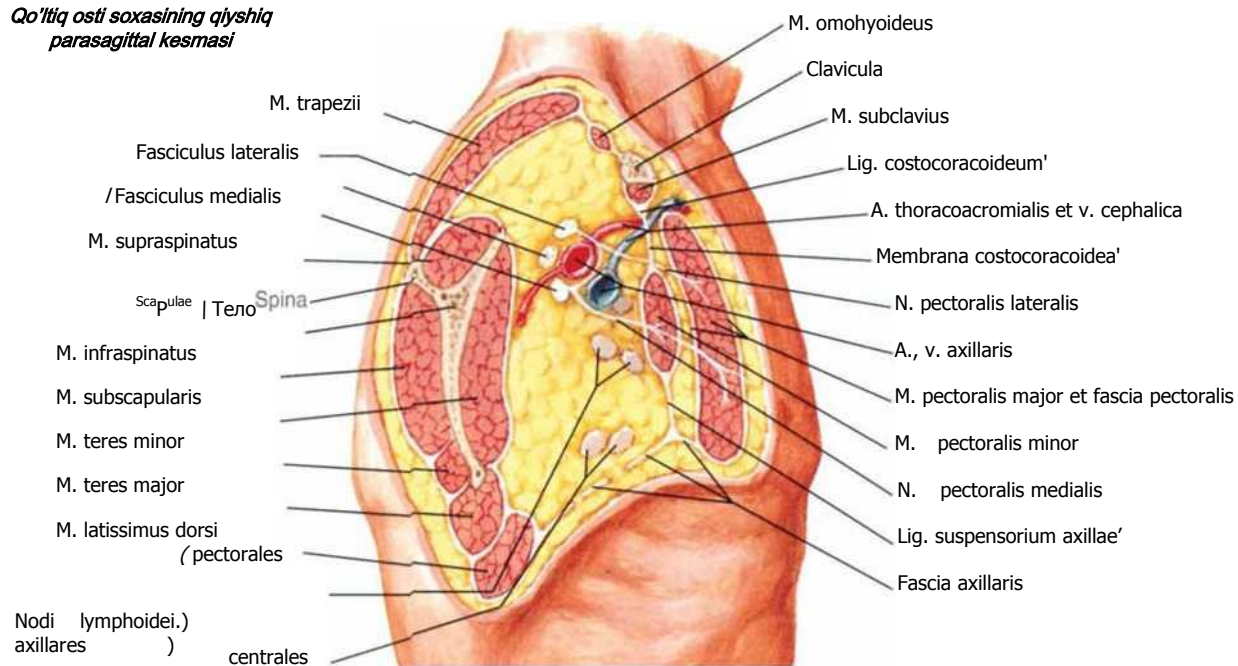


Orqadan ko'rinishi

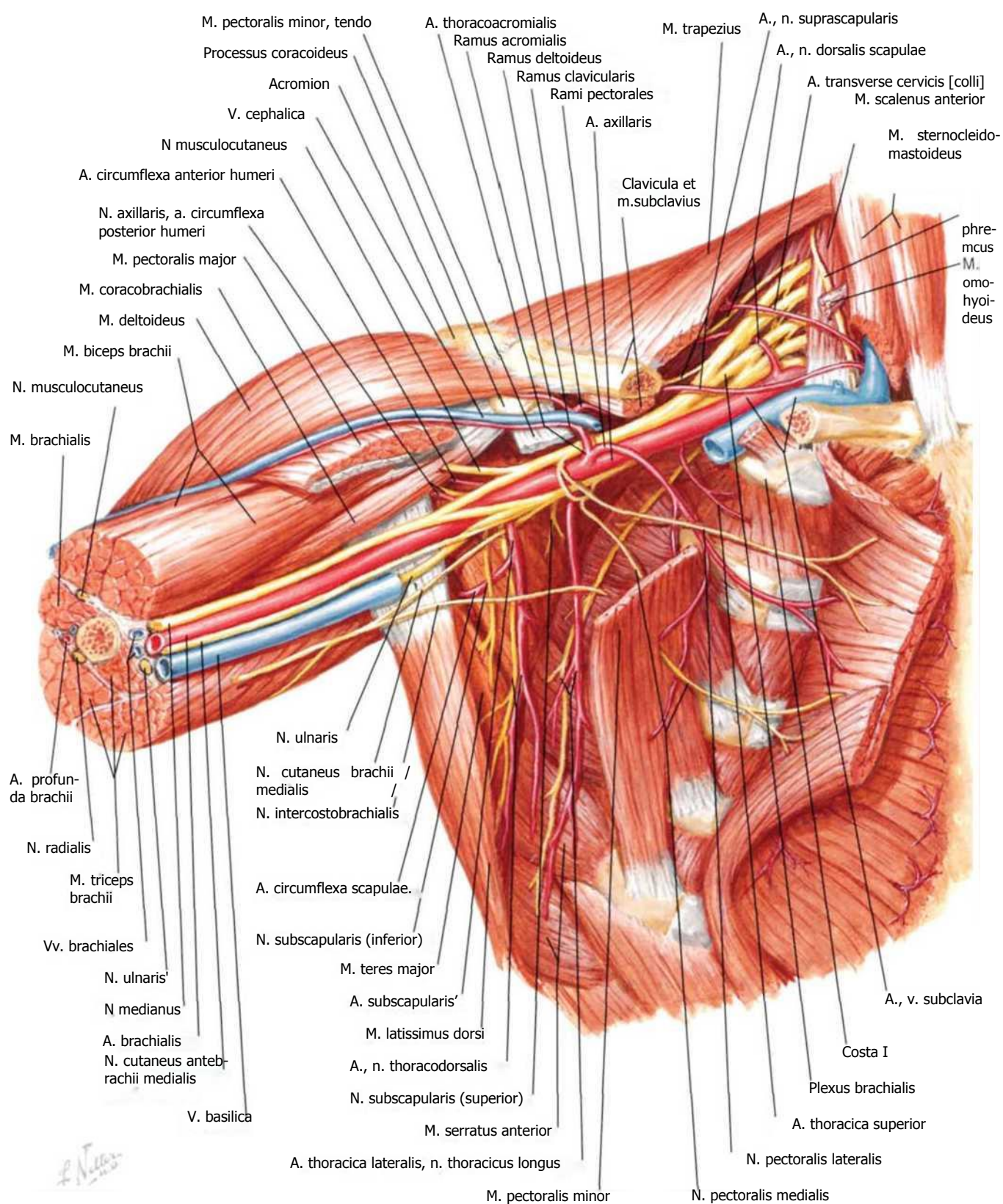
Ko'krak, to'sh-o'mrov va qo'l'tiq osti fastsialari



Qo'l'tiq osti soxasining qiyshiq parasagittal kesmasi

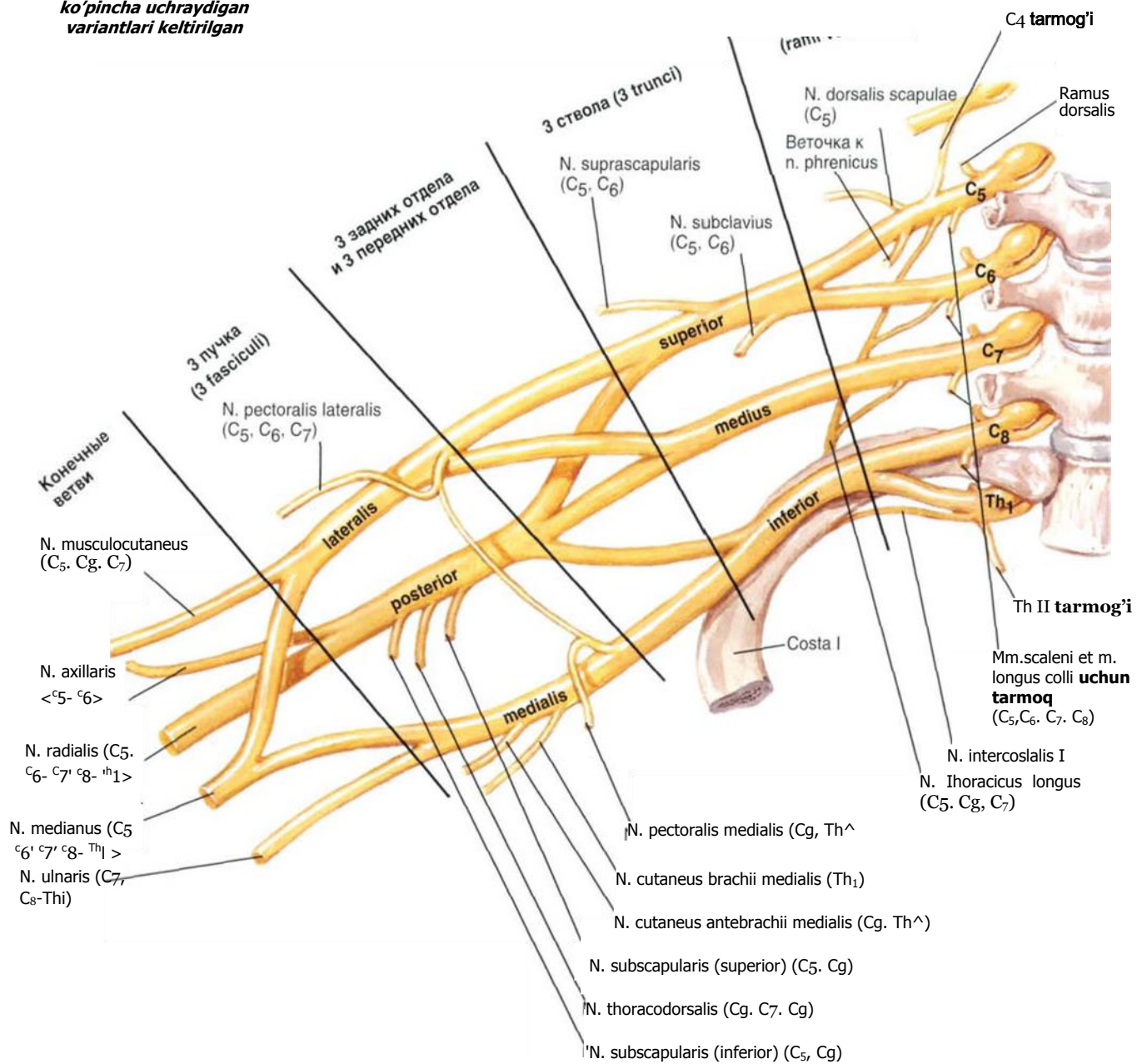


Axilla: oldindan ko'rinishi

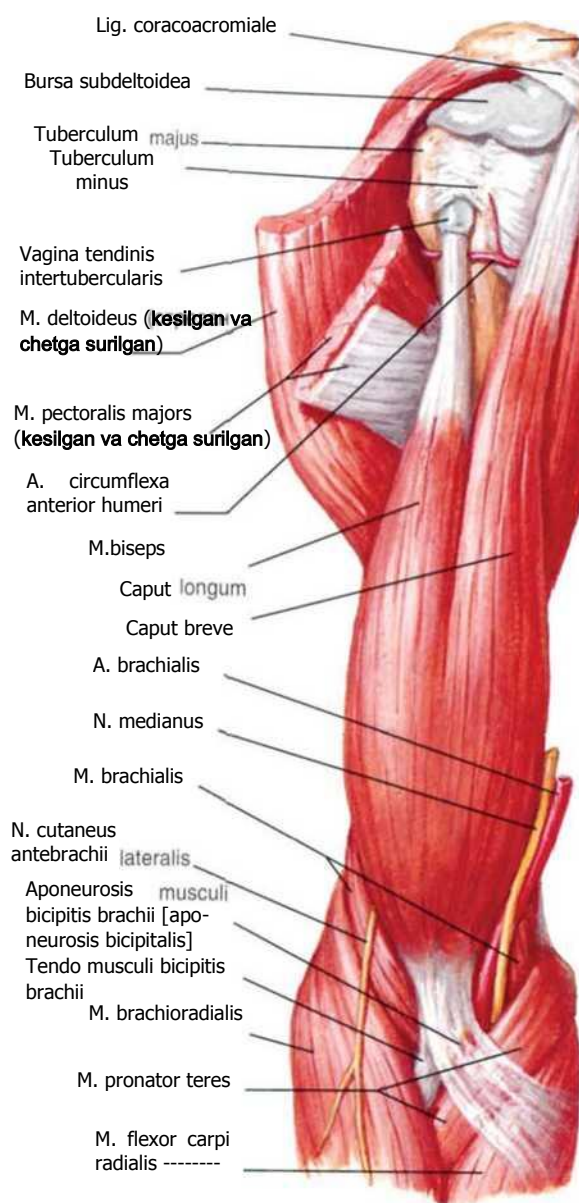


Elka chigali (plexus brachialis): sxemasi

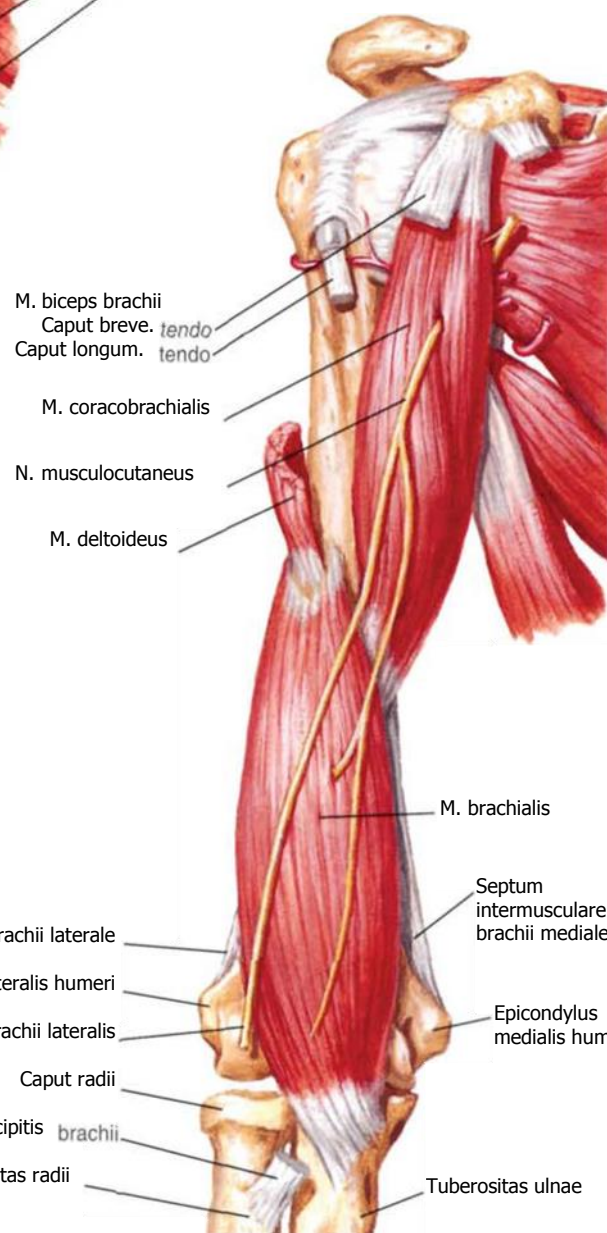
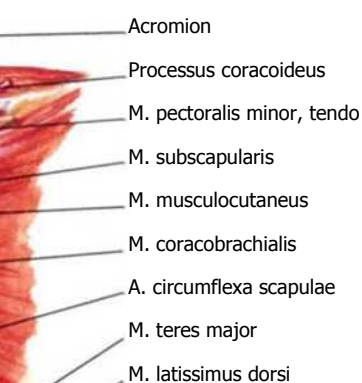
**Sxemada tarmoqlanishning
ko'pincha uchraydigan
variantlari keltirilgan**



Elka muskullari: oldindan ko'rinishi

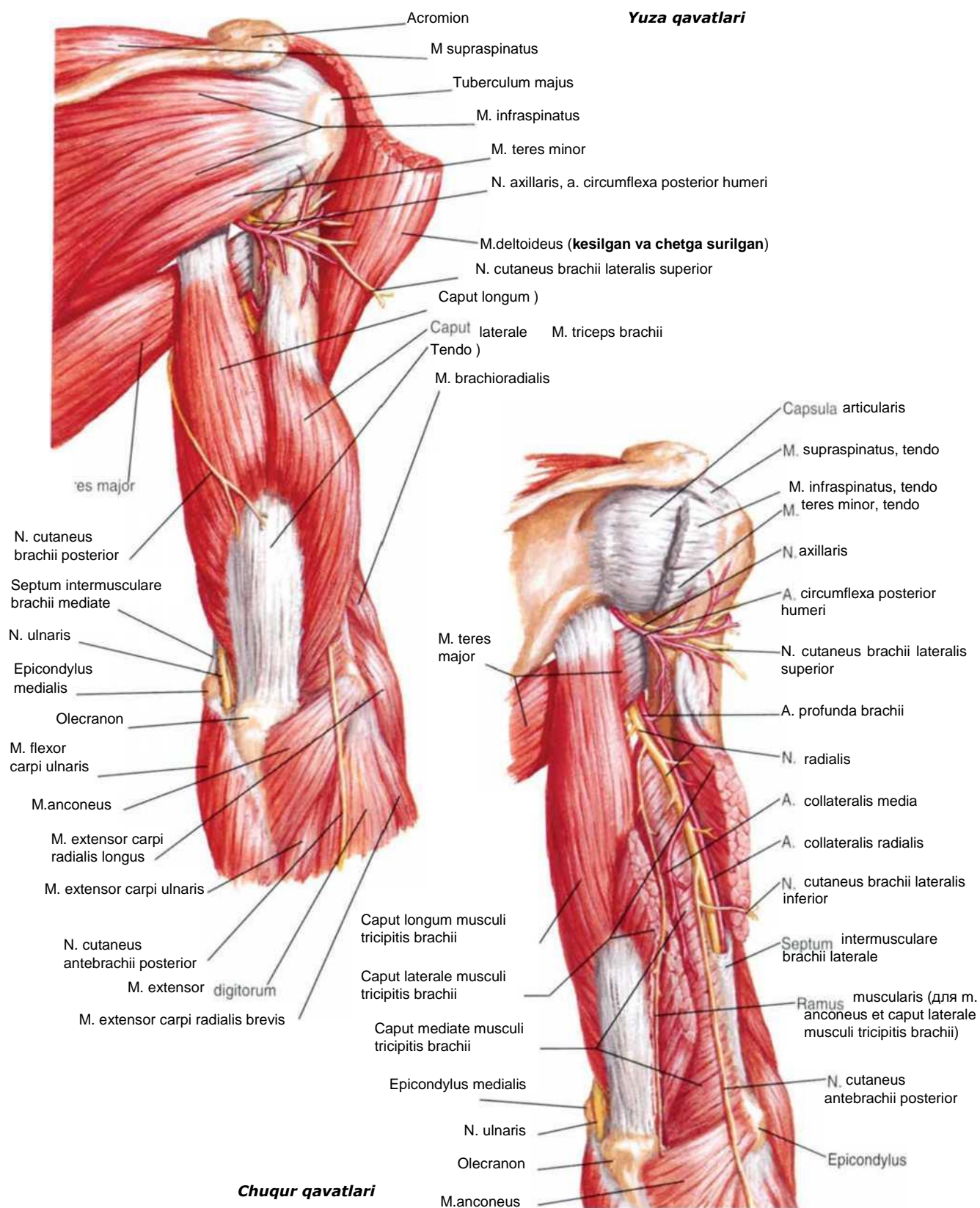


Yuza qavatlar

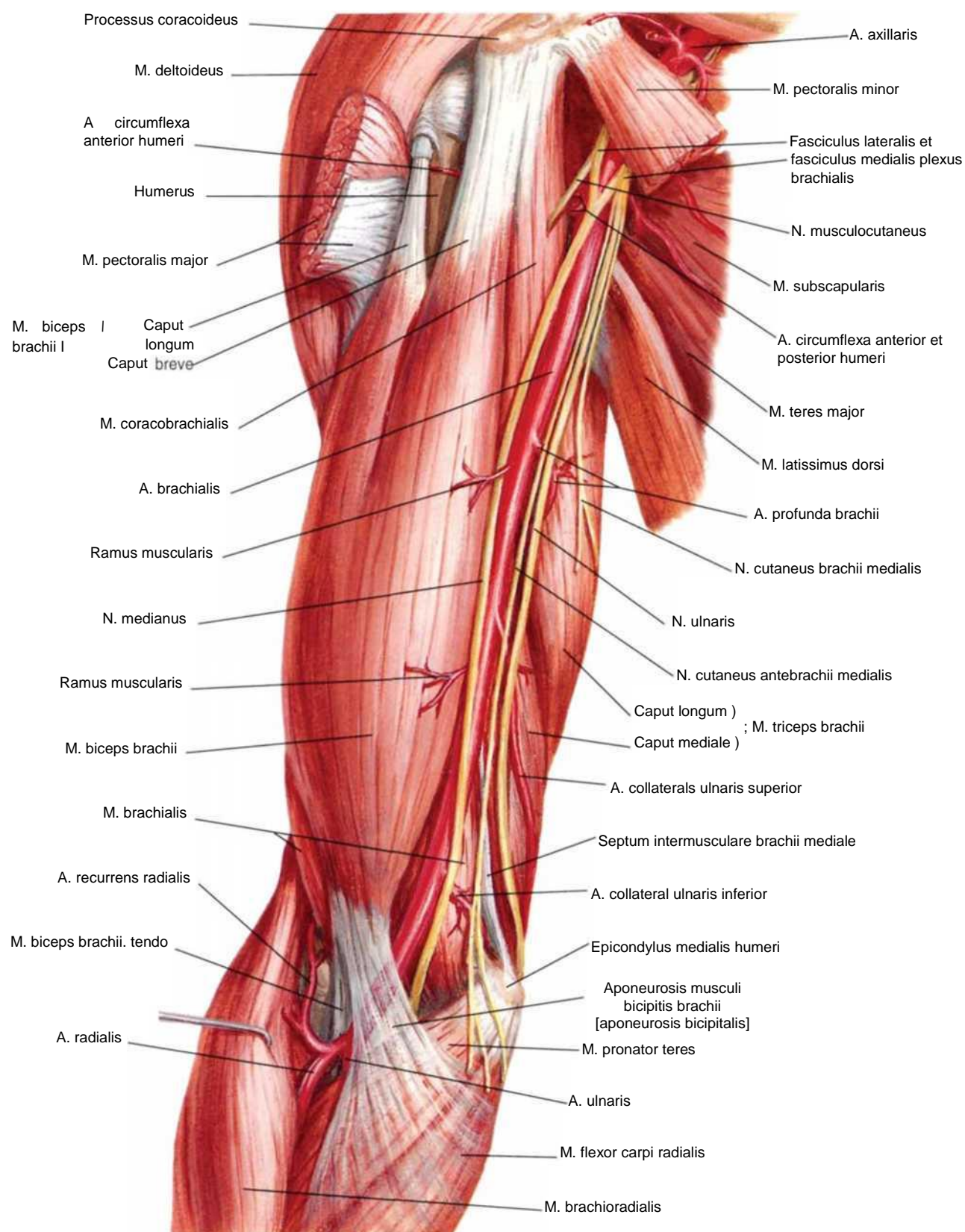


Chuqur qavatlar

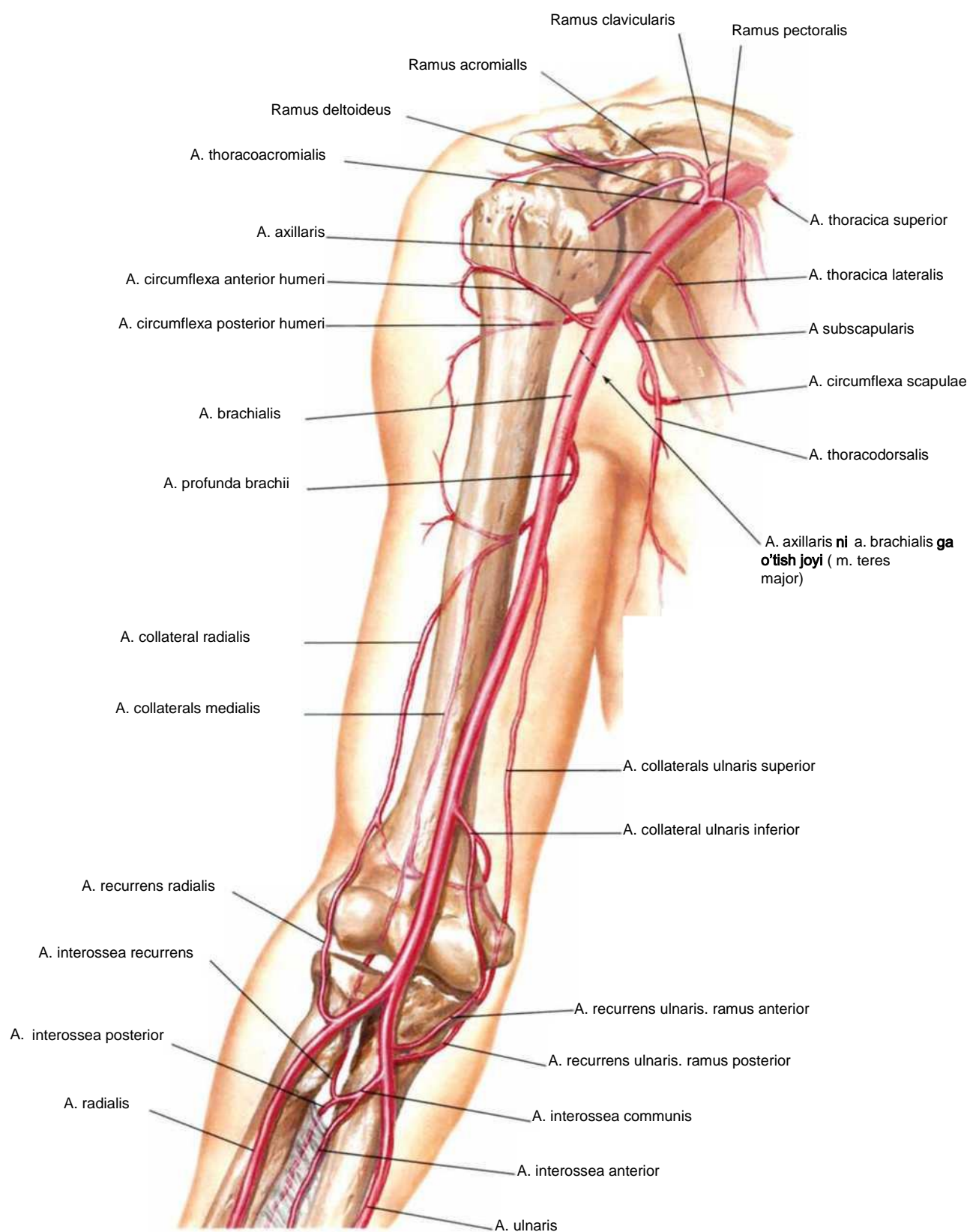
Elka muskullari: orqadan ko'rinishi



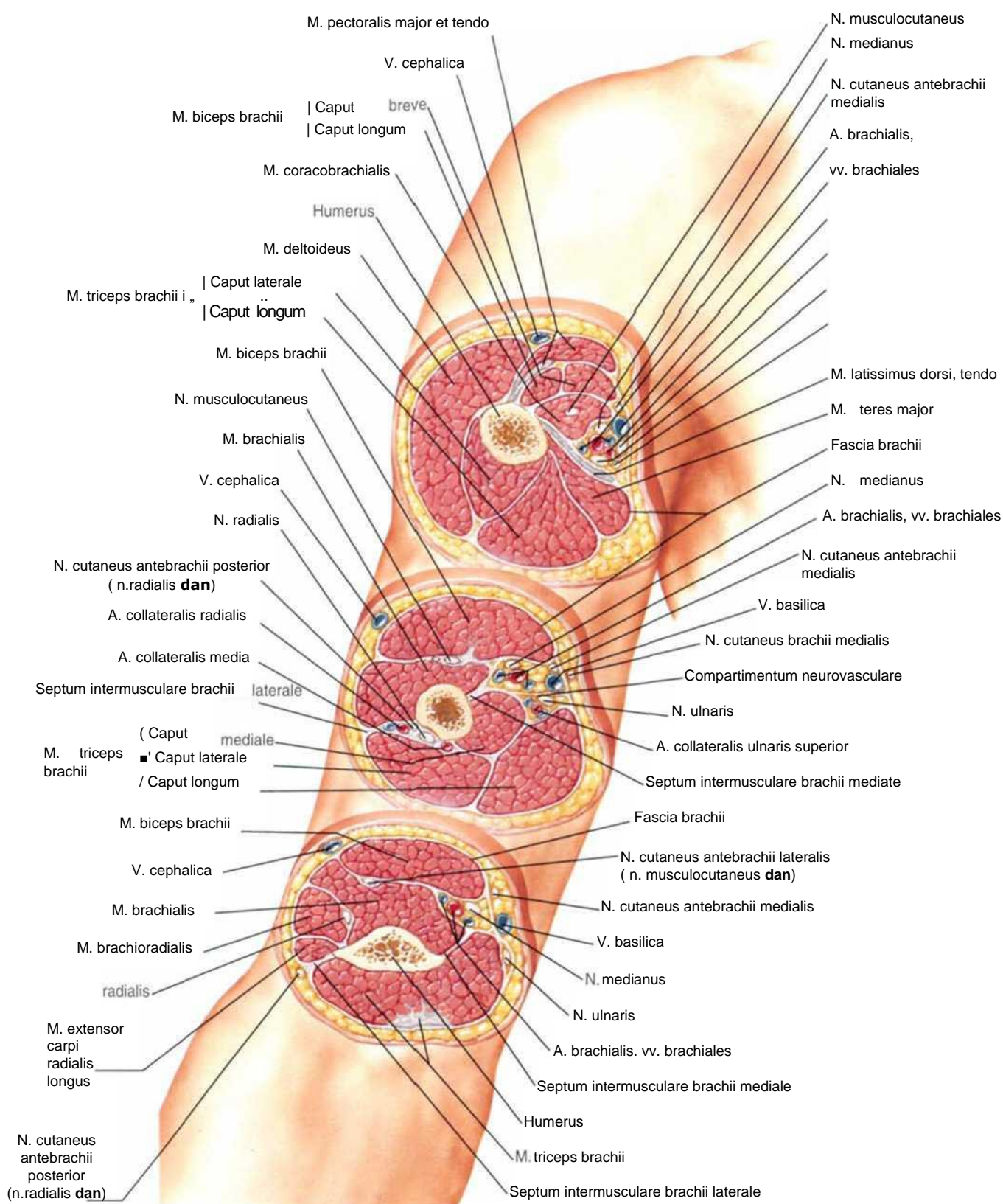
Elka arteriyasi (arteria brachialis)



Elka arteriyasi va tirsak bo'g'imi atrofidagi anastamozlar

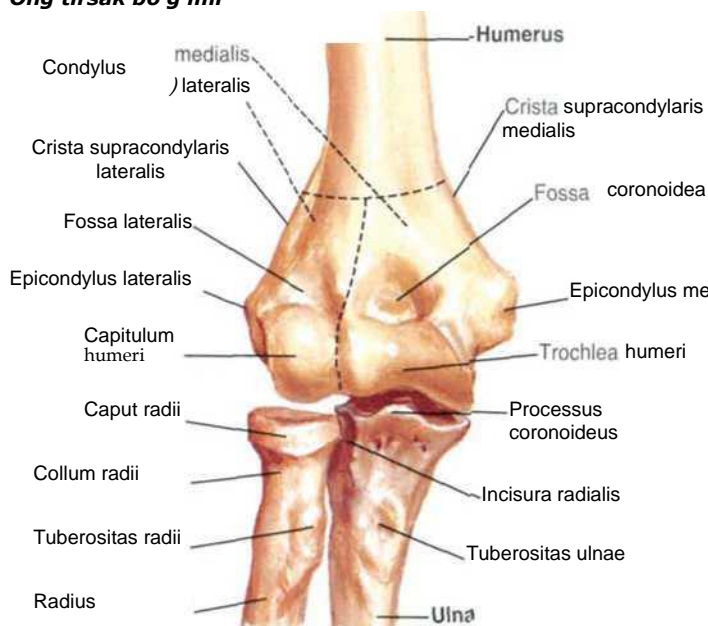

Elka: turli darajalarda ko'ndalang kesmasi

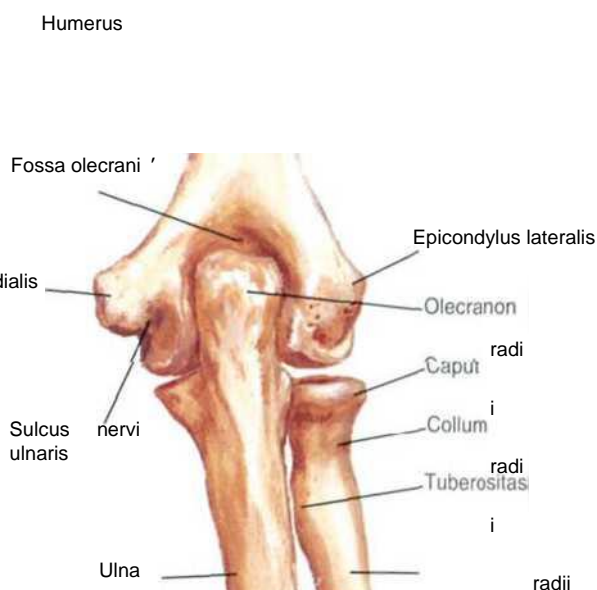


Tirsak bo'g'imi (articulatio cubiti)

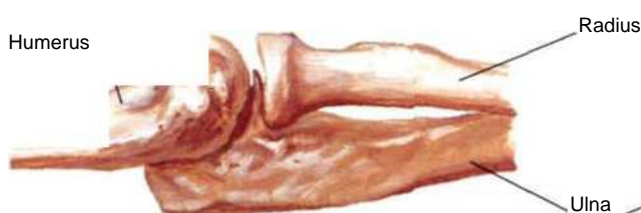Ong tirsak bo'g'imi



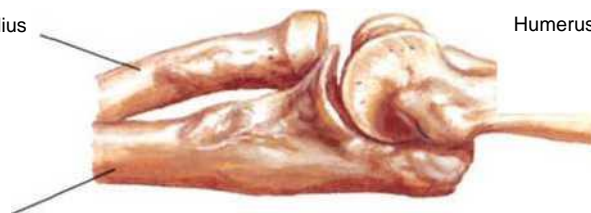Tirsak bo'g'imining to'liq yozilgan xolati: oldindan ko'rinishi



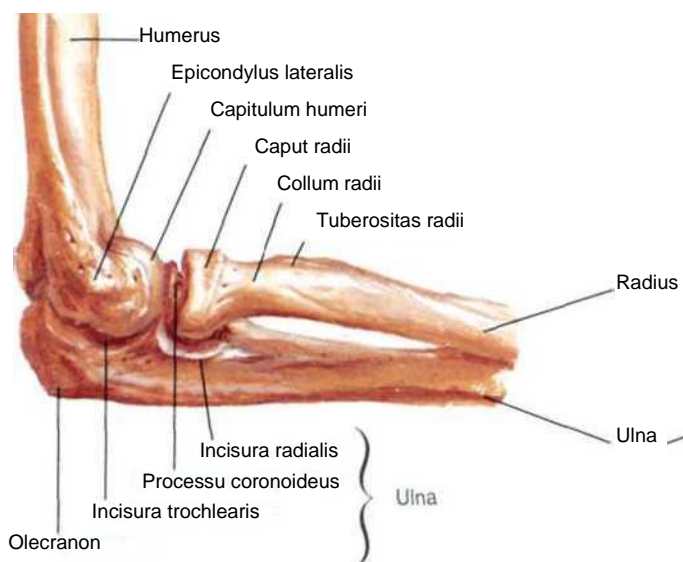
Tirsak bo'g'imining to'liq yozilgan xolati: orqadan ko'rinishi



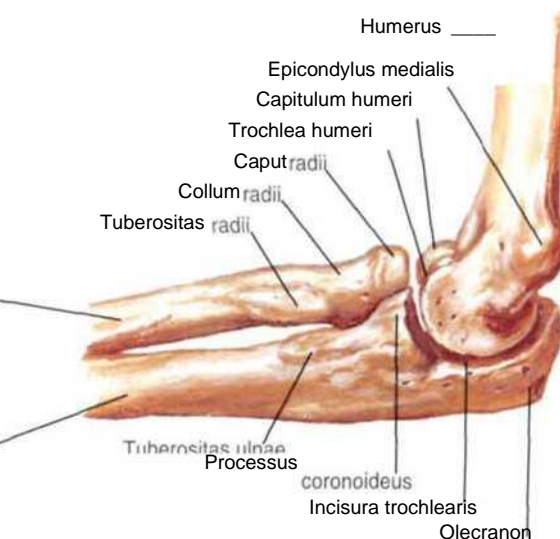
Tirsak bo'g'imining to'liq yozilgan xolati: lateral tarafdin ko'rinishi



Tirsak bo'g'imining to'liq yozilgan xolati: medial tarafdin ko'rinishi



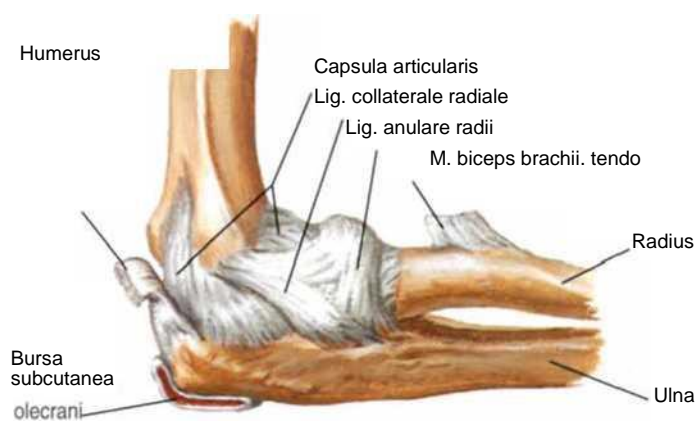
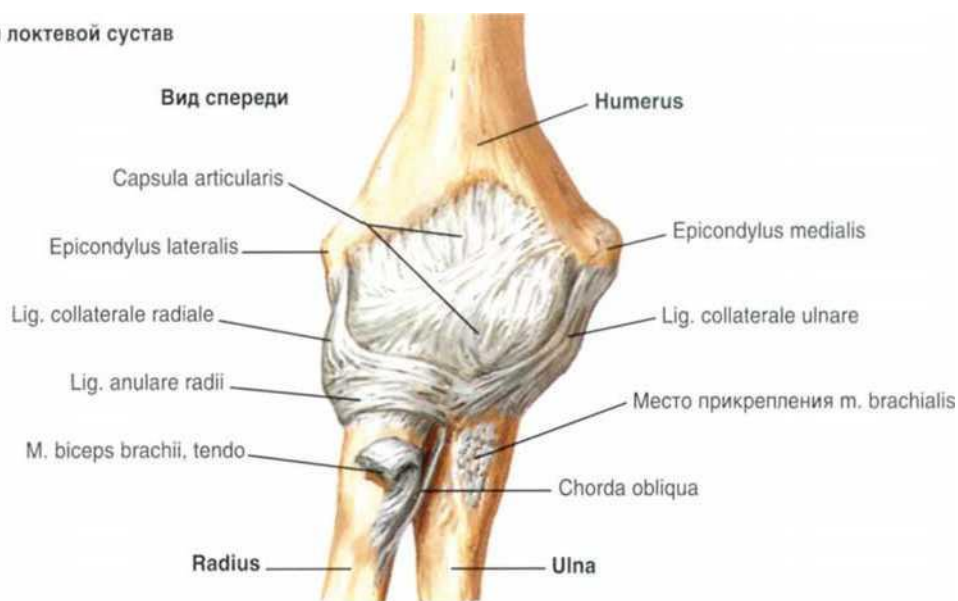Tirsak bo'g'imini 90° burchakda bukilgan xolati, lateral tarafdin ko'rinishi



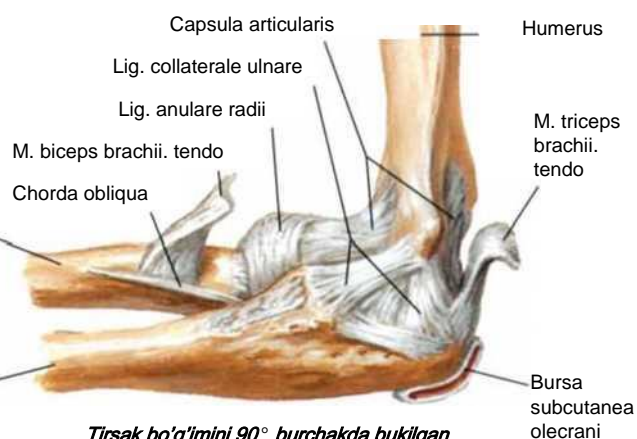
Tirsak bo'g'imini 90° burchakda bukilgan xolati, medial tarafdin ko'rinishi

Tirsak bo'g'imi boylamlari

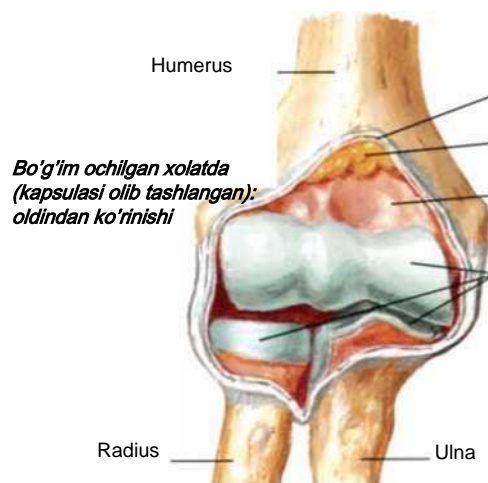Правый локтевой сустав



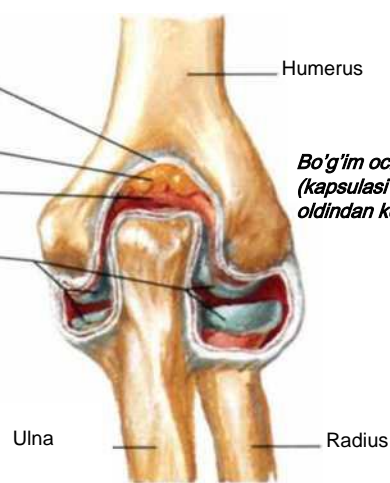
Tirsak bo'g'imini 90° burchakda bukilgan xolati, lateral tarafdan ko'rinishi



Tirsak bo'g'imini 90° burchakda bukilgan xolati, medial tarafdan ko'rinishi



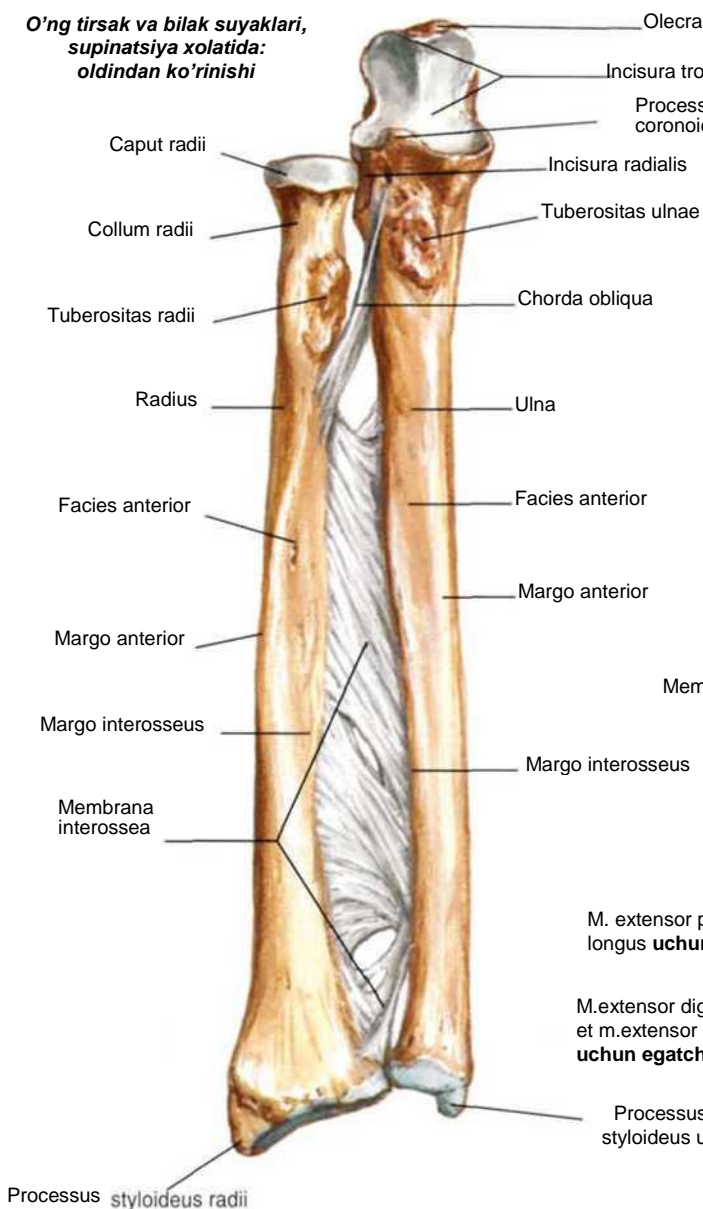
Bo'g'im ochilgan xolatda (kapsulasi olib tashlangan): oldindan ko'rinishi



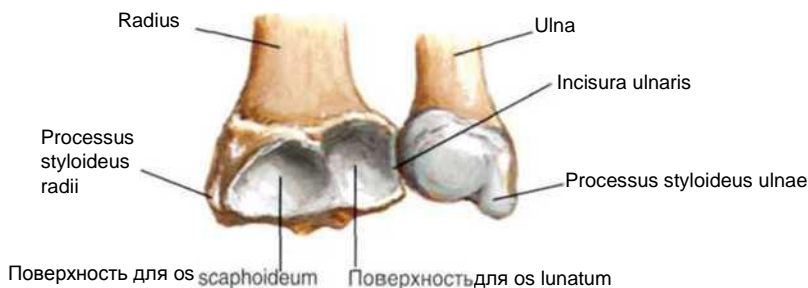
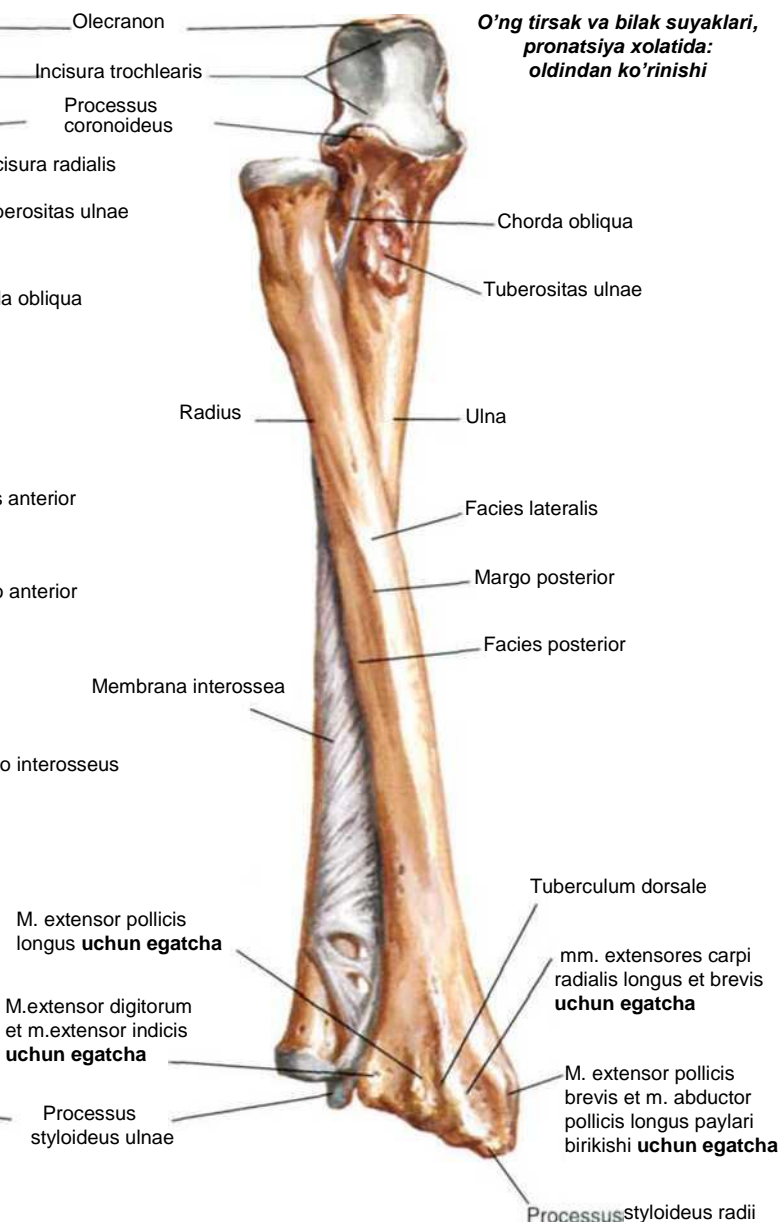Bo'g'im ochilgan xolatda (kapsulasi olib tashlangan): oldindan ko'rinishi

Bilak soxasi suyaklari

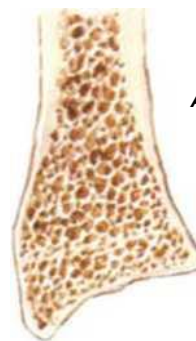
O'ng tirsak va bilak suyaklari,
supinatsiya xolatida:
oldindan ko'rinishi



O'ng tirsak va bilak suyaklari,
pronatsiya xolatida:
oldindan ko'rinishi



Bilak-kaftusti bo'g'imining
bo'g'im yuzalari



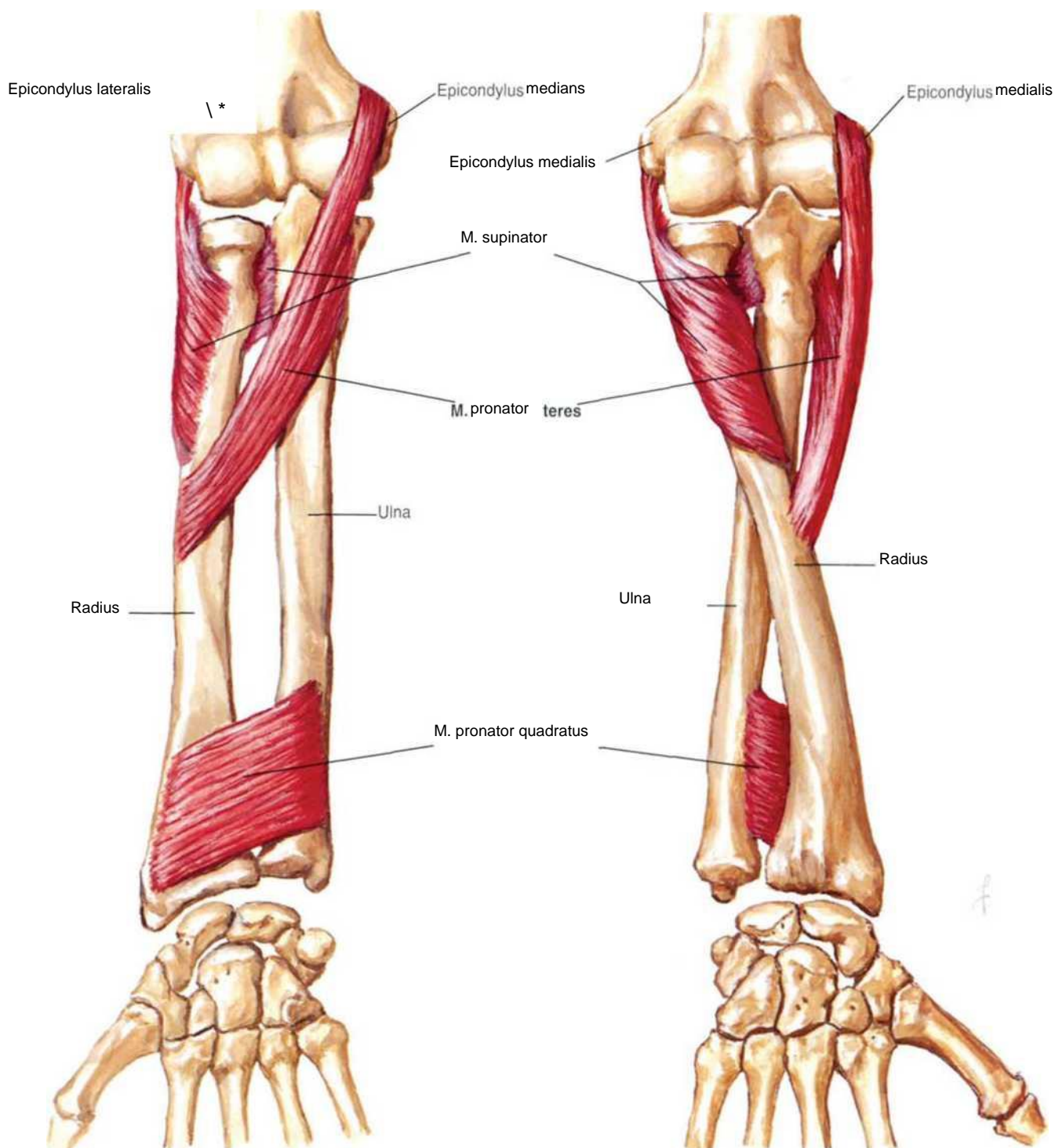
Arralab kesilgan bilak suyagi,
diafizning kortikal qavatini
suyakning distal qismiga
kelib yupqalashib
borayotganini ko'rish
mumkin

Bilak soxasining aloxida muskullari: bilak suyagini buruvchilar

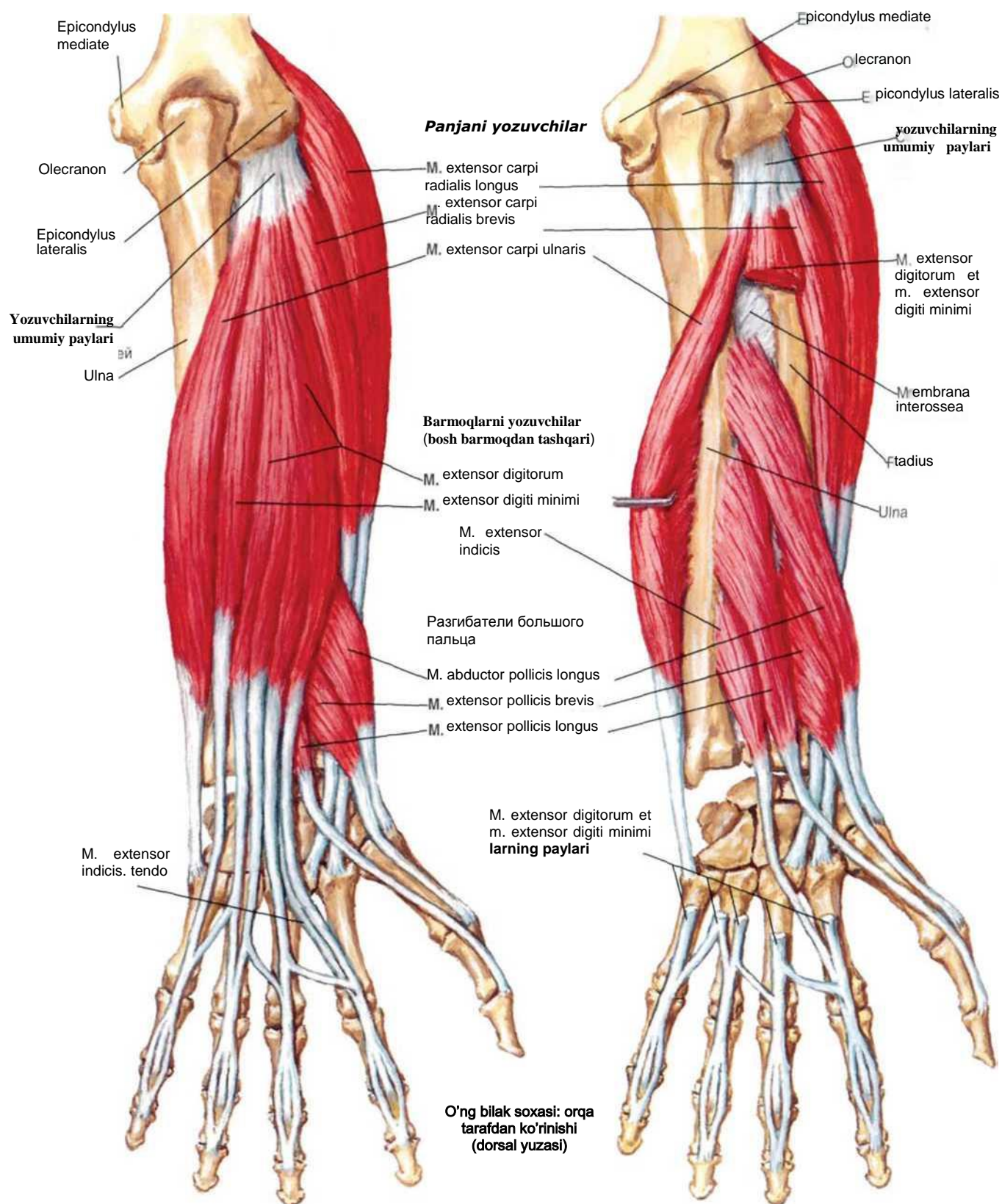
O'ng bilak soxasi oldindan ko'rinishi

Tashqariga burilishi - supinatio

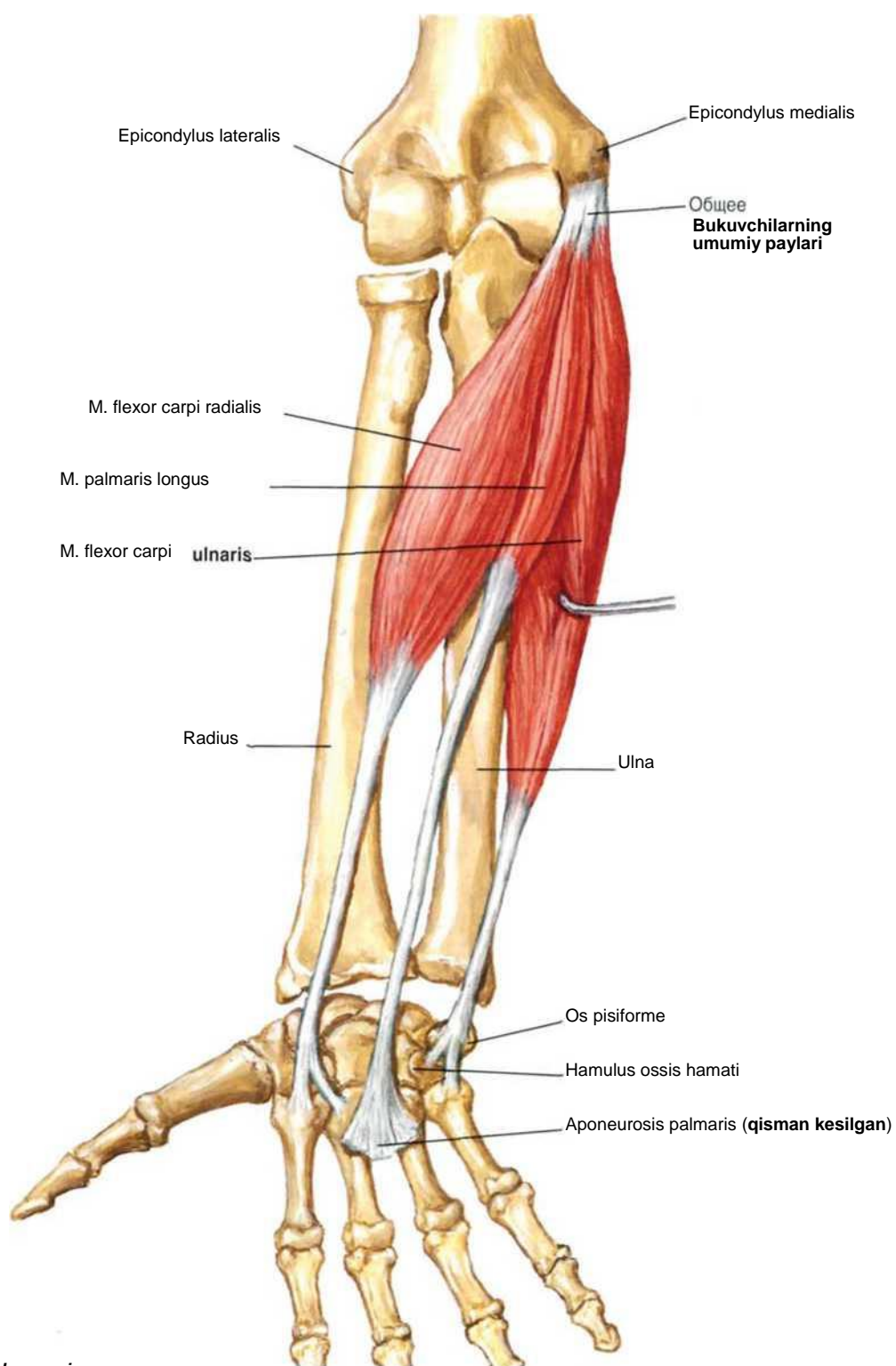
Ichkariga burilishi - pronatio



Bilak soxasining aloxida muskullari: panja va barmoqlarni yozuvchilar

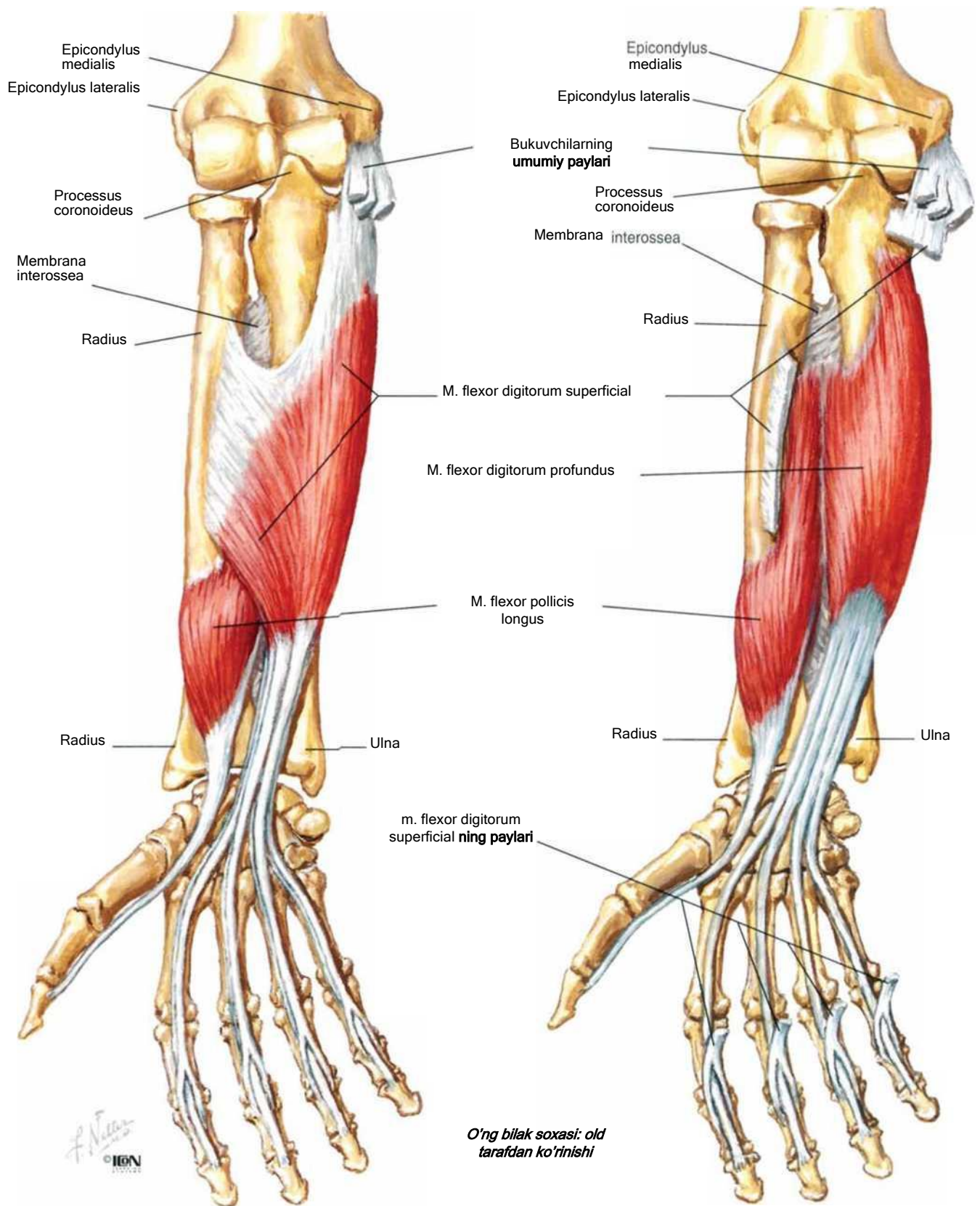


Bilak soxasining aloxida muskullari: kaft usti soxasini bukuvchilar

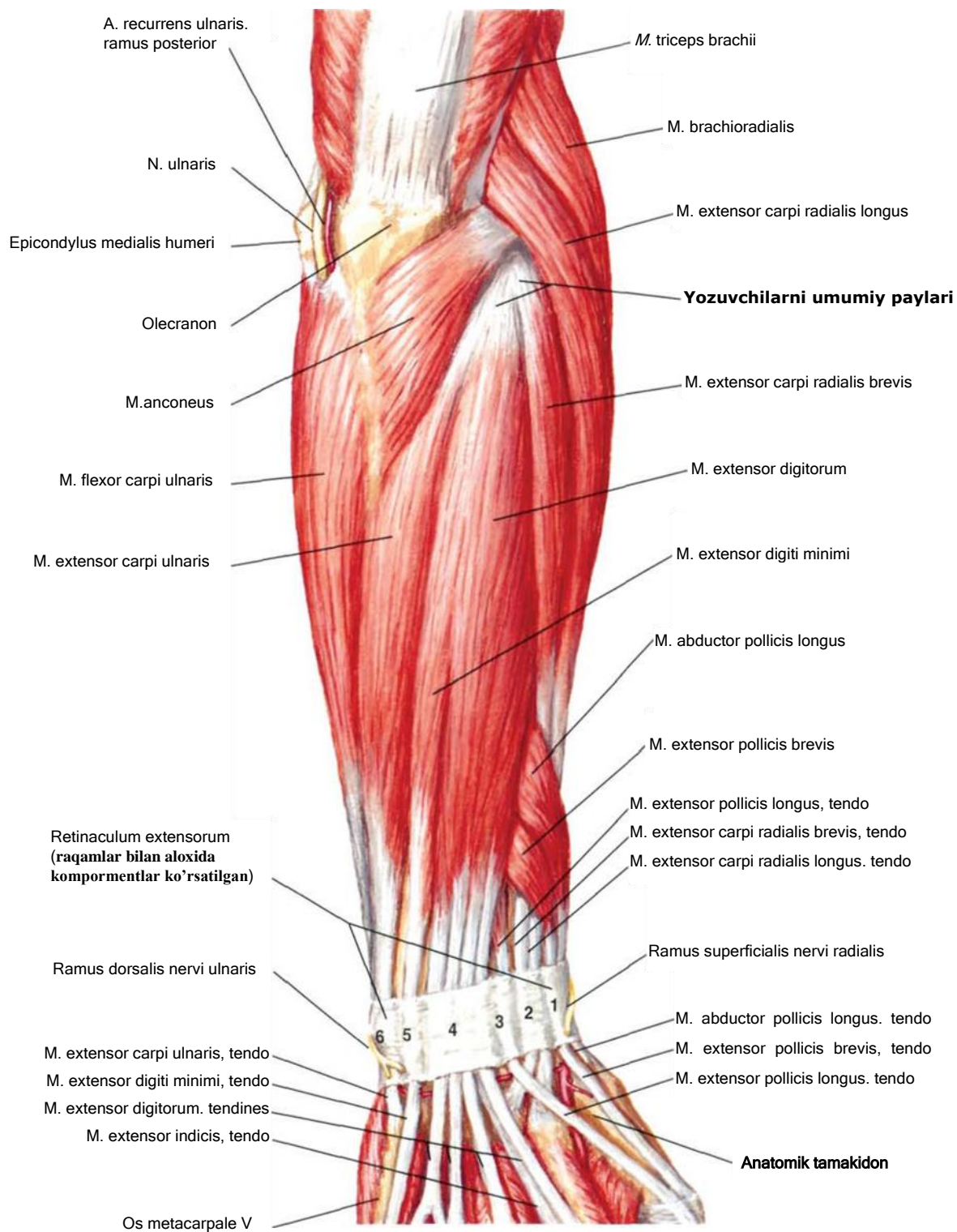


**O'ng bilak soxasi:
oldindan ko'rinishi**

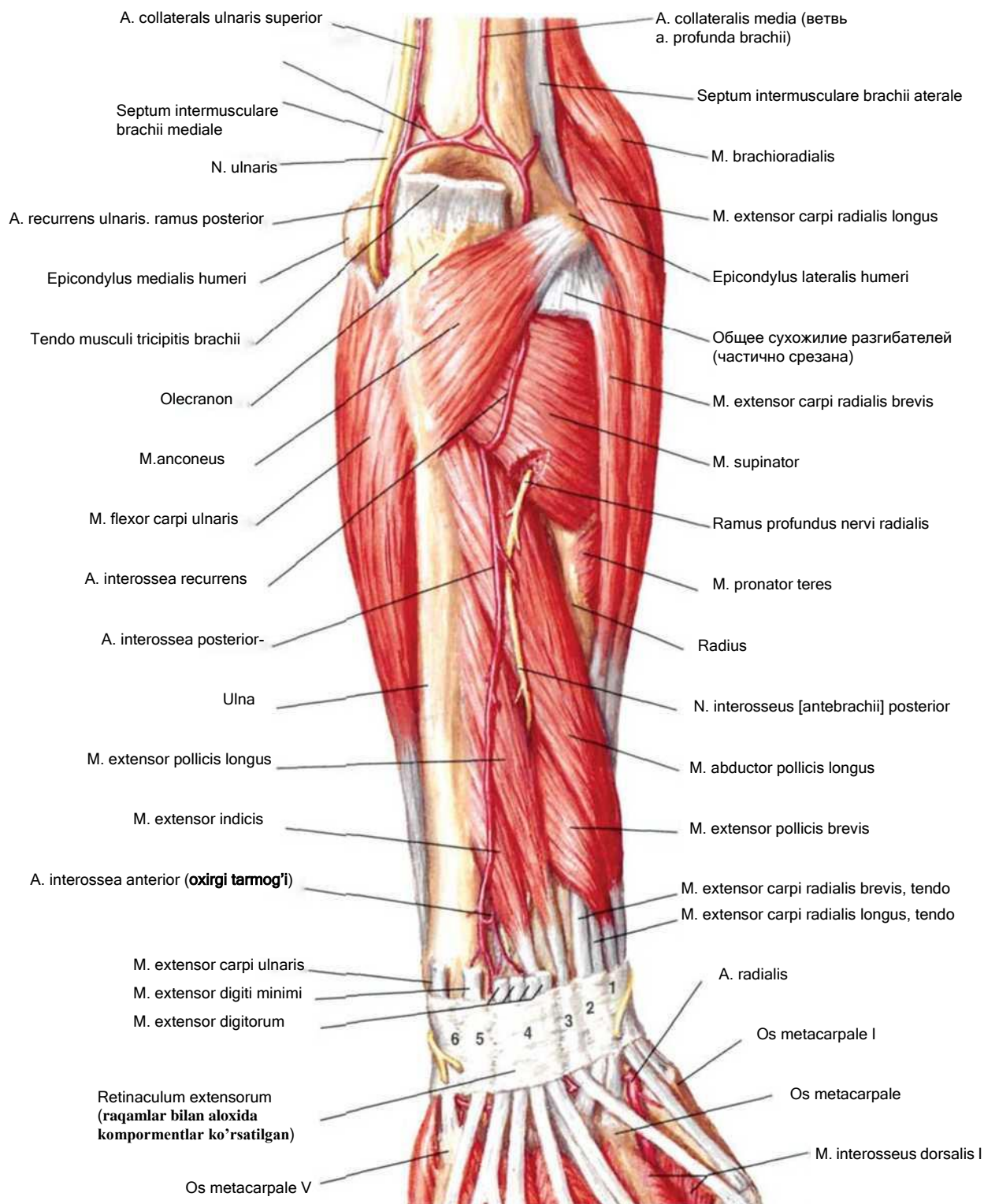
Bilak soxasining aloxida muskullari: barmoqlarni bukuvchilar



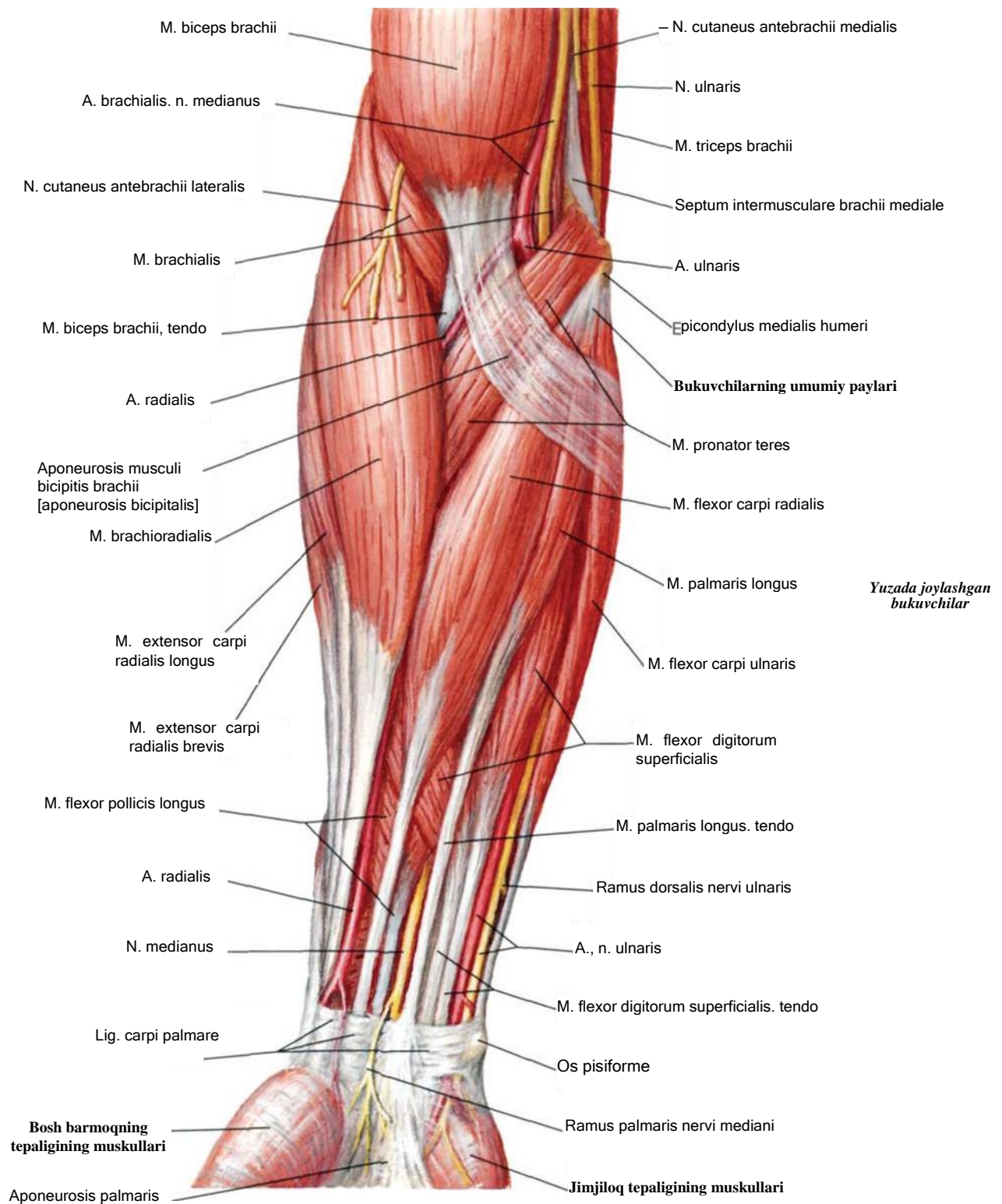
Bilak soxasi muskullari (yuza qavat): orqadan ko'rinishi



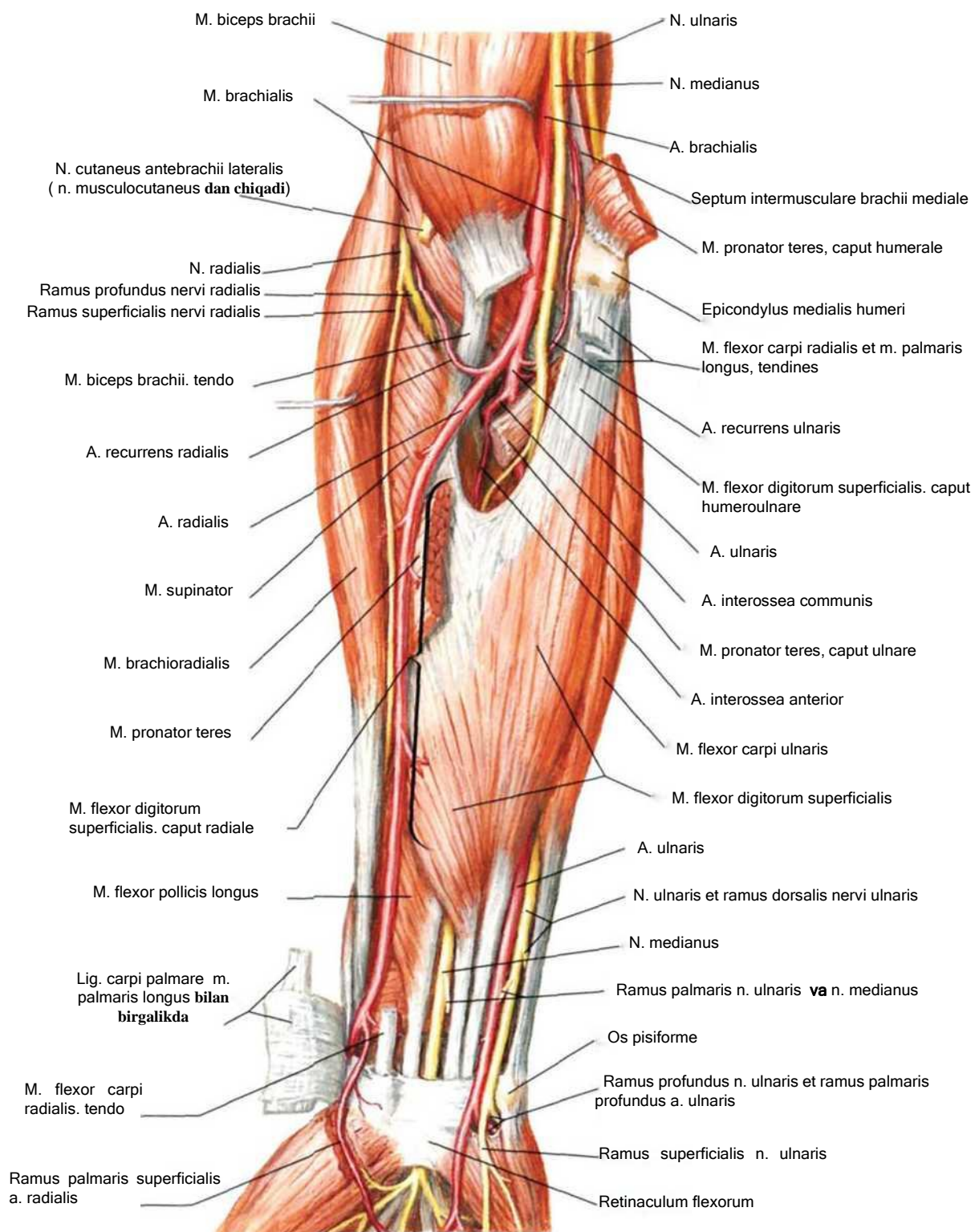
Bilak soxasi muskullari (chuqur qavatlar): orqadan ko'rinishi



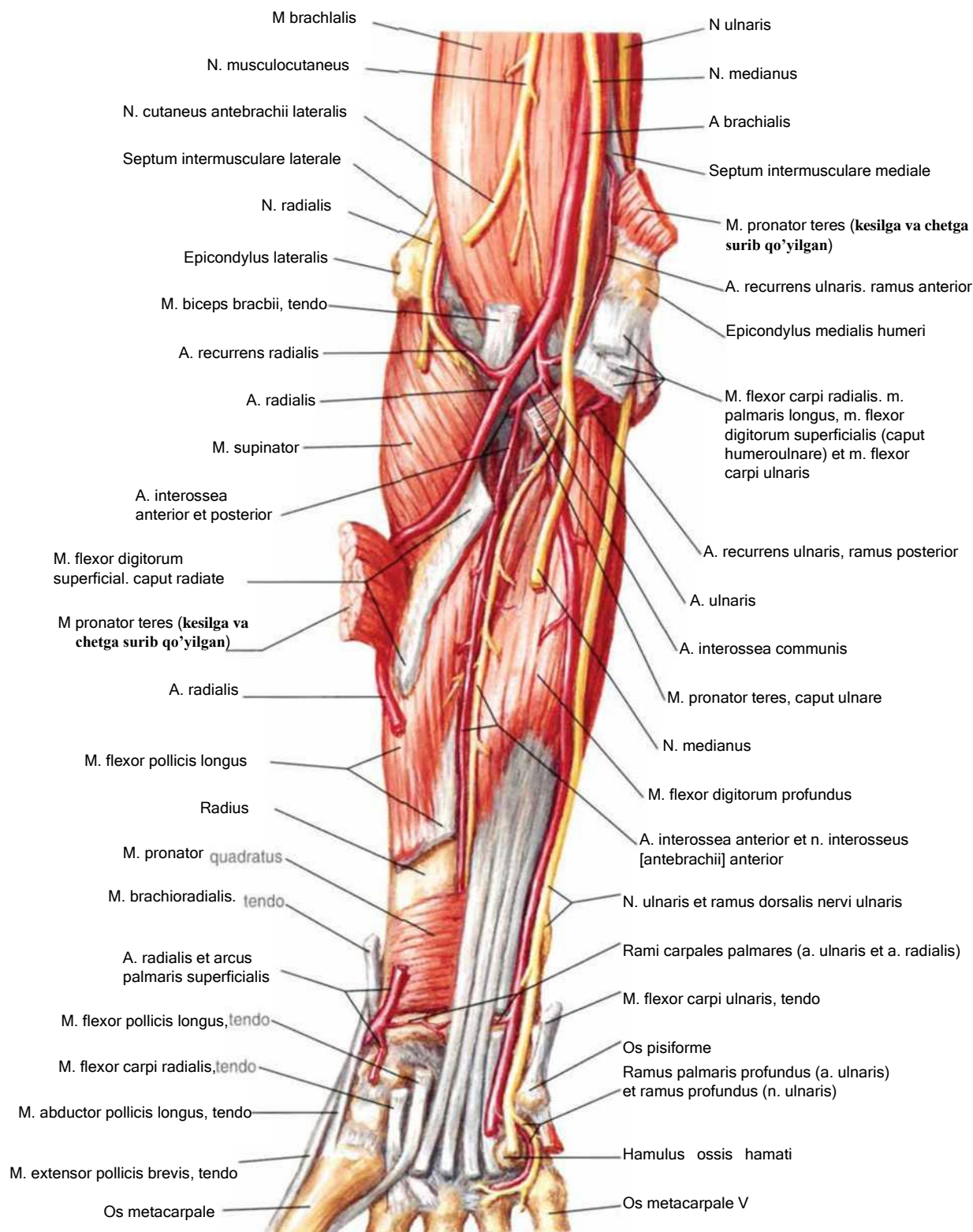
Bilak soxasi muskullari (yuza qavat): oldindan ko'rinishi



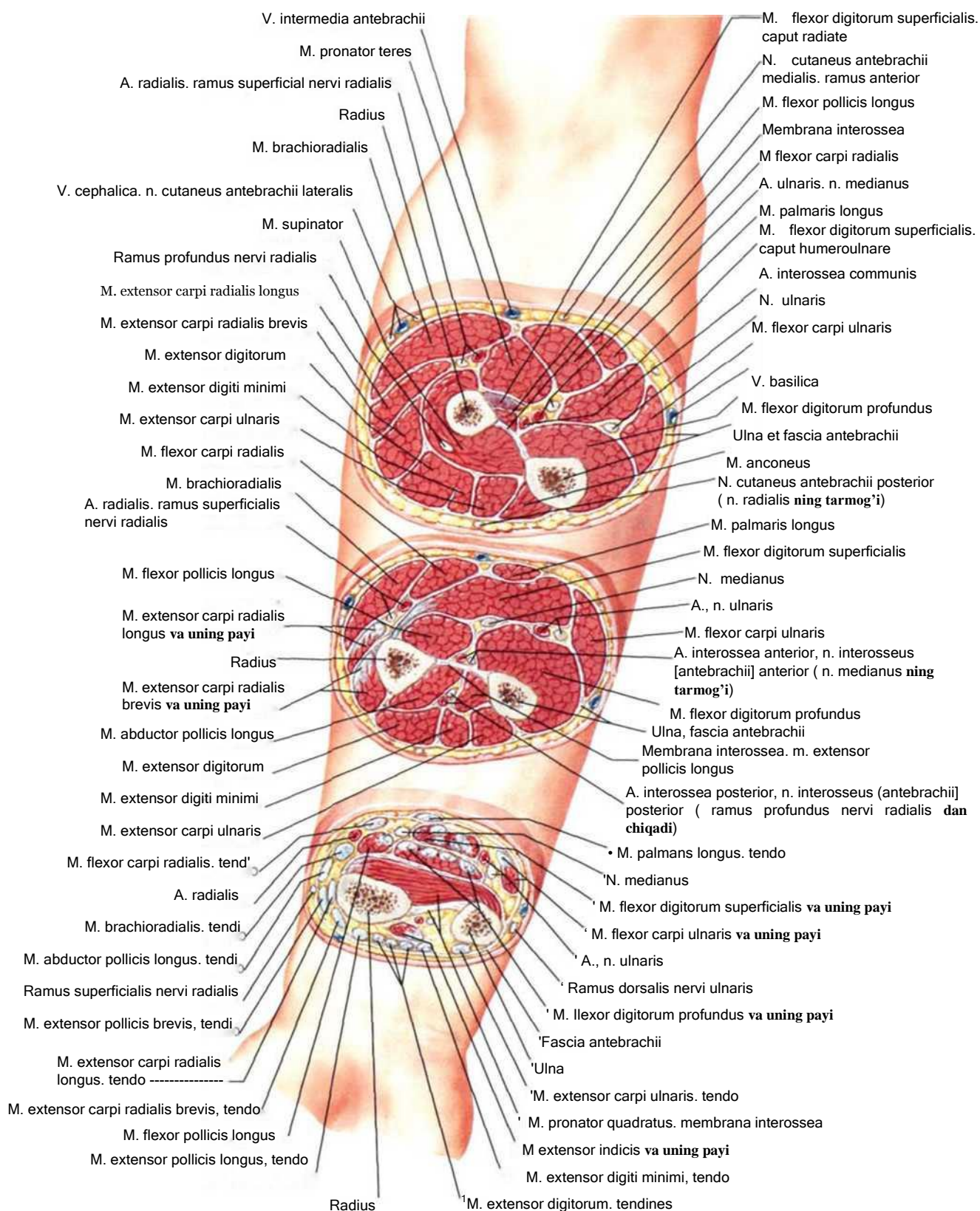
Bilak soxasi muskullari (o'rta qavat): oldindan ko'rinishi



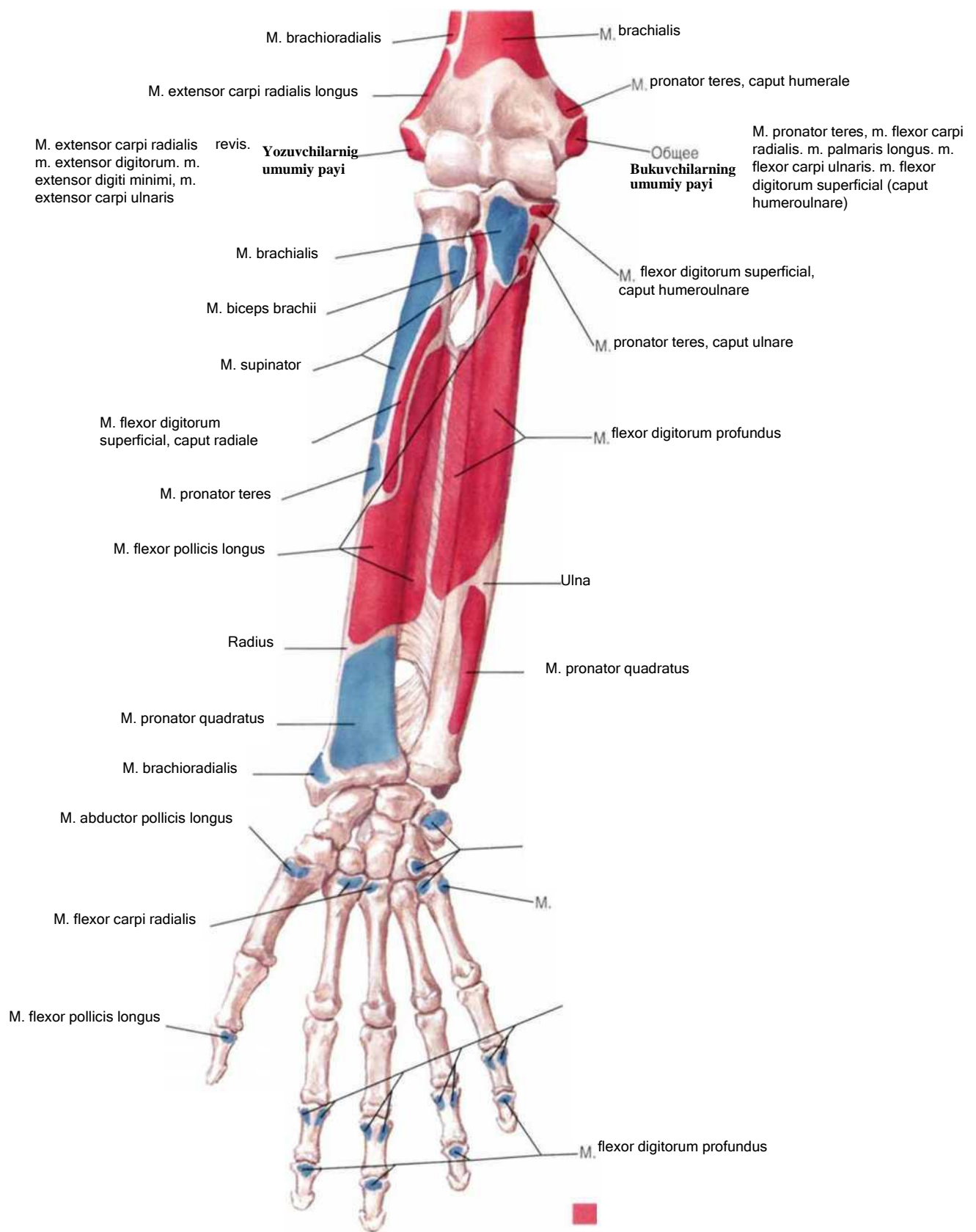
Bilak soxasi muskullari (chuqur qavat): oldindan ko'rinishi



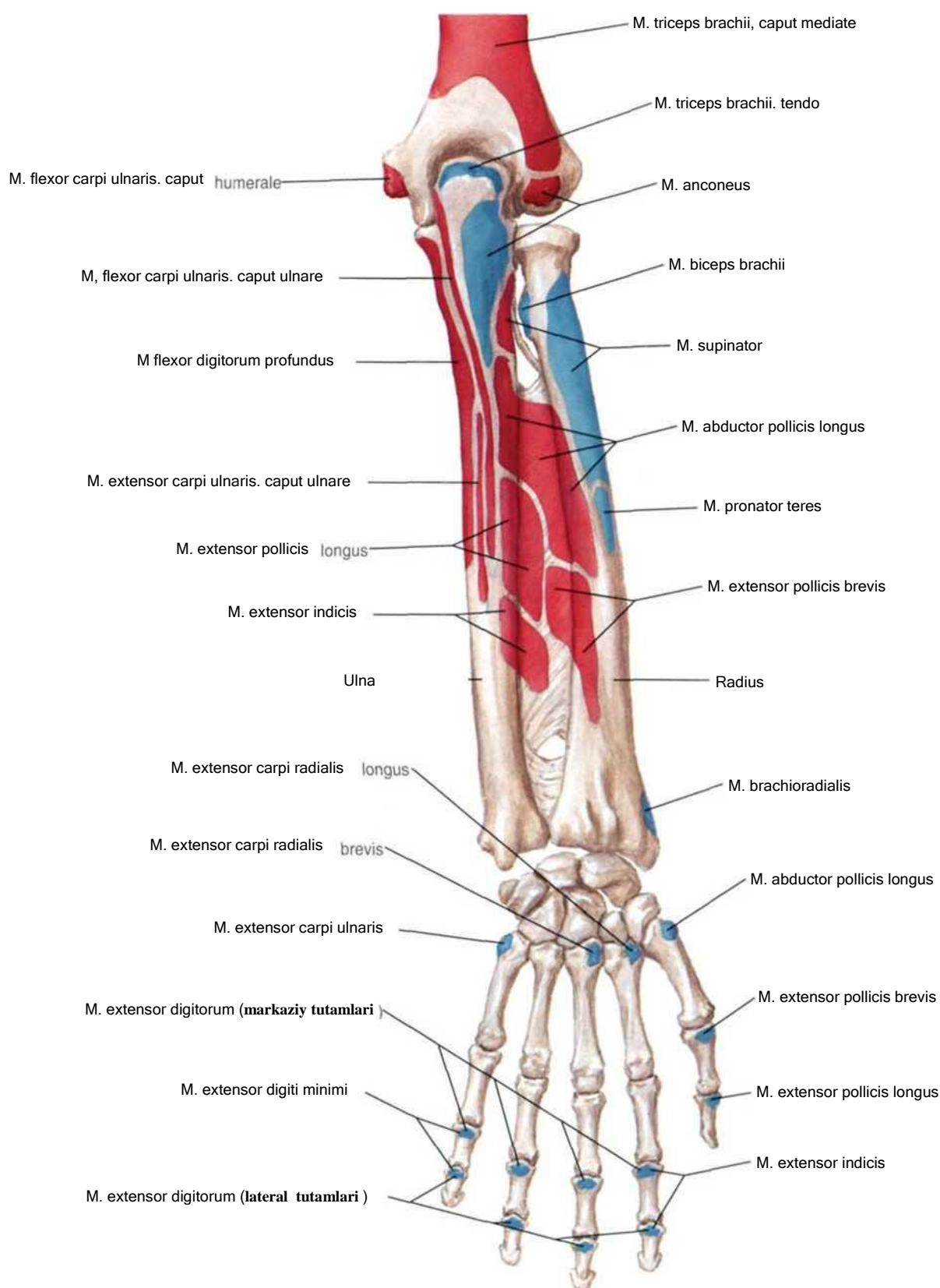
Bilak soxasi: turli darajalarda ko'ndalang kesmasi



Bilak soxasi muskullarining boshlanishi va birikishi: oldindan ko'rinishi

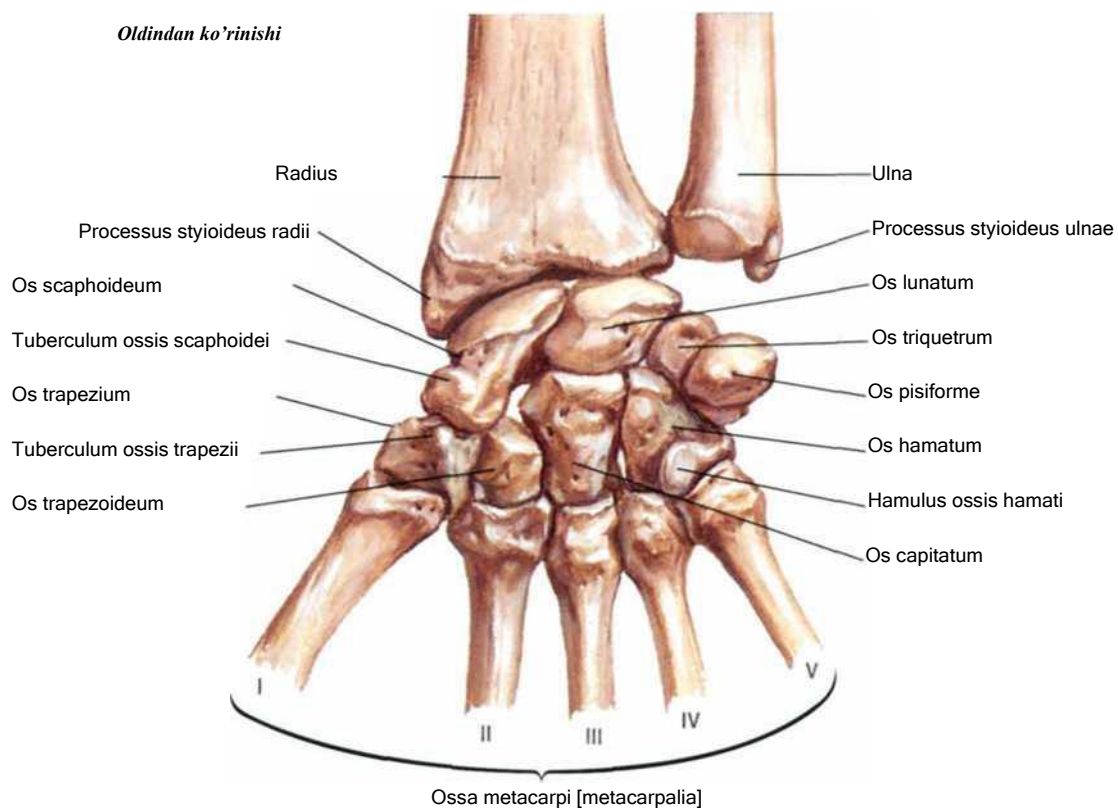


Bilak soxasi muskullarining birikishi: orqadan ko'rinishi

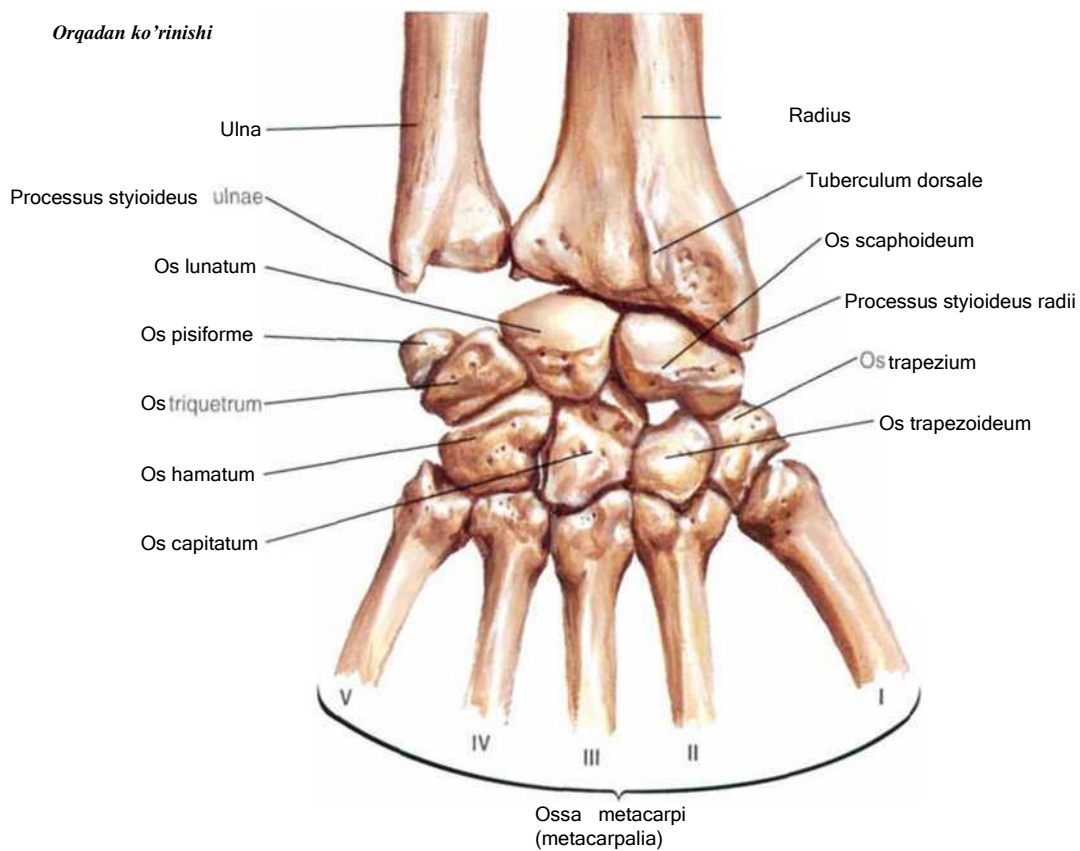


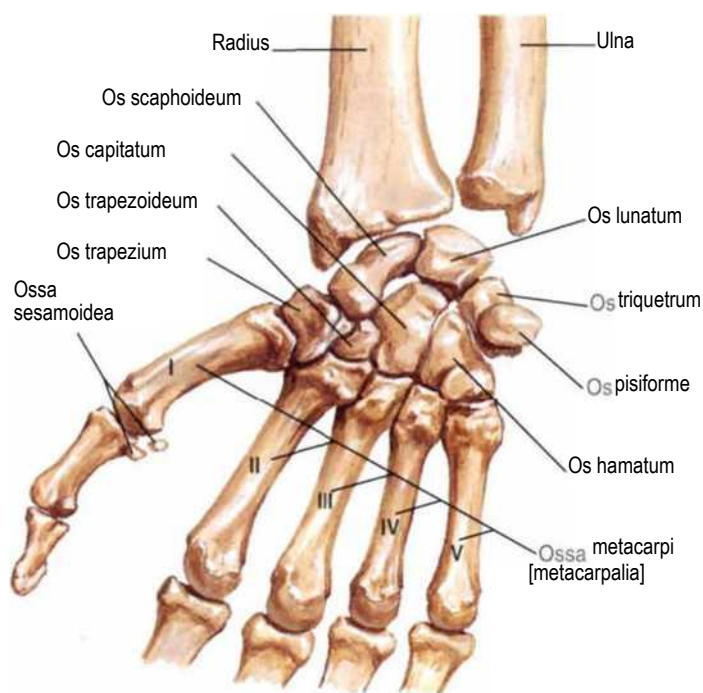
Kaft usti suyaklari (ossa carpi)

Oldindan ko'rinishi

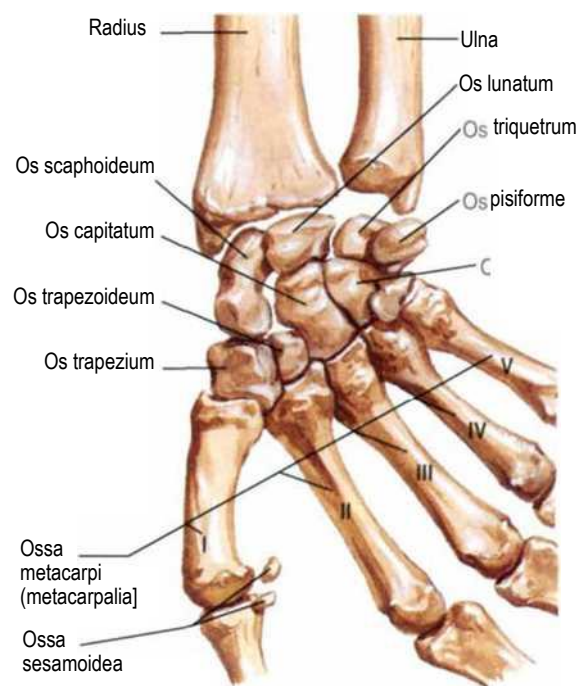


Orqadan ko'rinishi

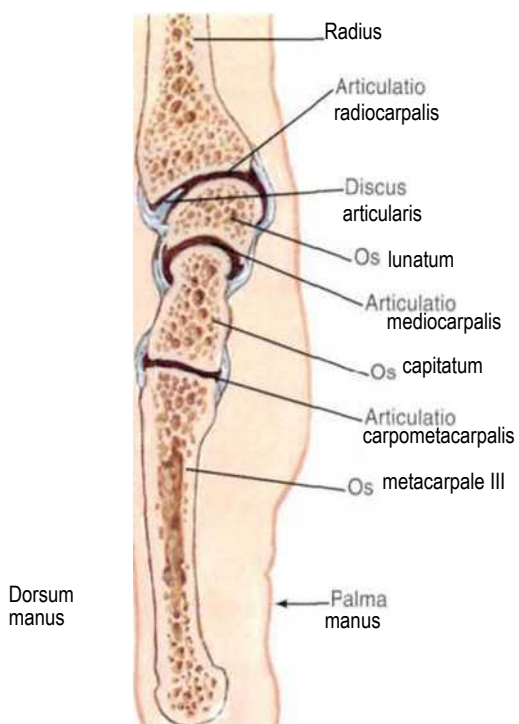




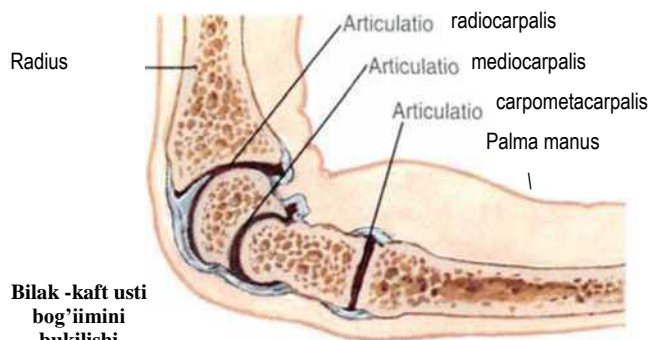
*Panjani uzoqlashtirishda
(old tarafdan ko'rinishi)*



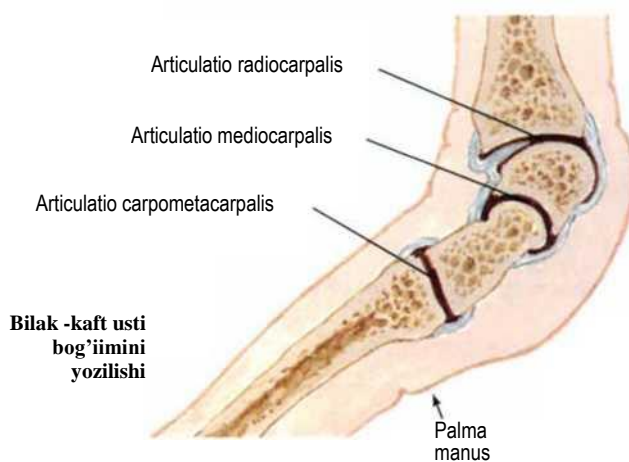
Приведение кисти
(вид спереди)



*O'rta barmoq va kaft usti
suyaklari orqali sagittal kesma*

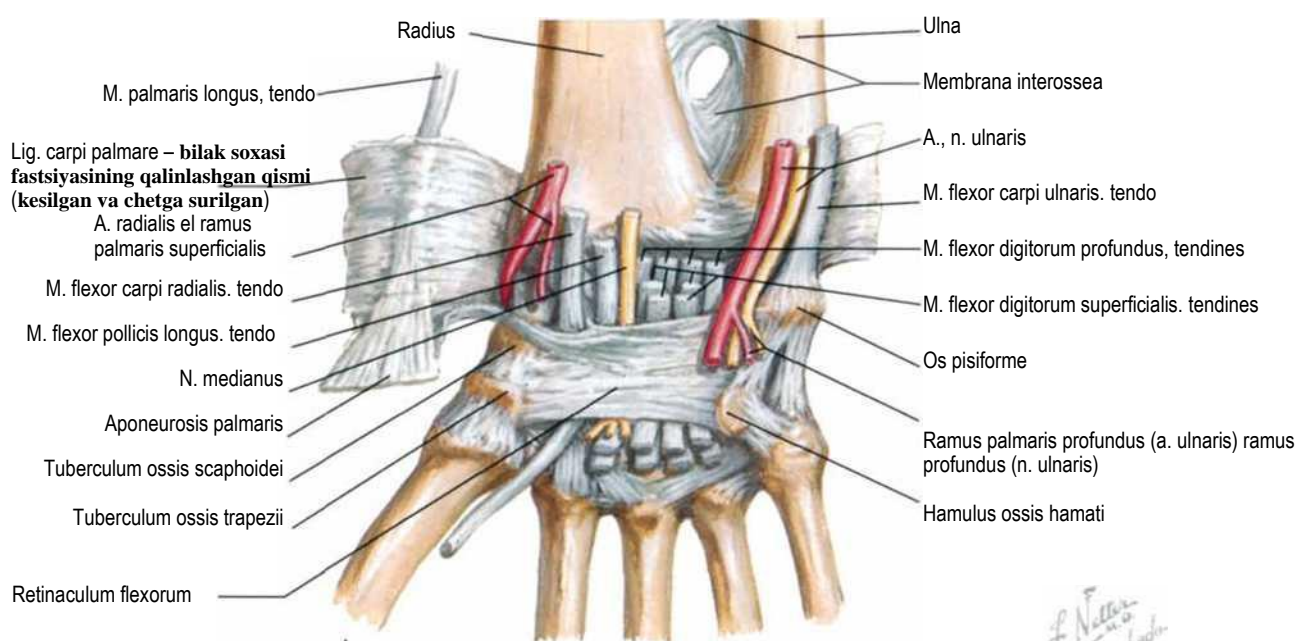


**Bilak -kaft usti
bog'iimini
bukilishi**

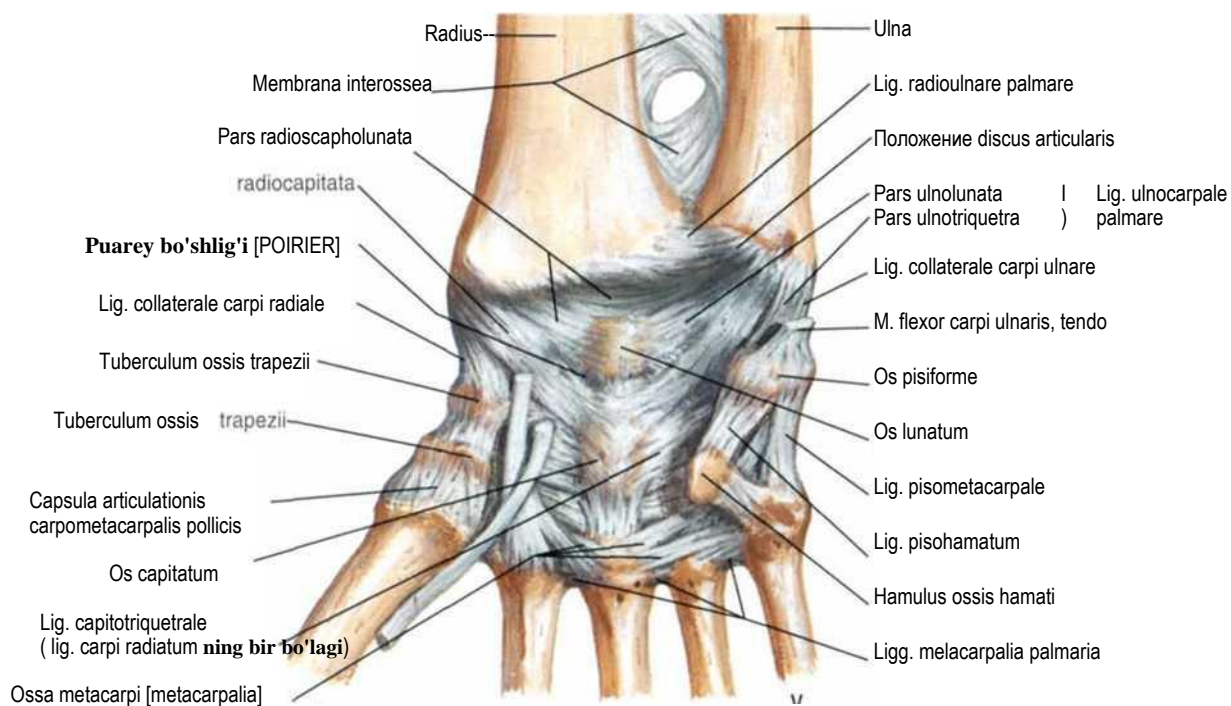


**Bilak -kaft usti
bog'iimini
yozilishi**

Kaft usti soxasi boylamlari



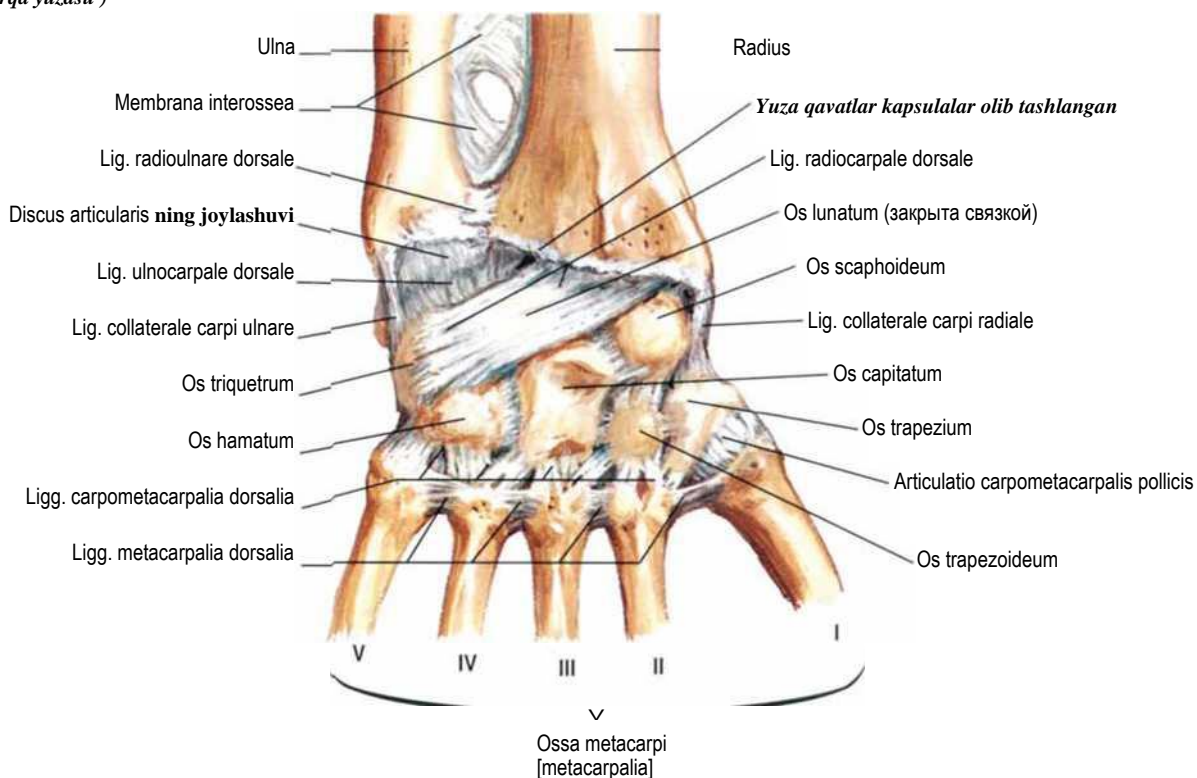
Ossa metacarpi
[metacarpalia]



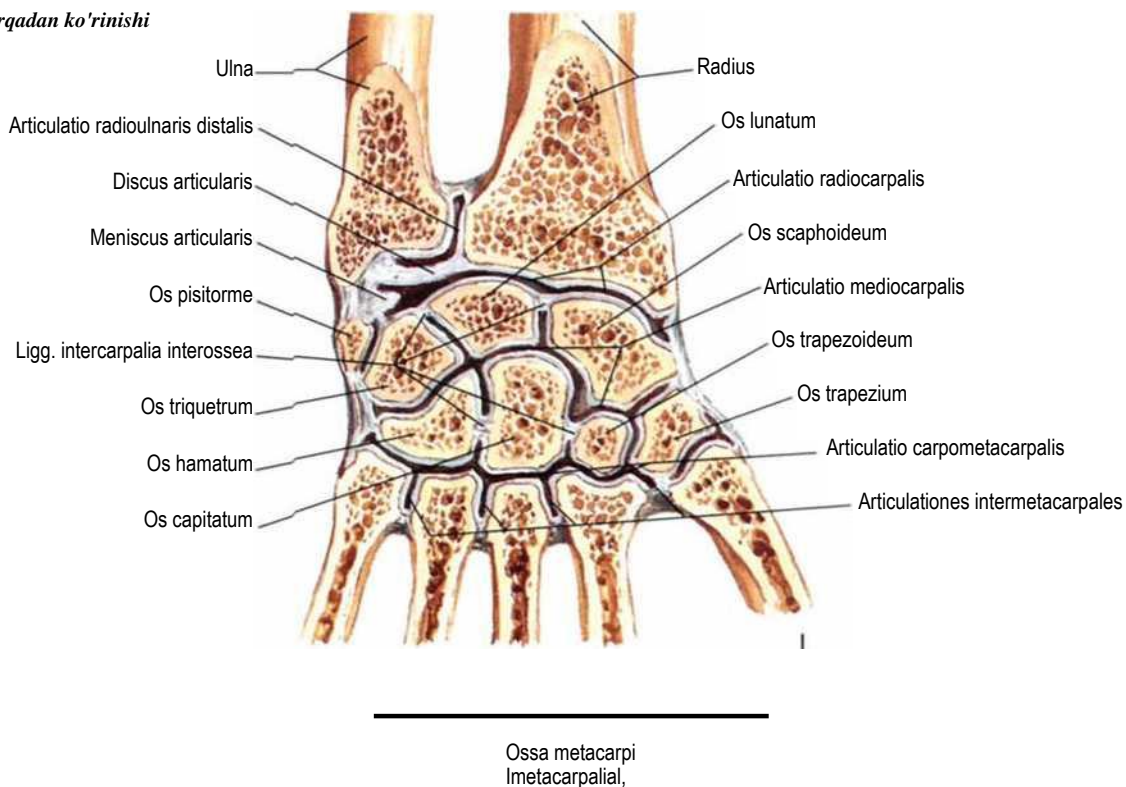
Ossa metacarpi
[metacarpalia]

Kaft usti soxasi boylamlari (davomi)

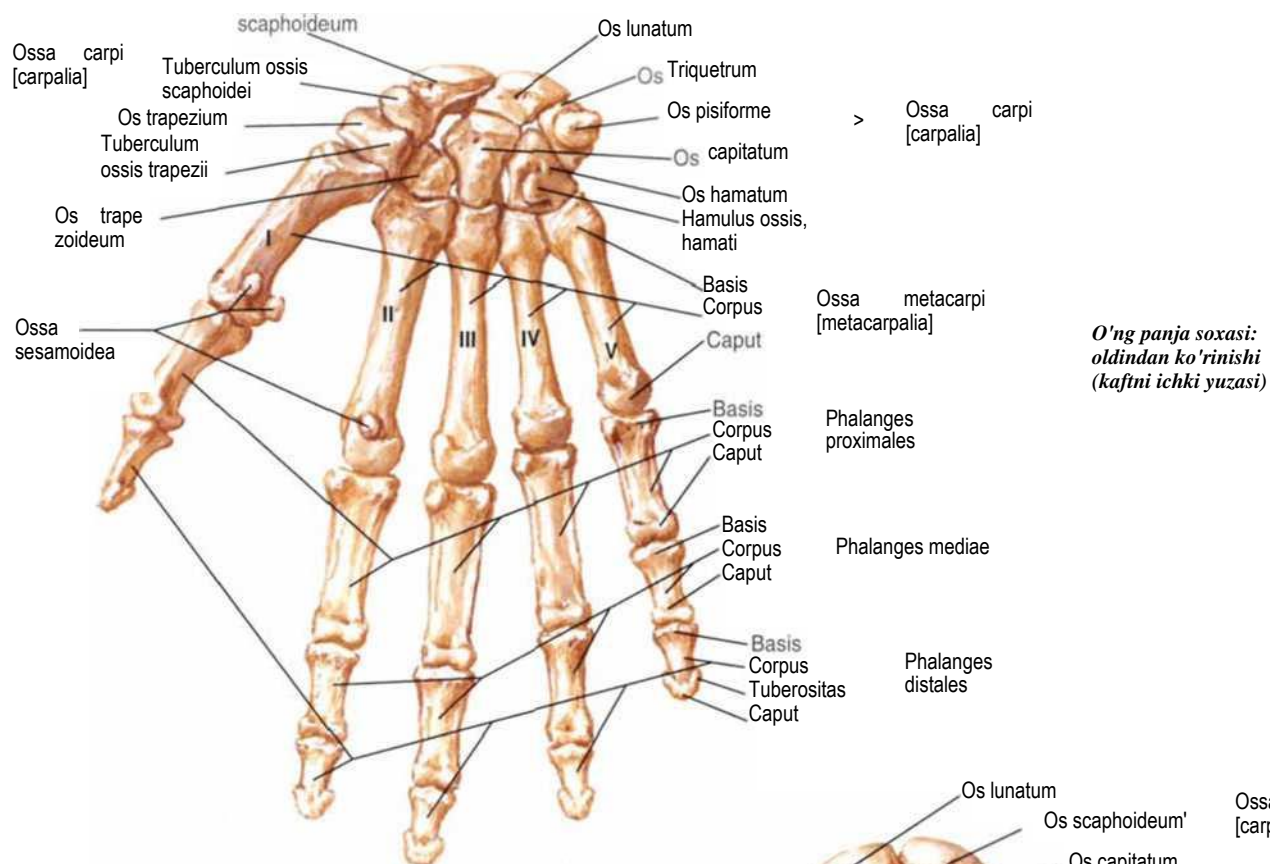
*Orqadan ko'rinishi
(panjaning orqa yuzasu)*



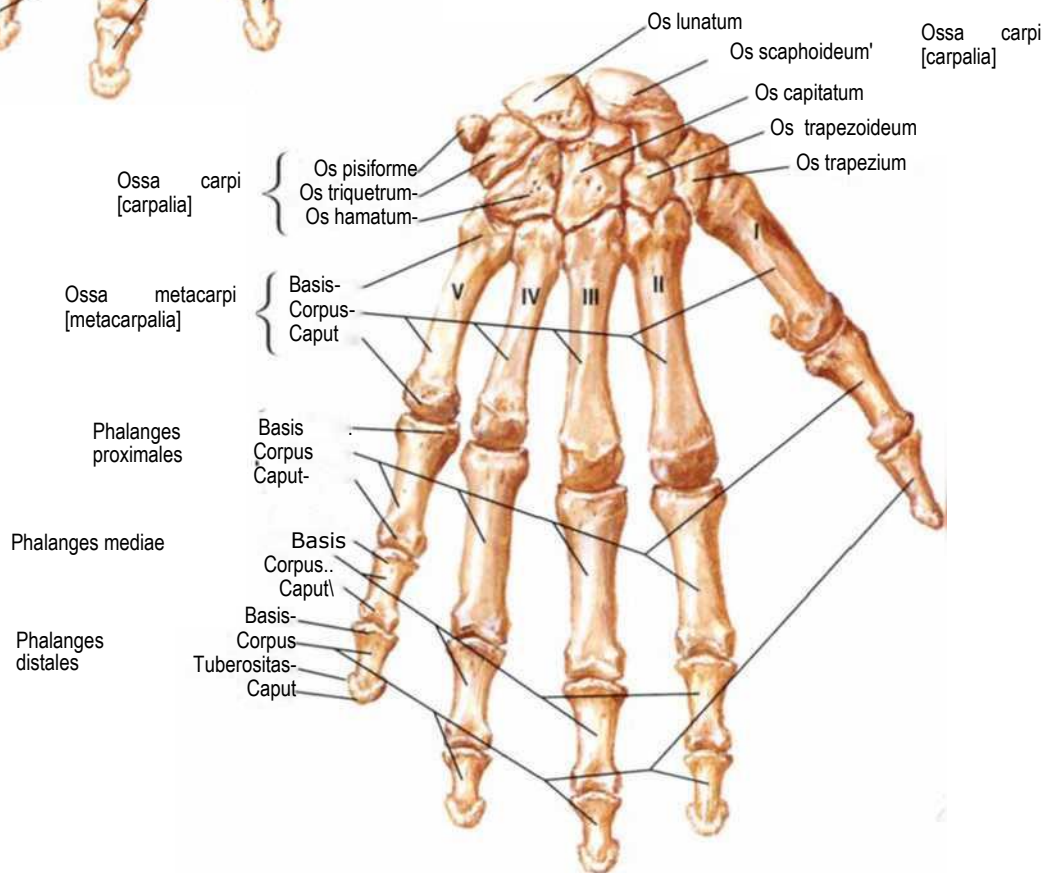
Frontal kesma, orqadan ko'rinishi



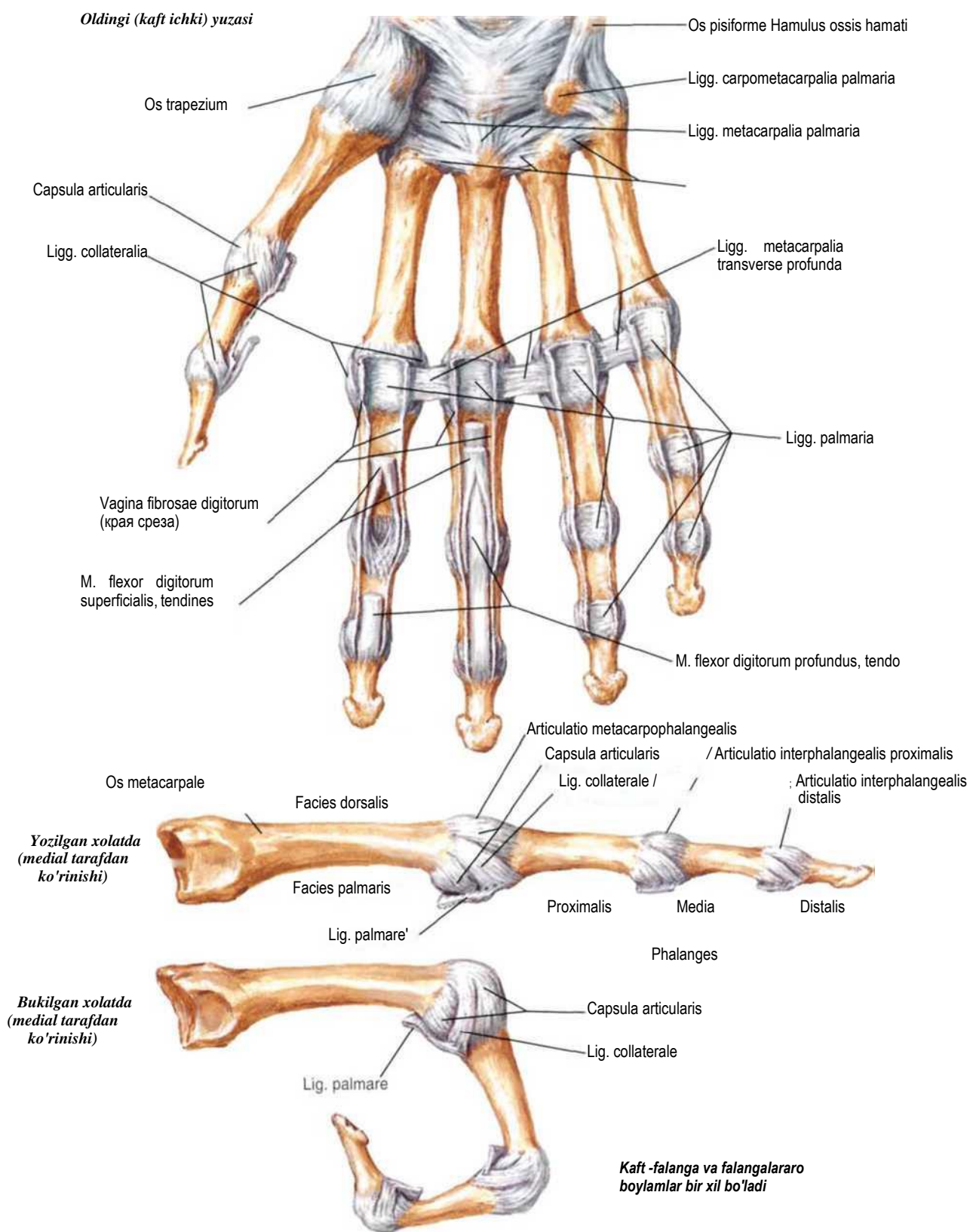
Panja suyaklari



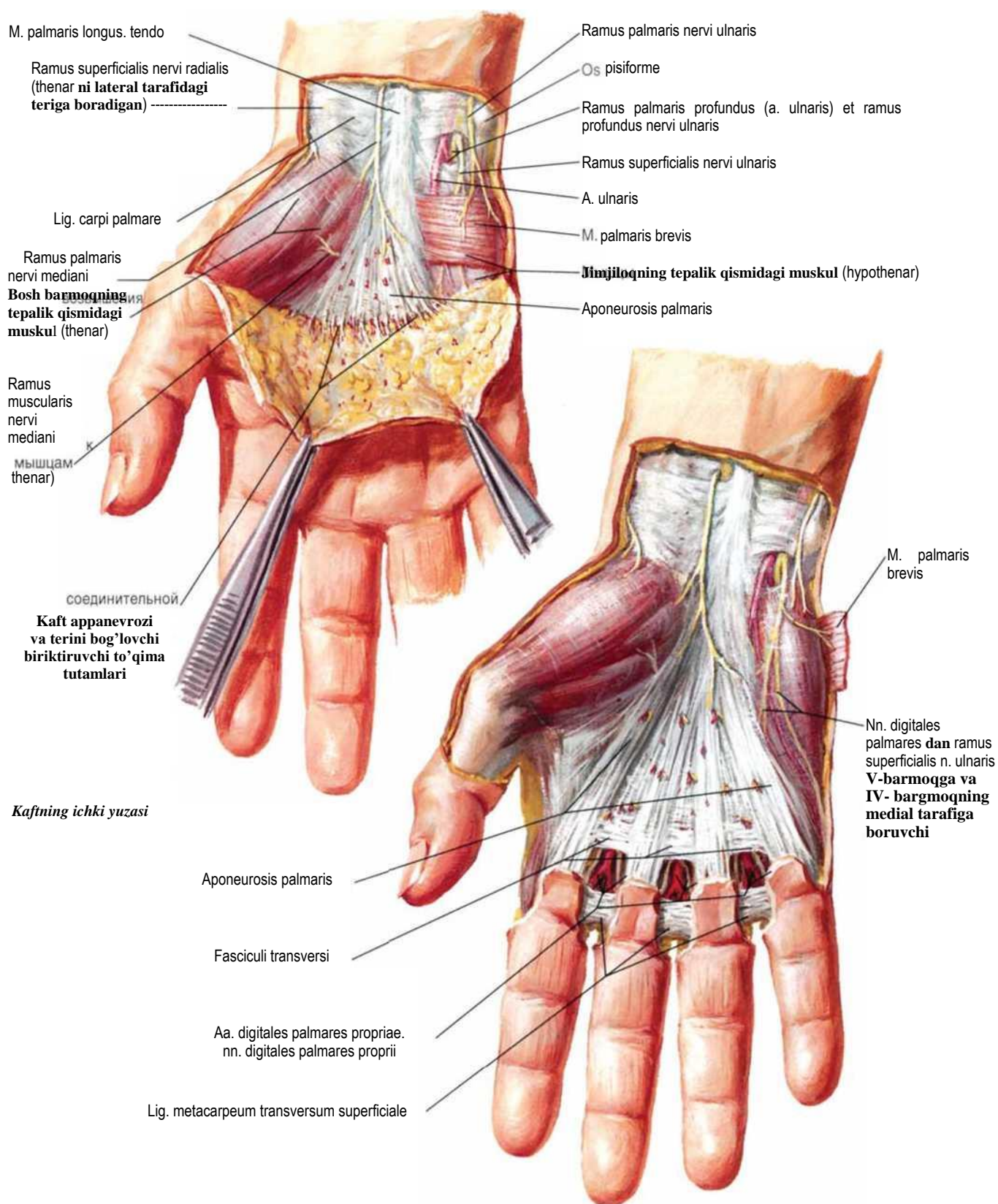
O'ng panja soxasi: oldindan ko'rinishi (kaftni tashqi yuzasi)



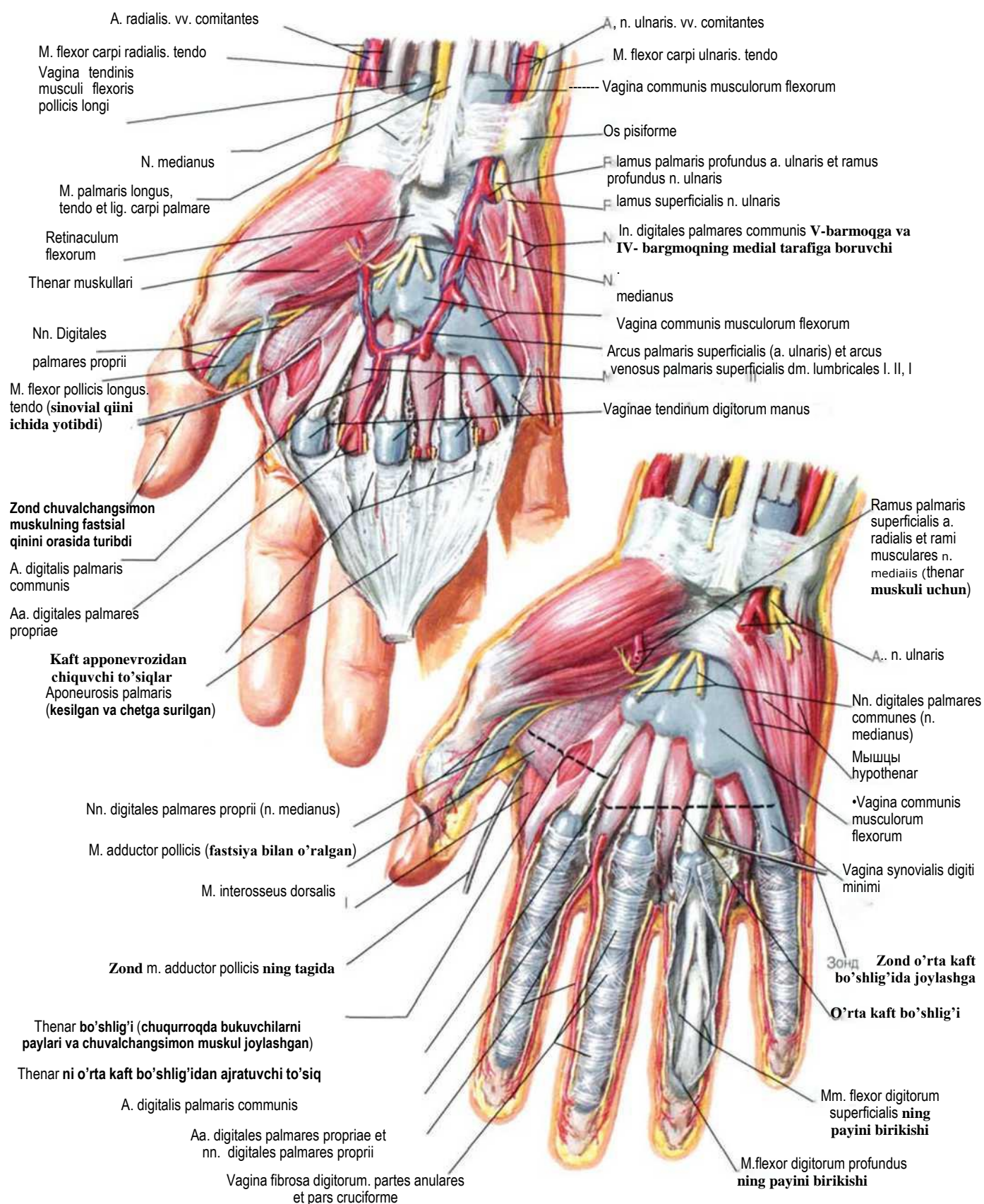
Kaft va falangalararo boylamlar



Kaftni ichki yuzasi: yuza qavatlarini ko'rinishi

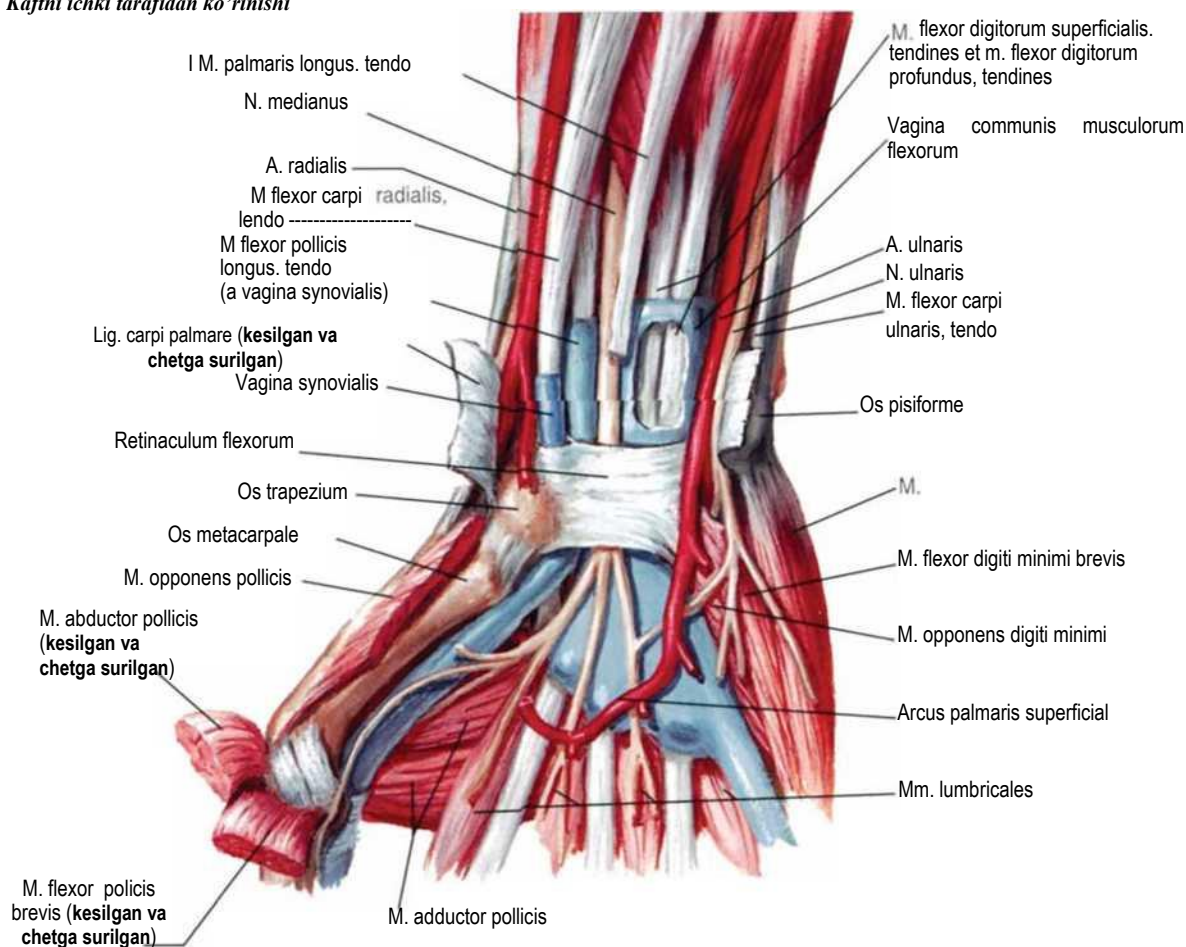


Kaftni ichki yuzasi: chuqur tuzilmalari

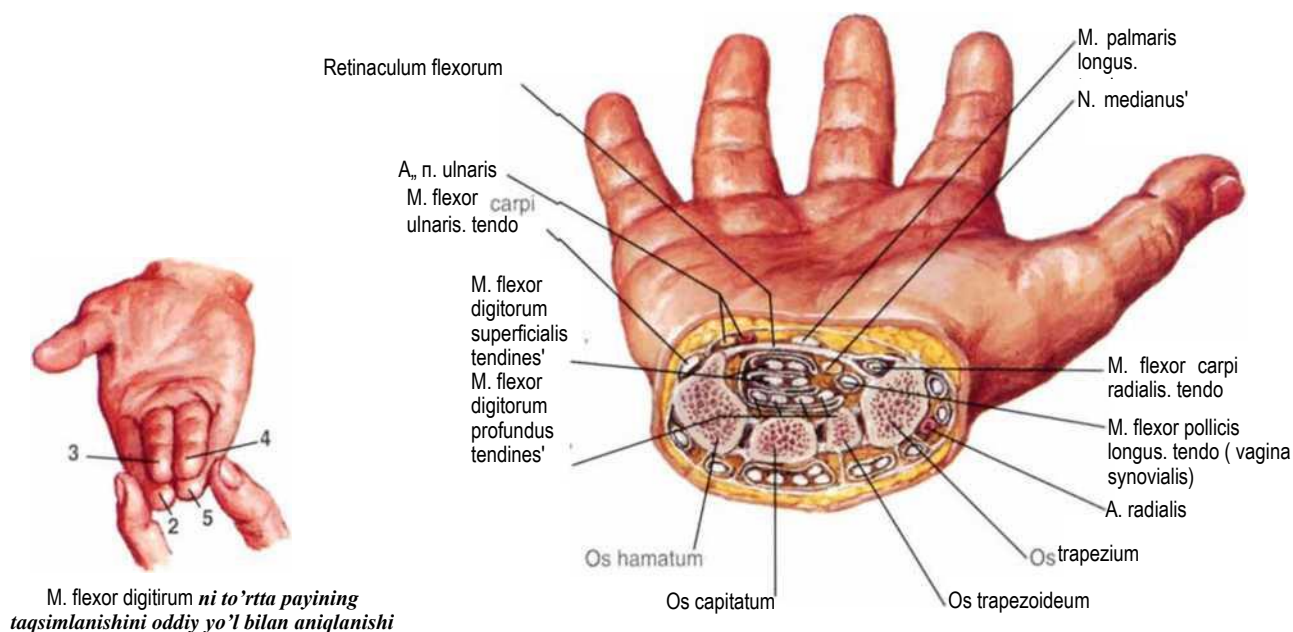


Panjaning bukuvchi muskullari paylari,arteriyalari va nervlari

Kaftni ichki tarafidan ko'rinishi

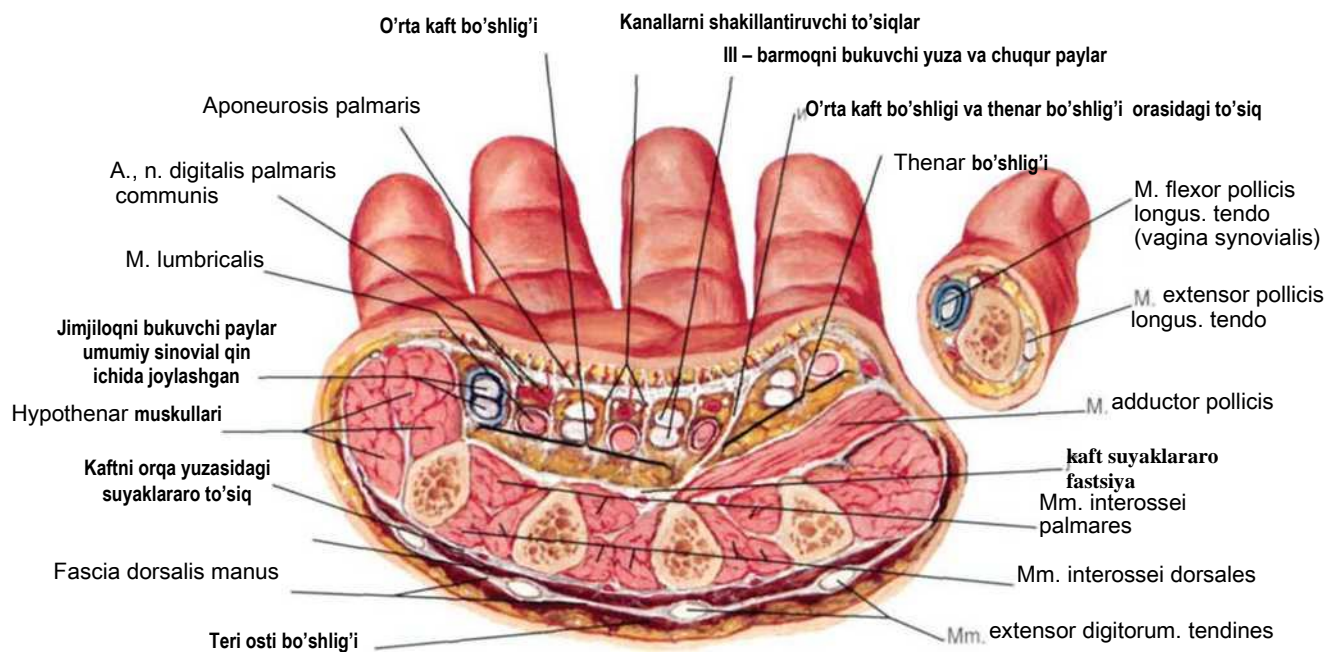
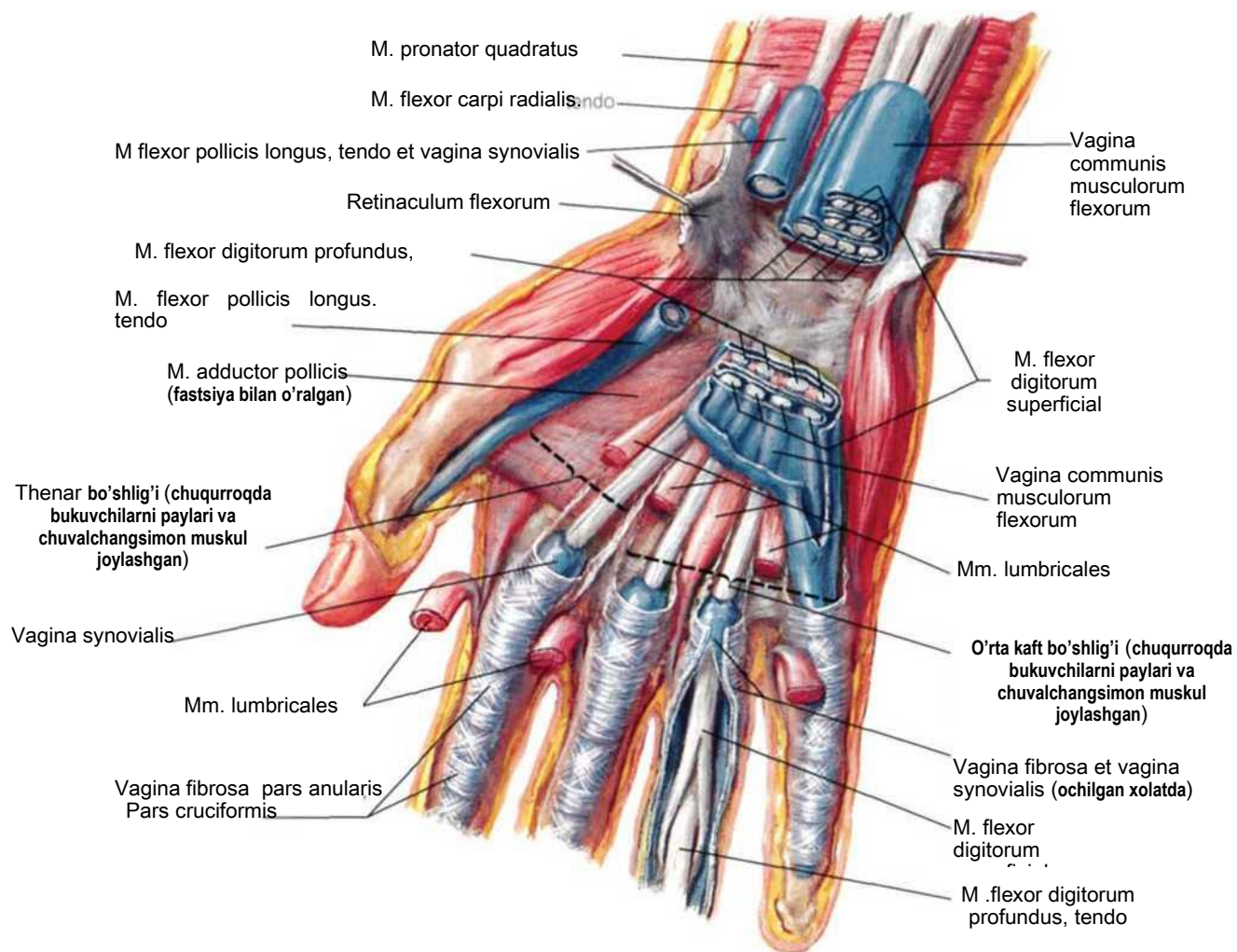


Kaft usti kanali orqali ko'ndalang kesma



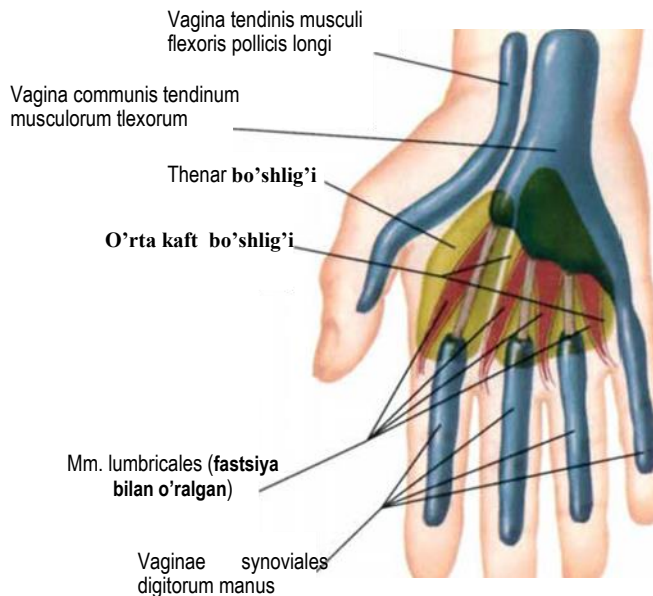
M. flexor digitorum ni to'rtta payining taqsimlanishini oddiy yo'l bilan aniqlanishi

Sinovial qin (vagina synoviales) va panja paylari

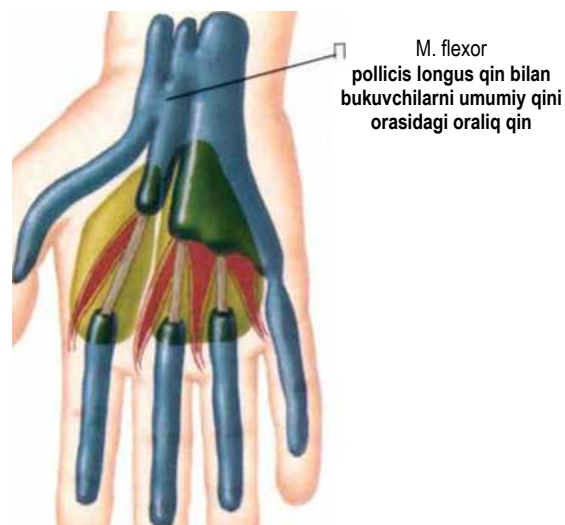


Mm. lumbricales, bo'shliq va sinovial qin: sxema

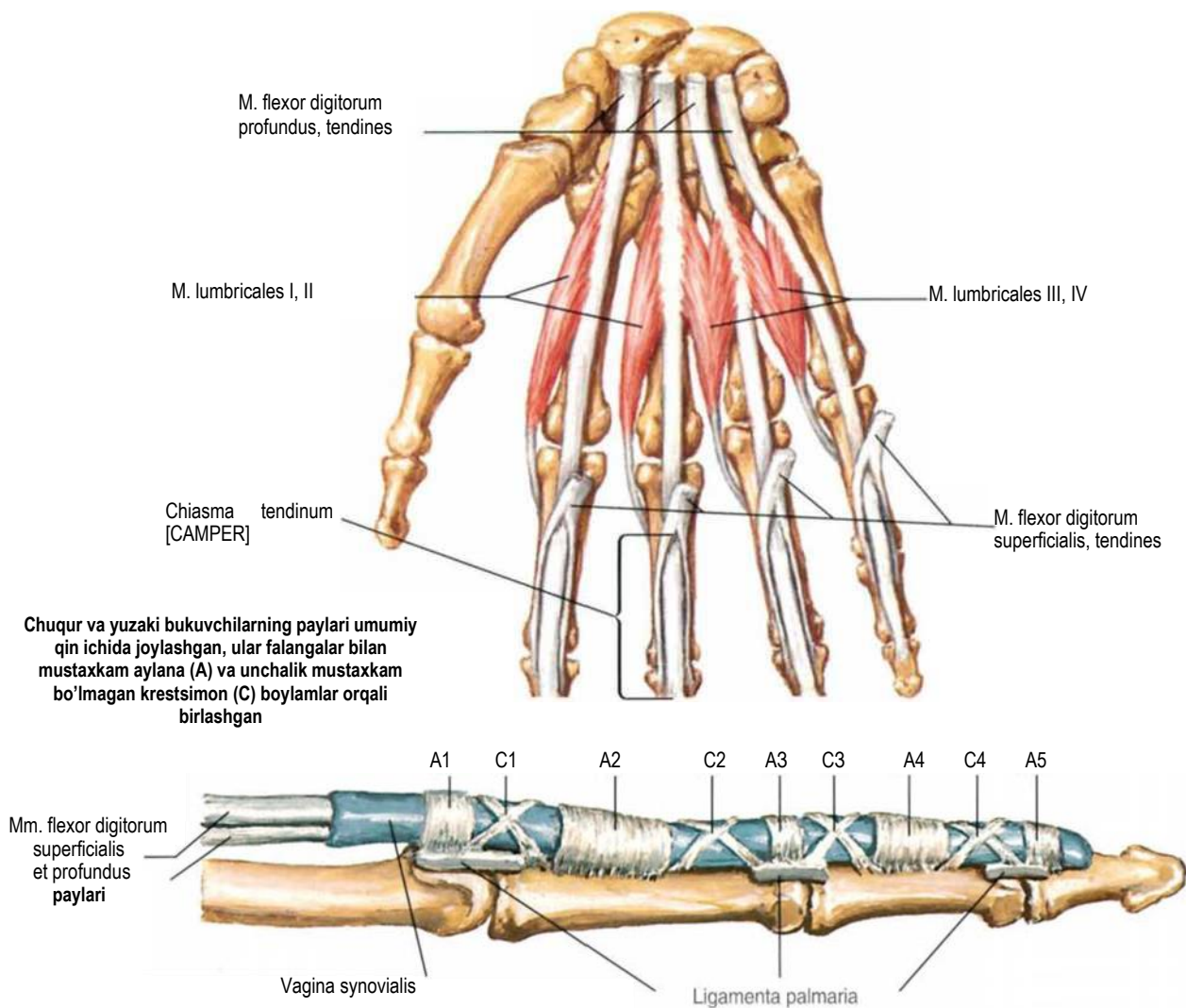
Oddiy tuzilishi



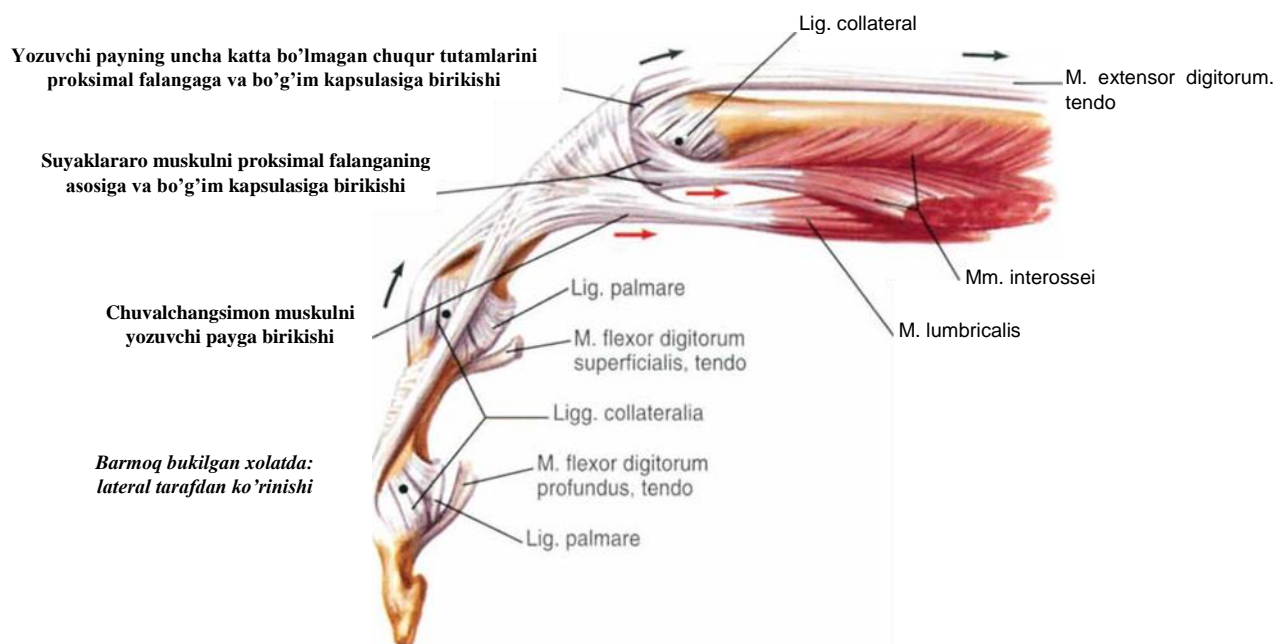
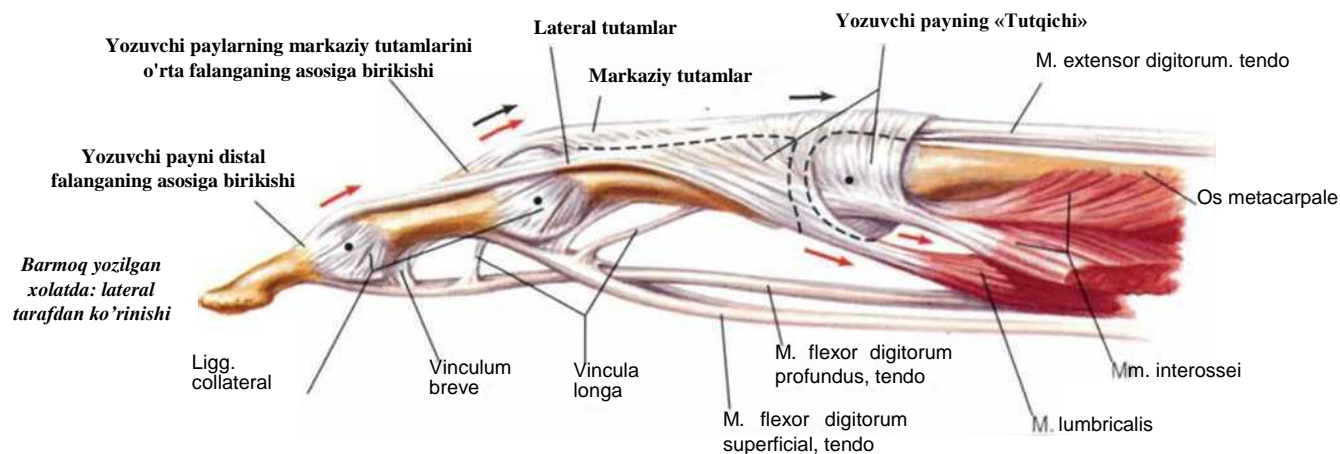
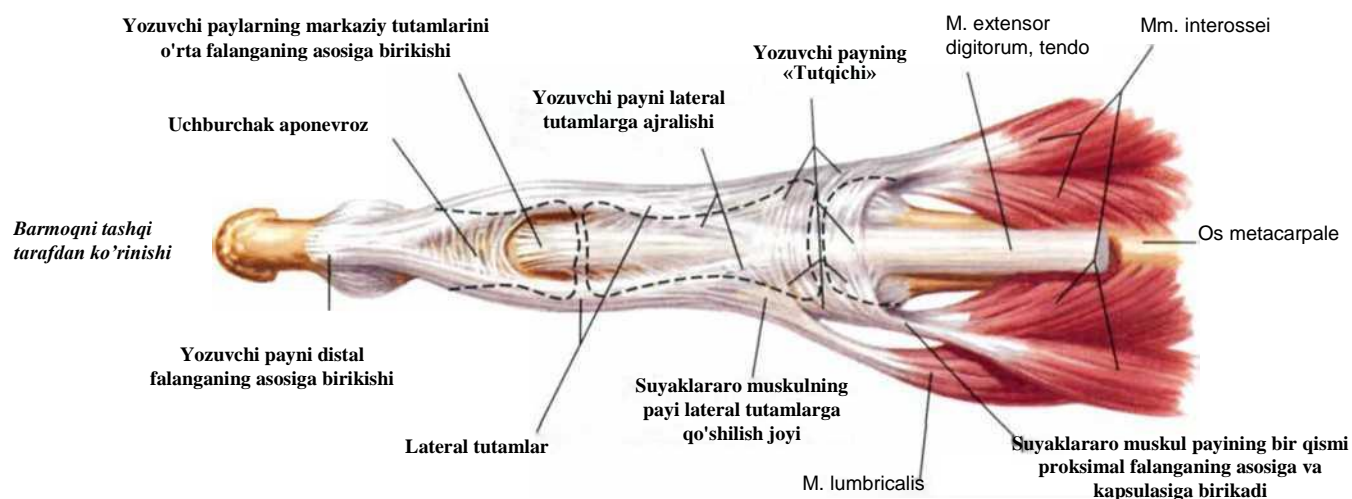
Umumiy variant



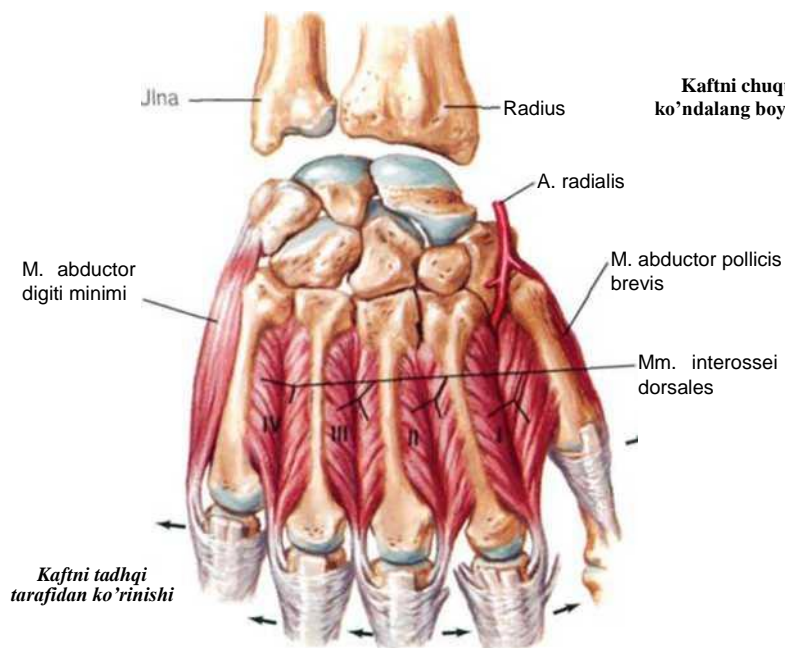
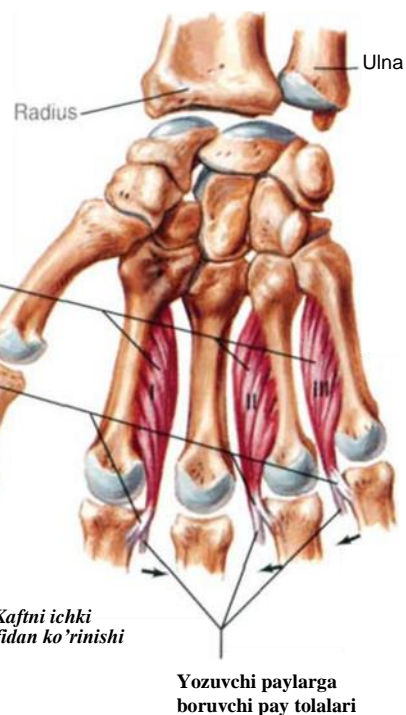
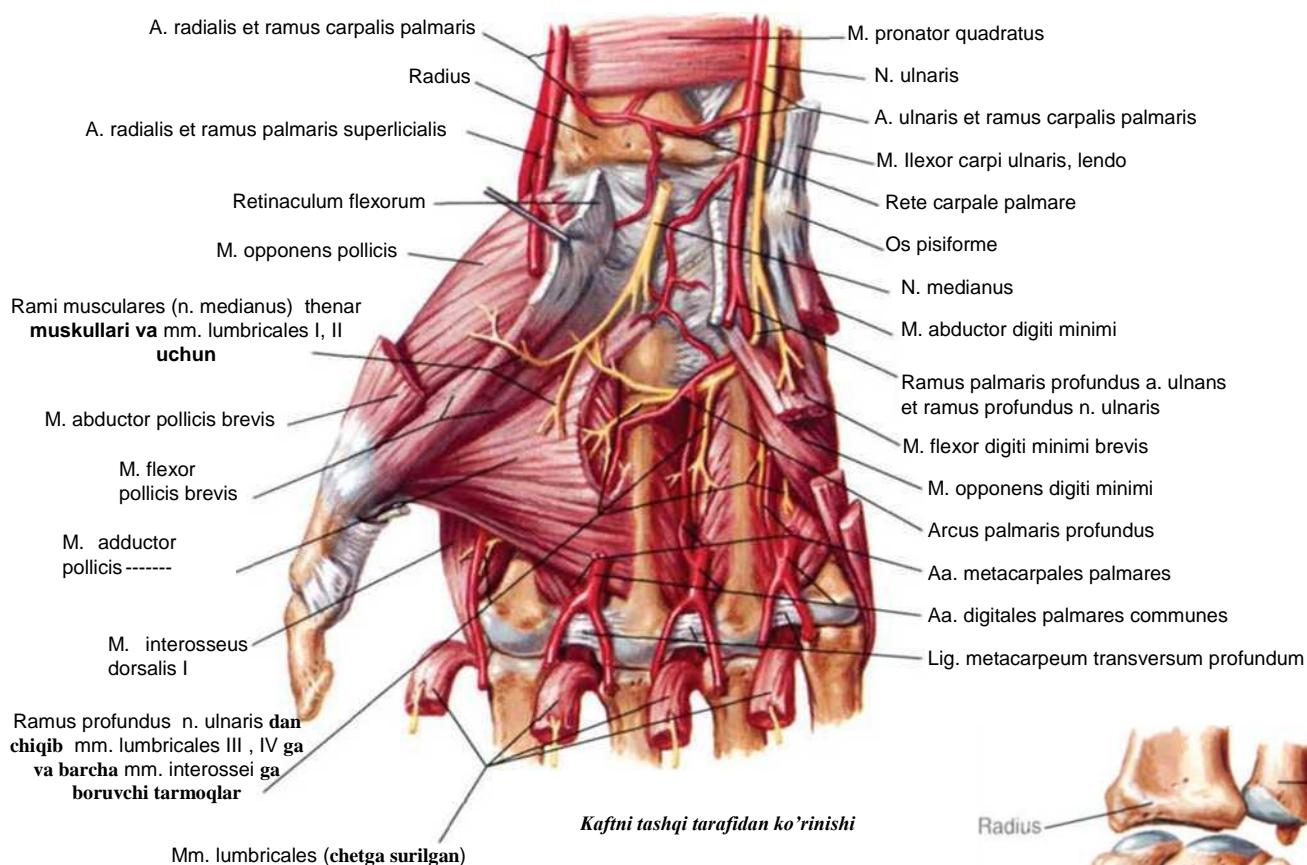
Chuvalchangsimon mukullar (mm. lumbricales): sxema



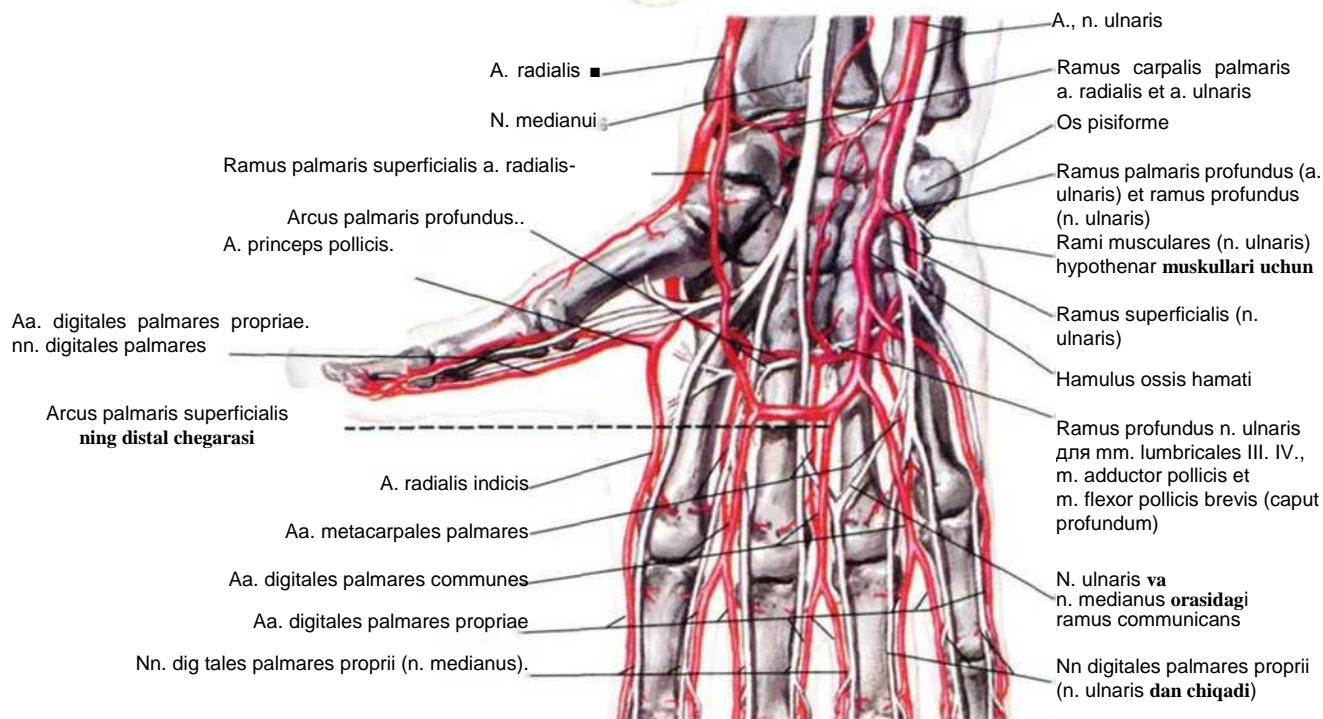
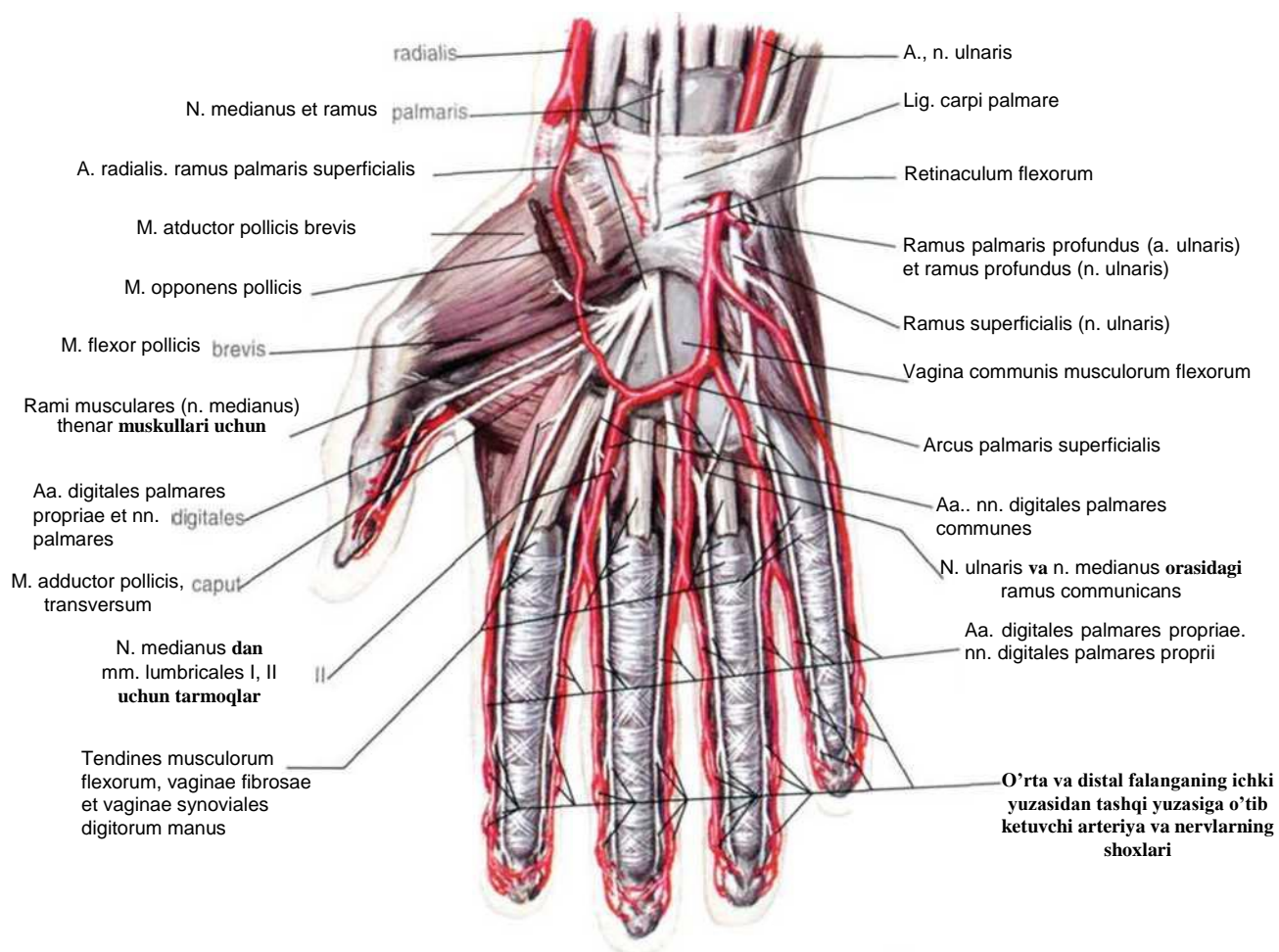
Barmoqlarni bukuvchi va yozuvchi paylar



Panjaning chuqur muskullari

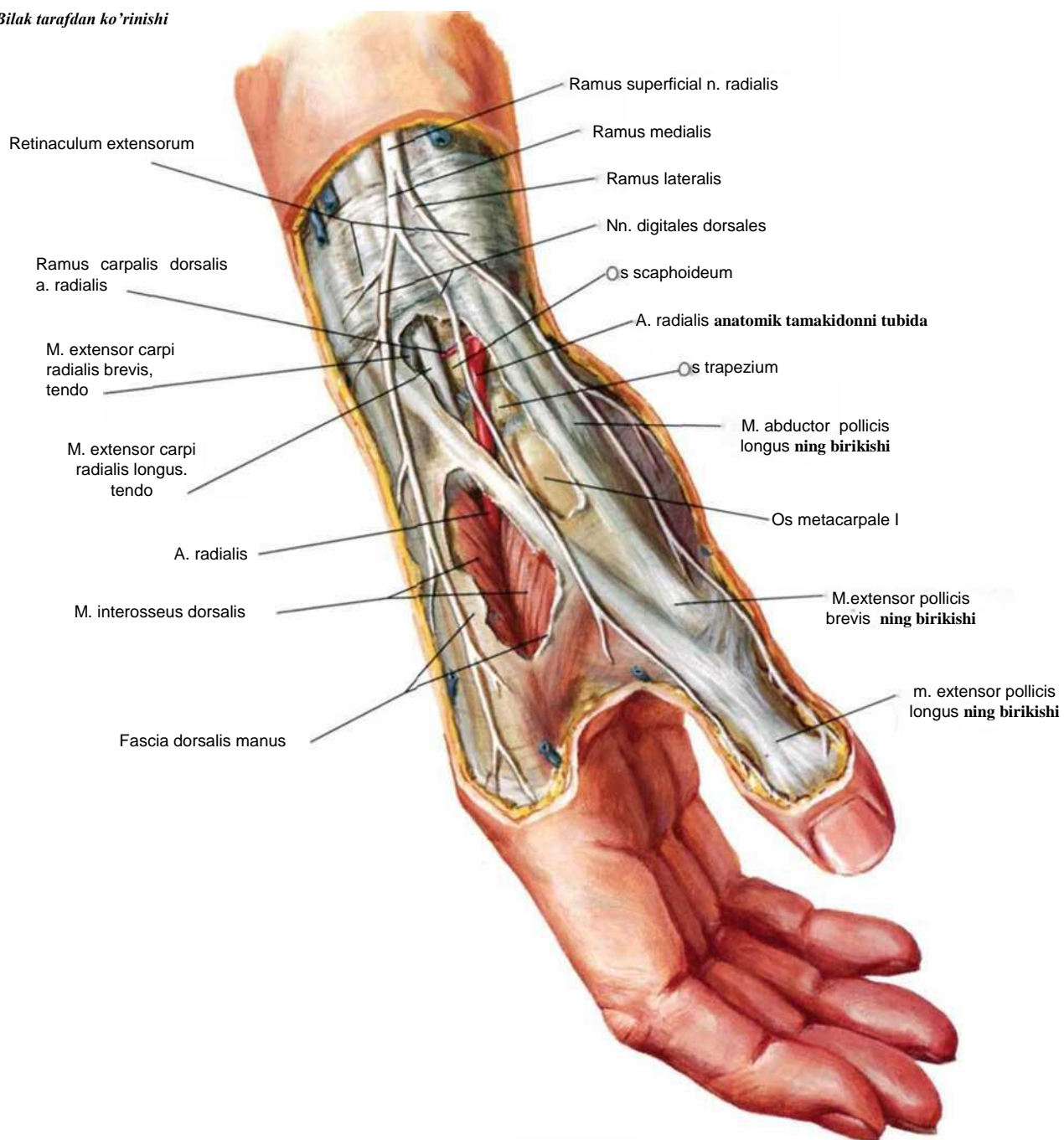


Panjaning arteriya va nervlari: kaftni ichki yuzasi



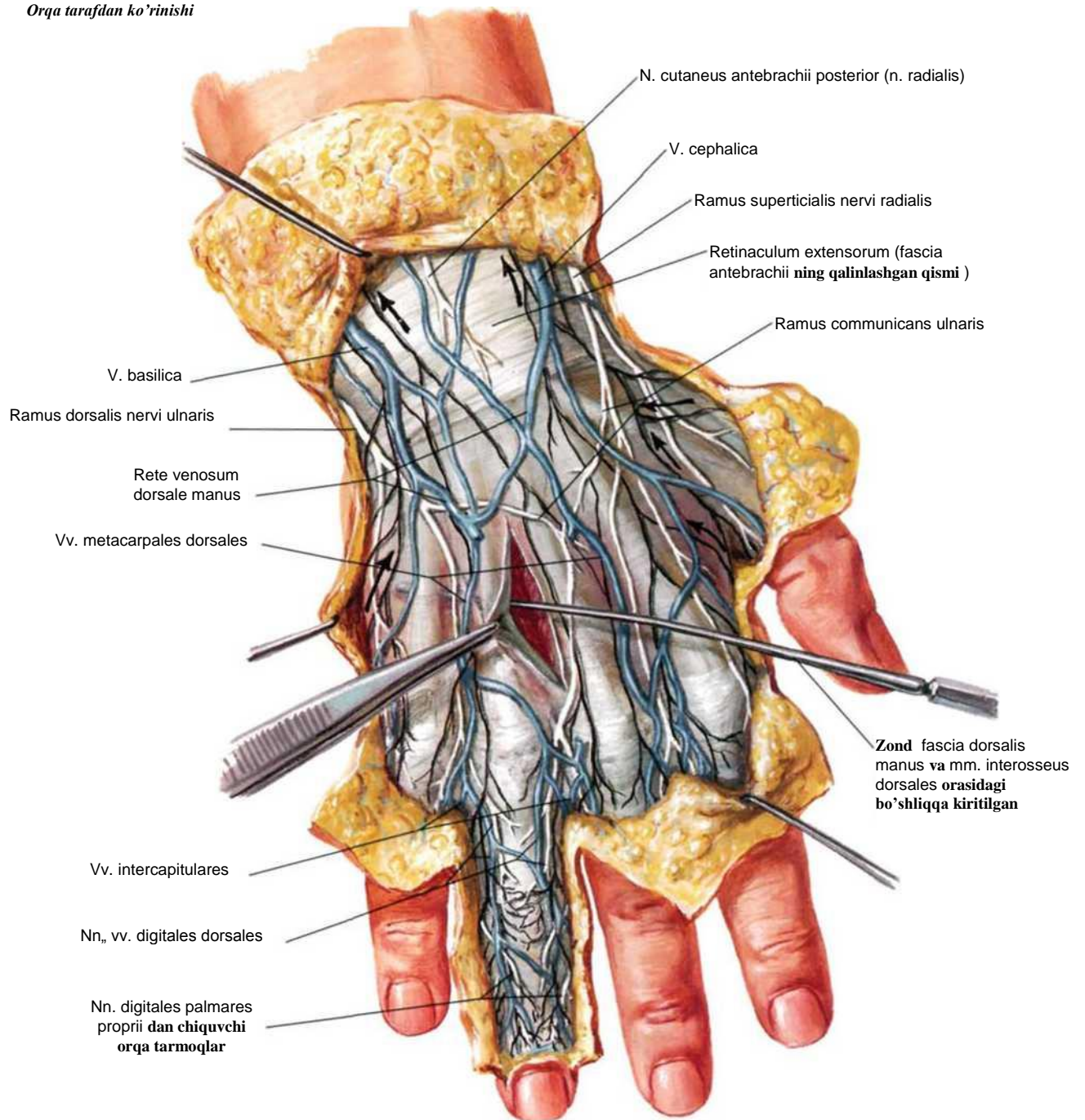
Panja: bilak tarafi

Bilak tarafidan ko'rinishi



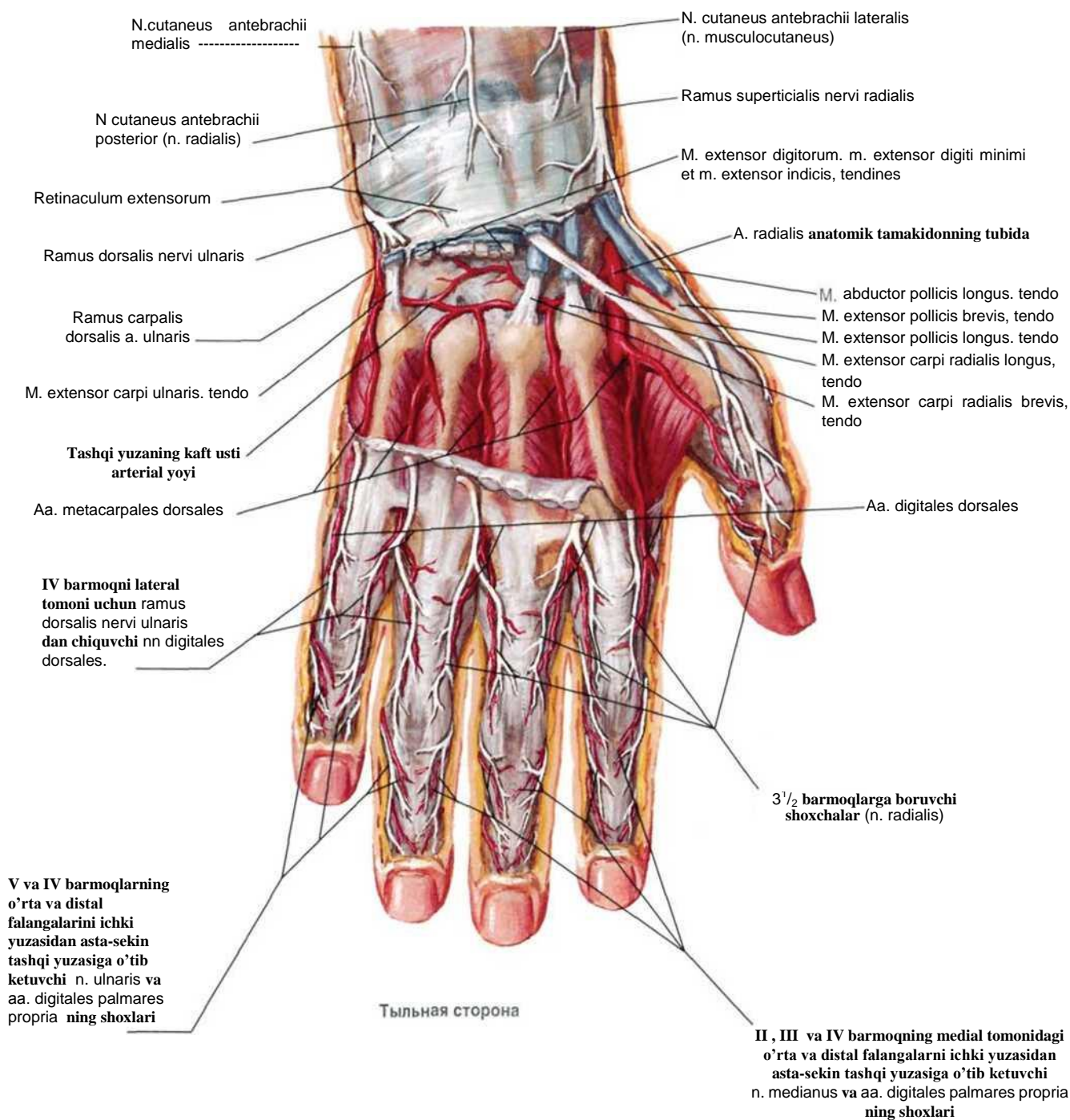
Panja: orqa tarafi

Orqa tarafdin ko'rinishi



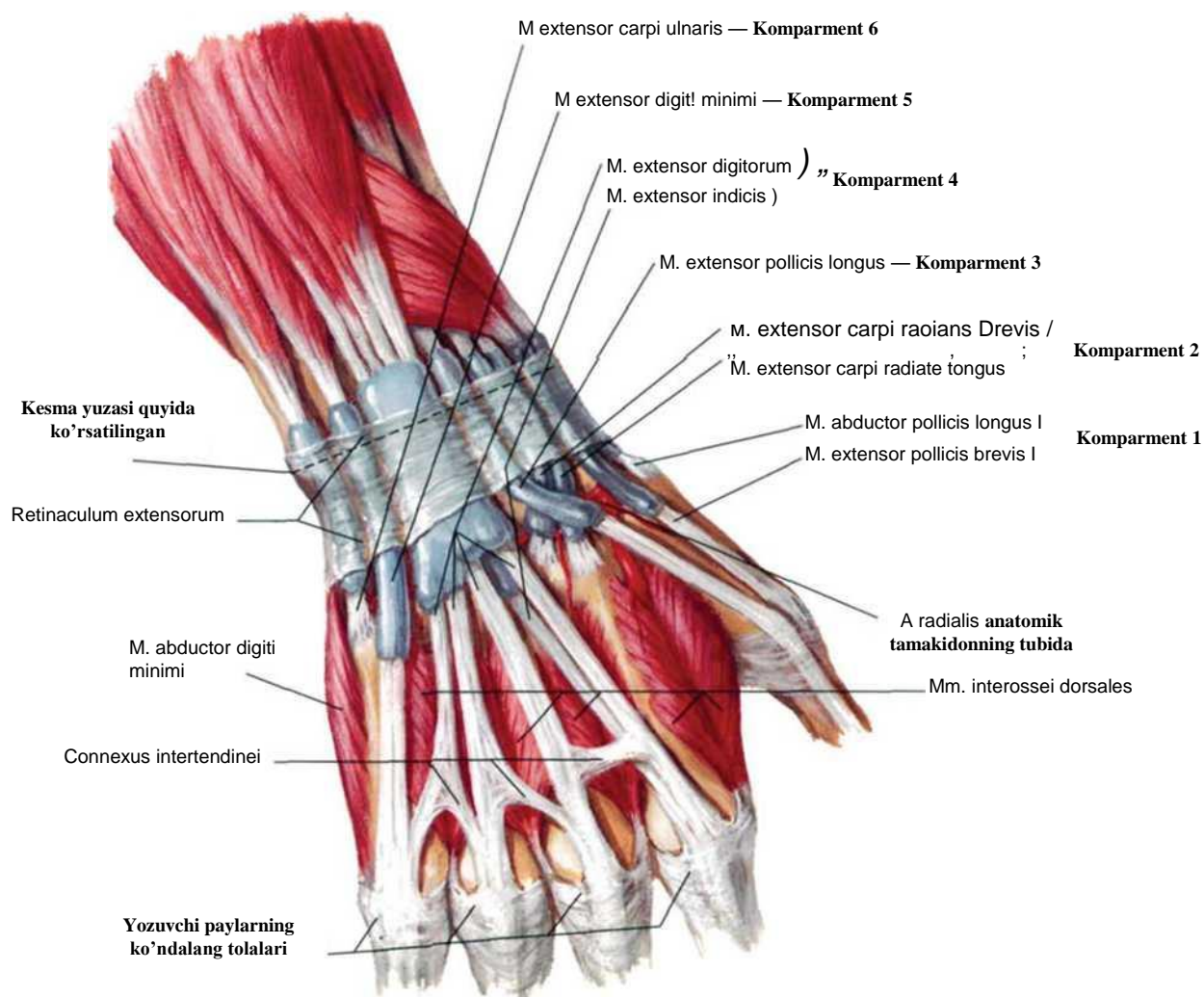
Limfa tomirlari qora rangda ifodalangan, ularni oqimi strelkalar bilan ko'rsatilingan

Panja: chuqur tuzulmalari

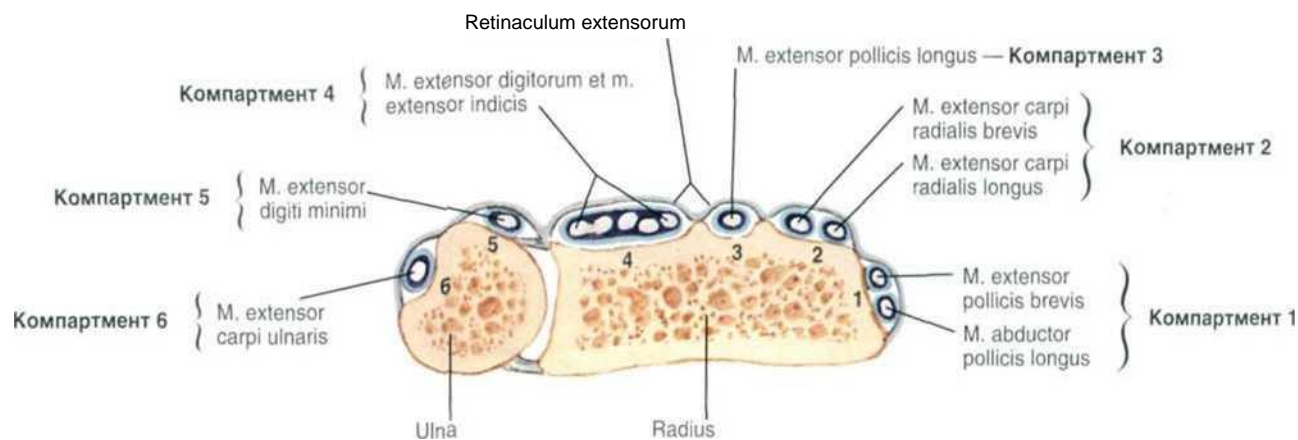


Panjaning orqa tarafidagi yozuvchilarning paylari

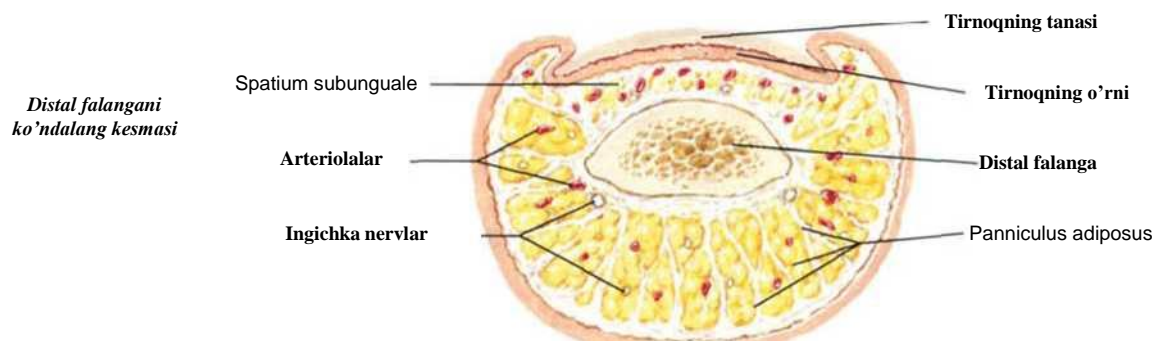
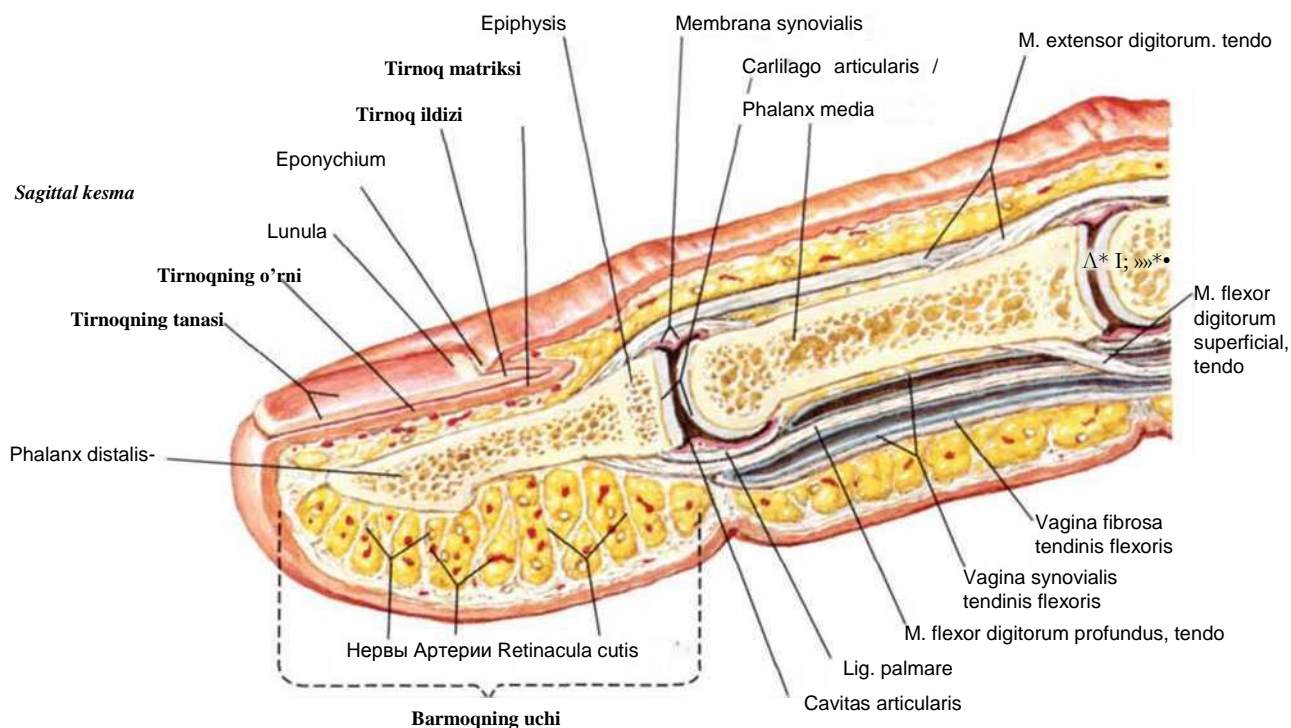
Orqa tarafdin ko'rinishi



Bilak soxasining distal qismini ko'ndalang kesmasi

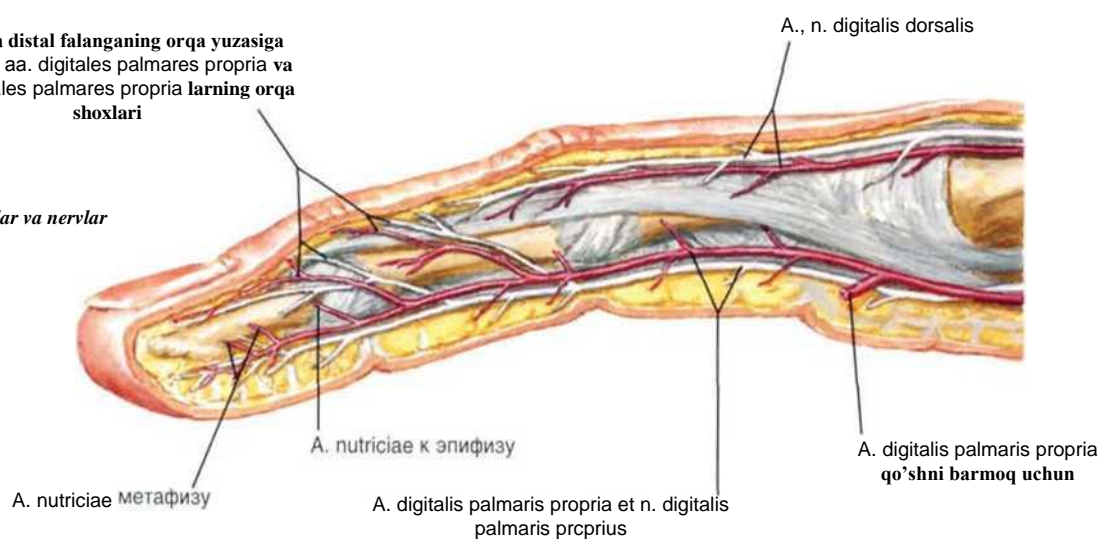


Barmoqlar(digiti)



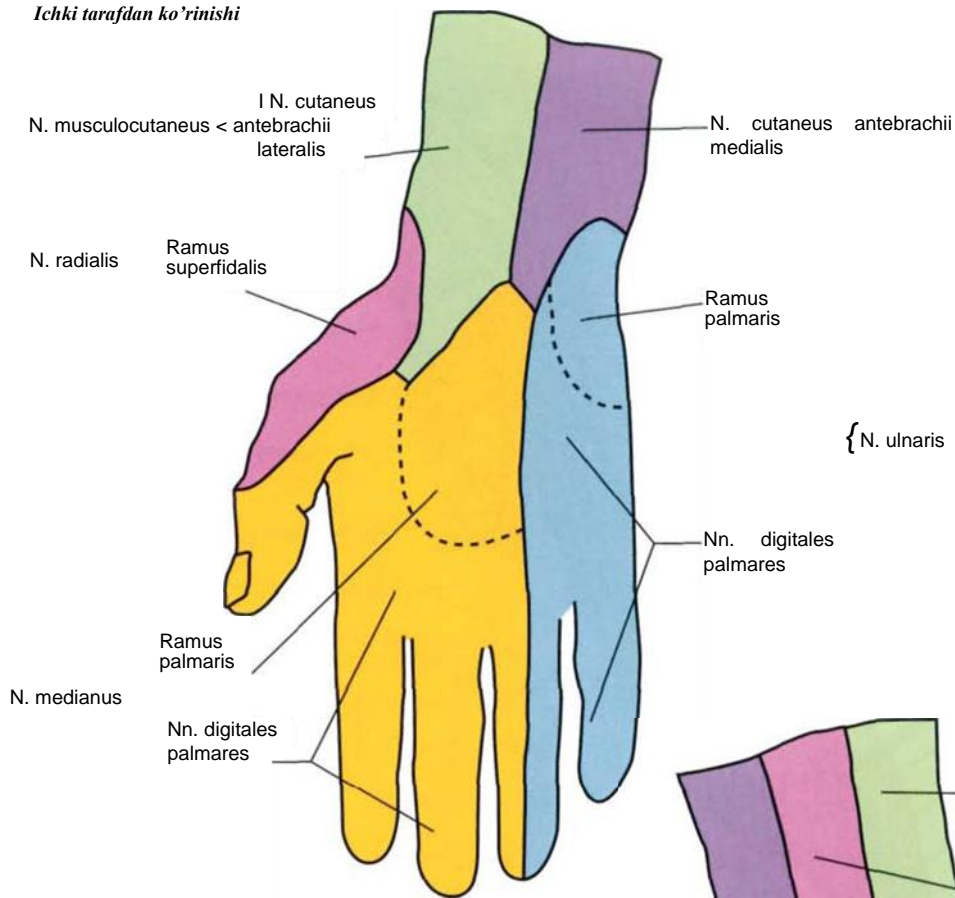
O'rta va distal falanganing orqa yuzasiga boruvchi aa. digitales palmares propria va nn. digitales palmares propria larning orqa shoxlari

Arteriyalar va nervlar



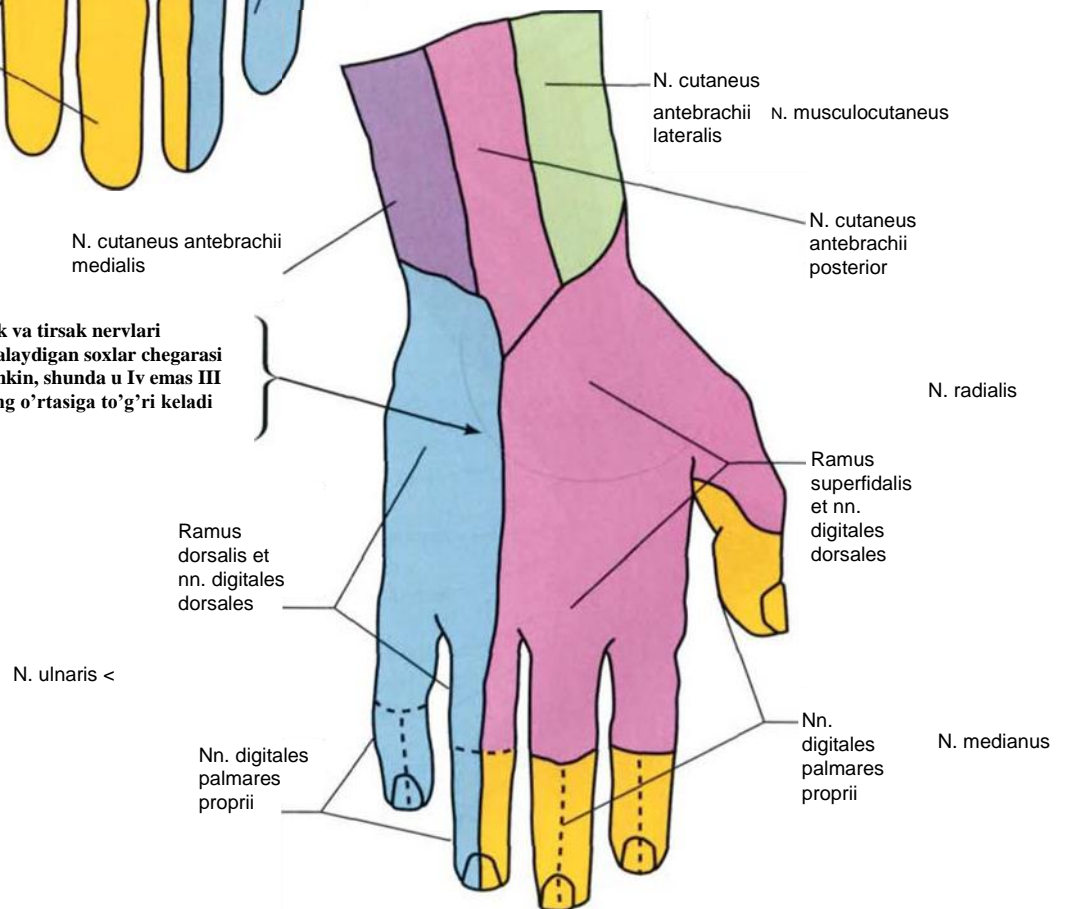
Panja terisi innervatsiyasi

Ichki tarafdin ko'rinishi



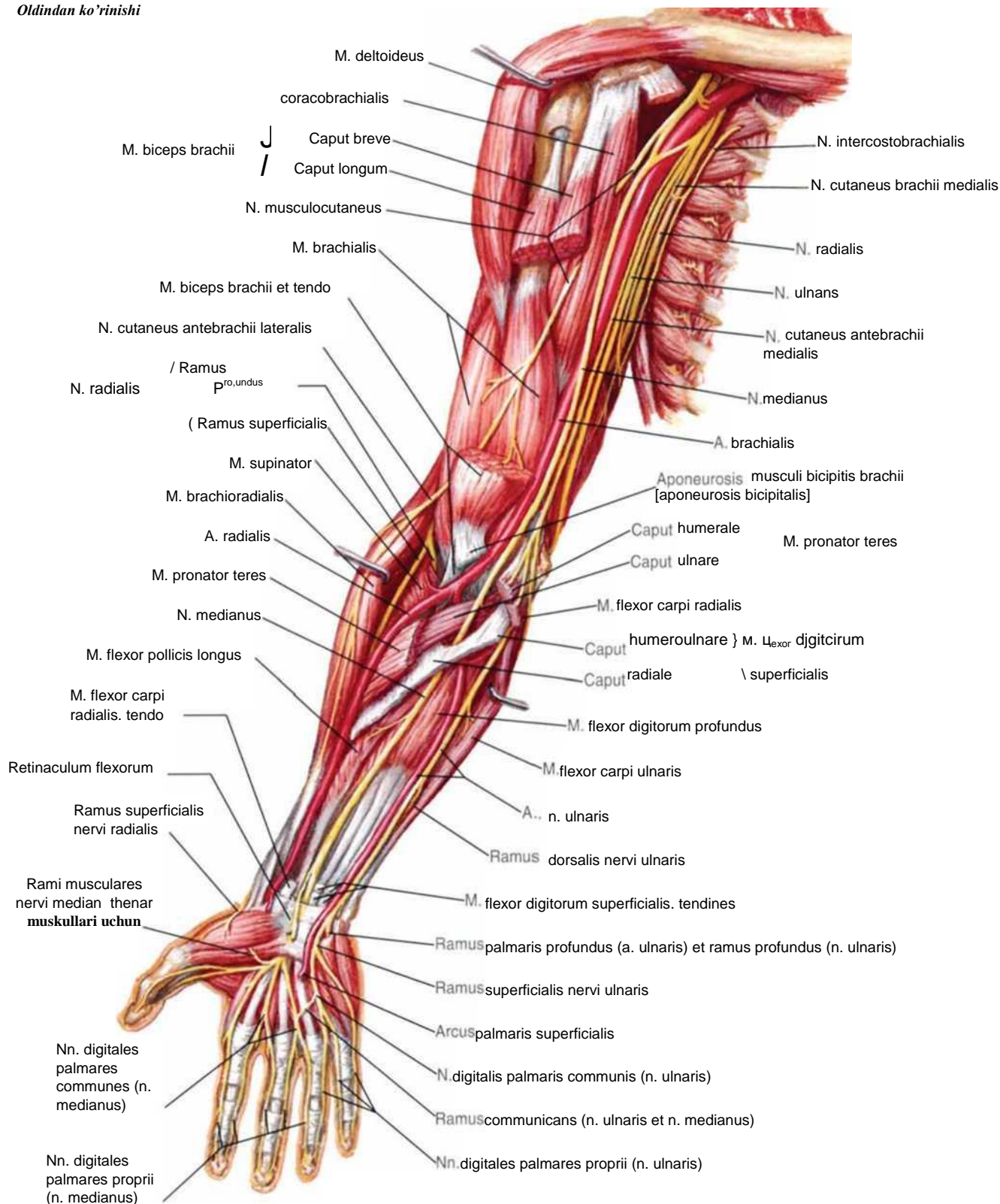
Orqa tarafdin ko'rinishi

**Bilak va tirsak nervlari
innervatsiyalaydigan soxlar chegarasi
siljishi mumkin, shunda u Iv emas III
barmoqning o'rtasiga to'g'ri keladi**



Qo'l soxasining arteriya va nervlari

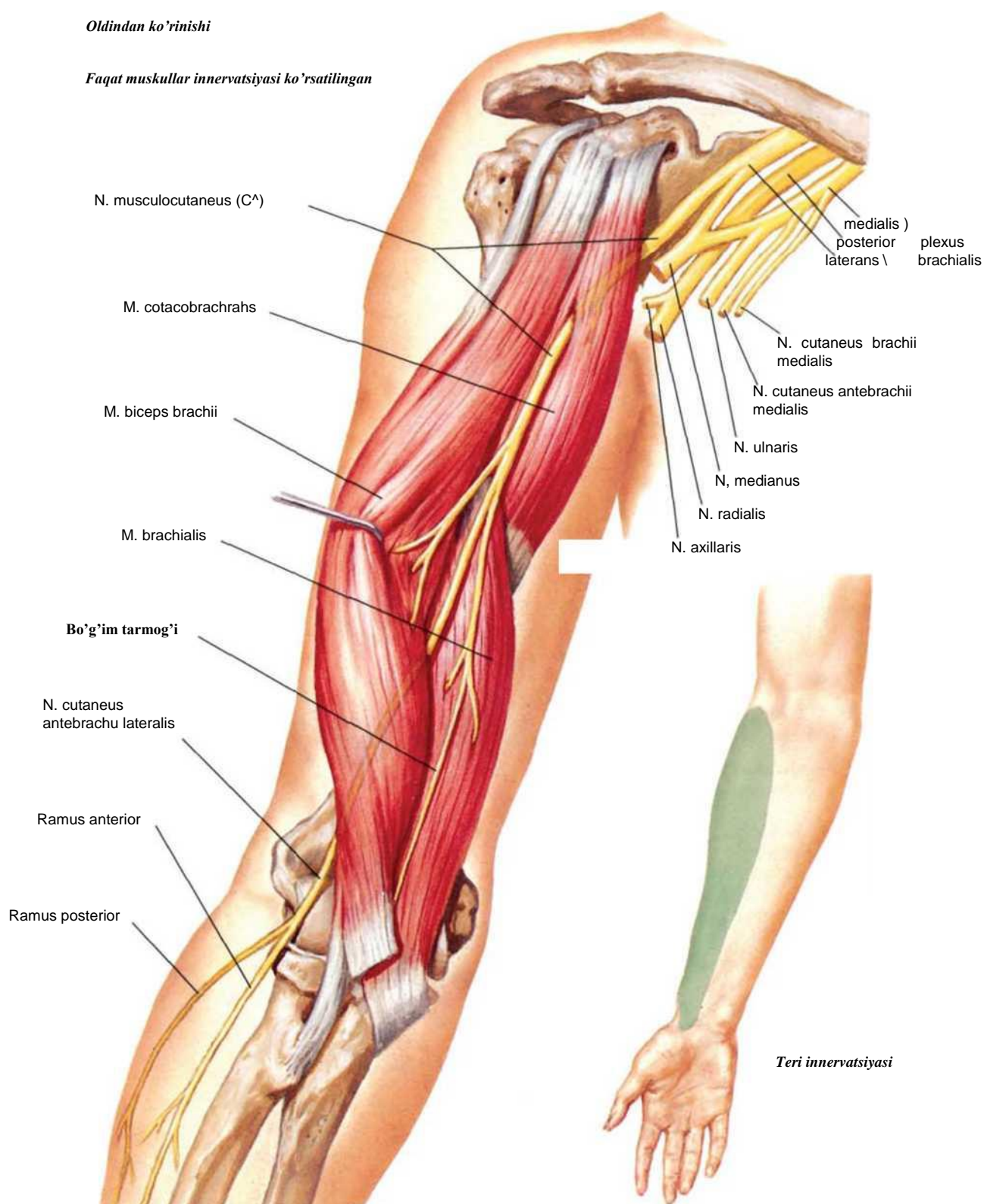
Oldindan ko'rinishi



Mushak-teri nervi (n. musculocutaneus)

Oldindan ko'rinishi

Faqat muskullar innervatsiyasi ko'rsatilingan

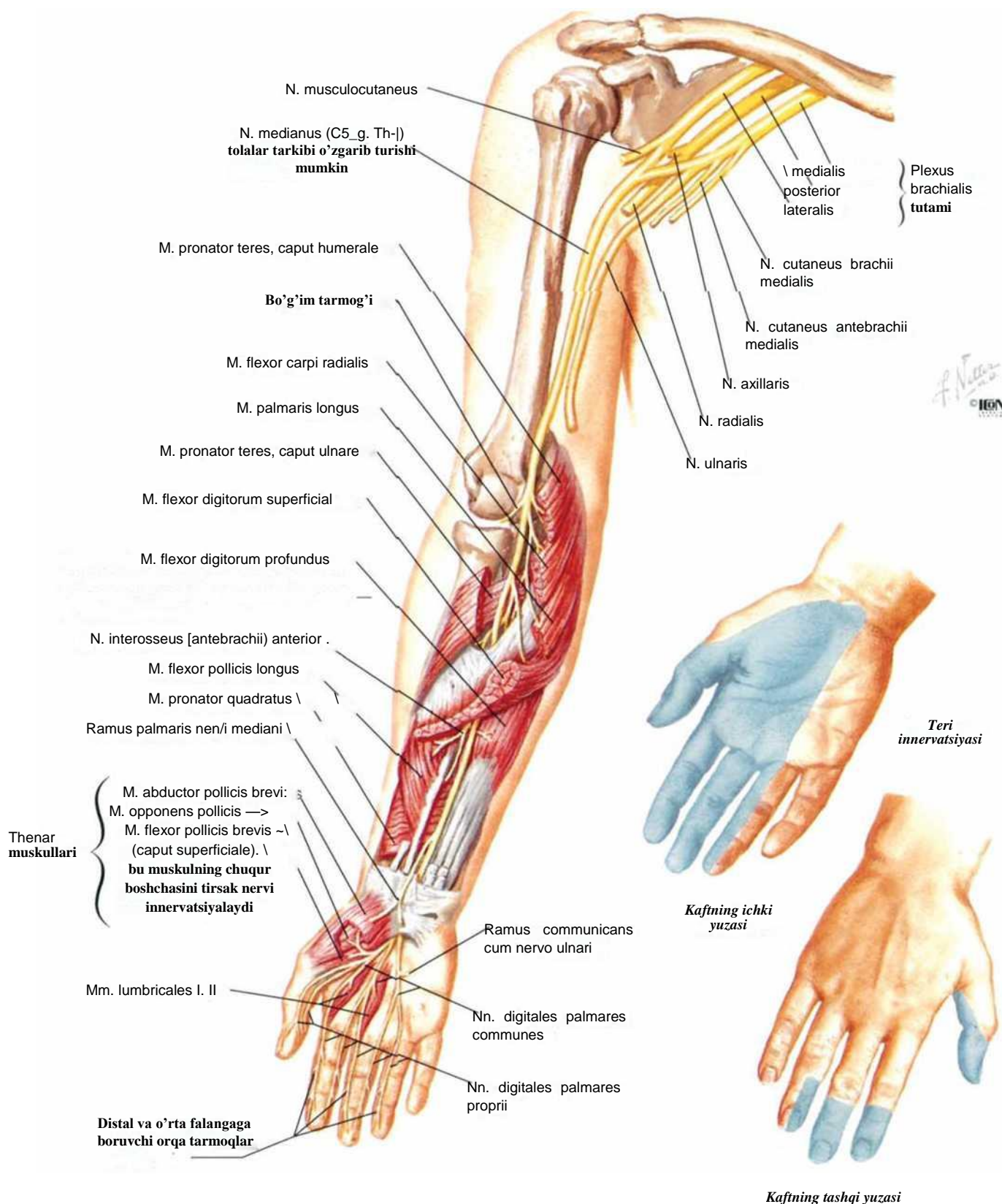


Ichki tarafdan ko'rinishi

O'rta nerv (n. medianus)

Oldindan ko'rinishi

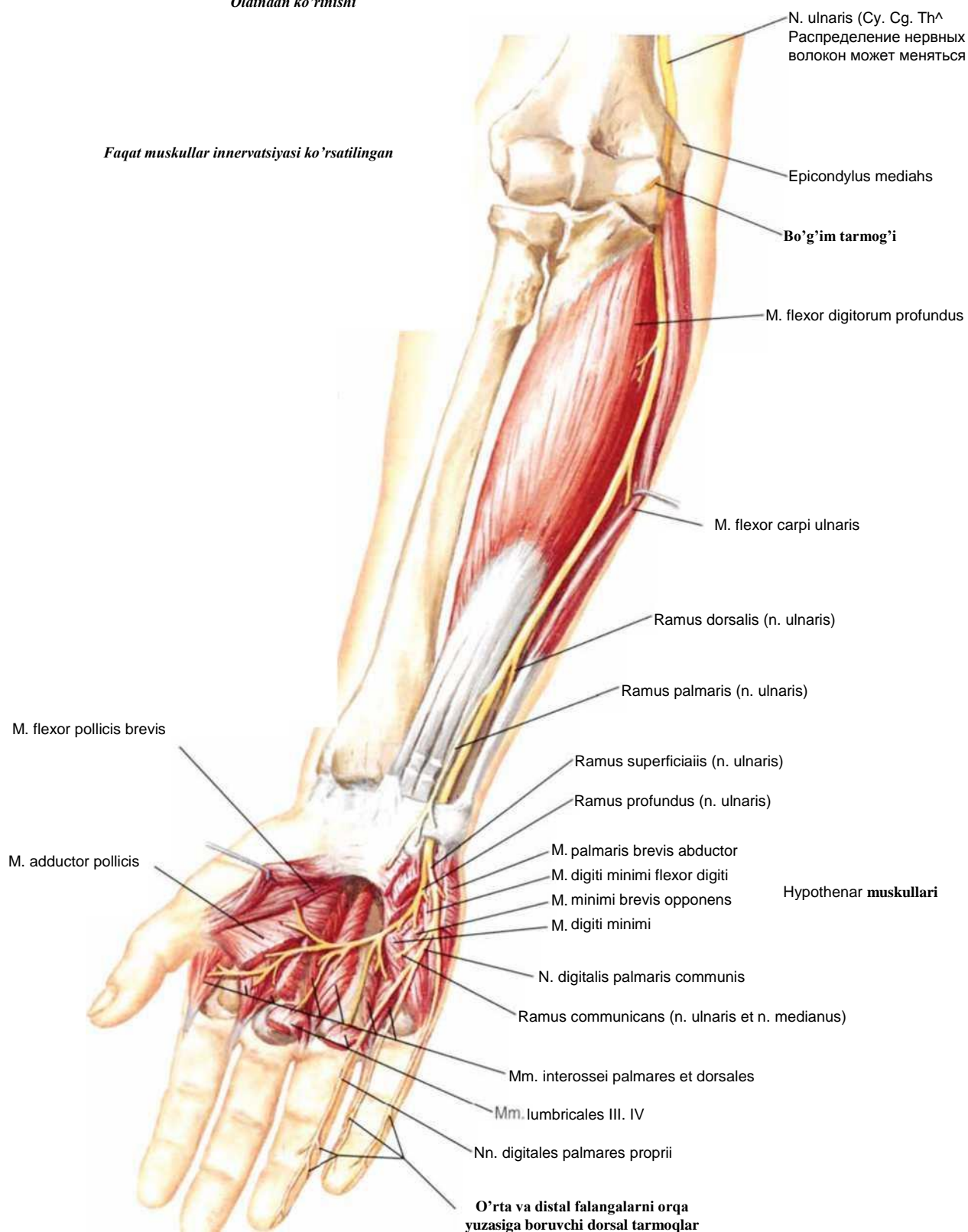
Faqat muskullar innervatsiyasi ko'rsatilingan



Tirsak nervi (n. ulnaris)

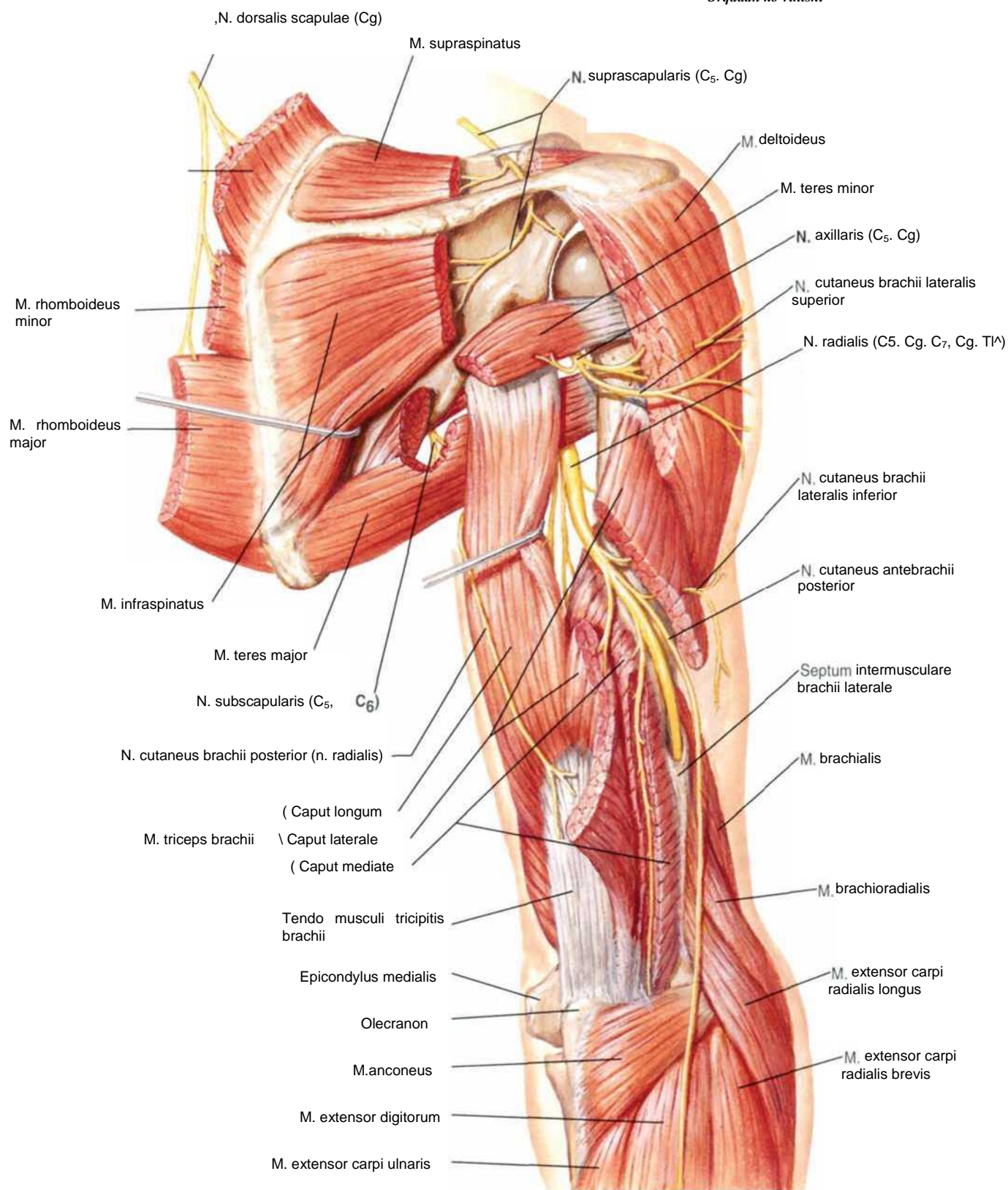
Oldindan ko'rinishi

Faqat muskullar innervatsiyasi ko'rsatilingan

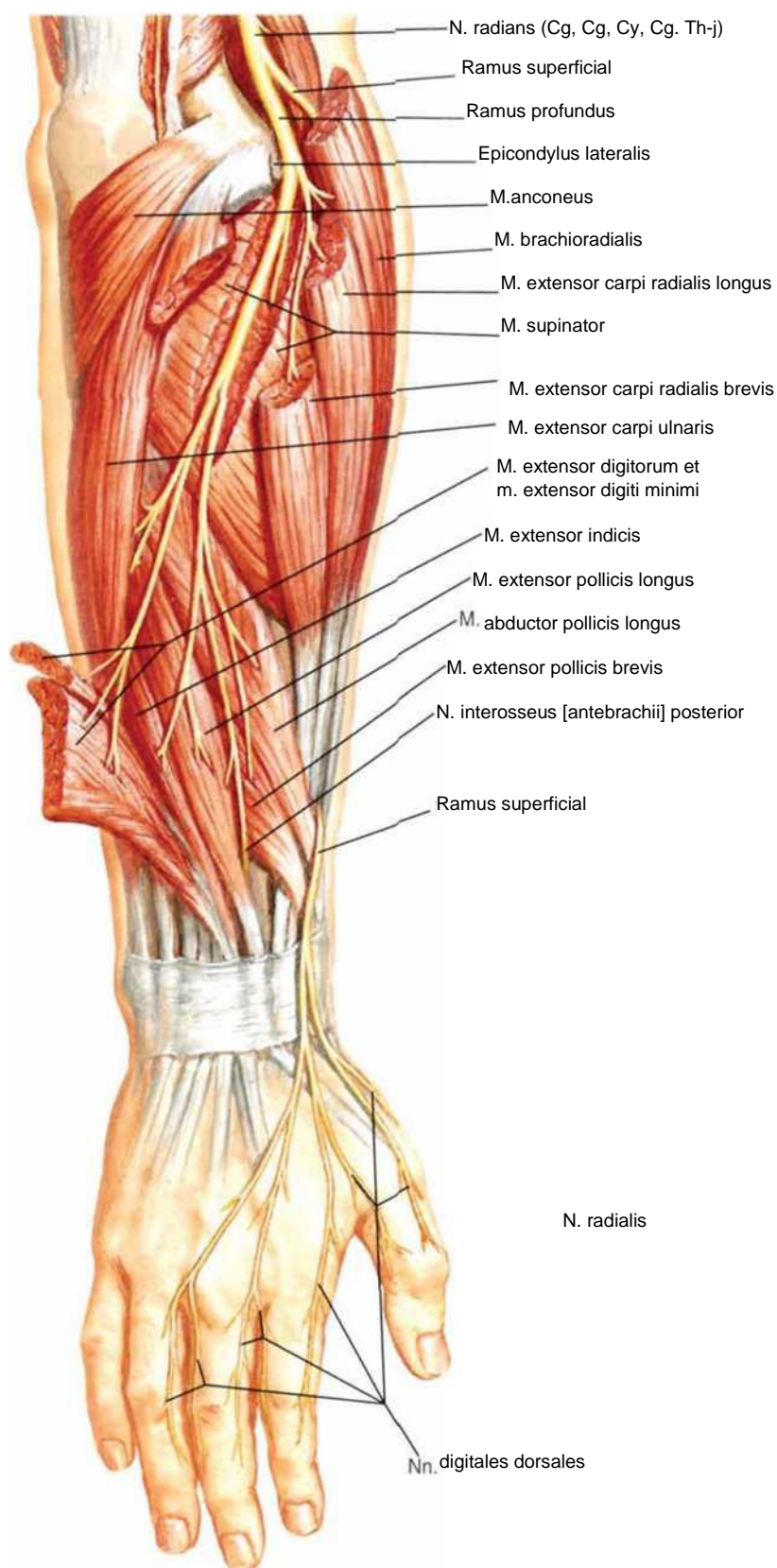


Elka kamari va elkaning orqa guruhi muskullari

Orqadan ko'rinishi



Bilak nervi (n. radialis): panja va bilak soxasi innervatsiyasi

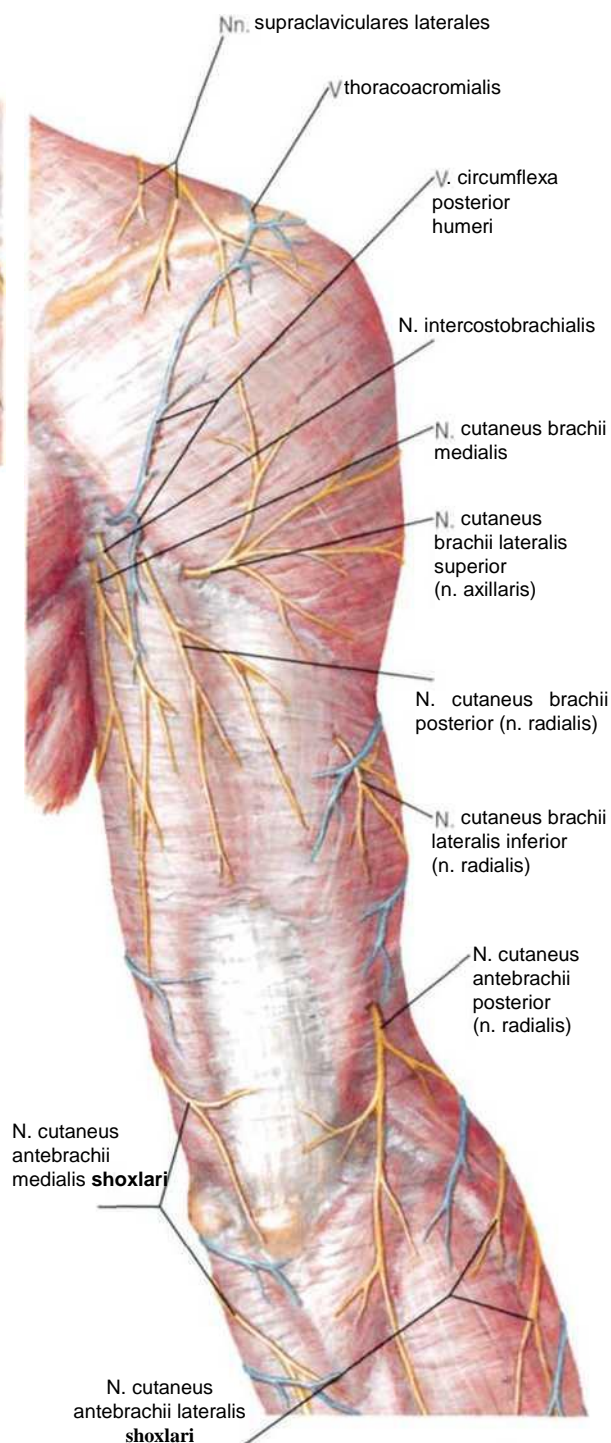
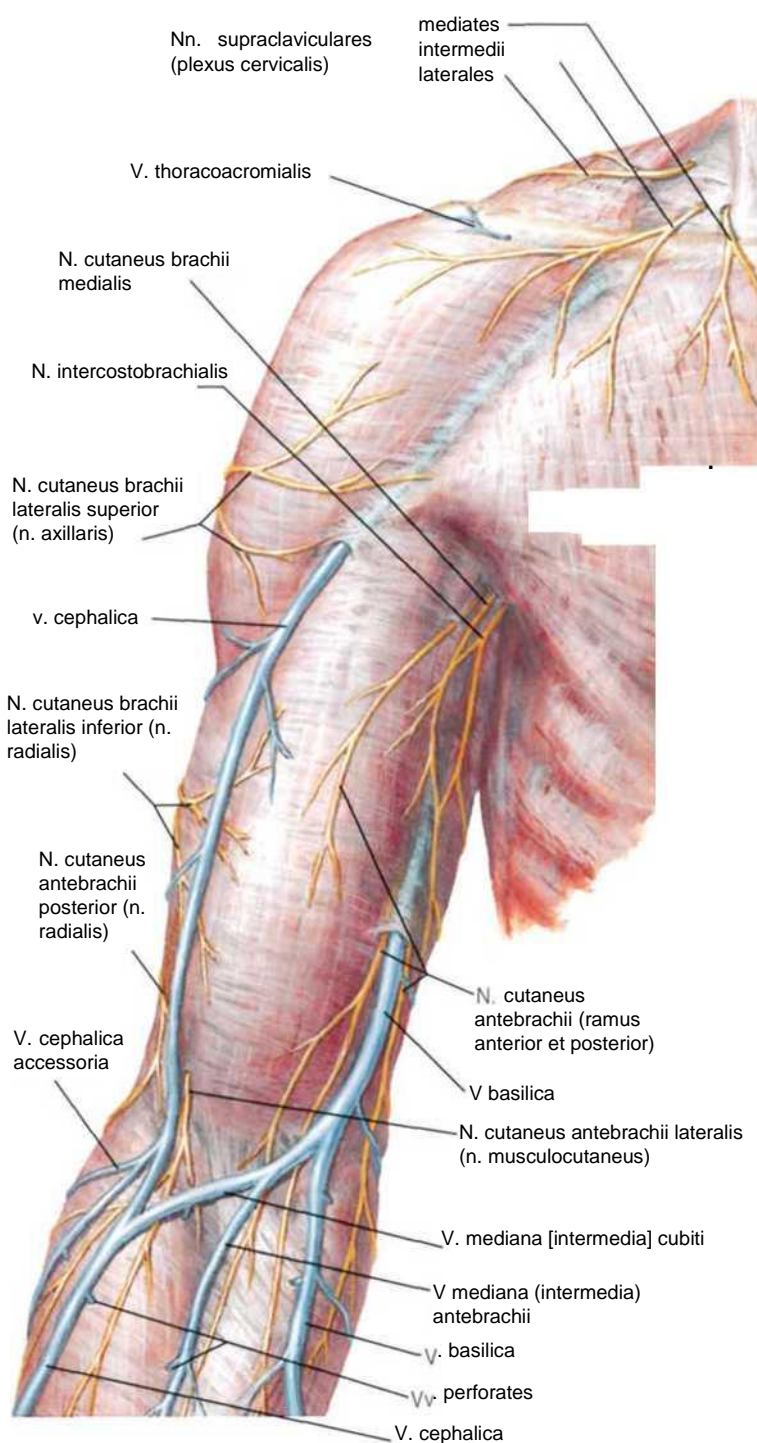


Orqadan ko'rinishi

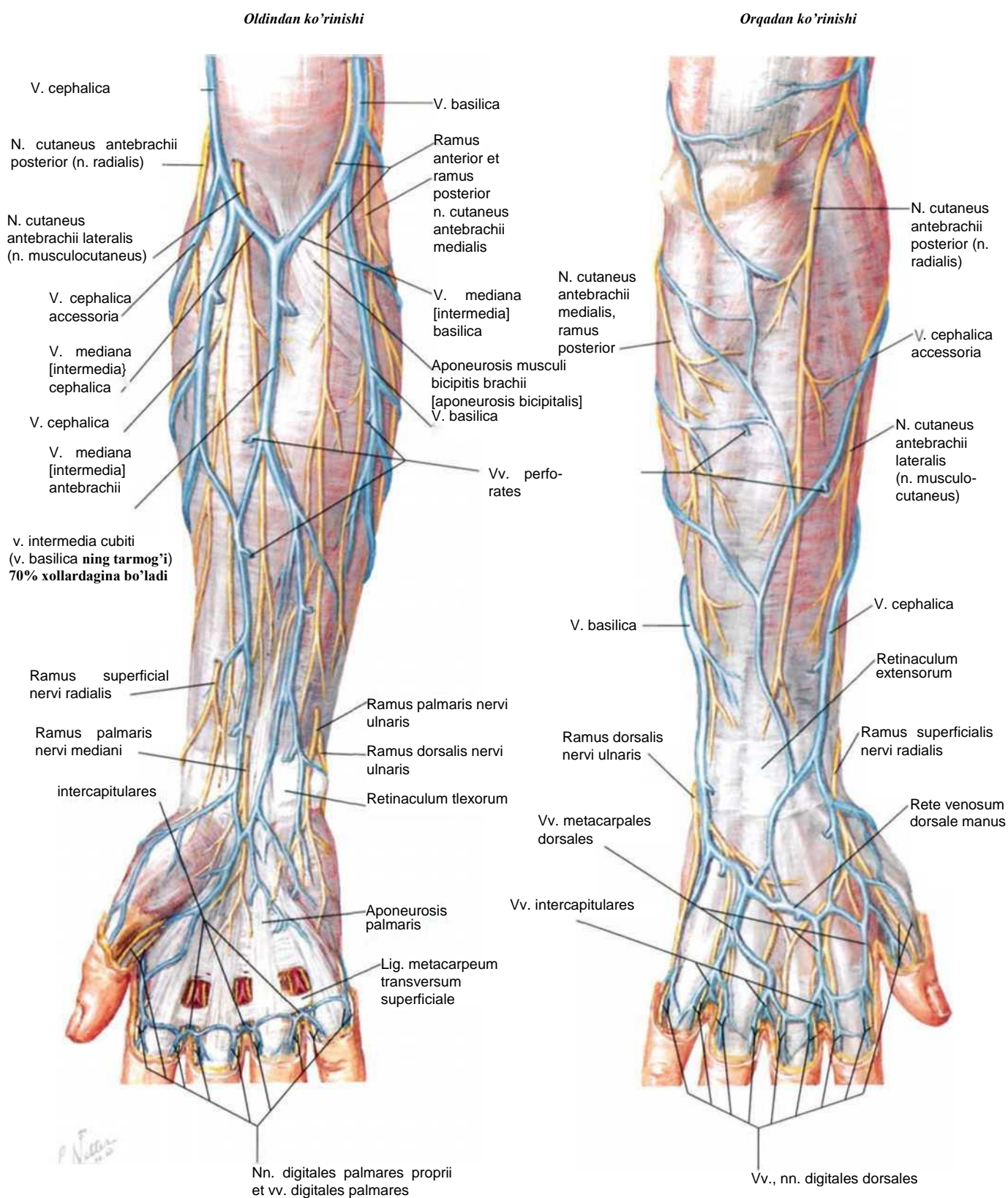
Teri nervlari va elkaning teri osti venalari

Oldindan ko'rinishi

Orqadan ko'rinishi



Teri nervlari, bilak va panja soxasining teri osti venalari



Qo'l soxasi terisining innervatsiyasi

Oldindan ko'rinishi

Nn. supraclaviculares (plexus cervicalis — C3. C4)

N. axillaris
N. cutaneus brachii
lateralis superior
(C₅-C₆) -----

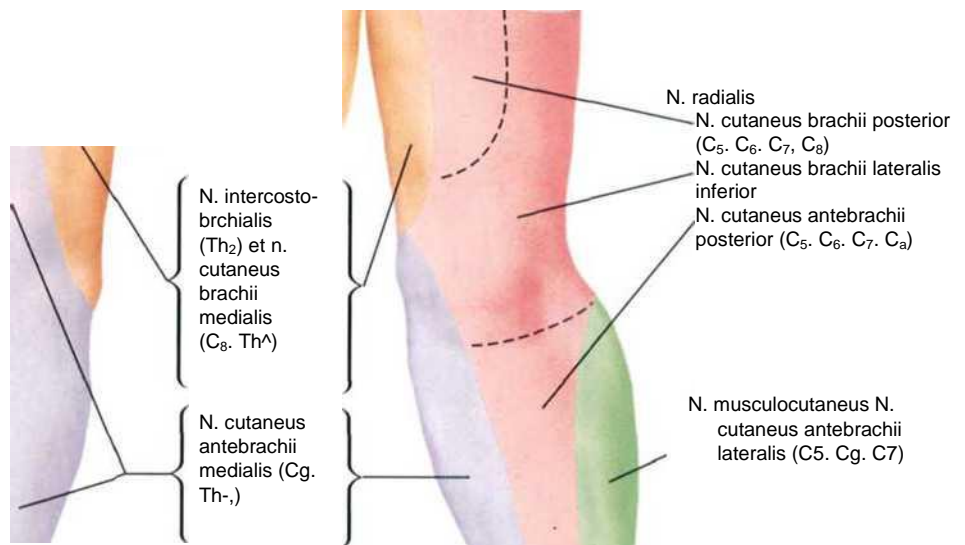
N. radialis
N. cutaneus brachii
lateralis inferior (C₅.
C₆) -----

N. musculocutaneus N.
cutaneus antebrachii
lateralis -----
(C₅. C₆[C₇])

Orqadan ko'rinishi

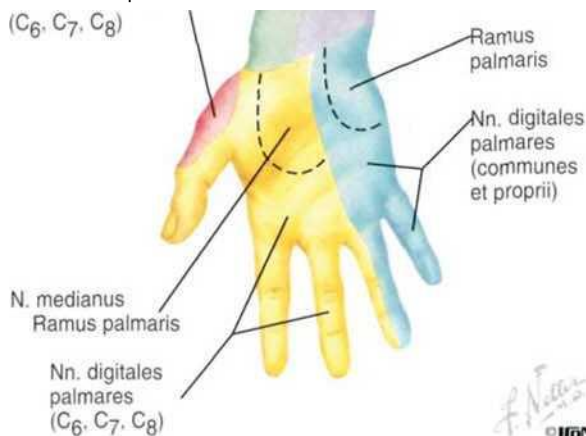
Nn. supraclaviculares
(n3 plexus cervicalis — C3. C4)

N. axillaris -N. cutaneus
brachii lateralis superior
(C₅-C₆)

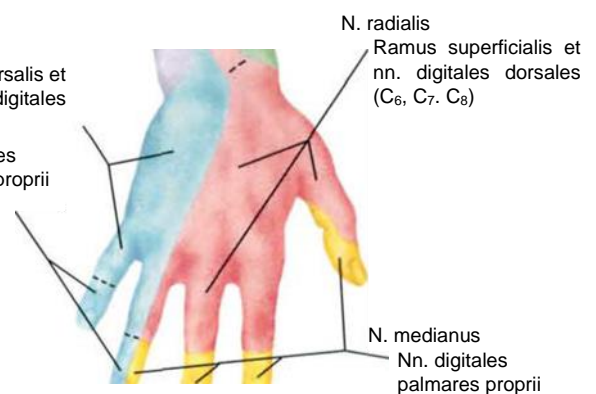


N. radialis
Ramus superficialis
(C₆. C₇. C₈)

N. ulnaris (C₈. Th-1)

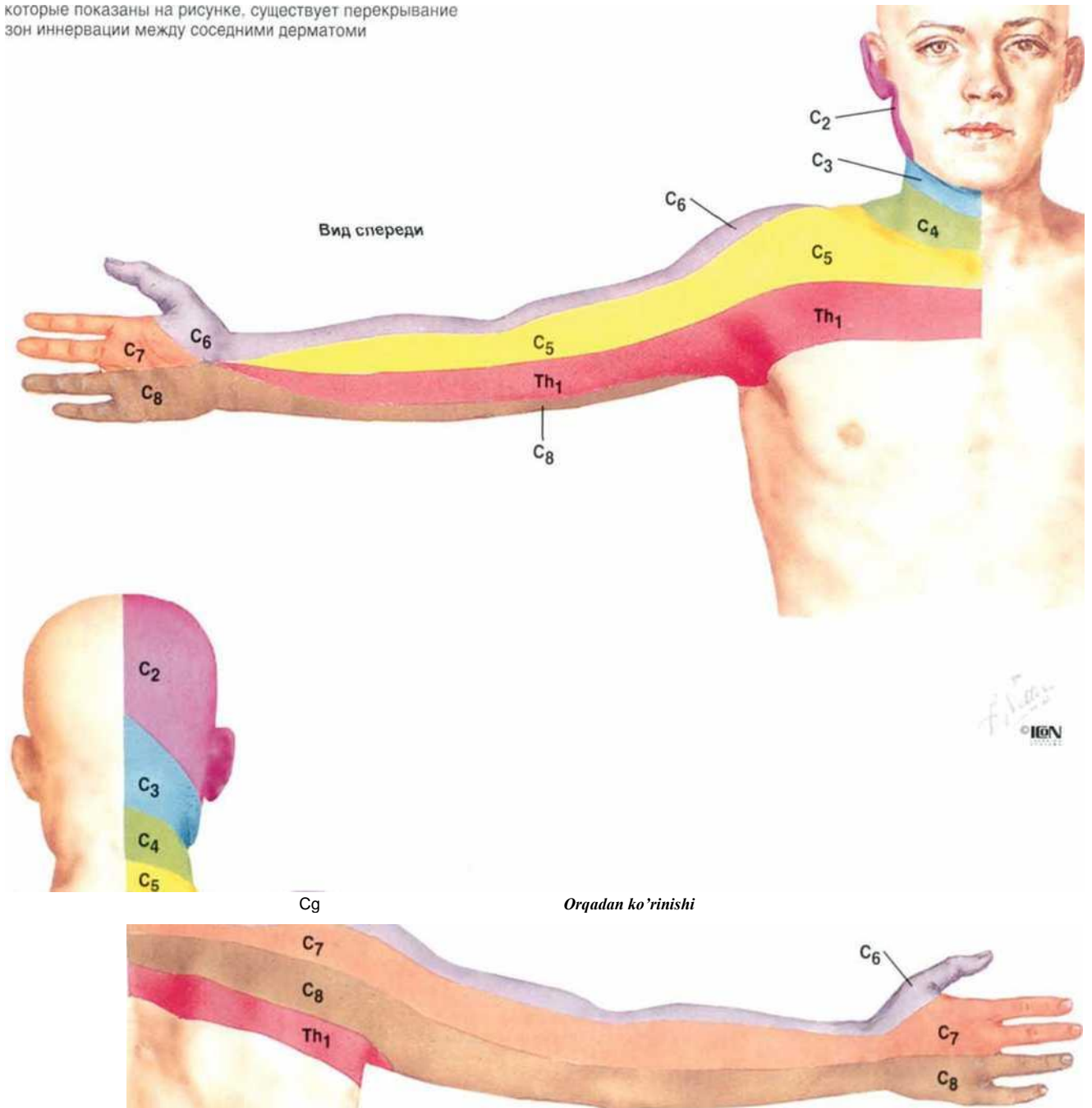


Ramus dorsalis et
nn. digitales
dorsales
Nn. digitales
palmares proprii

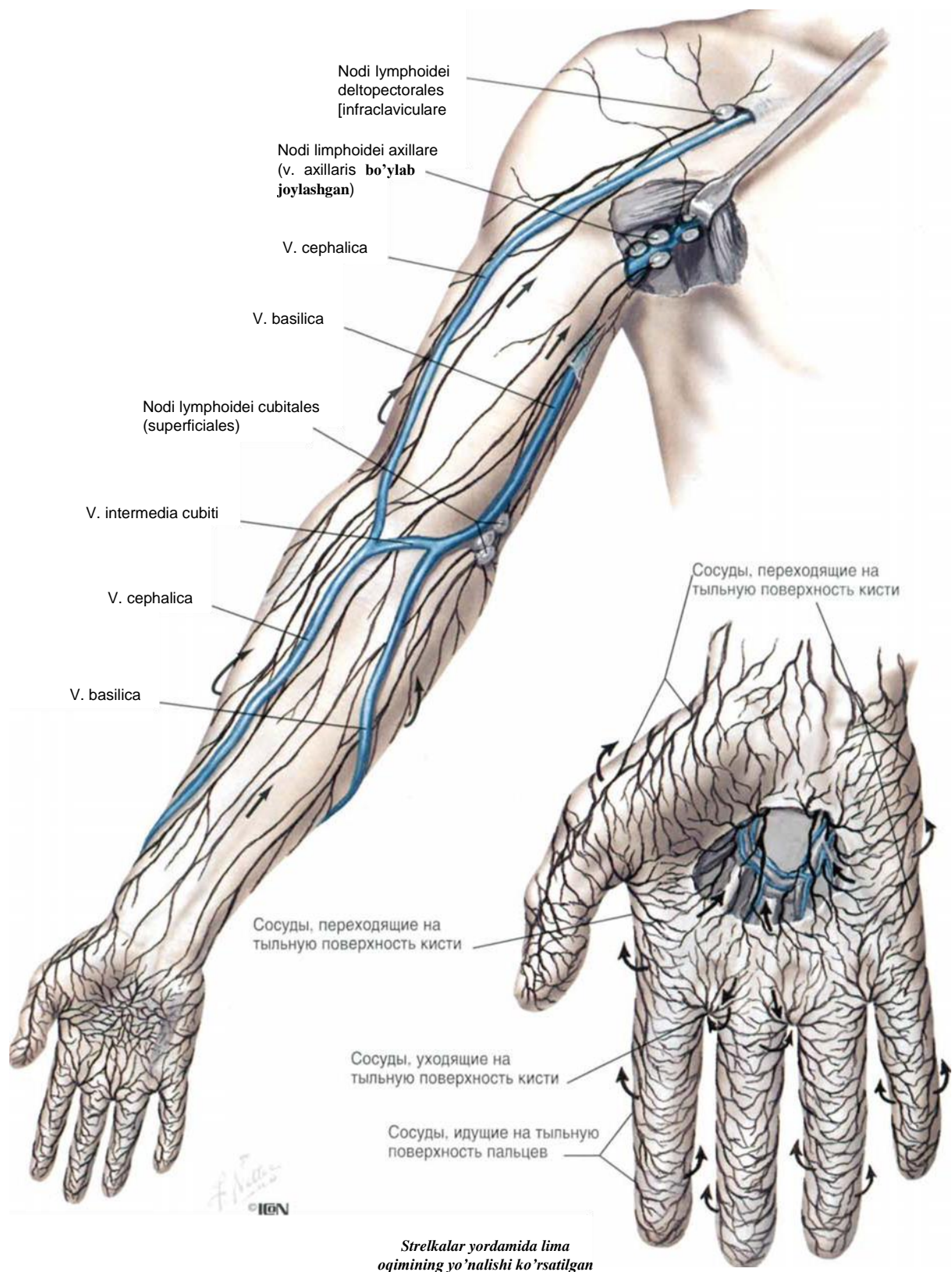


Qo'l soxasi dermatomlari

Несмотря на чёткие границы между дерматомами, которые показаны на рисунке, существует перекрывание зон иннервации между соседними дерматомами



Qo'l soxasining limfatik tomirlari va tugunlari



VII Bo'lim

OYOQ

SOXASI

TOS VA SON

453-471 Rasm

453. *Chanoq suyagi (os coxae)*
454. *Chanoq-son bo'g'imi (articulatio coxae)*
455. *Son suyagi (femur)*
456. *Oyoq kamari va oyoq soxasi muskullarining boshlanishi va birikishi: oldindan ko'rinishi*
457. *Oyoq kamari va oyoq soxasi muskullarining boshlanishi va birikishi: orqadan ko'rinishi*
458. *Son muskullari: oldindan ko'rinishi*
459. *Son muskullari: oldindan ko'rinishi (davomi)*
460. *Son muskullari: lateral tarafdin ko'rinishi*
461. *Tos va son muskullari: orqadan ko'rinishi*
462. *Bel (m. psoas major et minor) va yonbosh (m. iliacus) muskullari*
463. *Bel- dumg'aza chigallari (plexus lumbosacralis) va dum chigali (plexus coccygeus)*
464. *Bel chigali*
465. *Dumg'aza- dum chigali (plexus sacralis et plexus coccygeus)*
466. *Sonning arteriya va nervlari: oldindan ko'rinishi*

467. *Sonning arteriya va nervlari: oldindan ko'rinishi (davomi)*

468. *Sonning arteriya va nervlari: orqadan ko'rinishi*

469. *Dumba soxasi nervlari*

470. *Son suyagi boshchasi va bo'yinchasi arteriyalari*

471. *Sonning ko'dalang kesmasi*

TIZZA

472-477 Rasm

472. *Tizza (genu), medial va latral tarafdin ko'rinishi*

473. *Tizza: oldindan ko'rinishi*

474. *Tizza bo'g'imi (articulatio genus)*

475. *Tizza bo'g'imi: krestsimon va kollateral boylamlari (ligg. cruciata et ligg. collateralia)*

476. *Tizza bo'g'imi: sagittal kesmasi va orqadan ko'rinishi*

477. *Son va tizza arteriyalari*

BOLDIR

478-487 Rasm

478. *Boldir suyaklar: katta boldir (tibia) va kichik boldir (fibula) suyagi*

479. *Boldir suyaklar: katta boldir (tibia) va kichik boldir (fibula) suyagi (davomi)*
480. *Boldir va oyoq panjasiga muskullarning birikishi*
481. *Boldir muskullari: orqa guruh muskullari*
482. *Boldir muskullari: orqa guruh muskullari (davomi)*
483. *Boldir muskullari: orqa guruh, chuqur qavati (davomi)*
484. *Boldir muskullari: oldingi guruh muskullar*
485. *Boldir muskullari: oldingi guruh muskullar (chuqur qavatlari)*
486. *Boldir muskullari: lateral tarafdan ko'rinishi*
487. *Boldirni ko'ndalang kesmasi: fastsial qinlari*

BOLDIR-PANJA BO'G'IMI VA OYOQ PANJASI
488-501 Rasm

488. *Oyoq panja suyaklari*
489. *Oyoq panja suyaklari (davomi)*
490. *Tovon suyagi (calcaneus)*
491. *To'piqning pay va boylamlari*
492. *Oyoq panjasining pastki yuzasini pay va boylamlari*
493. *Paylarning sinovial qinlari*
494. *Oyoq panjasining ustki yuzasini yuza muskullari*
495. *Oyoq panjasining ustki yuzasini chuqur muskullari*

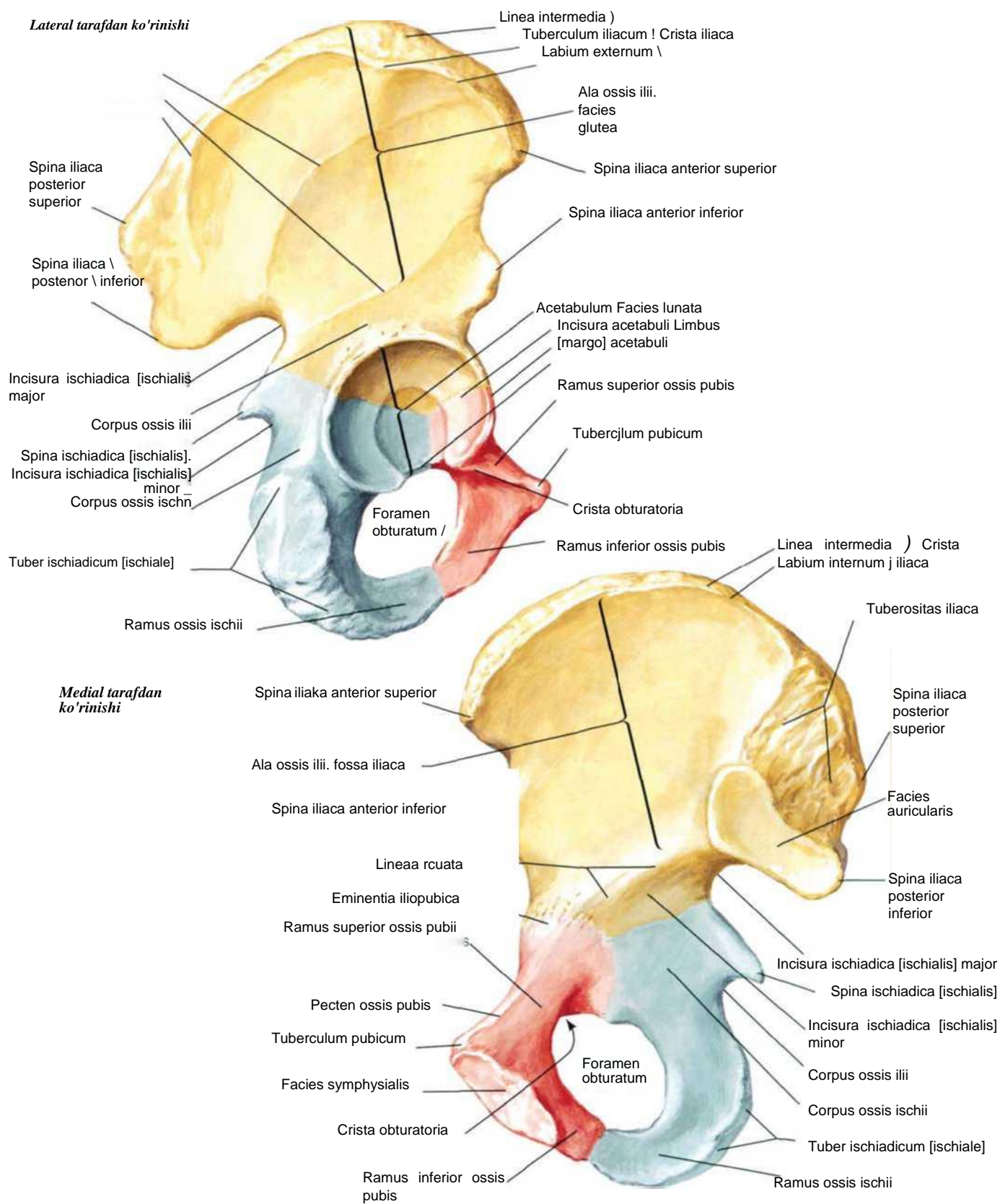
496. *Oyoq panjasining pastki yuzasini yuza tuzilmalari*
497. *Oyoq panjasining yuza qavatidagi muskullari*
498. *Oyoq panjasining muskullari (ikkinchi qavat)*
499. *Oyoq panjasining muskullari (uchinchi qavat)*
500. *Oyoq panjasining suyaklararo muskullari va chuqur arteriyalari*
501. *Oyoq panjasining suyaklararo muskullari*

QON BILAN TA'MINLANISHI VA
INNERVATSIYA

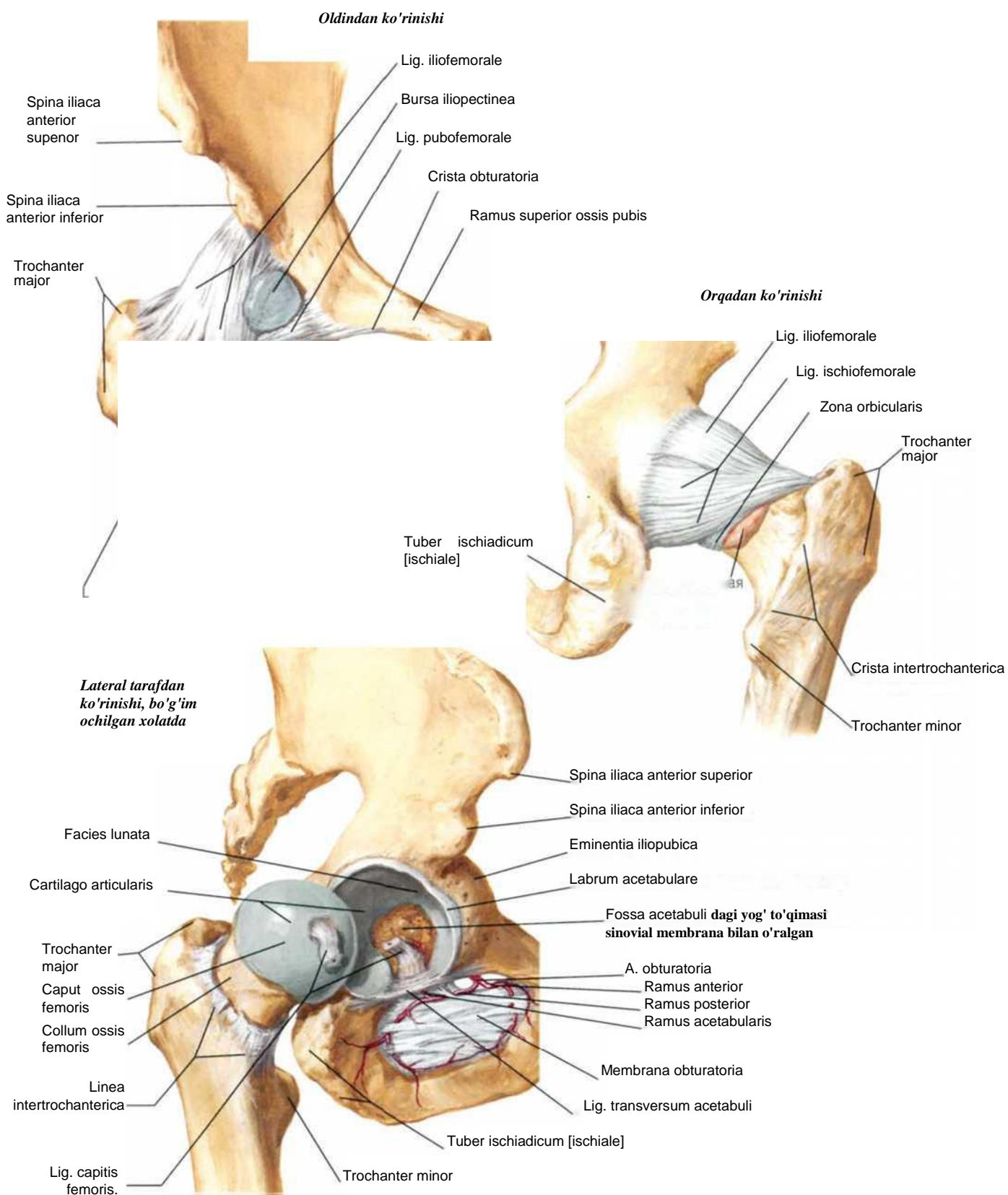
502-510 Rasm

502. *Son nervi (nervus femoralis) va son terisining lateral nervi (nervus cutaneus femoris lateralis)*
503. *Yopiluvchi nerv (nervus obturatorius)*
504. *Quymich nervi (nervus ischiadicus) va son terisining orqa nervi (nervus cutaneus femoris posterior)*
505. *Katta boldir nervi (nervus tibialis)*
506. *Umumiy kichik boldir nervi (nervus peroneus communis)*
507. *Oyoq soxasining dermatomlari*
508. *Oyoq soxasining yuza nervlari va teri osti venalari: oldindan ko'rinishi*
509. *Oyoq soxasining yuza nervlari va teri osti venalari: orqadan ko'rinishi*
510. *Oyoq soxasining limfatik tomirlari va tugunlari*

Chanoq suyagi (os coxae)



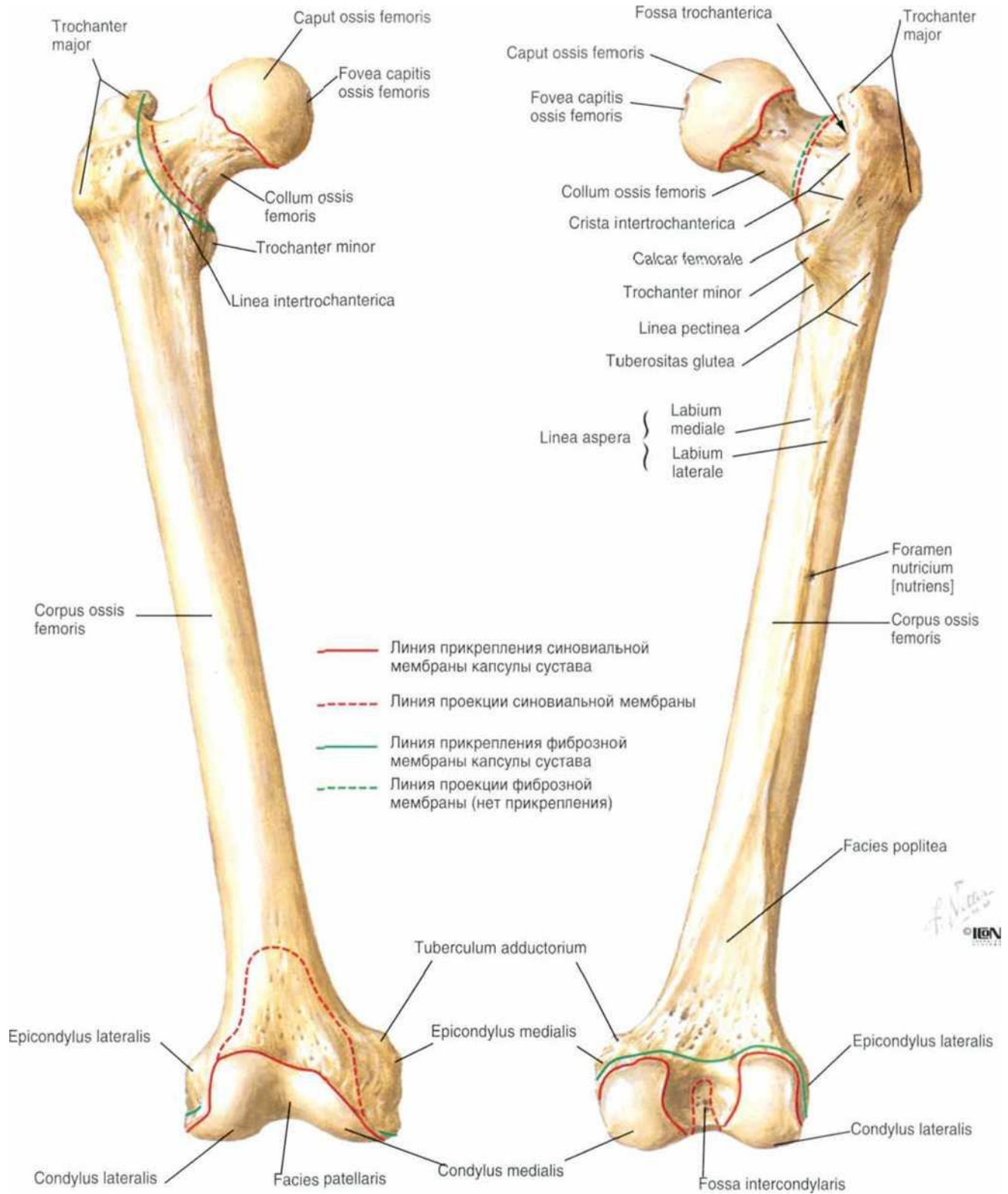
Chanoq-son bo'g'imi (articulatio coxae)



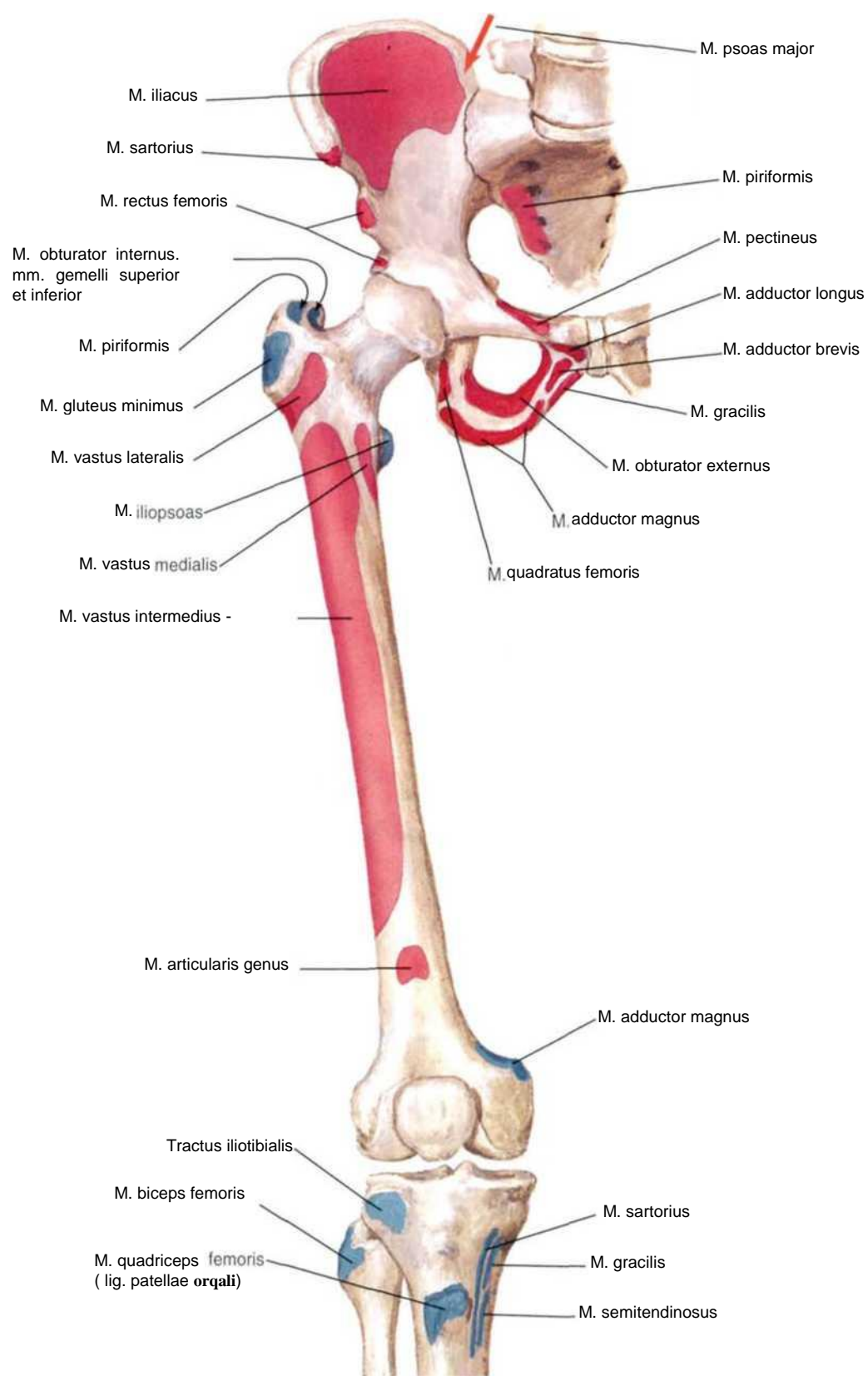
Son suyagi (femur)

Oldindan ko'rinishi

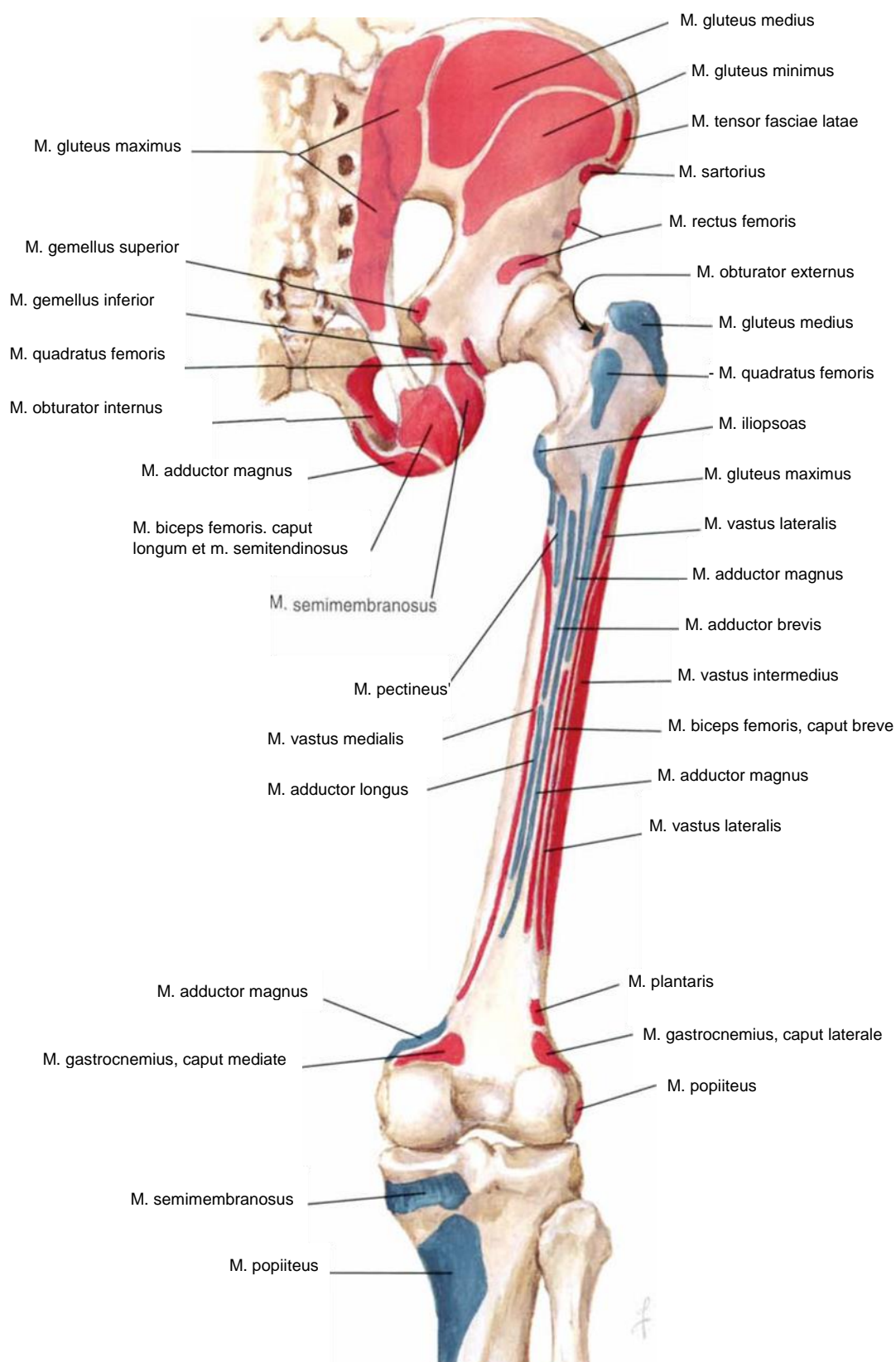
Orqadan ko'rinishi



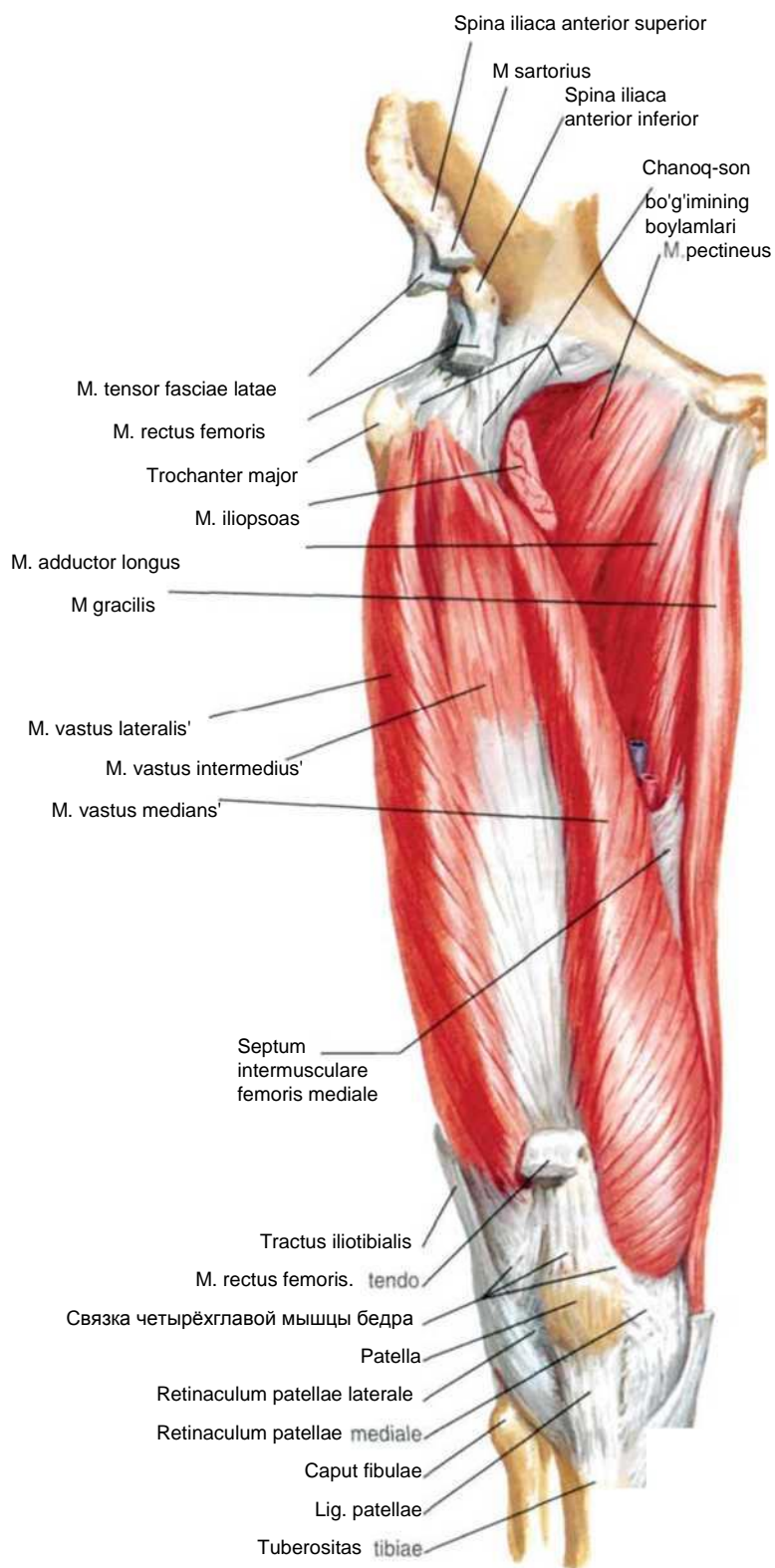
Oyoq soxasi muskullarining birikishi; oldindan ko'rinishi



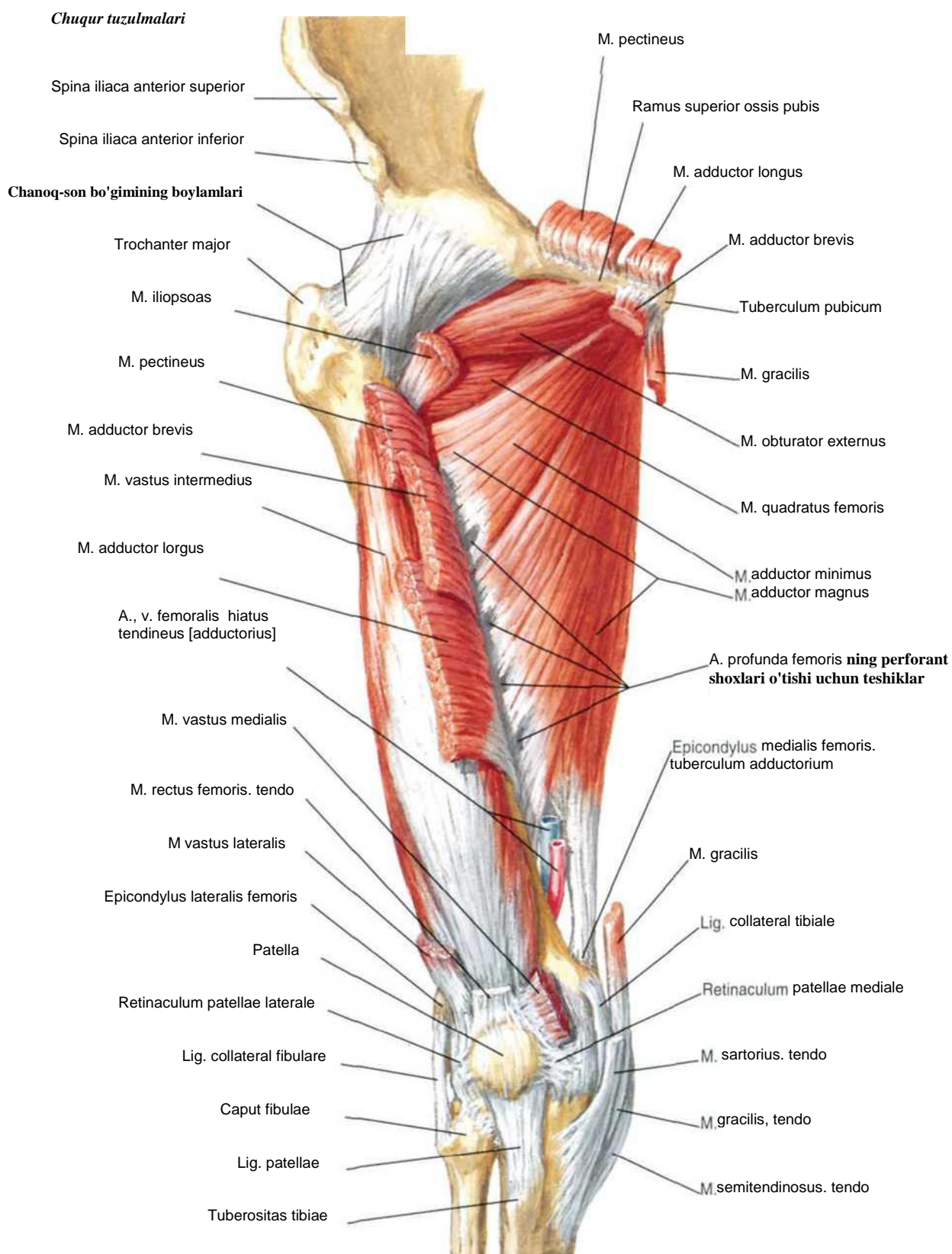
Oyoq soxasi muskullarining birikishi; orqadan ko'rinishi



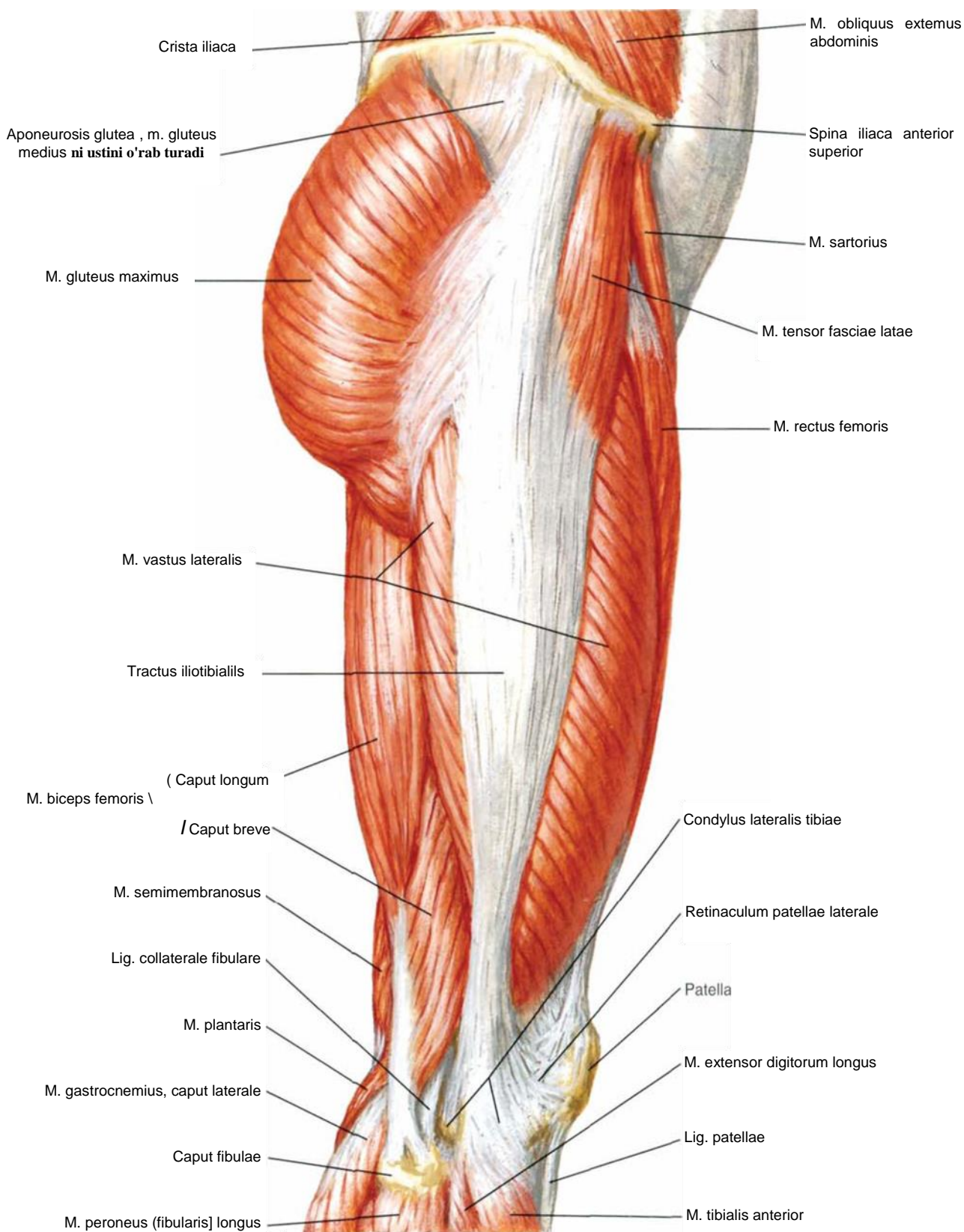
Son muskullari: oldindan ko'rinishi



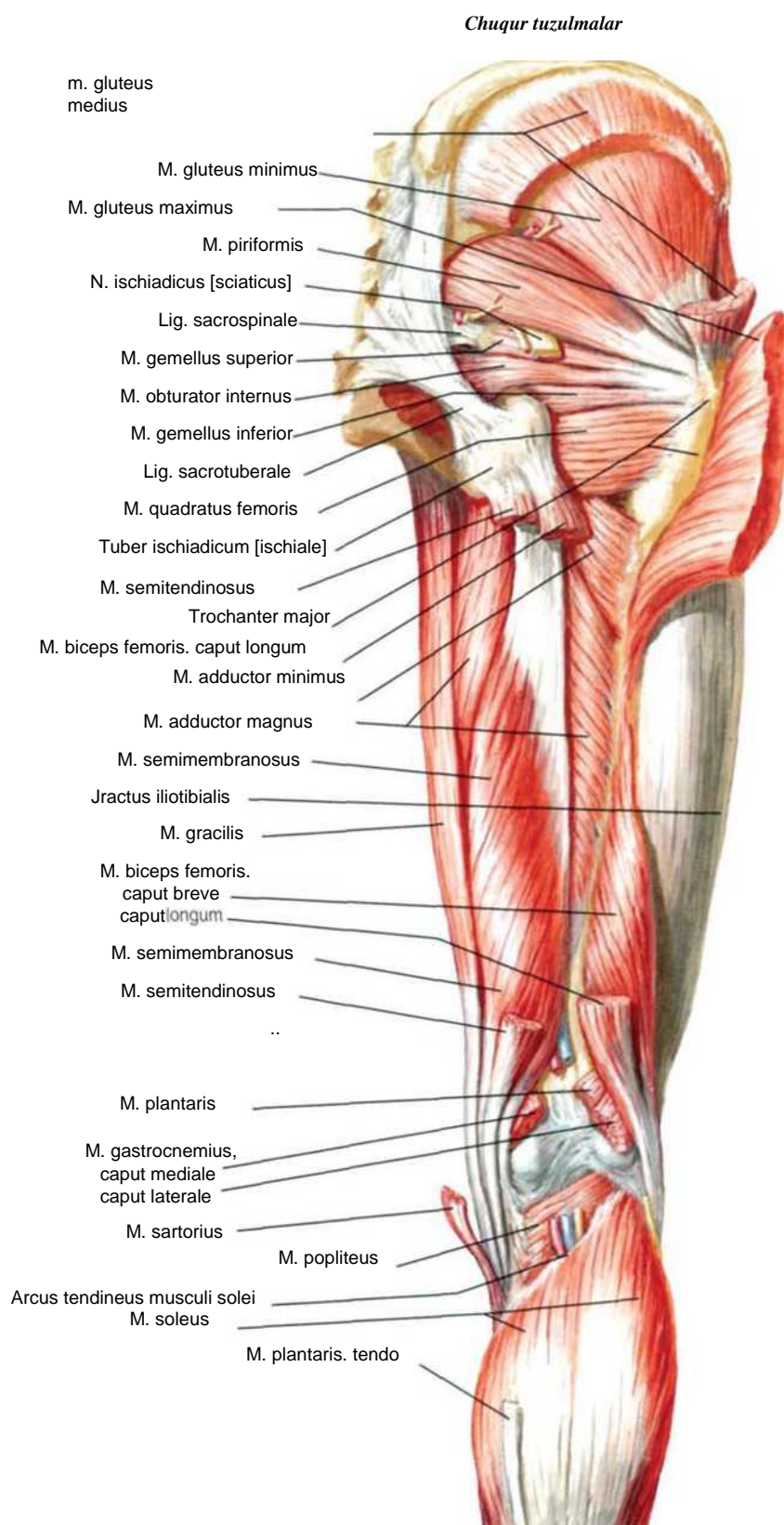
Son muskullari: oldindan ko'rinishi (davomi)



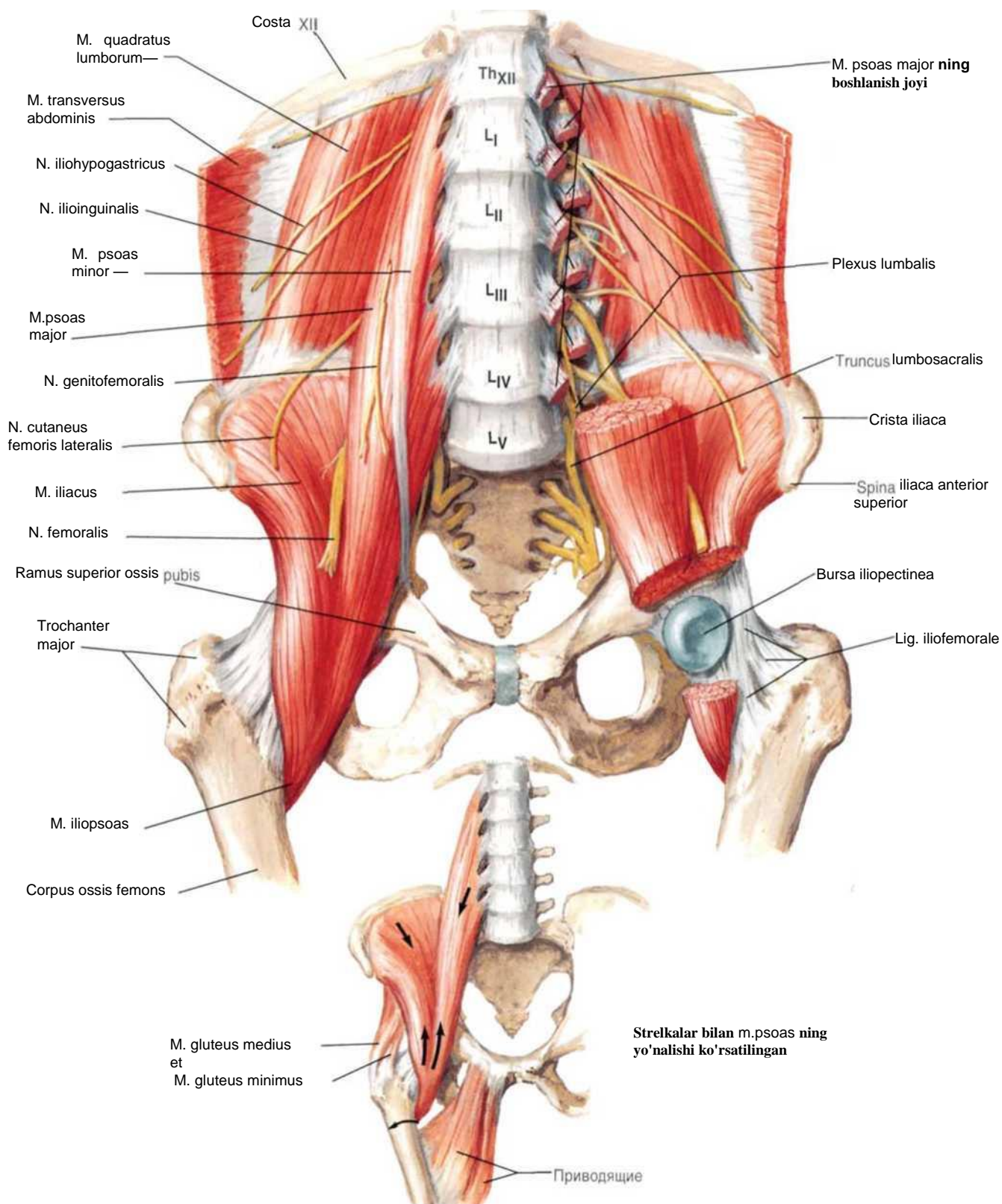
Son muskullari: lateral tarafdin ko'rinishi



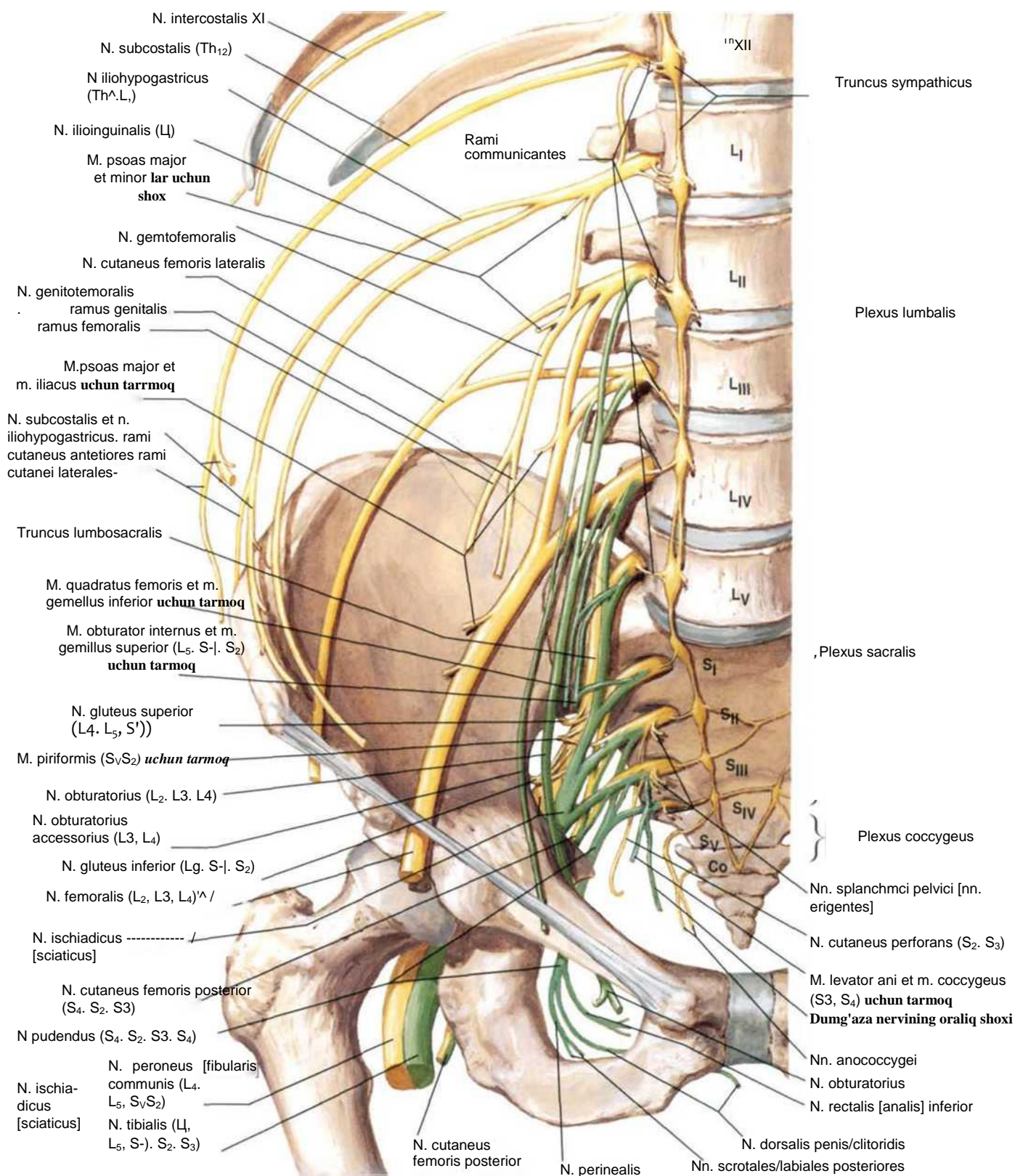
Chanoq va son muskullari: orqadan ko'rinishi

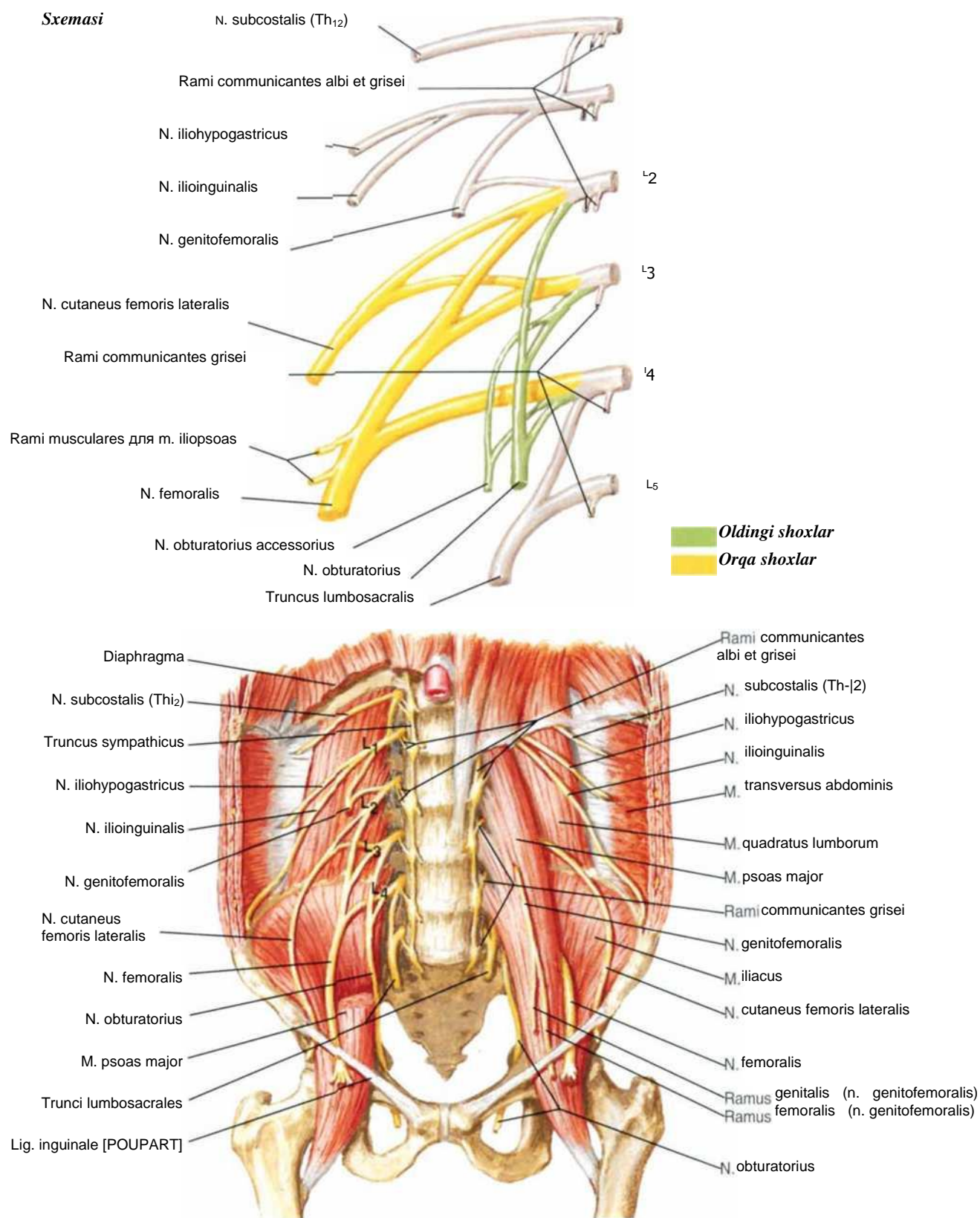


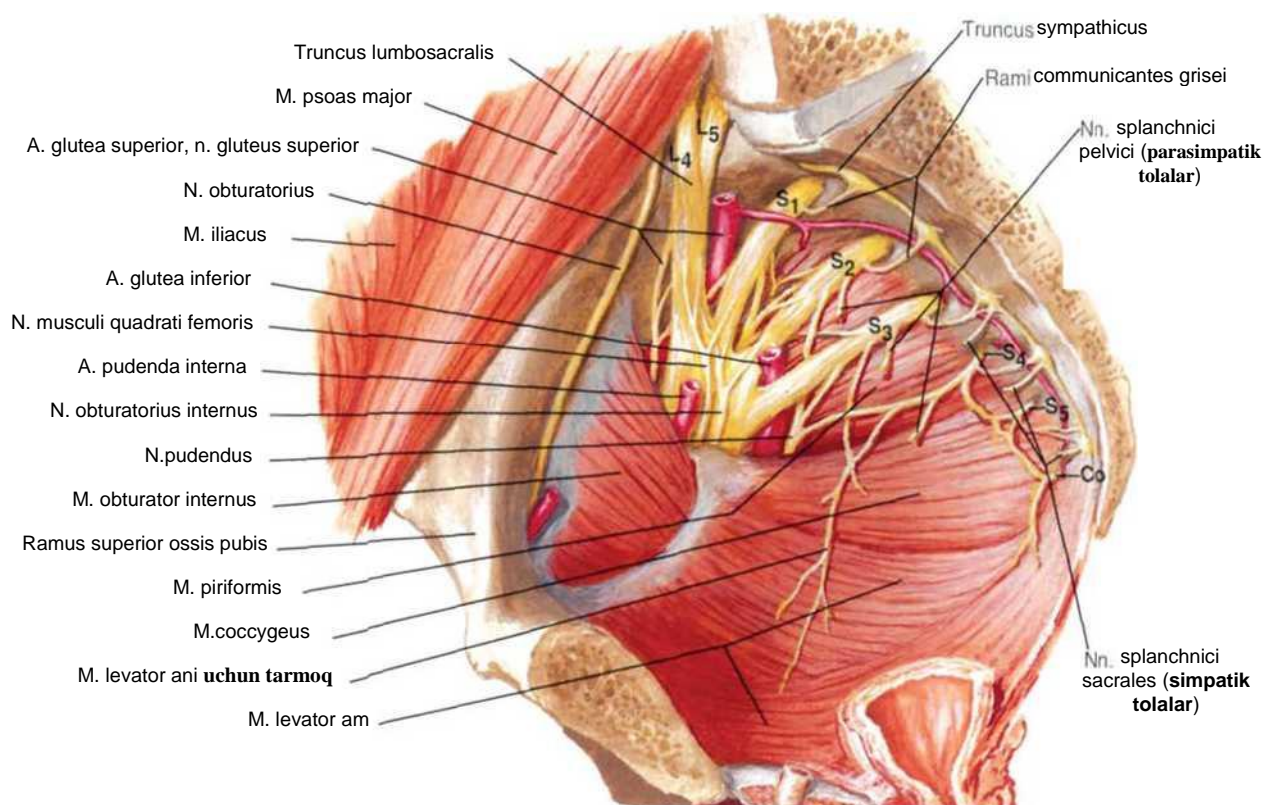
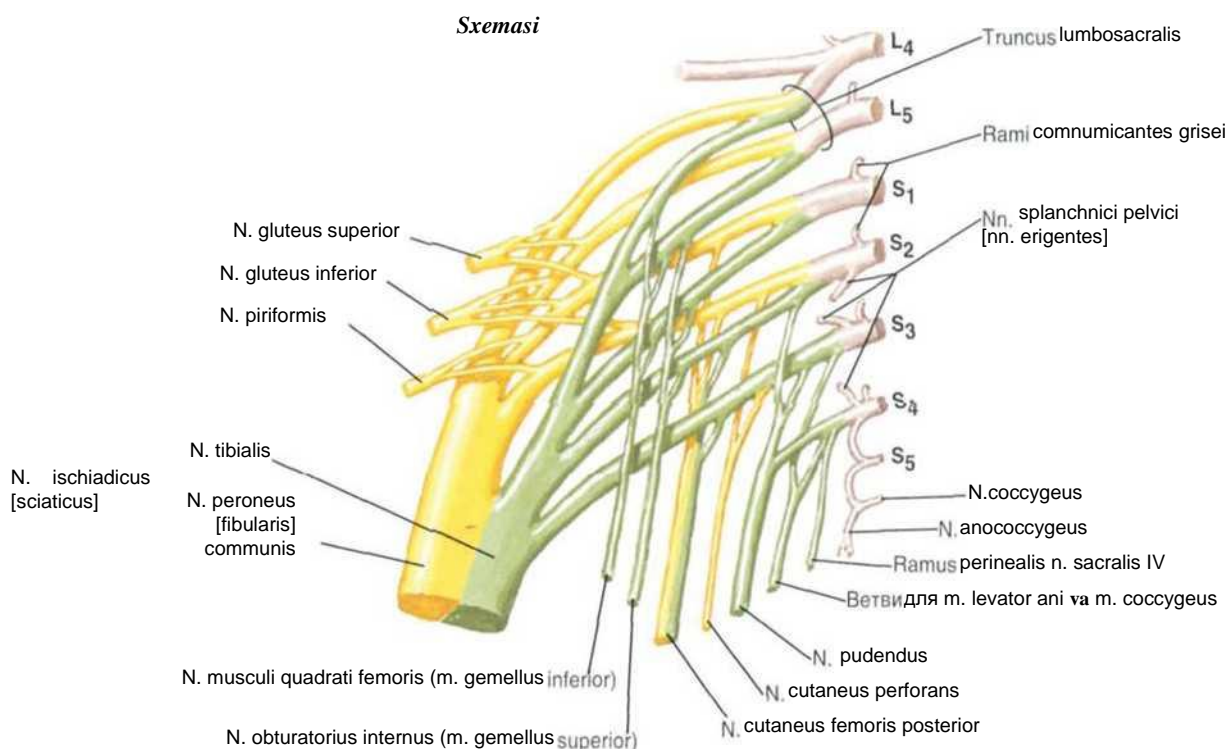
Bel va yonbosh muskuli



Bel-dumg'aza va dum chigallan



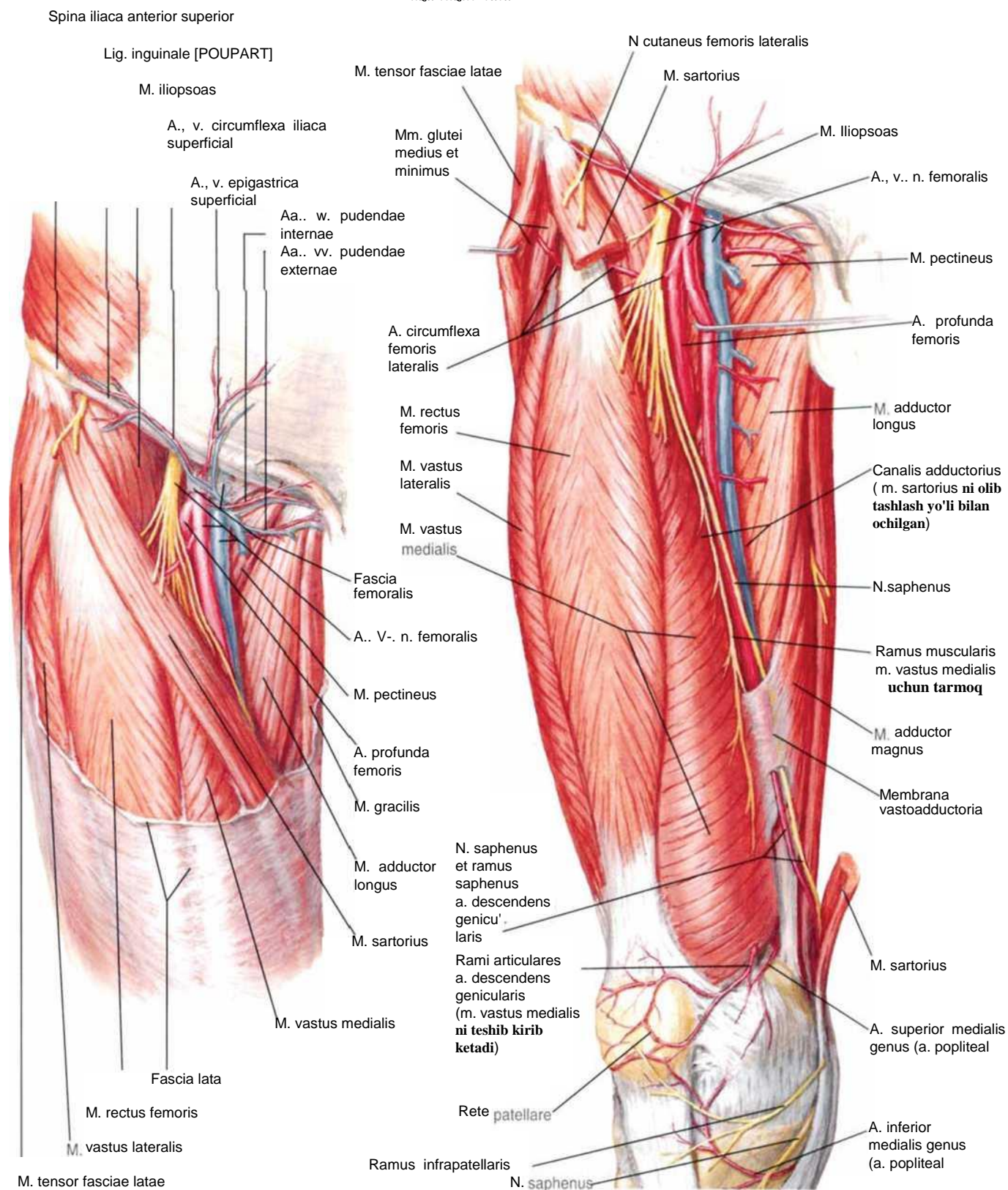




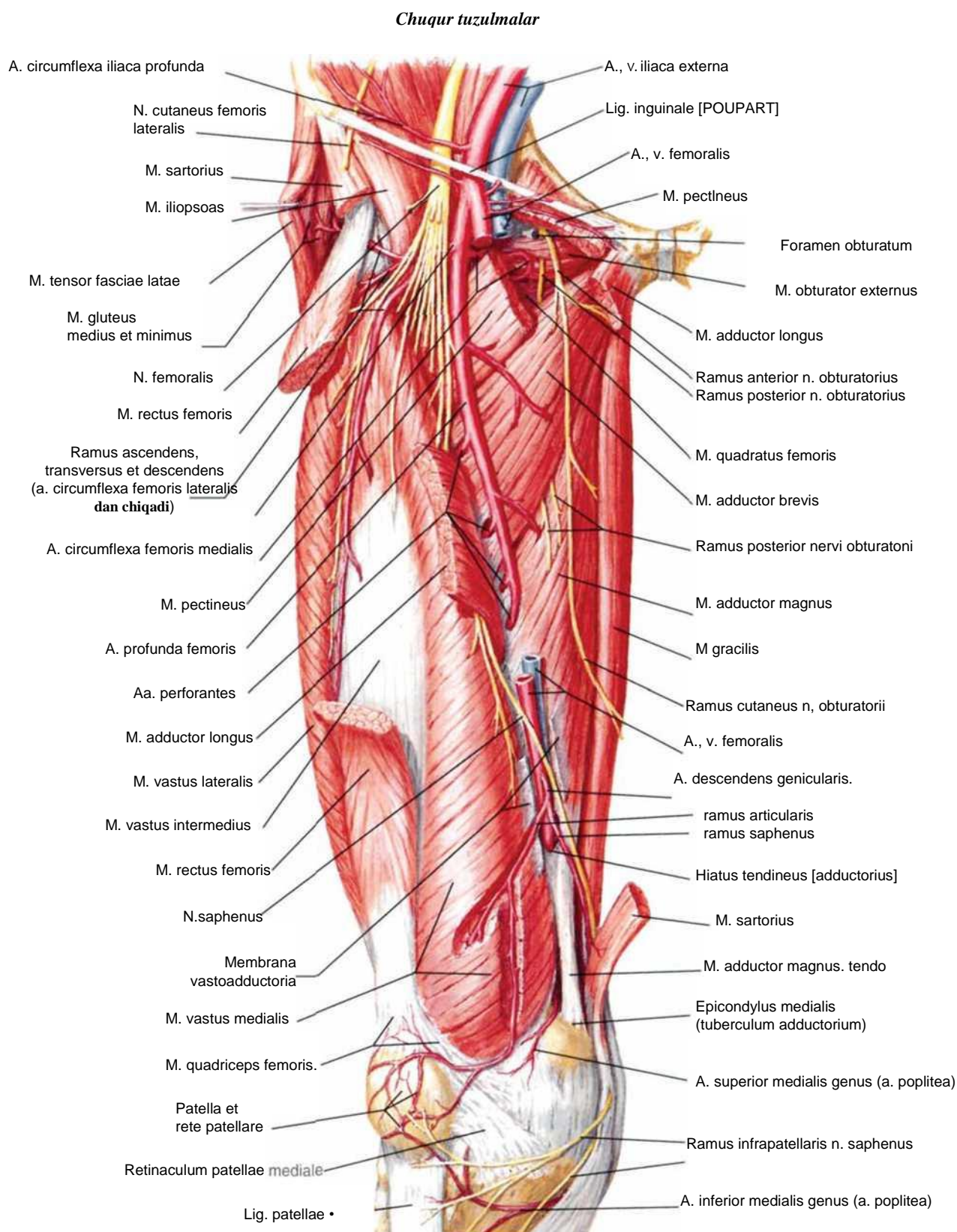
Tosning ichki yuzasini ko'rinishi

Sonning arteriya va nervlari: oldindan ko'rinishi

Yuza tuzilmalar

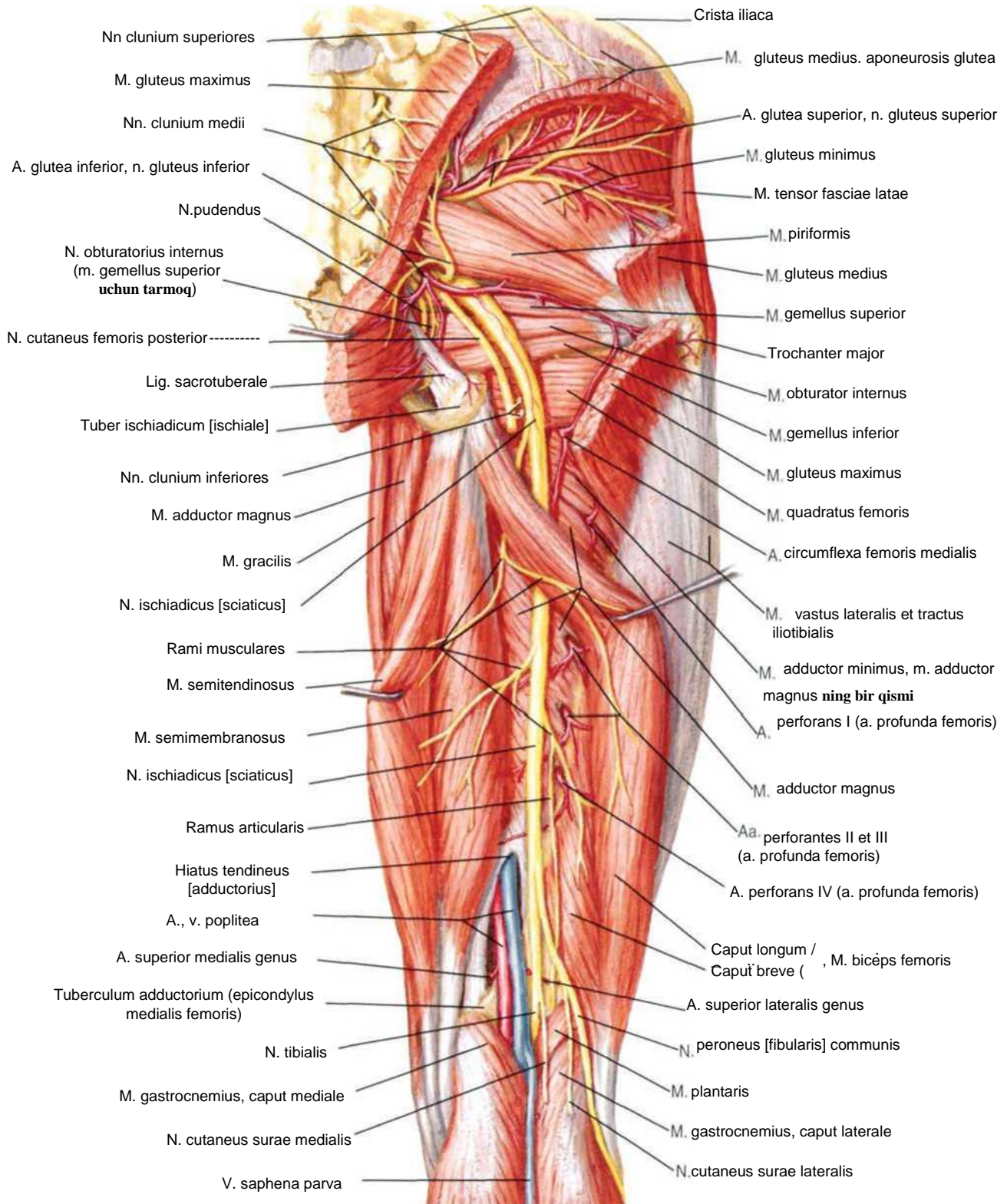


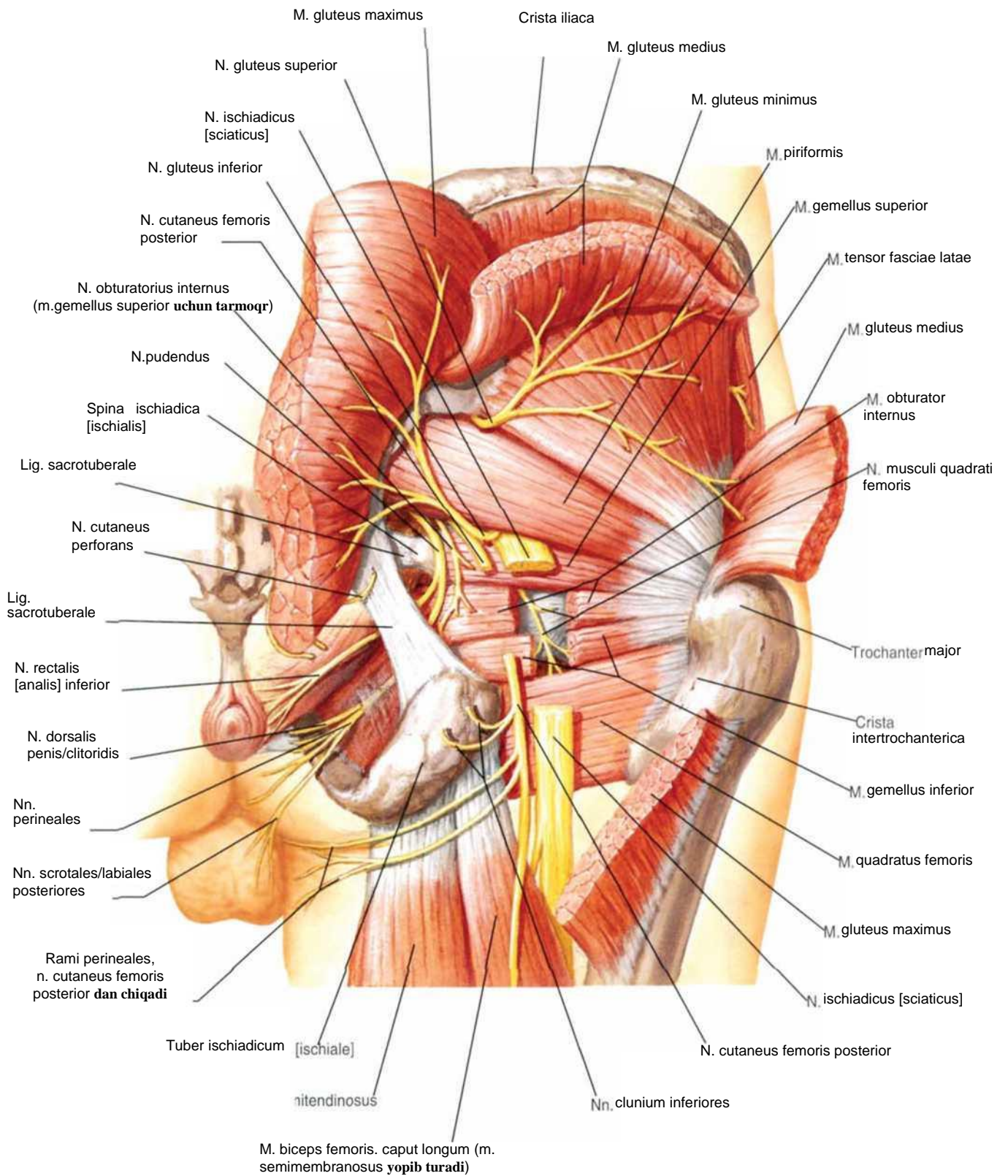
Sonning arteriya va nervlari: oldindan ko'rinishi (davomi)



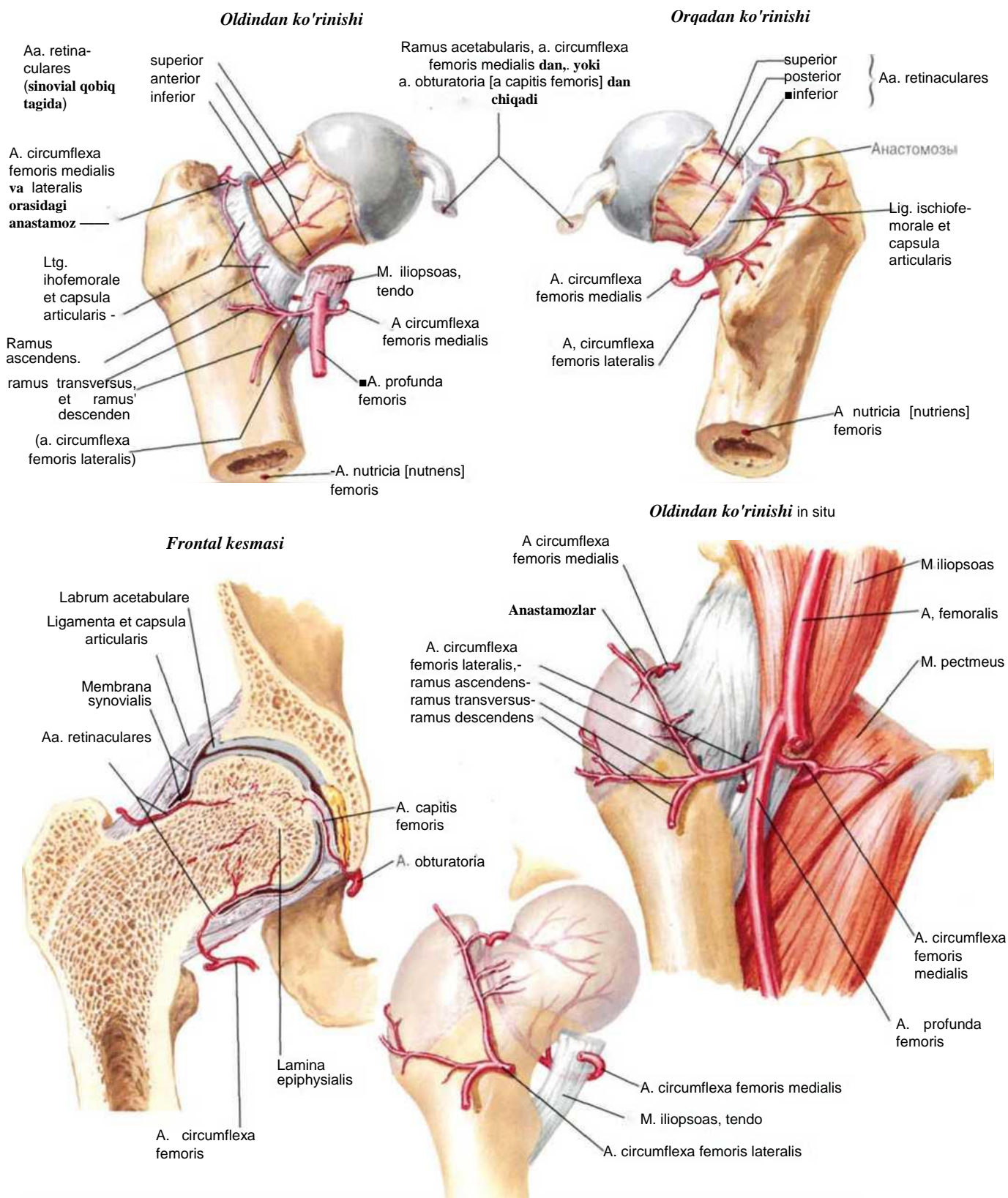
Sonning arteriya va nervlari: orqadan ko'rinishi

Chuqur tuzilmalar

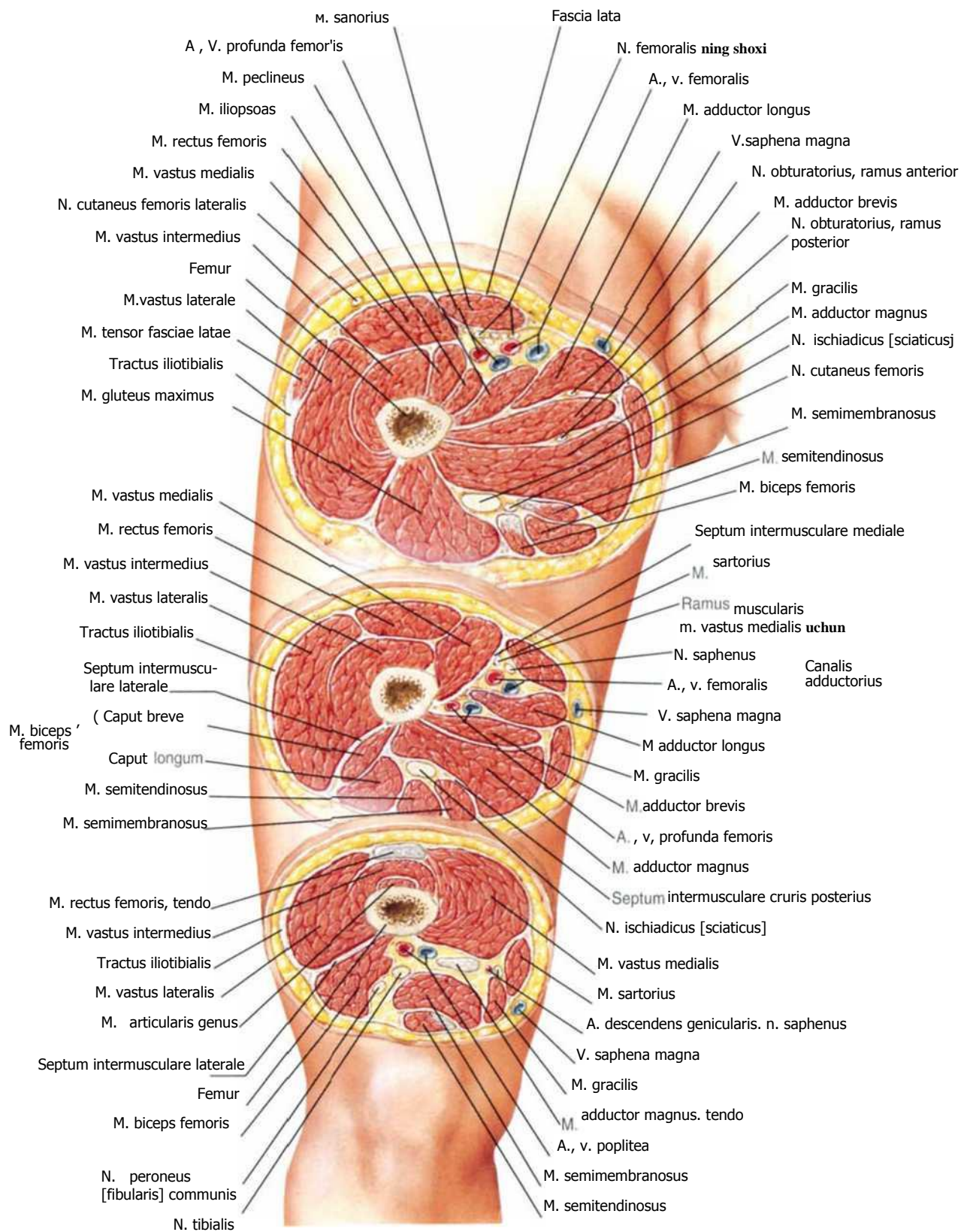




Son suyagi boshchasi va bo'yinchasining arteriyalar

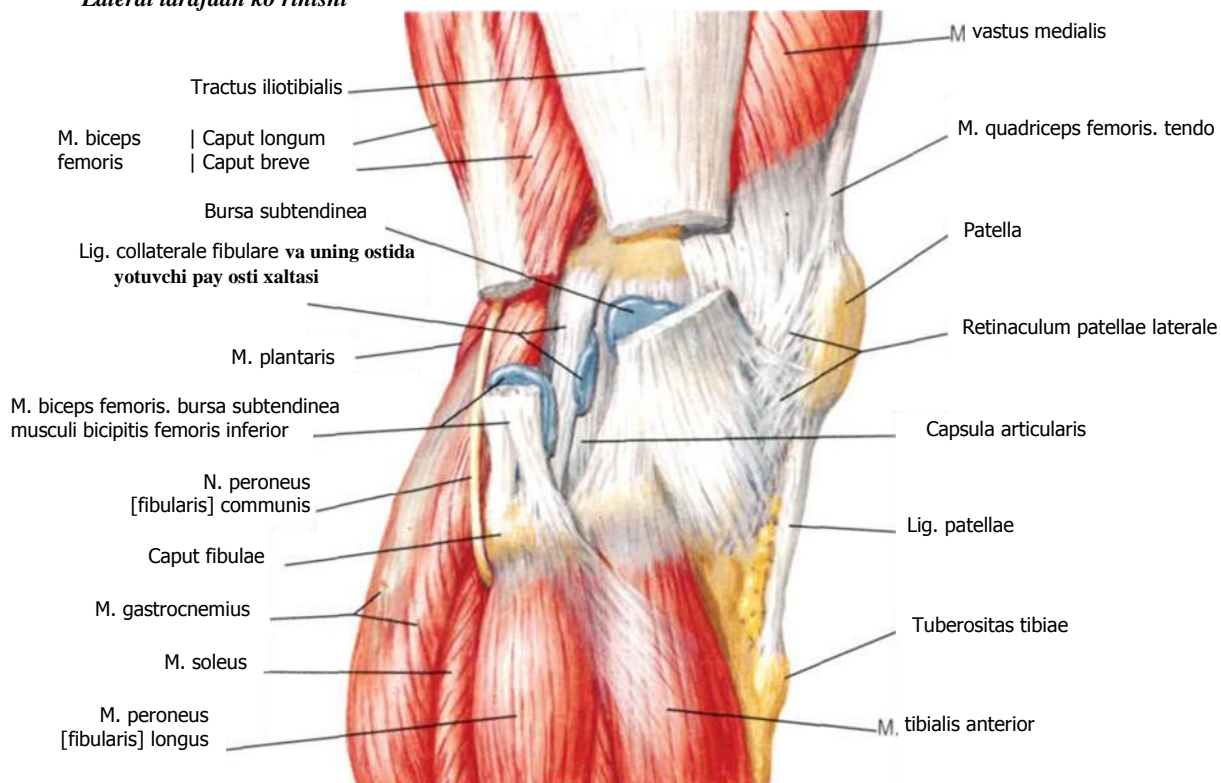


Chaqaloqning son suyagi: oldindan ko'rinishi

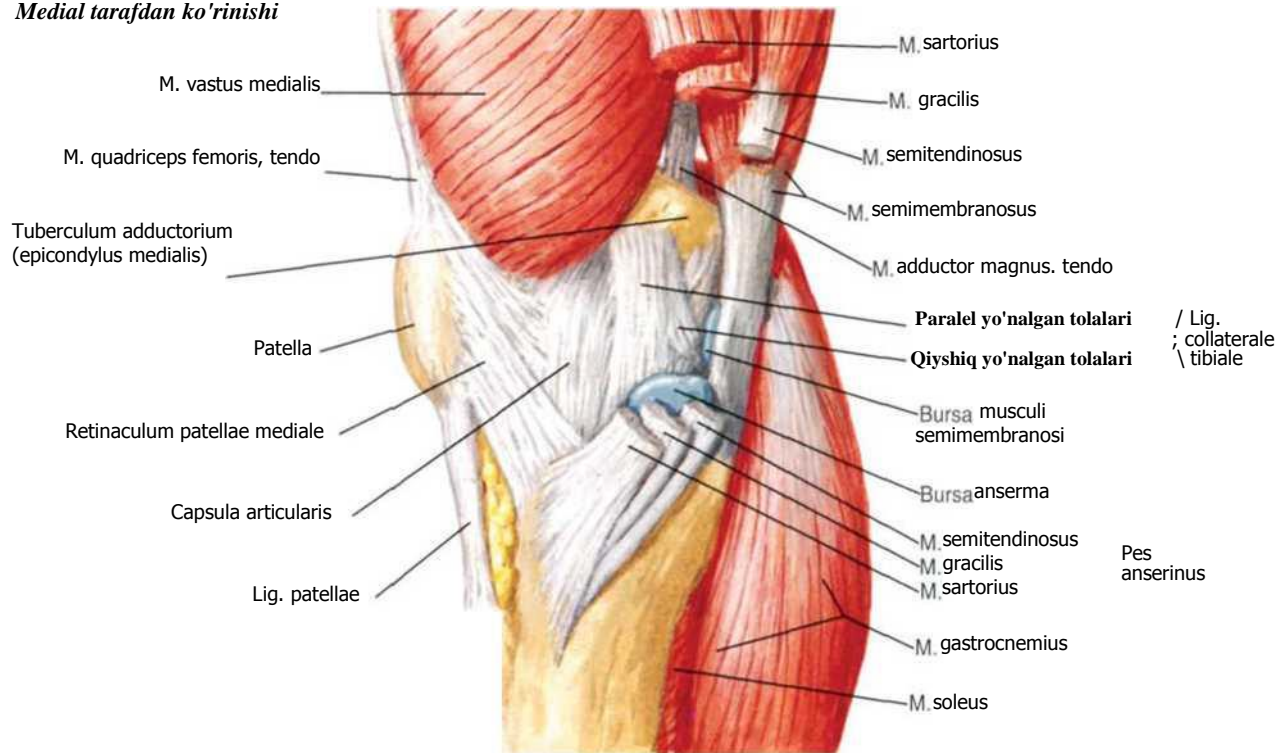


Tizza (genu), medial va lateral tarafdin ko'rinishi

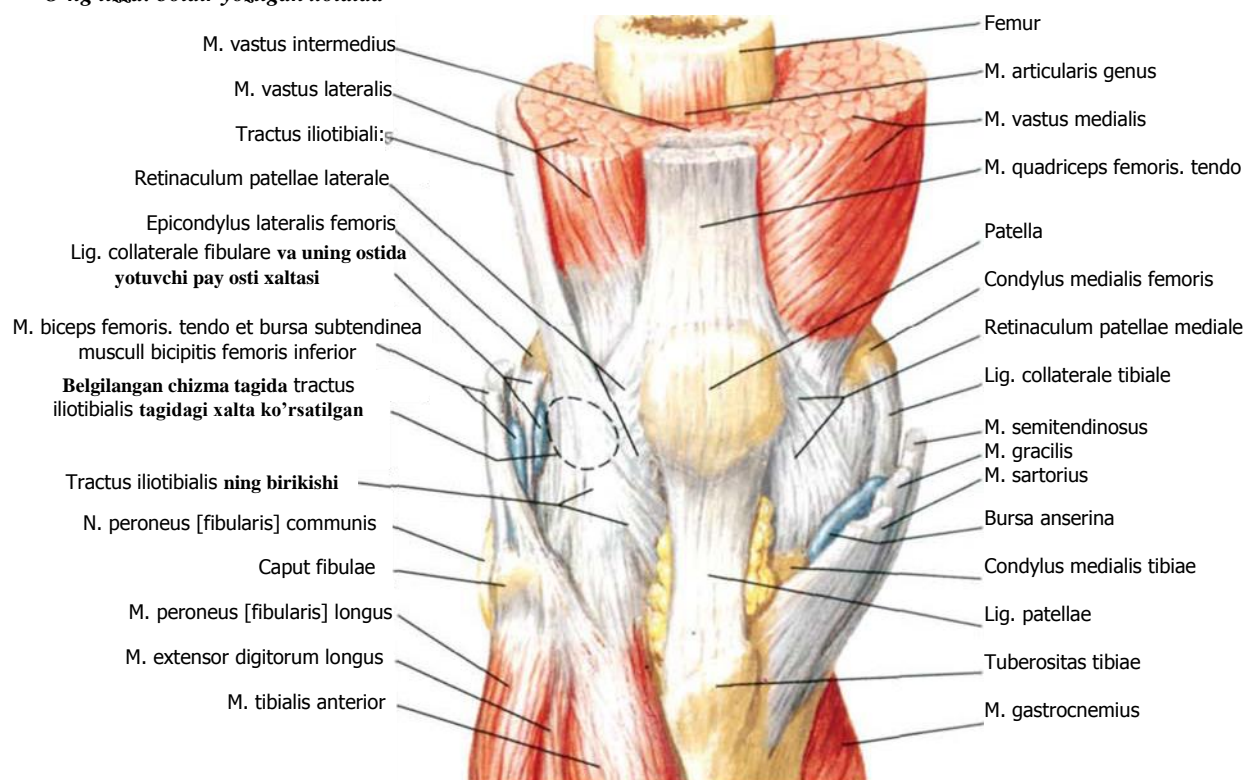
Lateral tarafdin ko'rinishi



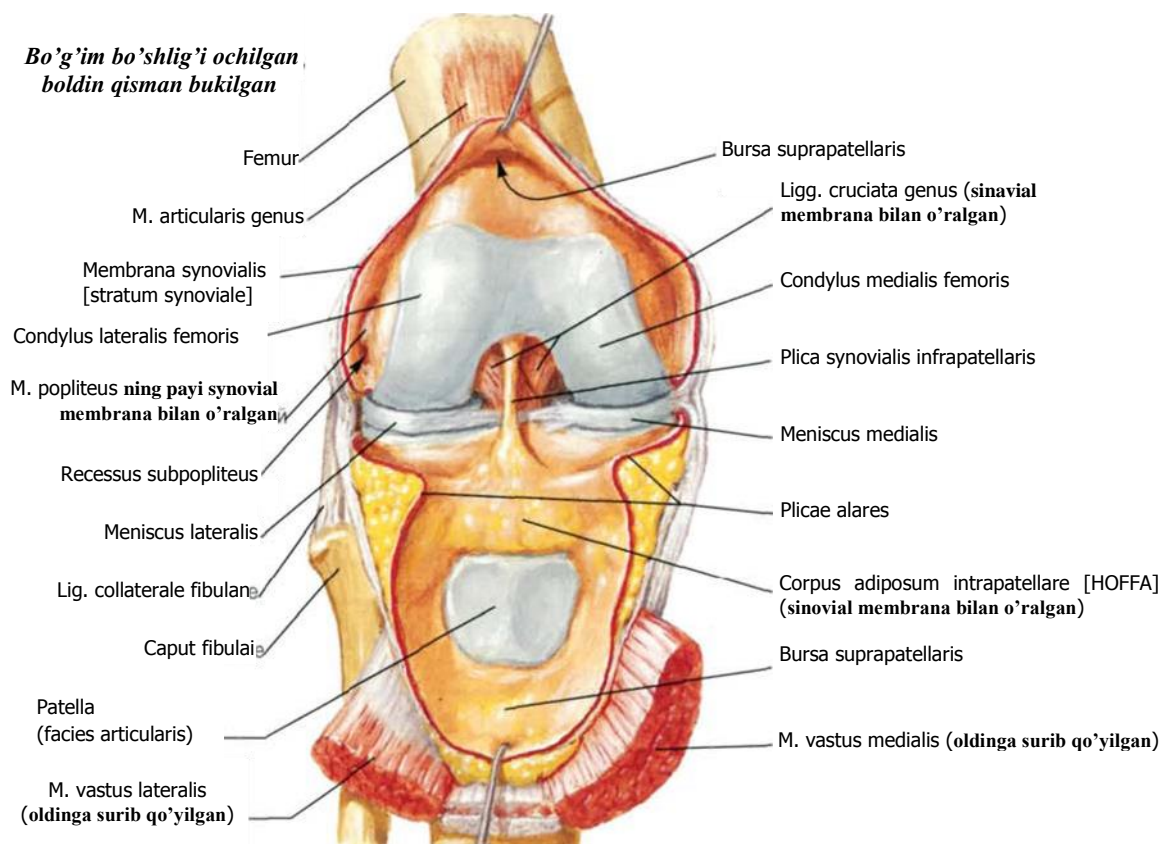
Medial tarafdin ko'rinishi



O'ng tizza: boldir yozilgan xolatda

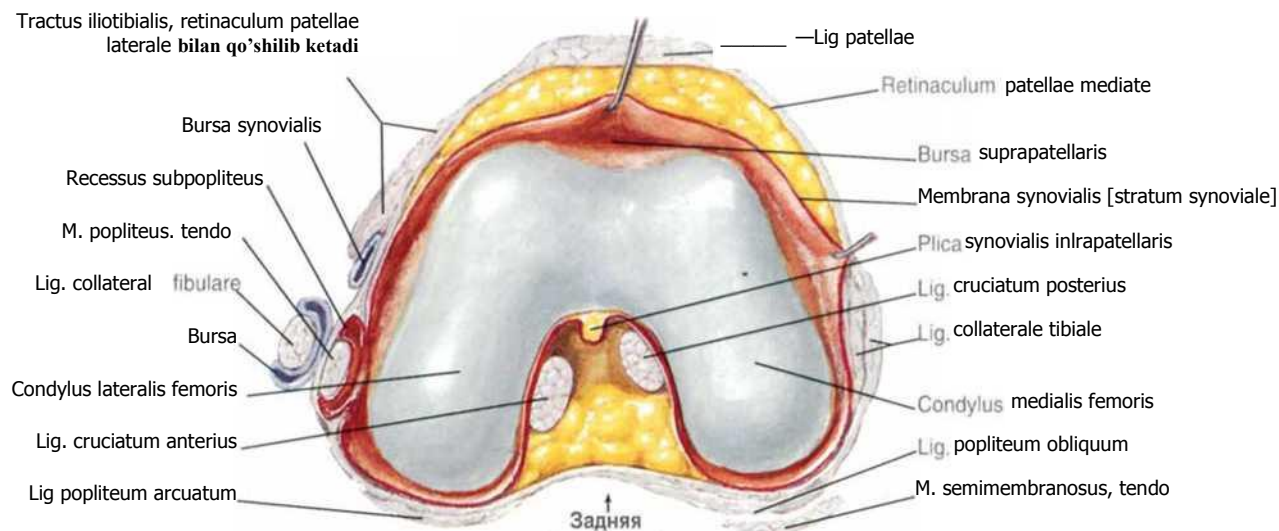


Bo'g'im bo'shlig'i ochilgan boldin qisman bukilgan

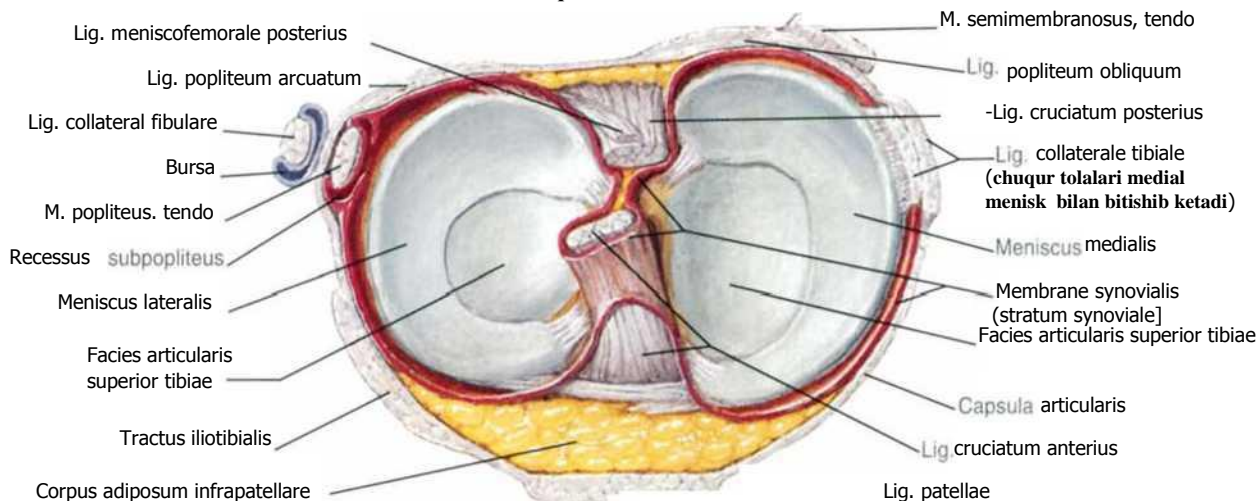


Tizza bo'g'imi (articulatio genus)

Pastdan ko'rinishi

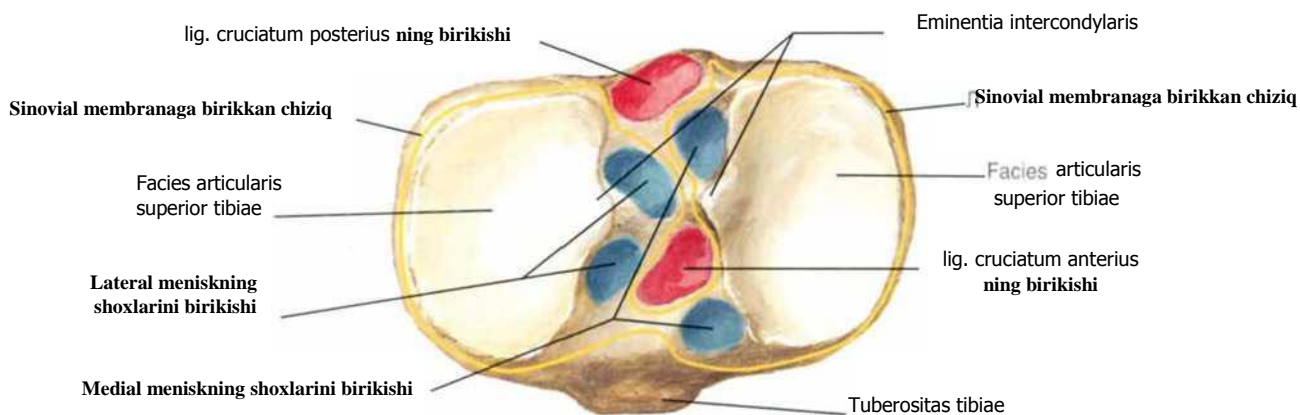


Yuqoridan ko'rinishi



Oldingi yuzasi

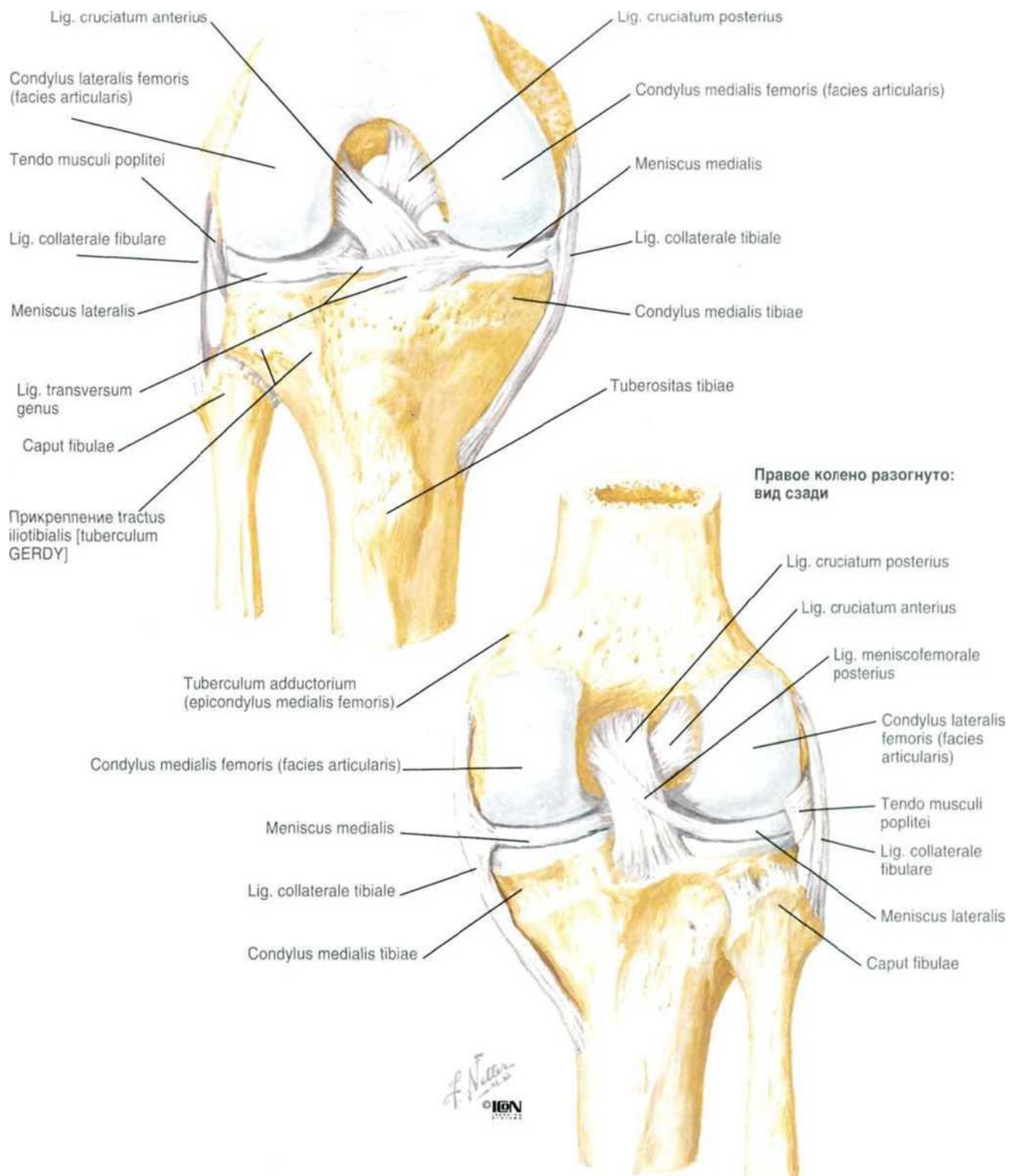
Yuqoridan ko'rinishi: boylam va tog'aylari olib tashlangan



Oldingi yuzasi

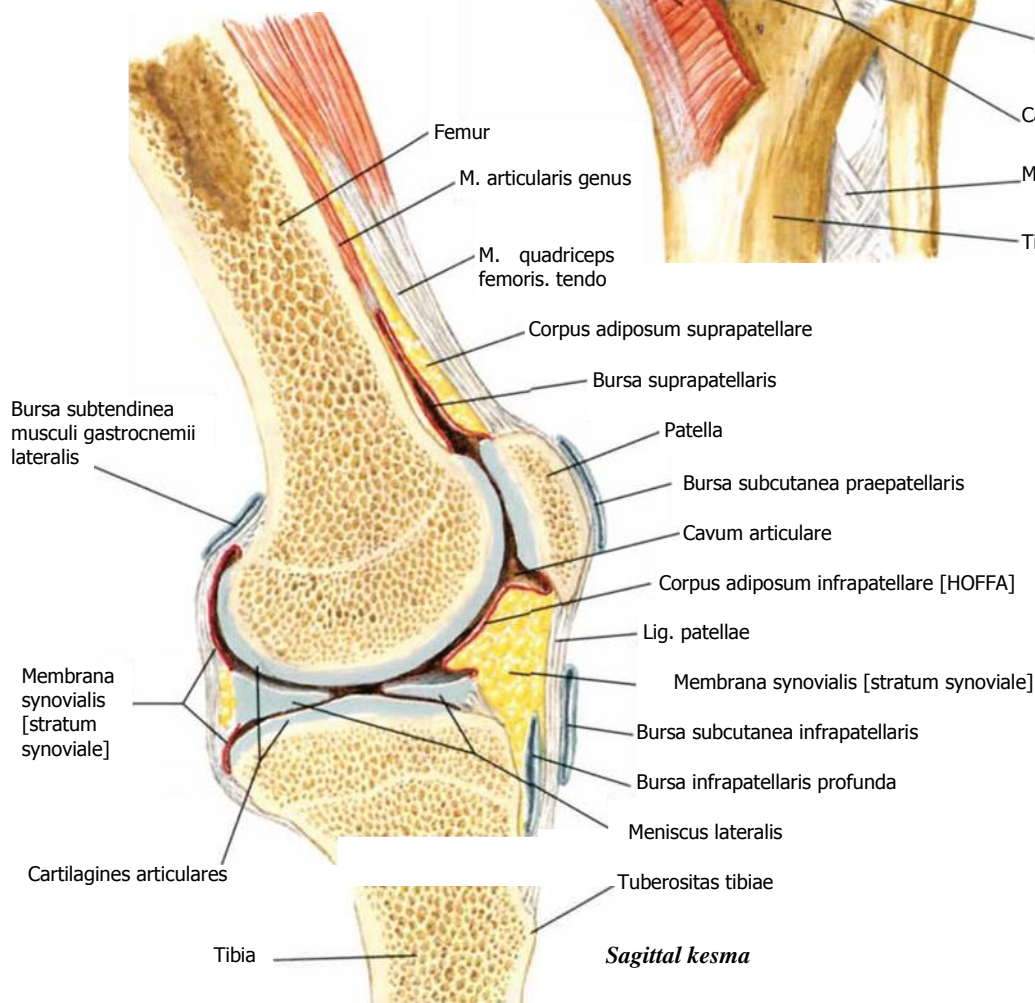
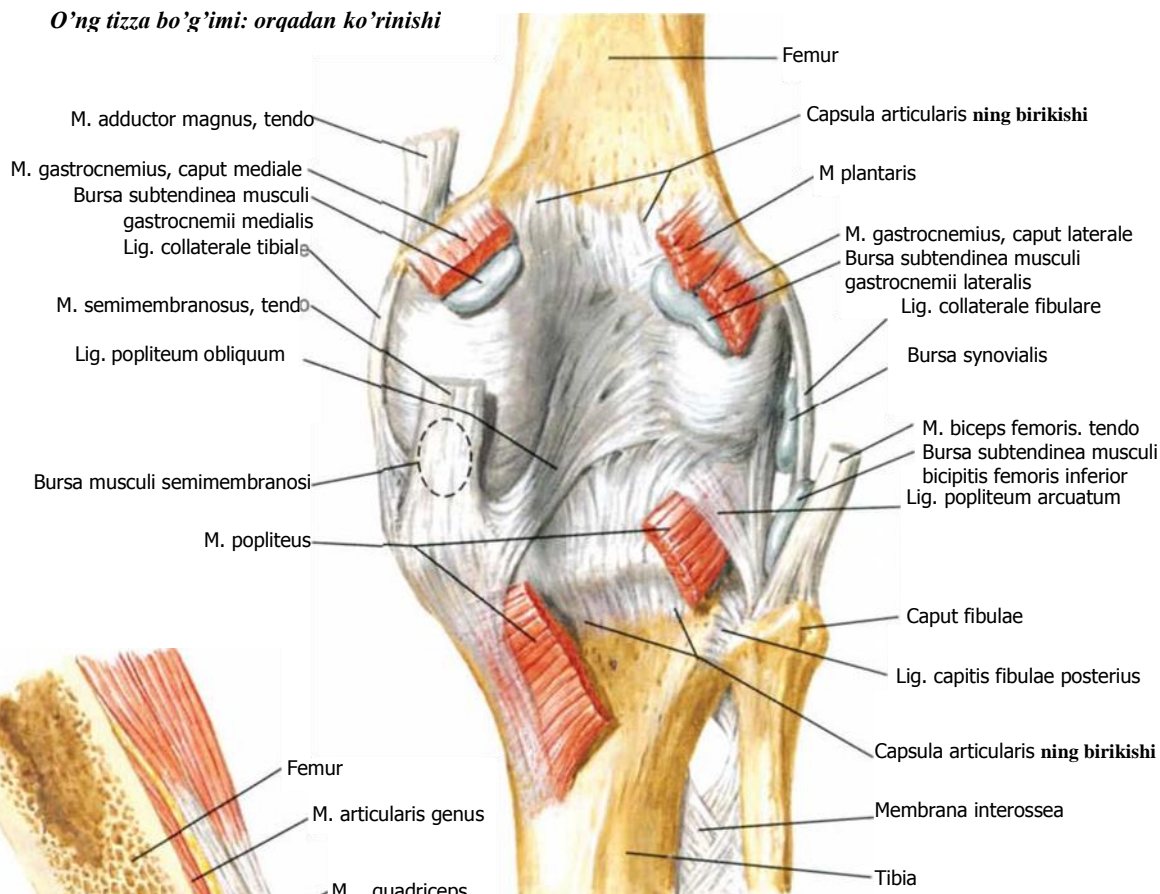
Tizza bo'g'imi: krestsimon va kollateral boylamlar

O'ng tizza bo'g'imi bukilgan: oldindan ko'rinishi

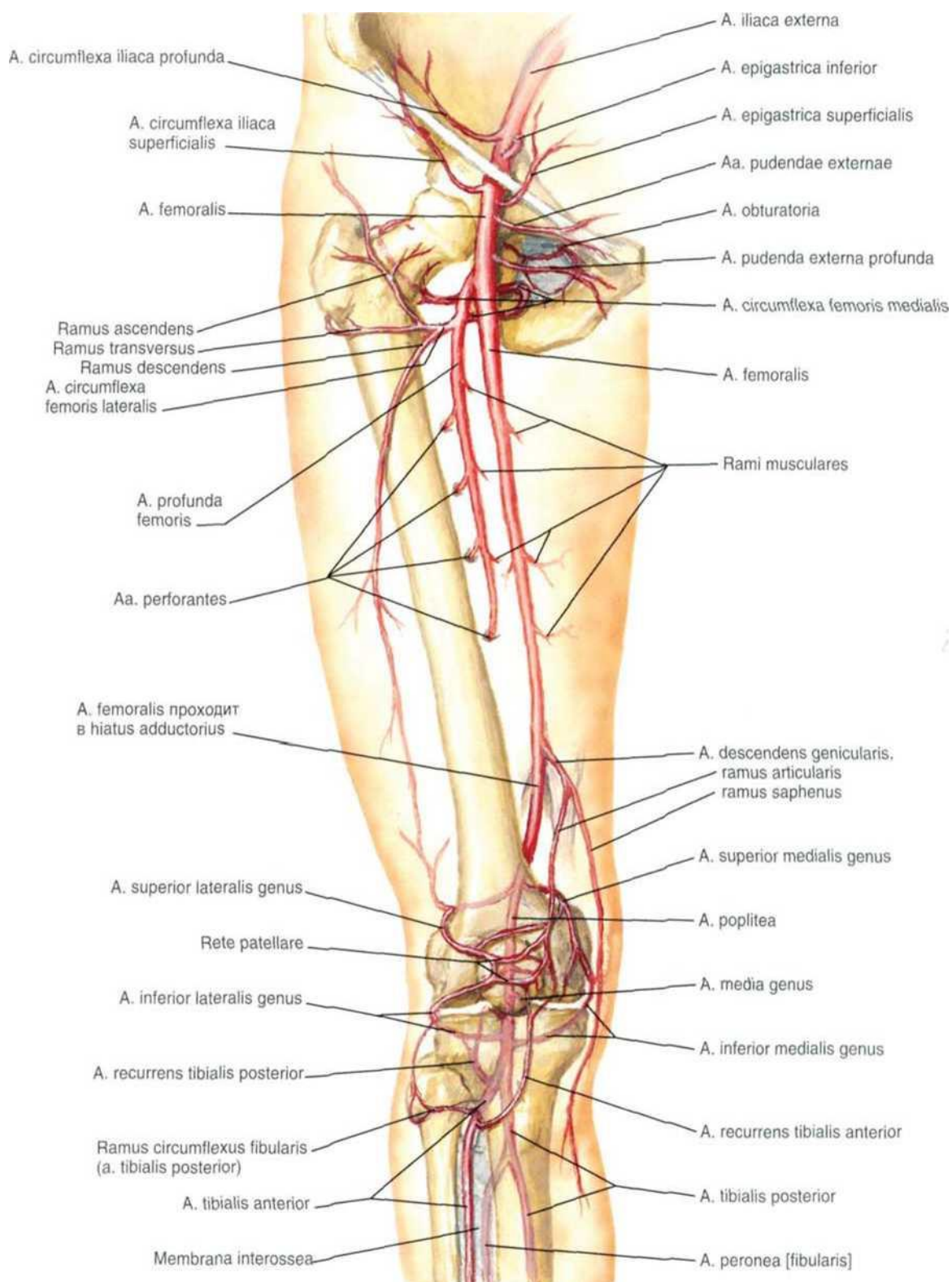


Tizza bo'g'imi: orqadan ko'rinishi va sagittal kesmasi

O'ng tizza bo'g'imi: orqadan ko'rinishi



Sagittal kesma

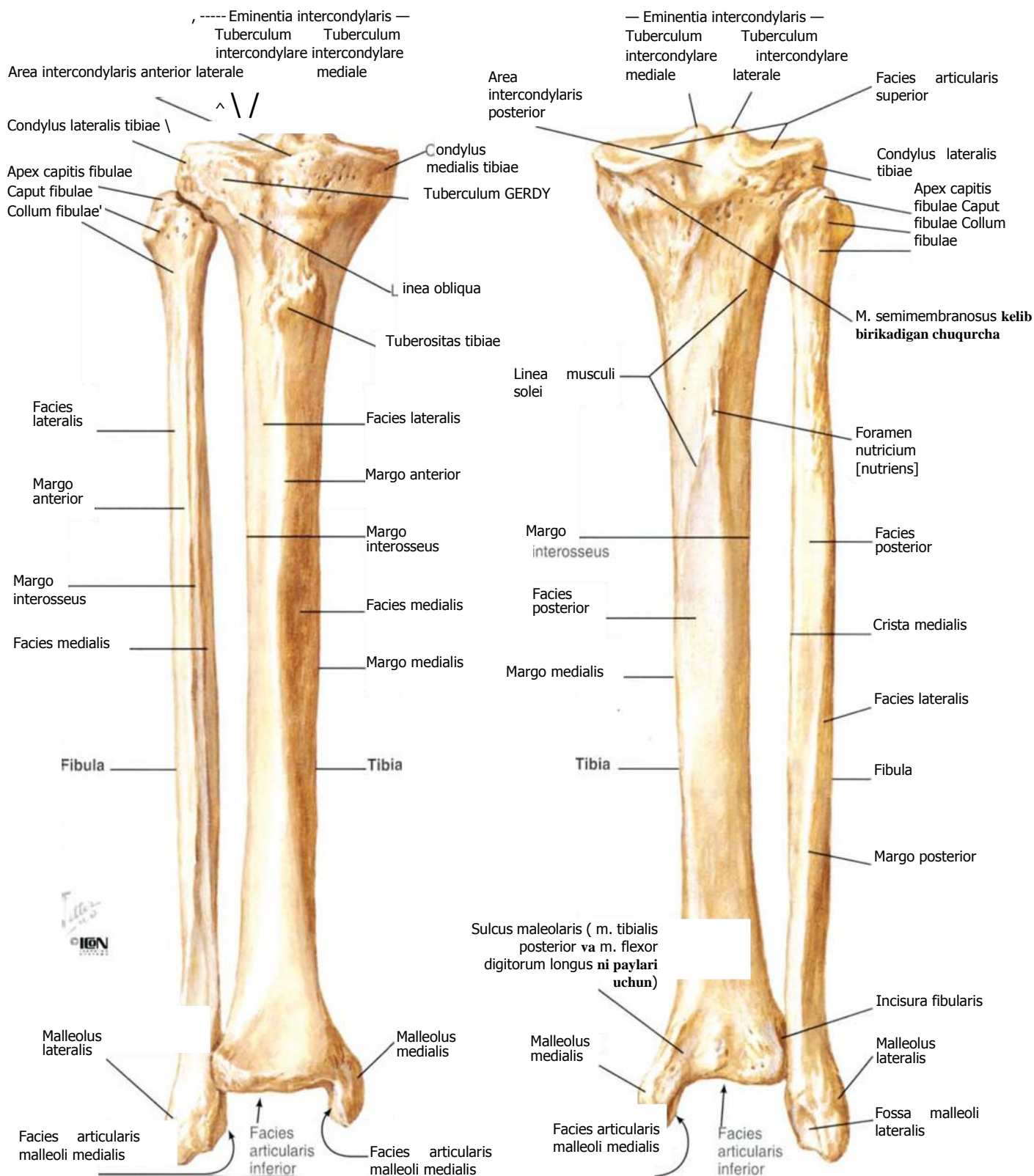


Boldir suyaklari: katta va kichik boldir suyaklari

O'ng boldir soxasi suyaklari

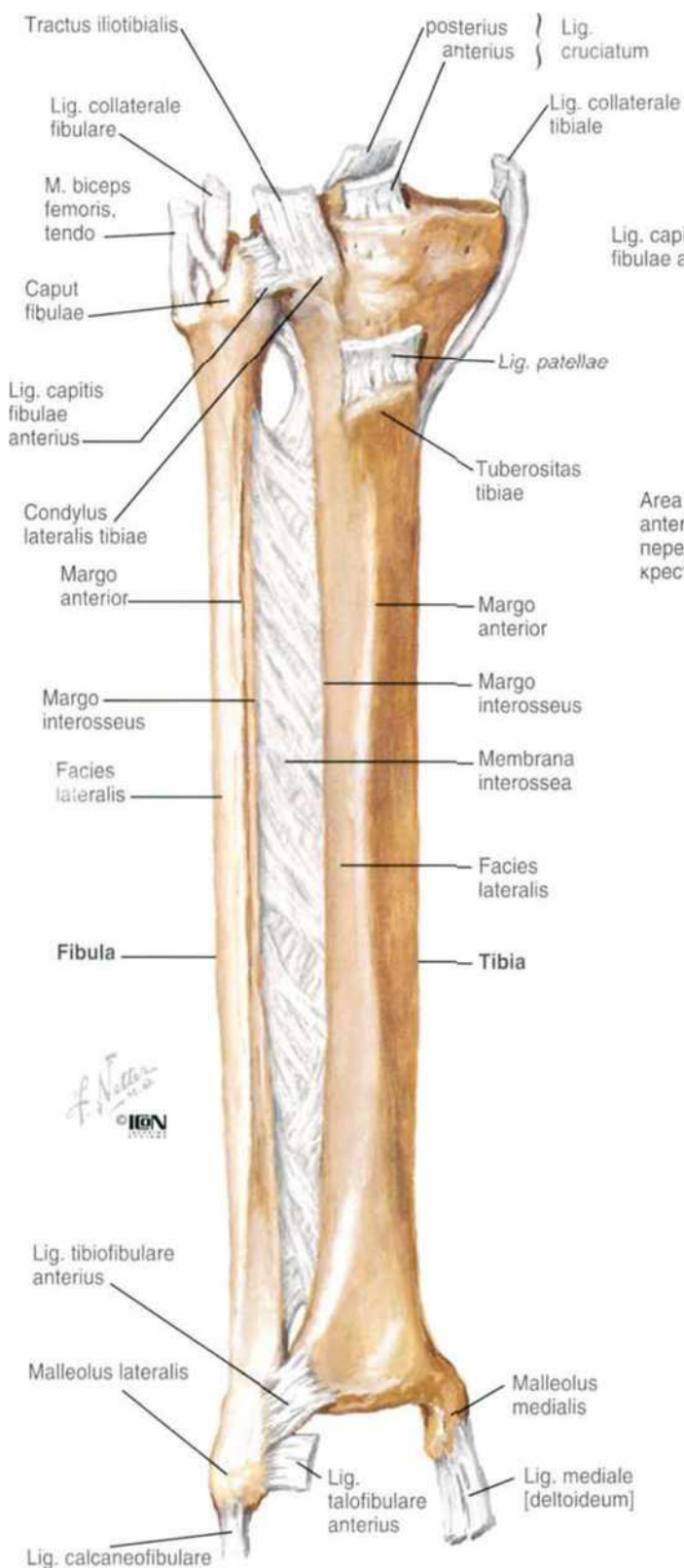
Oldindan ko'rinishi

Orqadan ko'rinishi

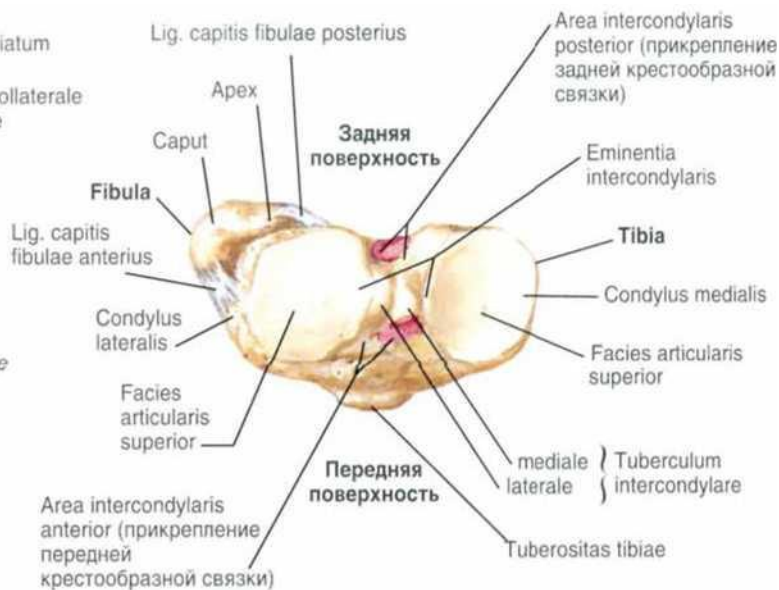


Katta boldir va kichik boldir suyaklari (davomi)

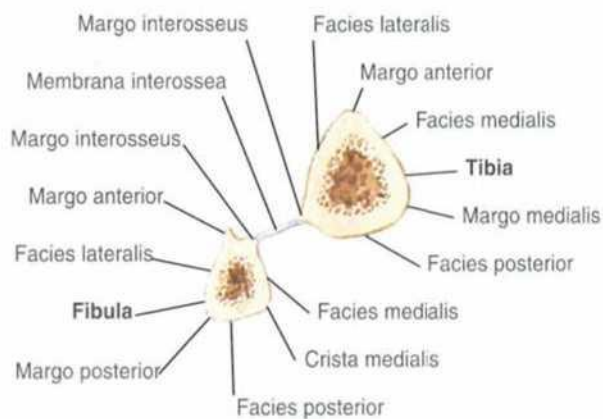
Oldindan ko'rinishi



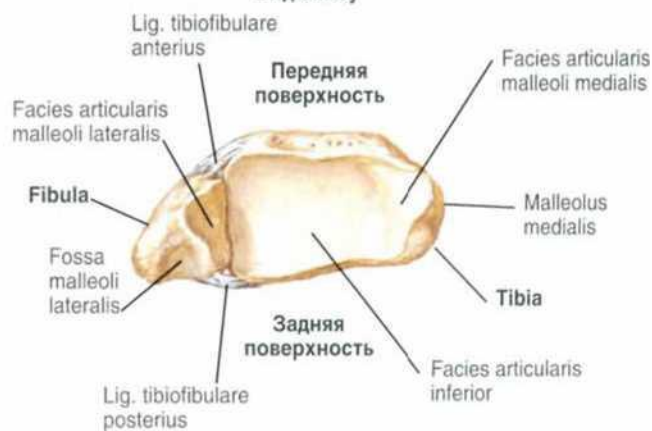Orqadan ko'rinishi



Поперечный срез

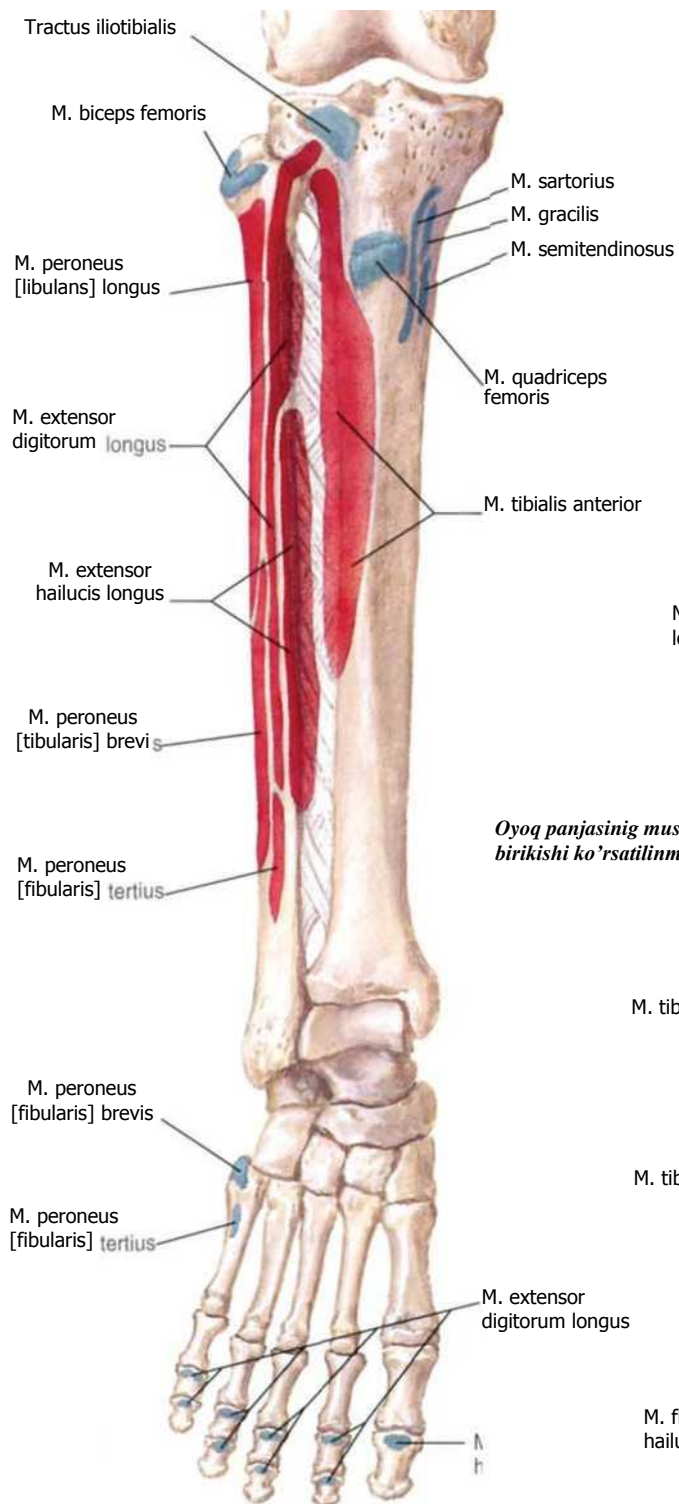


Вид снизу

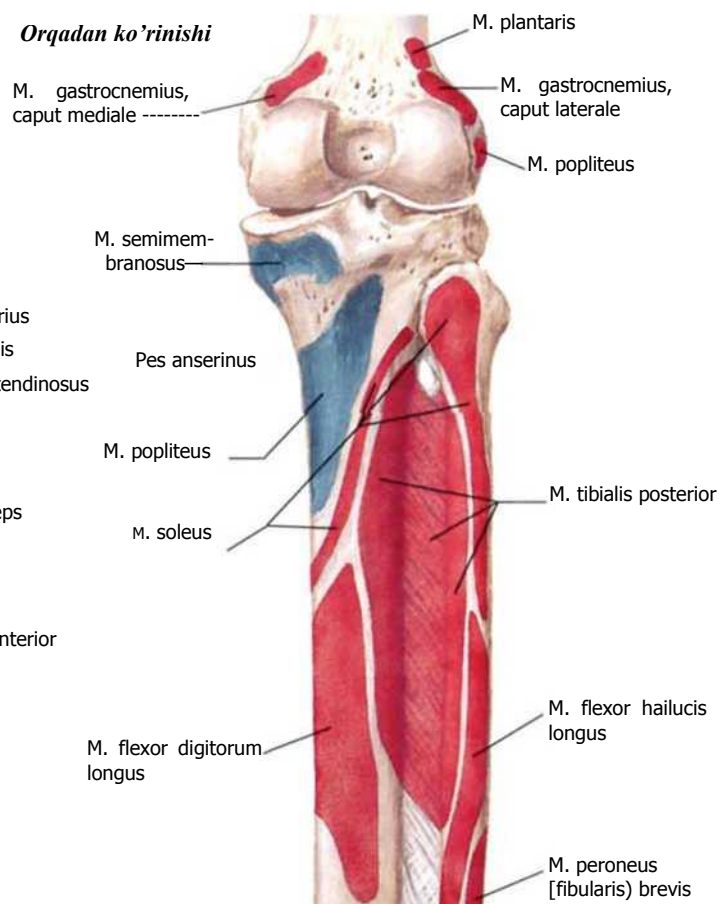


Boldir va oyoq panjasiga muskullarni birikishi

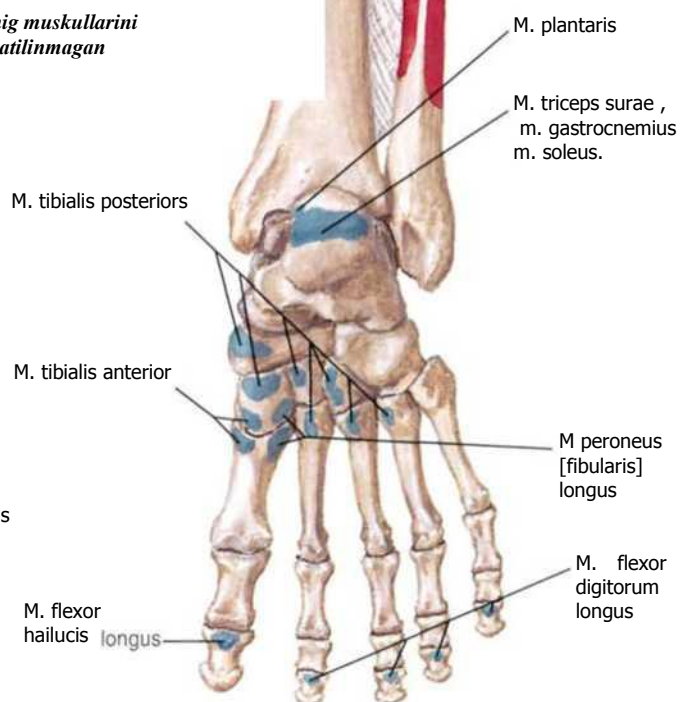
Oldindan ko'rinishi



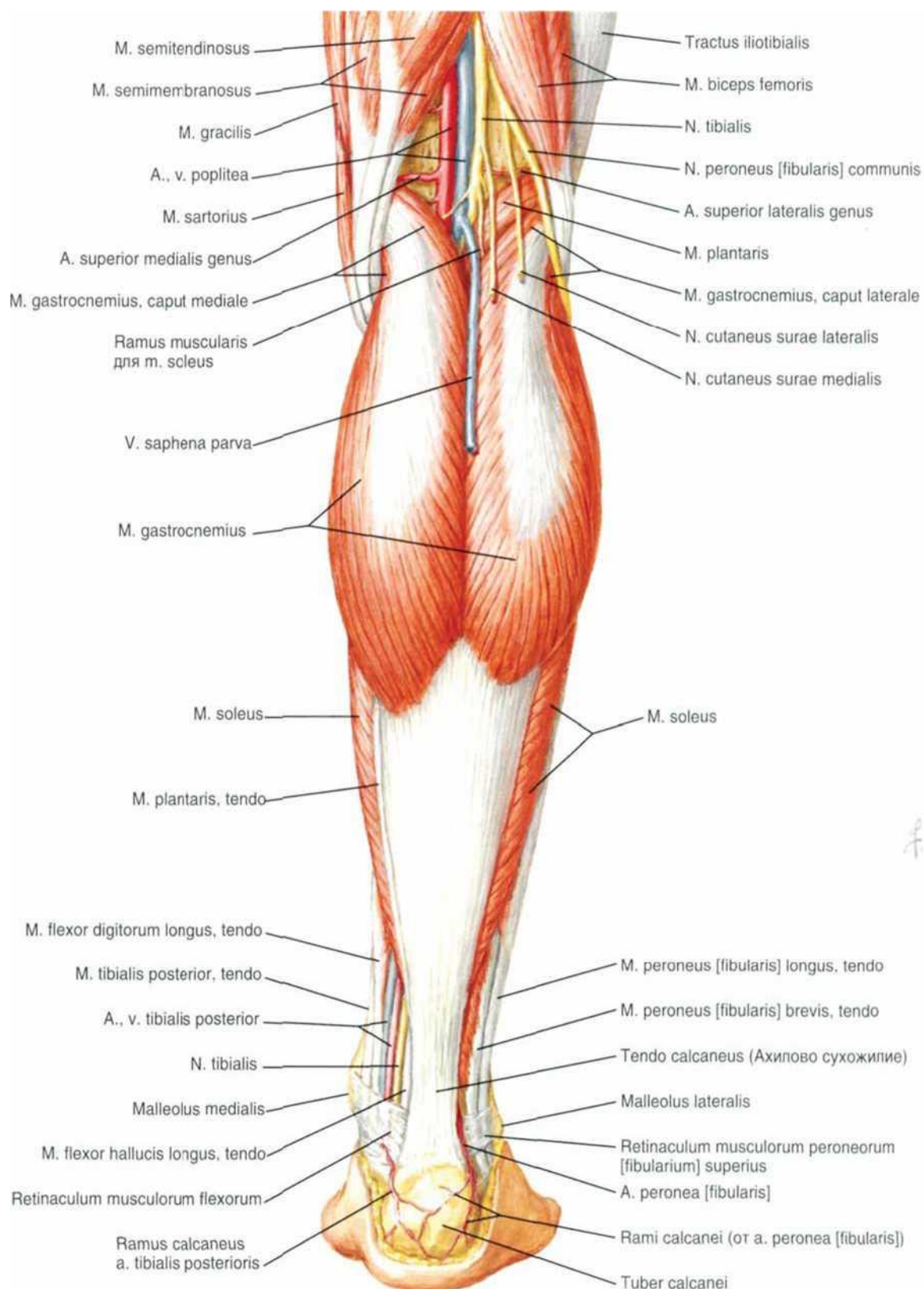
Orqadan ko'rinishi



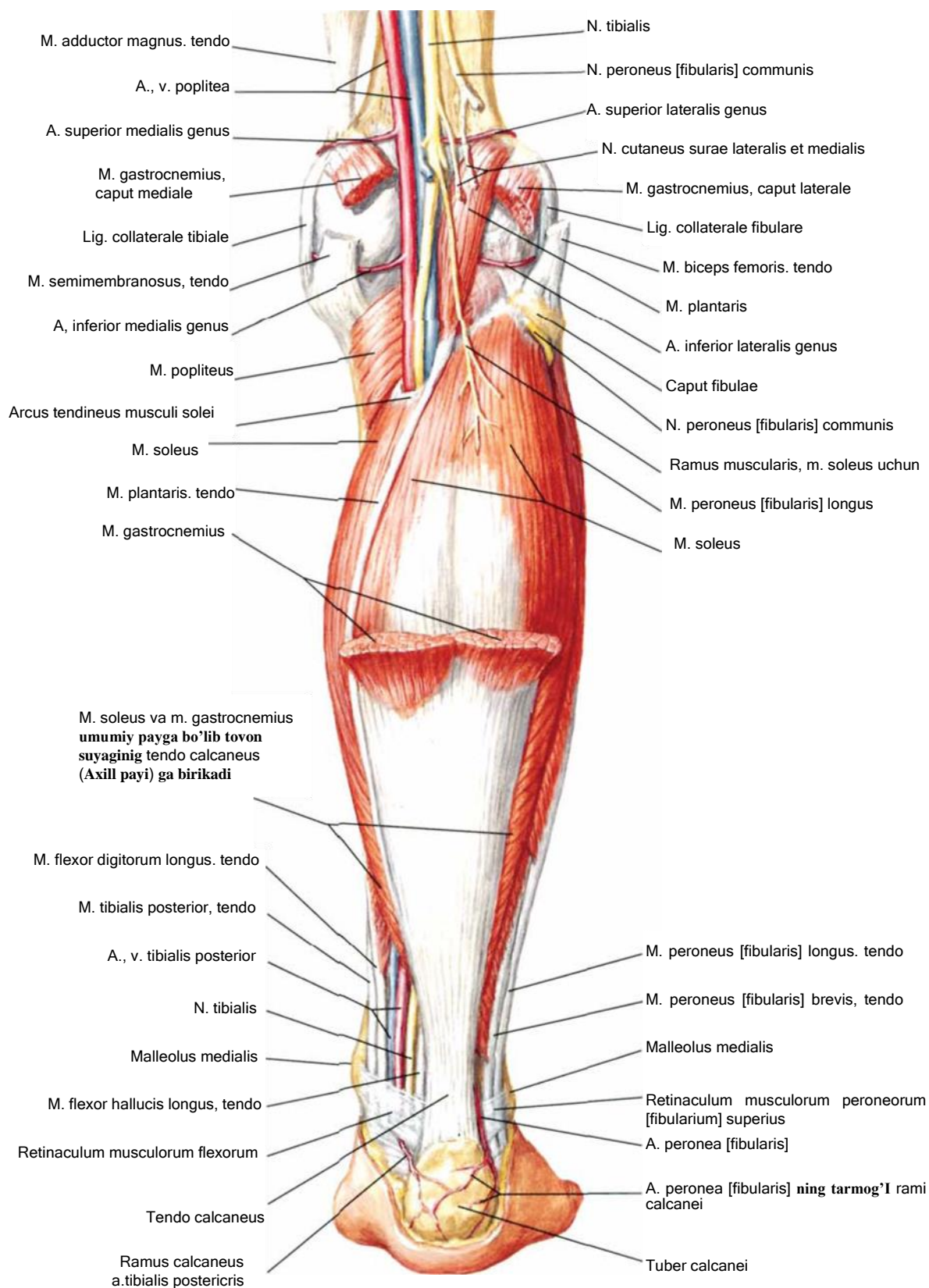
Oyoq panjasig muskullarini birikishi ko'rsatilmagan



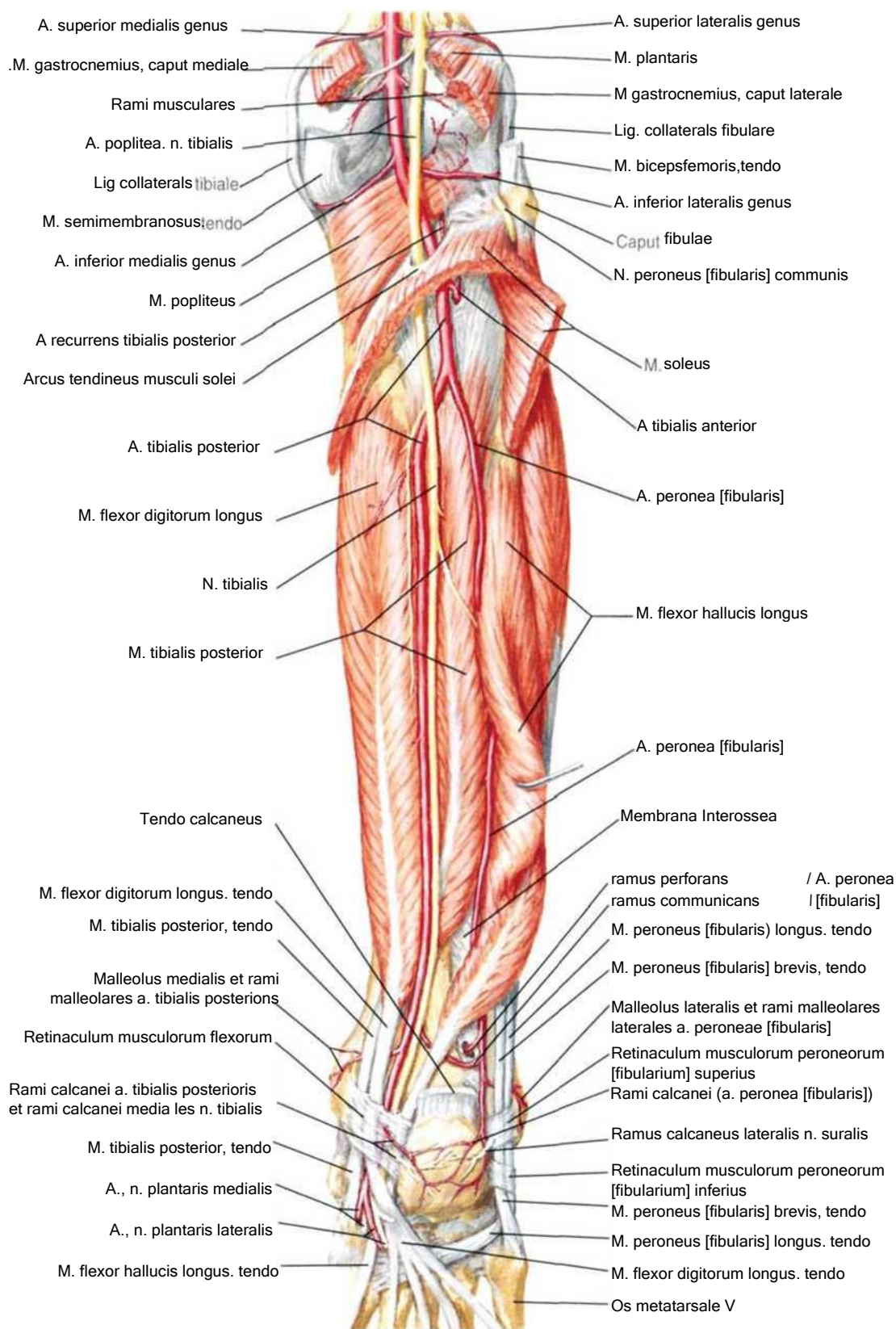
Boldir muskullari: orqa guruhdagi muskullari



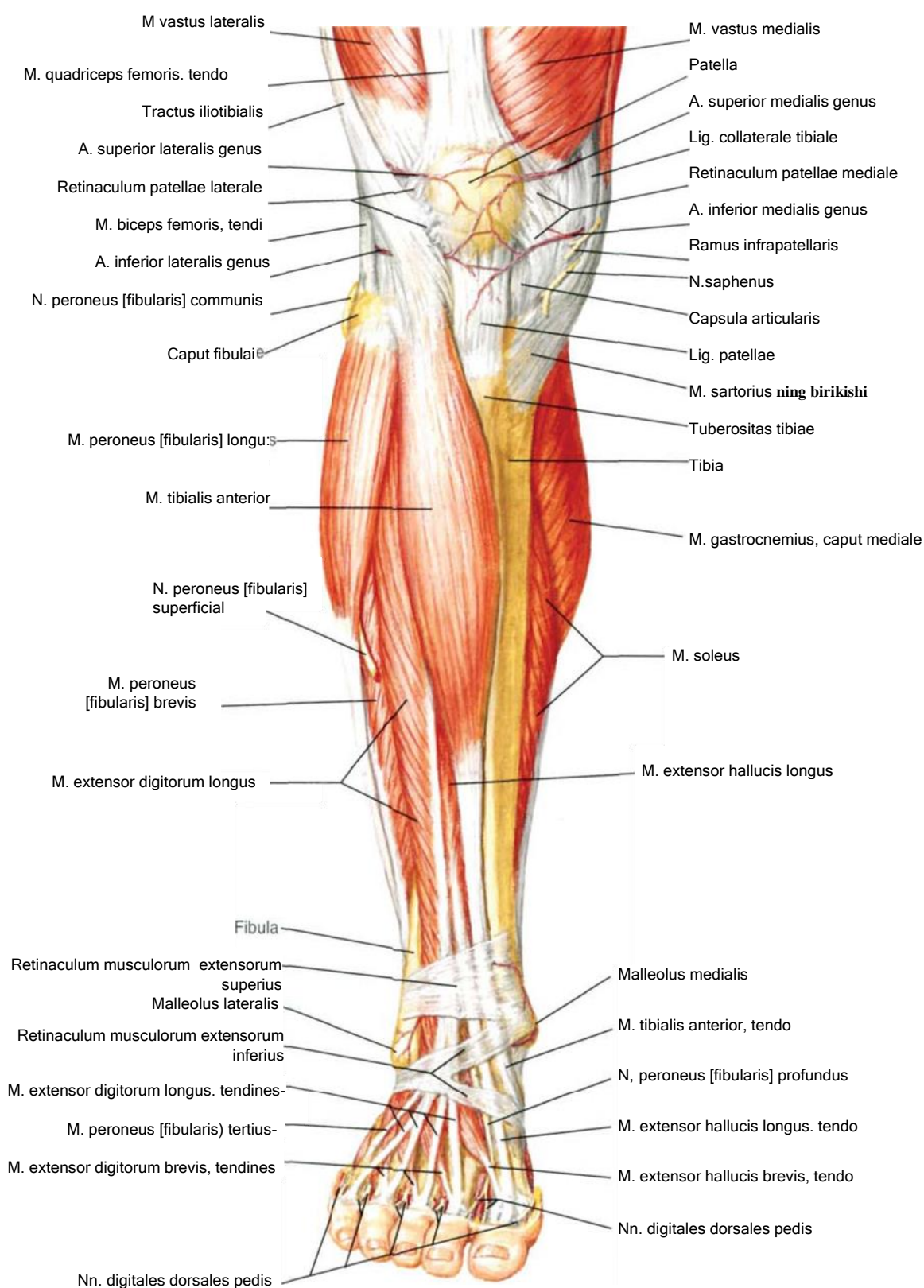
Boldir muskullari: orqa guruhdagi muskullari (davomi)



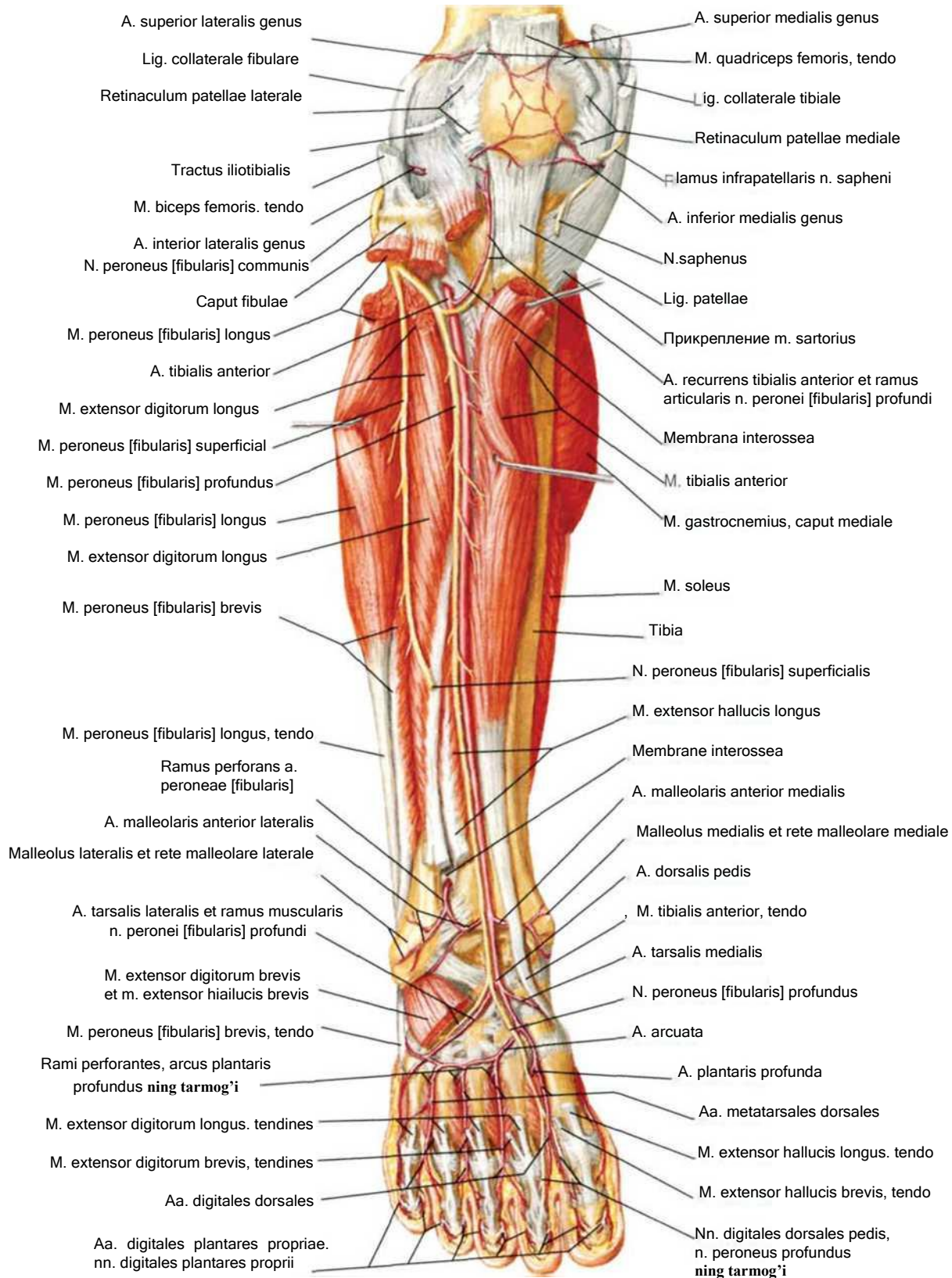
Boldir muskullari: orqa guruhi, chuqur qavatlar (davomi)



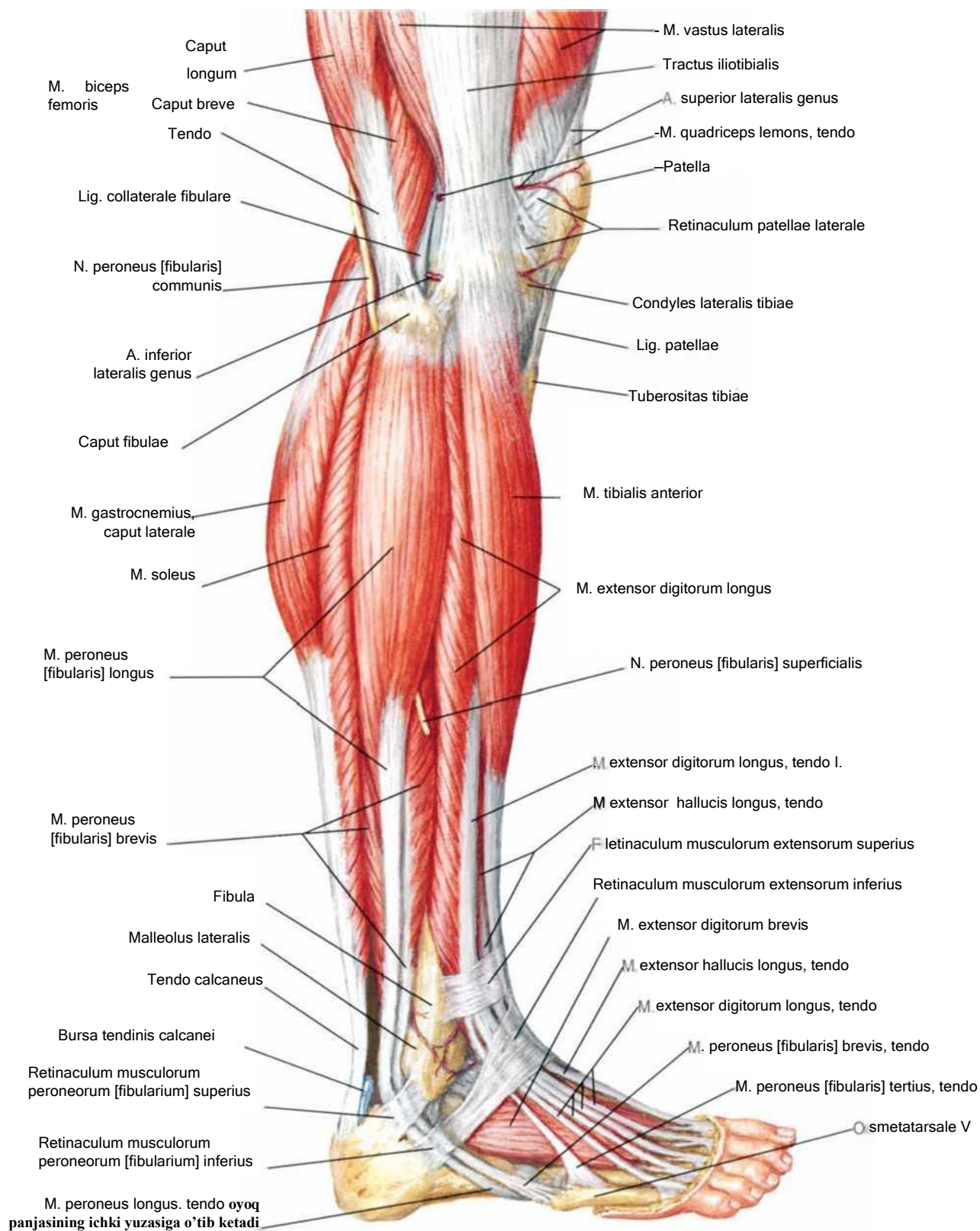
Boldir muskullari: oldingi guruhdagi muskullar



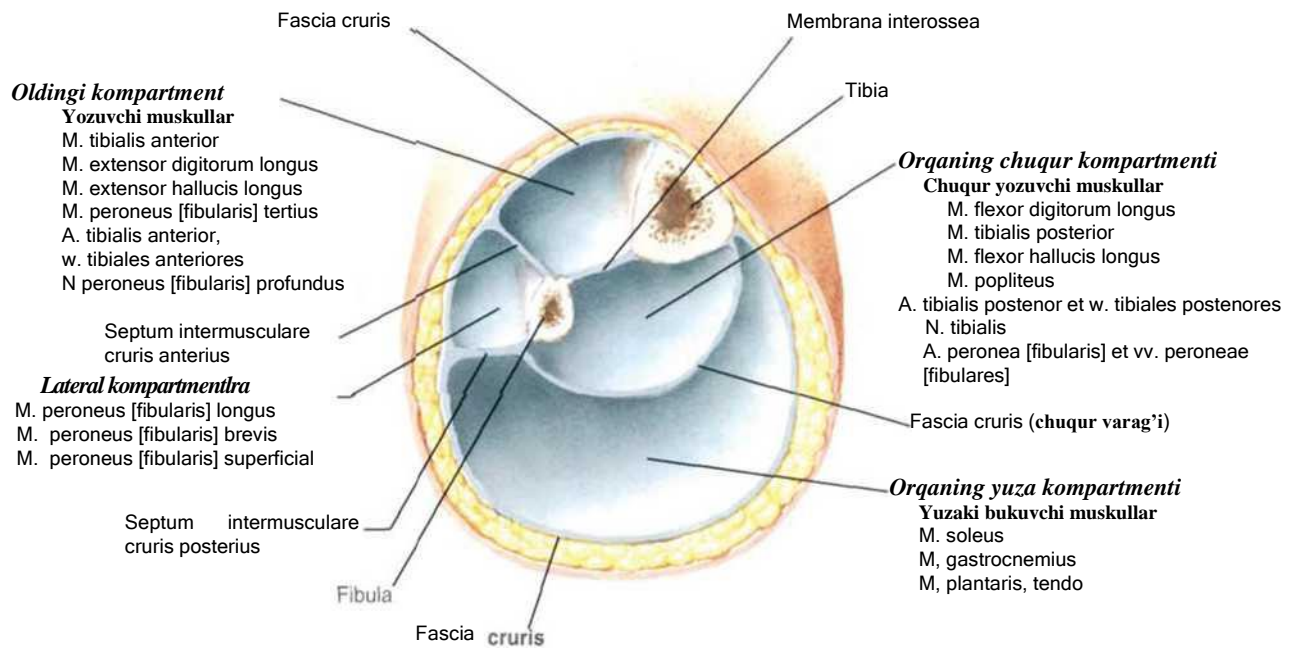
Boldir muskullari: oldingi guruhdagi muskullar (chuqur qavati)



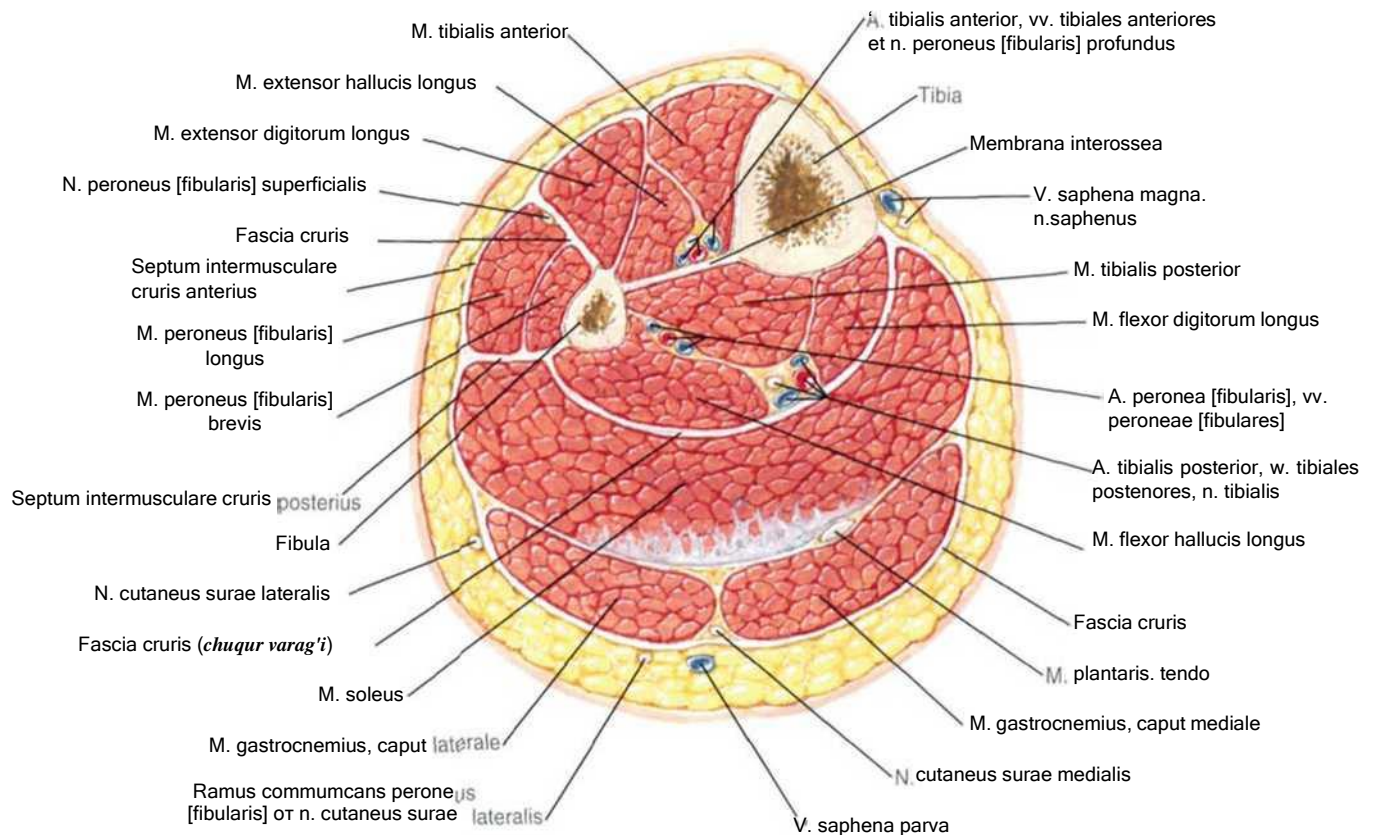
Boldir muskullari: lateral tarafdin ko'rinishi



Boldirni ko'ndalang kesmasi: fastsial qinlar

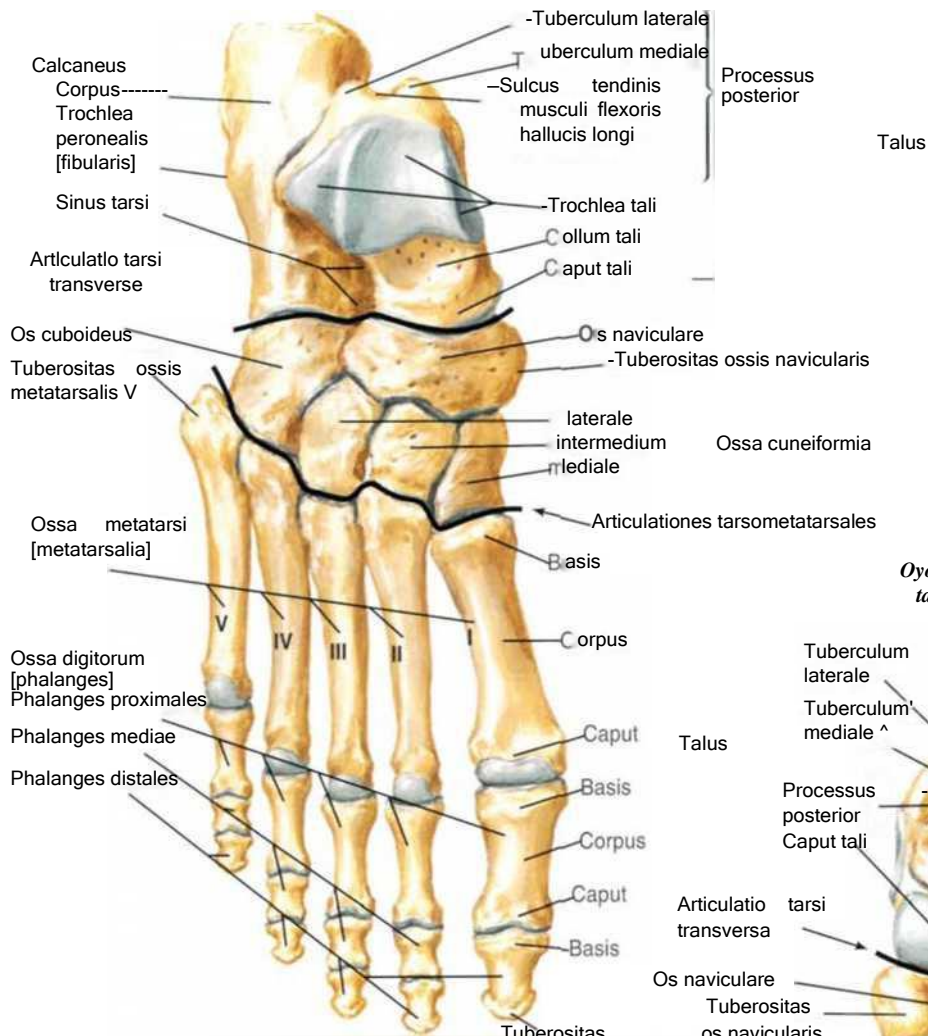


Boldirning o'rta qismining teparog'idan o'tgan ko'ndalang kesma

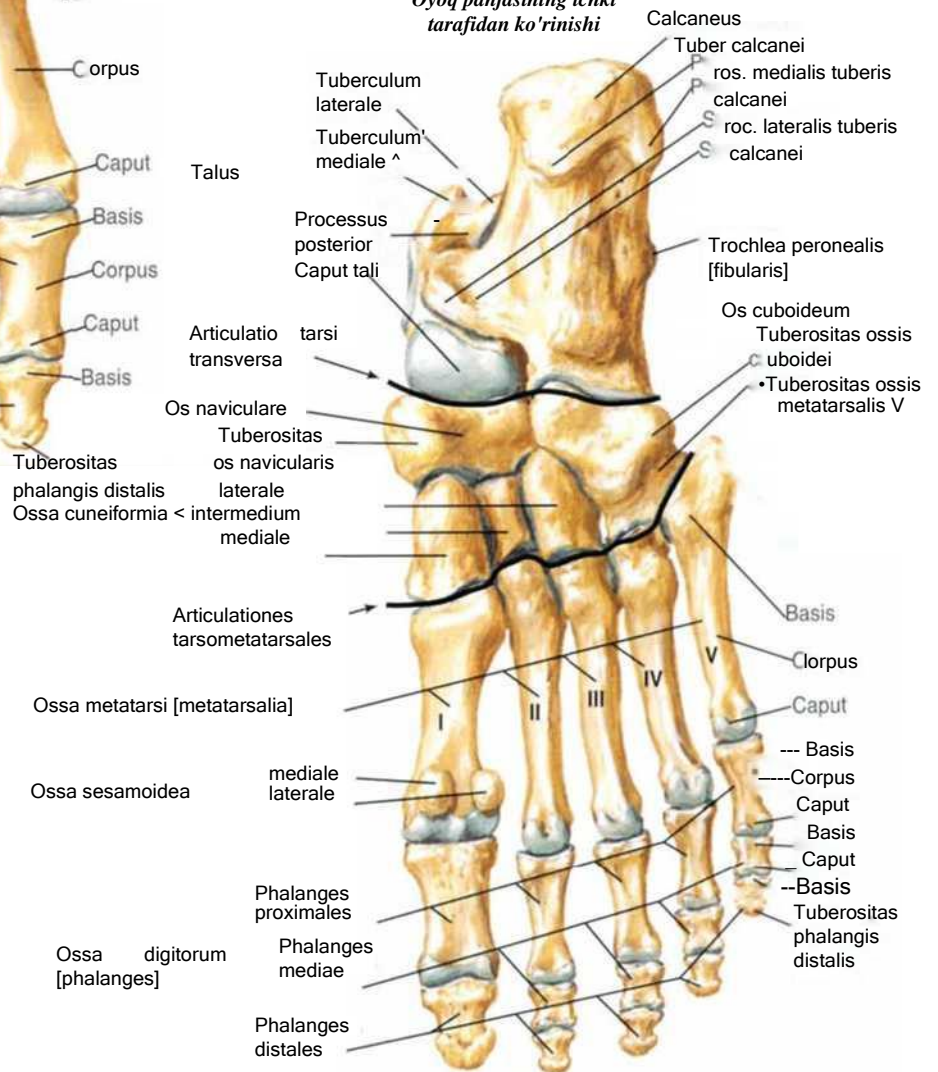


Oyoq panjasi suyaklari

Yuqoridan ko'rinishi

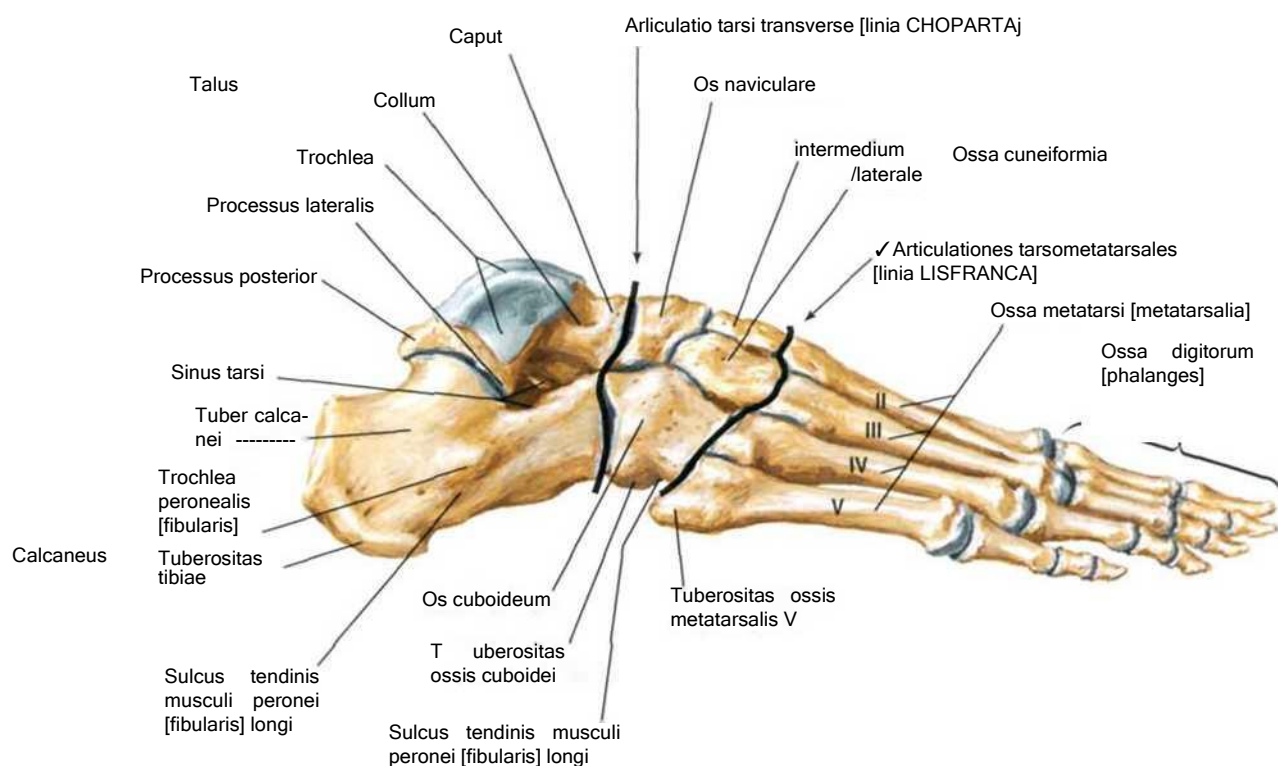


*Oyoq panjasining ichki
tarafidan ko'rinishi*

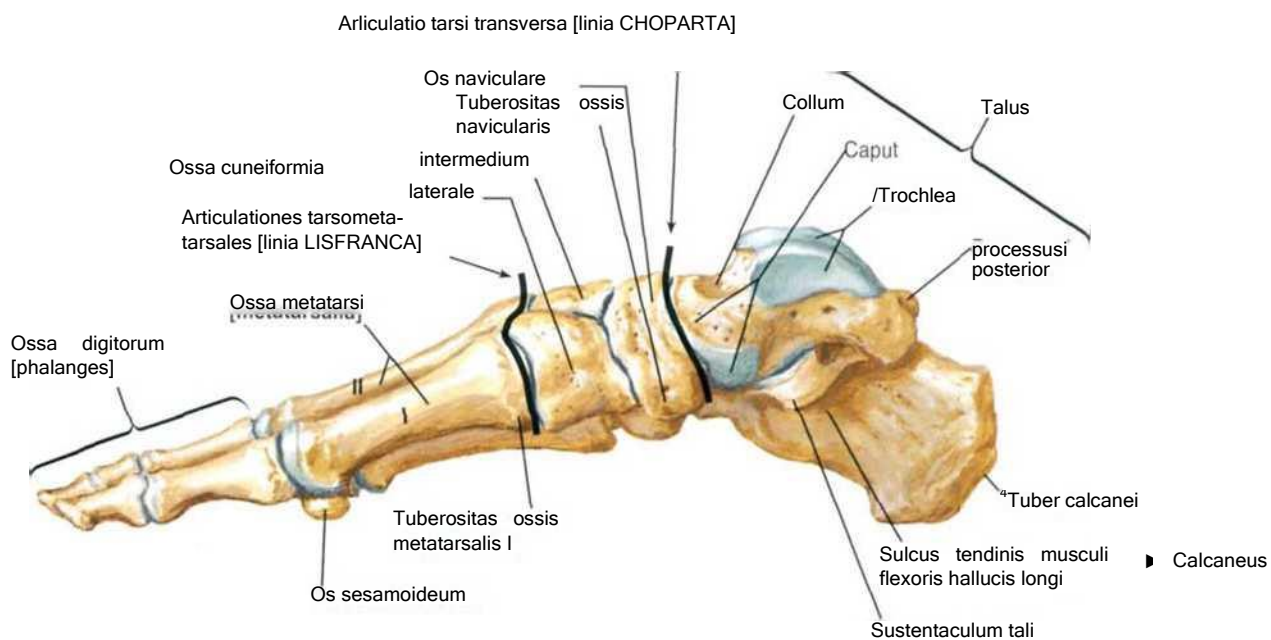


Oyoq panjasi suyaklari

Lateral tarafdin ko'rinishi

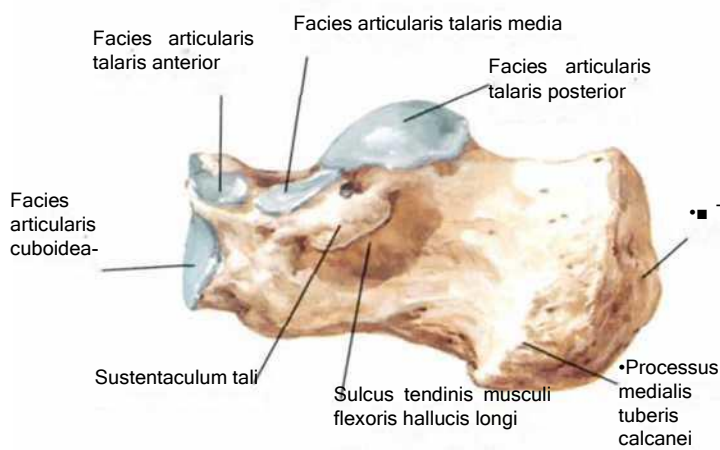
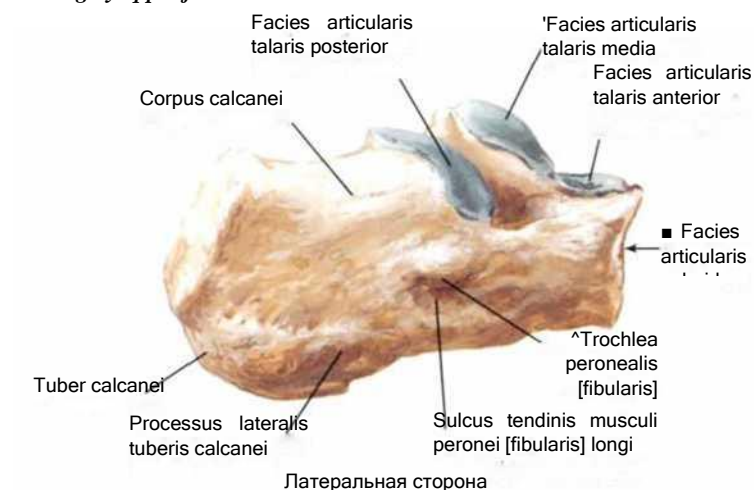


Medial tarafdin ko'rinishi

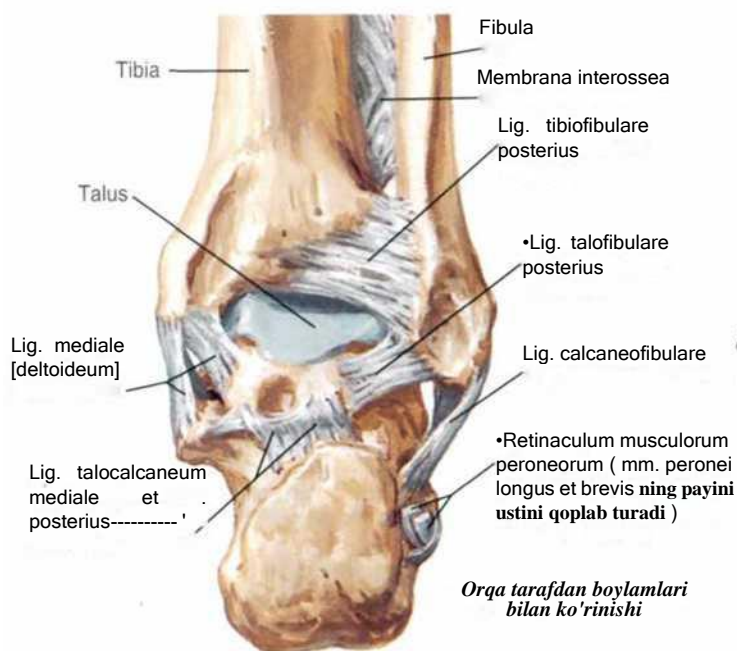


Tovon suyagi (calcaneus)

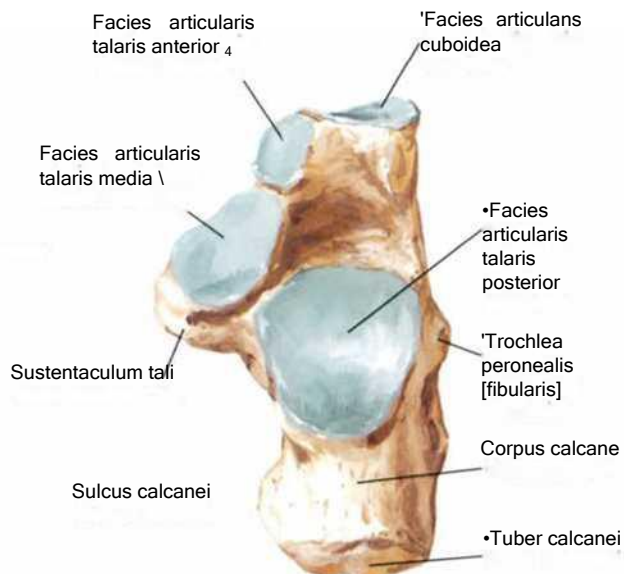
O'ng oyoq panjasi



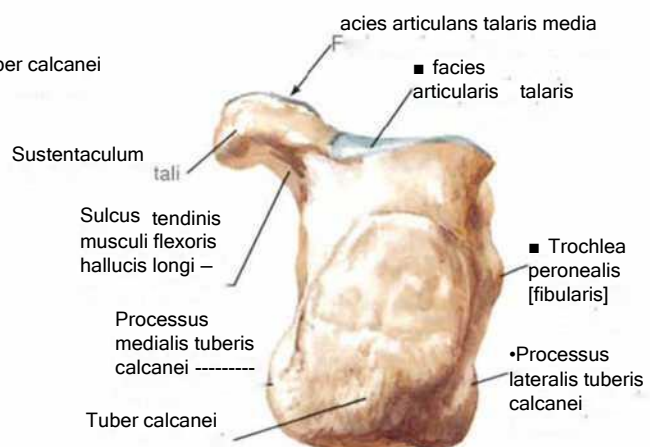
Medial tarafi



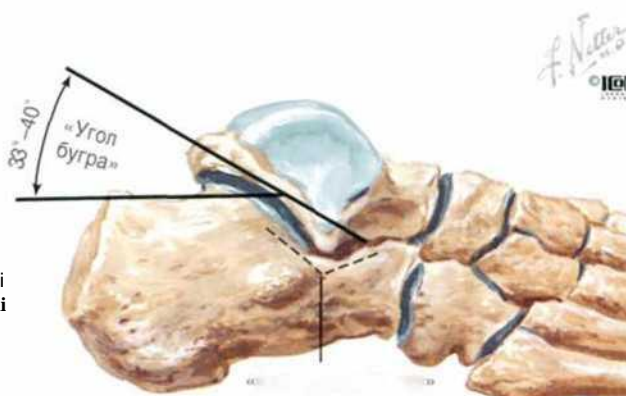
Orqa tarafdin boylamlari bilan ko'rinishi



Yuqoridan ko'rinishi

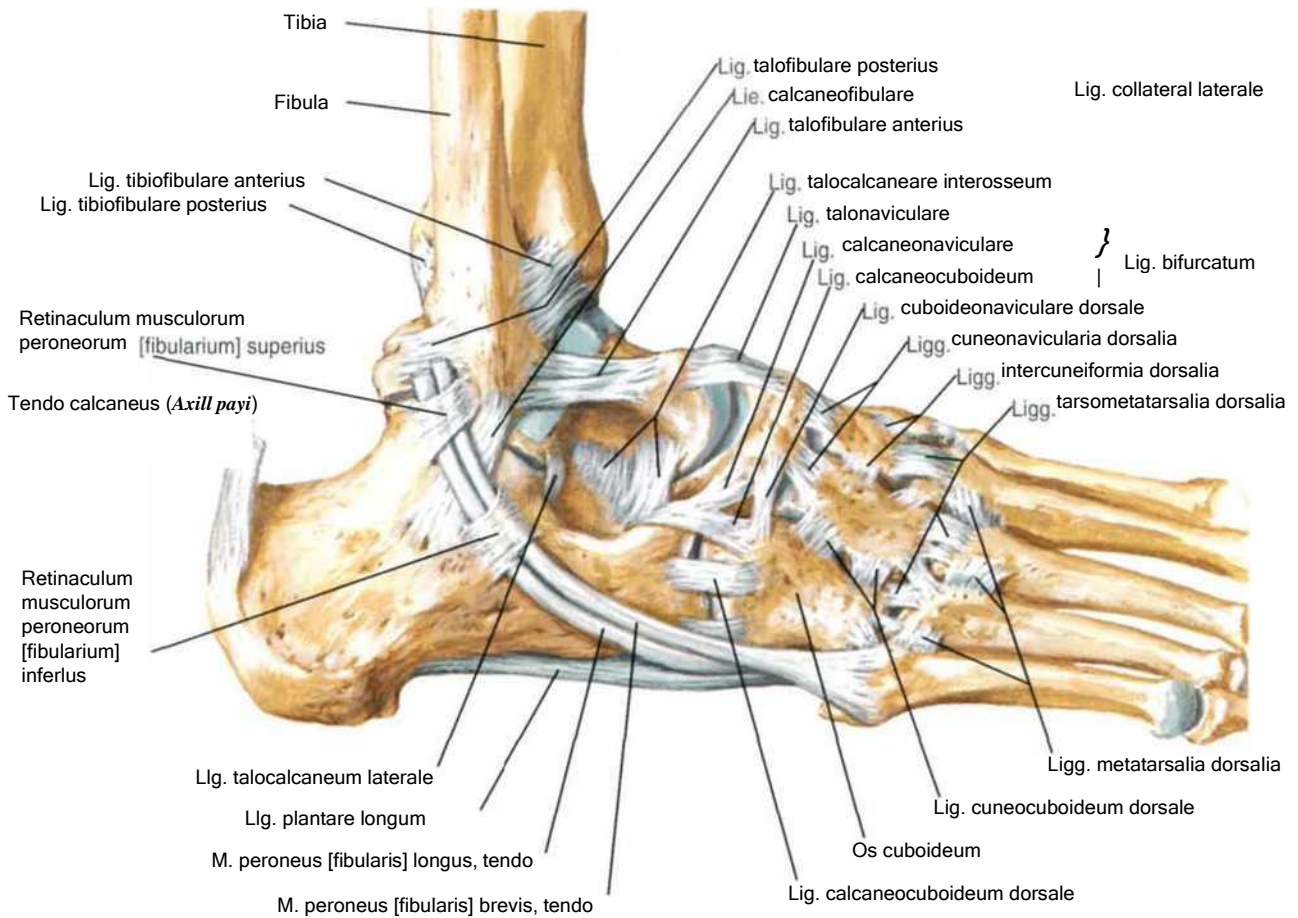


Orqadan ko'rinishi

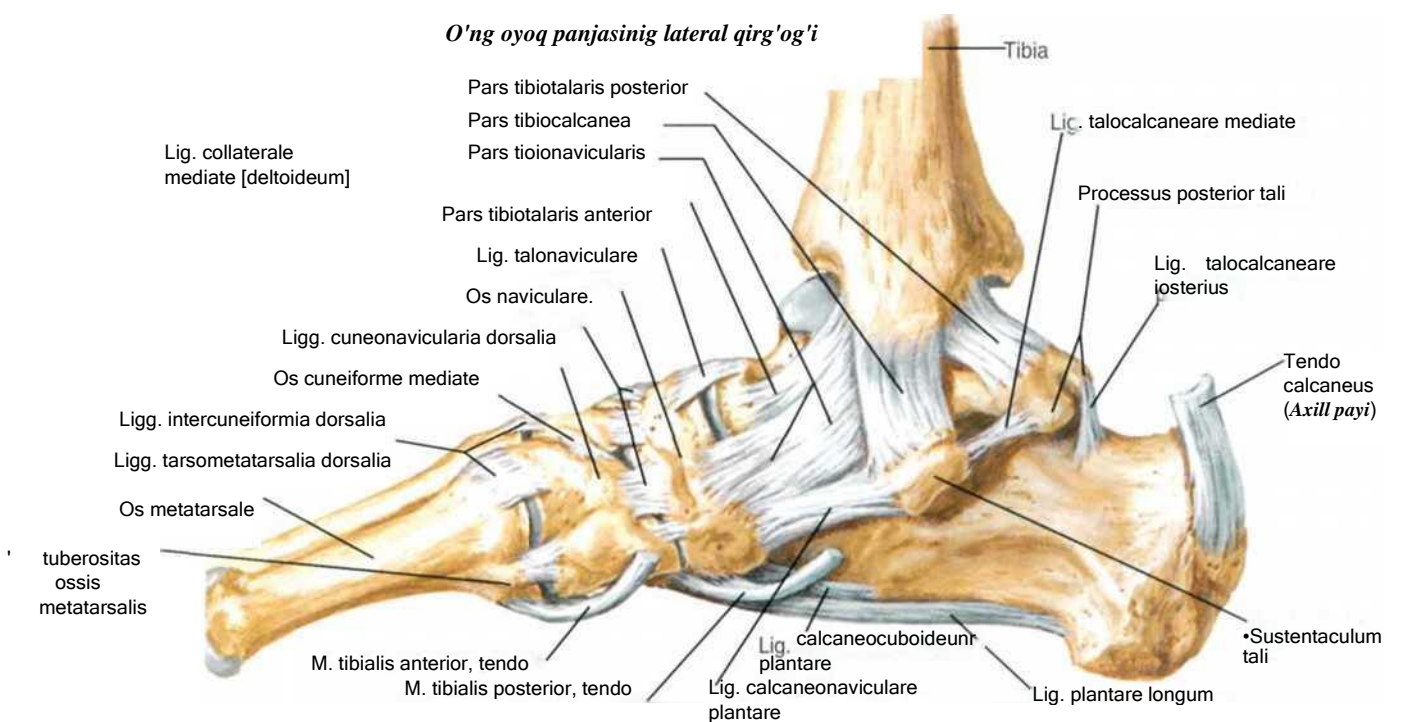


Tovon suyagining yondosh suyaklar bilan funktsional munosabati

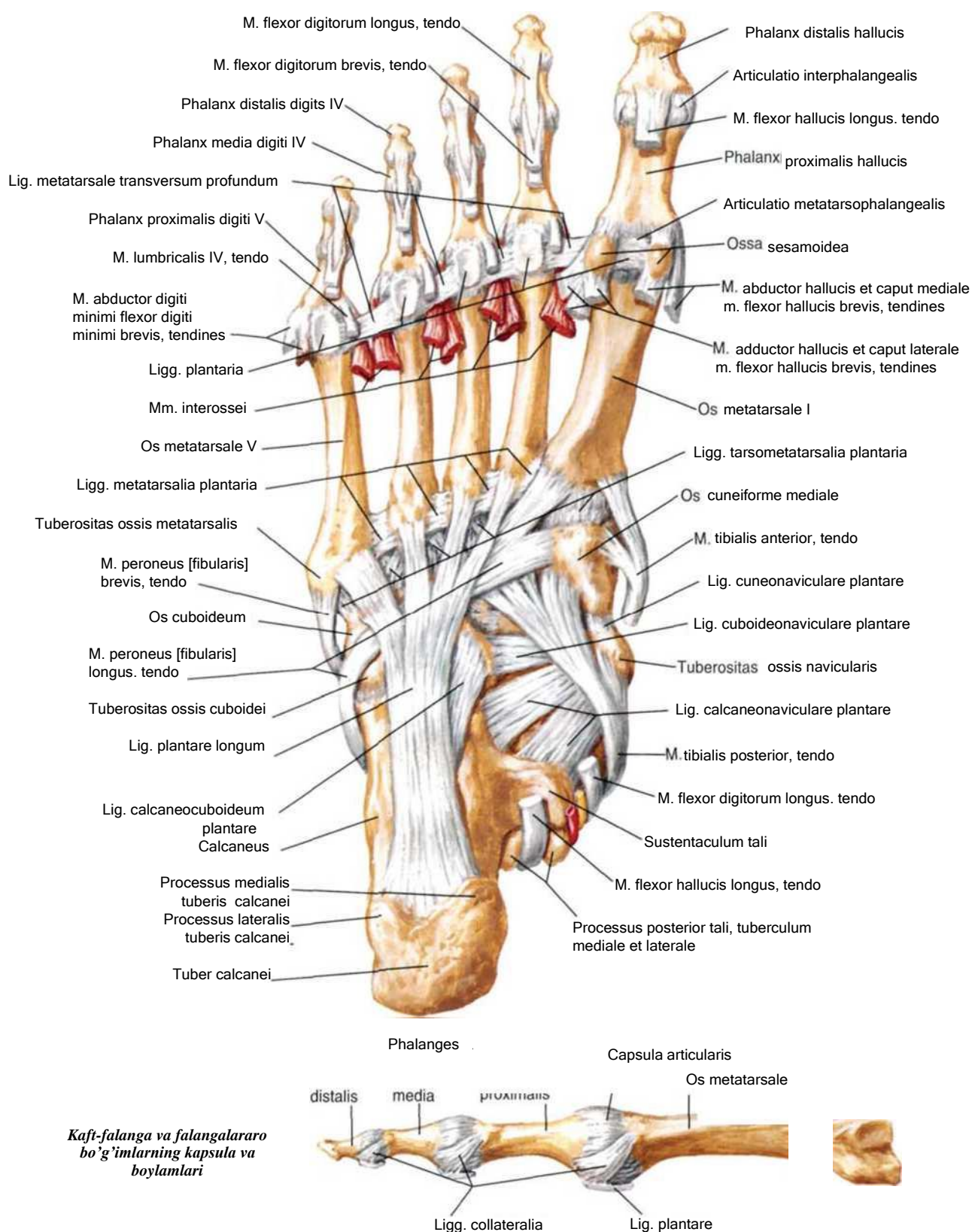
O'ng oyoq panjasinig lateral qirg'og'i



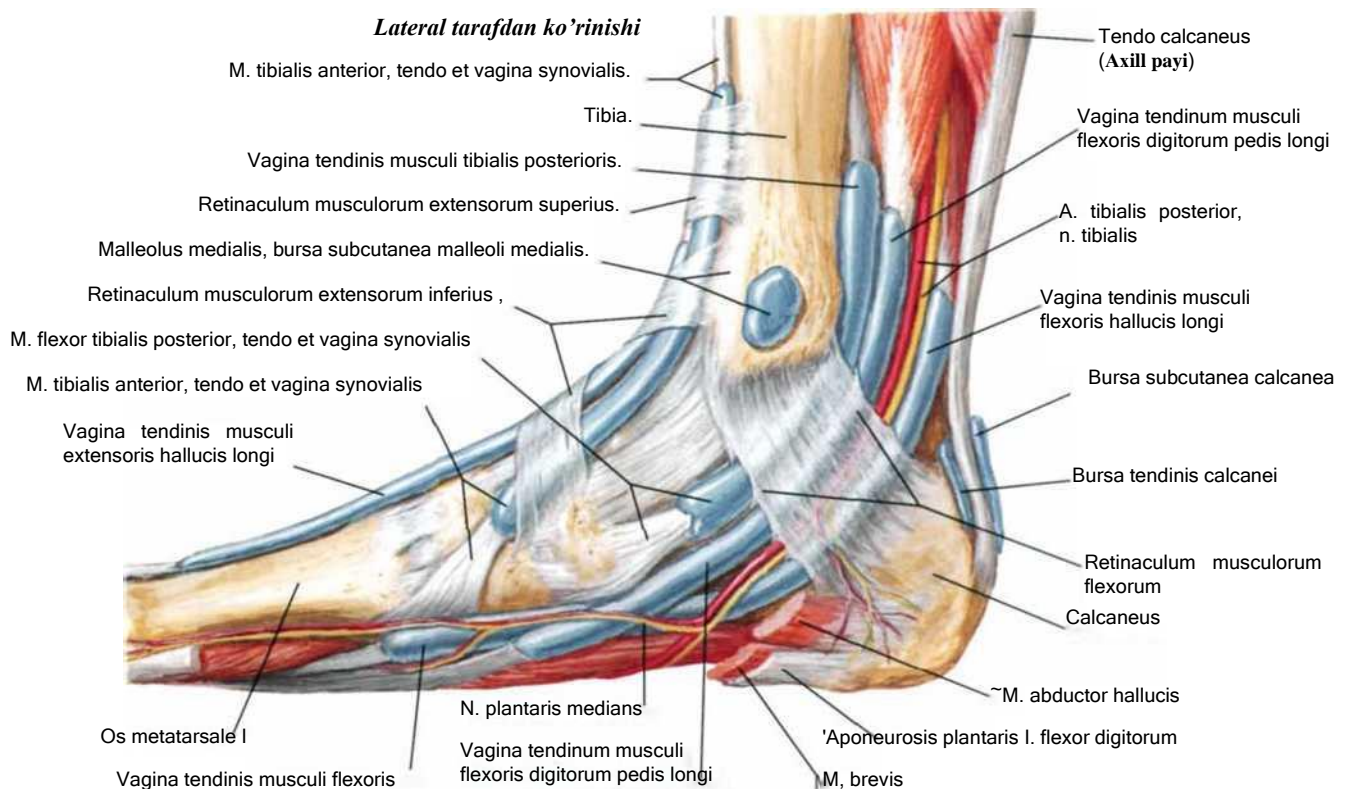
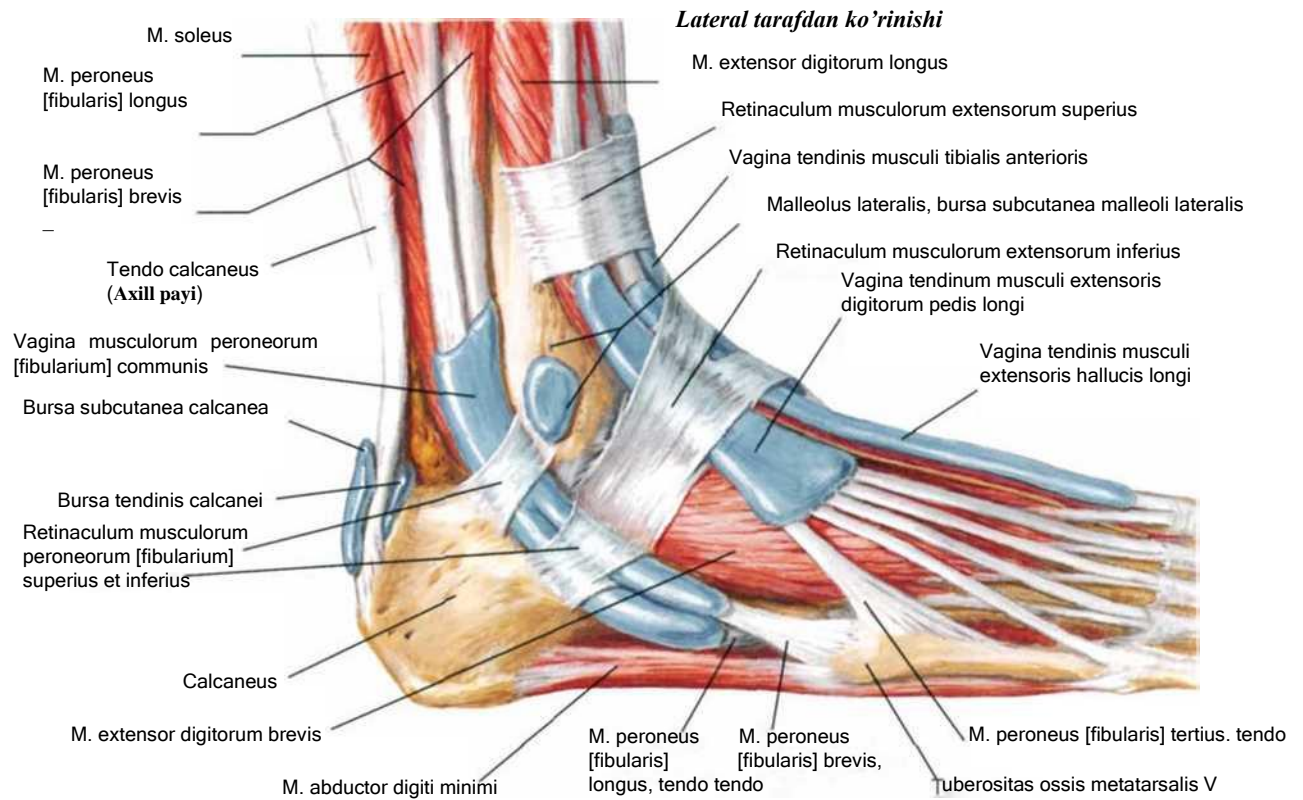
O'ng oyoq panjasinig lateral qirg'og'i



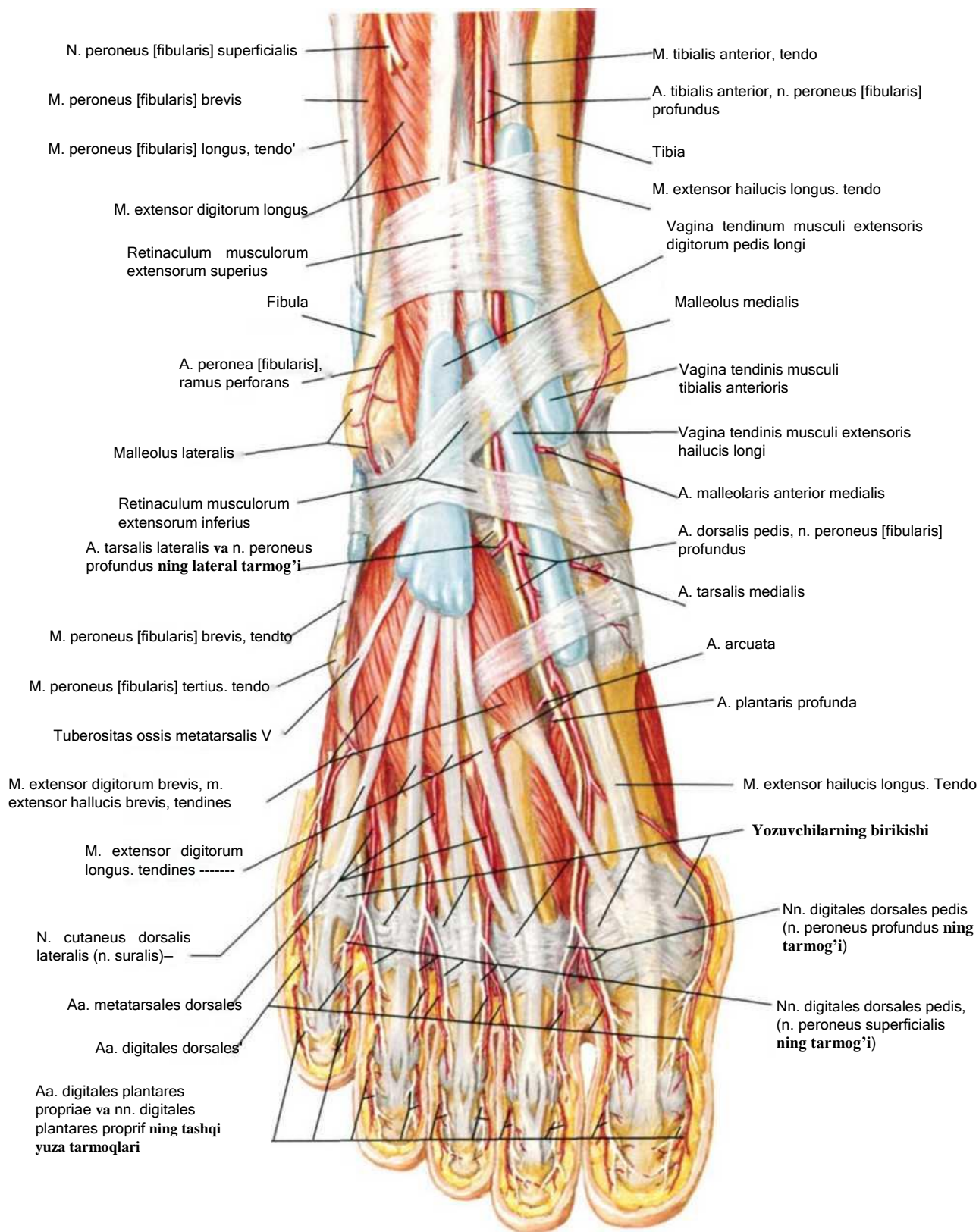
Oyoq panjasining ichki yuzasini pay va boylamlari



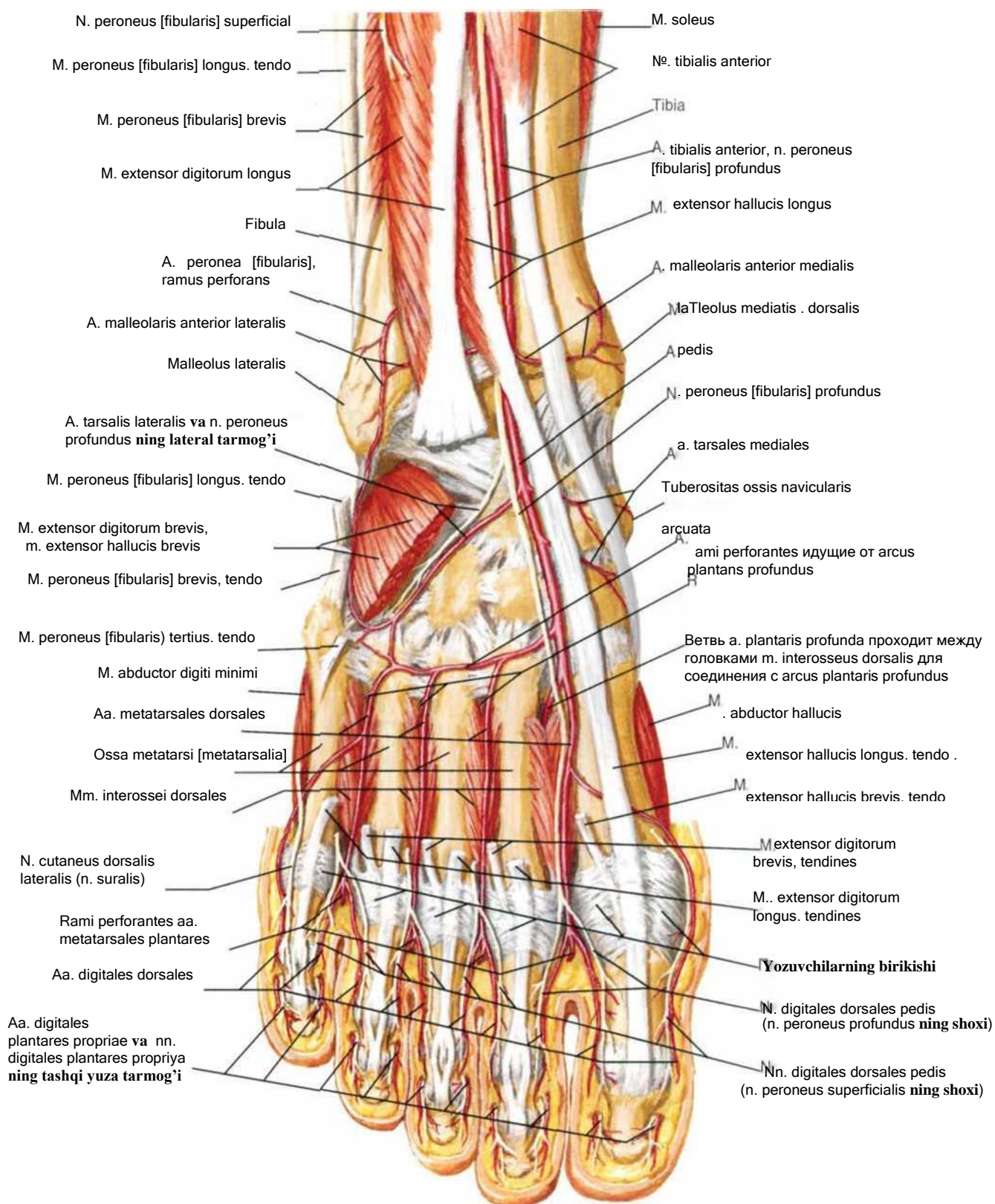
Paylarning sinovial qinlari

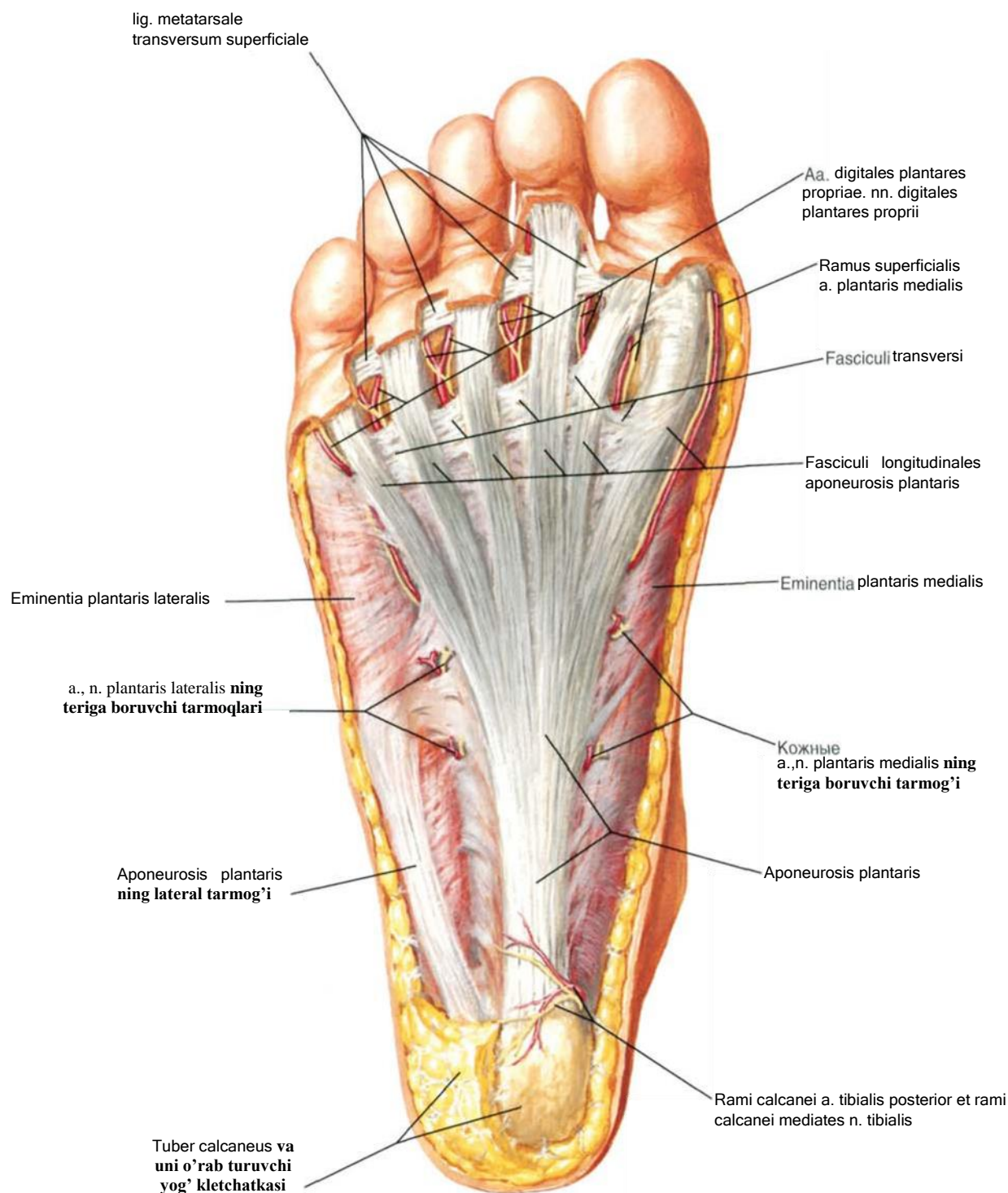


Oyoq panjasini tashqi yuzasining yuza qavat muskullari

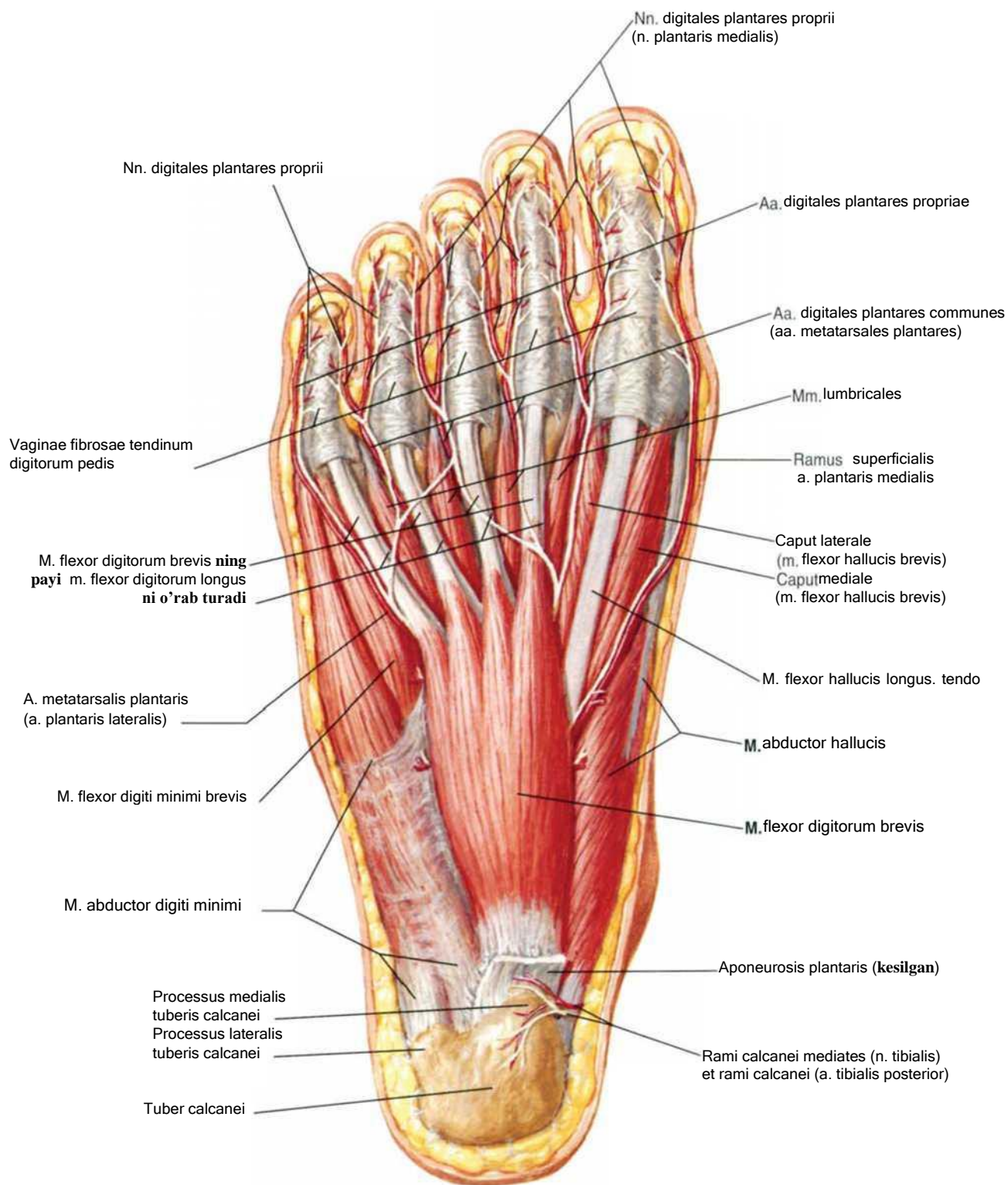


Oyoq panjasi tashqi yuzasining chuqur muskullari

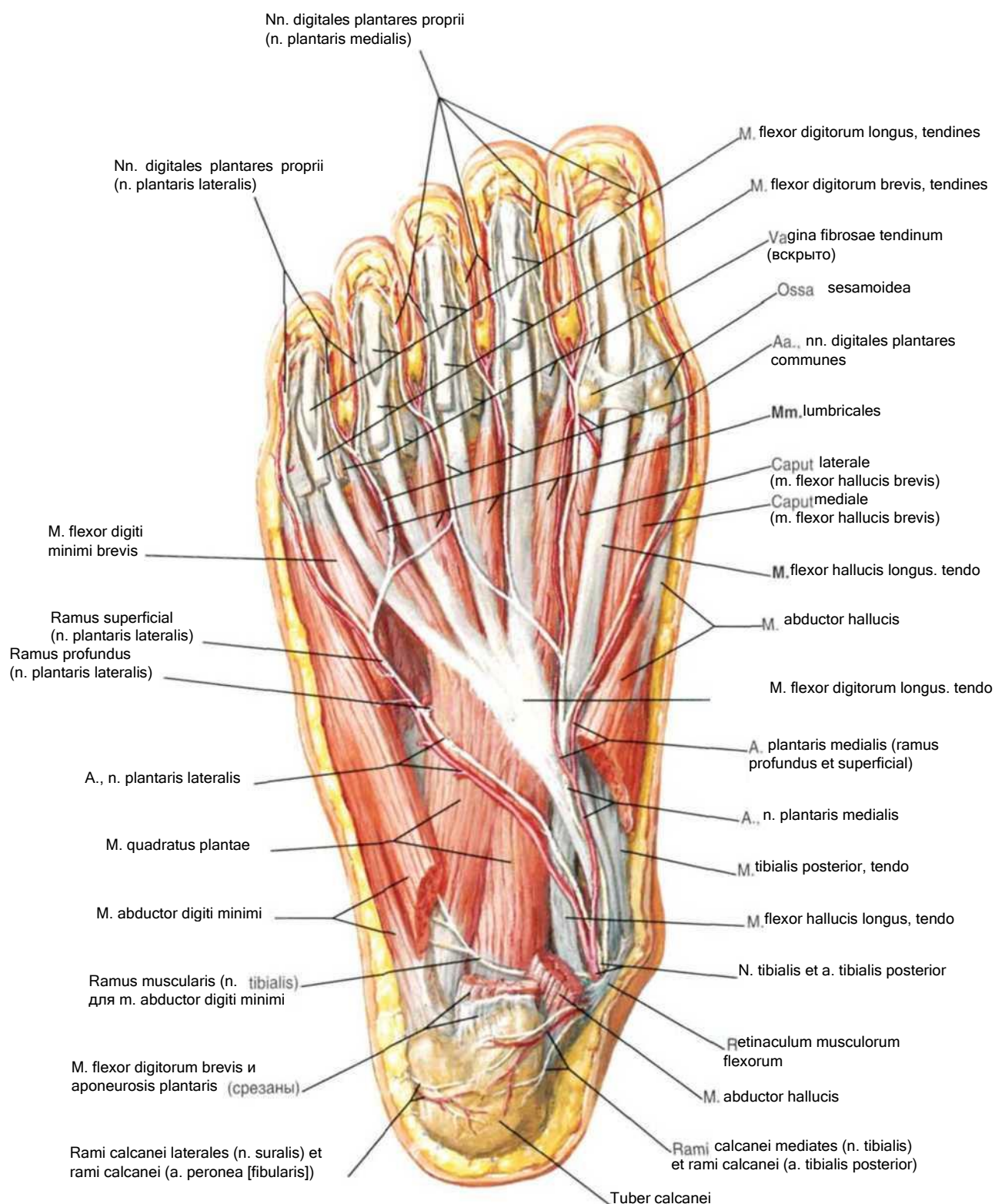




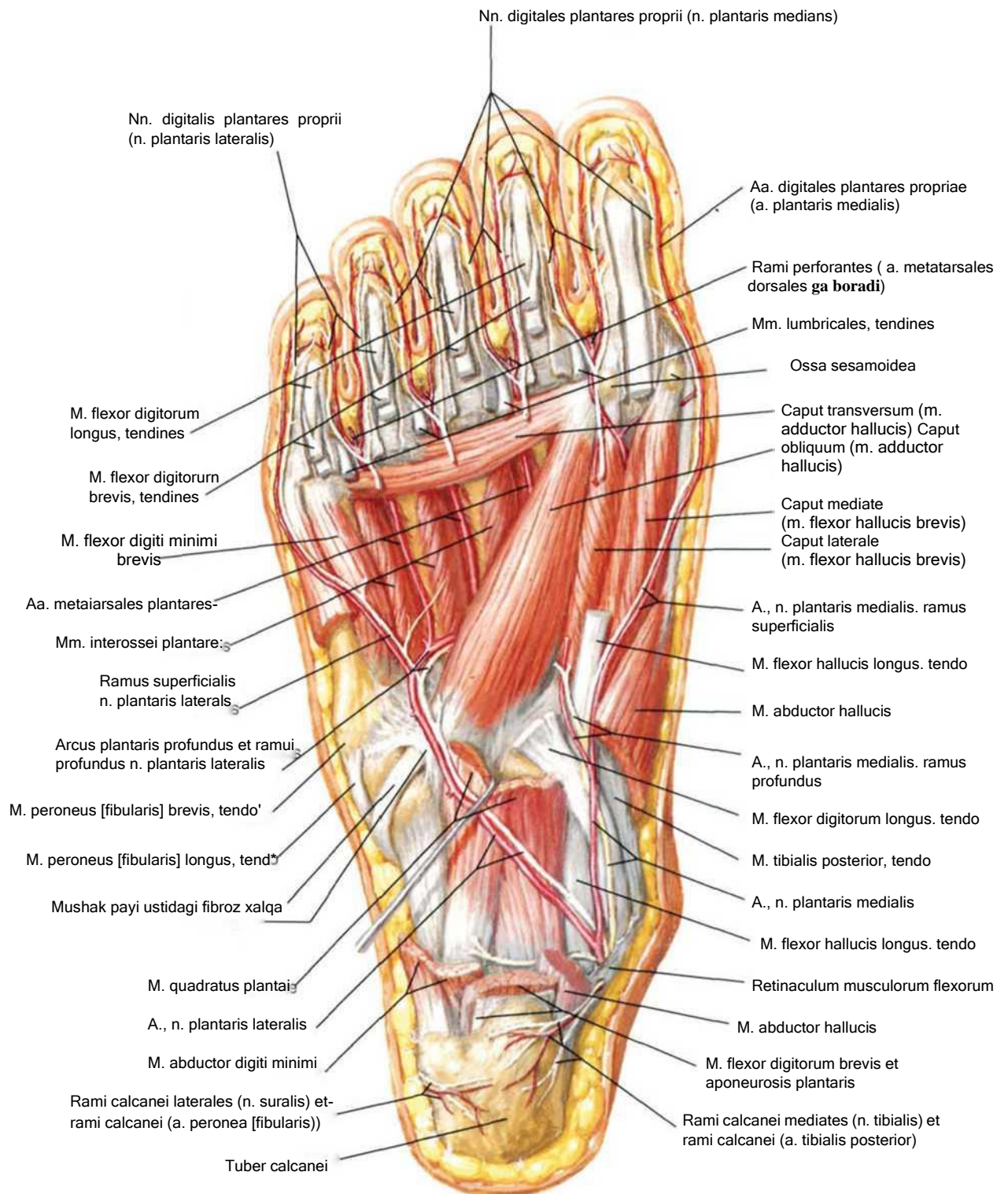
Oyoq panjasining yuza qavat muskullari



Oyoq panjasi muskullari (ikkinchi qavat)

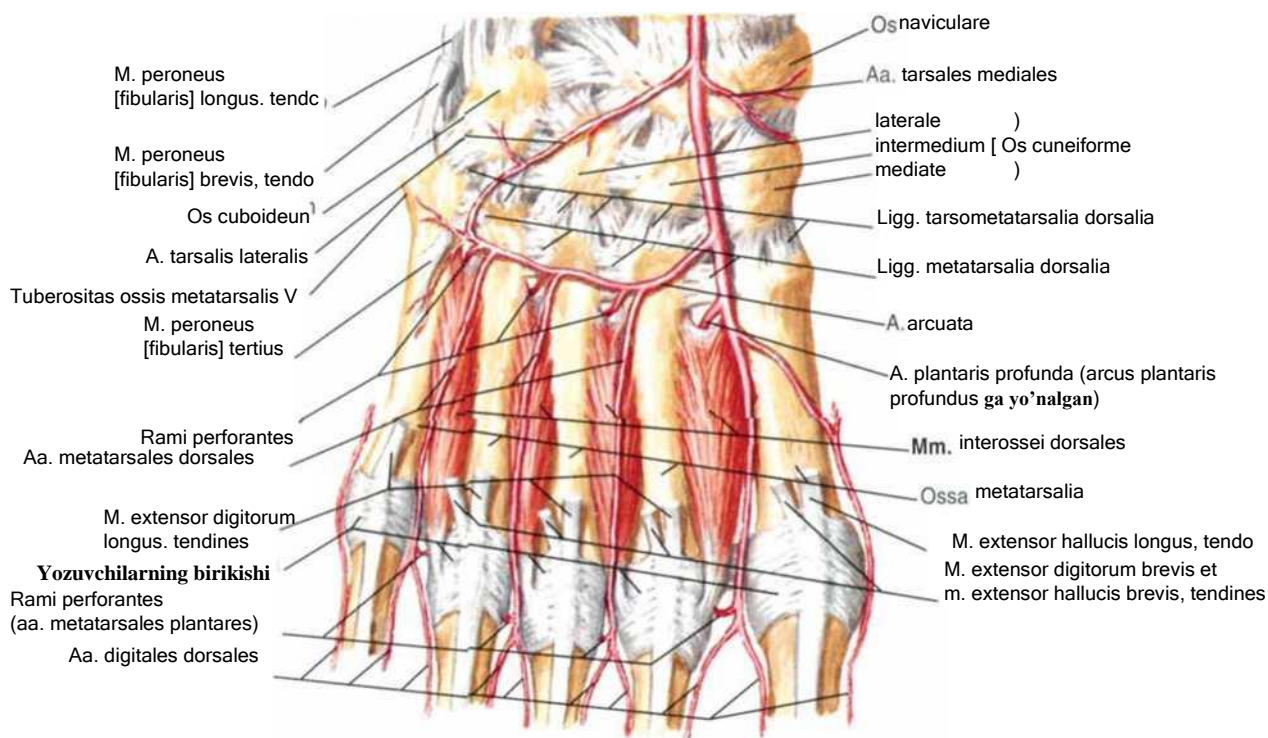


Oyoq panjasi muskullari (uchinchi qavat)

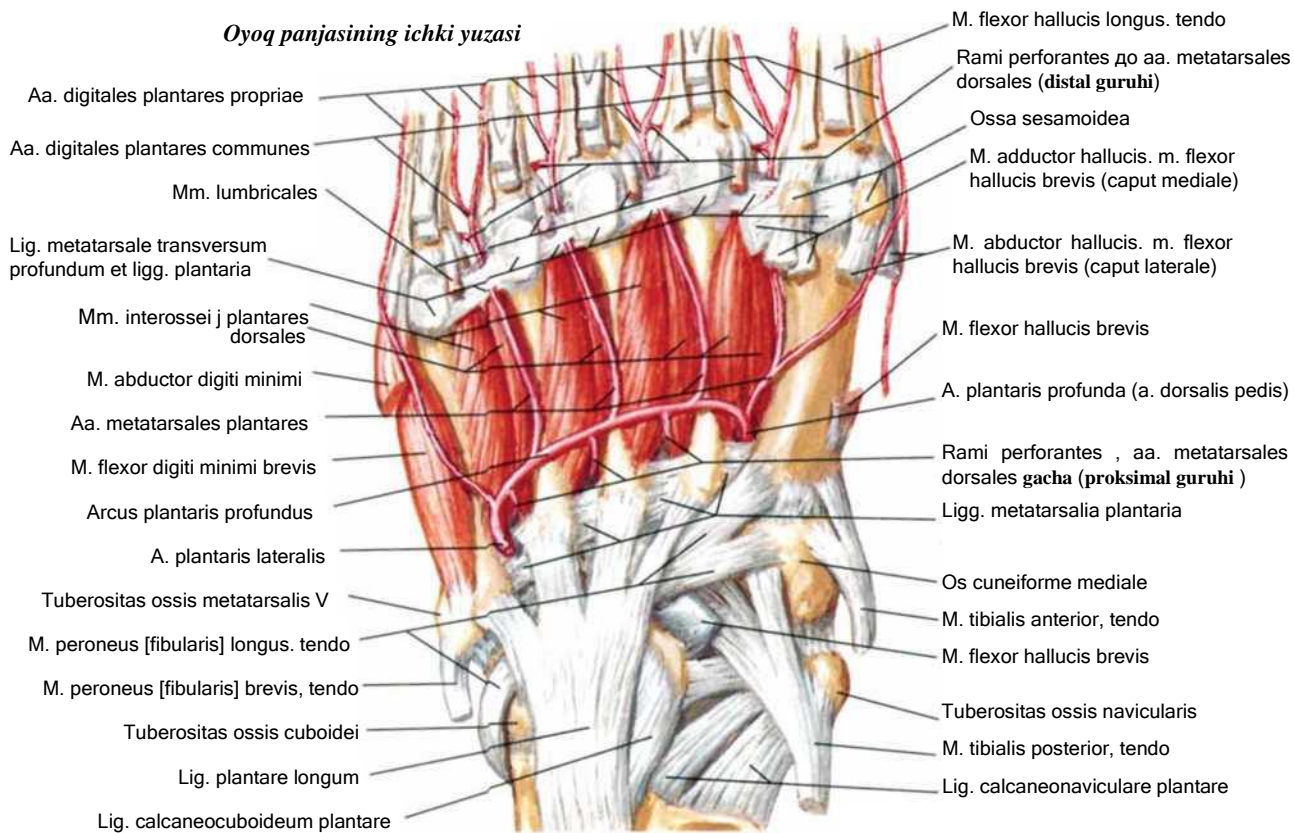


Oyoq panjasining suyaklararo muskullari va chuqur arteriyalari

Oyoq panjasining tashqi yuzasi

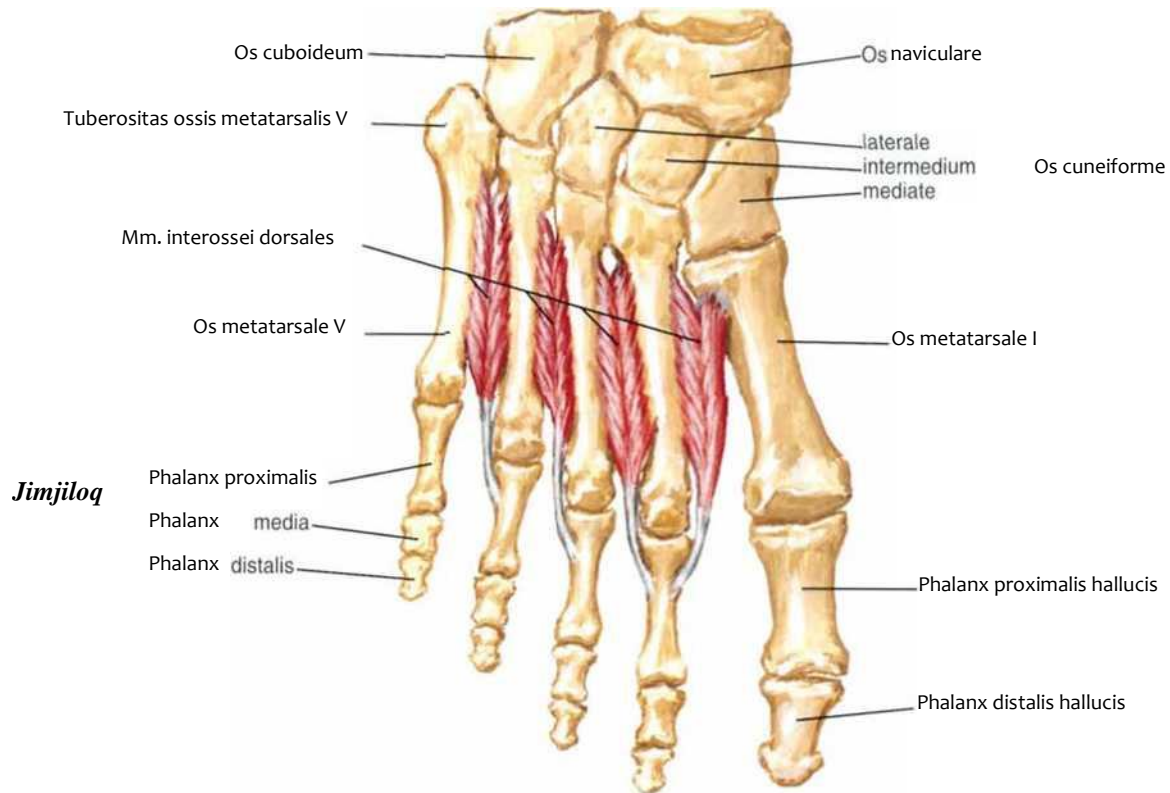


Oyoq panjasining ichki yuzasi

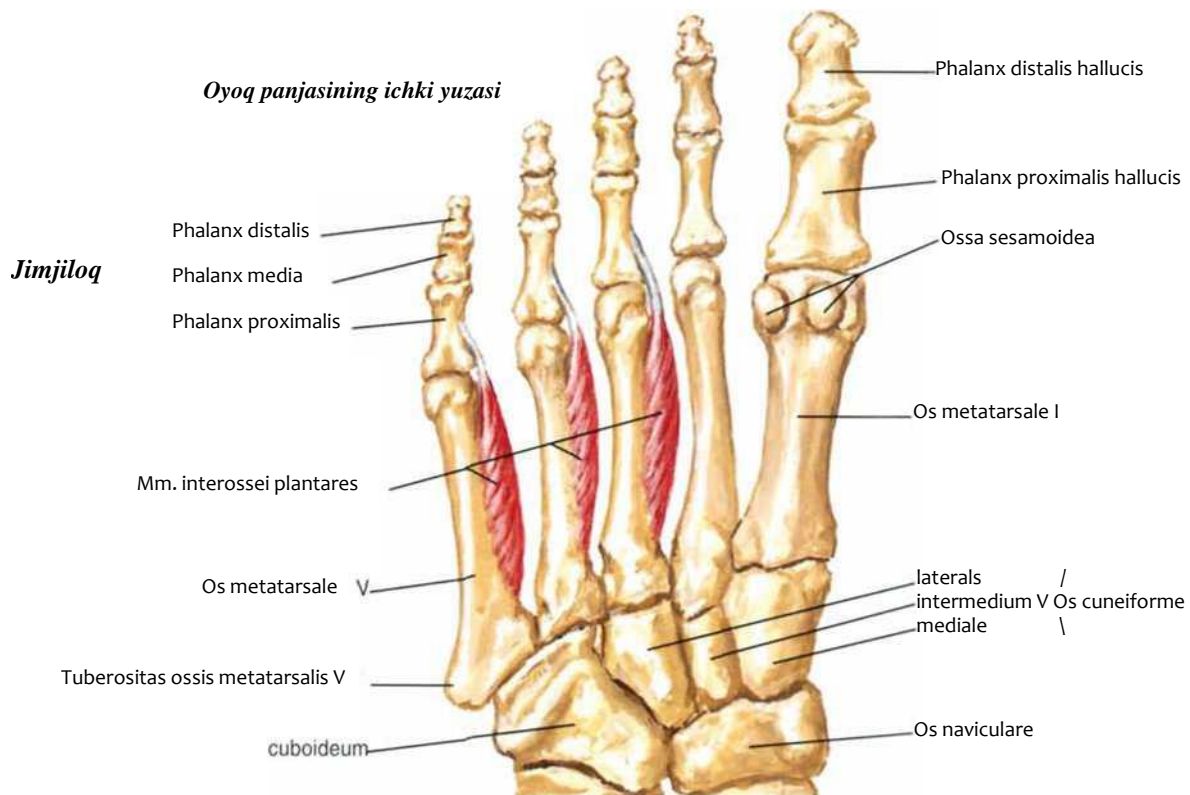


Oyoq panjasining suyaklararo muskullari

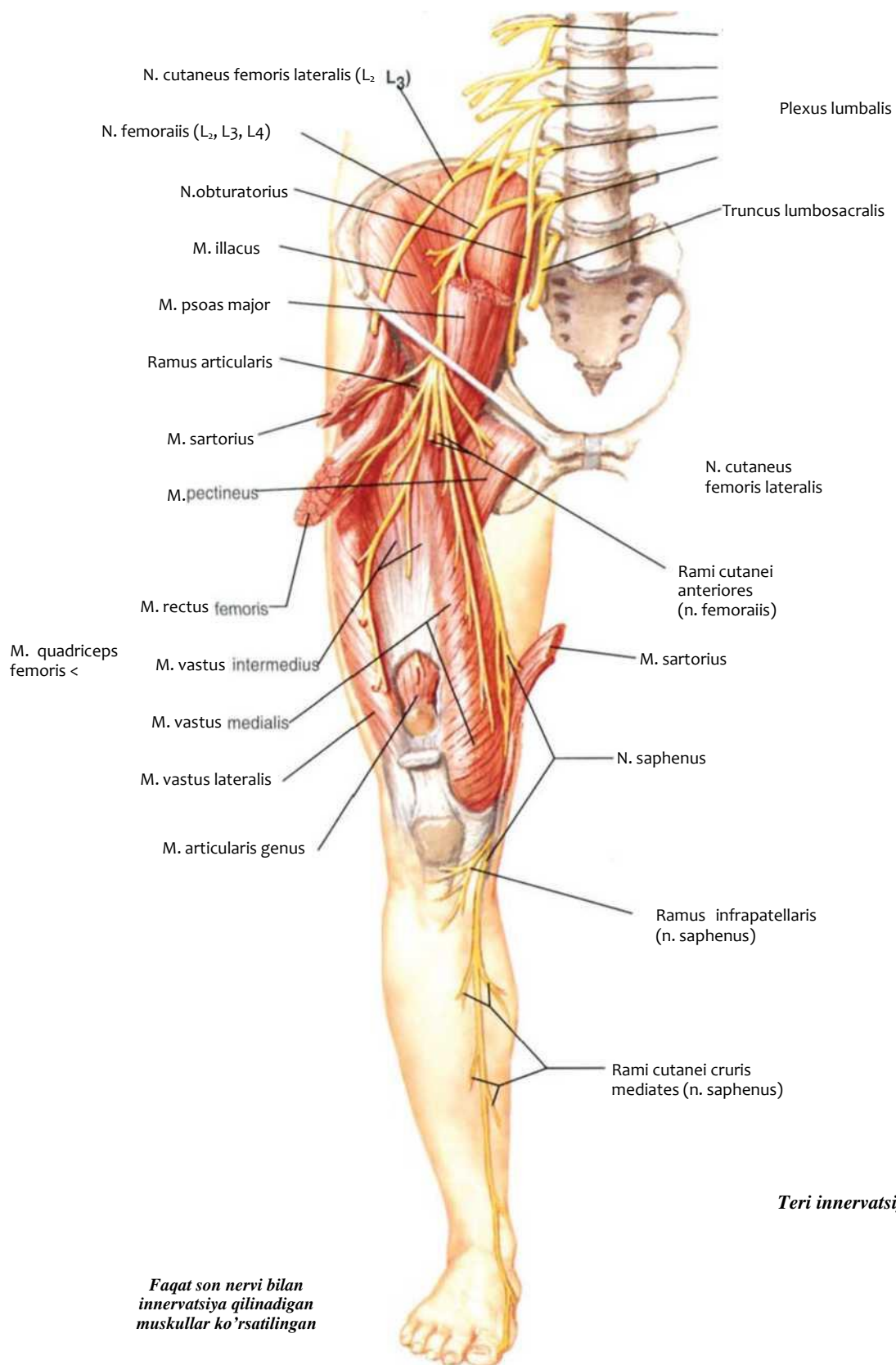
Oyoq panjasining tashqi yuzasi



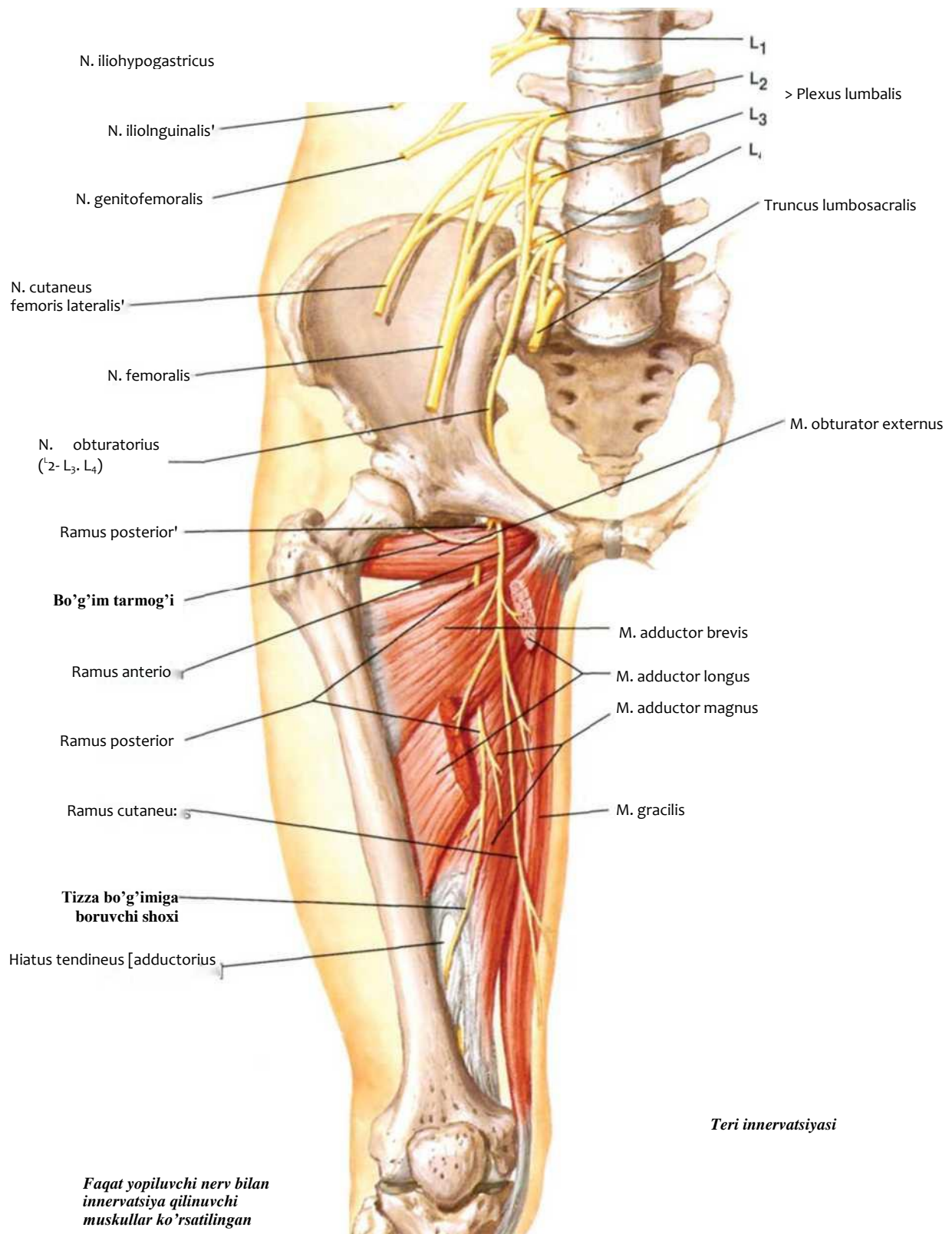
Oyoq panjasining ichki yuzasi



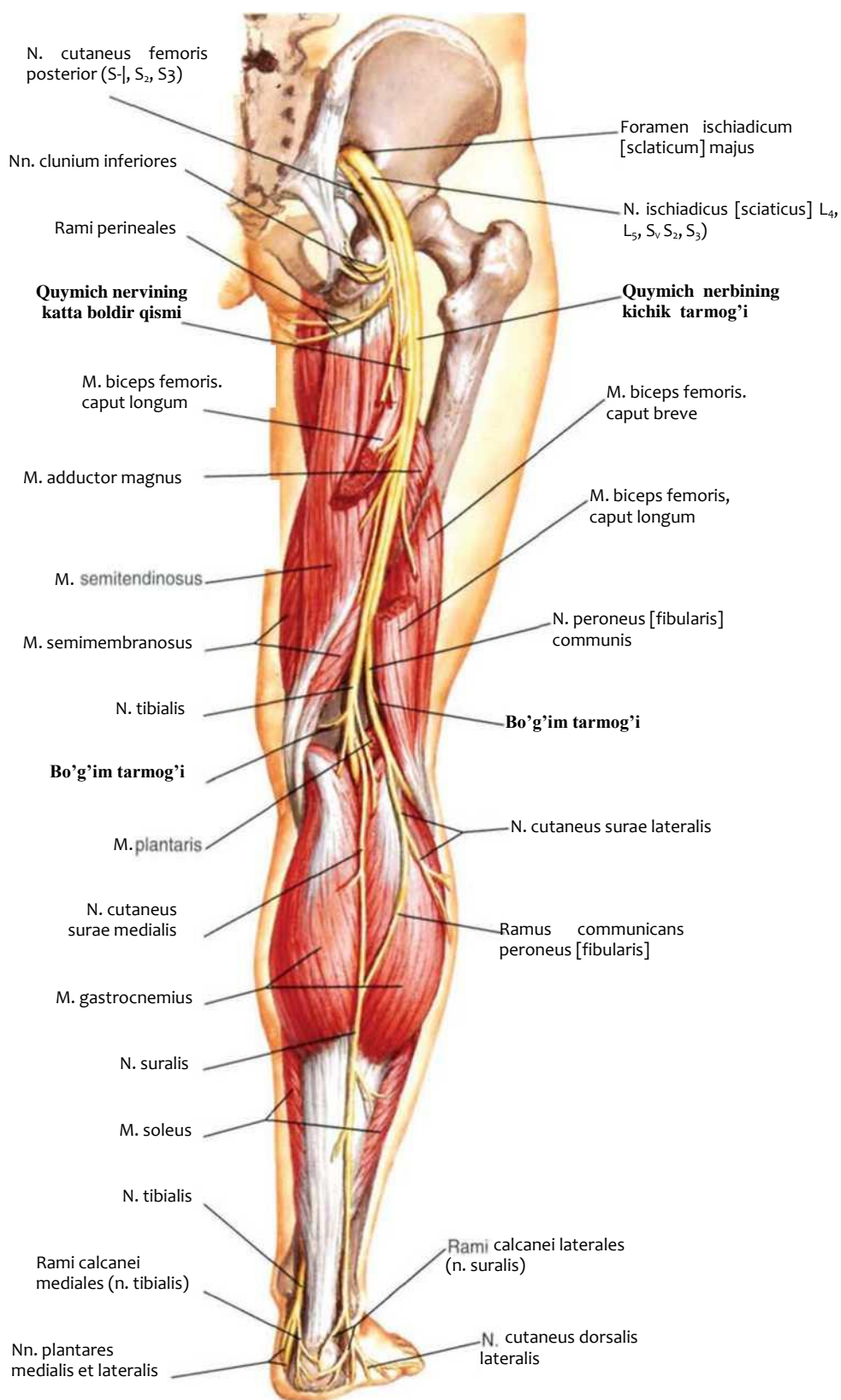
Son nervi va sonning lateral teri nervi



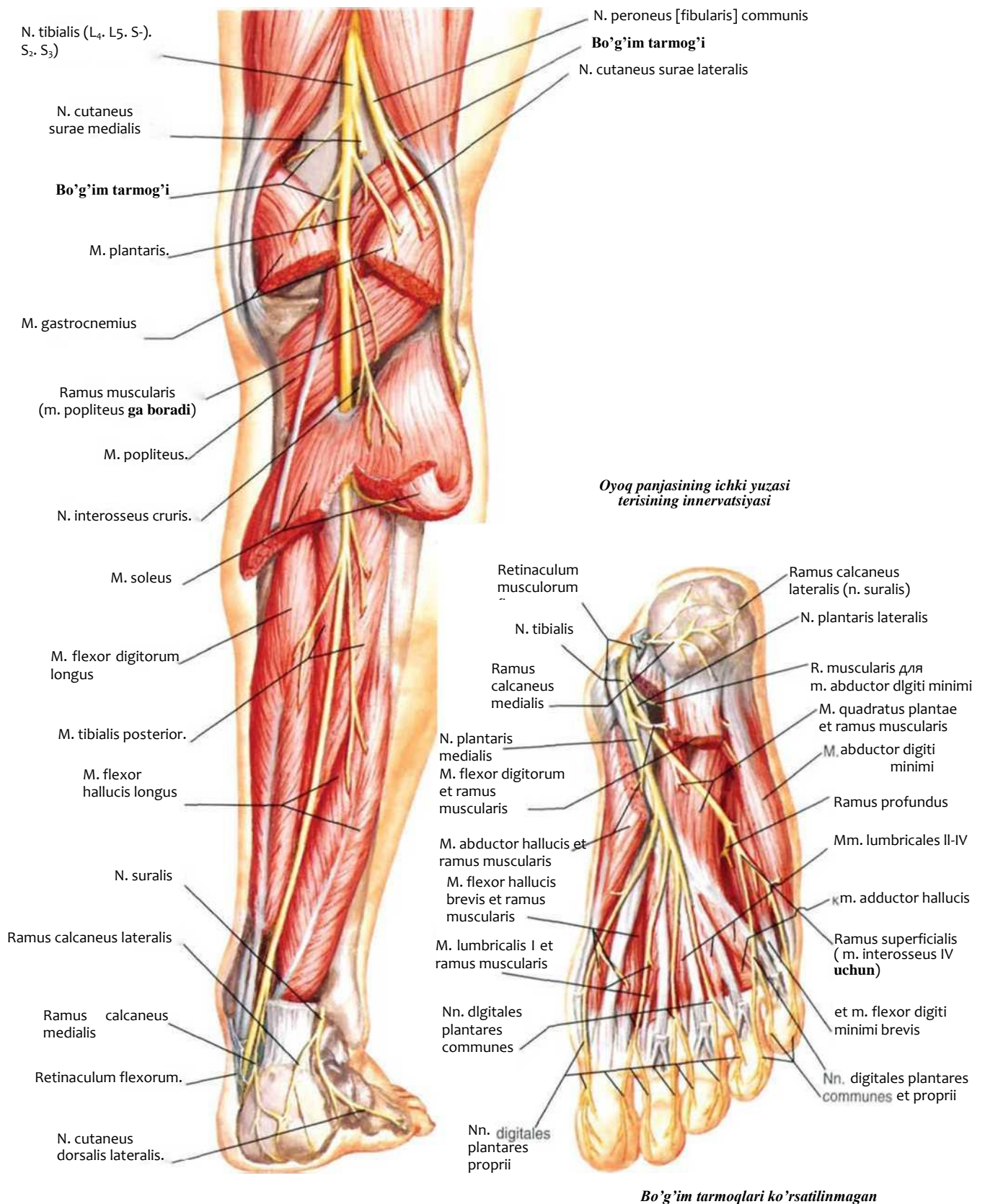
Yopiluvchi nerv (nervus obturatorius)



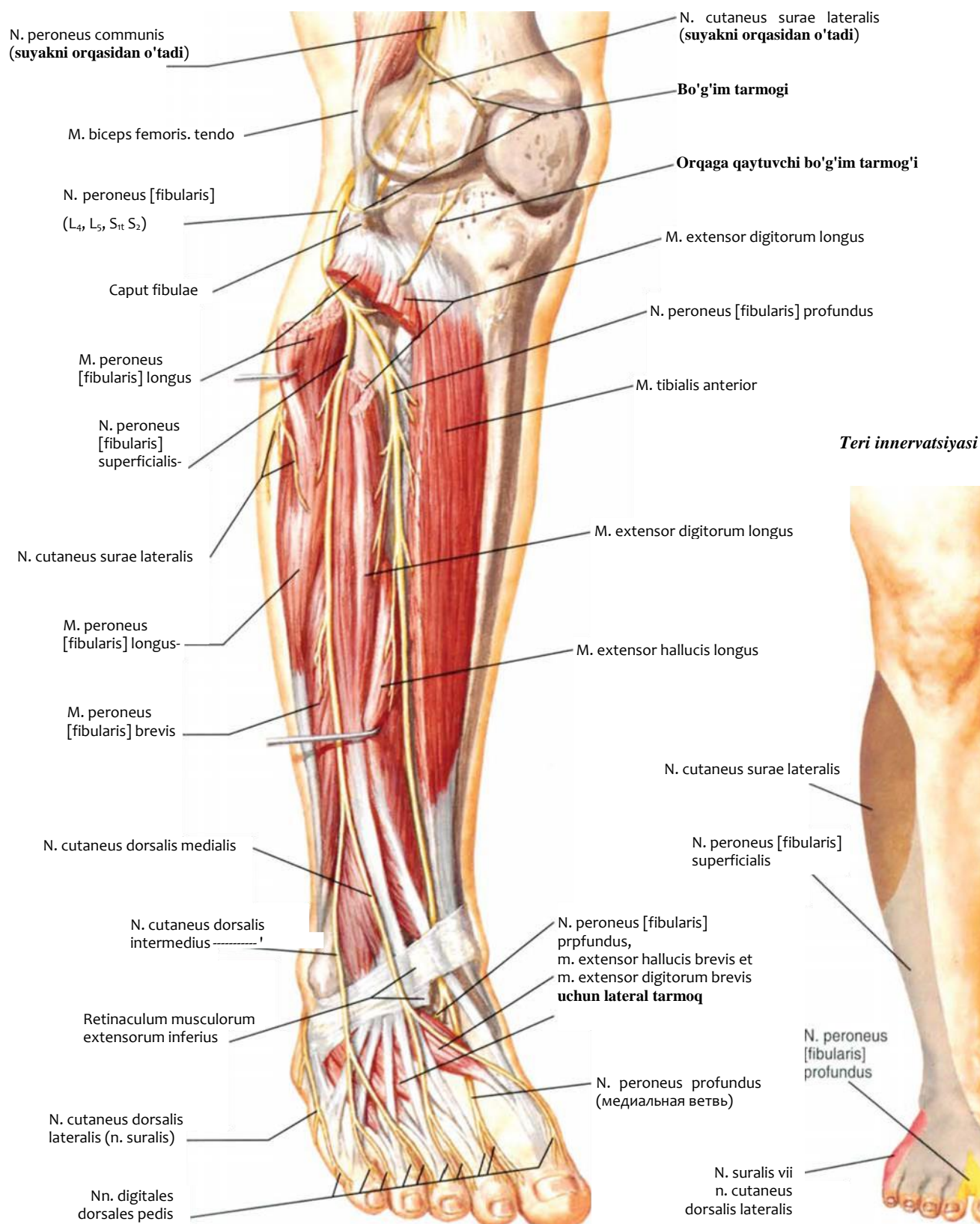
Quymich nervi va sonning orqa terisini nervi



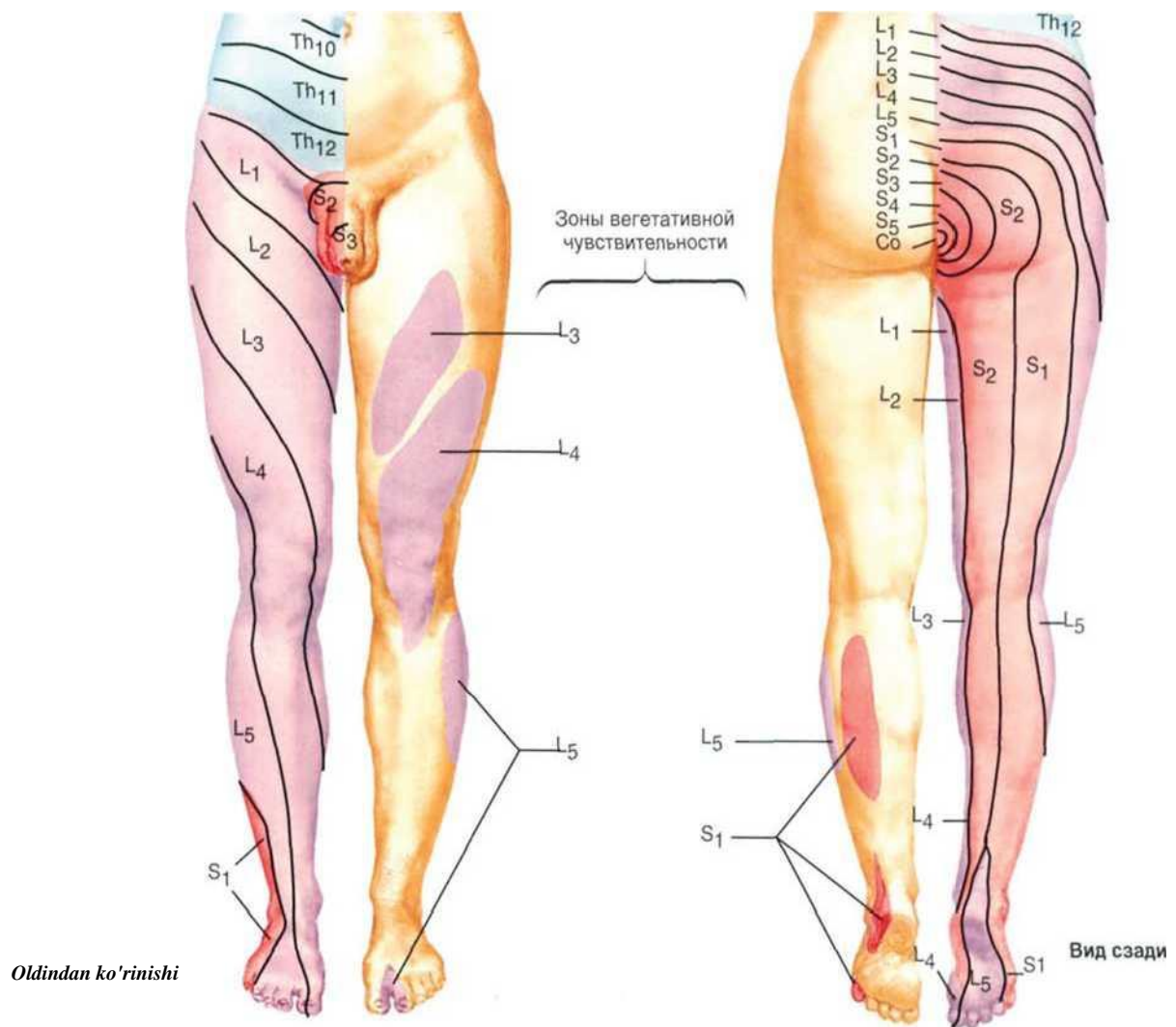
Katta boldir nervi (nervus tibialis)



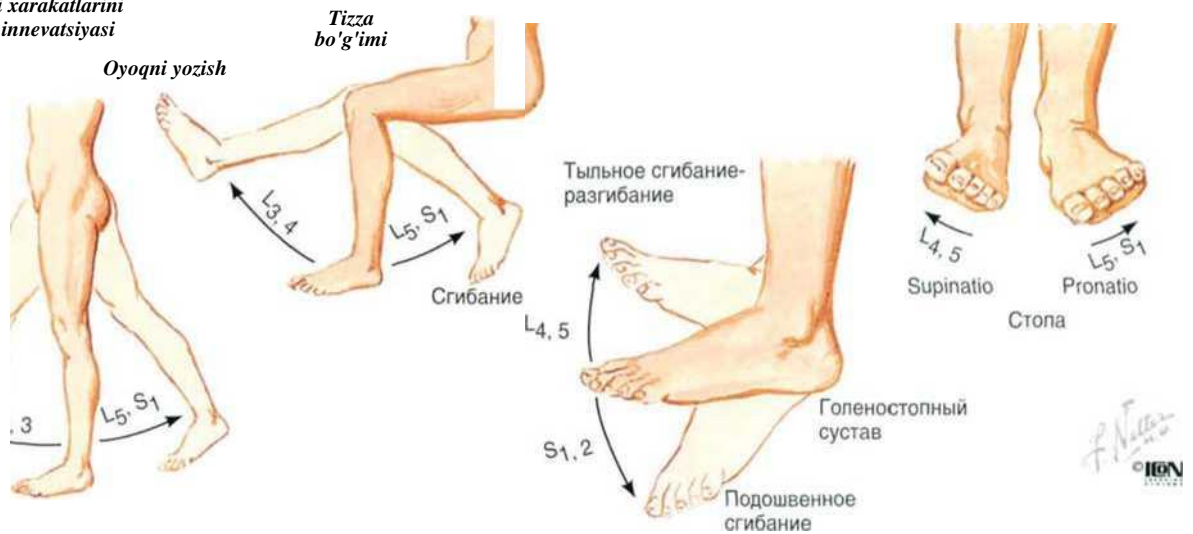Umumiy kichik boldir nervi (nervus peroneus communis)



Oyoq soxasi dermatomlari



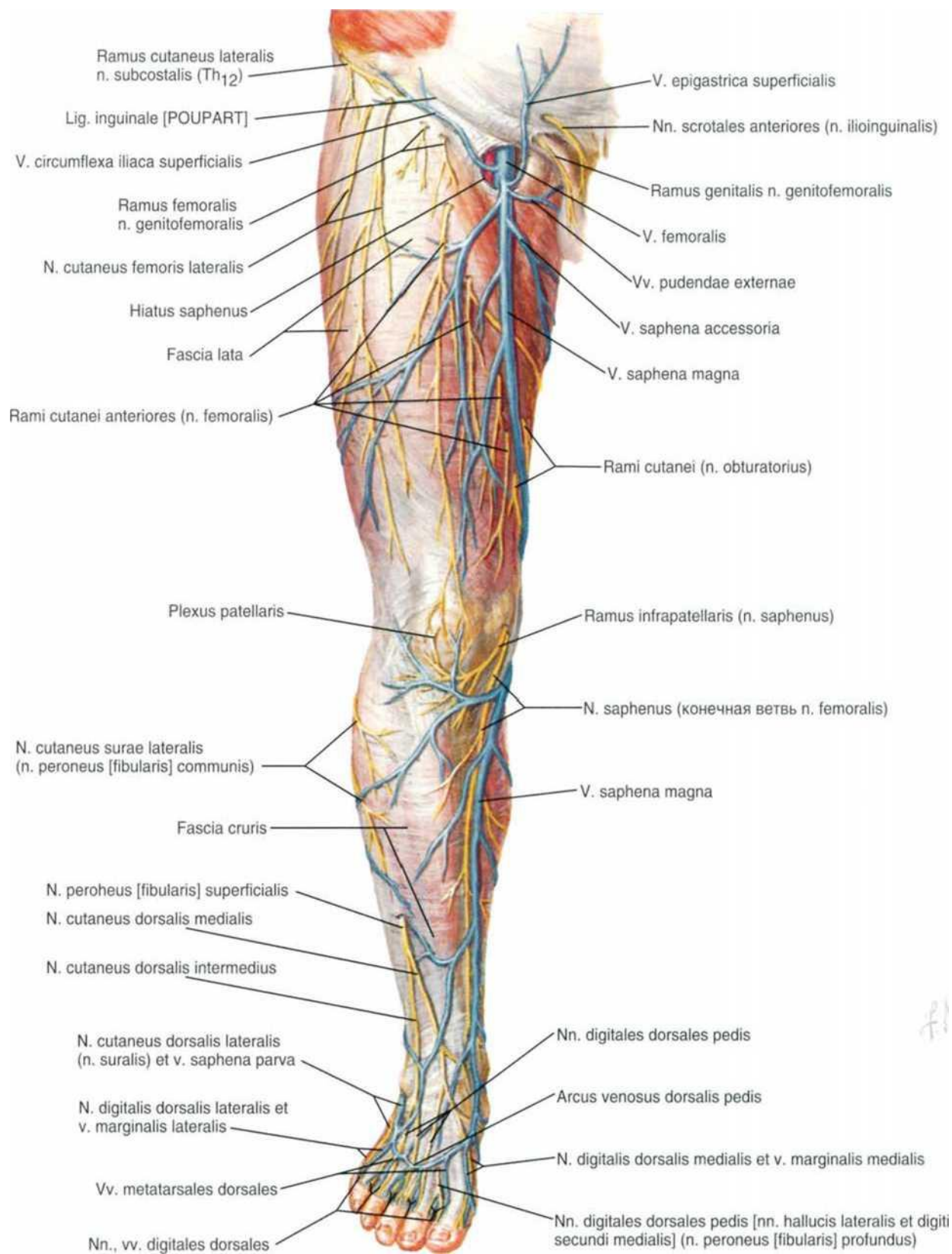
Oyoq soxasi xarakatlarini
segmentar innervatsiyasi



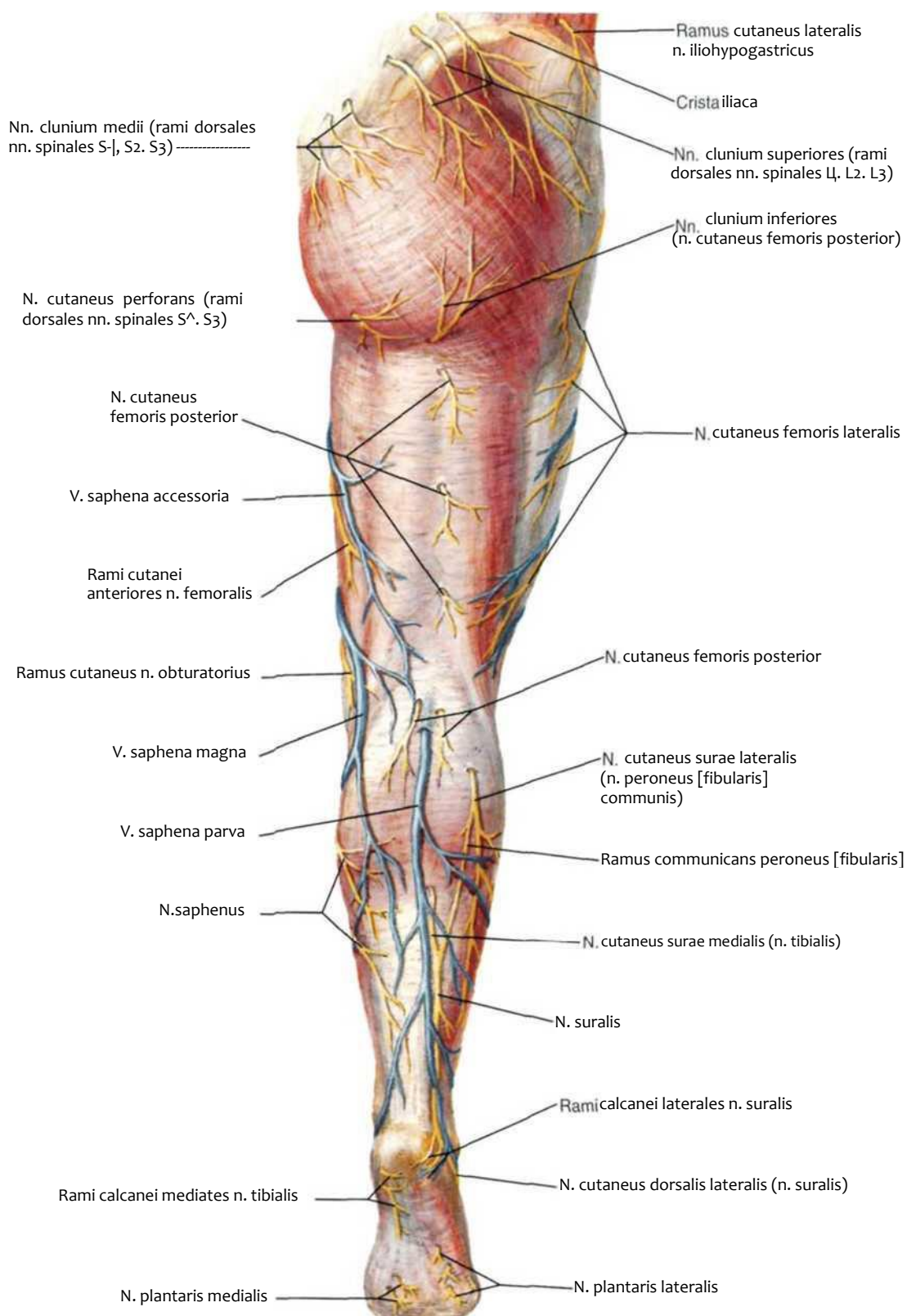
OYOQ INNERVATSIYASI

507-Rasm

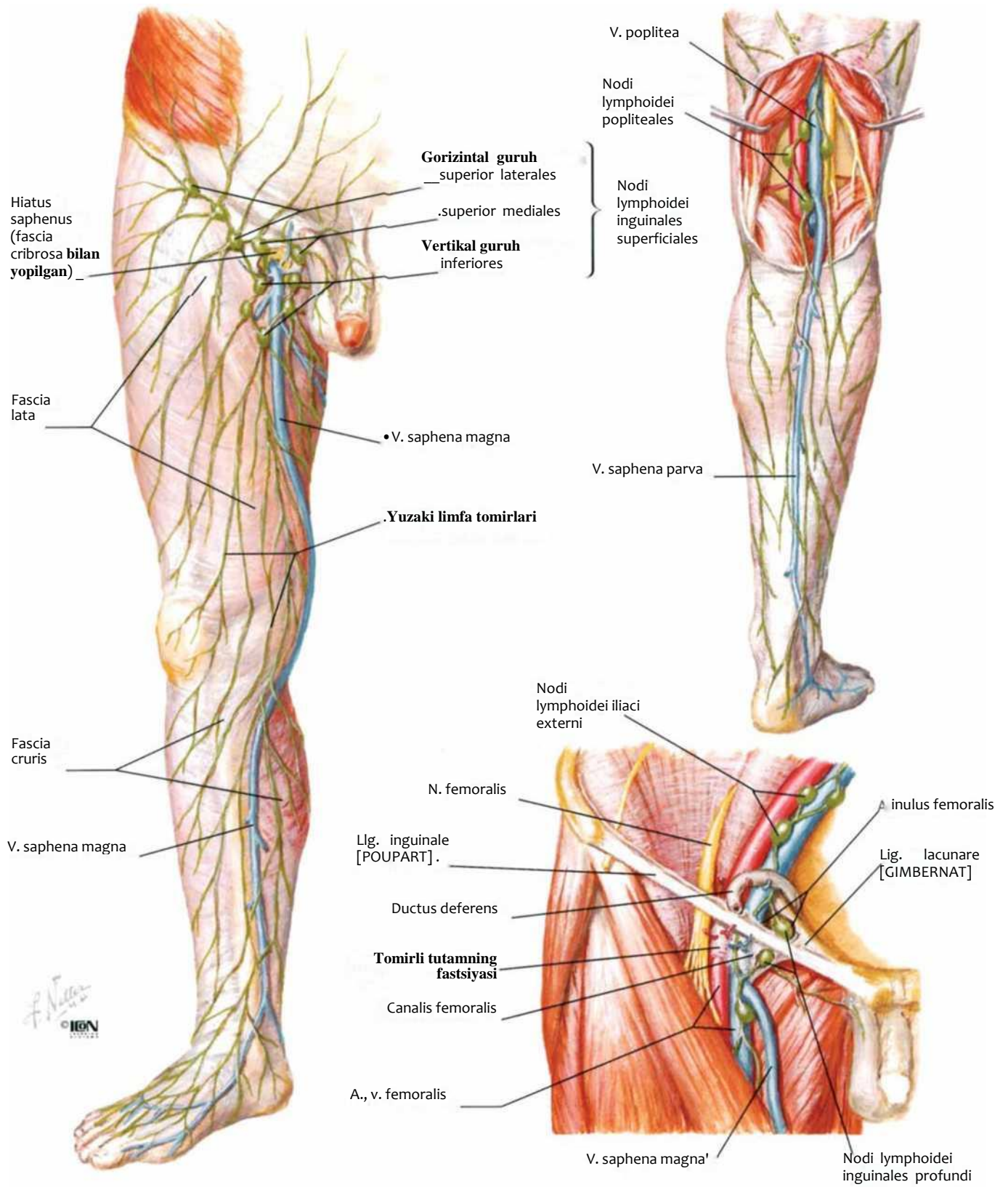
Oyoq soxasi yuza nervlari va venalari: oldindan ko'rinishi



Oyoq soxasi yuza nervlari va venalari: orqadan ko'rinishi



Oyoq soxasining limfatik tomirlari va tugunlari



VIII Bo'lim

KO'NDALANG

KESMA

TERI

511- Rasm

511. Teri kesmasi: mikroskopik ko'rinishi

KO'NDALANG KESMALARNING KO'RINISHI

512-Rasm

512. Ko'ndalang kesmalarning darajalari

KO'KRAK QAFASI

513-516 Rasm

513. Ko'krak qafasi: elka-bosh tomirlari, Th_{III}-Th_{IV} darajada ko'ndalang kesma

514. Ko'krak qafasi: aorta ravog'i, Th_{IV}-Th_V darajada ko'ndalang kesma

515. Ko'krak qafasi: o'pka stvoli, Th_V-Th_{VI} darajada ko'ndalang kesma

516. Ko'krak qafasi: yurakning to'rtta kamerasi, Th_{VI} darajasida ko'ndalang kesma

QORIN BO'SHLIG'I

517-522 Rasm

517. Qorin: qizilo'ngachni oshqozonga o'tish joyi, Th_X darajada ko'ndalang kesma

518. Qorin: oshqozon osti bezi tanasi va oshqozonning pilorik qismi, Th_{XII} darajada ko'ndalang kesma

519. Qorin: qorin o'zani va darvoza venasi, Th_{XII}-L_I darajada kesilgan

520. Qorin: buyrak darvozasi, L_I-II darajada kesmasi

521. Qorin: ileotsekal klapan, L_V darajada kesilgan

522. Qivot: dumg'aza do'ngligi, S_I darajada kesilgan

ERKAKLAR TOSI

523-Rasm

523. Erkaklar tosi: siydik qopi va prostata bezi, dum umurtqasi darajasida kesmasi

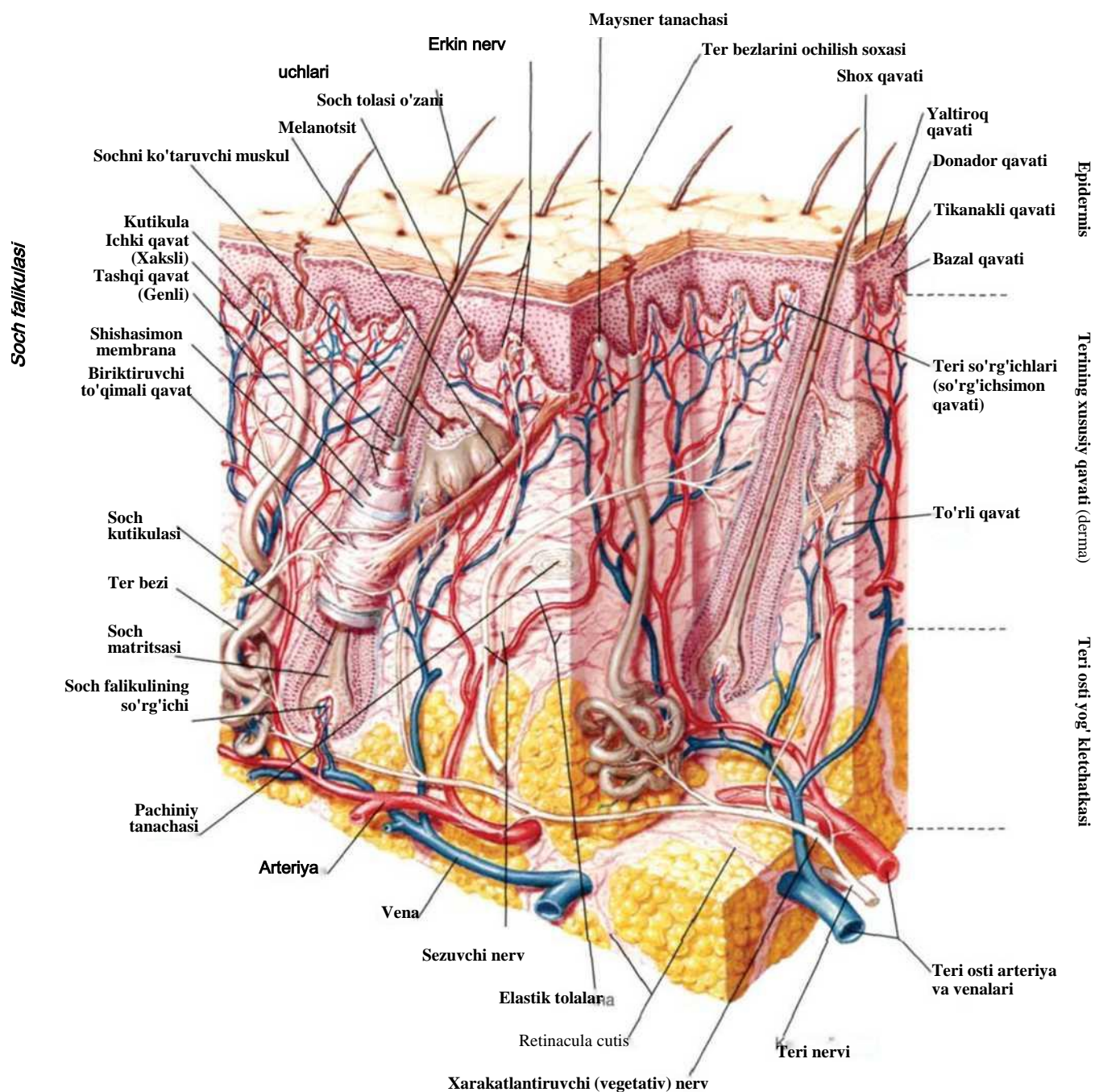
KO'KRAK QAFASI

524-525 Rasm

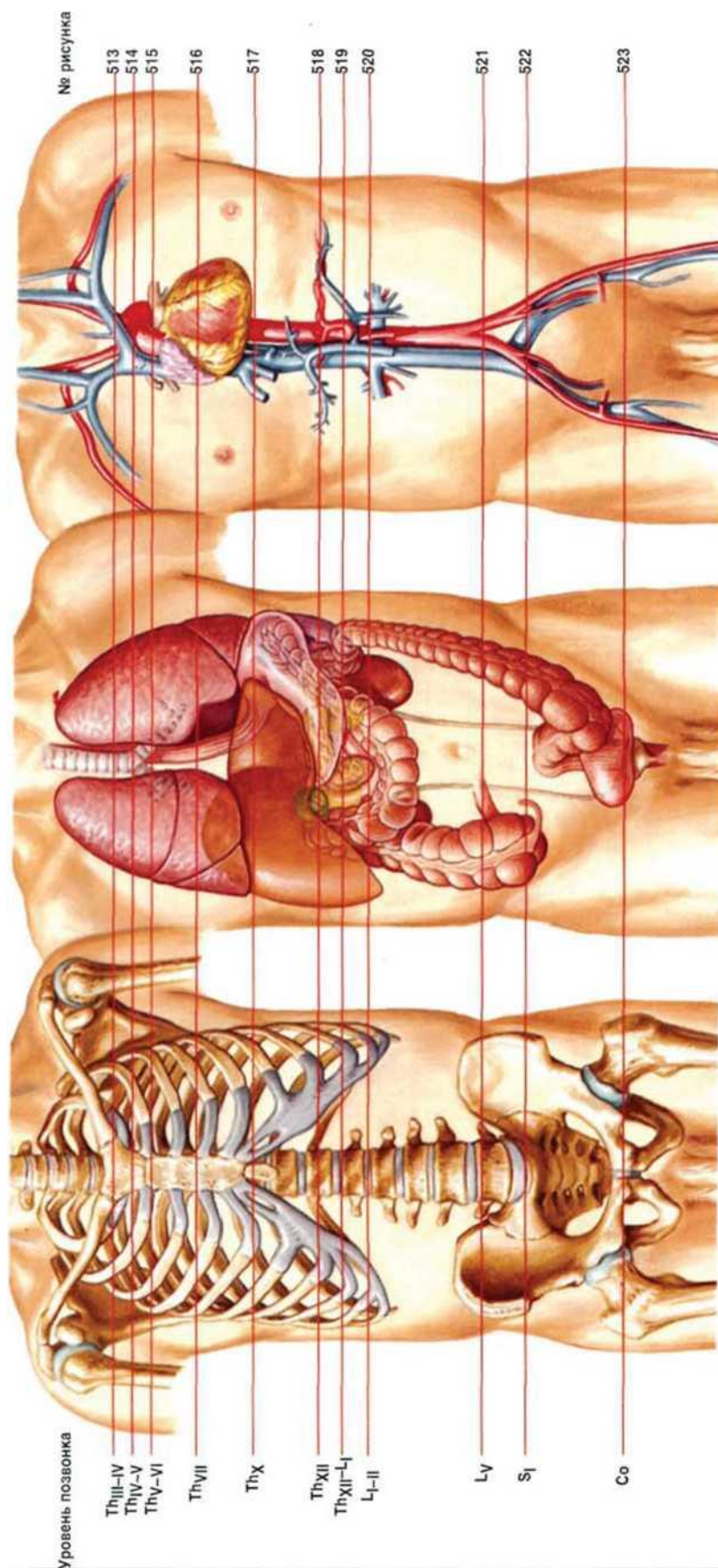
524. Ko'krak qafasi: aortani ko'tariluvchi qismi

525. Ko'krak qafasi: traxeyaning bifurkatsiyasi, chap bo'lmacha

Terining kesmasi: mikroskopik ko'rinishi

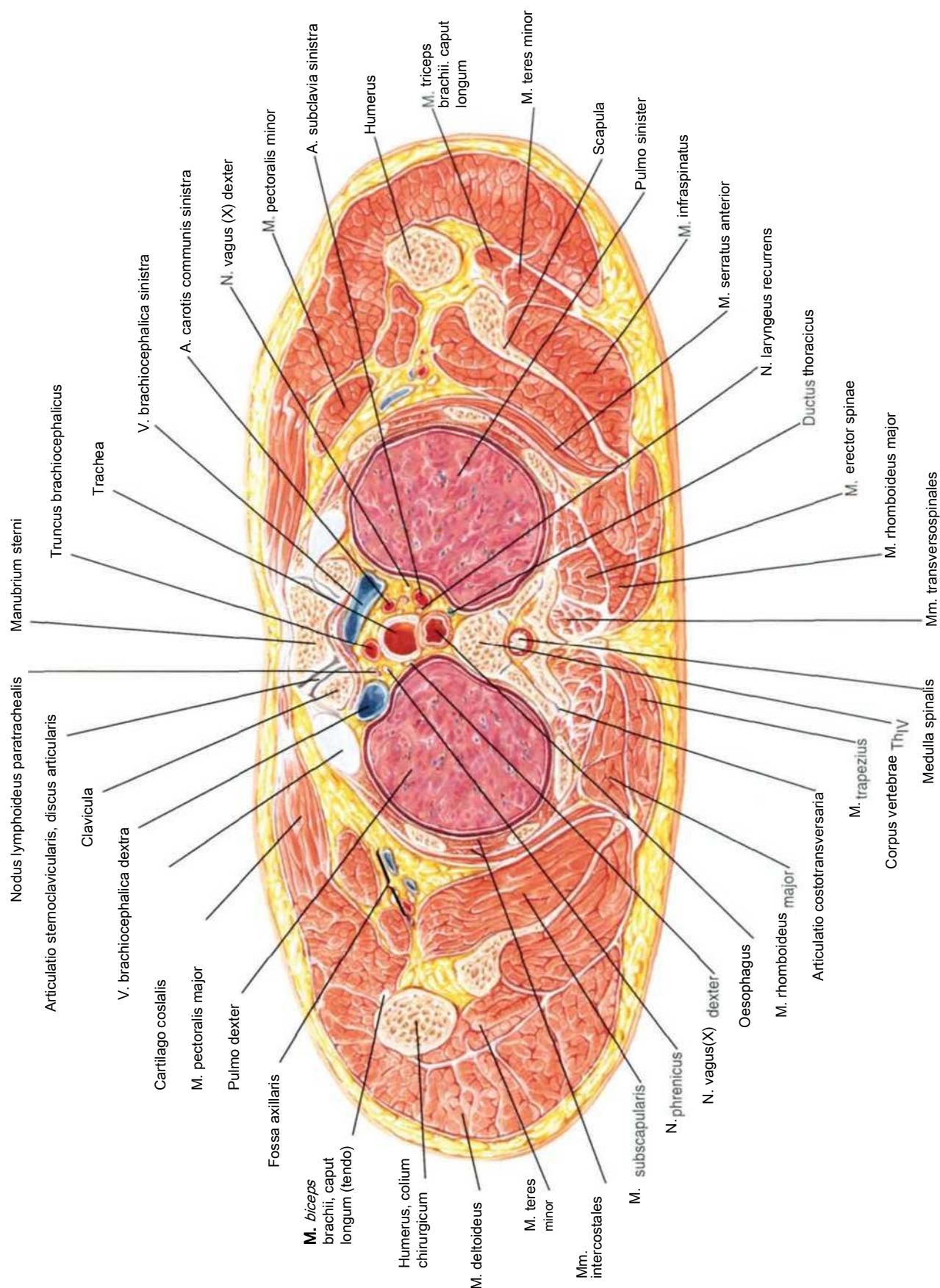


Ko'ndalang kesma darajalari



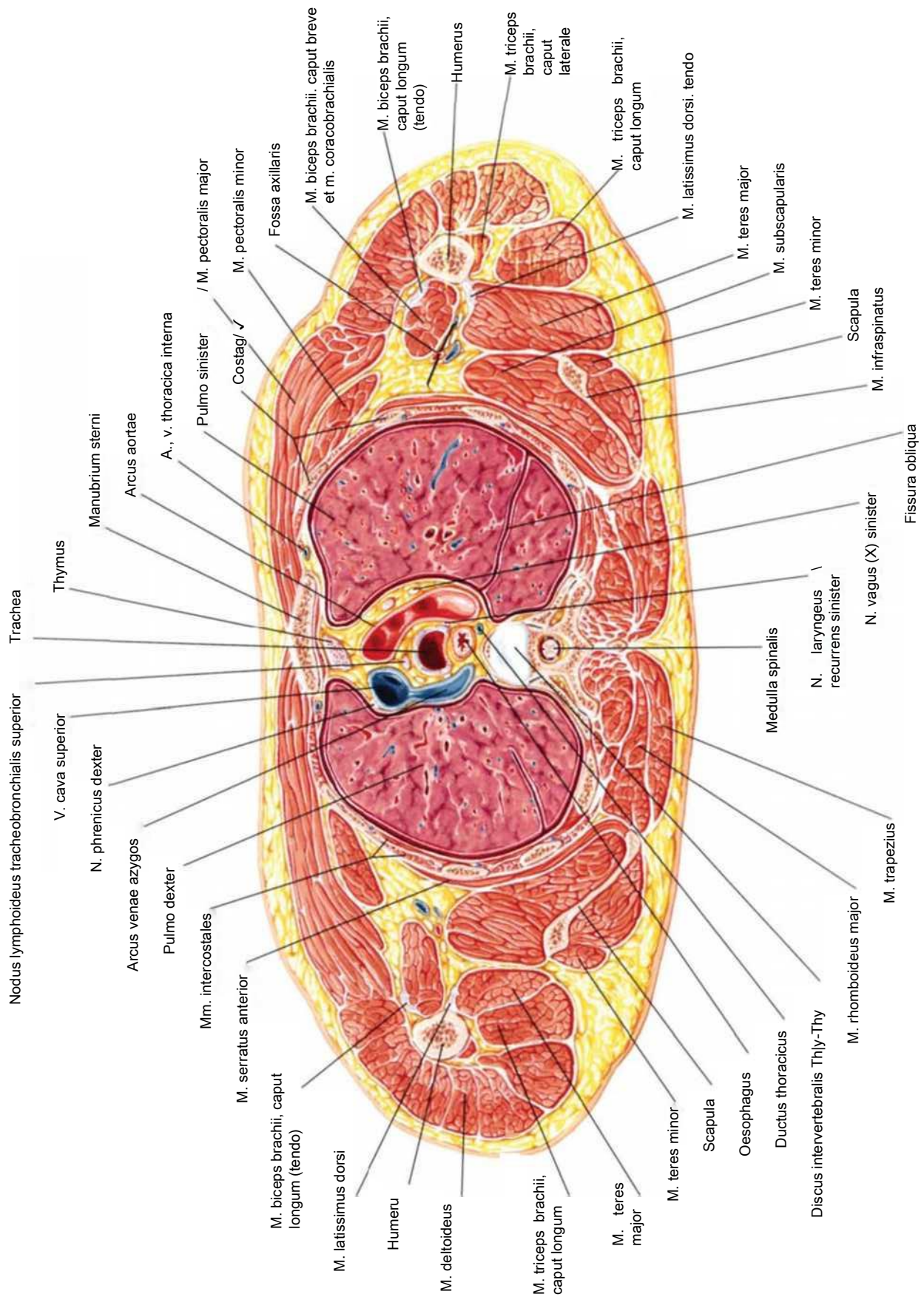
Ko'krak qafasi: elka-bosh o'zani Th_{II}–Th_{IV} darajasida kesmasi

To'sh- o'mrov bo'g'imi va Th IV darajasida ko'ndalang kesma



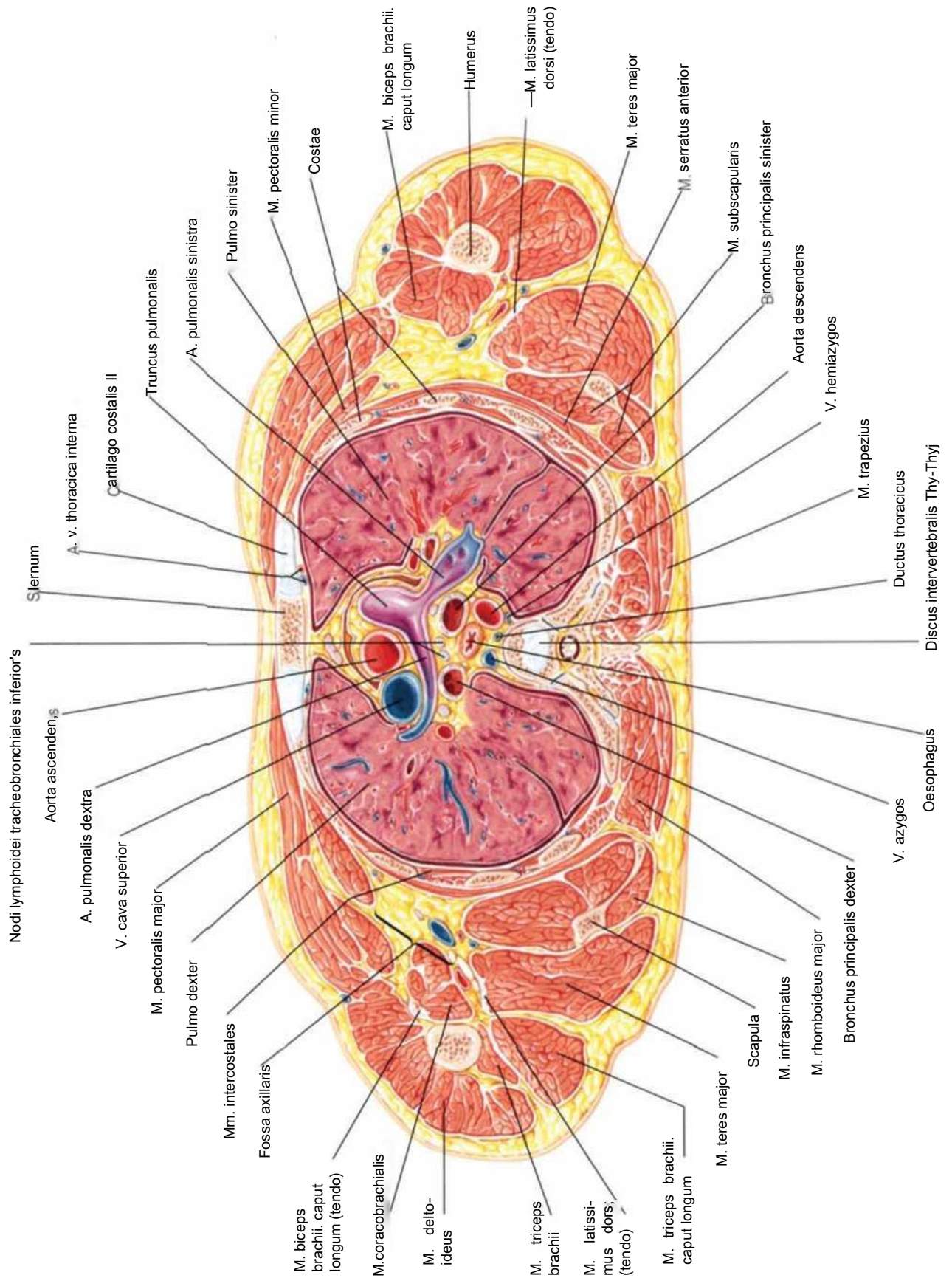
Ko'krak qafasi: aorta ravogi, Th_{IV}-Th_V darajasida kesmasi

Ko'ndalang kesma: Th_{IV}- Th_V umurtqalararo disk



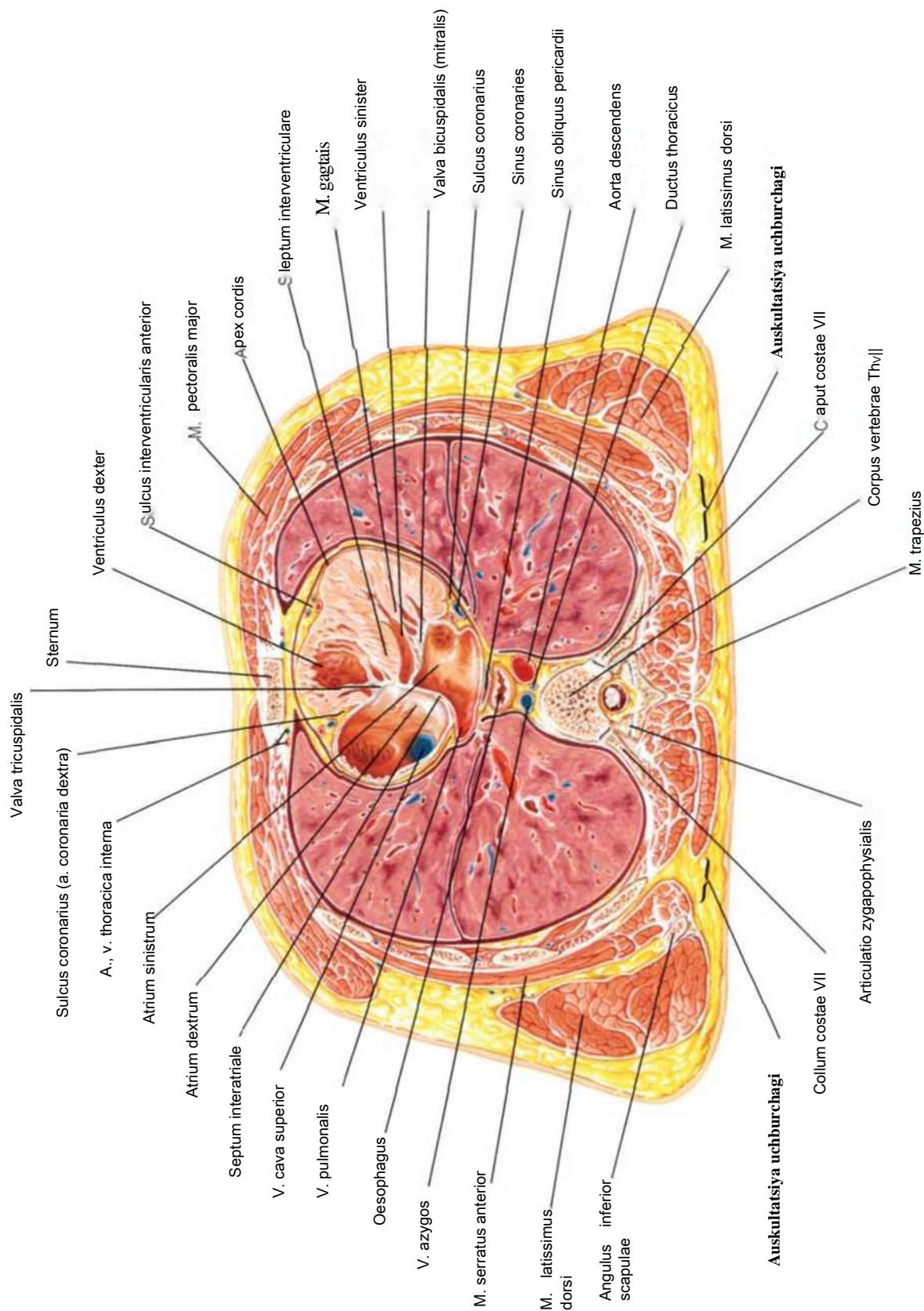
Ko'krak qafasi: o'pka stvoli, Thv-Th_M darajada kesmasi

Ko'ndalang kesmasi: Thv-Th_{VI} umurtqalararo disk va to'sh suyagining burchagi

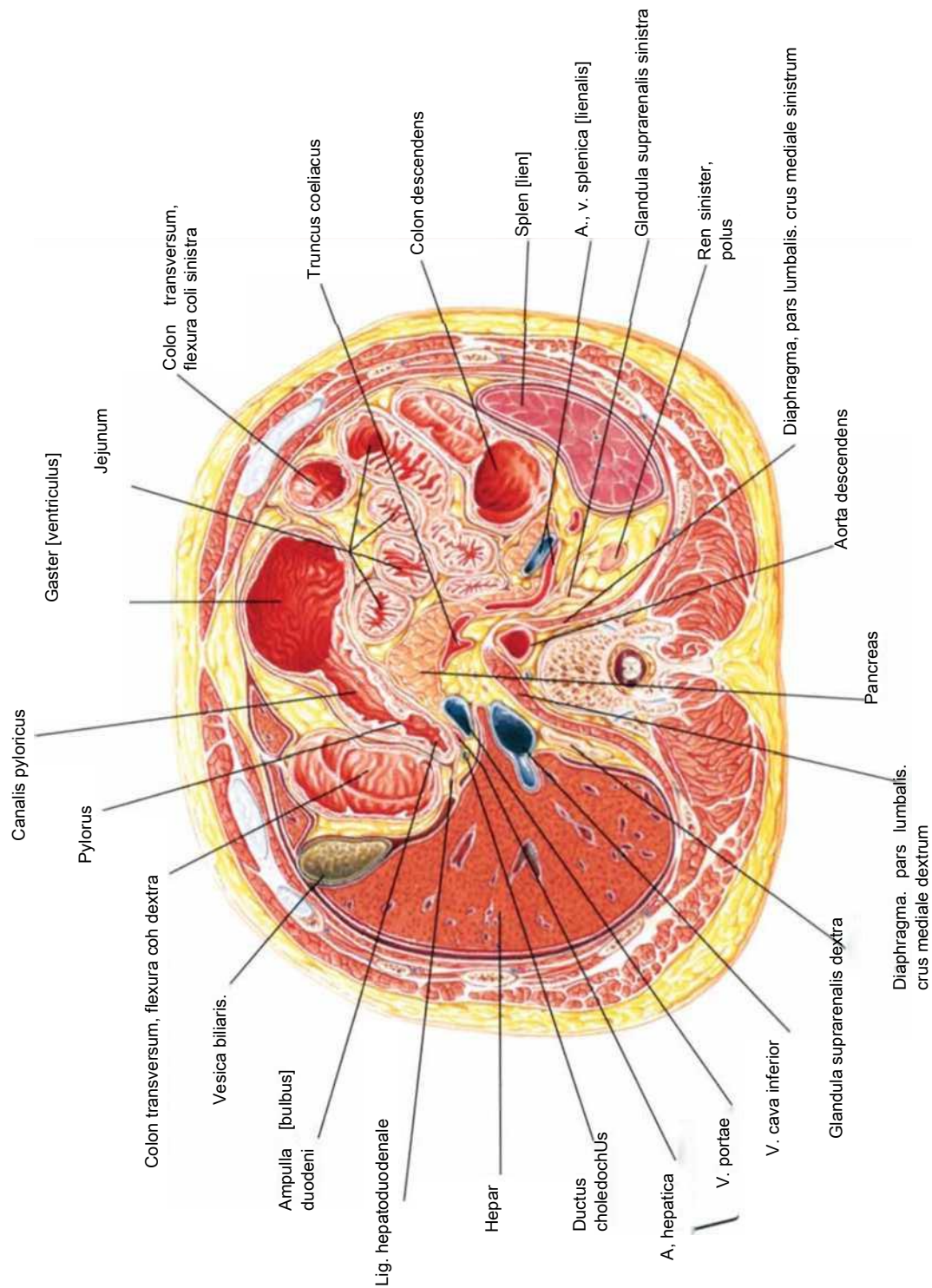


Ko'krak qafasi: yurqkning to'rt kamerasi, Th_{VI} darajada kesmasi

Ko'ndalang kesma: ThVI umurtqalararo disk

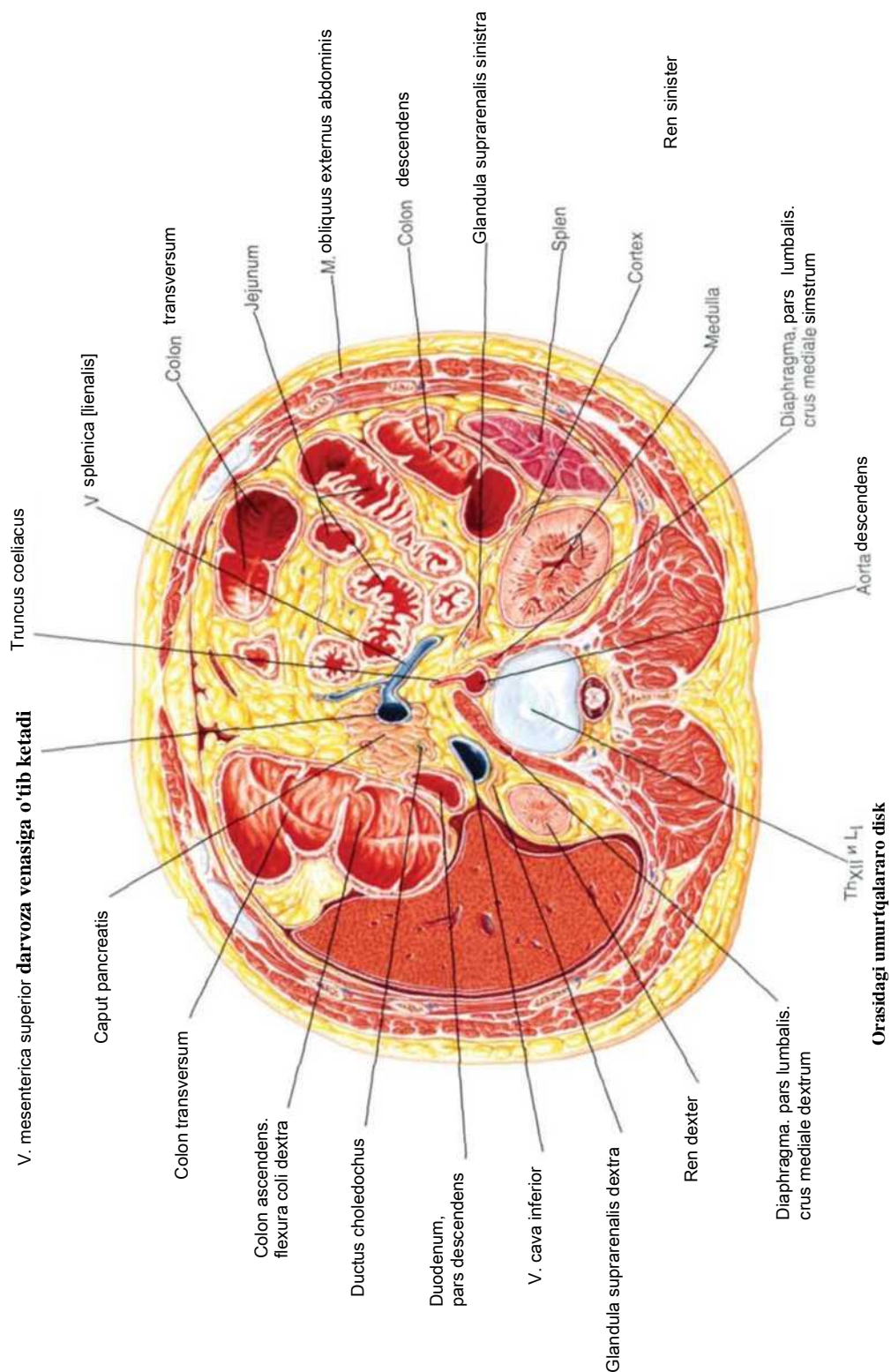


Ko'ndalang kesma: Th_{xII} va xanjarsimon o'simta



Qorin: qorin o'zani va darvoza venasi, Th_{xII}-L_I darajada kesmasi

Ko'ndalang kesma: Th_{xII}-L_I

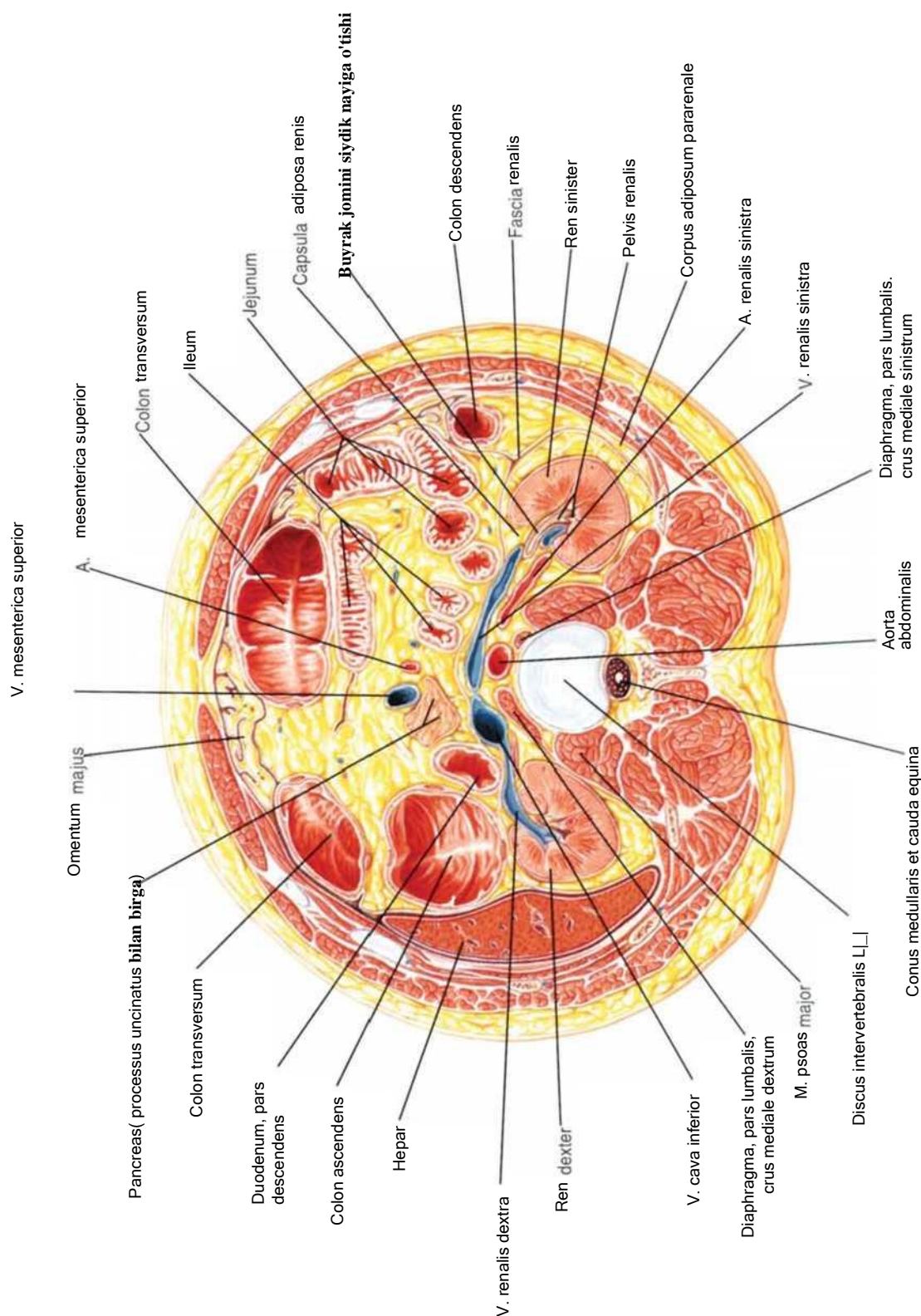


QORIN BO'SHLIG'I

519-Rasm

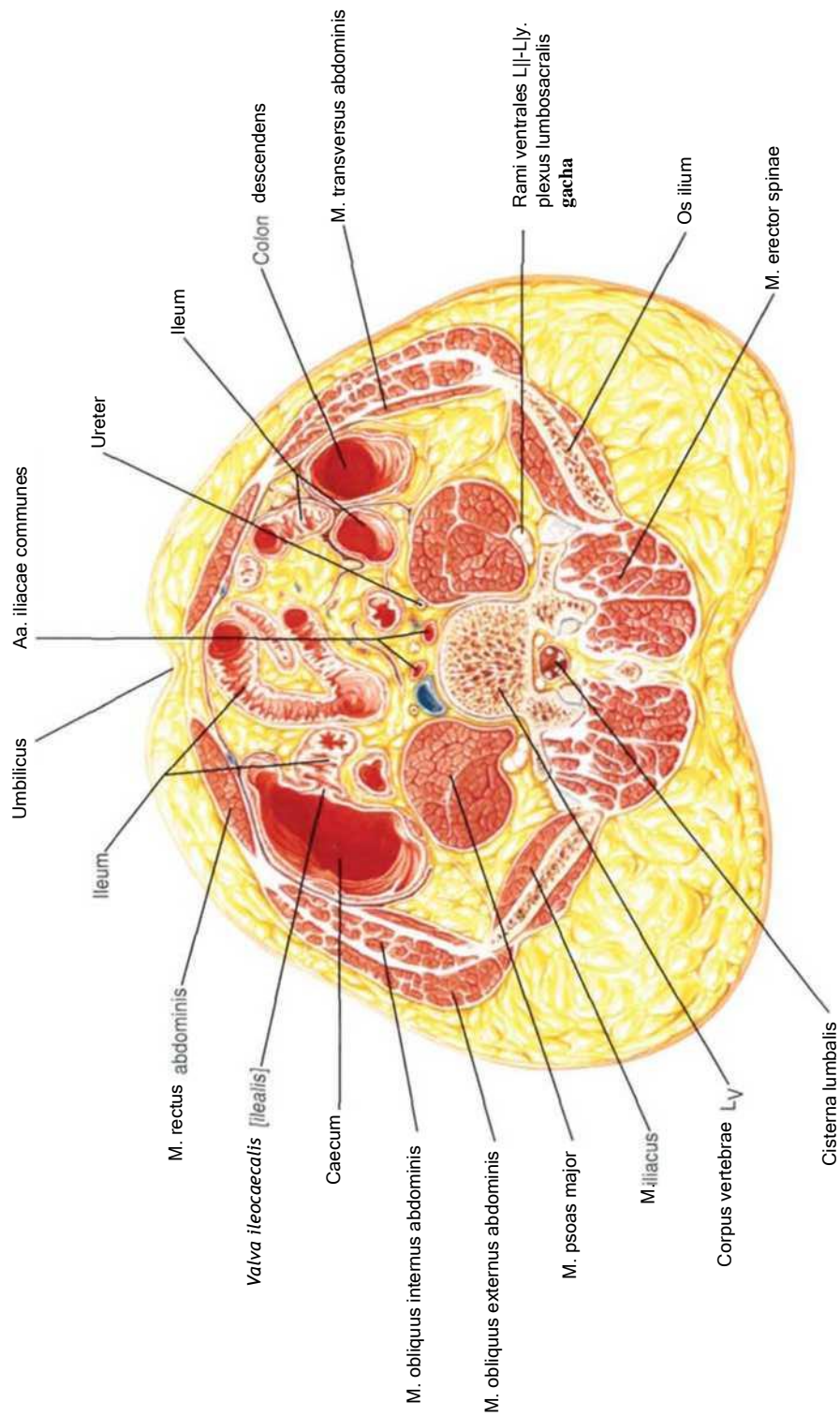
Qorin: buyrak darvozasi, L_{I-II} darajasida ko'ndalang kesmasi

Ko'ndalang kesma: discus intervertebralis L_{I-II}



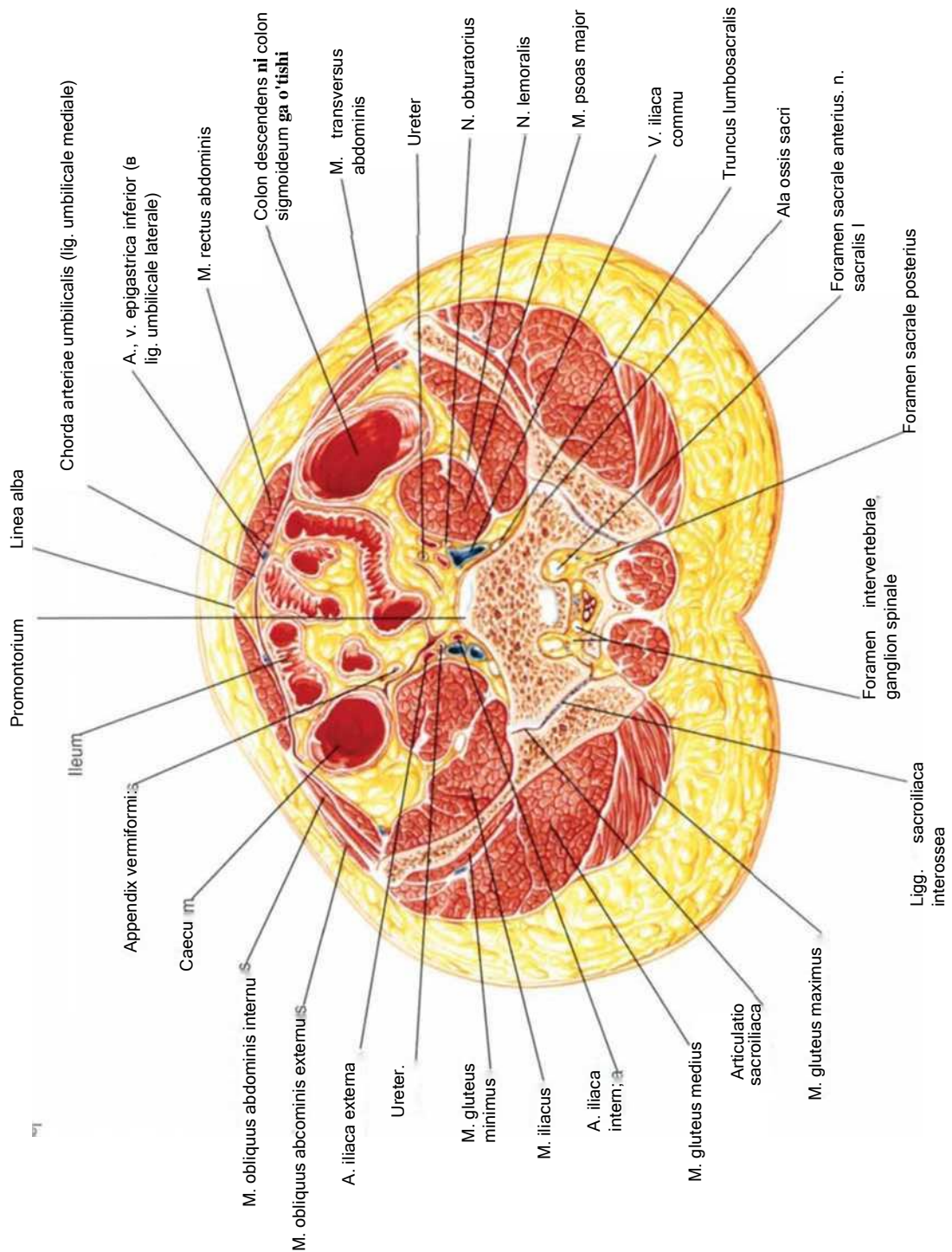
Qorin: iliotsekal klapan, Lv darajasida kesmasi

Ko'dalang kesma: Lv darajada



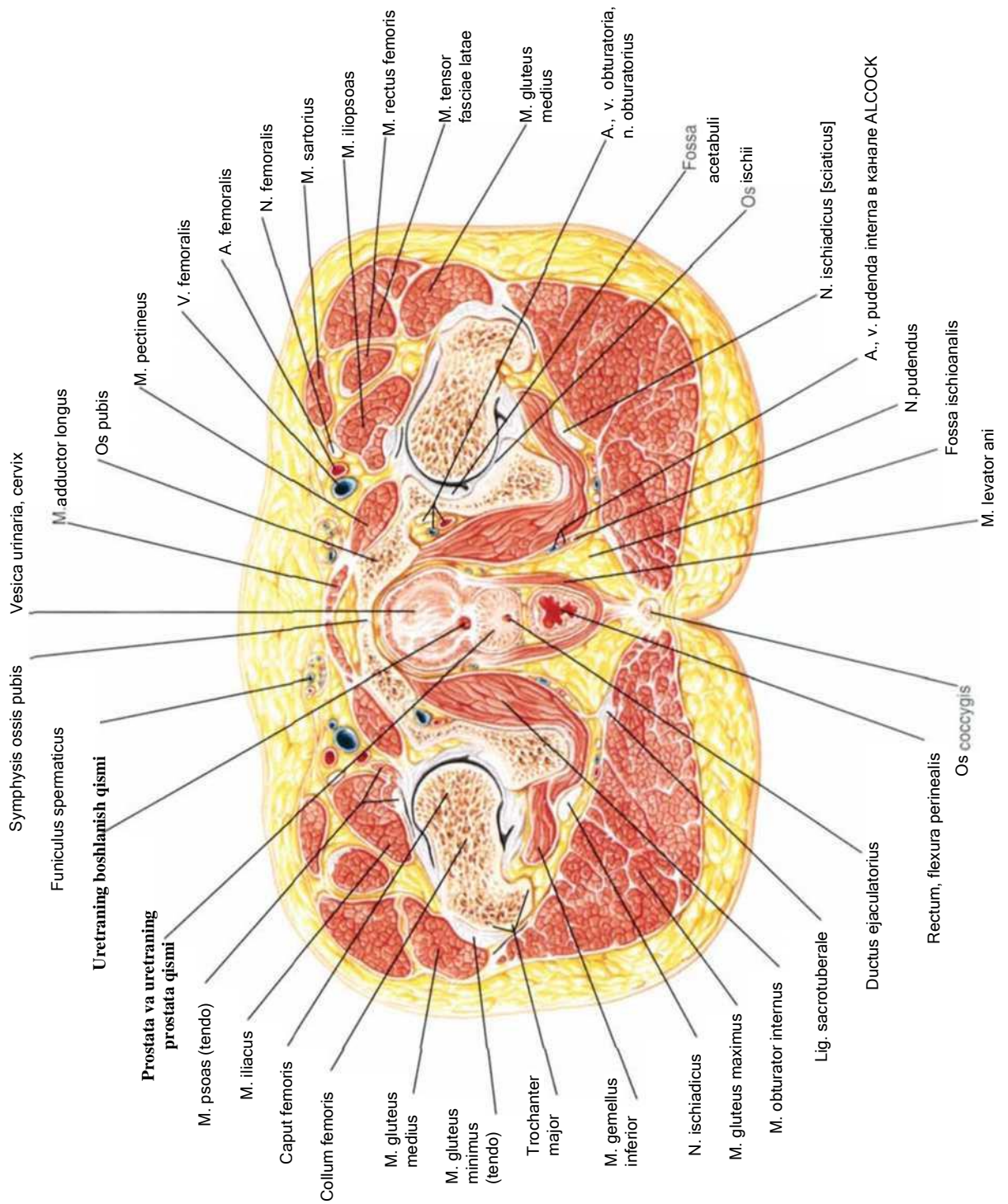
Qorin: dumg'aza do'nngligi, Sı darajasida kesmasi

Si darajada ko'ndalang kesma, yonbosh suyagining oldingi yuqorigi o'sig'i



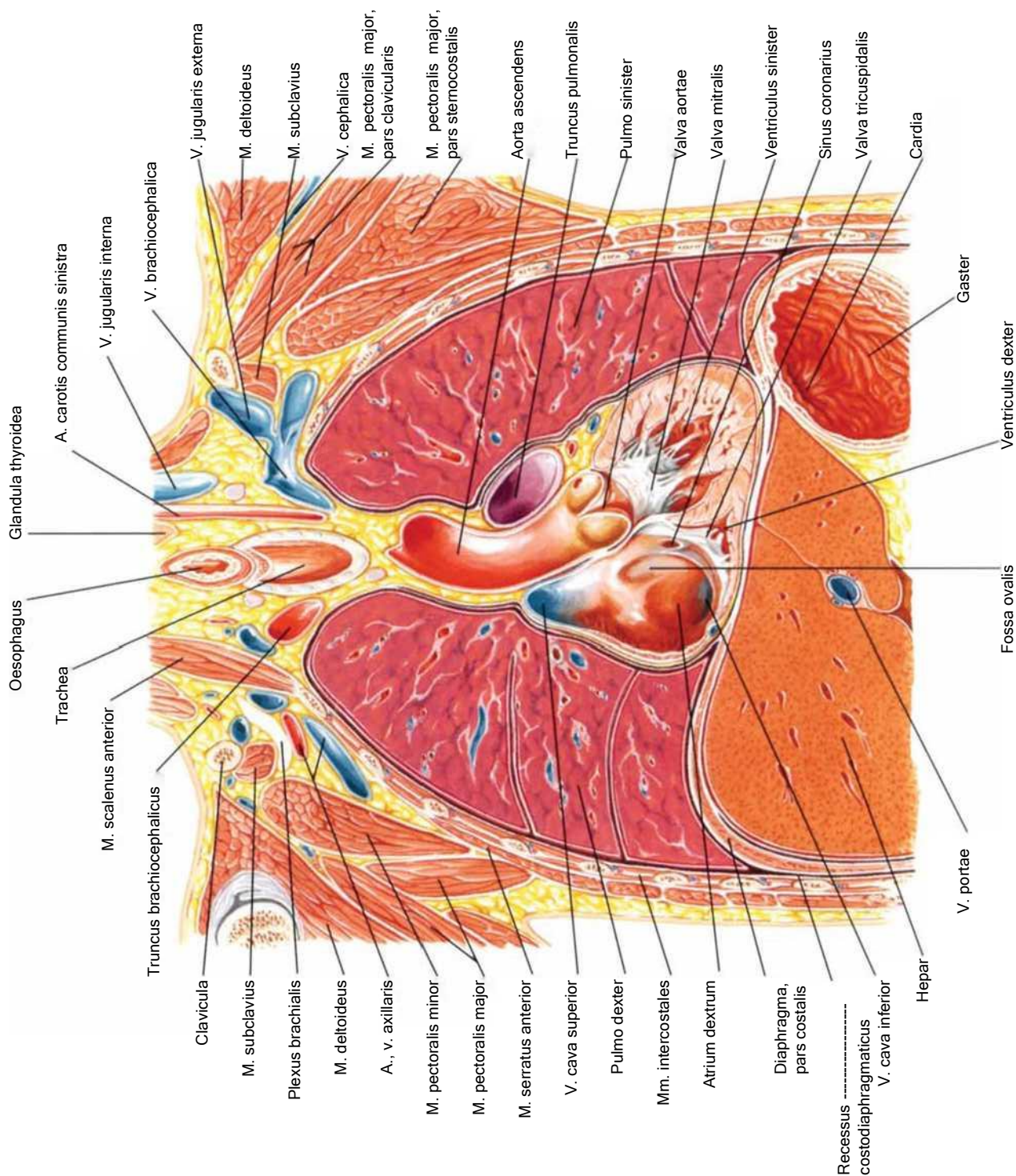
Erkaklar tosi: dum umurtqasi darajasida kesmasi

Ko'ndalang kesma: qov suyagi, son suyagining boshchalari, dum umurtqasi



Ko'krak qafasi: aortaning ko'tariluvchi qismi

Oldingi qo'ltiq osti chizig'i bo'ylab frontal yuza bo'yicha kesma



Ko'krak qafasi: traxeya bifurkatsiyasi, chap bo'lmacha

O'rta qo'ltiq osti chizig'i bo'ylab frontal yuza bo'yicha kesma

