

# An eText of Human Anatomy and Physiology

*Dr. Bruce Forciea*

Scientific information continuously progresses and changes. The author has done substantial work in order to ensure the information presented in this book is accurate, up to date, and within acceptable standards at the time of publication. The author is not responsible for errors or omissions, or for consequences from the application of the information contained in this book and makes no warranty, expressed or implied, with regard to the contents of this book.

### About the Author

Bruce Forcica is a full-time science instructor at [Moraine Park Technical College](http://www.morainepark.edu/). He primarily teaches anatomy and physiology. Besides developing courses, teaching, and dabbling in digital media, he enjoys writing fiction and playing guitar.

### Images

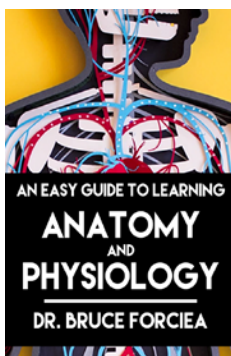
The images were selected primarily from [Wikimedia Commons](https://commons.wikimedia.org/) and some were modified by the author. The remaining images were produced by the author.

### Other Books by the Author



#### The X-Cure (Fiction-Thriller)

Dr. Alex Winter, a brilliant biomedical engineer, teams with Dr. Xiu Ling, a beautiful Chinese scientist, to discover a revolutionary cure for cancer. But Tando Pharmaceuticals, the world's largest and richest drug producer, also has an interest in the cure, and when they discover that the treatment is flawed as recipients begin to die after four months, causing a media frenzy and a drop in Tando's stock, they call upon their 'Mercenary Soldiers of Medicine' to maintain global domination.



#### An Easy Guide to Learning Anatomy and Physiology (Non-Fiction)

An Easy Guide to Learning Anatomy and Physiology can really help to ease the struggle of learning anatomy and physiology. This book breaks down complex concepts by presenting a simplified version of the main idea (called the Big Picture) before getting into the details. Written in an easy to understand and humorous way.

## Forward

Welcome to An etext of Anatomy and Physiology! I sincerely hope you find this text helpful in your study of the human body. This “streamlined” text provides detailed information about the salient topics covered in a traditional first year two course sequence in college Anatomy and Physiology without a lot of peripheral information. This allows students to focus on the primary concepts without getting lost in ancillary information that may or may not be relevant. This text should also serve as a good review for anyone wanting to brush up on the subject.

Interested readers will include allied health students such as nursing, surgical technology, physical therapy, medical assistant, dental assistant, massage therapy, pre-medical and pre-chiropractic. It is presented in an etext format that allows a number of advantages over printed medium. These include the ability to search through the text by entering terms in the search window (eliminating the need for an index), the ability to enlarge diagrams, and the portability of an electronic file.

There are also review questions at the end of each chapter with an answer key in the back of the text. Lastly there is a text webpage that includes learning plans, podcasts, powerpoints, links and videos to help students along.

This material is licensed under the creative commons license. This means that instructors are free to share, copy, modify and distribute. The only requirement is to cite the author.

I hope you enjoy this text as much as I’ve enjoyed developing it.

Sincerely,

Bruce

Dr. Bruce Forciea  
Moraine Park Technical College  
Unitek College

Visit my sites at:

[www.drbruceforciea.com](http://www.drbruceforciea.com)

Check out my anatomy and physiology study guide:

[An Easy Guide to Learning Anatomy and Physiology](#)

<b>Table of Contents</b>	<b>Page</b>
Chapter 1 Introduction to the Human Body	6
Chapter 2 Basic Chemistry Review	26
Chapter 3 Cells	41
Chapter 4 Overview of Cellular Metabolism	78
Chapter 5 Tissues	89
Chapter 6 The Integument	104
Chapter 7 The Skeletal System	117
Chapter 8 Joints	188
Chapter 9 Muscular System Anatomy	207
Chapter 10 Muscular System Physiology	259
Chapter 11 Nervous System Anatomy	285
Chapter 12 Nervous System Physiology	348
Chapter 13 The Senses	378
Chapter 14 The Endocrine System	417
Chapter 15 The Blood	441
Chapter 16 The Lymphatic System	463
Chapter 17 Immunity	474
Chapter 18 Cardiovascular System Anatomy	489
Chapter 19 Cardiovascular System Physiology	532
Chapter 20 Respiratory System Anatomy	557
Chapter 21 Respiratory Physiology	571
Chapter 22 Urinary Anatomy	586
Chapter 23 Urinary Physiology	600
Chapter 24 Fluids, Electrolytes, Acid-Base Balance	616
Chapter 25 Digestive System Anatomy	634
Chapter 26 Digestive System Physiology	667
Chapter 27 Reproductive System Anatomy	683
Chapter 28 Reproductive System Physiology	697
Chapter 29 Overview of Genetics	710
Chapter 30 Fetal Circulation	716
Answers to Review Questions	722



# Chapter 1

## An Introduction to the Human Body

## Introduction to the Human Body

Welcome to the fascinating world of human anatomy and physiology. The human is the ultimate living system on our planet. Your body is literally packed with complex systems working in harmony to keep you alive.

### Here are some cool facts about the human body:

*Your body has on the order of 10 trillion cells.*

*Every second your body is producing 15 million red blood cells.*

*Your nervous system can transmit impulses as fast as 450 miles per hour.*

*During an average lifetime the heart beats about 2.5 billion times.*

*In one day your blood travels nearly 1000 miles.*

Anatomy and physiology are the cornerstones for nearly all health professions. But before we get into learning about the body let's go over some strategies for success in this course.

***Use anatomical terminology as often as possible.*** The language of anatomy is quite foreign to some students and it takes a good deal of practice to feel comfortable pronouncing and using the terms. One way to practice is to simply use the terms by making up sentences. For example, you could say that your arm and wrist includes the brachial, antebrachial and carpal regions.

***Form small study groups.*** Study groups are a great way to practice terms and concepts. Small groups are much better than larger groups because they tend to stay more focused. One of the worst study groups I have been involved in consisted of 8-10 students. The group could not stay focused and a lot of time was lost. The best situation is to have a study partner or perhaps two other people besides you.

***Study in smaller time periods more frequently.*** Repetition is a key to learning anatomical structures. It is better to study in smaller time periods than one or two long study sessions right before an exam.

***Look at pictures and diagrams from other sources and try to name the parts.*** Sometimes students get locked into one particular picture for a set of structures. Looking at several different pictures of the same structure helps to provide a more three dimensional understanding of the structure.

## **Life**

So how would tell the difference between something living and something non-living? In other words how would you define a living system?

All living systems have certain characteristics. Living systems can move, grow, and respond to stimuli. They also need energy from food and oxygen from the air or water. These substances must be digested and absorbed so that they can be assimilated for growth, maintenance and energy. Also waste products need to be excreted.

## **Homeostasis**

Homeostasis is an important concept with regard to life. Life maintains itself by virtue of what is called homeostasis.

Homeostasis refers to a system's ability to maintain a range of values. Think of how your body maintains certain levels of substances in your blood. For example, your blood contains a sugar called glucose. Your body maintains a certain level of glucose by monitoring the glucose and then secreting certain hormones to raise or lower it. If glucose levels get too high your body responds by secreting a hormone called insulin to lower it. If glucose levels get too low then your body responds by secreting a hormone called glucagon to raise it.

Homeostasis relies on what are called feedback mechanisms. Your body has thousands of feedback systems in place that work to regulate many substances.

There are two types of feedback:

Negative Feedback is when the response is opposite to the stimulus.

Positive feedback is where the response is the same as the stimulus.

It is helpful to think of feedback in this "stimulus/response" way. A great example of feedback is a thermostat. Let's say we set the thermostat at 70 degrees. It's summer and hot outside and the room temperature begins to rise. Once it gets above 70 degrees the thermostat senses it and turns on the air conditioner. The result is the room cools down to below 70 degrees.

Let's review the stimulus response part.

Stimulus = room getting warmer.

Response = turn on air conditioner to cool room down.

Can you see that the stimulus and response are opposite? This is an example of negative feedback.

Now let's say we still have our thermostat set at 70 degrees but this time it is winter and we open the window. The temperature in the room begins to lower until it gets lower than 70 degrees. The system now responds by turning on the furnace. The room then gets warmer until the temperature gets above 70 degrees.

Again, let's review the stimulus response part.

Stimulus = room getting colder.

Response = turn on furnace to warm room up.

Can you see that the stimulus and response are still opposite? So this is still an example of negative feedback.

Now let's say that I wired up the thermostat the wrong way. Now when the temperature in the room rises above 70 degrees instead of turning on the air conditioner the furnace turns on and raises the room temperature. Can you see that the stimulus and response are now the same?

Stimulus = room getting warmer

Response = turn on furnace to make room even warmer

Since the stimulus and response are the same we call this positive feedback.

### **Levels of Organization**

The body is organized according to levels of complexity. The lowest level of complexity is the atom. The highest level of complexity is the organism.

Here are the levels from lowest to highest complexity:

- Atom
- Molecule
- Cell
- Organelle
- Organ
- Organ System
- Organism (human body)

## Basic Concepts

The human body can be divided into two basic sections. The axial section contains the head, neck and trunk. The appendicular section contains the arms and legs, also known as the upper and lower extremities.

The body also contains hollow areas called cavities. There are 2 large cavities. One cavity is in the front part of the body and is called the ventral cavity. The other is in the back and is called the dorsal cavity.

Both cavities can be subdivided into smaller cavities. The ventral cavity can be subdivided into the thoracic and abdominopelvic cavities. The thoracic portion is in the chest area and the abdominopelvic portion is in the stomach area. The thoracic and abdominopelvic cavities are separated by a structure known as the diaphragm.

The dorsal cavity can also be subdivided into 2 smaller cavities. One cavity is called the cranial cavity and is located in the head. The other is called the spinal canal and runs down the back. The cranial cavity contains the brain and the spinal canal contains the spinal cord (see fig. 1.1).

There are also some smaller cavities in the body. These include:

- Oral (teeth, tongue)
- Nasal (sinuses)
- Orbital (eyes and associated muscles, nerves)
- Middle ear (middle ear bones)

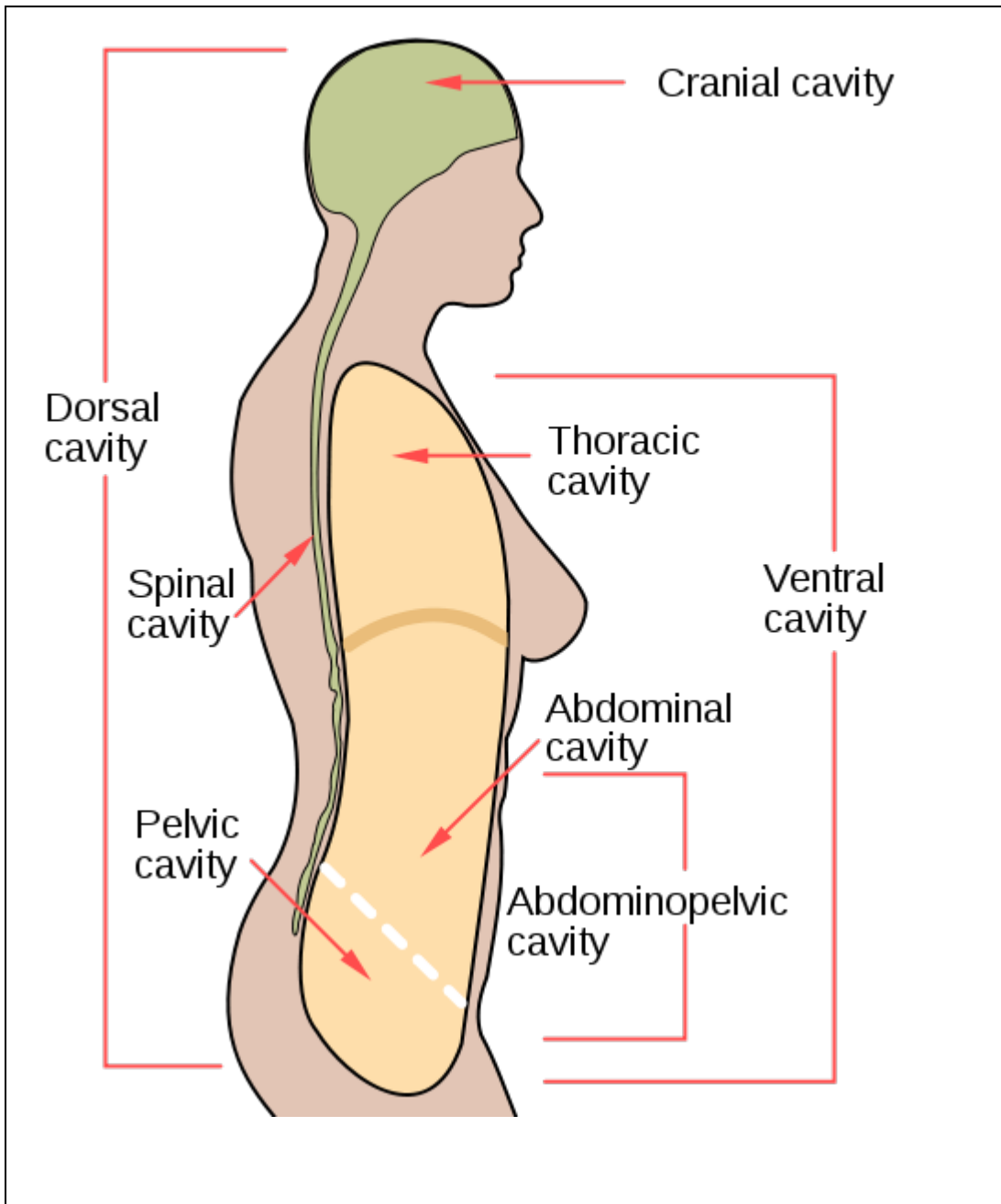


Figure 1.1 Body Cavities

[http://commons.wikimedia.org/wiki/File:Scheme\\_body\\_cavities-en.svg](http://commons.wikimedia.org/wiki/File:Scheme_body_cavities-en.svg)

## Overview of Body Systems

Let's look at an overview of all of the body systems. These include:

- Integumentary
- Skeletal
- Muscular
- Nervous
- Endocrine
- Lymphatic
- Digestive
- Respiratory
- Urinary
- Reproductive

The integumentary system consists of the hair, skin, nails, sweat glands, and sebaceous glands. Its function is protection of the body, secretion of waste products, production of vitamin D and regulation of body temperature. The integumentary system also supports sensory receptors that send information to the nervous system.

The skeletal system consists of the bones, ligaments, and cartilage. It provides protection and support and produces red blood cells. It also stores chemical salts.

The muscular system produces movement, helps to maintain posture and produces heat.

The nervous system consists of the brain, spinal cord, and receptors. It receives sensory information, detects changes, and in response, stimulates muscles and glands.

The endocrine system is a series of glands that secrete hormones. The endocrine system contains many feedback systems to help maintain homeostasis. The glands include:

- Pituitary
- Thyroid
- Parathyroid
- Adrenal
- Pancreas
- Ovaries
- Testes
- Pineal
- Thymus
- Hypothalamus

The cardiovascular system includes the heart, arteries, capillaries and veins. The function of the cardiovascular system is to transport blood.

The lymphatic system includes the lymph vessels, lymph nodes, thymus and spleen. The function of the lymphatic system is to return tissue to blood as well as transport some absorbed food molecules and defend against infection.

The respiratory consists of the nasal cavity, lungs, pharynx, larynx, trachea, and bronchi. The respiratory system supplies the body with oxygen and eliminates carbon dioxide.

The digestive system includes:

- Mouth
- Tongue
- Teeth
- Salivary glands
- Pharynx
- Esophagus
- Liver
- Gallbladder
- Pancreas
- Intestines

The function of the digestive system is to receive, break-down, and absorb food. It also eliminates wastes.

The urinary system includes the:

- Kidneys
- Ureters
- Urinary bladder
- Urethra

The function of the urinary system is to remove wastes, maintain water and electrolyte balance, and store and transport urine.

The male reproductive system includes:

- Scrotum
- Testes
- Epididymes
- Vasa deferentia
- Seminal vesicles
- Prostate
- Bulbourethral glands



Urethra  
penis

The female reproductive system includes:

Ovaries  
Uterine tubes  
Uterus  
Vagina  
Clitoris  
Vulva

The function of the reproductive systems is to pass genetic information down to future generations as well as produce hormones that help the body to mature.

### **Anatomical Terminology**

Now that we are a little familiar with the overview of the body, let's get into some anatomical terminology. We'll start with learning the anatomical terms for the parts of the body. In anatomy we always reference the body with regard to anatomical position (see fig. 1.2).

Here is a picture of anatomical position:

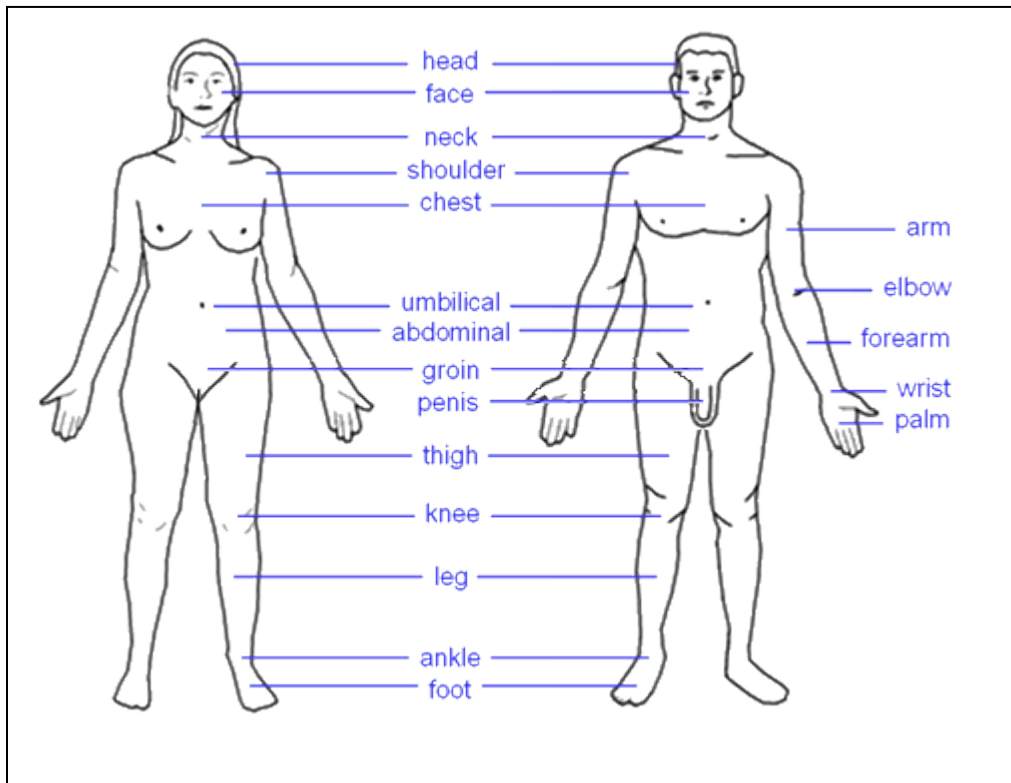


Figure 1.2 Anatomical Position.

[http://commons.wikimedia.org/wiki/Image:Human\\_body\\_features.png](http://commons.wikimedia.org/wiki/Image:Human_body_features.png)

In anatomy body parts have special names that differ from common names. In other words in anatomy the knee cap is not called the knee cap but is called the patella. It will take some practice to get used to these anatomical terms.

We will start with some regions of the body. A region is a broader area such as the upper leg (femoral region). Although a region may sound like an actual body part, it is not. It is an area.

## Anatomical Regions

Common Term	Anatomical Term	Region
Foot	Pes	Pedal
Shin	Crus	Crural
Calf	Sura	Sural
Front of knee	Patella (knee cap)	Patellar
Back of knee	Popliteus	Popliteal
Thigh	Femoris	Femoral
Groin	Inguina	Inguinal
Butt	Buttock	Gluteal
Stomach	Abdomen	Abdominal
Low Back	Lumbus	Lumbar
Chest and Middle back	Thorax	Thoracic
Lateral chest	Pectorus	Pectoral
Middle chest	Sternum	Sternal
Neck	Cervicis	Cervical
Chin	Mentum	Mental
Head	Cephalon	Cephalic
Shoulder	Acromion	Acromial
Arm	Brachium	Brachial
Elbow (front)	Antecubitus	Antecubital
Elbow (back)	Olecranon	Olecranal
Wrist	Carpus	Carpal
Hand	Manus	Manual
Forearm	Antebrachium	Antebrachial

## Dividing the Abdomen

The abdomen can be divided two ways which helps to describe the locations of structures. In one method the abdomen is divided into 9 sections much like tic-tac-toe (fig. 1.4). The other method is a bit simpler in that the abdomen is divided into 4 sections (fig 1.3).

Four planes are needed in order to divide the abdomen into 9 equal sections. There are 2 parasagittal planes (sometimes called lateral lines) and 2 transverse planes. The superior transverse plane is called the transpyloric plane and the inferior plane is called the transtubercular plane. The center of the 9 regions is the umbilicus. The 3 superior regions are the epigastric and right and left hypochondriac. The middle regions are the umbilical and right and left lumbar. The lower regions are the hypogastric and right and left inguinal.

The other method of dividing up the abdominal area consists of using a transverse and mid-sagittal plane intersecting at the umbilicus. This results in 4 quadrants including the right and left upper quadrants and right and left lower quadrants.

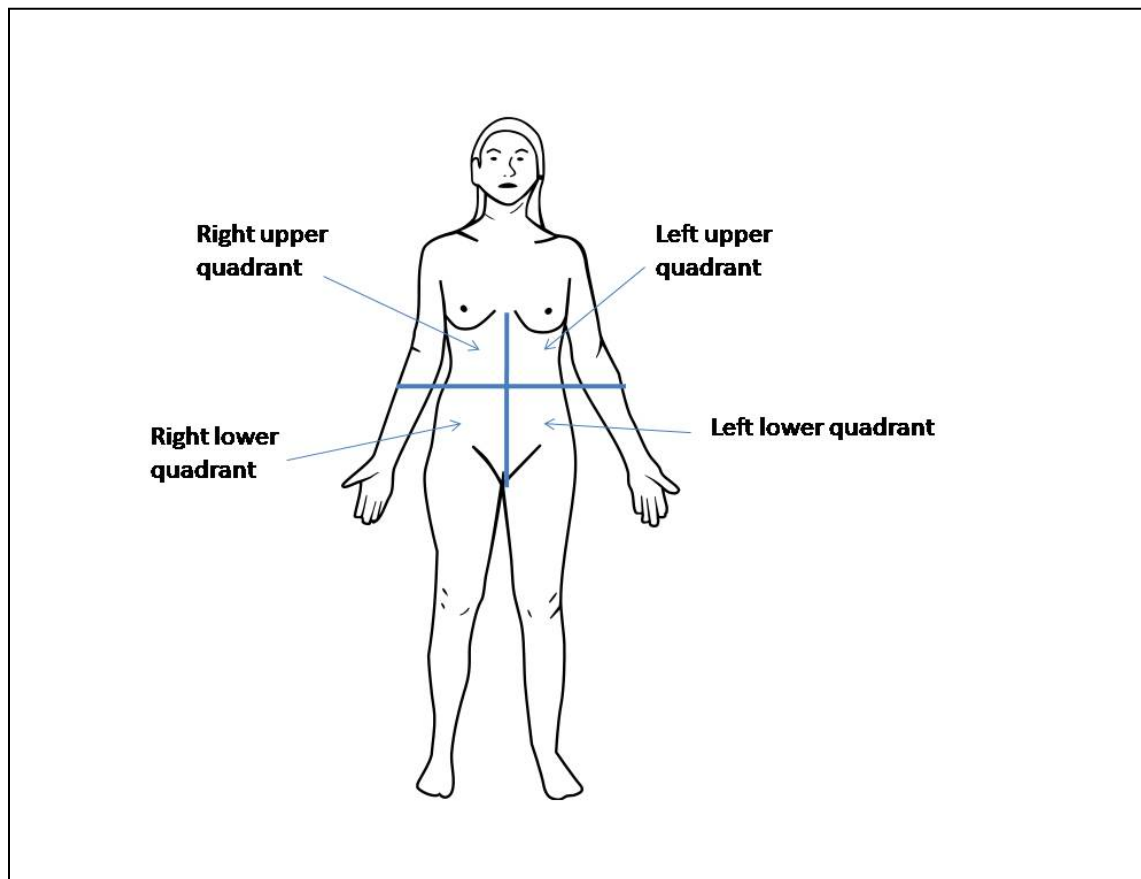


Figure 1.3 Abdominal quadrants

Modified from: [http://commons.wikimedia.org/wiki/File:Human\\_body\\_features.svg](http://commons.wikimedia.org/wiki/File:Human_body_features.svg)

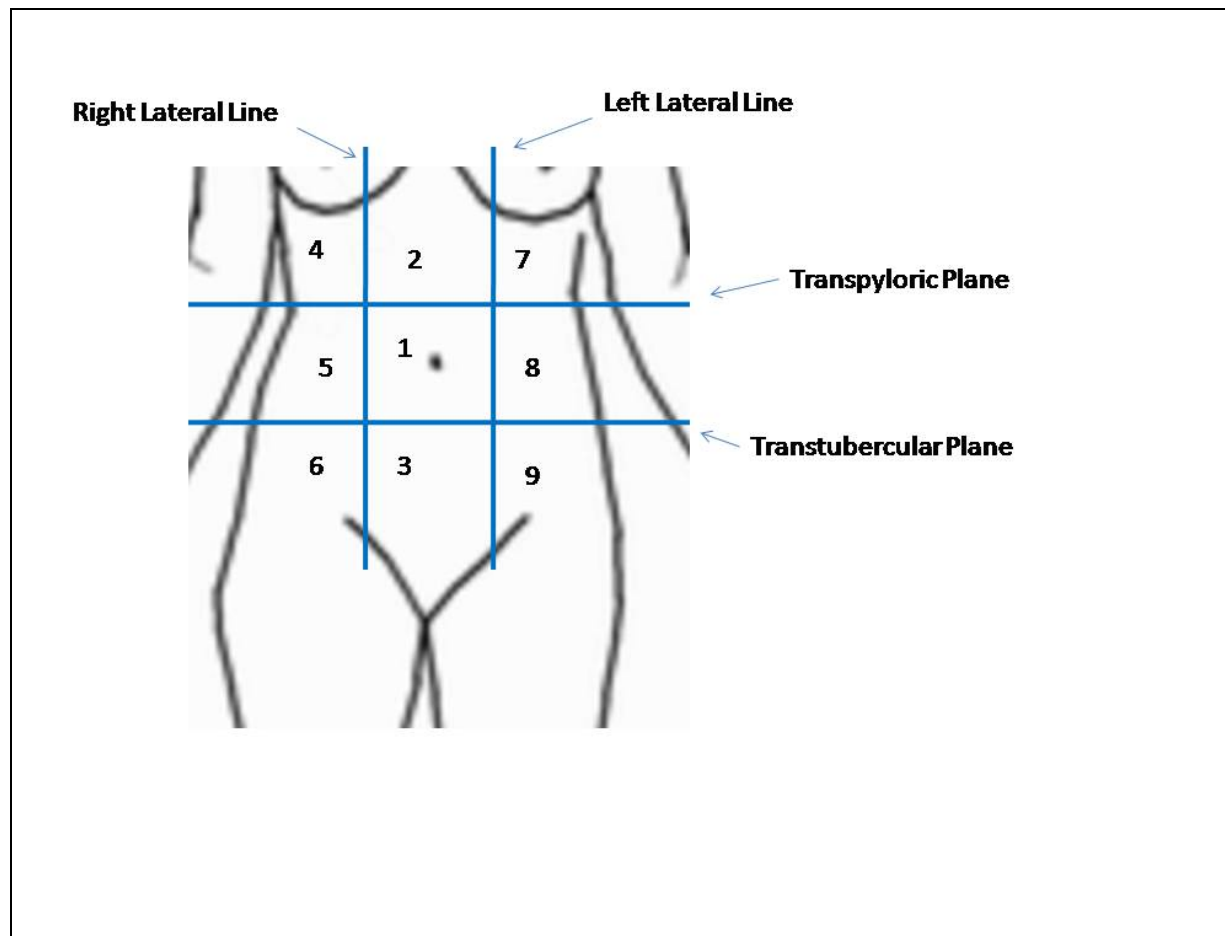


Figure 1.4 Planes dividing the abdominal region into 9 areas.

1. Umbilical
2. Epigastric
3. Hypogastric
4. Right hypochondriac
5. Right lumbar
6. Right iliac
7. Left hypochondriac
8. Left lumbar
9. Left iliac

## Positional Terms

Next we will learn about positional terminology. We use positional terminology in order to specify locations of anatomical structures. The positional terms usually go in pairs. For example superior and inferior go together. Superior means above and inferior means below.

So we could write a statement stating that the head is superior to the chest or to be more specific—the cephalon is superior to the thorax.

AND

The reverse would also be true:  
The thorax is inferior to the cephalon.

Here are some other terms:

Anterior means towards the front.

Posterior means towards the back.  
Ex: the sternum is anterior to the heart...  
OR the heart is posterior to the sternum.

Medial means toward the midline of the body.

Lateral means away from the midline.  
Ex: the ears are lateral to the nose

And...  
The nose is medial to the ears.

Proximal means towards the trunk of the body.

Distal means away from the trunk.  
Proximal and distal are usually used when describing structures in the extremities.  
Ex: the elbow is proximal to the wrist.  
The wrist is distal to the elbow.

Superficial means toward the surface.  
Deep means under the surface.

Ex: the skin is superficial to the stomach.

The stomach is deep to the skin.

Ipsilateral means on the same side.

Contralateral means on the opposite side.

Ex: the right shoulder and elbow are ipsilateral.

The right shoulder and left elbow are contralateral.

### Anatomical Planes

Anatomical planes are used for studying slices of the body. For example, magnetic resonance imaging (MRI) can “slice” the body into sections in order to look for abnormalities (fig. 1.5).

The anatomical planes divide the body in various ways (fig. 1.6, 1.7).

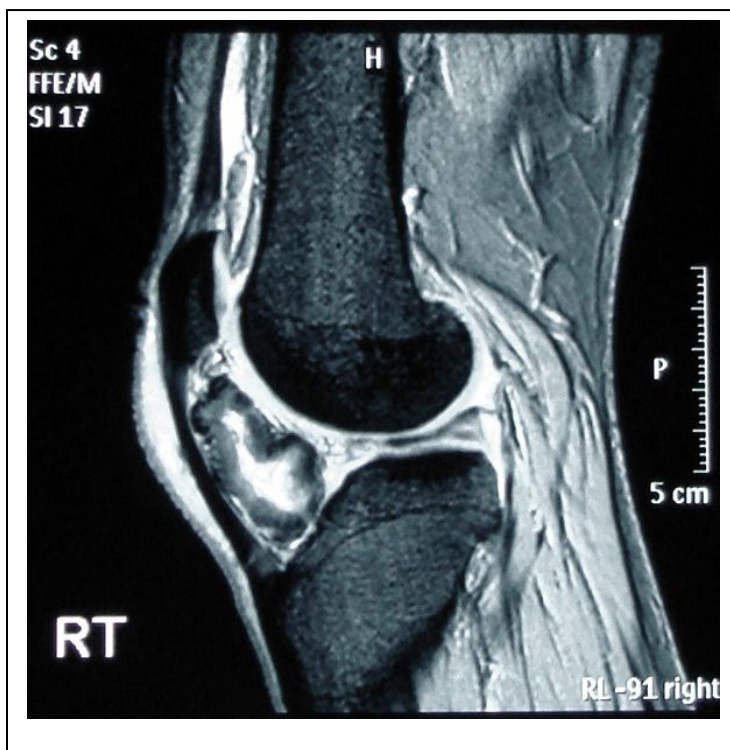

Figure 1.5. MRI Image of the knee. The MRI presents a slice of the body. In this picture we see a sagittal section of the knee.

[http://commons.wikimedia.org/wiki/File:Osteochondroma\\_MRI.JPG](http://commons.wikimedia.org/wiki/File:Osteochondroma_MRI.JPG)

## Planes

The sagittal plane divides body into right and left portions.

The transverse plane divides body into superior and inferior portions.

The coronal plane divides body into anterior and posterior portions.

The oblique plane divides the body at an angle.

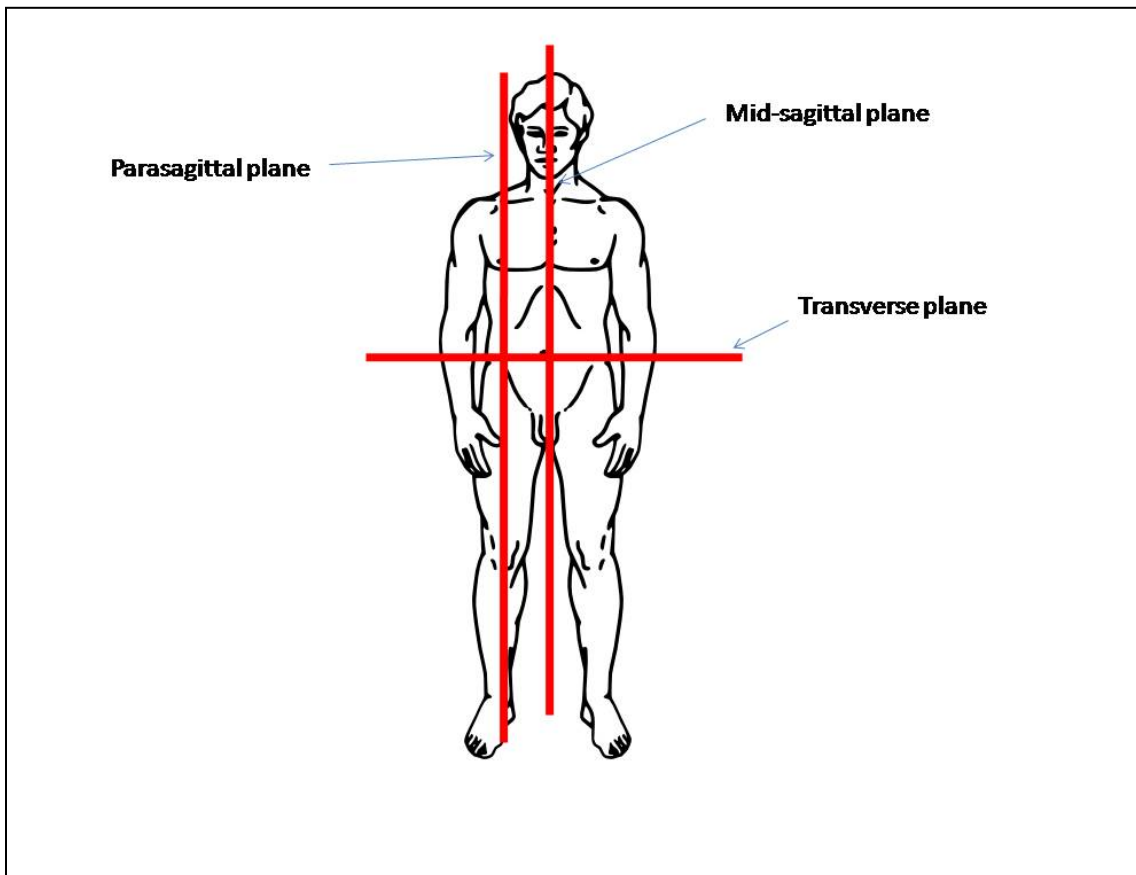


Figure 1.6 Anatomical planes

[http://commons.wikimedia.org/wiki/File:Line-drawing\\_of\\_a\\_human\\_man.svg](http://commons.wikimedia.org/wiki/File:Line-drawing_of_a_human_man.svg)

Courtesy of NASA  
Original image modified by Dr. Bruce Forciea



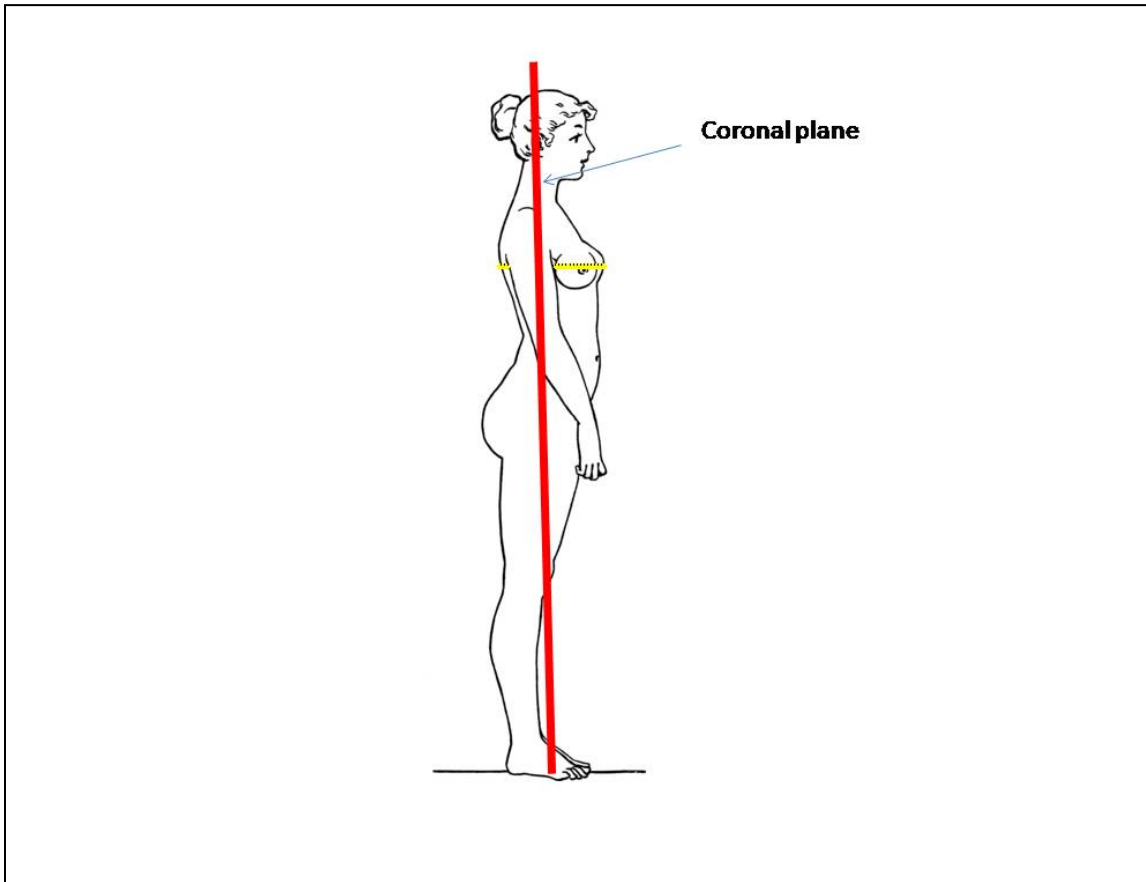


Figure 1.7 Coronal plane

[http://commons.wikimedia.org/wiki/File:NormalerKorper\\_mit\\_full\\_bust.PNG](http://commons.wikimedia.org/wiki/File:NormalerKorper_mit_full_bust.PNG)

## **Real World A&P**

### **Using Anatomical Terms in Medical Reports**

Can you interpret the following excerpt from a medical report:

The patient reported with a moderate injury to the cervical region on the right side with radiation of pain into the ipsilateral brachial region extending distally to the antebrachium and carpals.

The lesion extends from the medial aspect of the inguinal region laterally to the lateral femoral region.

How about this anatomical description:

The lungs are located in the thoracic cavity deep to the sternum and lateral to the mediastinum. The medial border of the lungs extends along a parasagittal plane beginning at the lateral margins of the mediastinum and extending laterally to the margins of the thoracic cavity. The lungs terminate inferiorly with the diaphragm and superiorly with the superior margin of the thoracic cavity.

## Review Questions Chapter 1

1. The study of physiology involves which of the following:
  - a. Structure of the body
  - b. Function of the body
  - c. The position of the body
  - d. All of the above
2. Homeostasis incorporates the use of \_\_\_\_\_.
  - a. Muscles
  - b. Feedback systems
  - c. Equilibrium
  - d. Movement
3. Which of the following is an example of negative feedback:
  - a. Thermostat
  - b. Sound system feedback
  - c. Stimulus and response are the same
  - d. An increase in secretion of a substance causing a subsequent increase in the same substance
4. The \_\_\_\_\_ level of complexity is greater than the \_\_\_\_\_ level of complexity:
  - a. Organ, molecule
  - b. Atom, molecule
  - c. Organ system, organism
  - d. Molecule, cell
5. Which body system secretes hormones:
  - a. Skeletal
  - b. Muscular
  - c. Integument
  - d. Endocrine
6. Nails are part of which body system:
  - a. Endocrine
  - b. Muscular
  - c. Skeletal
  - d. Integument
7. Joints are part of which body system:
  - a. Muscular
  - b. Integument
  - c. Nervous
  - d. Skeletal

8. In the 9 region abdominal divisions the \_\_\_\_\_ plane is superior to the \_\_\_\_\_ plane:
- Transpyloric, transtubercular
  - Sagittal, transverse
  - Mid-sagittal, coronal
  - Transtubercular, transpyloric
9. The \_\_\_\_\_ region is inferior to the \_\_\_\_\_ region:
- Umbilical, hypogastric
  - Right inguinal, right hypochondriac
  - Epigastric, umbilical
  - Left hypochondriac, right hypochondriac
10. In the 4 quadrant abdominal regions 2 planes intersect at the \_\_\_\_\_
- Stomach
  - Diaphragm
  - Umbilicus
  - Bladder
11. The \_\_\_\_\_ plane divides the body into anterior and posterior sections:
- Sagittal
  - Coronal
  - Transverse
  - Oblique
12. The head is called the \_\_\_\_\_:
- Cervical
  - Cephalix
  - Cephalon
  - Cranish
13. The anterior part of the leg below the knee is called the \_\_\_\_\_ region:
- Femoral
  - Popliteal
  - Crural
  - Sural
14. The forearm is called the \_\_\_\_\_
- antebrachium
  - brachium
  - cubital
  - olecranal
15. The highest part of the shoulder is called the \_\_\_\_\_ region:
- Pectoral
  - Acromial
  - Thoracic
  - Cervical

16. This positional term means “in front of”

- a. Medial
- b. Anterior
- c. Distal
- d. Superior

17. This positional term means “on the same side as”

- a. Proximal
- b. Ipsilateral
- c. Anterior
- d. Medial

18. This positional term is typically used for describing the extremities:

- a. Anterior
- b. Superficial
- c. Medial
- d. Proximal

## Chapter 2

### Basic Chemistry Review

## Basic Chemistry Review

In this presentation we will review some basic chemistry concepts that are relevant to the study of anatomy and physiology.

We'll start with the building blocks of matter.

All matter is made up of elements. There are 26 elements in your body. Carbon, Oxygen, Nitrogen and Hydrogen make up about 96% of your body. The elements are made up of atoms (fig. 2.1).

		Group																		
		I	II											III	IV	V	VI	VII	VIII	
Period	1	1 H																		2 He
	2	3 Li	4 Be											5 B	6 C	7 N	8 O	9 F	10 Ne	
	3	11 Na	12 Mg											13 Al	14 Si	15 P	16 S	17 Cl	18 Ar	
	4	19 K	20 Ca	21 Sc	22 Ti	23 V	24 Cr	25 Mn	26 Fe	27 Co	28 Ni	29 Cu	30 Zn	31 Ga	32 Ge	33 As	34 Se	35 Br	36 Kr	
	5	37 Rb	38 Sr	39 Y	40 Zr	41 Nb	42 Mo	43 Tc	44 Ru	45 Rh	46 Pd	47 Ag	48 Cd	49 In	50 Sn	51 Sb	52 Te	53 I	54 Xe	
	6	55 Cs	56 Ba	*	72 Hf	73 Ta	74 W	75 Re	76 Os	77 Ir	78 Pt	79 Au	80 Hg	81 Tl	82 Pb	83 Bi	84 Po	85 At	86 Rn	
	7	87 Fr	88 Ra	**	104 Rf	105 Db	106 Sg	107 Bh	108 Hs	109 Mt	110 Ds	111 Rg	112 Uub	113 Uut	114 Uuq	115 Uup	116 Uuh	117 Uus	118 Uuo	
	8	119 Uun																		
			* Lanthanides			57 La	58 Ce	59 Pr	60 Nd	61 Pm	62 Sm	63 Eu	64 Gd	65 Tb	66 Dy	67 Ho	68 Er	69 Tm	70 Yb	71 Lu
		** Actinides			89 Ac	90 Th	91 Pa	92 U	93 Np	94 Pu	95 Am	96 Cm	97 Bk	98 Cf	99 Es	100 Fm	101 Md	102 No	103 Lr	

Alkali metals	Alkaline earth metals	Lanthanides	Actinides	Transition metals
Poor metals	Metalloids	Nonmetals	Halogens	Noble gases

State at standard temperature and pressure

Atomic number in red: gas

Atomic number in blue: liquid

Atomic number in black: solid

solid border: at least one isotope is older than the Earth (Primordial elements)

dashed border: at least one isotope naturally arise from decay of other chemical elements and no isotopes are older than the earth

dotted border: only artificially made isotopes (synthetic elements)

no border: undiscovered

Figure 2.1. Periodic table of the elements.

[http://commons.wikimedia.org/wiki/Periodic\\_table](http://commons.wikimedia.org/wiki/Periodic_table)

## Atoms

Atoms are made from 3 basic particles. Protons are positively charged and reside in the nucleus (atom core). Electrons are negatively charged and orbit around the nucleus. Neutrons carry no charge and are located in the nucleus (fig. 2.2).

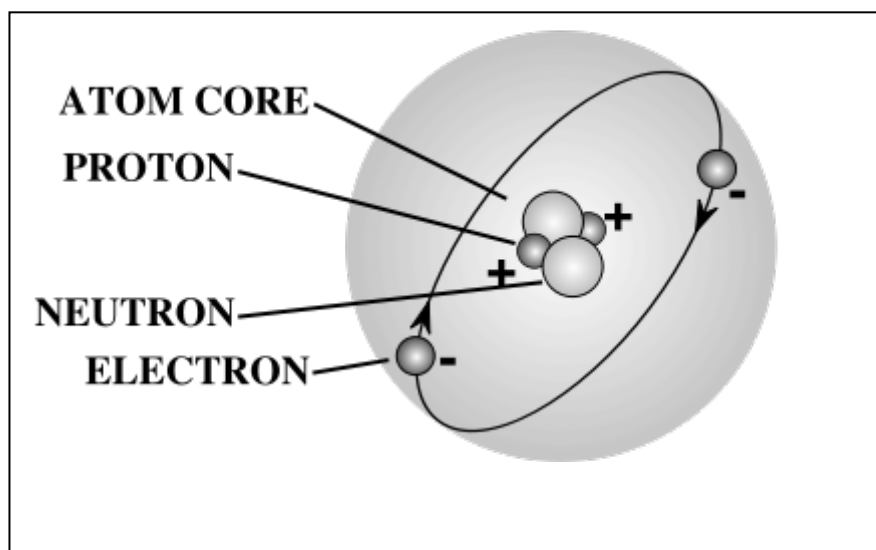


Figure 2.2. The atom. Protons and neutrons are located in the core or nucleus with electrons located in shells surrounding the nucleus.

<http://commons.wikimedia.org/wiki/Image:Atom-struct.svg>

The basic structure of the atom is a core or nucleus surrounded by electrons orbiting in “shells.” These shells can hold different numbers of electrons (fig. 2.3).

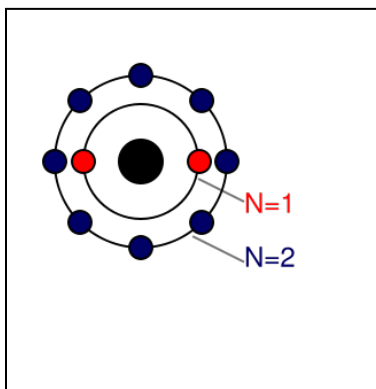


Figure 2.3. Here is a diagram of the Neon atom. Notice that there are 2 possible orbits or shells that carry electrons. The shells are named N1 and N2 respectively.

[http://commons.wikimedia.org/wiki/Image:Neon\\_Atom.svg](http://commons.wikimedia.org/wiki/Image:Neon_Atom.svg)



## Atomic Number

The number of protons in the atom is known as the atomic number. If we add the protons and neutrons together we have what is known as the mass number. Usually, the atom has the same number of protons and neutrons. If an atom has a different number of protons and neutrons it is known as an isotope.

If an atom has equal numbers of protons and electrons it is said to be neutral. The positive and negative charges balance each other out. If an atom has unequal numbers of protons and electrons it will be charged and is known as an ion. In physiology we call these atoms electrolytes.

The atomic mass is the sum of the masses of protons, neutrons and electrons and represents the average mass of all naturally occurring isotopes.

Generally atoms and molecules built from atoms like to have their outer shells filled with electrons. Electrons usually fill these shells in even numbers. However this does not always occur. If an atom or molecule has an unpaired electron in the outer shell it is known as a free radical.

## Chemical Bonds

Atoms are held together by forces. There are 4 fundamental forces in the universe. These are the strong and weak nuclear forces, gravity and the electromagnetic force. The forces are carried by tiny particles. The force that accounts for chemical bonding is the electromagnetic force which is carried by the photon.

### Ionic Bonds

If an atom loses an electron and another picks up an electron, an ionic bond forms (fig. 2.4). Some ionic bonds can “break up” or dissociate in solution. This dissociation occurs because water molecules surround the sodium and chloride atoms. The sodium chloride is then said to have dissolved in water. Ionic bonds are characterized by this exchange of electrons.

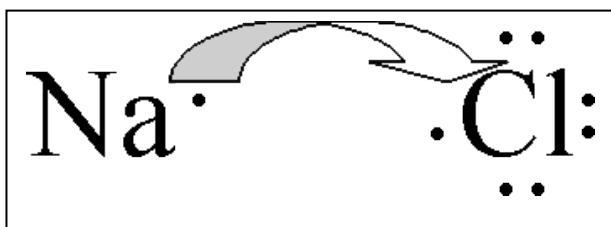


Fig. 2.4.Sodium (Na) loses an electron and Chloride (Cl) gains an electron forming an ionic bond (NaCl).

[http://commons.wikimedia.org/wiki/Image:NaCl\\_ionic.png](http://commons.wikimedia.org/wiki/Image:NaCl_ionic.png)

Faraaz Damji

## Covalent Bonds

Some atoms can “share” electrons. In this case the bond is known as a covalent bond. The more electrons are shared, the stronger the bond. Most organic molecules are covalently bonded. Covalent bonds are stronger than ionic bonds (fig. 2.5).

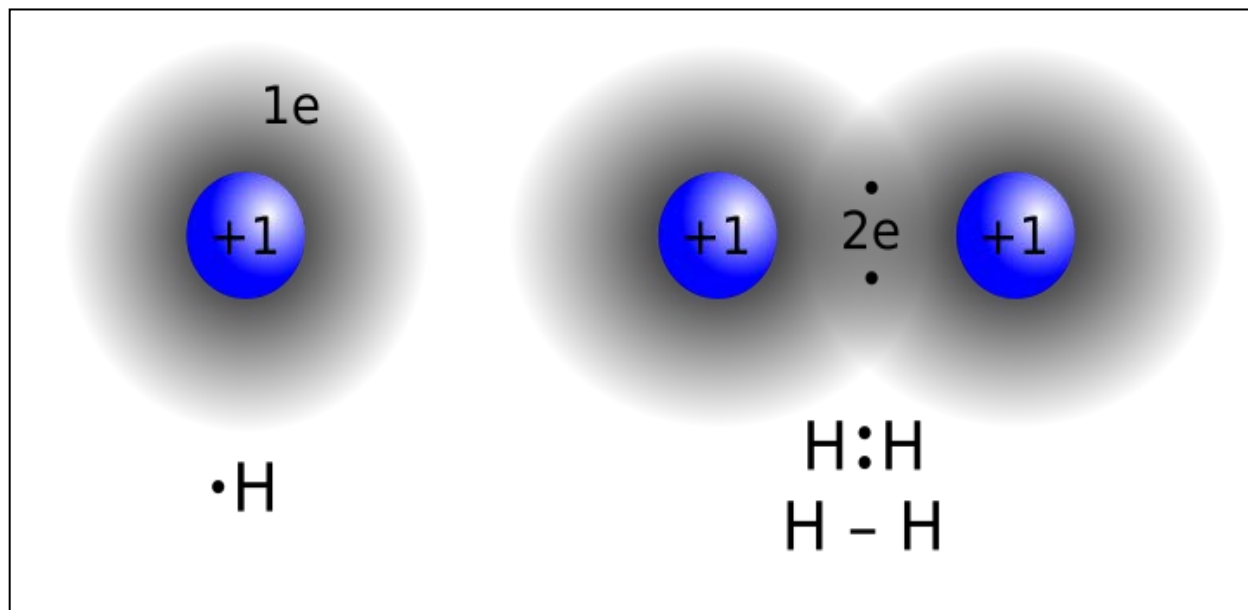


Figure 2.5. Hydrogen can form a covalent bond with itself. Electrons are shared in a covalent bond.

[http://commons.wikimedia.org/wiki/Image:Covalent\\_bond\\_hydrogen.svg](http://commons.wikimedia.org/wiki/Image:Covalent_bond_hydrogen.svg)

by Jacek FH

## Polar Covalent Bonds

If the electrons are not equally shared one side carries a greater charge. The molecule is then described as polar (fig. 2.6)

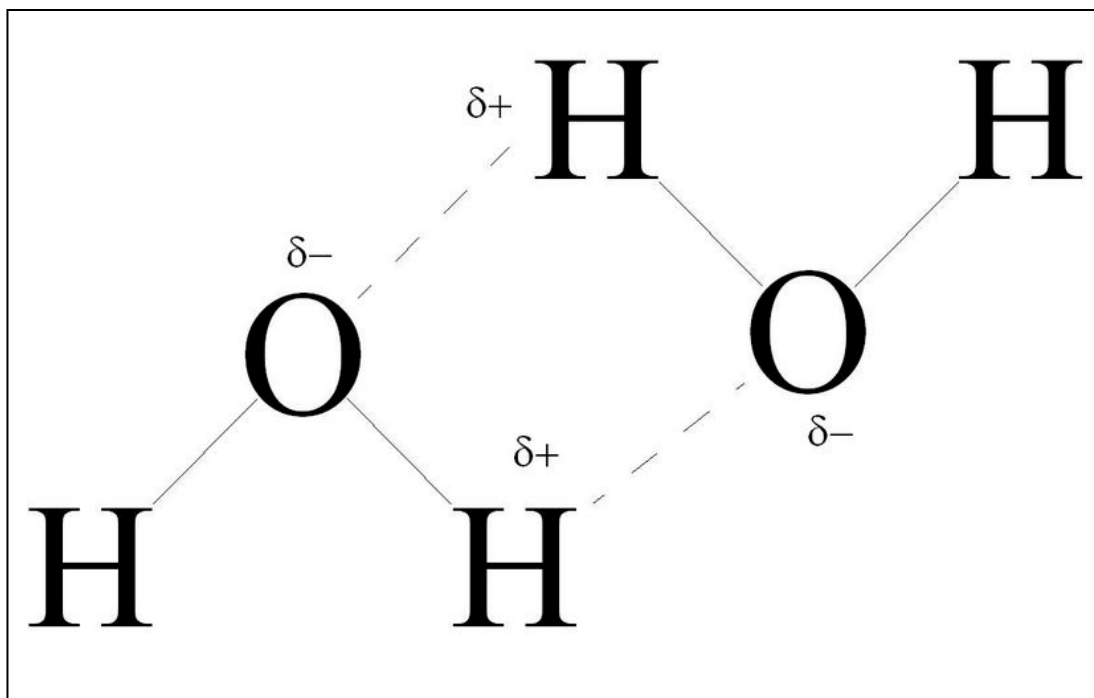


Figure 2.6. Water has a partial positive charge on the hydrogen side and a partial negative charge on the oxygen side. Notice how these 2 water molecules can bond together. The partial positive and negative sides attract forming weak bonds called polar covalent bonds.

<http://commons.wikimedia.org/wiki/Image:Legameidrogeno-h2o.jpg>

Polar covalent bonds are weak bonds formed by the partial positive and negative charges in molecules such as water. They are responsible for a force on the surface of water called surface tension.

## Chemical Reactions

Chemical bonds can break and new bonds form in chemical reactions. The substances we start with are known as the reactants. The substances that are formed are known as the products (fig. 2.7).

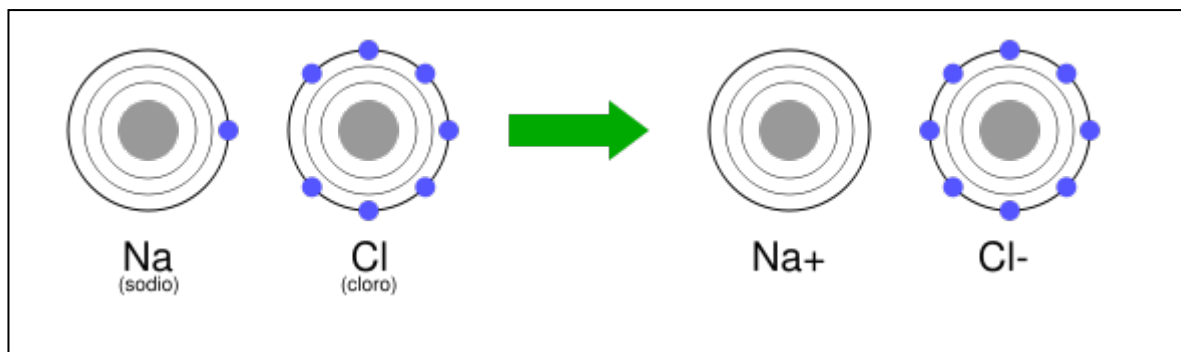


Figure 2.7. In this reaction sodium and chlorine are the reactants and sodium chloride is the product.

[http://commons.wikimedia.org/wiki/Image:Legame\\_ionico\\_fra\\_sodio\\_e\\_cloro.svg](http://commons.wikimedia.org/wiki/Image:Legame_ionico_fra_sodio_e_cloro.svg)

Some reactions release more energy than they absorb. These are known as exergonic reactions. Others absorb more energy than they produce. These are known as endergonic reactions.

Chemical reactions need a certain amount of energy to get started. The energy needed to break the bonds in a reaction is known as the activation energy.

Let's look at a theoretical reaction. Let's say that we would like to get reactants A and B together to form the product AB. We will put a little bit of A in a beaker and a little bit of B in the same beaker. There is a certain probability that A and B will get together. But let's say we would like to increase our chances. We could put more A and B in the beaker (increase the concentration of A and B) or we could heat up our beaker to get A and B moving around more. Both an increase in concentration and temperature will increase our chances of getting the product AB.

There is another way to get A and B together without raising the concentration or temperature. We could use a third substance known as a catalyst or enzyme. Enzymes work by virtue of their shapes. They act like templates or jigs that allow substances to either get together or break apart (fig. 2.8).

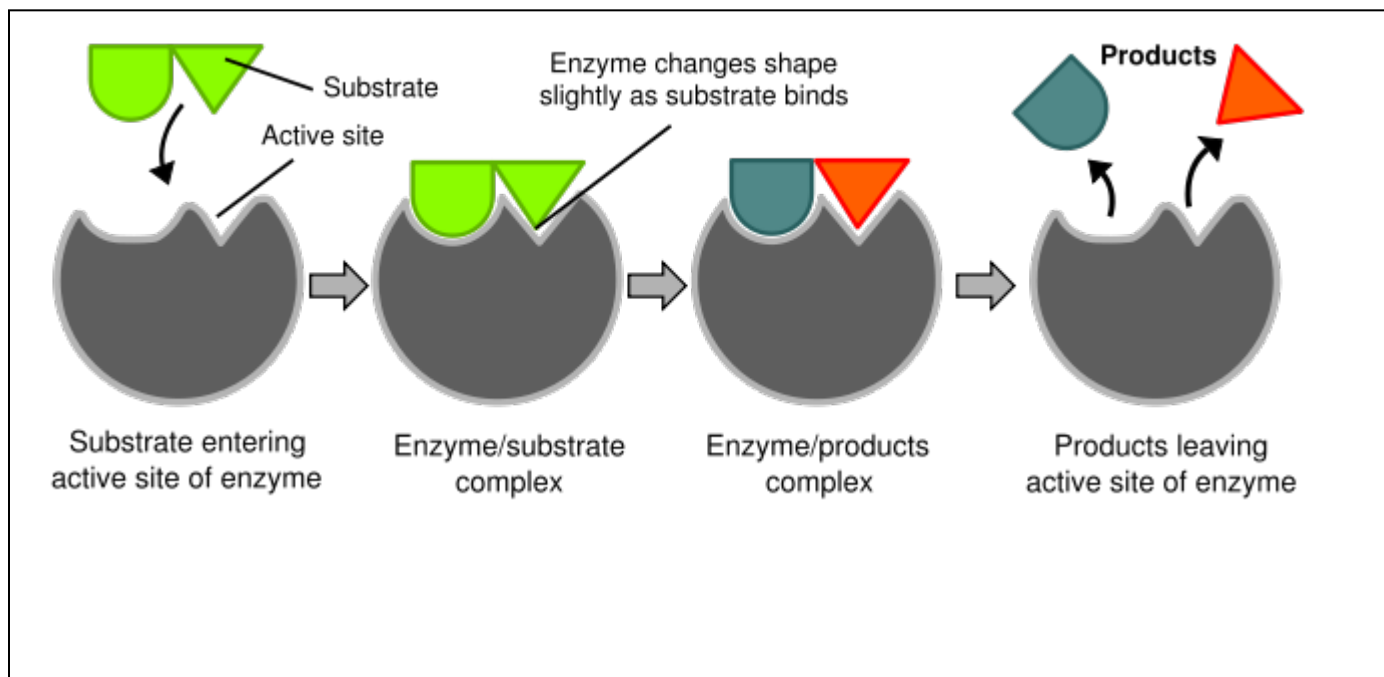


Figure 2.8. Enzymes work like templates. The site on the enzyme that connects to the reactants is known as the active site.

The area on the reactant that connects to the enzyme is known as the substrate.

[http://commons.wikimedia.org/wiki/Image:Induced\\_fit\\_diagram.svg](http://commons.wikimedia.org/wiki/Image:Induced_fit_diagram.svg)

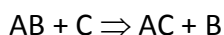
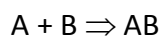
Enzymes can speed up chemical reactions by lowering the activation energy.

## Cellular Metabolism

Many chemical reactions occur in the human body. These reactions are controlled by enzymes. If we add all of the reactions of the body together we have what is called the metabolism of the body.

## Reaction Pathways

Chemical reactions occur in specific directions or pathways where the product of one reaction may influence another:



## Metabolic Reactions

There are 2 main types of metabolic reactions. Anabolic reactions produce larger molecules from smaller ones. Catabolic reactions break larger molecules down into smaller ones.

The human body uses anabolism for building substances for growth and repair. It also uses catabolism for breaking substances down and liberating energy.

We can build larger organic molecules from smaller molecules through a reaction called dehydration synthesis. Dehydration synthesis is an example of an anabolic reaction.

Dehydration means “to remove water”

Synthesis means “to assemble”

So we are assembling larger molecules by removing water.

Carbohydrates, fats and proteins are assembled via dehydration synthesis.

Dehydration synthesis

- Joins sugar molecules together to form glycogen (carbohydrate)
- Joins fatty acid molecules and glycerol together to form fat molecules
- Joins amino acids together to form peptides and eventually proteins.

So we can build the major organic molecules by the process called dehydration synthesis.

For example if we take 2 simple sugars such as glucose and put them together we form a more complex carbohydrate called a disaccharide (maltose).

And if we take a glycerol molecule and combine it with 3 fatty acid molecules we get a type of fat called a triglyceride.

And if we take a large number of amino acids and combine them we get a protein.

There is also catabolism.

Catabolism is the opposite of anabolism. It is the breaking down of larger molecules into smaller. For example a triglyceride can be broken down into glycerol and fatty acids.

The name of this catabolic reaction is called hydrolysis.

Hydro means to “add water”

Lysis means to “breakdown”

So now we have 2 reactions (dehydration synthesis and hydrolysis).

What causes reactions to go one way or the other?

Both dehydration synthesis and hydrolysis require use of specific *enzymes*.  
Some enzymes cause anabolism and some enzymes cause catabolism.

There are many different types of enzymes. Here are a few examples:

Lipase—catabolizes lipids

Protease—catabolizes proteins

Amylase—catabolizes carbohydrates

### **Co-factors/Co-enzymes**

Sometimes, an enzyme is not active until it combines with a non-protein molecule called a co-factor or co-enzyme.

Co-enzymes are usually vitamins.

### **Acids and Bases**

If a substance dissociates into hydrogen ions (positive) and negative ions (known as anions) it is called an acid.

If a substance dissociates into hydroxide ions (OH<sup>-</sup>) and positive ions it is called a base.

Some substances dissociate into anions and cations that are not hydrogen or hydroxide. These are known as salts.

A measure of the acidity or alkalinity is known as pH. If a solution has a lot of hydrogen ions it is known as acidic. If a solution has a lot of hydroxide ions it is known as alkaline (basic).

The pH scale is a logarithmic scale and ranges from 0 to 14. Between 0 and 7 is acidic with 7 being neutral. Between 7 and 14 is basic (fig. 2.9).

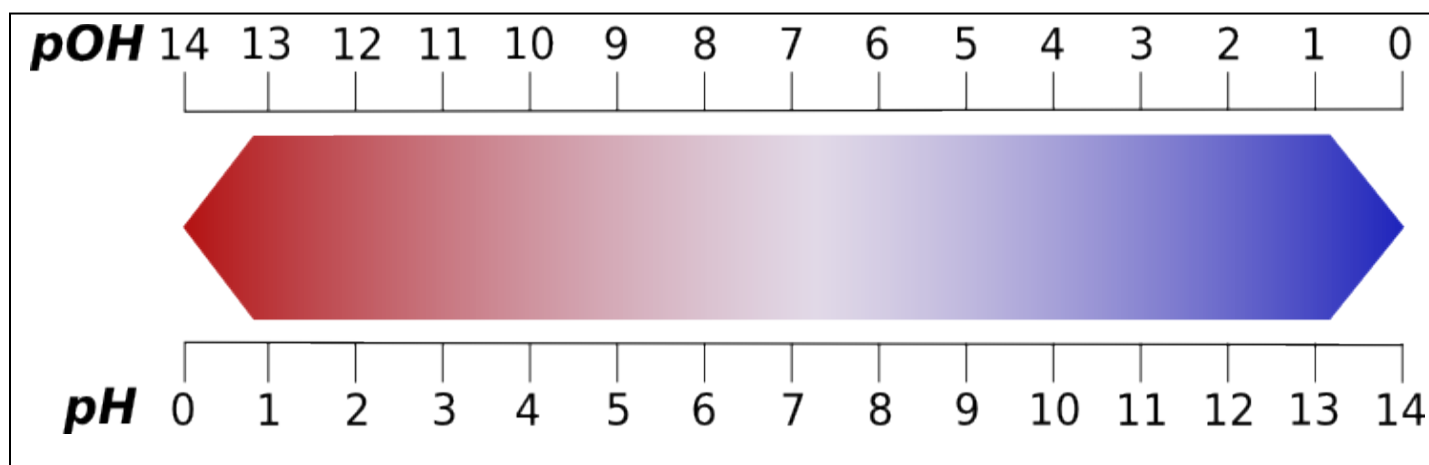


Figure 2.9. The pH scale ranges from 0 to 14.

<http://commons.wikimedia.org/wiki/Image:PHscalenolang.png>

Patrícia R.

## Carbohydrates, Lipids and Proteins

Carbohydrates are known as sugars and starches. Some examples of carbohydrates include monosaccharides, dissacharides and polysaccarides.

Monosaccharides are considered simple sugars (fructose, galactose and glucose). Examples are honey and fruits. Dissacharides are also simple sugars. Examples are milk sugar, cane sugar, beet sugar and molasses. Polysaccarides are considered complex sugars. Examples are starches from grains, vegetables and glycogen from meat. Cellulose is also a carbohydrate. Cellulose cannot be digested by human system and provides bulk to diet.

Glucose is also converted to glycogen in the liver by a process called glycogenesis and stored as a reserve. Excess glucose is stored as fat.

## Lipids

Lipids consist of fats, oils, phospholipids and cholesterol. A common dietary lipid is called a triglyceride. Triglycerides come from meat, eggs, milk, butter, palm, coconut oil. A triglyceride is made up of a glycerol molecule and 3 fatty acids.

Fats contain more than twice energy of carbohydrates or proteins. In order to use energy from fats, the fat molecules must first undergo hydrolysis.



Digestion breaks down triglycerides into fatty acids and glycerol. After absorption, they travel to bloodstream by way of the lymphatic system. Some lipids are not produced or synthesized by the liver and must be taken in by diet. These are known as essential fatty acids.

## **Proteins**

Proteins consist of chains of amino acids.

Proteins are used by body in:

- Enzymes
- Clotting factors
- Skin and hair keratins
- Elastin and collagen
- Plasma proteins
- Muscle components
- Hormones
- antibodies

Proteins also supply energy. However your body will use the carbohydrates and lipids before using proteins for energy.

## **Adenosine Triphosphate**

Next we will look at an energy molecule in the body known as adenosine triphosphate (ATP) (fig. 2.10).

ATP is a major source of energy for many physiological processes in the body. These include muscle contraction in skeletal muscles and the heart, production of nerve impulses and metabolism. ATP consists of an adenosine molecule, a ribose molecule and 3 phosphates. What is important about ATP is that it can store and release energy. Energy can be extracted from food molecules such as carbohydrates and then used to make ATP.

The energy that is available for use in the body is stored in ATP in the phosphate bond. This is sometimes called the high energy phosphate bond. The basic reaction that releases ATP goes like this:

ATP = ADP + Phosphate + Energy

Notice that ATP releases energy by giving up a phosphate. The product includes adenosine biphosphate or ADP.

Energy can also be stored in ATP by adding a phosphate to ADP. This process is known as phosphorylation.

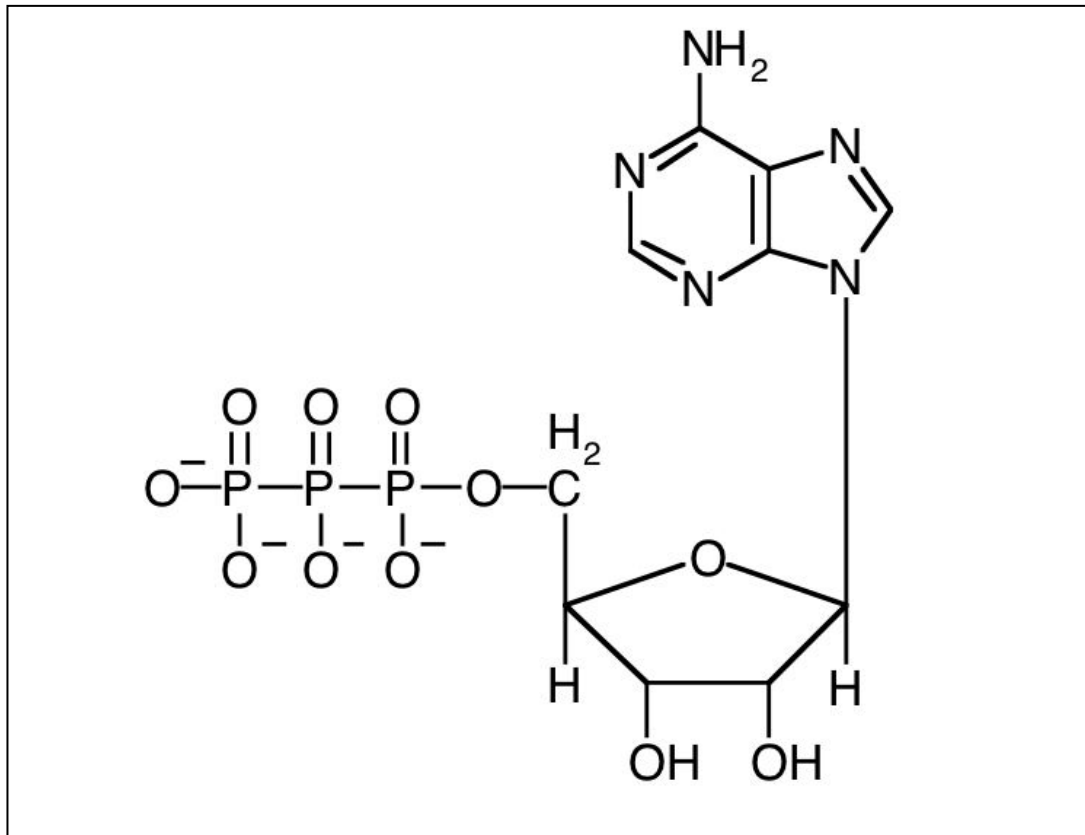


Figure 2.10. ATP contains an adenosine molecule (containing nitrogens), a ribose (ring molecule) and 3 phosphates.

[http://commons.wikimedia.org/wiki/File:ATP\\_structure\\_revised.png](http://commons.wikimedia.org/wiki/File:ATP_structure_revised.png)

## Review Questions Chapter 2

1. Which of the following structures is not part of an atom:
  - a. Proton
  - b. Neutron
  - c. Electron
  - d. Gravitron
  
2. Which of the following elements is commonly found in the human body:
  - a. Helium
  - b. Carbon
  - c. Rubidium
  - d. Palladium
  
3. The mass number represents:
  - a. The number of protons in the nucleus
  - b. The number of electrons orbiting the nucleus
  - c. The number of neutrons in the nucleus
  - d. The total protons and neutrons in an atom
  
4. An unequal number of protons and electrons in an atom produces:
  - a. Explosion
  - b. Electrolyte
  - c. Molecule
  - d. Mixture
  
5. Which type of chemical bond is characterized by a sharing of electrons:
  - a. Ionic
  - b. Covalent
  - c. Anionic
  - d. Hydrostatic
  
6. Sodium chloride (table salt) is held together by which type of bond:
  - a. Covalent
  - b. Ionic
  - c. Hydrostatic
  - d. Anionic
  
7. Water molecules can form weak bonds with other water molecules. These bonds are called:
  - a. Ionic
  - b. Hydrostatic
  - c. Polar covalent
  - d. Anionic

8. Which of the following is an example of an anabolic reaction in the body:
- a. Breaking down carbohydrates shortly after a meal
  - b. Digesting fats
  - c. Building proteins from amino acids
  - d. Releasing a phosphate from ATP
9. This reaction is characterized by removing a water to create a more complex molecule:
- a. Catabolism
  - b. Dehydration synthesis
  - c. Hydrolysis
  - d. Exothermic
10. Which of the following best describes the action of an enzyme:
- a. Raises the activation energy of a reaction
  - b. Combines with reactants to slow down a reaction
  - c. Works by virtue of its shape to speed up reactions
  - d. Causes exothermic reactions
11. Fructose is considered a:
- a. Dissacharide
  - b. Protein
  - c. Lipid
  - d. Monosaccharide
12. A common lipid known as a triglyceride can be broken down into:
- a. 3 glycerides
  - b. Monosaccharides
  - c. A glycerol and 3 fatty acids
  - d. Amino acids
13. Which of the following is a use for proteins:
- a. Store glycogen
  - b. Insulation and energy storage
  - c. Synthesis of hormones
  - d. Making disaccharides
14. ATP contains energy by virtue of its:
- a. Adenosine
  - b. Phosphate bond
  - c. Molecular structure
  - d. Shape

# Chapter 3

## Cells

## Cells

Cells are a major part of our bodies. In this section we will review the major parts of a cell and investigate cellular transport mechanisms.

The human body has something on the order of 10 trillion cells all working in harmony to keep us alive. Cells are fundamental building blocks for many of the tissues and organs of our bodies.

In this section we will primarily be concerned with studying cells that contain a nucleus known as eukaryotic cells.

The lowest level of organization was the atom followed by molecules and tissues. Then there were organelles and cells. So cells contain smaller structures called organelles. These are much like the organs in our bodies. The organelles have various functions that are important in maintaining the cell (fig. 3.1).

Let's look at a few of the major parts of the cell and its organelles.

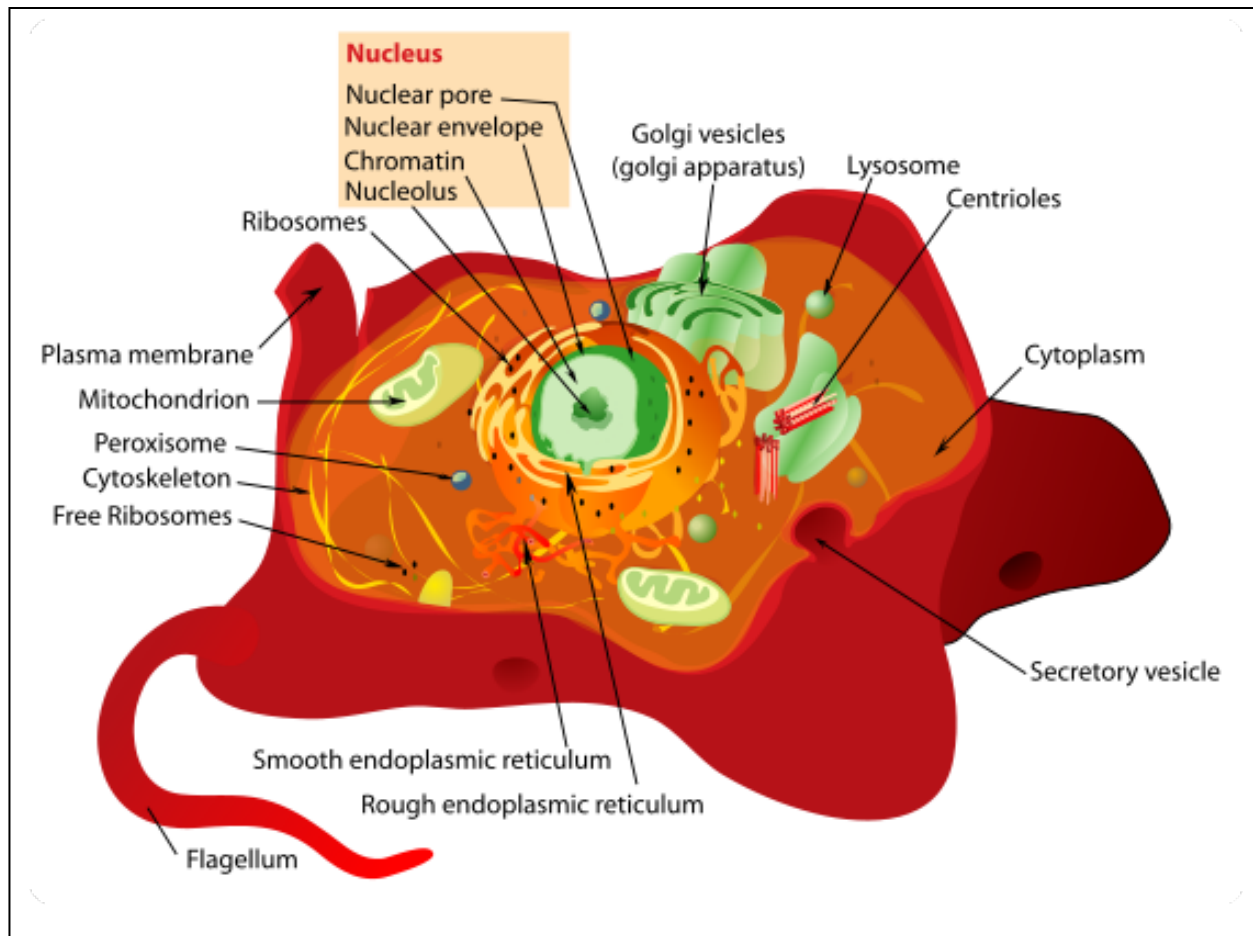


Figure 3.1. The cell contains a variety of organelles

[http://commons.wikimedia.org/wiki/Image:Animal\\_cell\\_structure\\_en.svg](http://commons.wikimedia.org/wiki/Image:Animal_cell_structure_en.svg)

## Cell Membrane

We will start by looking at the cell membrane.

The structure of the cell membrane has a lot to do with its function. The cell membrane is composed of molecules called phospholipids (fig. 3.2).

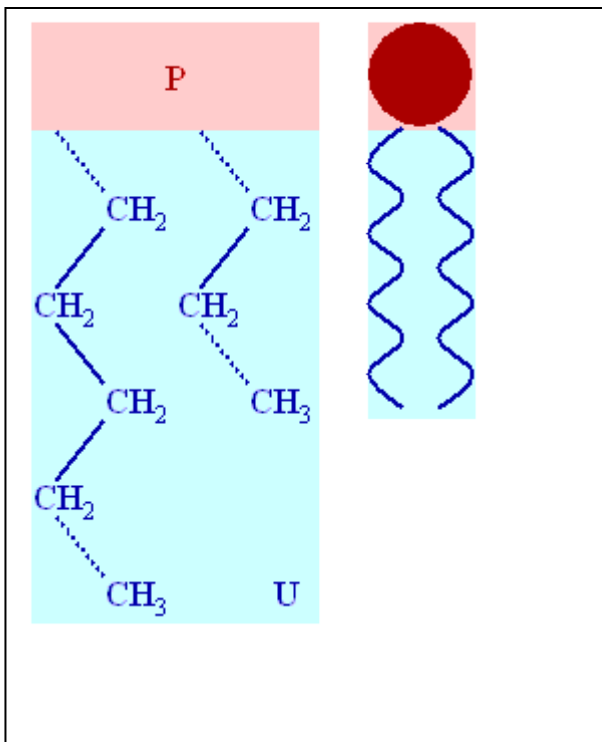


Figure 3.2. Phospholipids contain a phosphate head and a lipid tail.

[http://commons.wikimedia.org/wiki/Image:Phospholipid\\_structure.png](http://commons.wikimedia.org/wiki/Image:Phospholipid_structure.png)

The phosphate head of the phospholipid likes water so it is called hydrophilic while the lipid tail is called hydrophobic or “water hating.” Because of the water loving and hating characteristics of the heads and tails, phospholipids arrange themselves in what is known as a bilayer (fig. 3.3).



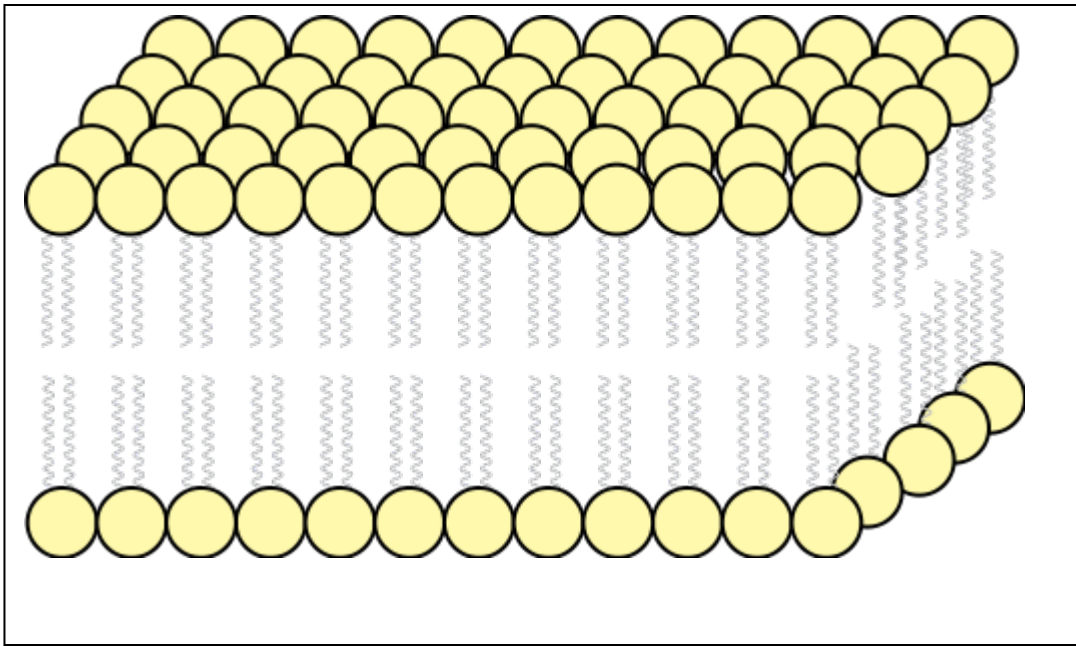


Figure 3.3. Phospholipids arrange themselves into a bilayer.

[http://commons.wikimedia.org/wiki/Image:Fluid\\_Mosaic.svg](http://commons.wikimedia.org/wiki/Image:Fluid_Mosaic.svg)

Jerome Walker

The cell membrane also lets certain substances in or out. We say that it is selectively permeable. For example, lipid soluble substances can pass right through the cell membrane. Examples of lipid soluble substances include oxygen, carbon dioxide and steroids.

Water soluble substances cannot pass through the cell membrane and require carrier proteins in order to get in or out of the cell.

The cell membrane also contains a number of proteins. Some of these proteins are imbedded on the surface of the cell and some go all the way through the cell membrane.

Some proteins act as channels to allow substances to pass through the membrane. Others act as receptors that receive information carried by proteins. Still others act as connection points for other cells to attach. These are known as intercellular junctions.

Let's look at some of the other parts of a cell.

## Cytoplasm

The cytoplasm or cytosol is the fluid inside the cell. It contains a network of channels and support structures called the cytoskeleton. This is much like the skeleton in your body.

## Endoplasmic Reticulum

Another important organelle is the endoplasmic reticulum (fig. 3.4). The endoplasmic reticulum comes in two varieties; rough and smooth. Rough endoplasmic reticulum is studded with ribosomes. The ribosomes function in making proteins (protein synthesis). Smooth endoplasmic reticulum does not contain ribosomes. It functions in making lipids (lipid synthesis). Ribosomes contain RNA, protein and the enzymes needed for protein synthesis.

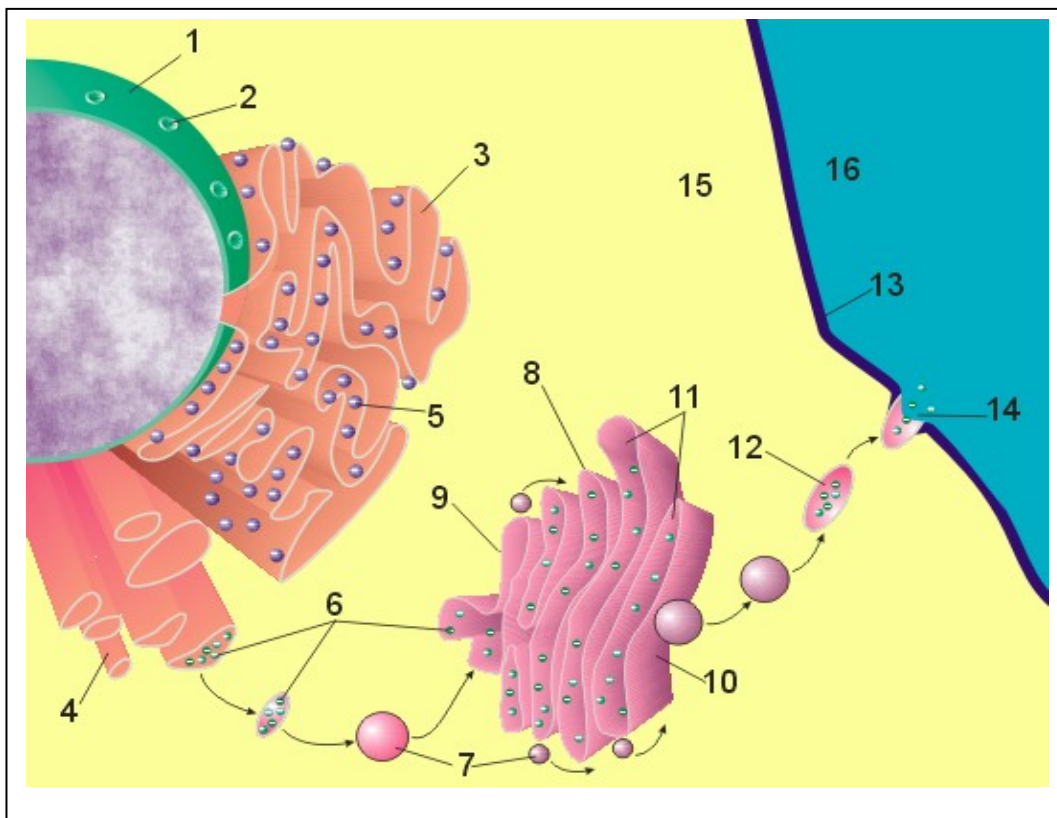


Figure 3.4. The endoplasmic reticulum (3) contains ribosomes (5) that function in making proteins.

The Golgi apparatus (11) then packages the proteins in vesicles (12).

[http://commons.wikimedia.org/wiki/Image:Nucleus\\_ER\\_golgi.jpg](http://commons.wikimedia.org/wiki/Image:Nucleus_ER_golgi.jpg)

After the endoplasmic reticulum synthesizes the proteins they need to be packed up and shipped out to other parts of the cell or to other cells. That's where the Golgi apparatus takes over. The Golgi apparatus packs up the proteins.

Besides the vesicles from the Golgi apparatus, there are other vesicles containing enzymes for breaking up debris in the cell. These are called lysosomes.

### Mitochondrion

The next organelle we will investigate is very important because it produces energy that is needed throughout the body. It is known as the “powerhouse” of the cell and is called the mitochondrion (fig. 3.5). The mitochondrion takes in fuel such as glucose and extracts the energy from it to make ATP. The inner portion of the mitochondrion is folded into shelves called cristae. These are studded with enzymes needed for the many chemical reactions used to make ATP.

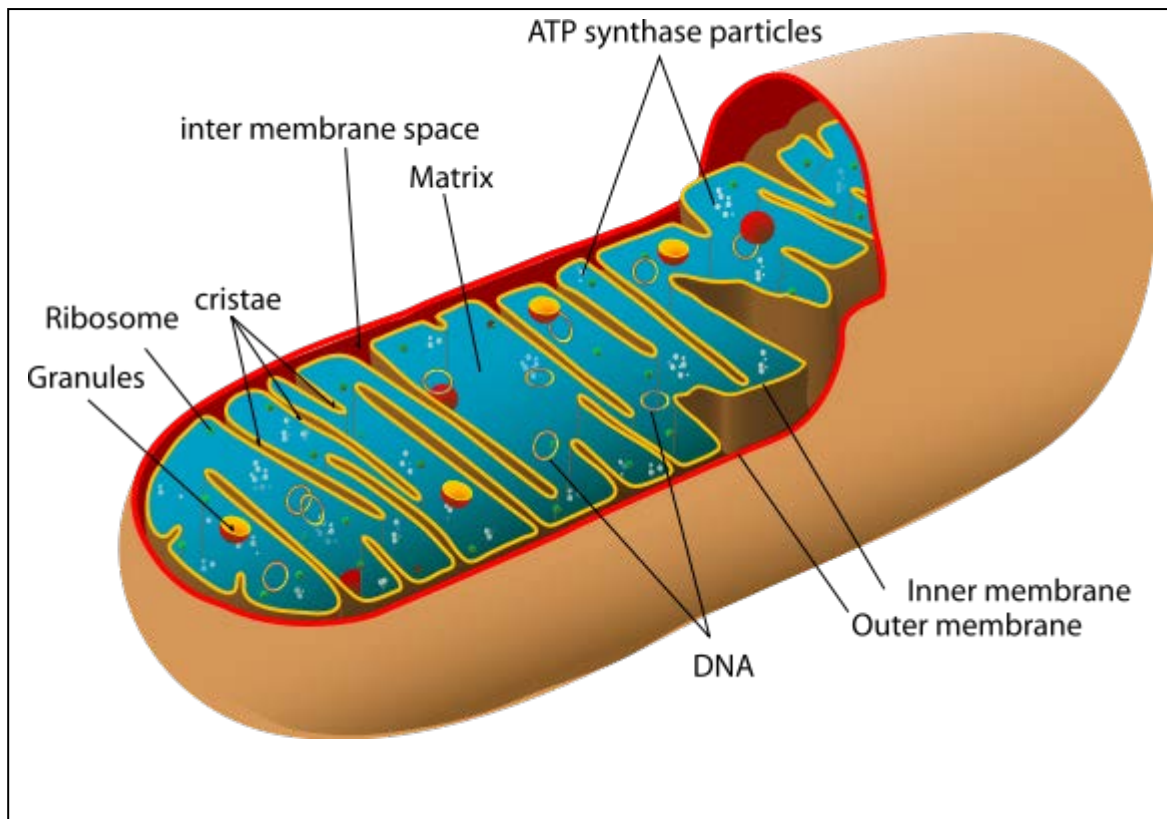


Figure 3.5. The mitochondrion.

[http://commons.wikimedia.org/wiki/Image:Diagram\\_of\\_an\\_animal\\_mitochondrion.svg](http://commons.wikimedia.org/wiki/Image:Diagram_of_an_animal_mitochondrion.svg)

## Centrosome

The centrosome is important in producing a structure called the mitotic spindle that helps to separate the chromosomes during mitosis. The centrosome consists of 2 hollow cylinders called centrioles. The centrioles are constructed from tubular proteins (fig. 3.6).

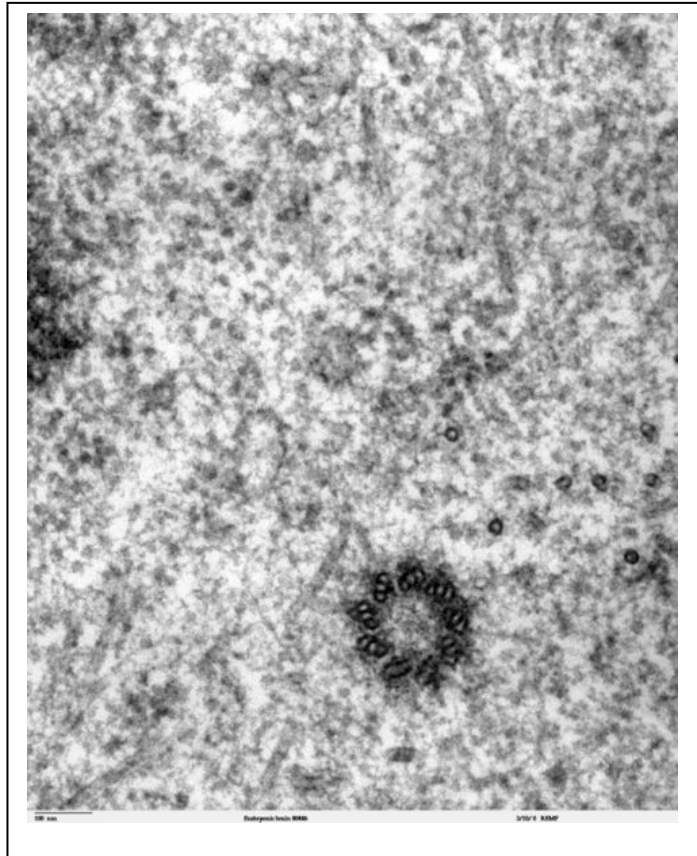


Figure 3.6. This is a picture of a centriole. Notice the circular structure in the lower right-hand corner. The centriole consists of tubular proteins.

[http://commons.wikimedia.org/wiki/Image:Spindle\\_centriole\\_-\\_embryonic\\_brain\\_mouse\\_-\\_TEM.jpg](http://commons.wikimedia.org/wiki/Image:Spindle_centriole_-_embryonic_brain_mouse_-_TEM.jpg)

## Cilia and Flagella

The cell contains other protein structures called cilia and flagella. Cilia and flagella are important in cellular movements (fig. 3.7).

Cilia are protein structures that move substances across cells. A flagellum is a long protein structure that moves the cell. Cells may have many cilia but will only have one flagellum.

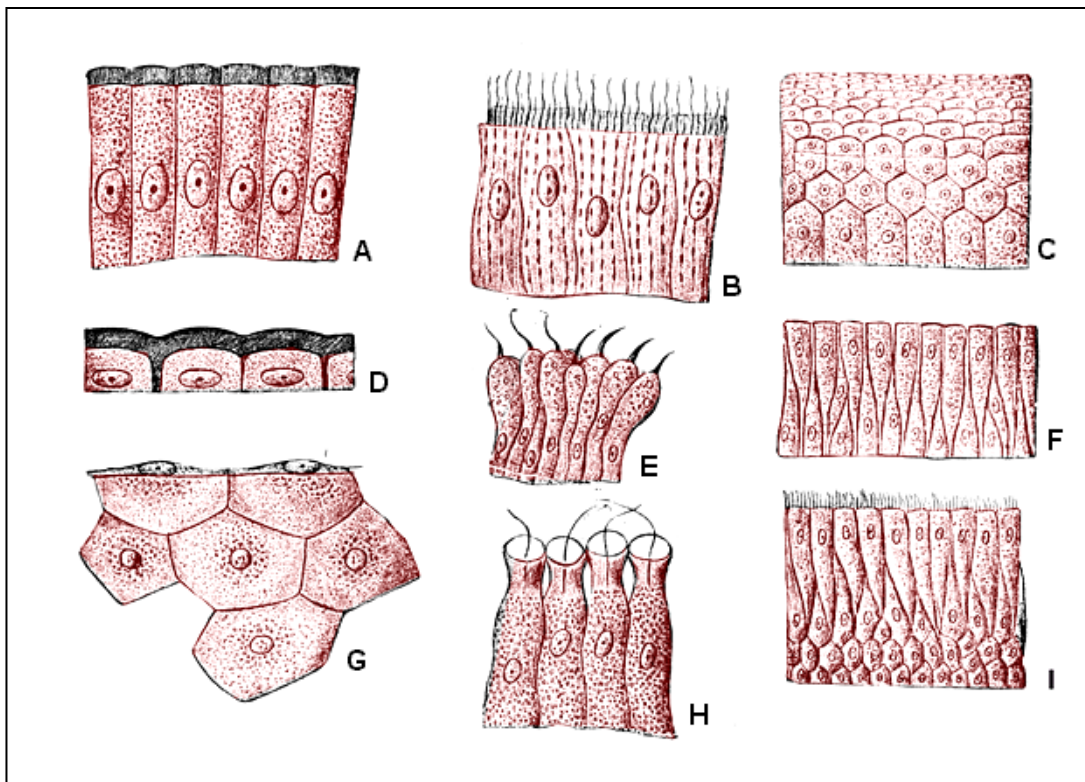


Figure 3.7. Notice the hair-like structures on B, E, H and I. These are cilia. Cilia can move substances along the surface of cells.

[http://commons.wikimedia.org/wiki/Image:Tkanka\\_nablonkowa.png](http://commons.wikimedia.org/wiki/Image:Tkanka_nablonkowa.png)



## Microfilaments and Microtubules

Microfilaments are solid protein structures that form the cytoskeleton to support the cell. Microtubules are hollow and can transport substances around the cell (fig. 3.8).

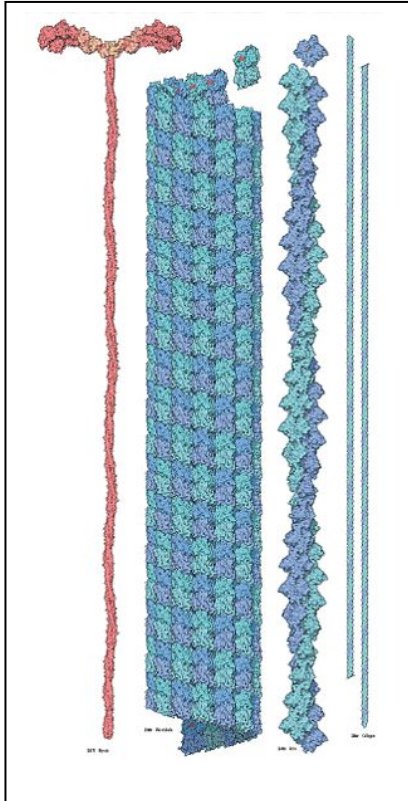


Figure 3.8. Here is a picture of the microfilament called myosin. Myosin is found in muscles.

[http://commons.wikimedia.org/wiki/Image:Myosin\\_Microtubule\\_Actin\\_Collagen.jpg](http://commons.wikimedia.org/wiki/Image:Myosin_Microtubule_Actin_Collagen.jpg)

## Nucleus

The nucleus contains the DNA of the cell. It is surrounded by a membrane much like the cell membrane. Inside the nucleus is the nucleolus which contains RNA and proteins. This is where ribosomes are synthesized (fig. 3.9).

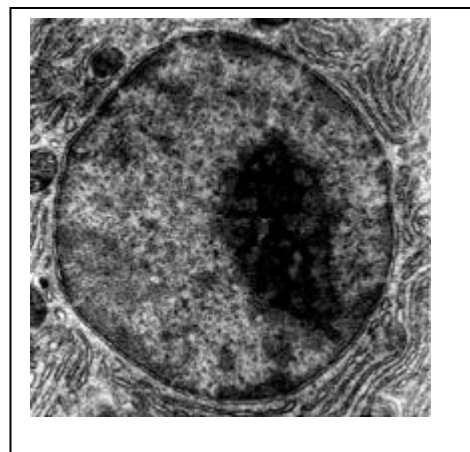


Figure 3.9. The nucleus. The dark spot on the right side is the nucleolus. The nucleolus is the site of ribosome production.

<http://commons.wikimedia.org/wiki/Image:Nucleus%26Nucleolus.gif>

## Substance Transport in Cells

Now that we have been introduced to some of the components of the cell, let's look at how substances move in and out of the cell.

Remember that the cell membrane is made up of phospholipids. Since the membrane is composed of phospholipids, then lipid soluble substances can move across the membrane. Remember some examples of lipid soluble substances include oxygen, carbon dioxide and steroids.

But what pushes or pulls a substance across the membrane?

### Diffusion

Diffusion is the movement of substances from an area of higher concentration toward an area of lower concentration until reaching equilibrium. The force that drives diffusion comes from differences in concentration called concentration gradients.

The actual mechanism behind diffusion is quite complex and has to do with the second law of thermodynamics. This law states that in any given system there must be an increase in entropy. To explain this in simpler terms, substances tend to move from an organized state (concentrated state) to a more disorganized state (less concentrated state).

The process of diffusion can be illustrated by making a glass of Kool Aide. When the powder first hits the water it is in higher concentration than its surrounding fluid. The powder will dissolve and then begin to distribute evenly throughout the glass of water. The powder is said to move from an area of higher concentration to lower concentration until it is equally distributed throughout the glass (fig. 3.10).

Another example is with an aerosol spray. Let's say I stood in front of the class and sprayed a room freshener into the air. The particles would eventually distribute evenly throughout the room so that even the students in the back of the room could smell it.



Figure 3.10. A drop of dye evenly disperses throughout a glass of water. This is an example of diffusion.

<http://commons.wikimedia.org/wiki/Image:Diffusion.gif>

Other examples of lipid soluble substances include alcohols, fatty acids and lipid soluble drugs.

Substances can diffuse at different rates. The rate of diffusion depends on a number of factors. These include:

- Molecule size—smaller molecules diffuse faster than larger molecules.
- Size of concentration gradient—the larger the difference in concentration the faster substances will diffuse.



- Temperature—because diffusion relies on the movement of molecules, higher temperatures will cause more movement and speed up diffusion. For example, substances will diffuse faster at body temperature than room temperature.
- Distance—the shorter the distance, the faster substances will diffuse.
- Electrical forces—Cells generally carry a negative charge on the inside. Negative charges will attract positive electrolytes and repel negative ones. This can speed up or slow down the rate of diffusion.

## Facilitated Diffusion

Now we know how lipid soluble substances pass through cell membranes powered by diffusion but how do non-lipid soluble substances get in and out of the cell?

The answer has to do with what is known as facilitated diffusion (fig. 3.11).

Cell membranes contain proteins. Some of these proteins go all the way through the membrane and act as channels for specific substances. Examples of substances that move via facilitated diffusion include sodium, potassium, and chloride.

The force that moves substances in facilitative diffusion is the same as diffusion. That is, the difference in concentration or concentration gradient. Again, substances still move from areas of higher to lower concentration but this time they move through a protein channel.

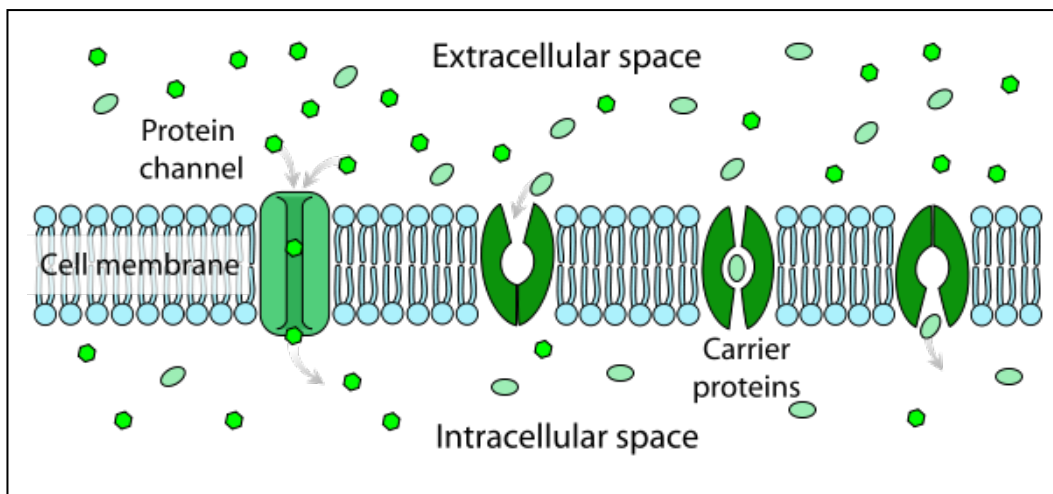


Figure 3.11. Carrier proteins allow non-lipid soluble substances to move in and out of cells in channel-mediated diffusion.

[http://commons.wikimedia.org/wiki/Image:Scheme\\_facilitated\\_diffusion\\_in\\_cell\\_membrane-en.svg](http://commons.wikimedia.org/wiki/Image:Scheme_facilitated_diffusion_in_cell_membrane-en.svg)

Substances moving in and out of cells by facilitated diffusion must bind to receptors on the protein channel. Once they bind, the protein changes its shape allowing the substance in or out of the cell.

Since proteins only have so many receptors, once the receptors become saturated there cannot be movement of any additional substances. Therefore in some cases a larger concentration gradient will not move substances at a faster rate (unlike diffusion). The rate of diffusion then partially depends on the saturation of the receptors on the protein channel.

One example of a substance transported into the cell via facilitated diffusion is glucose. Glucose is used by cells to make ATP, an important energy molecule in the body. Muscle cells require glucose to make ATP for muscle contraction. In order for glucose to move into a muscle cell it not only needs to connect to a receptor on the protein channel but another hormone called insulin also needs to connect to a special insulin receptor on the protein.

In some cases the insulin receptors become resistant to insulin causing blood glucose levels to rise. This occurs in what is known as insulin resistant diabetes. We will learn more about diabetes in a later chapter.

## **Osmosis**

Water moves within the human body across a variety of membranes. The membranes are called semipermeable because they only allow water to move across them, not solute. The movement of water across a semipermeable membrane has a special name; osmosis.

Water moves like every other substance in our universe, from an area of higher concentration to lower concentration. However, we typically do not talk about concentration in terms of water. We usually talk about concentration in terms of solute.

So you could think of osmosis in 2 ways:

1. Water moves across a semipermeable membrane from a higher area of concentration of water to a lower concentration of water.
2. Water moves across a semipermeable membrane from an area of lower concentration of solute to an area of higher concentration of solute.

One simple way to remember osmosis is the phrase “water follows salt” to mean that water always moves toward an area of higher concentration of solute. Here is a simple osmosis experiment (fig. 3.12).

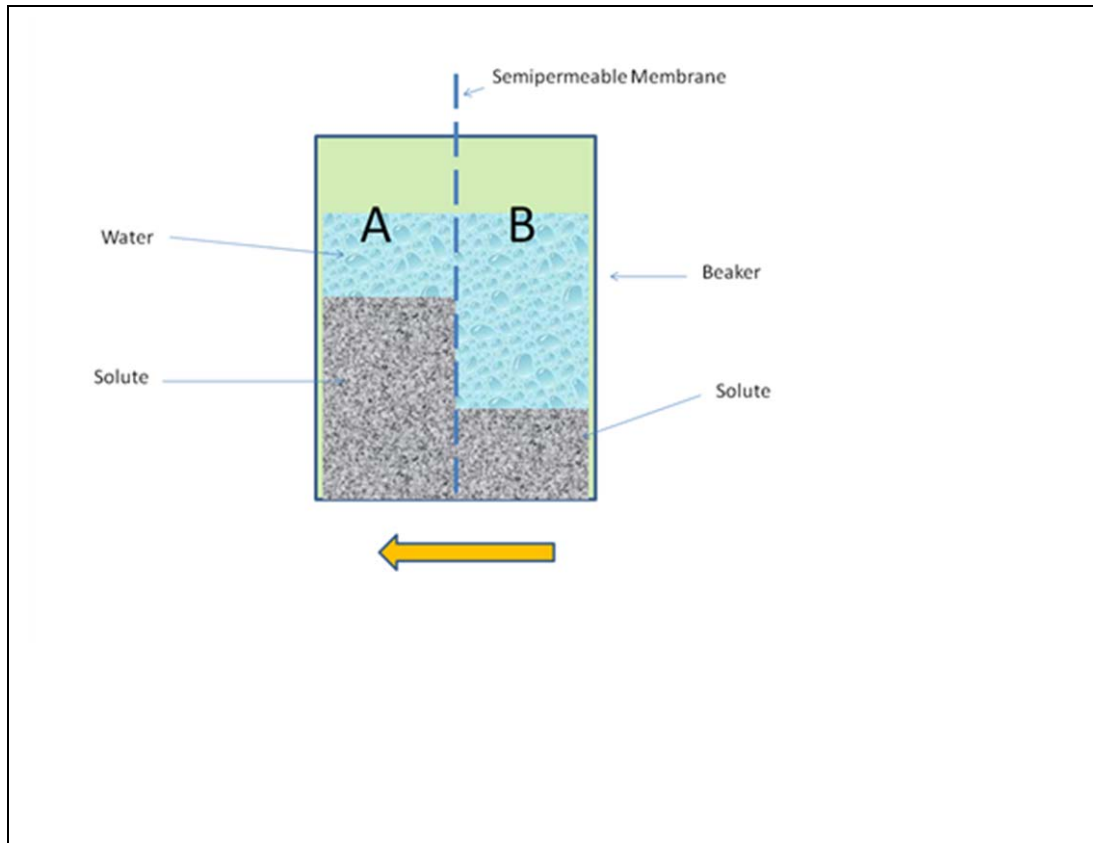


Figure 3.12. Water moves toward an area of higher solute concentration in osmosis.

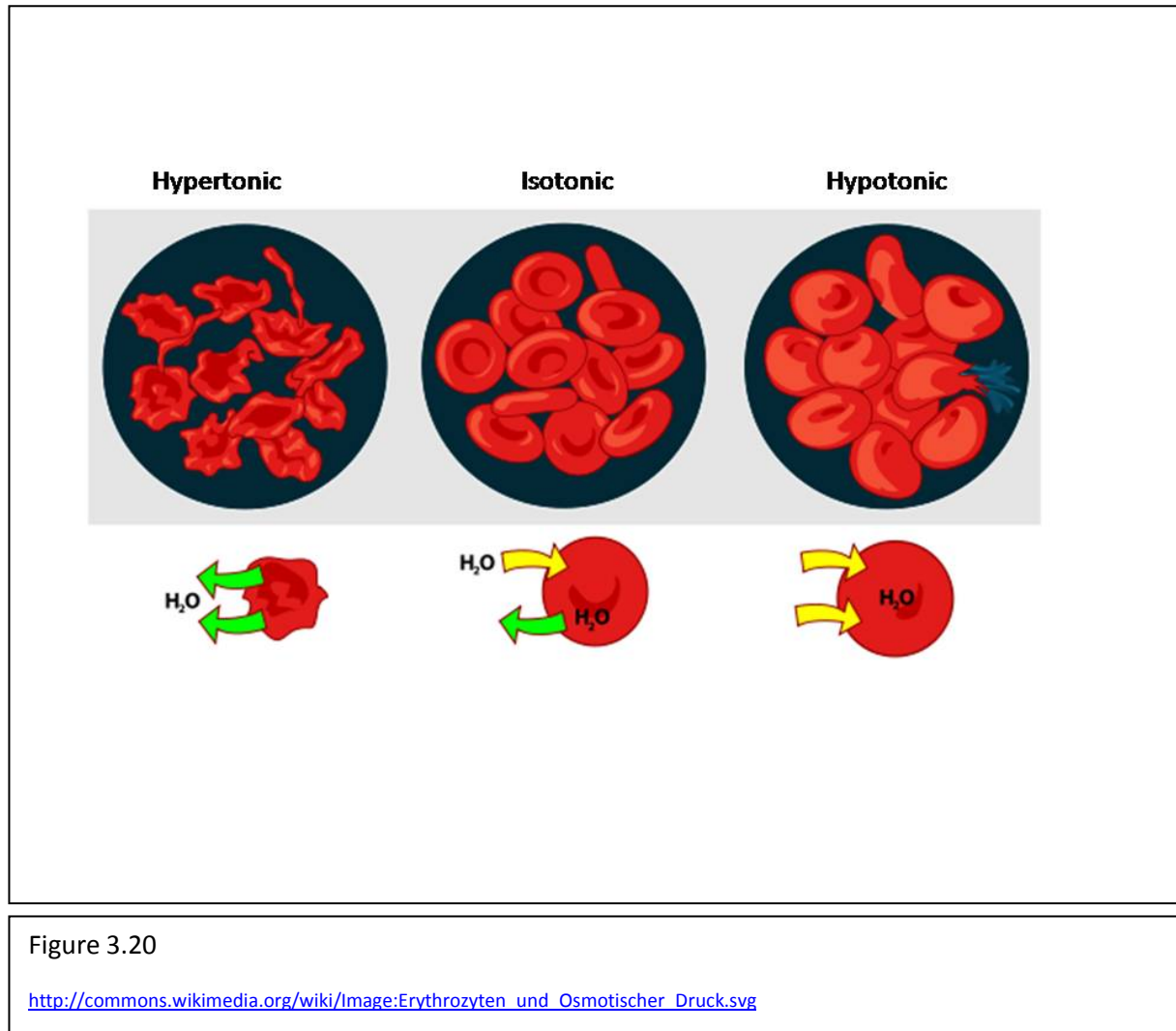
### Isotonic/Hypotonic/Hypertonic Solutions

The force exhibited by osmosis is called osmotic pressure. This pressure is related to the solute concentration of the solution. In chemistry we describe concentration in terms of osmolarity. However, in physiology when we are concerned with concentration with regard to cells we use the term tonicity. Tonicity is related to the human cell whereby osmolarity is the number of osmoles per liter. Osmolarity depends on the number of particles of solute. For example, one mole of glucose in water would equate to 1 osmole since glucose remains as 1 molecule in water. However, one mole of sodium chloride would equate to 2 osmoles because sodium chloride dissociates in water to form 2 particles.

If a solution has the same osmolarity as body fluids we say the solution is isotonic. The human body's osmolarity is close to .30 osmoles or 300 milliosmoles.

If a solution is less concentrated than body fluids we say the solution is hypotonic. And if the solution is more concentrated than body fluids we say the solution is hypertonic. Tonicity is important when it comes to introducing solutions to the human body. Let's see why.

Here is another short experiment regarding solutions (fig 3.20).



In the first image on the left a red blood cell is placed in a hypertonic solution. Since the solution is more concentrated than the red blood cell, the cell shrivels up or crenates. In the middle picture the red blood cells are placed in an isotonic solution. Since the tonicity is equal nothing happens to the cell. In the final picture on the right the cells are placed in a hypotonic solution. Since there is more concentration inside the cells water flows in and the cells swell (and can burst).

## Filtration

Sometimes cells arrange themselves in thin layers and substances can move between the cells. These layers or membranes work the same way as filters. Filters sort substances based on size. Smaller substances move through the spaces and larger substances do not. Think of a coffee filter. The filter has very small holes that only allow the water to move through. The grounds are too large to fit through the holes.

The force that drives filtration is fluid pressure. This pressure is also known as hydrostatic pressure. In order to move substances through a filter they must move from an area of higher pressure to lower pressure.

There are many examples of filters in the body. These include the capillaries and kidneys.

## Active Transport

So far we have seen how substances move down their respective concentration gradients in diffusion and facilitative diffusion. But what if a substance needs to be moved *against* its concentration gradient?

In active transport substances are moved against their concentration gradients by carrier proteins. However, there is an energy cost to be paid for this action. So the carrier proteins use ATP as an energy source.

An example of an active transport protein is the sodium potassium pump (fig. 3.21). Normally there is more sodium outside of the cell than in so sodium would move from outside to in.

Also, there is usually more potassium inside the cell than out, so potassium would follow its concentration gradient and move out of the cell.

However, we want to move these molecules against their concentration gradients. So this can be done but energy must be used to do so.

Energy is used by the pump in the form of ATP.

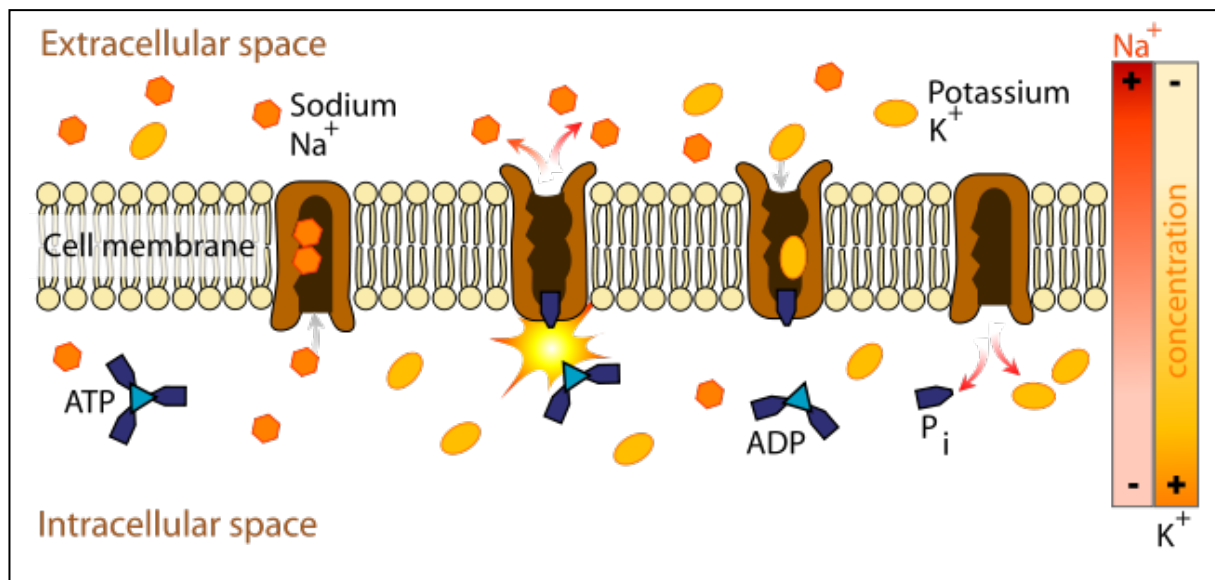


Figure 3.21. The sodium-potassium pump. Sodium moves out of the cell against its gradient while potassium moves into the cell (also against its gradient). The carrier protein must use energy in the form of ATP. One ATP moves 3 sodiums out of the cell and 2 potassiums in.

[http://commons.wikimedia.org/wiki/Image:Scheme\\_sodium-potassium\\_pump-en.svg](http://commons.wikimedia.org/wiki/Image:Scheme_sodium-potassium_pump-en.svg)

The sodium potassium pump is vital to the human body and works to maintain and establish the concentration gradients that keep us alive.

### Other Transport Mechanisms

Other ways that substances can move in and out of cells include cotransport, exocytosis and endocytosis (fig. 3.22).

In endocytosis substances enter cells via vesicles. There are 3 types of endocytosis. They include phagocytosis, pinocytosis and receptor-mediated endocytosis. All involve the cell membrane wrapping around and engulfing a vesicle.

In pinocytosis a cell can take in a small droplet of fluid.

In phagocytosis the cell takes in a solid then use a lysosome to break down the solid.

In receptor-mediated endocytosis substances bind to receptors on the cell membrane. The membrane responds by forming a vesicle and taking the substance into the cell.

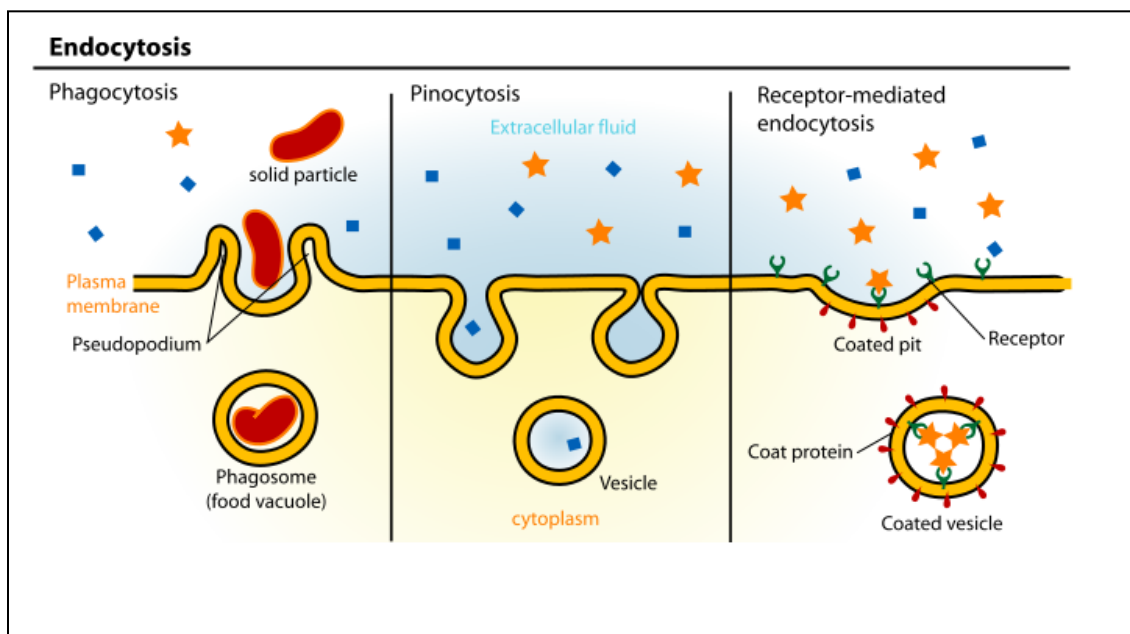


Figure 3.22. In phagocytosis the cell reaches out and engulfs a particle bringing it into the cell for destruction. The cell brings in fluid via pinocytosis. Substances attach to receptors on the cell membrane in receptor-mediated endocytosis.

[http://commons.wikimedia.org/wiki/Image:Endocytosis\\_types.svg](http://commons.wikimedia.org/wiki/Image:Endocytosis_types.svg)

Substances can exit cells by same method (exocytosis).

## Mitosis

We all begin as one cell. This one cell becomes many (trillions) cells by dividing in a process known as mitosis. In mitosis the genetic material (DNA) is carried on to daughter cells.

Some cells in the body do not divide. Once they are lost they must be replenished through differentiation of stem cells. Other cells divide all the time.

Examples of cells that do not divide are nerve cells known as neurons and red blood cells.

An example of a cell that divides is the epithelial cell located in the skin and digestive system.

Cells that undergo mitosis follow a cycle of rest followed by cell division. During the rest phase the cell gets ready to divide. The rest phase is called interphase.

During interphase the cell carries out processes of growth, metabolism and DNA replication.

There is another process of cell division known as meiosis in which the new cells have only one half of the DNA of the original cell. We will investigate meiosis when we cover the reproductive system.

## **Interphase**

Interphase is preparatory phase for the cell undergoing mitosis. Interphase consists of 3 subphases known as G1, S and G2.

During the G1 phase the cell produces copies of its organelles such as the mitochondria, endoplasmic reticuli, Golgi, and ribosomes. The centrioles begin to replicate. Some cells complete G1 in 8-12 hours.

Next the cell enters the S phase. During the S phase the cell replicates its DNA and ends up with 2 sets of identical chromosomes. DNA replication occurs during the S phase of interphase. During replication the 2 strands of DNA unwind and separate at the hydrogen bonds (between the bases). A new sequence of nucleotides then attaches to each individual strand with new hydrogen bonds forming. Some cells complete the S phase in 6-8 hours.

Finally the cell enters the G2 phase. The centrioles complete their replication and complete protein synthesis. Some cells complete the G2 phase in 2-5 hours. When the cell is finished it enters the M or mitosis phase.

## **Prophase**

Generally the DNA of the cell is in the form of chromatin which is loosely organized. During prophase the genetic material forms tightly coiled chromosomes. Remember that there are 2 sets of identical chromosomes. Each set is bound together by a central structure called a centromere (fig. 3.23).

During prophase the nuclear membrane begins to break up and disappear. The nucleolus also disappears as the chromosomes form. A system of microtubules form the mitotic spindle at opposite ends of the cell. The centromere is surrounded by a protein structure called a kinetochore. The spindle fibers attach themselves to the kinetochores.

## **Metaphase**

During metaphase the chromosomes all line up in the center of the cell. This area is called the metaphase plate (fig. 3.24).

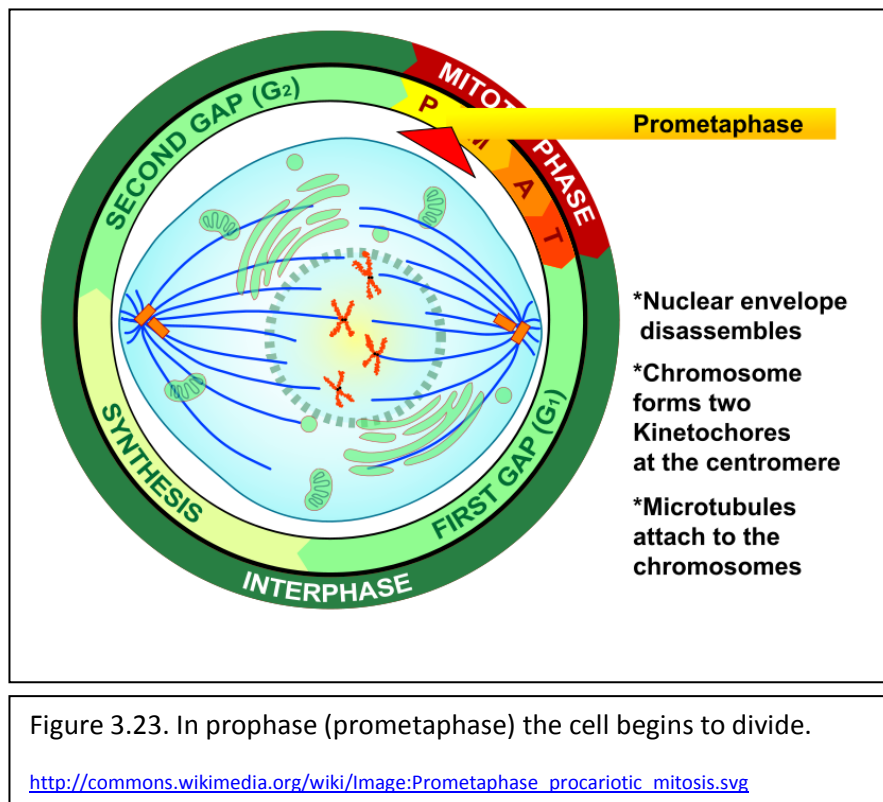


## Anaphase

During anaphase the spindle fibers shorten and the centromeres divide separating the pair of chromosomes. The chromosomes move to opposite sides of the cell (fig. 3.25).

## Telophase

The final stage of mitosis is telophase. The nuclear membrane and nucleolus begin to reappear. The mitotic spindle breaks up and the chromosomes uncoil. Two daughter cells are now present (fig. 3.26).



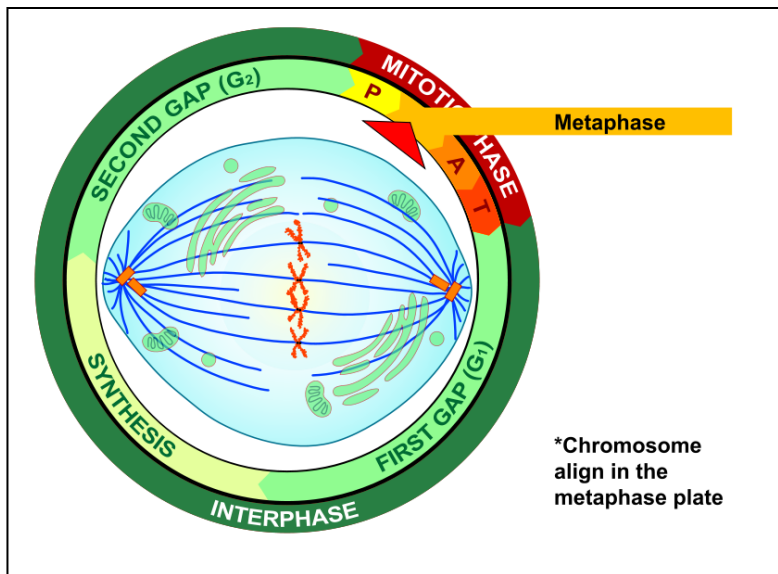


Figure 3.24. Metaphase.

[http://commons.wikimedia.org/wiki/Image:Metaphase\\_procarotic\\_mitosis.svg](http://commons.wikimedia.org/wiki/Image:Metaphase_procarotic_mitosis.svg)

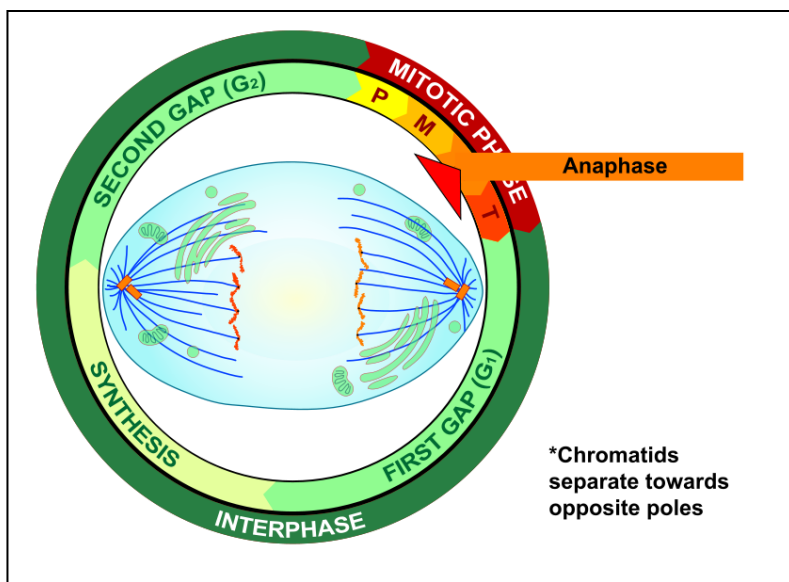


Figure 3.25. Anaphase.

[http://commons.wikimedia.org/wiki/Image:Anaphase\\_procarotic\\_mitosis.svg](http://commons.wikimedia.org/wiki/Image:Anaphase_procarotic_mitosis.svg)

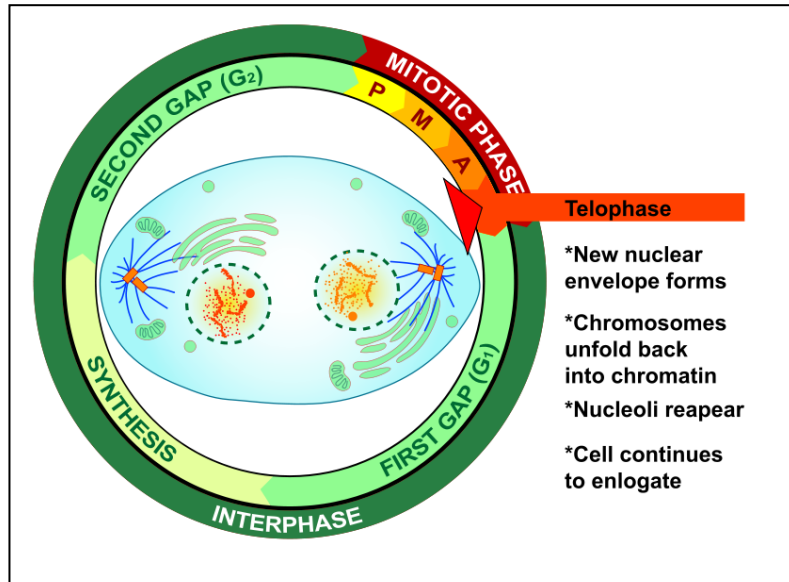


Figure 3.26. Telophase.

[http://commons.wikimedia.org/wiki/Image:Telophase\\_procarotic\\_mitosis.svg](http://commons.wikimedia.org/wiki/Image:Telophase_procarotic_mitosis.svg)

## **Protein Synthesis**

### **Transcription and Translation**

Proteins are vital information carriers in the body. Proteins consist of long chains of building blocks called amino acids. Proteins carry information by virtue of the sequence of amino acids.

The information flows from DNA to RNA to protein (fig. 3.27). This process is known as the central dogma of biology. The way information flows is by two processes called transcription and translation. In general, the information is transcribed from DNA to RNA then translated to proteins.

### **DNA Structure**

DNA consists of 3 main parts:

1. 5 carbon sugar (called a deoxyribose sugar)
2. Phosphate
3. Nitrogen containing base

Each 3-part structure is called a nucleotide. The nucleotides connect via the phosphates to form 2 strands much like a ladder. The 2 strands of nucleotides wrap around each other to form a double helix.

There are 4 bases in DNA:

1. Adenine (A)
2. Cytosine (C)
3. Thymine (T)
4. Guanine (G)

The bases can form pairs. One base of the pair “fits” into the other. We say the bases are complimentary. Cytosine pairs with guanine and adenine pairs with thymine (fig. 3.29).

The information in DNA is encoded in the sequence of bases. Each 3 base sequence along a strand of DNA is called a triplet code and can code for a specific amino acid. There are also start (promoter) and stop (terminator) codes (fig. 3.28).

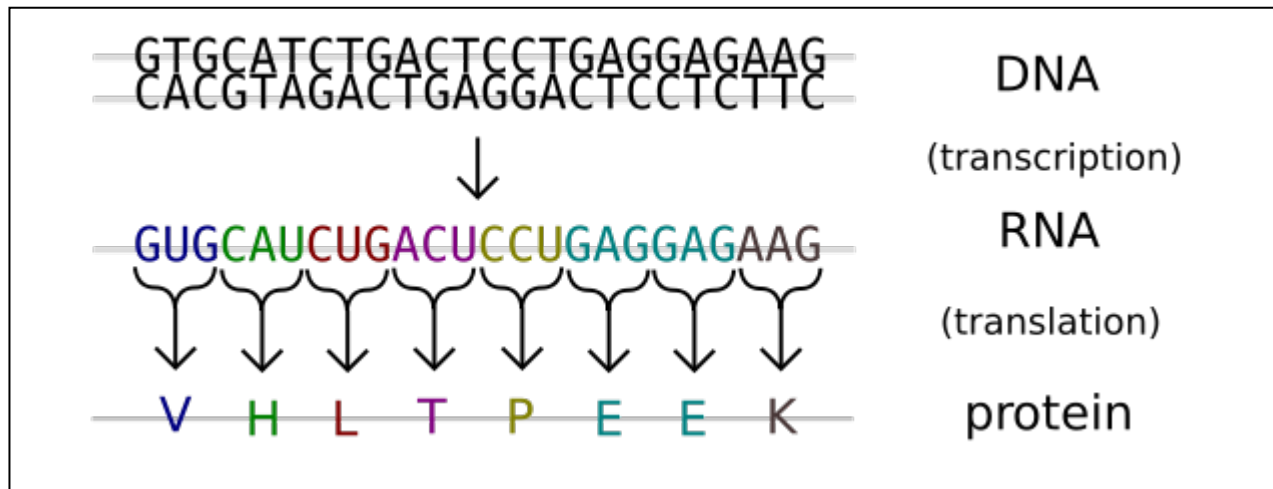


Figure 3.27. Information flows from DNA (transcription) to RNA (translation) to Protein. Each 3-base sequence codes for an amino acid.

[http://commons.wikimedia.org/wiki/Image:Genetic\\_code.svg](http://commons.wikimedia.org/wiki/Image:Genetic_code.svg)

Madeleine Price Ball

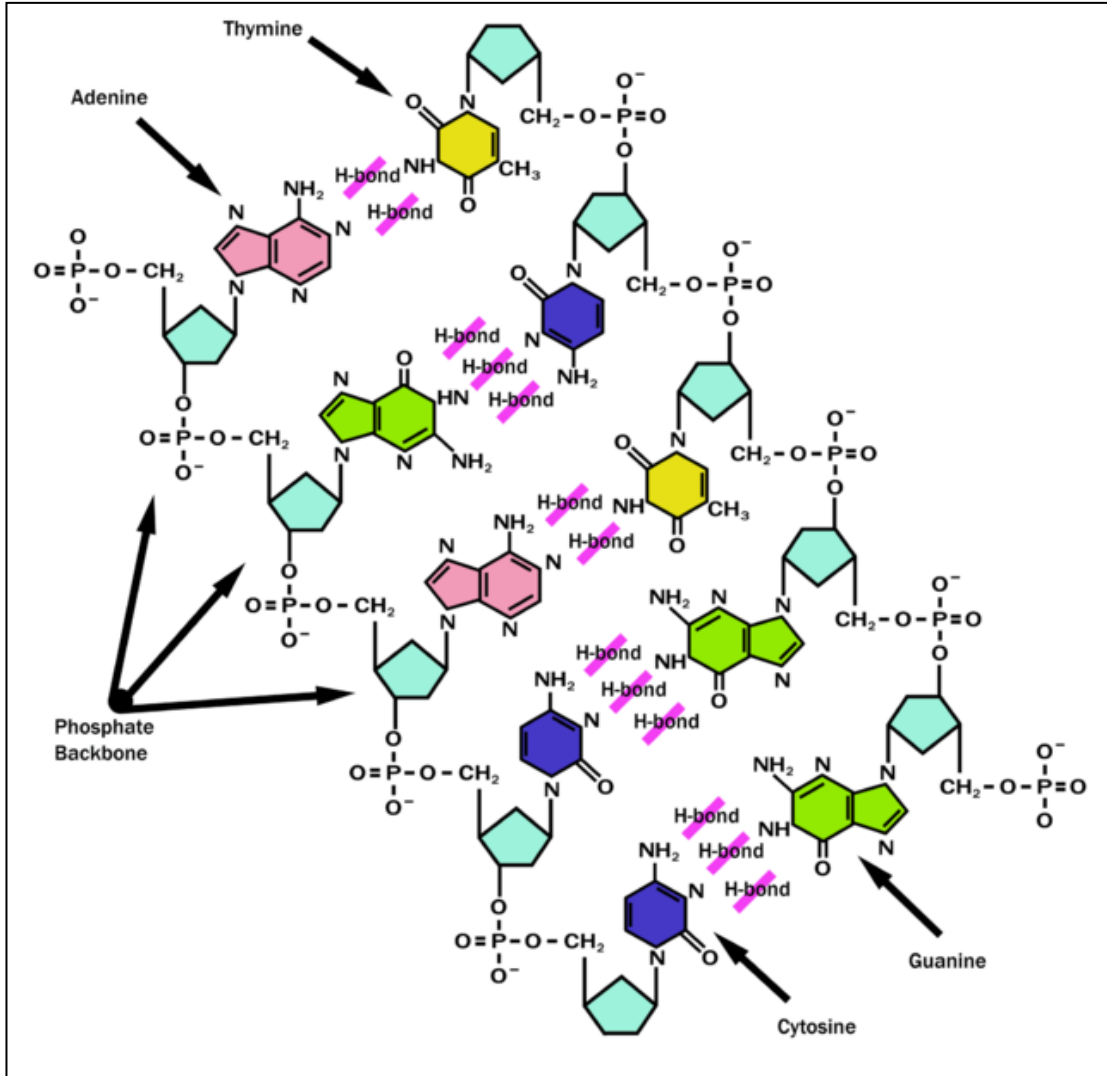


Figure 3.28. DNA consists of a 5 carbon deoxyribose sugar (turquoise), a phosphate, and 4 possible nitrogen bases. The bases connect to each other via hydrogen bonds.

<http://commons.wikimedia.org/wiki/Image:DNA-labels.png>

Mark Pellegrini

An area on DNA that contains the information for producing a specific trait is called a gene. All of the genes in DNA is known as the genome. The human genome contains 35,000 to 45,000 genes.

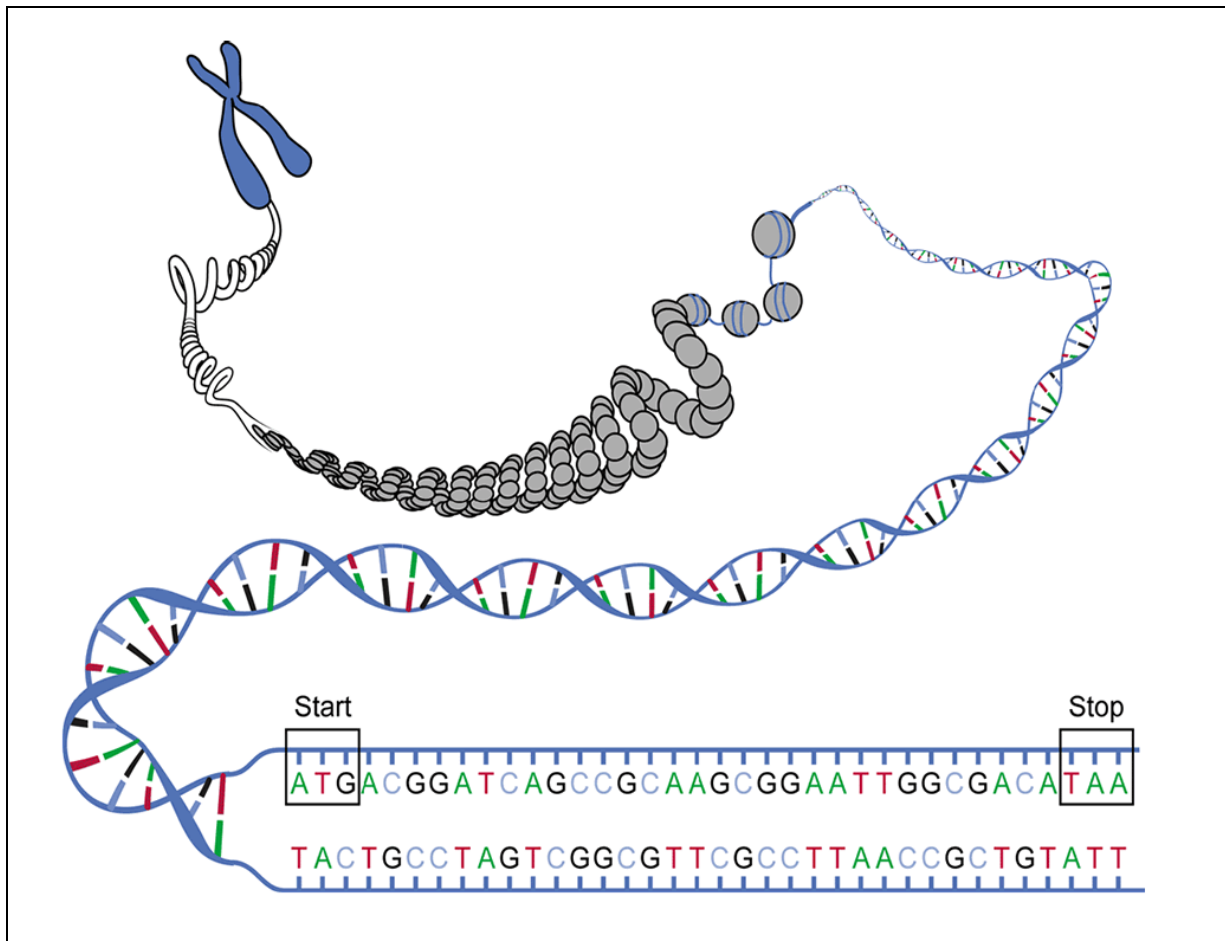


Figure 3.29. DNA is coiled into chromosomes. DNA contains information in its base pairs.

[http://commons.wikimedia.org/wiki/File:DNA\\_ORF.gif](http://commons.wikimedia.org/wiki/File:DNA_ORF.gif)

## RNA

RNA is very similar to DNA. RNA also contains 3 parts but unlike DNA's double stranded helix arrangement, RNA is single stranded (fig. 3.30). RNA contains:

- 5-carbon ribose sugar
- Phosphate
- Nitrogen bases

RNA has 3 of the 4 bases in DNA with one exception. RNA contains uracil instead of thymine. So instead of adenine pairing with thymine (as in DNA), adenine pairs with uracil in RNA.

In RNA the bases form the following pairs:

Uracil---Adenine

Cytosine---Guanine

Here is an example of base pairing during transcription. The bases on DNA can be read by mRNA.

DNA	mRNA
-----	------

A-----	U
--------	---

T-----	A
--------	---

C-----	G
--------	---

G-----	C
--------	---

C-----	G
--------	---

T-----	A
--------	---



RNA also comes in different types. There is the RNA that reads the information off of DNA called messenger RNA. There is also a type of RNA that assembles the amino acid sequence in translation called transfer RNA. And, there is ribosomal RNA.

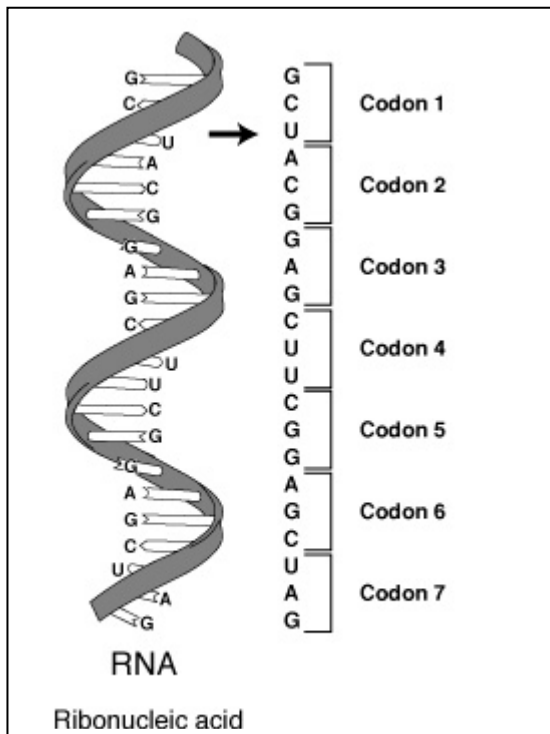


Figure 3.30. RNA is single stranded and contains the base uracil instead of adenine. Each section of 3-bases is called a codon.

<http://commons.wikimedia.org/wiki/Image:Codon.gif>

## Transcription

During transcription the information encoded by the sequence of bases on DNA needs to get out to the protein making machinery at the ribosome. The first step in translation is to expose the information on DNA. A special enzyme called RNA polymerase helps to unwind the DNA to expose the bases (fig. 3.31).

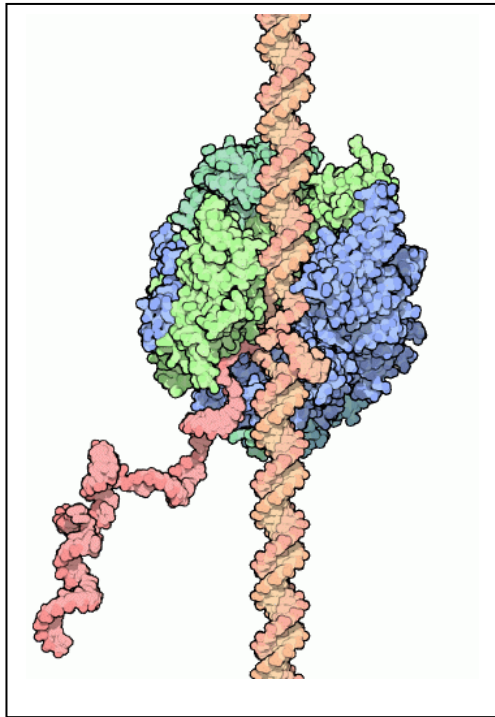


Figure 3.31. RNA polymerase helps to unwind the DNA molecule to expose the sequence of bases.

[http://commons.wikimedia.org/wiki/Image:RNA\\_polymerase\\_\(1i6h\).png](http://commons.wikimedia.org/wiki/Image:RNA_polymerase_(1i6h).png)

Illustration by David S. Goodsell of The Scripps Research Institute

Next a single stranded messenger RNA (mRNA) molecule “reads” the sequence of bases. The first 3-base code is a start code followed by codes for various amino acids. Some amino acids have more than one code so there is some redundancy in the coding. The 3 base code on mRNA is known as the codon (fig. 3.32).

The mRNA then takes its message out of the nucleus by moving through a nuclear pore and delivers it to the protein making machinery known as the ribosome (fig. 3.33).

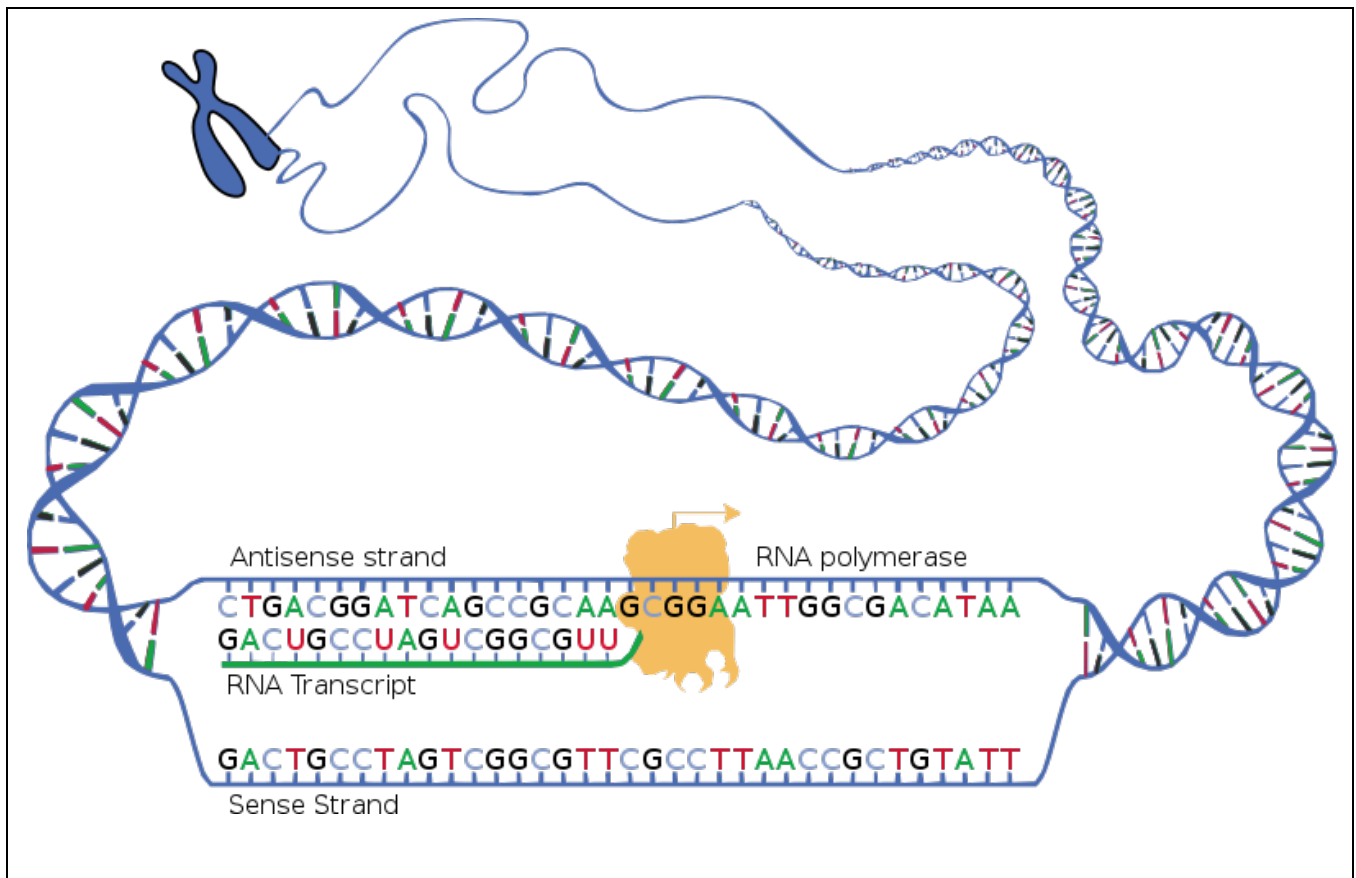


Figure 3.32. Transcription. RNA polymerase helps to unwind DNA exposing the bases. Messenger RNA (RNA Transcript) reads the exposed bases with its complimentary bases.

[http://commons.wikimedia.org/wiki/File:DNA\\_transcription.svg](http://commons.wikimedia.org/wiki/File:DNA_transcription.svg)

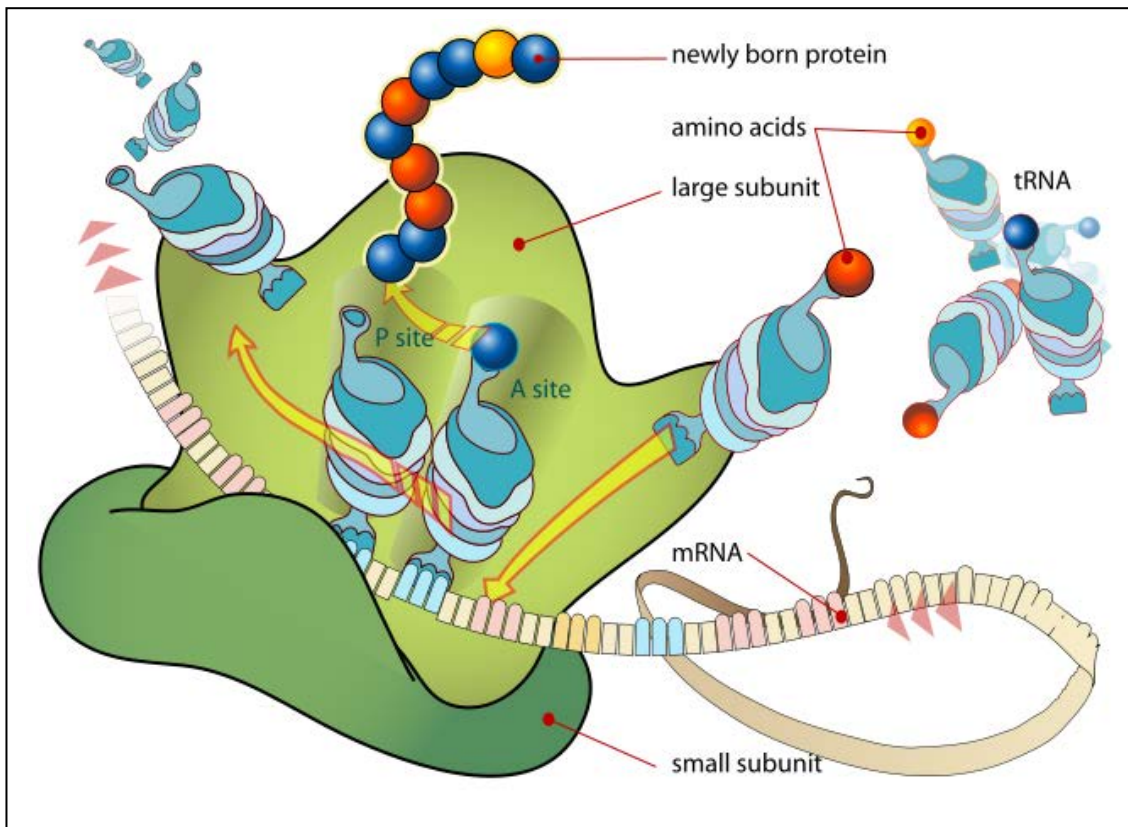


Figure 3.33. The ribosome is the site of polypeptide and protein synthesis. It consists of large and small subunits. Here mRNA meets up with transfer RNA (tRNA). The tRNA has 2 sites. One portion reads the code on the mRNA. The other has an amino acid binding site. The amino acids are bound together to form a large string.

[http://commons.wikimedia.org/wiki/Image:Ribosome\\_mRNA\\_translation\\_en.svg](http://commons.wikimedia.org/wiki/Image:Ribosome_mRNA_translation_en.svg)

## Translation

Translation occurs at the ribosome. Ribosomes contain large and small subunits. The messenger RNA (mRNA) carries the information for making the protein to the ribosome. There is a binding site for mRNA on the small ribosomal subunit. The transfer RNA (tRNA) attaches to a binding site on the large ribosomal subunit. Transfer RNA reads the information on the mRNA and assembles the protein accordingly. The 3 base code on the tRNA is known as the anticodon. There are 20 mRNA molecules, one for each of the 20 amino acids. On the other end of the tRNA is an amino acid binding site. The protein is assembled one amino acid at a time. The process stops when a stop code is reached. The completed protein then detaches from the tRNA and the ribosome splits into its 2 subunits. Sometimes another ribosome attaches to the same

strand of mRNA and transcribes it. When several ribosomes attach to one strand of mRNA we call this a polyribosome.

### **Real World A&P Blog Post**

#### **The New Science of Epigenetics**

When James Watson and Francis Crick first discovered the structure of DNA in 1953 they thought they had discovered the secret of life. This complex nucleic acid was capable of storing all of the information necessary to produce and maintain a living organism. The science of genetics was born and moved toward a complete understanding of the gene culminating in the genome project which mapped the human genome in 1993.

So definitive was this thinking that it was deemed the *Central Dogma of Biology*. In other words the command post of DNA sent its orders in a one-way direction--from DNA to RNA to protein to the rest of the body. It was thought that the information in DNA was locked in and would take many years of natural selection to change. You were essentially stuck with your DNA. .

This thinking is now changing with the exciting new science of epigenetics. Scientists are now discovering a new system in our cells that affects the way the information in DNA is expressed. In other words there may be a complex information system that affects the information flow from DNA to the cell without affecting the DNA itself. This system is affected by behavioral and environmental changes. This means that you may be able to change the information flow from DNA without actually changing the structure of DNA.

This idea has widespread ramifications. It is now thought that chronic diseases such as diabetes and heart disease are not solely caused by genes but also have a strong behavioral component. Information not only travels from DNA to cells but can also travel back to DNA from outside sources. There is a feedback loop of information flowing to and from DNA. The system consists of more than a static one-way flow of information but is more holistic in nature involving feedback from the organism.

A practical implication of this concept is the feedback from behaviors. For example, following a healthy lifestyle can not only provide benefits to your wellbeing but these benefits can also be passed on to your offspring. We have been touting the benefits of following a healthy lifestyle for years but until recently no one knew that actual genes could be turned on or off.

This opens up a whole new realm of thinking. In other words someone may have a gene for cancer or heart disease but it is possible for that gene never to be turned on. I personally find this information hopeful in finding new ways to live a healthy life and to heal. We are not slaves to our genes after all.

## **Real World A&P Blog Post**

### **The New Science of Epigenetics: Environment Influences Rheumatoid Arthritis**

Just because someone has the genetic predisposition for Rheumatoid Arthritis (RA) it doesn't mean that it will always be expressed. There is an exciting new field in biology called epigenetics that explores the connection between the environment and the expression of certain genetic traits. In other words, it was long thought that information flowed down a oneway street from DNA to RNA to protein. In fact this concept of information flow was deemed the central dogma of biology. However, in the past few years it has been discovered that there is feedback loop beyond the random mutations of natural selection that influences whether certain genes are expressed.

This provides new hope for those carrying disease causing genes. Proponents of epigenetics such as Bruce Lipton (author of Biology of Belief) go as far as to say that since beliefs affect behavior and behavior contributes to environmental influences then changing one's beliefs and behaviors can affect how genes are expressed. Positive behaviors can then be passed down through generations much like genetic traits.

One recent study investigated the effects of environment on the expression of Rheumatoid arthritis (RA). This study conducted at the Karolinska Institutet looked at the work environment. Researchers looked at what is called psychosocial workload. In particular they found a correlation between low decision latitude and RA.

In other words, jobs in which workers have little input in decision making had an increased incidence of RA. Lack of control in the workplace has also been associated with high blood pressure and heart attacks.

Other behavioral factors that have been associated with an increase in RA include smoking and drinking alcohol.

Reference:

Karolinska Institutet (2008, September 28). Working Environment Is One Cause Of Rheumatoid Arthritis.

### Review Questions Chapter 3

1. Which of the following organelles is involved in protein synthesis:
  - a. Mitochondrion
  - b. Endoplasmic reticulum
  - c. Vesicle
  - d. Centrosome
2. Which of the following best describes the structure of a phospholipid:
  - a. Hydrophilic phosphate head and a hydrophobic lipid tail
  - b. Hydrophobic lipid head and hydrophilic phosphate tail
  - c. Hydrophilic phosphate head and hydrophobic amino acid tail
  - d. Hydrophobic amino acid head and hydrophilic lipid tail
3. Which type of substances can move across a phospholipid bilayer membrane:
  - a. Water soluble
  - b. Amino acids
  - c. Lipid soluble
  - d. Glucose
4. Which of the following cell organelles forms the mitotic spindle:
  - a. Mitochondrion
  - b. Golgi apparatus
  - c. Centrosome
  - d. Vesicle
5. Which of the following organelles produces ATP:
  - a. Mitochondrion
  - b. Endoplasmic reticulum
  - c. Centrosome
  - d. Vesicle
6. Which of the following structures is a protein that can move substances across the surface of cells:
  - a. Microtubule
  - b. Flagellum
  - c. Cilium
  - d. Vesicle

7. In diffusion substances move from areas of higher to lower concentration until what happens:
- Reaching equilibrium
  - ATP runs out
  - The protein channel collapses
  - Nothing, they continue to move
8. Which of the following transport mechanisms uses ATP:
- Diffusion
  - Facilitated diffusion
  - Osmosis
  - Active transport
9. Which of the following transport mechanisms relies on fluid pressure changes:
- Diffusion
  - Facilitated diffusion
  - Filtration
  - Active transport
10. Which of the following transport mechanisms involves water moving across a semipermeable membrane:
- Diffusion
  - Facilitated diffusion
  - Osmosis
  - Active transport
11. In osmosis water always moves toward:
- An area of lower concentration of solute
  - An area of more water
  - An area of higher concentration of solute
  - An exit
12. In which stage of mitosis do the chromosomes line up in the center of the cell:
- Prophase
  - Anaphase
  - Metaphase
  - Telophase
13. In this stage of mitosis the nuclear membrane forms and the chromosomes uncoil:
- Anaphase
  - Telophase
  - Metaphase
  - Prophase



14. A DNA nucleotide consists of:

- a. Ribose sugar, phosphate, nitrogen containing base
- b. Phosphate, amino acid, nitrogen containing base
- c. Triglyceride, phosphate, nitrogen containing base
- d. Ribose sugar, amino acid, phosphate

15. Which of the following structures carries the information from DNA outside of the nucleus:

- a. Amino acids
- b. Messenger RNA
- c. Transfer RNA
- d. Ribosomal RNA

16. Where is the information from DNA translated:

- a. Nucleus
- b. Mitochondrion
- c. Golgi apparatus
- d. Ribosome

17. The 3-base sequence on tRNA that codes for an amino acid is known as the:

- a. Anticodon
- b. Code
- c. Codon
- d. Transcriber

18. Ribosomes consist of:

- a. 1 ribosomal subunit
- b. 2 ribosomal subunits
- c. 3 ribosomal subunits
- d. 4 ribosomal subunits

# Chapter 4

## Overview of Cellular Metabolism

## Overview of Cellular Metabolism

Cells need energy to keep us alive. Energy is needed to allow us to breathe, to keep our hearts pumping, muscles contracting and thousands of other vital processes in our bodies. Cells manufacture and store energy in the form of ATP (adenosine triphosphate). There are about one billion molecules of ATP in a typical cell (fig. 4.1).

ATP consists of an adenine molecule, a ribose sugar and 3 phosphates.

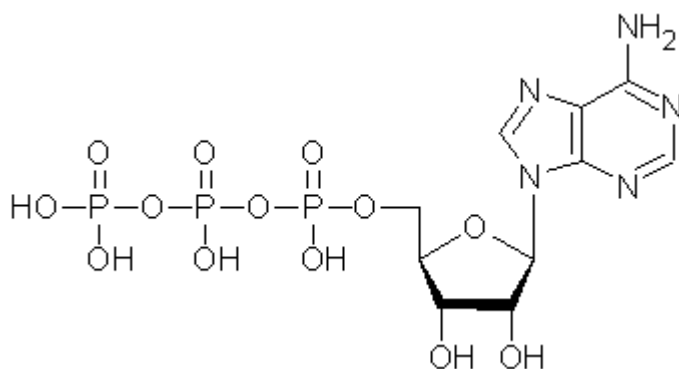


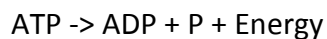
Figure 4.1. ATP

[http://commons.wikimedia.org/wiki/File:ATP\\_structure\\_revised.png](http://commons.wikimedia.org/wiki/File:ATP_structure_revised.png)

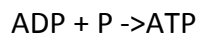
Remember that energy is stored in ATP in the high energy phosphate bond. When energy is needed the phosphate breaks off of ATP liberating the energy and leaving adenosine diphosphate (ADP). When energy is stored a phosphate is added to ADP to make ATP.

The storage and release of energy in ATP is controlled by enzymes.

When energy is liberated from ATP:



When energy is stored in ATP:

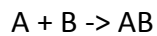


We call this phosphorylation (adding a phosphate) of ADP to make ATP.


## Cellular Metabolism

Metabolism is the sum total of all biochemical reactions in the body. There are 2 basic reactions; anabolic and catabolic. In anabolic reactions larger molecules are made from smaller molecules. Examples of anabolic reactions include the synthesis of proteins from amino acids and the construction of phospholipids from fatty acids. Catabolic reactions are characterized by the breaking down of larger molecules into smaller molecules. Every time you consume a food your body uses catabolic reactions to break the food down into smaller molecules. For example proteins are broken down into amino acids and complex carbohydrates are broken down into simple carbohydrates.

A general model for an anabolic reaction would be:



For a catabolic reaction:



Many of the metabolic reactions in the body have to do with the production of ATP. Energy is extracted from the foods we eat and used to store energy in ATP.

## Energy Systems

One way to look at how energy is produced in the body is to examine where the majority of energy comes from in different activities. Let's use an example to illustrate this concept. Let's say Hal is going on a long bicycle ride. Hal wants to make good time so he pedals vigorously.

During the first 30 seconds of Hal's ride the majority of energy comes from a process known as the ATP-phosphocreatine system. There are molecules of phosphocreatine (PCr) stored near Hal's muscles. The PCr contains a phosphate that easily lends itself to phosphoryllate ADP to make ATP to power Hal's muscles. There is only a small supply of PCr so the energy only lasts for about 30 seconds. The amount of PCr is what limits the system.

Hal continues to ride beyond 30 sec. During the next 180 seconds of intense activity the majority of Hal's energy comes from the anaerobic portion of a reaction known as glycolysis. Glycolysis is a reaction that breaks down glucose and extracts the energy for making ATP. Glycolysis is a bit more complicated than the ATP-PCr system.

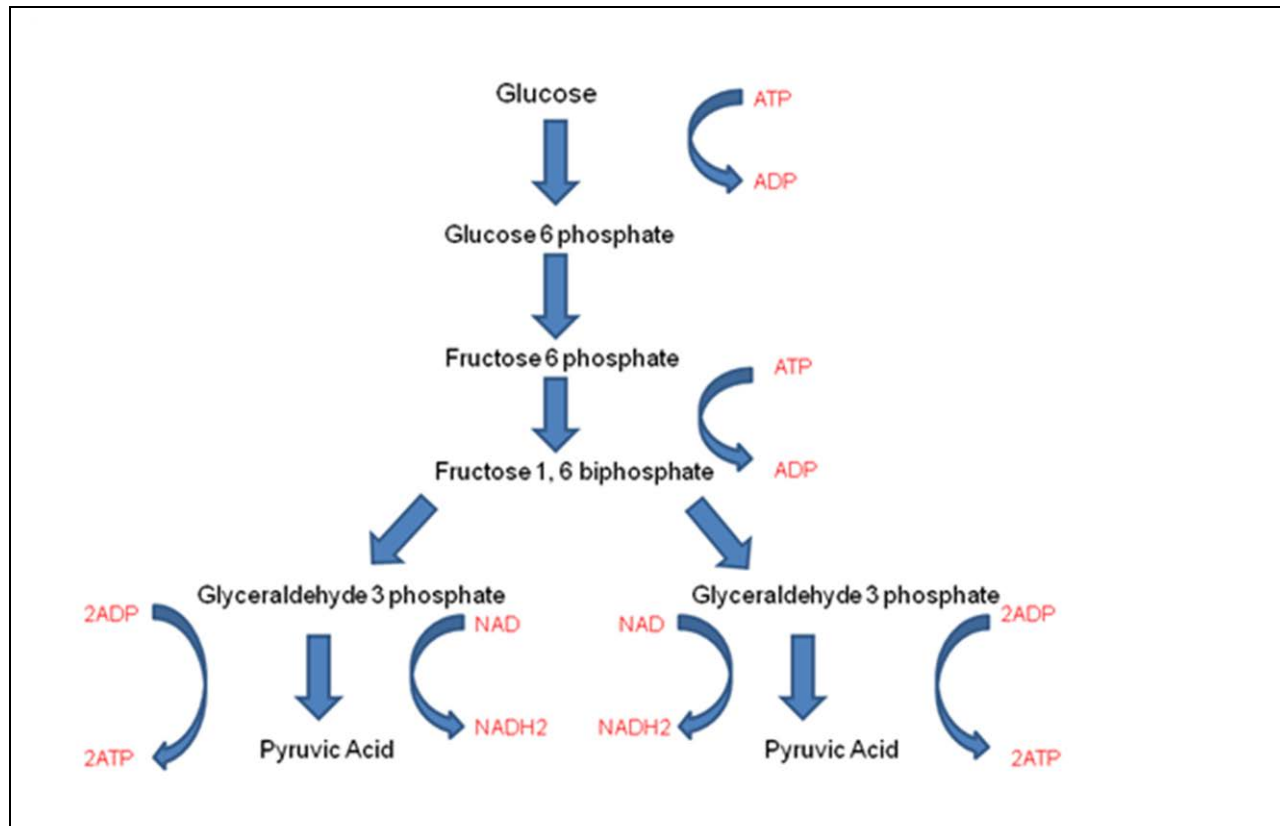


Figure 4.2. Glycolysis (abbreviated form).

Author

Glycolysis occurs in the cytoplasm of the cell. Glucose enters the cell and is split into two 3-carbon molecules called glyceraldehyde 3 phosphate. ATP is used to prime the reactions and the 2 molecules of glyceraldehyde 3 phosphate are converted to 2 molecules of pyruvic acid (pyruvate) (fig. 4.2).

Here is a summary of the steps of glycolysis.

First of all, glucose needs a bit of help to get things going so a couple of ATPs are needed to get it ready.

Glucose + 2ATPs → Fructose, 1, 6 biphosphate

This molecule is then split into 2 molecules. You might remember that glucose is a 6 carbon molecule. When it splits it forms two 3-carbon molecules.

Fructose 1, 6 biphosphate → 2 glyceraldehyde 3 phosphate

The 2 molecules of glyceraldehyde 3 phosphate lose hydrogen atoms (oxidized) and gain phosphates to form 2 molecules of:

1, 3 diphosphoglycerate

A byproduct of this reaction is the formation of 2NADH molecules that will be used later.

The 2 molecules of 1, 3 diphosphoglycerate each give up one phosphate to phosphoryllate ADP making 2 ATPs and converting to 2 molecules of:

3-phosphoglycerate

The phosphates move to another carbon forming:

2-phosphoglycerate

Water is removed from these molecules (dehydration) forming 2 molecules of:

Phosphoenolpyruvate

The phosphates are removed and added to ADP to make 2 more ATPs forming 2 molecules of:

Pyruvate

If the pyruvate is converted to lactic acid the 2 molecules of NADH are used. If not, pyruvate is converted to acetyl-coenzyme A and enters the KREBS cycle (coming up next). The conversion of pyruvate to acetyl coenzyme A produces 2 more NADH molecules.

Notice that 2 ATP molecules are used to get the reactions started and 4 ATPs are produced. This results in a net gain of 2 ATPs. Glycolysis also produces 2 molecules of NADH which can be used by the electron transport chain to phosphoryllate ADP to make ATP.

If oxygen is not present the 2 molecules of pyruvate are converted to lactic acid. The 2 molecules of NADH are used in this process. This is what happens to Hal during the next 30—180 seconds of cycling.

As Hal continues to cycle beyond 180 seconds his body switches to the aerobic energy systems. The pyruvate is now converted to acetyl coenzyme A which enters the Krebs cycle. The Krebs cycle occurs in the mitochondrion and consists of a number of reactions using enzymes located in the cristae of the mitochondrion (fig. 4.3). Each turn of the Krebs cycle produces the following products:

- 1 Molecule of ATP
- 3 Molecules of NADH
- 1 Molecule of FADH<sub>2</sub>

Since 2 molecules of pyruvate enter the Krebs cycle the reactions occur twice producing twice the amount of product. Since we began with one molecule of glucose at this point we end up with:

- 2 Molecules of ATP
- 6 Molecules of NADH
- 2 Molecules of FADH<sub>2</sub>

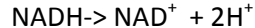The NADH and FADH carry energy that can be used to phosphorylate ADP. This occurs in the electron transport chain which is also located in the mitochondrion.

The electron transport chain is a series of enzymes that pass electrons from one to another. The enzymes pass the electrons along to lower energy levels. The energy is extracted to power an enzyme complex known as ATP synthase which phosphorylates ADP (fig. 4.4).

Notice that NADH and FADH<sub>2</sub> enter the electron transport chain at different levels. The electron transport chain is going to extract some energy from these molecules and use it to make ATPs by adding a phosphate to ADP. NADH has enough energy to make 3 ATPs while FADH<sub>2</sub> only has enough energy for 2 ATPs.

We know that energy is stored in the phosphate bond in ATP but how do these molecules of NADH and FADH<sub>2</sub> store energy? The energy is stored in electrons. Remember that electrons are tiny objects that “orbit” around the nucleus of an atom. If an atom is *excited* (takes on energy) the electrons move to the outer orbital shells. If the atom *calms down* (by releasing energy) the electrons move to the inner shells.

It turns out that NADH for example *donates* electrons to the system. This is called oxidation when a molecule loses electrons. When it does it loses 2 hydrogen atoms (which are also called protons):



As we stated earlier the electron transport chain is located in the mitochondrion. On the inside of the mighty mitochondrion is a folded membrane called the cristae. The inside of the membrane is called the matrix while the area outside of the membrane is called the intramembraneous space. Located in the membrane is a set of 5 special proteins.

The big picture is that the first 4 proteins extract the energy from the electrons from NADH and FADH<sub>2</sub> and use this energy to pump protons across the membrane (from the matrix to the intramembraneous space). The protons build up on one side of the membrane forming a proton gradient. The proton gradient is used by the fifth membrane protein to add phosphates to ADP. This is called phosphorylation of ADP which makes ATP.

### Protein I

NADH encounters the first protein and loses 2 hydrogens and 2 electrons (oxidized). The 2 hydrogens are picked up by a molecule in the protein (FMN→FMNH<sub>2</sub>) which then passes the electrons from the hydrogens to iron (Fe). The hydrogens pick up their lost electrons and are transferred to a third molecule (ubiquinone aka coenzyme Q10). The hydrogens again separate from their electrons and the electrons are again passed to iron. Iron again passes the electrons to another ubiquinone located outside of the protein and in the membrane. In order to do this the hydrogens must recombine with their lost electrons.

In summary, the first membrane protein acts as an active transport pump that pumps hydrogens from the matrix, across the membrane and into the intramembraneous space of the mitochondrion.

### **Protein II**

This protein works with FADH<sub>2</sub> generated from the KREBS cycle. The hydrogens are then stripped from FADH<sub>2</sub> forming FAD<sup>+</sup> and are combined with iron. The iron transfers the electrons to ubiquinone where they recombine with their hydrogens.

### **Protein III**

The membrane bound ubiquinone releases electrons that are picked up by the third protein. This protein passes the electrons via an electron carrier called cytochrome C. The cytochrome C transports electrons to the 4<sup>th</sup> protein.

### **Protein IV**

At the fourth protein the electrons combine with hydrogen and oxygen (from breathing) to form water. We say that oxygen is the final electron acceptor.

The energy allowing the electrons to move from carrier to carrier is used to pump protons (H<sup>+</sup>) across the membrane. NADH can pump more protons than FADH<sub>2</sub>. The protons build up and form a proton gradient. This gradient is used by the final protein to make ATP.

### **Protein V**

The final protein is actually an enzyme called ATP synthase. This enzyme uses the proton gradient to add a phosphate to ADP (this is called phosphorylation).

Since NADH releases its electrons on one side of the inner membrane the hydrogens (protons) build up. This creates a proton gradient whereby the protons move from one side of the membrane to the other.

### **Total ATPs From 1 Molecule of Glucose**

You may be wondering just how many molecules of ATP can be produced from one molecule of glucose. If we add up all of the energy producing molecules we get the following:

Glycolysis = net gain of 2ATP

KREBS cycle (2 turns) = 2ATP

Remember that there is enough energy in one molecule of NADH to make 3ATPs. Likewise there is enough energy in one molecule of FADH<sub>2</sub> to make 2 ATPs. So let's total them up.

NADHs from conversion of pyruvate to acetyl coenzyme A = 2      2 X 3 = 6 ATPs

NADHs from glycolysis = 2      2 X 3 = 6 ATPs

NADHs from KREBS (2 turns) = 6      6 X 3 = 18 ATPs

FADH<sub>2</sub>s from KREBS (2 turns) = 2      2 X 2 = 4 ATPs

So the grand total is: 2+2+6+6+18+4 = 38 ATPs from one molecule of glucose!



## In Summary

The Krebs cycle and glycolysis do not require oxygen directly but are still part of the aerobic metabolism of glucose. This is due to the use of oxygen by the electron transport chain. The last enzyme in the chain gives up a pair of electrons that combine with hydrogen ions and oxygen to form water. Oxygen is the last electron acceptor in the chain.

So when Hal cycles longer than 3 minutes, most of the energy comes from the aerobic metabolism systems. These same systems provide energy what Hal is at rest.

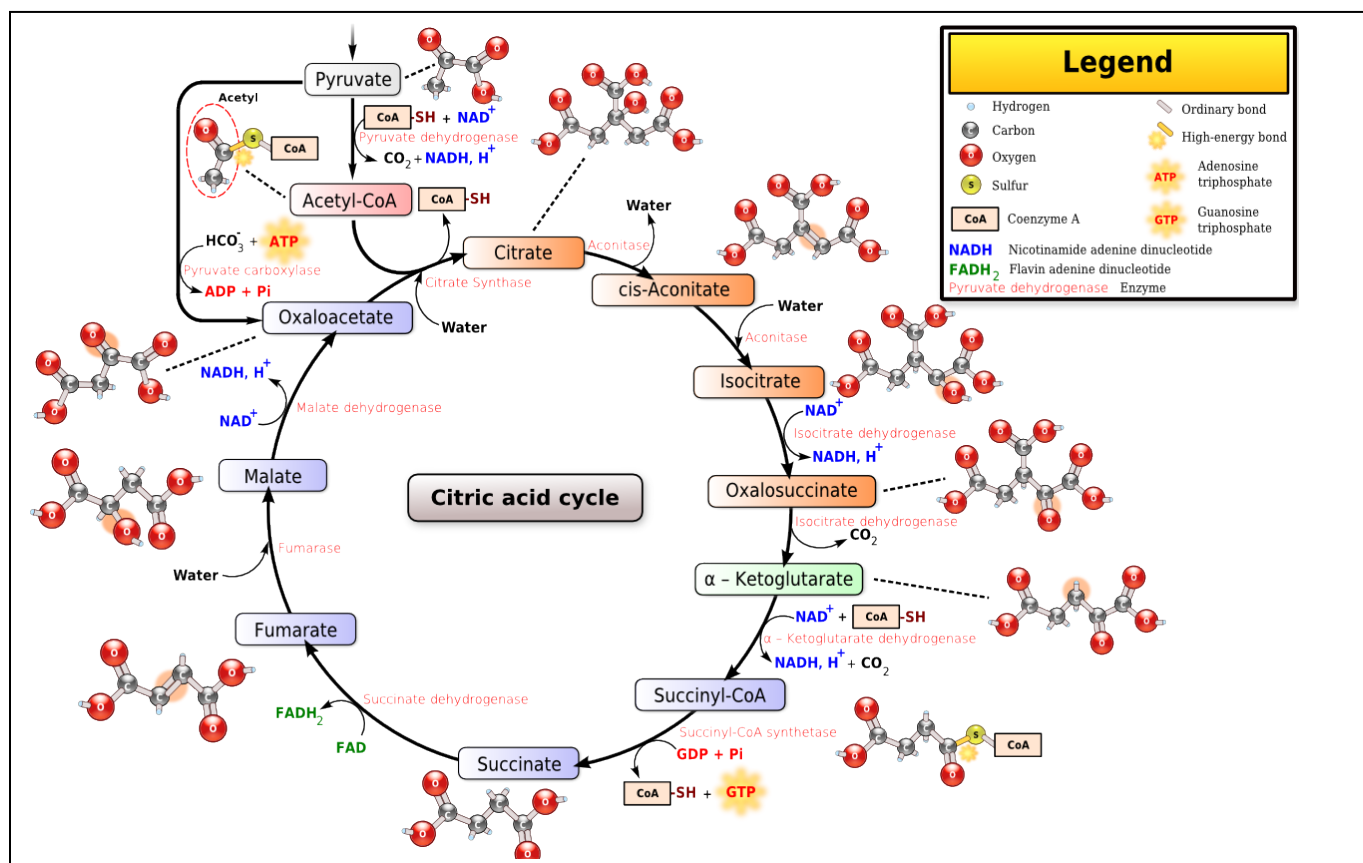


Figure 4.3. KREBS (Citric Acid cycle). The important events include the entrance of acetyl-CoA and its conversion to citrate; the production of  $\text{NADH + H}$  when isocitrate is converted to oxalosuccinate, alpha-ketoglutarate is converted to succinyl-CoA, and malate to oxaloacetate; the production of  $\text{FADH}_2$  when succinate is converted to fumarate; and the production of GTP (or ATP).

[http://commons.wikimedia.org/wiki/File:Citricacidcycle\\_ball2.png](http://commons.wikimedia.org/wiki/File:Citricacidcycle_ball2.png)

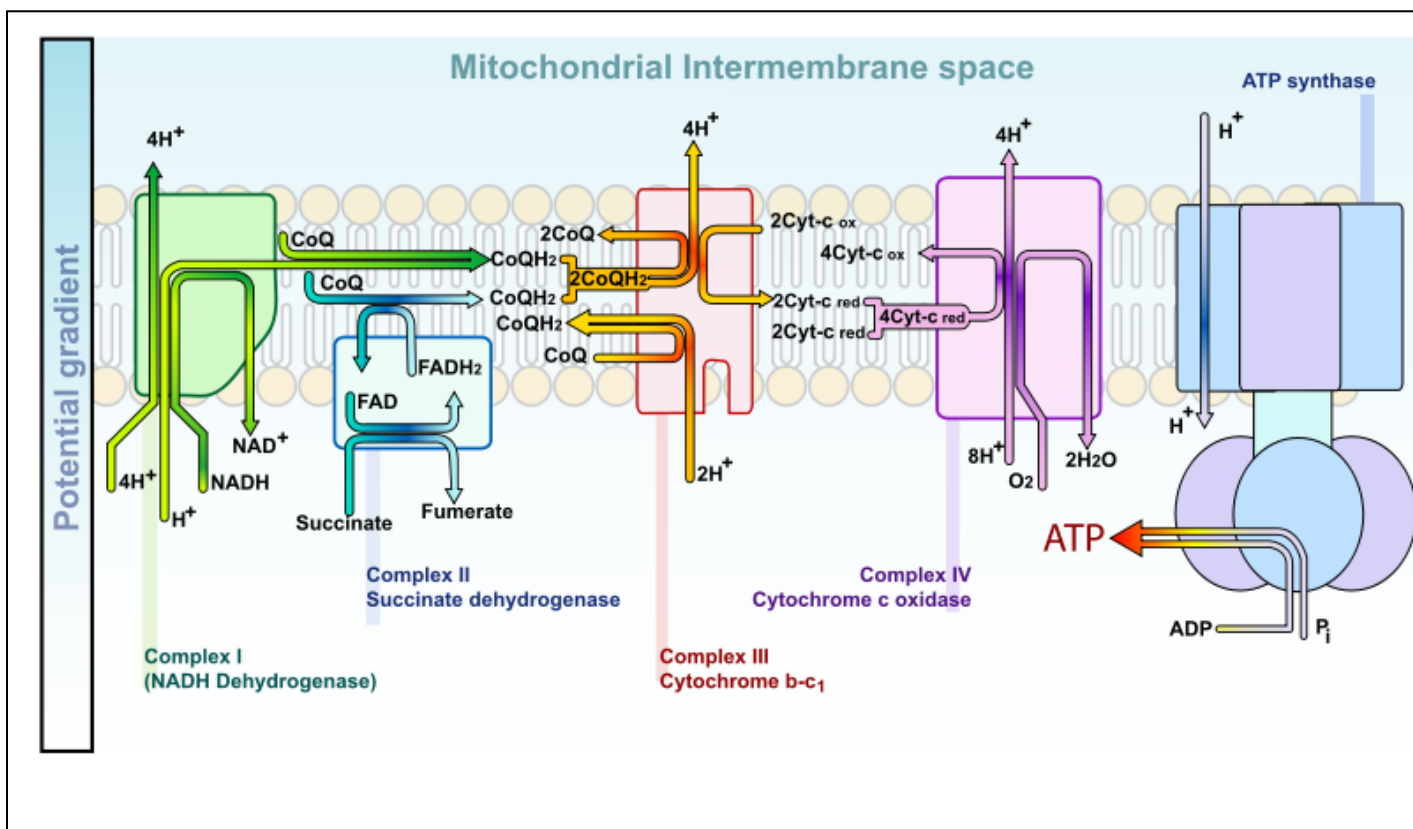


Figure 4.4. Electron Transport Chain. Electrons are passed from NADH and FADH<sub>2</sub> to electron carrier molecules. H<sup>+</sup> ions are released from NADH and FADH<sub>2</sub> and “pumped” into the outer mitochondrial membrane creating a proton gradient. The proton pumps use electrons to move H<sup>+</sup> ions and then pass electrons to the next carrier. The final carrier forms water by combining H<sup>+</sup> with oxygen. The proton gradient powers the ATP synthase molecule to phosphorylate ADP.

[http://commons.wikimedia.org/wiki/File:ETC\\_electron\\_transport\\_chain.svg](http://commons.wikimedia.org/wiki/File:ETC_electron_transport_chain.svg)

## Review Questions Chapter 4

1. When Hal is at rest most of the ATP to power his muscles comes from:
  - a. Anaerobic glycolysis
  - b. ATP-Phosphocreatine system
  - c. Cytosol
  - d. KREBS and ETC
2. If Hal were to lift a heavy weight for a few seconds which system would generate the most ATP:
  - a. ATP-Phosphocreatine
  - b. Anaerobic glycolysis
  - c. KREBS and ETC
  - d. Mitochondria
3. If intense activity ceases at about 2 minutes which of the following occurs:
  - a. Pyruvic acid is converted to lactic acid
  - b. Pyruvic acid is converted to acetyl coenzyme A
  - c. Acetyl coenzyme A enters the KREBS cycle
  - d. Lipids and proteins are converted to pyruvic acid
4. Anaerobic glycolysis produces a net gain of how many ATPs:
  - a. 1
  - b. 2
  - c. 3
  - d. 4
5. For each turn of the KREBS cycle how many NADHs are produced:
  - a. 1
  - b. 2
  - c. 3
  - d. 4
6. The energy from each NADH can be converted to phosphoryllate how many ATPs:
  - a. 1
  - b. 2
  - c. 3
  - d. 4

7. Extraction of energy from NADH and FADH occurs where:
- a. Anaerobic glycolysis
  - b. ATP-Phosphocreatine
  - c. KREBS
  - d. Electron transport chain
8. Building a protein from amino acids is an example of which type of reaction:
- a. Catabolic
  - b. Exothermic
  - c. Anabolic
  - d. Endothermic
9. During the first couple of steps of glycolysis 2 ATP are used for:
- a. Phosphoryllating ADP
  - b. Adding phosphates to glucose
  - c. Taking phosphates off of glucose
  - d. Energy
10. KREBs and ETC occur where:
- a. Cytosol
  - b. Endoplasmic reticulum
  - c. Mitochondrion
  - d. Nucleus

# Chapter 5

## Tissues

## Tissues

Welcome to the fascinating world of tissues. The body is packed with many different kinds of tissues. Some are highly organized and some are not. When studying tissues it helps to think about the relationship between the structure of a tissue and its function.

The study of tissues is known as histology. People who study histology spend a lot of time looking in microscopes at the various body tissues.

Let's look at how tissues are categorized.

There are 4 main categories of tissues in the human body:

- A. Epithelium
- B. Connective
- C. Muscle
- D. Nervous

Epithelium is a tissue that covers other structures (fig. 5.1). Therefore one side is always exposed to the outside (which could still be inside the body). You will see epithelial tissue covering the inside of body cavities and organs. The outer or superficial portion of your skin is an epithelial tissue. Epithelial tissue does not have a blood supply. Therefore nutrients must enter the tissue by diffusion. Epithelial tissue anchors to other structures via a basement membrane.

We can categorize epithelial tissue according to the shape of the cells and number of layers (figure 5.2).

There are 3 basic shapes of epithelial cells:

- A. Squamous cells are flattened.
- B. Cuboidal cells look like cubes.
- C. Columnar cells are rectangular.

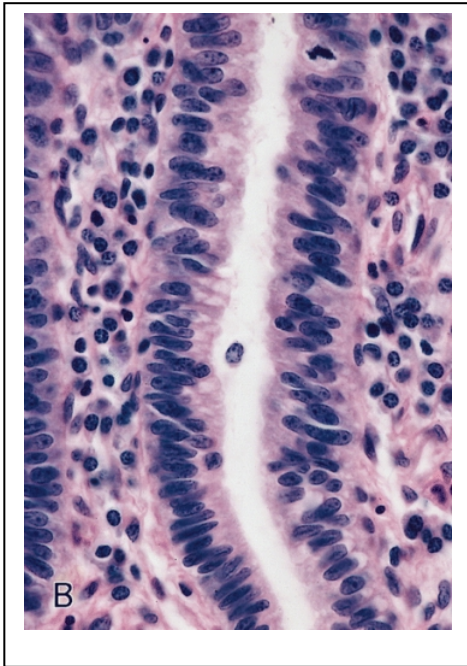


Figure 5.1. Example of epithelium. Notice the tissue acts as a covering. The shape of these cells is columnar.

[http://commons.wikimedia.org/wiki/Image:Barrett%27s\\_mucosa,\\_low-grade\\_dysplasia,\\_high-power\\_magnification.jpg](http://commons.wikimedia.org/wiki/Image:Barrett%27s_mucosa,_low-grade_dysplasia,_high-power_magnification.jpg)

One layer of epithelial cells is called “simple.”  
More than one layer is called “stratified.”

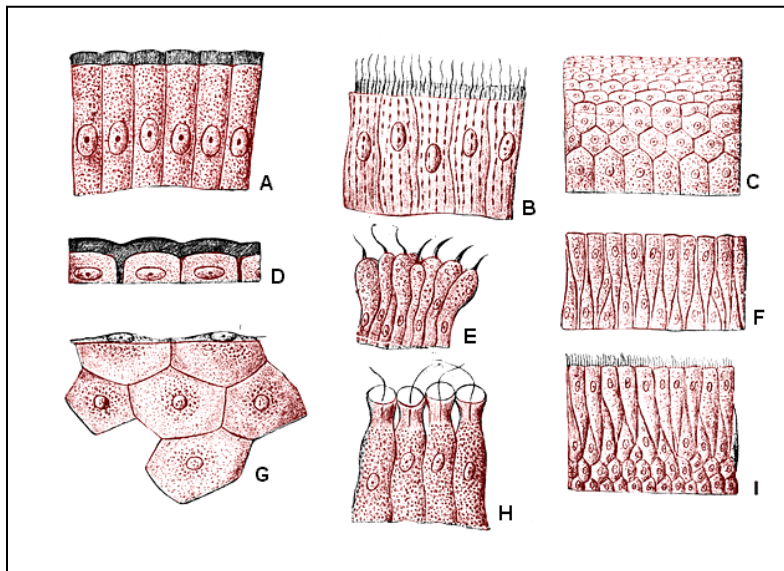


Figure 5.2. Different types of epithelium.

- A. Simple columnar
- B. Simple columnar with cilia
- C. Stratified squamous
- D. Simple squamous
- E. Transitional
- F. Pseudostratified columnar.
- G. Cuboidal
- H. Choanocytes
- I. Pseudostratified columnar with cilia

[http://commons.wikimedia.org/wiki/Image:Tkanka\\_nablonkowa.png](http://commons.wikimedia.org/wiki/Image:Tkanka_nablonkowa.png)

Simple squamous epithelium is a very thin tissue. It is often the site of substance transport. Simple squamous epithelium is found in capillaries, the kidneys and in the alveoli of the lungs.

Simple cuboidal epithelium is a little thicker than simple squamous. It is found lining tubular ducts. Examples of where simple cuboidal epithelium is found include the ovaries, kidney tubules, ducts (fig. 5.3).

Simple columnar epithelium is even thicker than simple cuboidal and is found in the urethra, pharynx and vas deferens.

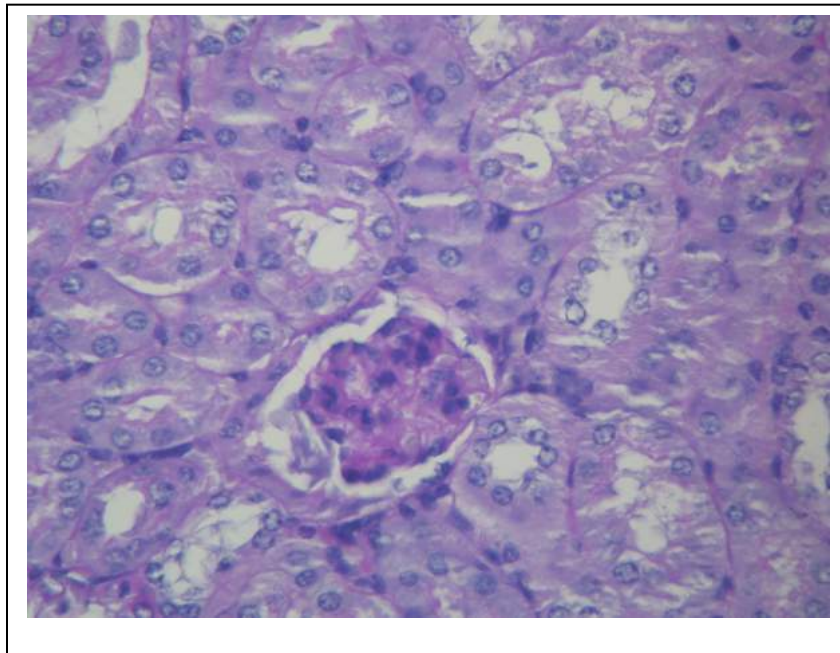


Figure 5.3. Simple cuboidal epithelium lines the tubules in the kidneys.

[http://upload.wikimedia.org/wikipedia/commons/4/4c/Glomerulus\\_pas.JPG](http://upload.wikimedia.org/wikipedia/commons/4/4c/Glomerulus_pas.JPG)

Stratified squamous epithelium has a specific structure. The cells in the deeper layers are more cuboidal in shape. The more superficial layers contain flattened cells. You can find stratified squamous in the superficial layer of the skin known as the epidermis. You can also find it in the oral cavity, anal canal and vagina (figure 5.4).



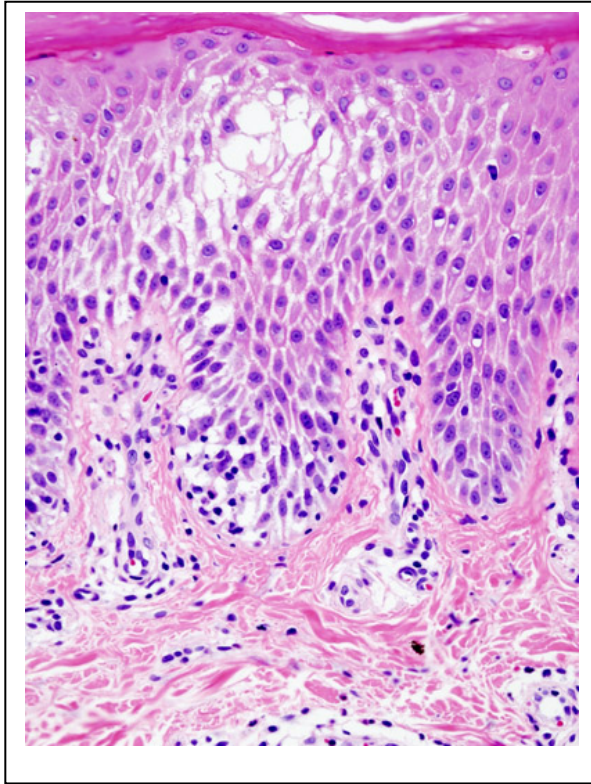


Figure 5.4. Stratified squamous epithelium is found in the superficial layer of the skin. The cells in the deeper layers are rounded and become flattened at the surface.

[http://upload.wikimedia.org/wikipedia/commons/9/9d/Spongiotic\\_dermatitis\\_%282%29Dyshidrotic.JPG](http://upload.wikimedia.org/wikipedia/commons/9/9d/Spongiotic_dermatitis_%282%29Dyshidrotic.JPG)

Stratified cuboidal epithelium also lines ducts. It can be found in the ducts of mammary glands, sweat glands, salivary glands, and pancreas.

Columnar epithelium can also be stratified. This tissue is found in the vas deferens and pharynx. It provides a thicker lining for some tubular structures in the body.

There are some special cases of epithelium. We'll take a look at these now.

The first special case is called pseudostratified columnar epithelium. It is called pseudostratified because it looks like stratified (more than one layer) but it's not. It looks stratified because the nuclei of the cells are at various levels. But in reality there is only one layer (fig. 5.5).

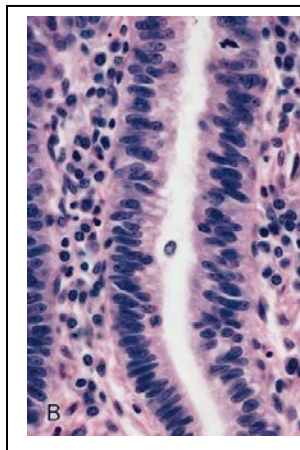


Figure 5.5. The nuclei appear to exist at different levels in pseudostratified columnar epithelium.

[http://commons.wikimedia.org/wiki/Image:Barrett%27s\\_mucosa,\\_low-grade\\_dysplasia,\\_high-power\\_magnification.jpg](http://commons.wikimedia.org/wiki/Image:Barrett%27s_mucosa,_low-grade_dysplasia,_high-power_magnification.jpg)

Pseudostratified columnar epithelium is found in the linings of the respiratory system.

The other special case of epithelium is called transitional. Transitional epithelium is found in the urinary bladder. Transitional epithelium looks somewhat like stratified squamous, but there is a difference. In stratified squamous the cells are rounder in the deeper layers and then flatten out near the top. In transitional epithelium the cells are also rounder in the deeper layers. However the cells remain rounded in the superficial layers.

### **Glandular Epithelium**

To finish up our discussion about epithelium, we will look at glandular epithelium. Glandular epithelium can secrete substances into the bloodstream (endocrine glands) or into ducts (exocrine glands).

Exocrine glands can be classified by method of secretion.

Merocrine glands release substances via exocytosis. Apocrine glands secrete substances by losing a small portion of the cell body. Holocrine glands secrete substances by releasing the entire cell.

### **Connective Tissue**

Next we will learn about another of the general categories of tissues known as connective tissue.

Connective tissue is the most abundant tissue in the body. It consists of special cells called fibroblasts surrounded by a matrix of intercellular material. Fibroblasts secrete protein fibers into the matrix. The matrix can contain fibers such as collagen, elastic, and reticular fibers. Other cells can exist in connective tissue such as macrophages and mast cells (both are types of white blood cells). Macrophages destroy bacteria and debris by phagocytosis. Mast Cells release heparin (an anticoagulant) and histamine (promotes inflammatory reactions).

There are 3 types of fibers produced by fibroblasts. Collagenous fibers are thick protein fibers that are strong but not flexible. They have a high tensile strength which means that they can take a lot of force along their long axis. Ligaments and tendons have a high number of collagenous fibers. Elastic fibers are also made of protein. Elastic fibers do not have a very high tensile strength but are very flexible. They are found in areas like the vocal cords and air passages of the respiratory system. Reticular fibers are thin protein fibers that form branching networks.

There are 5 basic types of connective tissue:

1. Loose
2. Dense
3. Adipose
4. Reticular
5. Elastic

There is also a category called “special” connective tissue that includes blood, bone, and cartilage.

Loose connective tissue is not very well organized tissue. It contains fibroblasts, matrix, and some fibers scattered about. It is found in the dermis and subcutaneous layers of the skin as well as surrounding muscles. Sometimes it is called fascia.

Adipose connective tissue consists of cells containing lipid (fat) called adipocytes. The lipid is used to store energy to be used by the body if needed.

Adipose tissue is also found around some organs and joints. It forms a cushion for shock absorption.

Adipose tissue also insulates the body (fig. 5.6).

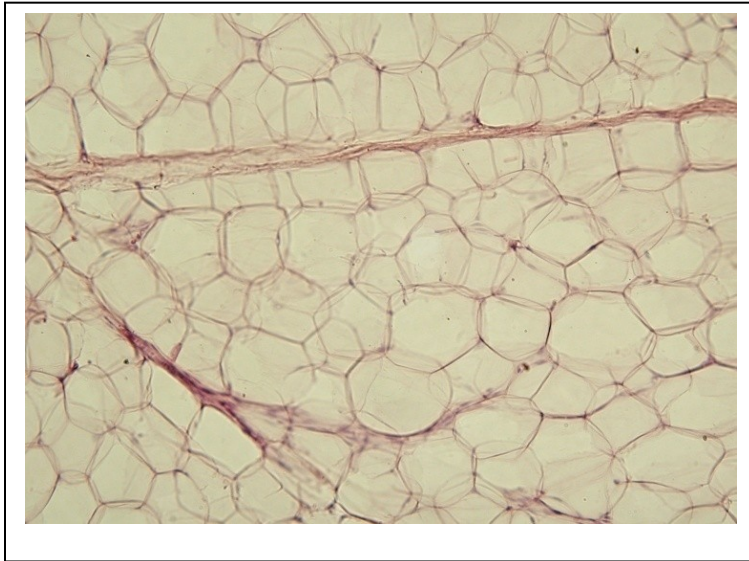


Figure 5.6. Adipose connective tissue consists of adipocytes. These large cells contain lipid.

[http://commons.wikimedia.org/wiki/Image:Yellow adipose tissue in paraffin section - lipids washed out.jpg](http://commons.wikimedia.org/wiki/Image:Yellow_adipose_tissue_in_paraffin_section_-_lipids_washed_out.jpg)

Courtesy: Department of Histology,  
Jagiellonian University Medical College

Reticular connective tissue consists of a thin supportive network of collagen fibers. It is found supporting the walls of the liver, spleen and lymphatic system.

Dense connective tissue contains thick collagenous fibers. It is found in ligaments and tendons which have a high tensile strength. Dense connective tissue has a poor blood supply which is why tendons and ligaments do not heal well. There are also some elastic fibers and fibroblasts.

Elastic connective tissue contains more elastic fibers than collagen fibers. Elastic connective tissue is found in attachments between vertebrae and in walls of some hollow internal organs.

There is also a special category of connective tissue that contains:

- Blood
- Bone
- Cartilage

Blood is considered a liquid connective tissue. Blood contains a fluid matrix called plasma along with cells called formed elements. Blood contains red blood cells (erythrocytes), white blood cells (leukocytes) and platelets. It transports gasses such as oxygen and carbon dioxide and functions in clotting and immunity (fig 5.7).

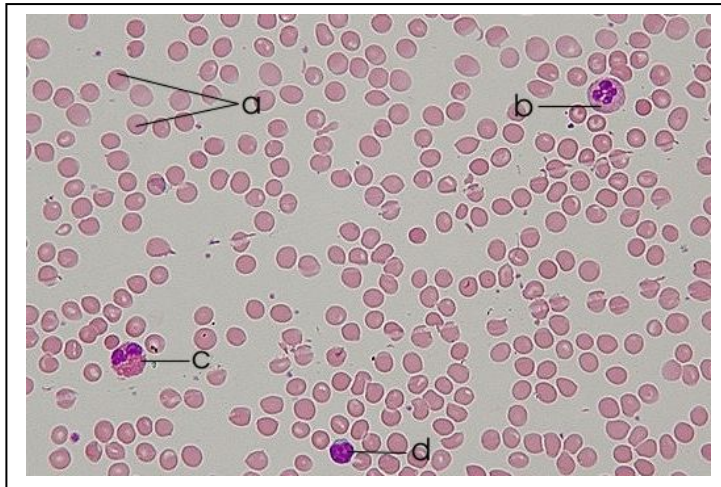


Figure 5.7. Blood consists of red blood cells (a) and white blood cells (b,c,d) suspended in a fluid matrix called plasma.

[http://commons.wikimedia.org/wiki/Image:Blood\\_smear.jpg](http://commons.wikimedia.org/wiki/Image:Blood_smear.jpg)

Courtesy: Department of Histology, Jagiellonian University Medical College

Bone is the most rigid of connective tissues. Its hardness comes from mineral salts such as calcium phosphate and calcium carbonate. It is highly organized into units called Haversian systems. The primary cell of bone is the osteocyte (fig. 5.8).

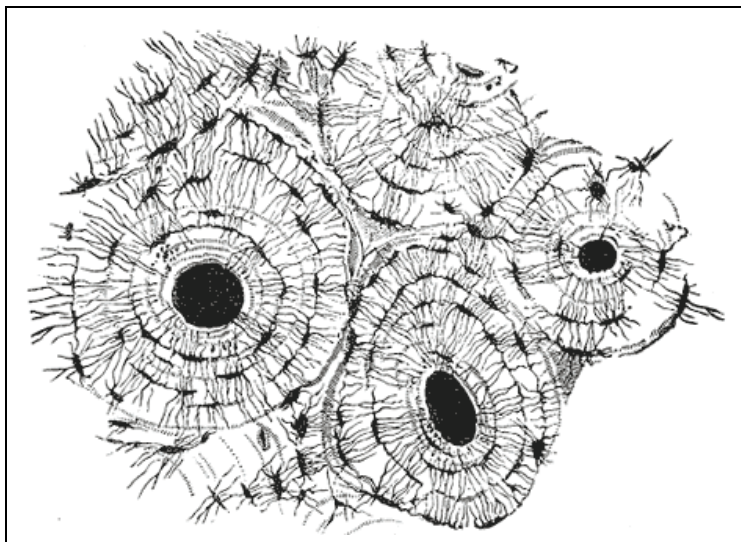


Figure 5.8. Bone is highly organized and contains structural units called Haversian systems. These are oriented along the long axis of bones to give it strength.

<http://commons.wikimedia.org/wiki/Image:Gray73.png>

There are 3 types of cartilage. These include hyaline, elastic and fibrocartilage. Cartilage contains cells called chondrocytes imbedded in a matrix. There are also elastic and collagen fibers. Cartilage is rigid and strong so it can provide support and protection. It also forms a structural model for developing bones. The matrix in cartilage consists of a chondromucoprotein substance. Cartilage has no direct blood supply so nutrients must enter by diffusion. Since the nutrients for cartilage diffuse into the tissue, the tissue needs water to help move these substances in. As humans age cartilage tends to “dry up” or become dehydrated which lends to degeneration of the tissue.



The cartilage cells or chondrocytes also do not divide very frequently which also contributes to poor healing. Chondrocytes are surrounded by a space called a lacuna. This is a very characteristic feature of cartilage.

Hyaline cartilage has the characteristic chondrocytes in lacunae arrangement along with a “ground glass” appearance to the matrix. It is found at the ends of bones, soft part of the nose, larynx and trachea. Hyaline cartilage serves as a model for bone growth (fig. 5.9).

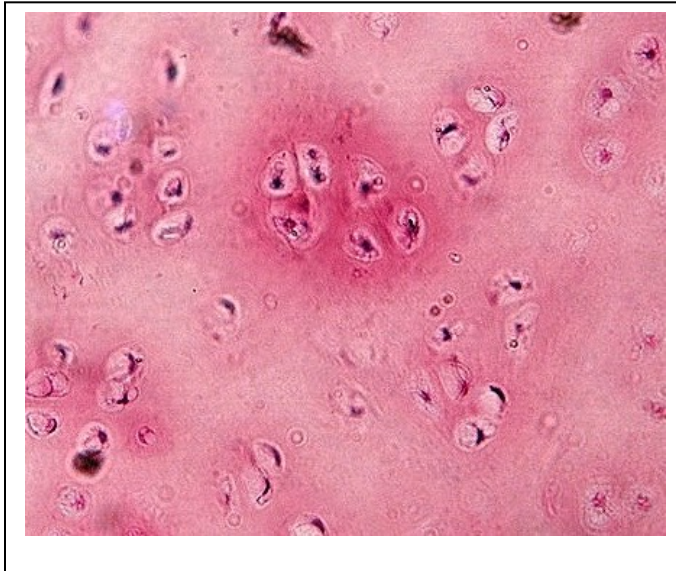

Figure 5.9. Hyaline cartilage has a smooth matrix. The chondrocytes are surrounded by a space called a lacunae.

[http://commons.wikimedia.org/wiki/Image:Hyaline\\_cartilage.jpg](http://commons.wikimedia.org/wiki/Image:Hyaline_cartilage.jpg)

Courtesy: Department of Histology,  
Jagiellonian University Medical  
College

Elastic cartilage also has the characteristic chondrocyte in lacunae along with elastic fibers. This cartilage is found in the larynx and the ear.

Fibrocartilage is characterized by rows of chondrocytes (in lacunae). It is a very strong cartilage and is found in the intervertebral discs.

## Muscle Tissue

Next we will investigate muscle tissue. There are 3 types of muscles tissue (fig. 5.13):

- Skeletal
- Cardiac
- Smooth

Skeletal muscle is striated. The striations are caused by the density of overlapping protein filaments called actin and myosin. The high concentration of protein filaments creates an optical illusion when light is shown on the muscle tissue. The filaments break up the light into light and dark areas causing the striated appearance (fig 5.10).

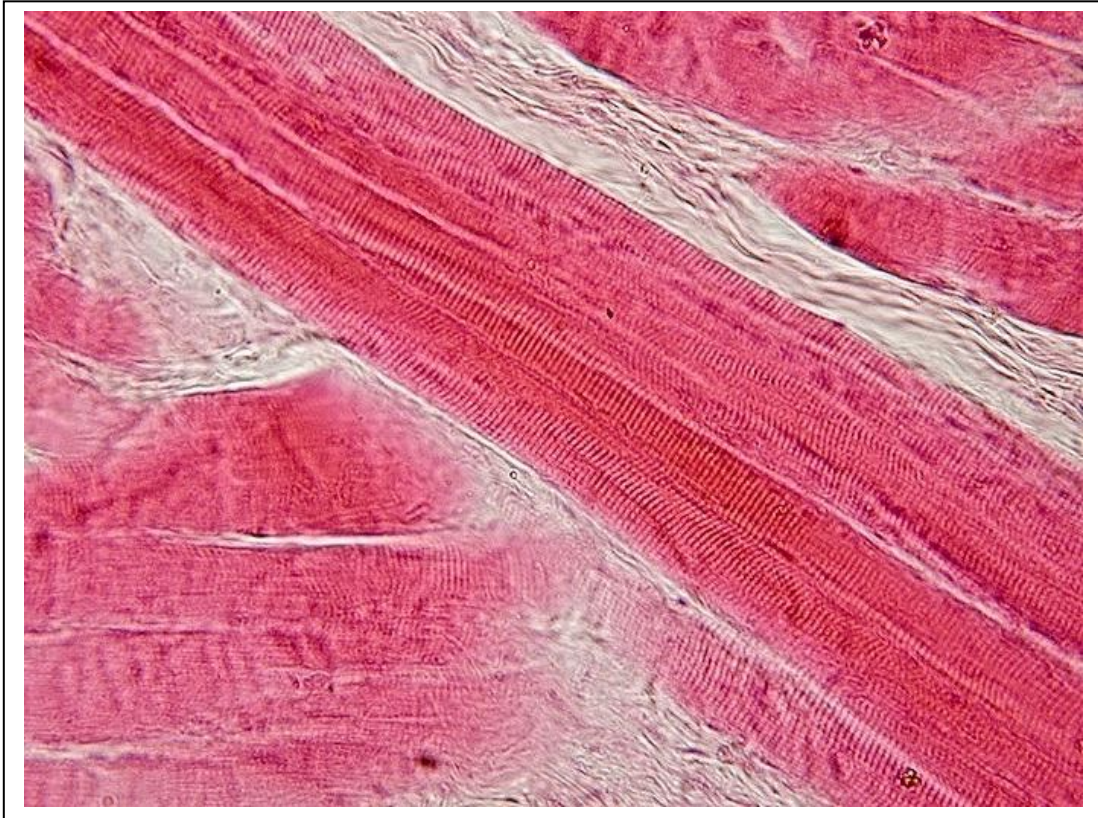


Figure 5.10. Skeletal muscle is characterized by long cells and has a striated appearance.

[http://commons.wikimedia.org/wiki/Image:Skeletal\\_muscle\\_-\\_longitudinal\\_section.jpg](http://commons.wikimedia.org/wiki/Image:Skeletal_muscle_-_longitudinal_section.jpg)

Courtesy: Department of Histology, Jagiellonian University Medical College

Cardiac muscle is also striated but has a unique structure called an intercalated disk. The disks are special intercellular junctions that allow electrochemical impulses to be conveyed across the tissue (fig. 5.11).

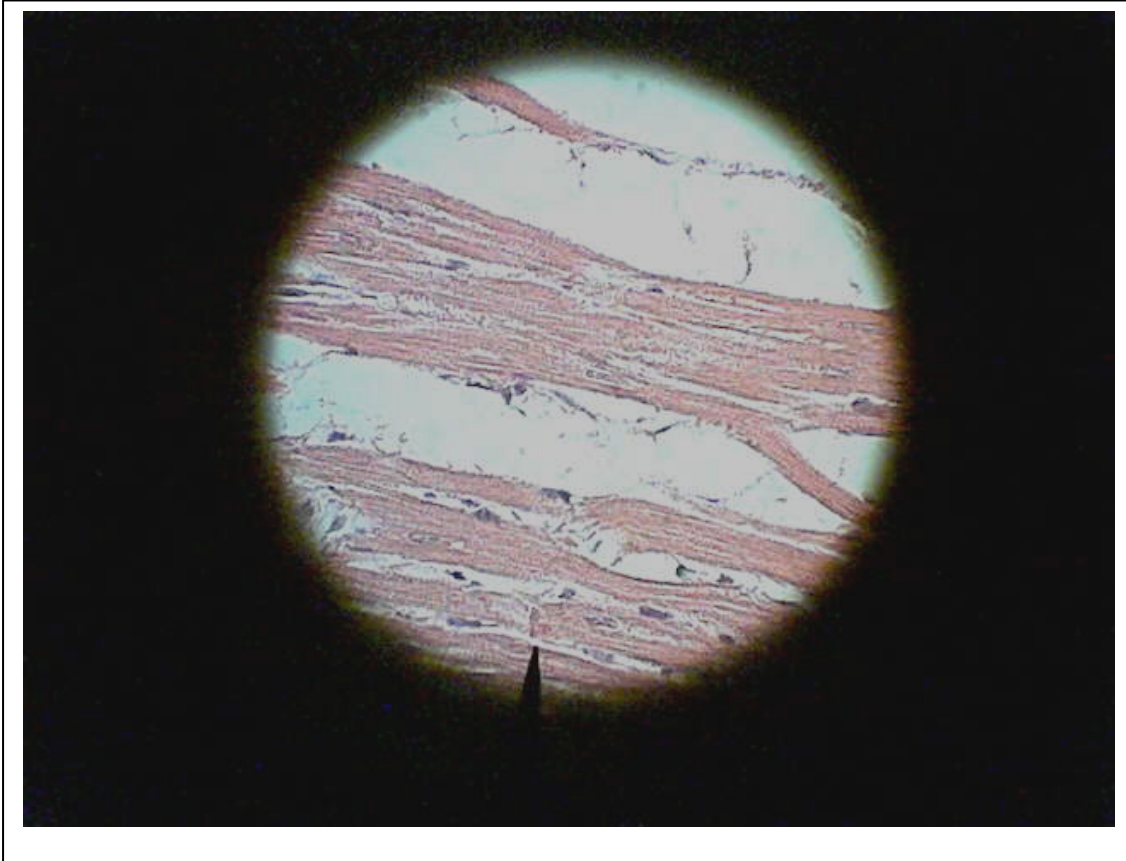


Figure 5.11. Cardiac muscle is also striated and contains special intercellular junctions called intercalated discs (see end of black arrow).

Photo by Bruce Forciea

Smooth muscle is more loosely organized with less concentrated protein filaments. Smooth muscle is not striated. Smooth muscle is found in organs such as in the gastrointestinal system and the arteries (fig. 5.12).

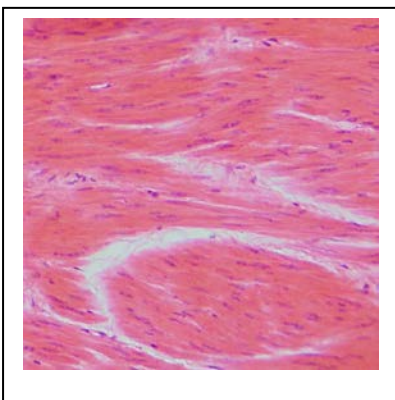



Figure 5.12. Smooth muscle is not striated because of the less dense arrangement of protein filaments.

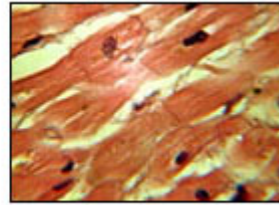
[http://upload.wikimedia.org/wikipedia/commons/3/3b/Glatte Muskulzellen.jpg](http://upload.wikimedia.org/wikipedia/commons/3/3b/Glatte_Muskulzellen.jpg)



Skeletal muscle



Smooth muscle



Cardiac muscle

Figure 5.13. 3 Types of Muscle Tissue

[http://commons.wikimedia.org/wiki/Image:Illu\\_muscle\\_tissues.jpg](http://commons.wikimedia.org/wiki/Image:Illu_muscle_tissues.jpg)



## Nervous Tissue

The last tissue we will investigate is nervous tissue. Nervous tissue consists of nervous system cells called neurons and supportive cells called glia (fig. 5.14).

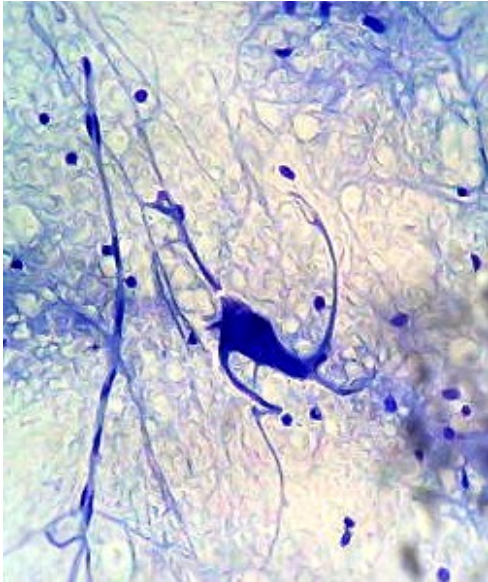

Figure 5.14. Nervous tissue contains large cells called neurons (stained dark blue) and supportive glial cells.

<http://commons.wikimedia.org/wiki/Image:Neuronehisto.jpg>

Fanny Castets

## Review Questions Chapter 5

1. Which of the following is not an epithelial cell shape:
  - a. Columnar
  - b. Squamous
  - c. Triangular
  - d. Cuboidal
2. More than one layer of epithelial tissue is called:
  - a. Layered
  - b. Stratified
  - c. Simple
  - d. Complex
3. Which epithelial tissue is found in capillaries:
  - a. Simple cuboidal
  - b. Stratified squamous
  - c. Simple columnar
  - d. Simple squamous
4. Which tissue is found lining ducts:
  - a. Loose connective
  - b. Simple cuboidal
  - c. Stratified squamous
  - d. Fibrocartilage
5. Which tissue does bone develop from:
  - a. Dense connective
  - b. Hyaline cartilage
  - c. Adipose
  - d. Dense connective
6. Which tissue is found in the epidermis of the skin:
  - a. Stratified squamous epithelium
  - b. Transitional epithelium
  - c. Loose connective
  - d. Fibrocartilage

7. Which tissue has the chondrocyte in lacunae arrangement:
- a. Cartilage
  - b. Bone
  - c. Epithelium
  - d. Connective
8. Which tissue is typically found in lymph nodes:
- a. Loose connective
  - b. Hyaline cartilage
  - c. Reticular connective
  - d. Cuboidal epithelium
9. Blood is considered which type of tissue:
- a. Epithelium
  - b. Cartilage
  - c. Connective
  - d. Blood is not a tissue
10. This tissue is found in the urinary bladder:
- a. Simple squamous epithelium
  - b. Transitional epithelium
  - c. Stratified squamous epithelium
  - d. Loose connective
11. Which of the following types of muscle tissue contains intercalated discs:
- a. Skeletal
  - b. Smooth
  - c. Reticular
  - d. Cardiac
12. Which of the following tissues contains Haversian systems:
- a. Cartilage
  - b. Muscle
  - c. Epithelium
  - d. Bone

# Chapter 6

## The Integument

## The Integument

In this chapter we will investigate the integumentary system as well as some of the membranes of the body.

The body has a number of epithelial membranes. The integumentary system or “skin” is one such membrane. There are also serous and mucous membranes in the body. Serous membranes line the body cavities. They secrete a slimy serous fluid to help reduce friction and allow organs to slide freely over one another. Serous membranes contain a superficial layer of simple squamous epithelium and a deeper layer of loose connective tissue.

Mucous membranes line the tubular structures that open to the outside of the body. An example of a “tube” is the oral cavity. Like serous membranes, mucous membranes contain a layer of epithelium along with loose connective tissue. The thickness of the epithelium varies depending on the location of the membrane. For example, the intestines are lined with pseudostratified columnar epithelium while the oral cavity is lined with stratified squamous epithelium.

The skin is a cutaneous membrane. The skin is the largest organ of the body and has a variety of functions. It provides a protective covering to the body that inhibits the loss of water, it helps to regulate temperature, houses sensory receptors that send information to the nervous system and synthesizes chemicals and excretes wastes. The skin also contains a good deal of immune system cells that help to protect the body against pathogens.

### Layers of the Skin

The skin contains 2 layers and a subcutaneous layer. The superficial layer is called the epidermis. The epidermis consists of stratified epithelium tissue arranged in layers called strata. Deep to the epidermis is the dermis. The dermis consists of loose connective tissue and a number of other structures we will investigate later. The deepest layer is the subcutaneous layer that consists of loose connective tissue and adipose tissue along with blood vessels and nerves (fig. 6.1).

The epidermis consists of stratified squamous epithelium arranged in layers or strata. The layers are:

- Stratum corneum
- Stratum lucidum
- Stratum granulosum
- Stratum spinosum
- Stratum basale

The epidermis is anchored to the dermis by means of a basement membrane. The epidermis does not contain any blood vessels. The cells of the stratum basale are nourished by the blood

vessels in the dermis. These cells can divide and move toward the surface pushing the old cells off of the superficial layers.

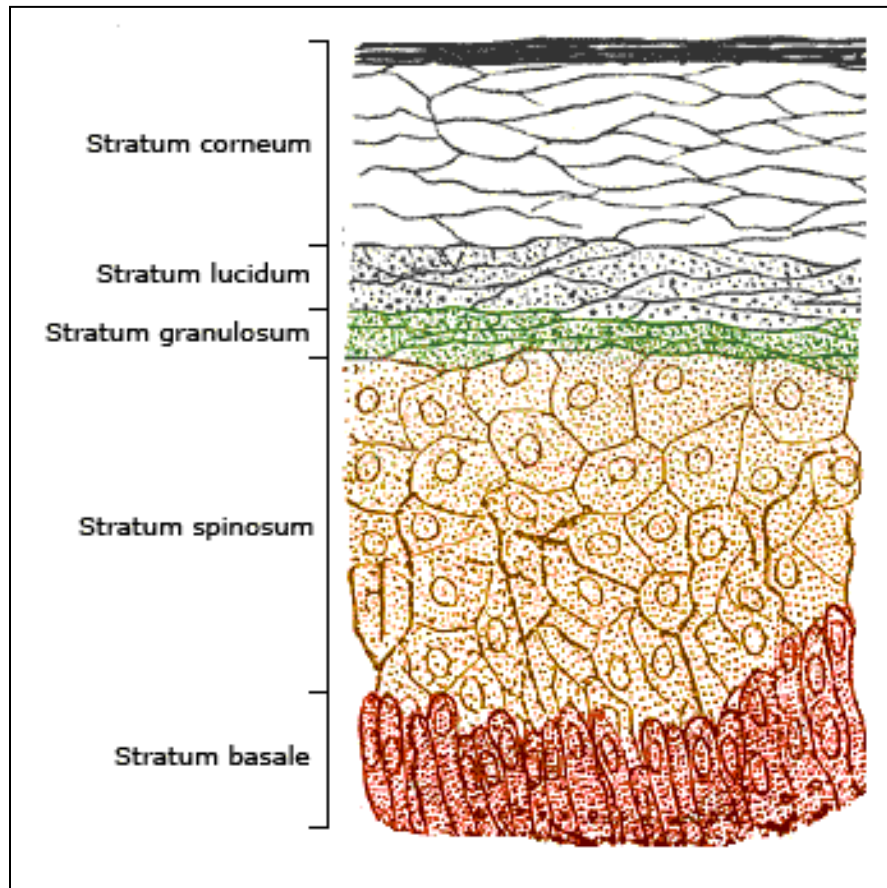


Figure 6.1. The epidermis is arranged in layers.

<http://commons.wikimedia.org/wiki/Image:Skinlayers.png>

The stratum corneum is the most superficial layer of the epidermis. It consists of cells that have been hardened with keratin. Keratin is secreted by cells located in the deep layers of the epidermis called keratinocytes.

The stratum lucidum is an additional layer that is found only in the palms of the hands and soles of the feet. It provides an added thickness to these layers.

The stratum granulosum contains cells that have lost their nuclei. These cells remain active and secrete keratin. The cells contain granules in their cytoplasm that harbor keratin.

The stratum spinosum contains cells called prickly cells. These cells have small radiating processes that connect with other cells. Keratin is synthesized in this layer.

The stratum basale or basal cell layer contains epidermal stem cells. This is the deepest layer of the epidermis. It consists of one layer of cells that divide and begin their migration to the superficial layers. This is the layer where basal cell cancer develops.

As we have seen, there are a good number of keratinocytes located in the epidermis.

Psoriasis is an abnormality of keratinocytes. Keratinocytes abnormally divide rapidly and migrate from stratum basale to stratum corneum. Many immature cells reach the stratum corneum producing flaky, silvery scales (mostly on knees, elbows and scalp).

The epidermis also responds to the environment. Friction causes the formation of corns and calluses.

Another kind of cell found in the epidermis is the melanocyte. This cell produces the pigment melanin that gives skin its color. Melanocytes are located in the deepest portion of the epidermis and superficial dermis.

The color of the skin results from the activity of the melanocytes, not the number. Melanocytes are located in the deepest layer of the epidermis. They respond to ultraviolet radiation by producing more melanin pigment which turns skin a darker color. Melanocytes respond to UVB radiation (approximately 320 nm wavelength). The hair and middle layer of the eye contain melanocytes. A condition known as malignant melanoma can develop in melanocytes.

#### Vitamin D

The skin also helps to synthesize vitamin D. Vitamin D (aka cholecalciferol) is synthesized when a precursor molecule known as 7-dehydrocholesterol absorbs ultraviolet radiation. This molecule then travels to the liver and kidney where it is converted to the active form of vitamin D (1,25 hydroxycholecalciferol)(fig. 6.2).

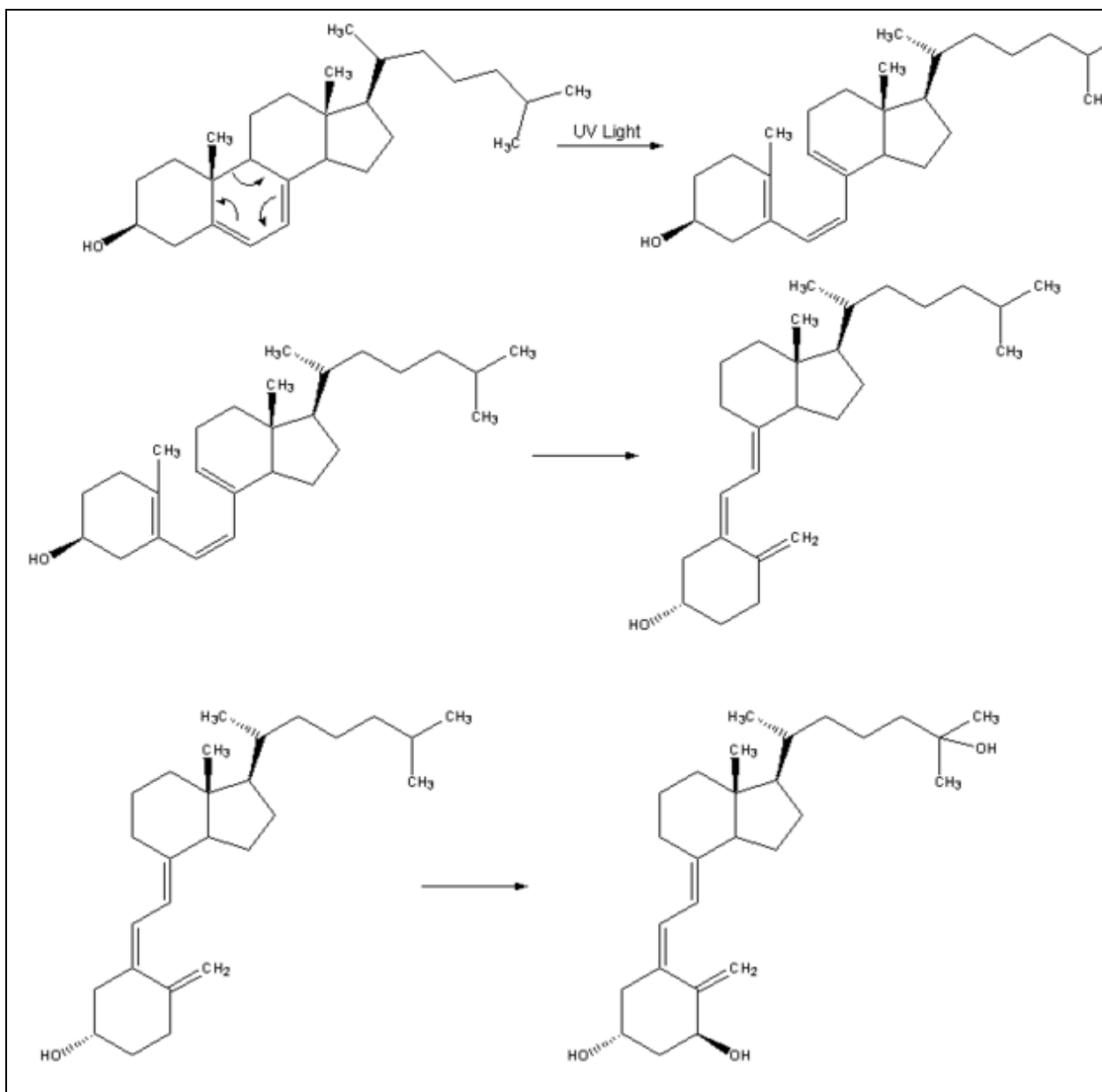


Figure 6.2. Vitamin D synthesis begins in the skin with the conversion of 7-dehydrocholesterol to cholecalciferol (row 1). Cholecalciferol travels to the liver and is converted to 25-hydrocholecalciferol (row 2). 25-hydrocholecalciferol in turn travels to the kidneys and is converted to the active form of Vit D (1,25 hydroxycholecalciferol).

<http://commons.wikimedia.org/wiki/Image:Calcitriol-Synthesis.png>



Vitamin D is an important substance in the body. It functions to help the body absorb calcium. It also works to help in calcium transport in the intestines.

### The Dermis

The dermis is the middle layer of the integument. The dermis consists of loose connective tissue and houses a number of accessory structures of the skin. The dermis connects to the epidermis by means of wavy structures called dermal papillae (fig. 6.3).

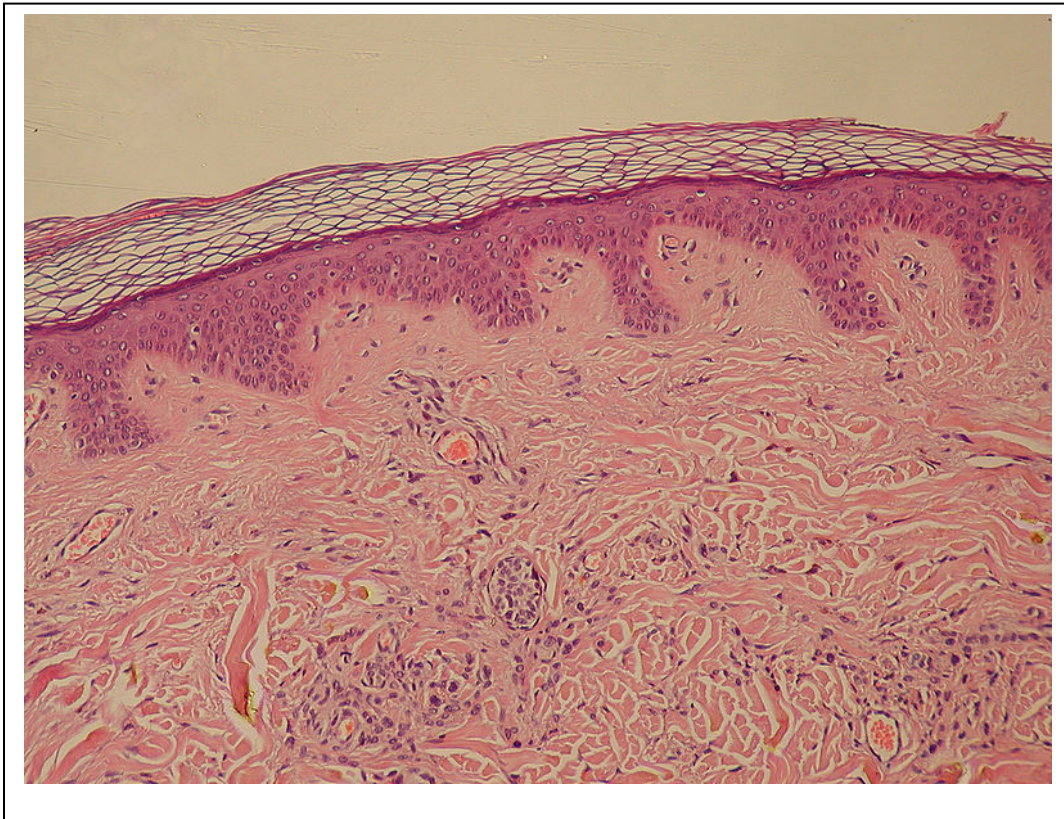


Figure 6.3. The integument. The epidermis (dark) connects to the dermis via wavy structures called dermal papillae.

[http://en.wikipedia.org/wiki/Image:Normal\\_Epidermis\\_and\\_Dermis\\_with\\_Intradermal\\_Nevus\\_10x.JPG](http://en.wikipedia.org/wiki/Image:Normal_Epidermis_and_Dermis_with_Intradermal_Nevus_10x.JPG)

## Structures of the Dermis

The dermis contains a variety of accessory structures of the integument (fig. 6.4). These include:

- Hair follicles
- Arrector pili muscles
- Sweat glands
- Sebaceous glands
- Sensory receptors
- Blood vessels

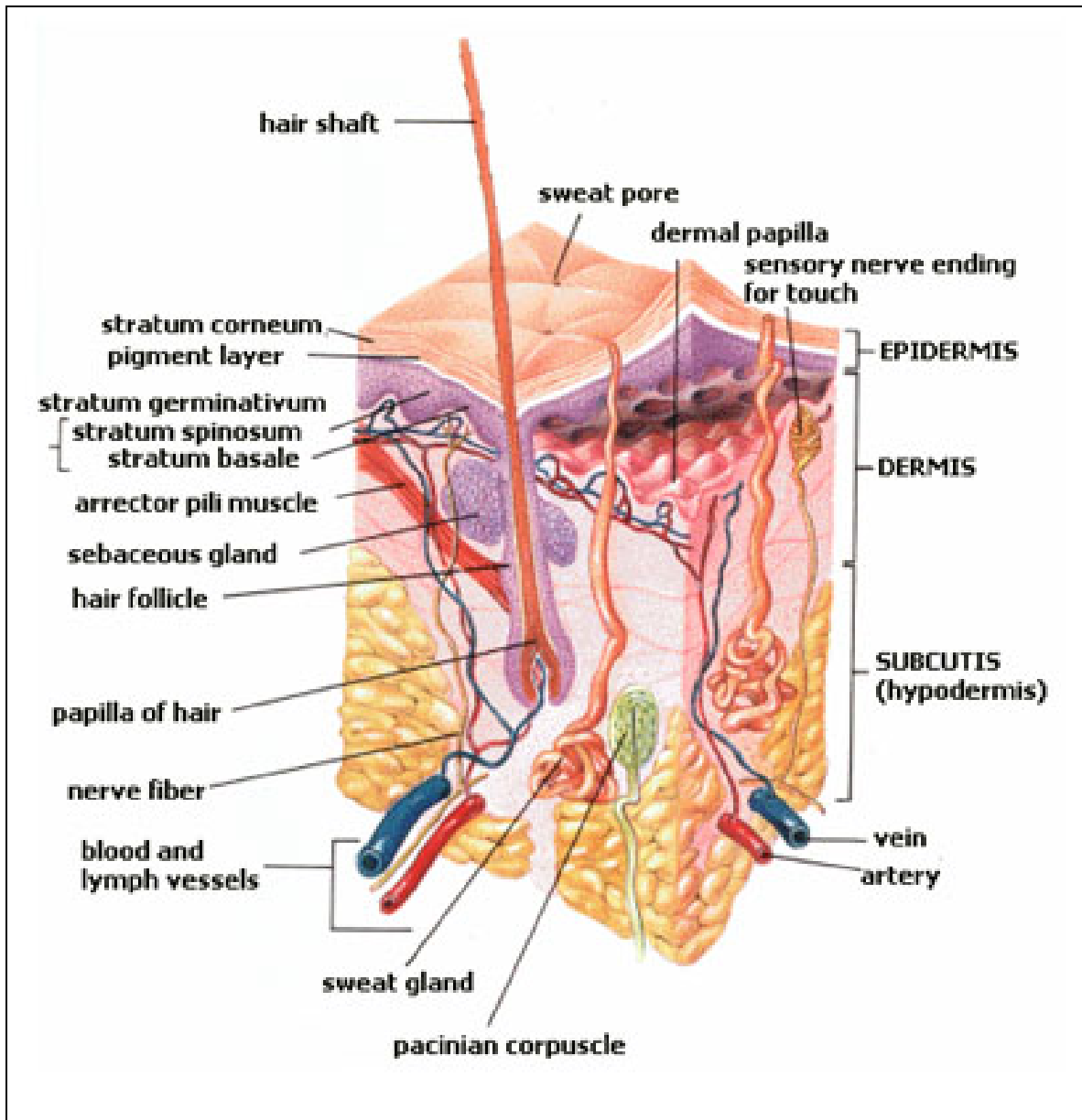


Figure 6.4. Integument. The dermis contains a number of accessory structures.

<http://commons.wikimedia.org/wiki/Image:Skin.jpg>

## **Hair Follicles/Sebaceous Glands**

The human body has approximately 2.5 million hairs on its surface. Hair is not found on the palms of the hands and soles of the feet as well as on the lips, parts of the external genitalia and sides of the feet and fingers. Hair is not alive and develops from old dead cells pushed outward by new cells. The cells contain keratin for hardness and melanin for color. Hairs can be very sensitive. This is due to a tiny plexus of nerves that surround each hair follicle. Hair is so sensitive that you can feel the movement of even a single hair.

A band of smooth muscle connects to each hair follicle. This structure, called an arrector pili muscle, is capable of moving each follicle causing it to stand up in times of sympathetic nervous system activity such as emotional stress.

Hair begins to grow at the base of the hair follicle in a structure called the hair bulb. The hair bulb is surrounded by a hair papilla that contains blood vessels and nerves. The cells of the hair bulb divide and push the cells toward the surface along the hair root and shaft.

Hair grows at a rate of about .33 mm per day. Normal adults lose about 50 hairs per day. A loss of over 100 hairs per day will cause a net loss of hair. This can happen especially in males due to changing levels of sex hormones (male pattern baldness).

There are 2 types of hair. Vellus hairs are the fine hairs located on much of your body's surface. Terminal hairs are thicker, more pigmented and are found on your head as well as genitals and axillary region.

A small sebaceous gland surrounds each hair follicle. The sebaceous glands secrete an oily substance known as sebum. Sebum is secreted in response to contraction of the arrector pili muscle. Sebum contains triglyceride, protein, cholesterol and some electrolytes. Sebum makes the hair more flexible and hydrated.

## **Sweat Glands**

Sweat glands (aka sudoriferous glands) are also located in the dermis. There are 2 types of sweat glands. Apocrine sweat glands secrete their substances into the hair follicles. The secretions of apocrine glands can develop odor. The odor can increase because the secretion acts as a nutrient for bacteria that enhance the odor. Apocrine glands begin to secrete substances at puberty and are located in the axilla and genital regions.

Eccrine sweat glands secrete their substances directly onto the surface of the skin. They are coiled tubular glands that secrete a substance that mostly consists of water with a trace of some electrolytes and a peptide with antibiotic properties. The eccrine sweat glands primary function is to help to regulate body temperature. The sweat can evaporate and carry away heat. The sweat also excretes water and electrolytes.

## Nails

The nails exist at the distal portions of the fingers and toes. The nail body is the visible portion of the nail sits over the nail bed. The nail begins deep in the skin proximal to where it is seen. It extends distally to beyond an area of thickened epidermis called the hyponychium. The nail begins to grow at the nail root which is close to the bone. A portion of the superficial epidermis (stratum corneum) extends over the proximal portion of the nail forming the eponychium or cuticle. Blood vessels deep to the nail give it a pink color. These vessels may be obscured leaving a white area known as the lunula.

Nails contain keratinized cells that are pushed from the root to the distal portions. The nails can reflect health problems. Some of these include:

- Bluish nails = circulatory problems.
- White nail = anemia
- Pigmented spot under nail = possible melanoma.
- Horizontal grooves = malnutrition.
- Clubbing= heart, lungs, liver problems.
- Red streaks = rheumatoid arthritis, ulcer, high blood pressure.
- Spoon nails=iron deficiency anemia

## Temperature Regulation

The skin is very important in regulating body temperature. The skin helps keep in heat produced by skeletal muscles and liver cells. When the body gets too hot the skin opens up the sweat pores so that the sweat can carry the heat away by evaporation.

Heat can be lost by the body in a number of ways. Heat always moves along a gradient from warmer to cooler temperatures. Heat can radiate from the body to the surrounding areas at lower temperatures. In conduction, heat moves via molecules from the warmer body to cooler objects. An example of conduction would be to lean against a cooler concrete wall. The heat flows from your body into the wall. In convection, heat moves via air molecules circulating around body. In evaporation fluid on the surface of the body carries heat away.

Body temperature is primarily regulated by an area in the brain known as the hypothalamus. The hypothalamus sets the body's temperature and controls it by opening and closing sweat glands and contracting muscles.

Let's say that it is a hot summer day and you are working hard mowing the lawn. As your body's temperature rises the hypothalamus senses this and sends a message to your sweat glands to open. The sweat evaporates off of your skin and you begin to cool down.

Now let's say that you've finished mowing the lawn and you go inside of your air conditioned home. Your body's temperature will begin to drop. The hypothalamus senses this and sends a

message to your sweat glands to close. If your body's temperature continues to drop the hypothalamus may send a message to your muscles to contract or shiver. The muscles will generate heat to help maintain your core temperature. In more severe cases of cold your blood vessels will constrict in your extremities in an attempt to conserve heat at the core of your body for survival.

If your core body temperature continues to drop you may develop a condition called hypothermia. You will progress from feeling cold to shivering, experiencing mental confusion, lethargy, loss of reflexes and eventually loss of consciousness and shutting down of organs.

Conversely if your core body temperature increases too much, you can develop hyperthermia. This can develop in humid conditions because of lack of evaporation. The signs of hyperthermia include light headedness, dizziness, headaches, muscle cramps, fatigue and nausea.

## **Skin Repair**

The skin has remarkable healing properties. It can heal cuts, bruises and burns.

A cut is known as a laceration. If the cut extends only into the epidermis the epidermal cells will divide rapidly to repair the skin.

If the cut extends into the dermis broken blood vessels form clot. The clot forms from fibrin which is a product of blood cells. Fibroblasts collect in the injured area and grow new collagen fibers.

Burns are described in 3 categories.

First degree burns are known as superficial partial thickness burns. Only the epidermis is affected. First degree burns usually heal quickly because growth occurs from the deeper layers of the dermis.

Second degree burns are known as deep partial thickness burns. In second degree burns the epidermis and some of the dermis is damaged. Fluid accumulates between the dermis and outer layer of epidermis forming blisters. The skin becomes discolored from dark red to waxy white. Healing depends on the accessory organs of skin because new cell growth emerges from these layers.

Third degree burns involve the epidermis, dermis and accessory organs. Third degree burns are called full thickness burns. In third degree burns there is no new cell growth from the damaged area. Growth can only occur from the margins of the burn. Skin substitutes can be used to cover the skin while healing. These include amniotic and artificial membranes and cultured epithelial cells. Skin grafts can also be used.

## **Real World A&P Blog Post**

### **Vit D, Cancer and the Winter Blues**

It has been a long and nasty winter here in the upper Midwest. Today as I sit writing this entry I look out the window and see the freezing rain turning to snow while the gray skies shed little light. I feel like hibernating and find it difficult to get up the ambition to go outside and fight the elements. I did manage to do so and skated across the frozen driveway covered with freezing rain to drive to my favorite writing spot--a local coffee shop.

We northerners obviously don't get as much sun as our southern neighbors. Yes, we have less incidence of skin cancer but we also can end up with less of an important vitamin that is synthesized right in our skin. This vitamin is vitamin D.

Why is vitamin D so important? Well, recently Dr. Louise Parker, an international expert on cancer has some good things to say about vitamin D. According to Dr. Parker, vitamin D deficiencies have been turning up in a number of cancers such as lung and colon cancer. Even the Canadian Cancer Society is now recommending 1000 mg of vitamin D during the long Canadian winter months.

As a nutritional consultant I have recommended vitamin D for women to help counter the effect of osteoporosis, especially during menopause. There is an important link between estrogen and calcium absorption. Low estrogen inhibits the absorption of calcium and vitamin D facilitates it. Now research that has followed women taking vitamin D with osteoporosis has also shown a decrease in cancers. This may indicate an important link between the two.

Vitamin D has also been shown to inhibit MS and ward off the winter blues.

Vitamin D is a fat soluble vitamin but has little risk of causing harm. Dr. Parker recommends a dose of 1000 mg/day during the winter months.

References:

Dalhousie University (2008, February 16). A Ray Of Sunshine In The Fight Against Cancer: Vitamin D May Help.

## Review Questions Chapter 6

1. Which of the layers of the epidermis only exist on the palms of the hands and the soles of the feet:
  - a. Stratum corneum
  - b. Stratum lucidum
  - c. Stratum basale
  - d. Basement membrane
2. Which of the layers of the epidermis contains hardened keratinized cells:
  - a. Stratum lucidum
  - b. Stratum basale
  - c. Stratum granulosum
  - d. Stratum corneum
3. Which of the following chemicals is responsible for skin color:
  - a. Keratin
  - b. Melanin
  - c. Vit D
  - d. Collagen
4. Vit D is synthesized in the skin by the action of \_\_\_\_\_
  - a. Melanin
  - b. UV radiation
  - c. Keratin
  - d. Vit A
5. Sweat glands consist of 2 types including:
  - a. Eccrine and apocrine
  - b. Holocrine and eccrine
  - c. Apocrine and sudoris
  - d. Sebaceous and eccrine
6. Which of the following is not a constituent of sebum:
  - a. Triglyceride
  - b. Protein
  - c. Electrolytes
  - d. Sucrose

7. A structure located in the dermis that allows for hair to stand on end is known as:
- Arrector pili muscle
  - Levator papillae muscle
  - Tertiary protein
  - Erector muscle
8. A patient presents with red streaks in their nails. What could this mean:
- Obesity
  - Low blood pressure
  - Pulmonary problems
  - High blood pressure
9. Spoon nails may indicate:
- High blood pressure
  - Iron deficiency anemia
  - Malnutrition
  - Pulmonary problems
10. Body temperature is regulated by:
- Hypothalamus
  - Sensory receptors in the skin
  - Brain stem
  - Thalamus
11. Which of the following should not happen in response to a lower than normal body temperature:
- Shivering
  - Vasoconstriction in extremities
  - Opening of sweat glands
  - Closing of sweat glands
12. The type of burn where healing must occur from the outer margins is called:
- First degree
  - Second degree
  - Third degree
  - Fourth degree



# Chapter 7

## The Skeletal System

## The Skeletal System

The skeletal system not only helps to provide movement and support but also serves as a storage area for calcium and inorganic salts and a source of blood cells. The adult human body has 206 bones in a variety of shapes and sizes. Basically there are 4 types of bones categorized according to shape:

- Long bones have a long longitudinal axis (fig. 7.1).
- Short bones have a short longitudinal axis and are more cube-like.
- Flat bones are thin and curved such as some of the bones of the skull.
- Irregular bones are often found in groups and have a variety of shapes and sizes.

There are also 2 types of bone tissue in different amounts in bones. Compact bone (sometimes called cortical bone) is very dense. Cancellous bone (sometimes called spongy bone) looks more like a trabeculated matrix (fig. 7.2). It is found in the central regions of some of the skull bones or at ends (epiphyses) of long bones. The bone forming cells (osteocytes) get their nutrients by diffusion.

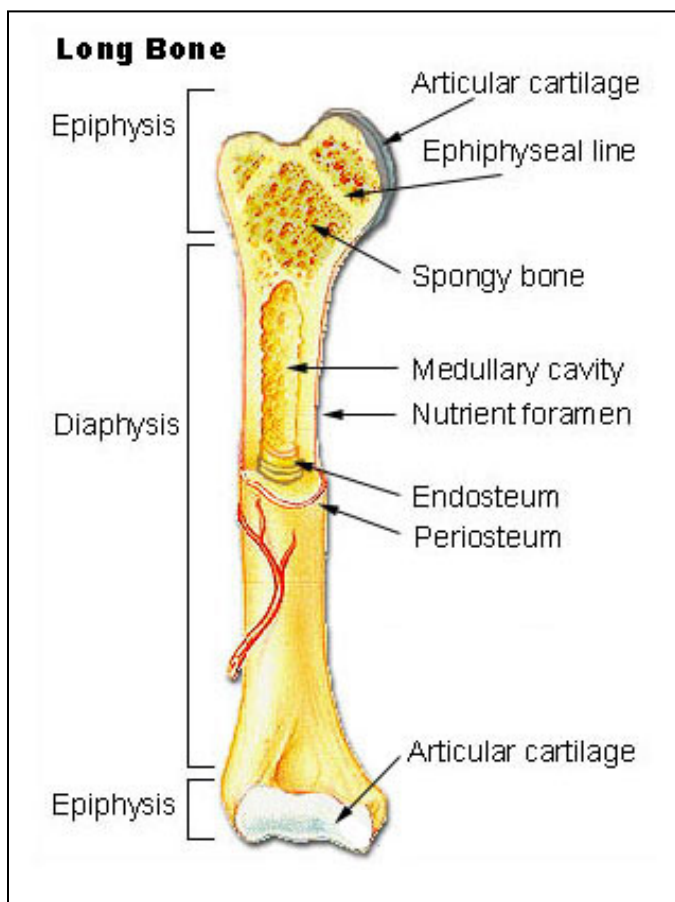


Figure 7.1. Parts of a long bone. Notice the long shaft or diaphysis in the middle of the bone. The diaphysis contains compact bone surrounding a medullary cavity containing bone marrow. On either end is an epiphysis containing cancellous or spongy bone. The epiphyseal line is a remnant of the growth plate. The epiphyses also contain hyaline cartilage for forming joints with other bones. Surrounding the bone is a membrane called the periosteum. The periosteum contains blood vessels and cells that help to repair and restore bone.

[http://commons.wikimedia.org/wiki/Image:Illu\\_long\\_bone.jpg](http://commons.wikimedia.org/wiki/Image:Illu_long_bone.jpg)

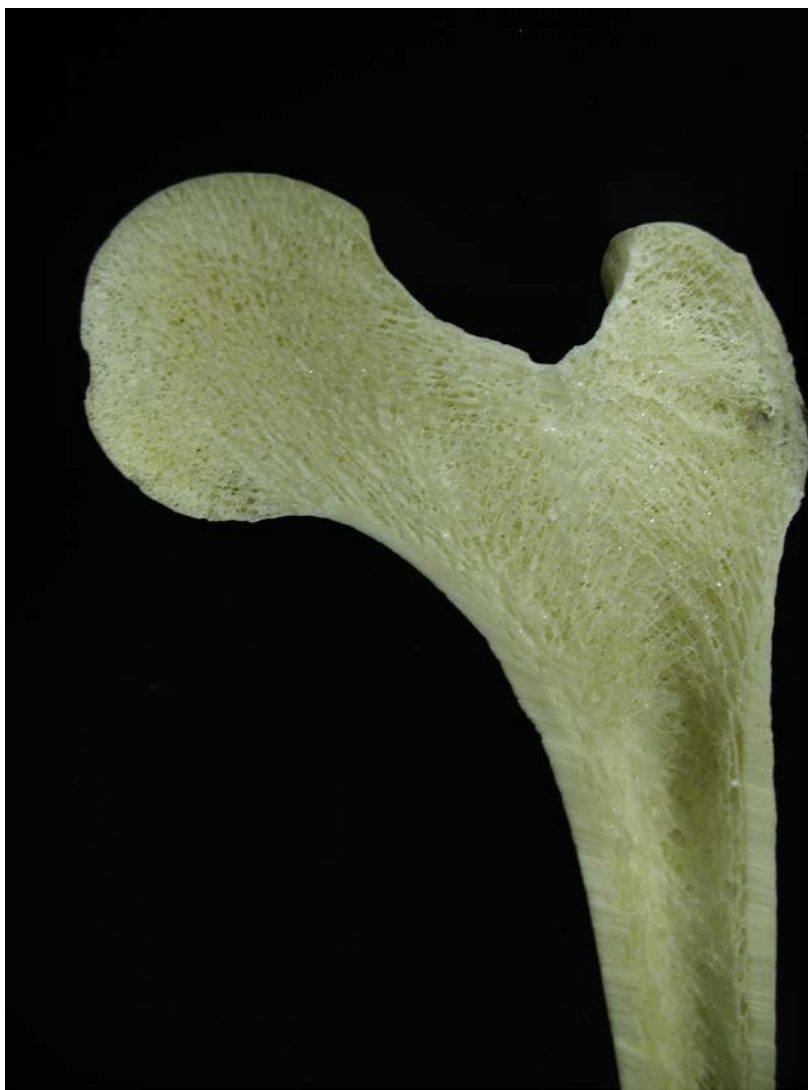

Figure 7.2. Trabecular and cortical bone of the femur. Notice the spongy appearance of the trabeculated bone. The cortical bone is located near the margins of the bone and is more dense.

Bruce Forciea

## Bone Structure

Compact bone is organized according to structural units called Haversian systems or osteons (fig. 7.3). These are located along the lines of force and line up along the long axis of the bone. The Haversian systems are connected together and form an interconnected structure that provides support and strength to bones.

Haversian systems contain a central canal (Haversian canal) that serves as a pathway for blood vessels and nerves. The bone is deposited along concentric rings called lamellae. Along the lamellae are small openings called lacunae. The lacunae contain fluid and bone cells called osteocytes. Radiating out in all directions from lacunae are small canals called canaliculi. Haversian systems are interconnected by a series of larger canals called Volkmann's canals (perforating canals).

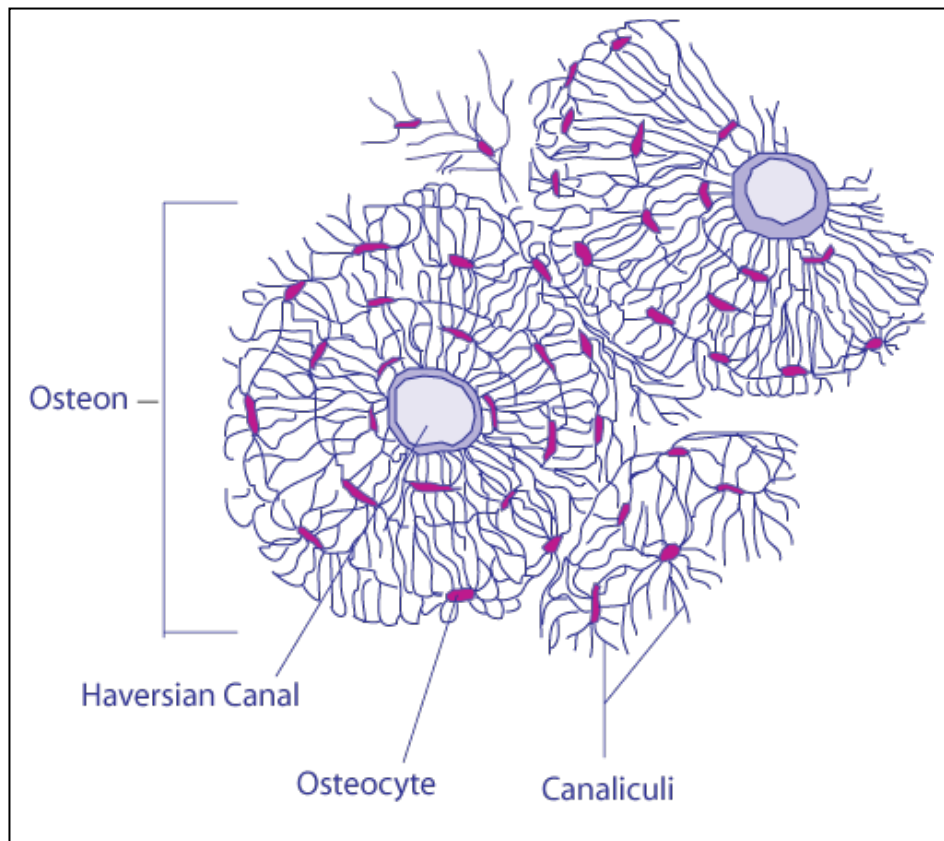


Figure 7.3. Haversian system.

[http://commons.wikimedia.org/wiki/Image:Transverse\\_Section\\_Of\\_Bone.png](http://commons.wikimedia.org/wiki/Image:Transverse_Section_Of_Bone.png)

Contributed by the following user: <http://en.wikipedia.org/wiki/User:Bduttabaruah>

## Bone Cells

There are 3 basic types of cells in bone. Osteoblasts undergo mitosis and secrete a substance that acts as the framework for bone. Once this substance (called osteoid) is secreted minerals can deposit and form hardened bone. Osteoblasts respond to certain bone forming hormones as well as from physical stress. Osteocytes are mature osteoblasts that cannot divide by mitosis (fig. 7.4). Osteocytes reside in lacunae. Osteoclasts are capable of demineralizing bone. They free up calcium from bone to make it available to the body depending on the body's needs.

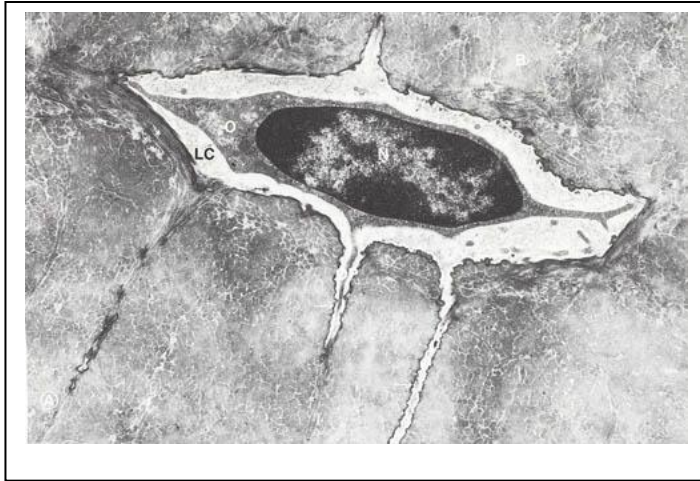


Figure 7.4. Osteocytes are mature osteoblasts that reside in a lacuna. They are surrounded by bony matrix.

[http://commons.wikimedia.org/wiki/Image:Osteocyte\\_2.jpg](http://commons.wikimedia.org/wiki/Image:Osteocyte_2.jpg)

## Bone Marrow

Bone marrow is located in the medullary (marrow) cavity of long bones and in some spongy bones. There are 2 kinds of marrow. Red marrow exists in the bones of infants and children. It is called red because it contains a large number of red blood cells. In adults the red marrow is replaced by yellow marrow. It is called yellow because it contains a large proportion of fat cells. Yellow marrow decreases its ability to form new red blood cells. However, not all adult bones contain yellow marrow. The following bones continue to contain red marrow and produce red blood cells:

- Proximal end of humerus
- Ribs
- Bodies of vertebrae
- Pelvis
- Femur

## **Bone Growth**

Bones begin to grow during fetal development and complete the growth process during young adulthood. There are 2 bone forming processes. Flat bones called intramembraneous bones develop in sheet like layers. Tubular bones called endochondral bones develop from cartilage templates.

### **Intramembraneous Ossification**

Flat bones such as some of the bones of the skull develop from a process called intramembraneous ossification. During this process bones form from sheet-like layers of connective tissue. These layers have a vascular supply and contain bone forming cells called osteoblasts. The osteoblasts secrete bony matrix in all directions around the cell. The matrix unites with that secreted by other osteoblasts as the bone forms. Eventually the osteoblasts may be walled off by the bony matrix. At this point the osteoblast is called an osteocyte.

### **Endochondral Ossification**

Tubular bones develop from a process known as endochondral ossification. During this process bones develop from hyaline cartilage templates. The template is surrounded by an area called the perichondrium. The perichondrium will become the periosteum (outer covering of bone) as the bone develops. Chondrocytes in the cartilage begin to secrete bony matrix and eventually wall themselves off in lacunae. Next, blood vessels extend into the bone and transport osteoblasts and osteoclasts from the perichondrium forming a primary ossification center. The bone continues to grow in a cylindrical fashion. Eventually blood vessels enter the calcified matrix of the epiphyses and form secondary ossification centers. Osteoclasts remove matrix from the center of the diaphysis to form a medullary cavity. The secondary ossification centers form about 1 month before birth. Bone continues to form from the cartilage until all of the cartilage is replaced except for the epiphyseal plates. These will complete their calcification in young adulthood (fig. 7.5).

### **Epiphyseal Plates**

Bone grows longitudinally as the epiphyseal plates secrete bony matrix. There are 4 zones in epiphyseal plates:

1. Zone of resting cartilage. This zone contains chondrocytes that do not divide rapidly.
2. Zone of proliferation. This zone contains active chondrocytes that produce new cartilage.
3. Zone of hypertrophy. In this zone chondrocytes from the zone of proliferation mature and enlarge.
4. Zone of calcification. In this zone the enlarged chondrocytes are replaced by osteoblasts from the endosteum. The osteoblasts secrete bone that calcifies the area.

As the chondrocytes produce cartilage and hypertrophy the bone grows on the diaphyseal side of the plate. The plate remains the same thickness because ossification on both sides of the plate occurs at the same rate. The epiphyseal plates complete their growth and ossify between the ages of 12-25 years depending on the bone.

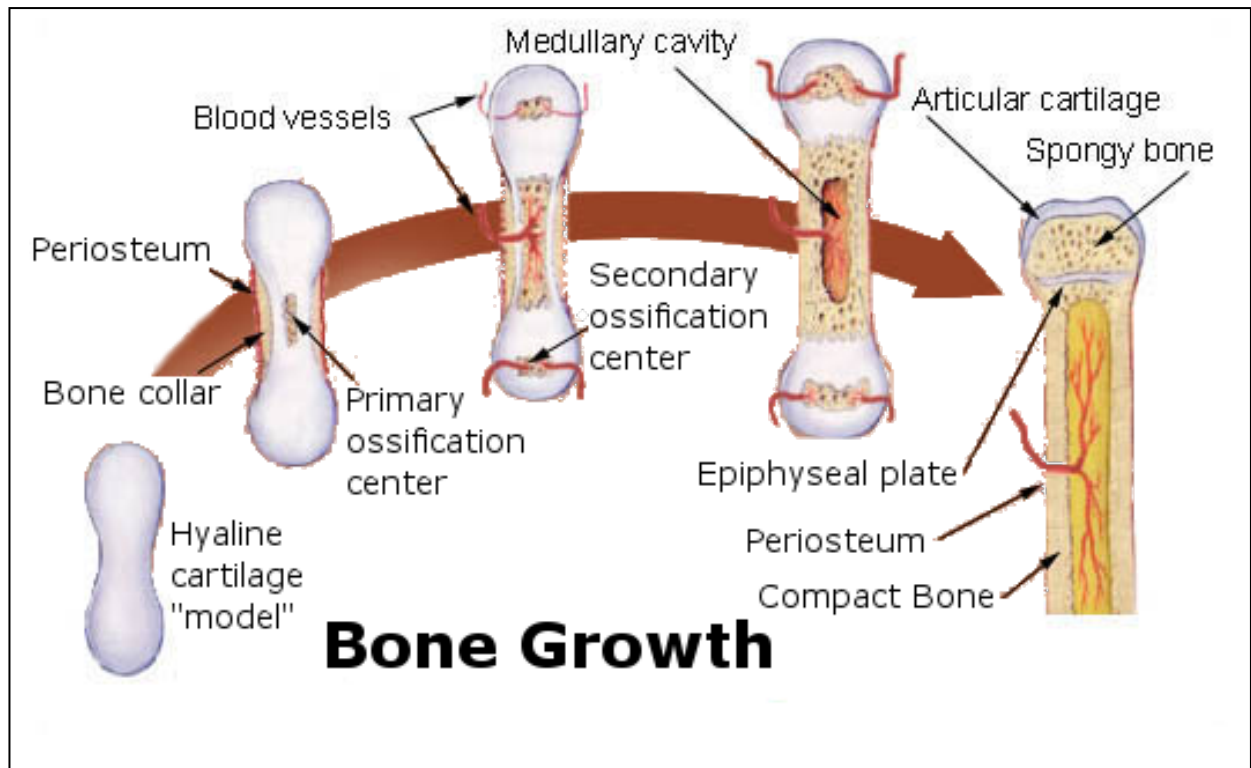


Figure 7.5. Endochondral ossification.

[http://commons.wikimedia.org/wiki/Image:Bone\\_growth.png](http://commons.wikimedia.org/wiki/Image:Bone_growth.png)

### Bone Growth Factors

The length of bones and subsequent height of an individual are determined genetically. However there are other factors that affect the expression of genes that in turn can affect bone growth. These include certain hormones, nutrition, and exercise.

Growth hormone is a hormone secreted by the anterior portion of the pituitary gland. Growth hormone stimulates protein synthesis and growth of cells in the entire body including bones. Thyroxine is secreted by the thyroid gland and increases osteoblastic activity in bones. Calcitrol is secreted by the kidneys and helps the digestive tract absorb calcium. The synthesis of calcitrol depends on vitamin D (see the integumentary system section). Sex hormones from the ovaries and testes also stimulate osteoblastic activity.

Vitamins such as vitamin D, C, A, K and B12 are also important in bone growth. Vitamin C is required for collagen synthesis and stimulates osteoblastic activity. A lack of vitamin D can lead to a condition called Rickets in children or osteomalacia in adults. Rickets is characterized by malformed bones (fig. 7.6). Calcium and phosphorus must be adequately supplied by the diet for use in boney matrix. Vitamin A stimulates osteoblastic activity and vitamins K and B12 are needed for protein synthesis in bone cells.

Bone grows according to the imposed demands of the body. This is known as Wolf's law. In other words the body produces bone along lines of force. For example weight bearing exercises will increase the strength of bones. Likewise bones that are cast during the healing process for fractures will be weaker. This is one reason that weight-bearing exercise is recommended for those predisposed to osteoporosis.

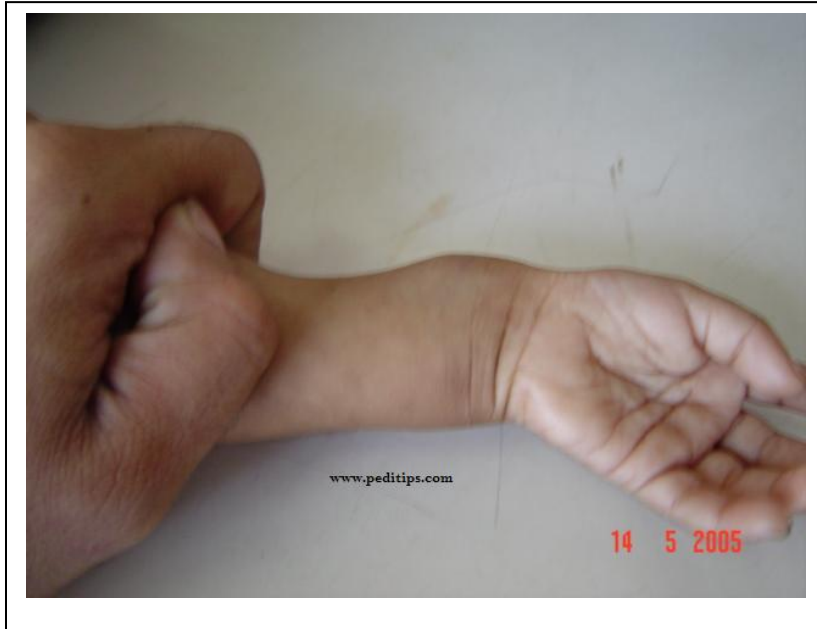

Figure 7.6. Rickets is characterized by malformed bones.

[http://commons.wikimedia.org/wiki/Image:Rickets\\_wrist.jpg](http://commons.wikimedia.org/wiki/Image:Rickets_wrist.jpg)

## Fractures

There are many ways bones can break or fracture. Closed fractures are contained within the body. Closed fractures are also called “simple” and are contained within the surrounding tissues that help them to heal. Open fractures protrude through the skin and are more dangerous because of the risk of infection and bleeding. Complete fractures go all the way through a bone and incomplete fractures only go partially through a bone (figs. 7.7-7.10).



Other types of fractures include the following:

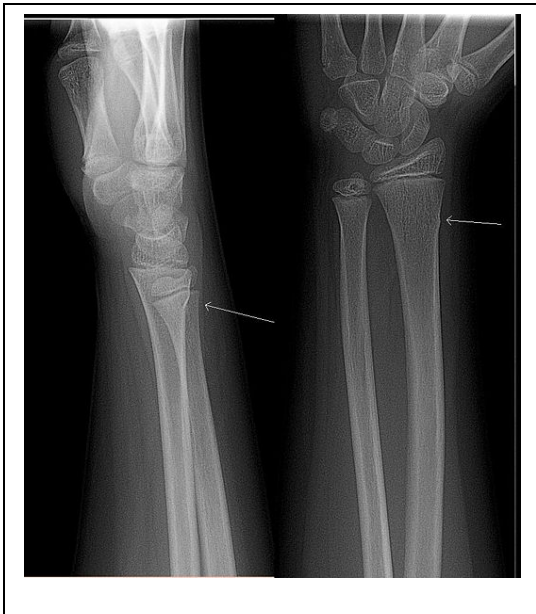

Figure 7.7. Greenstick fractures occur on the convex side of the bone and are incomplete.

<http://commons.wikimedia.org/wiki/File:Greenstick.jpg>

Author: [Lucien Monfils](#)

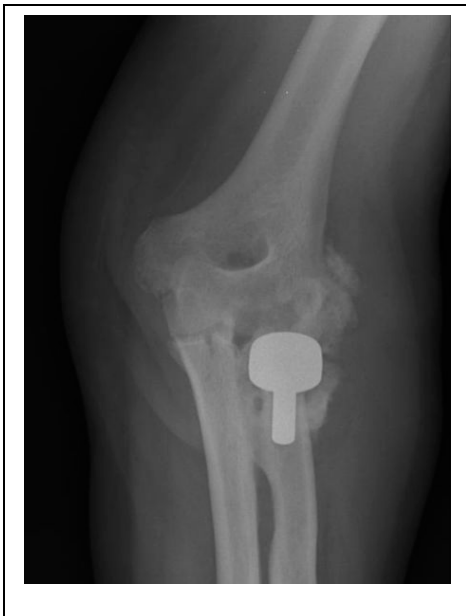

Figure 7.8. Comminuted fractures can be described as a shattering of bone. This picture illustrates a comminuted fracture of the elbow with some hardware.

[http://commons.wikimedia.org/wiki/Image:Heterotopic\\_Ossification\\_Elbow2.JPG](http://commons.wikimedia.org/wiki/Image:Heterotopic_Ossification_Elbow2.JPG)

Author: <http://commons.wikimedia.org/wiki/User:Tdvorak>

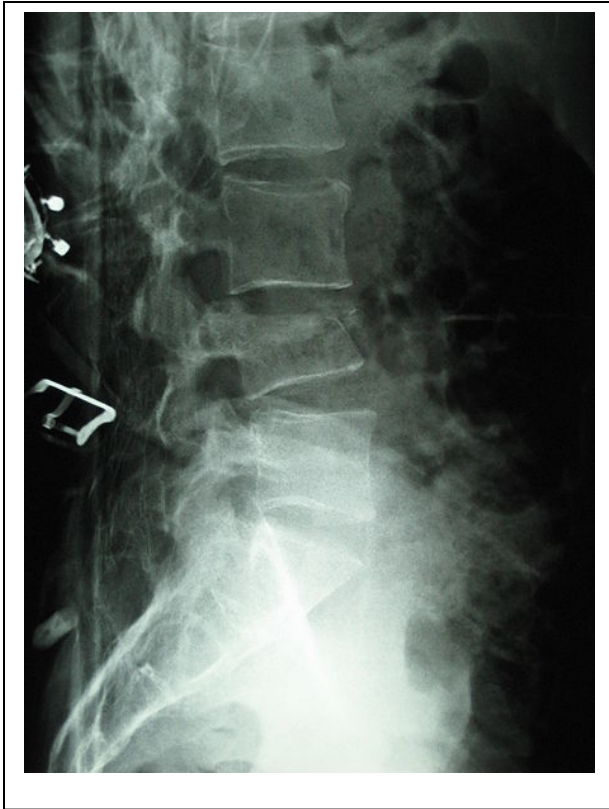


Figure 7.9. Compression fracture. A compression fractures occur when bones are subjected to axial forces. Notice the trapezoidal vertebral body.

[http://commons.wikimedia.org/wiki/Image:L4\\_compressionFracture2008.jpg](http://commons.wikimedia.org/wiki/Image:L4_compressionFracture2008.jpg)

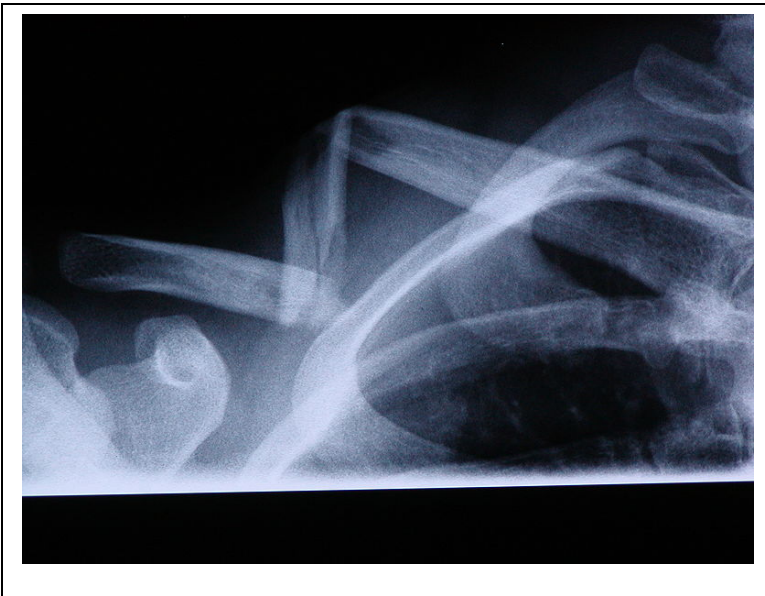


Figure 7.10. Fracture of the clavicle.

<http://commons.wikimedia.org/wiki/Image:Claviculafraktur.JPG>

## Healing Fractures

Bone has remarkable healing properties. Bones heal from fractures in about 6 weeks. Shortly after a fracture occurs a hematoma forms. This fracture hematoma produces a fibrous network for repair. Next cells of the periosteum and endosteum undergo rapid mitosis with new cells moving into the damaged area. The new cells form a callus. The external portion of the callus consisting of cartilage and bone extends around the damaged area. The internal portion is located in the marrow cavity. Cells in the callus differentiate into osteoblasts and begin to secrete boney matrix. Spongy bone forms and replaces the cartilage of the external callus. This provides strength to the damaged area. Finally, osteoblasts and osteoclasts work to remodel the damaged area for up to a year. The callus disappears leaving only a remnant line. The bone is as strong as it was previous to the fracture.

## The Axial Skeleton

The skeleton is divided into 2 sections: the axial and appendicular sections. The axial skeleton includes the skull, spine, ribcage, and sacrum (fig 7.11).

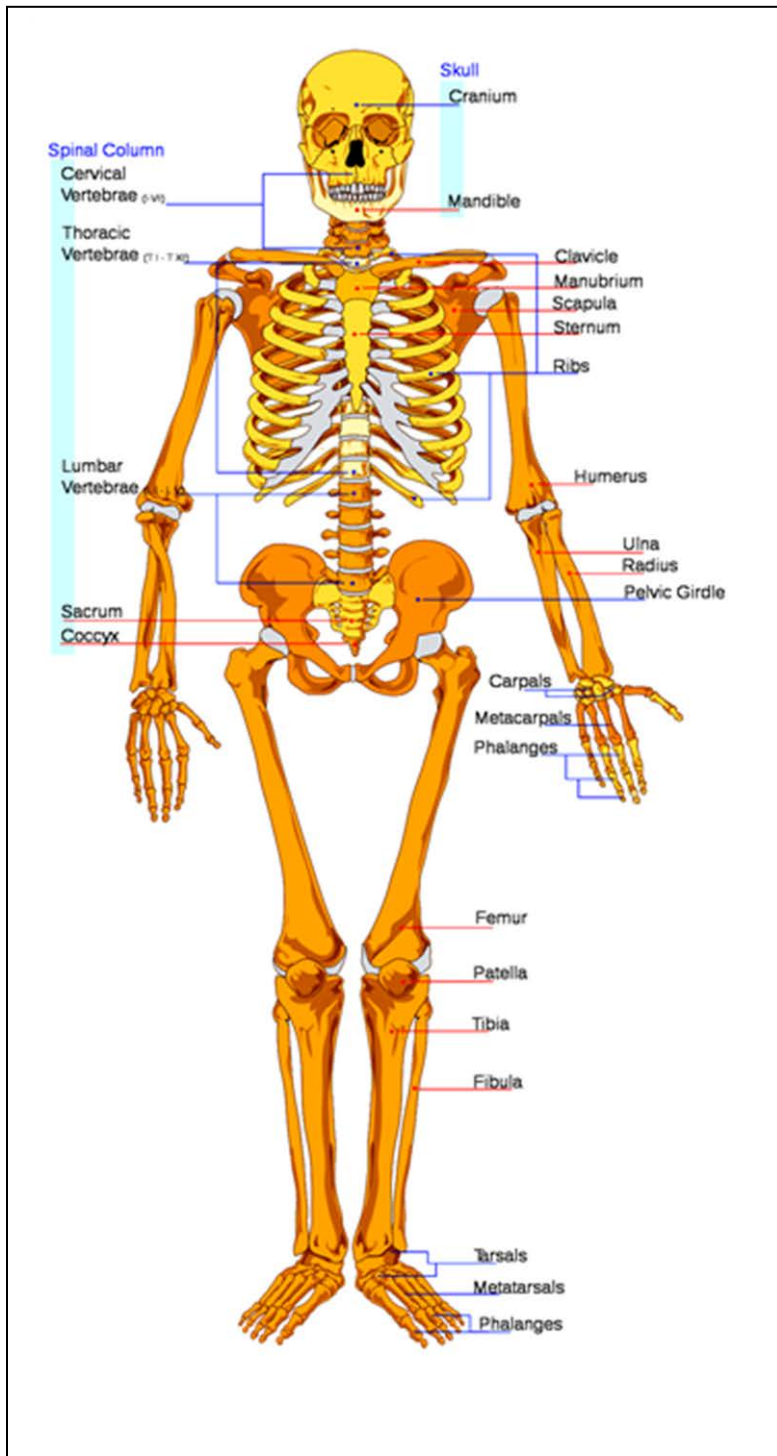


Figure 7.11. The skeleton.

[http://commons.wikimedia.org/wiki/File:Human\\_skeleton\\_front\\_ms.svg](http://commons.wikimedia.org/wiki/File:Human_skeleton_front_ms.svg)

## **The Bones of the Skeleton**

### **The Skull**

The skull contains the brain and sensory structures such as the eyes, ears, nasal passages, and mouth. There are 22 bones in the skull with 8 forming the cranium (figs. 7.12-7.15). The 8 bones of the cranium include:

1. Frontal
2. Occipital
3. Right Parietal
4. Left Parietal
5. Right Temporal
6. Left Temporal
7. Sphenoid
8. Ethmoid

The bones are held together by special joints called sutures. These joints are considered immovable and are composed of dense fibrous connective tissue (figs. 7.16, 7.17).

The sutures include:

- Sagittal suture—connects the parietal bones at the top of the skull. It lies in the sagittal plane.
- Coronal suture—connects both parietal bones to the frontal bone on the top of the skull. It lies in a coronal plane.
- Lambdoidal suture—connects the occipital bone to the posterior portions of the parietal bones.
- Squamosal suture—connects the parietal bones to the temporal bones.

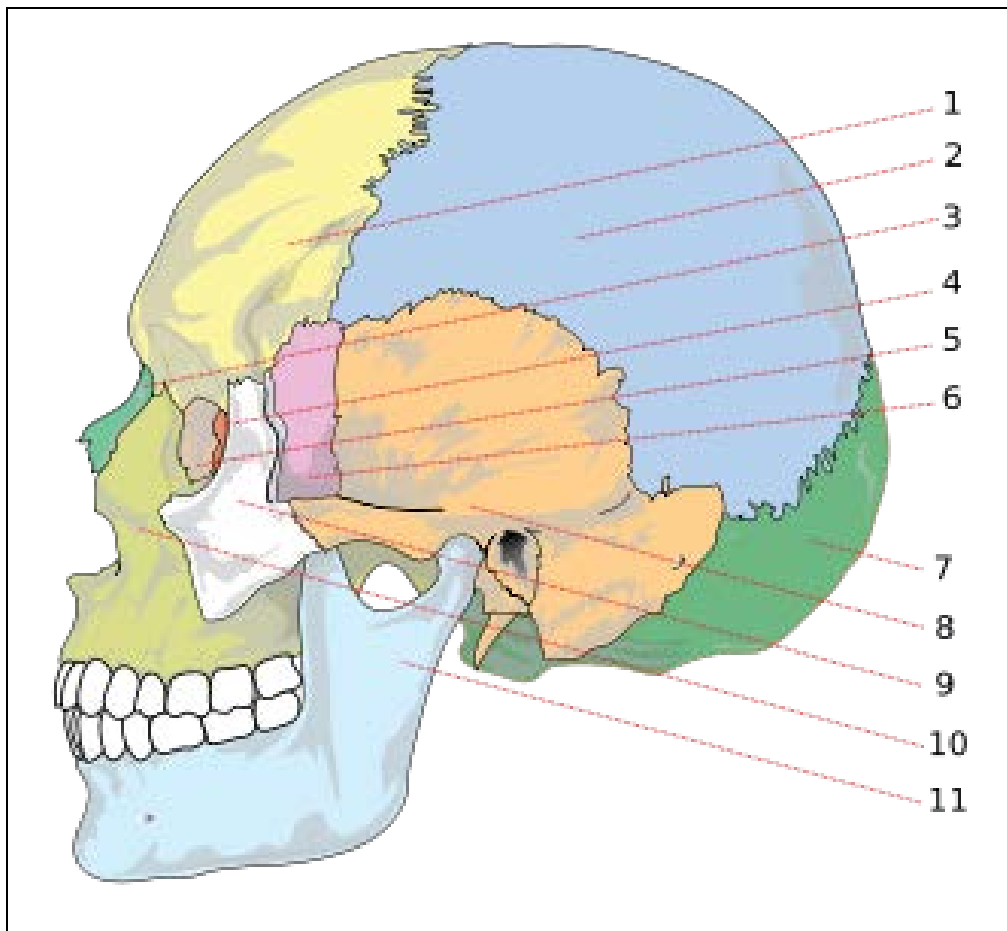


Figure 7.12. The skull.

1. Frontal
2. Parietal
3. Nasal
4. Lacrimal
5. Ethmoid
6. Sphenoid
7. Occipital
8. Temporal
9. Zygomatic
10. Maxilla
11. Mandible

[http://commons.wikimedia.org/wiki/Image:Human\\_skull\\_side\\_bones\\_numbered.svg](http://commons.wikimedia.org/wiki/Image:Human_skull_side_bones_numbered.svg)

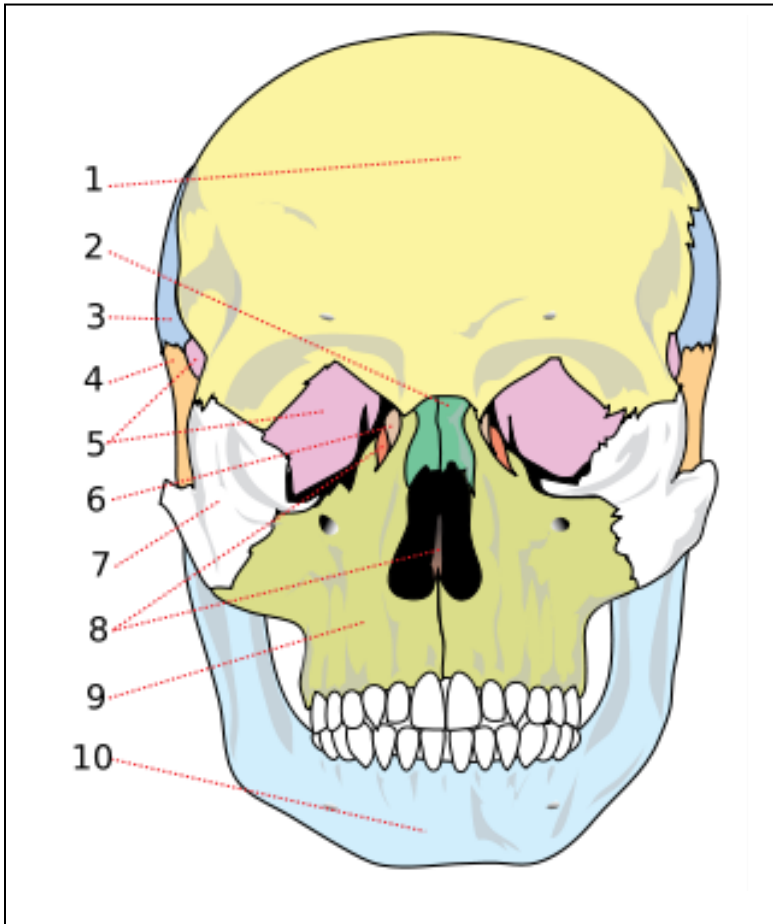


Figure 7.13. The Skull

1. Frontal
2. Nasal
3. Parietal
4. Temporal
5. Sphenoid
6. Ethmoid
7. Zygomatic
8. Ethmoid
9. Maxilla
10. Mandible

[http://commons.wikimedia.org/wiki/Image:Human\\_skull\\_front\\_bones\\_numbered.svg](http://commons.wikimedia.org/wiki/Image:Human_skull_front_bones_numbered.svg)

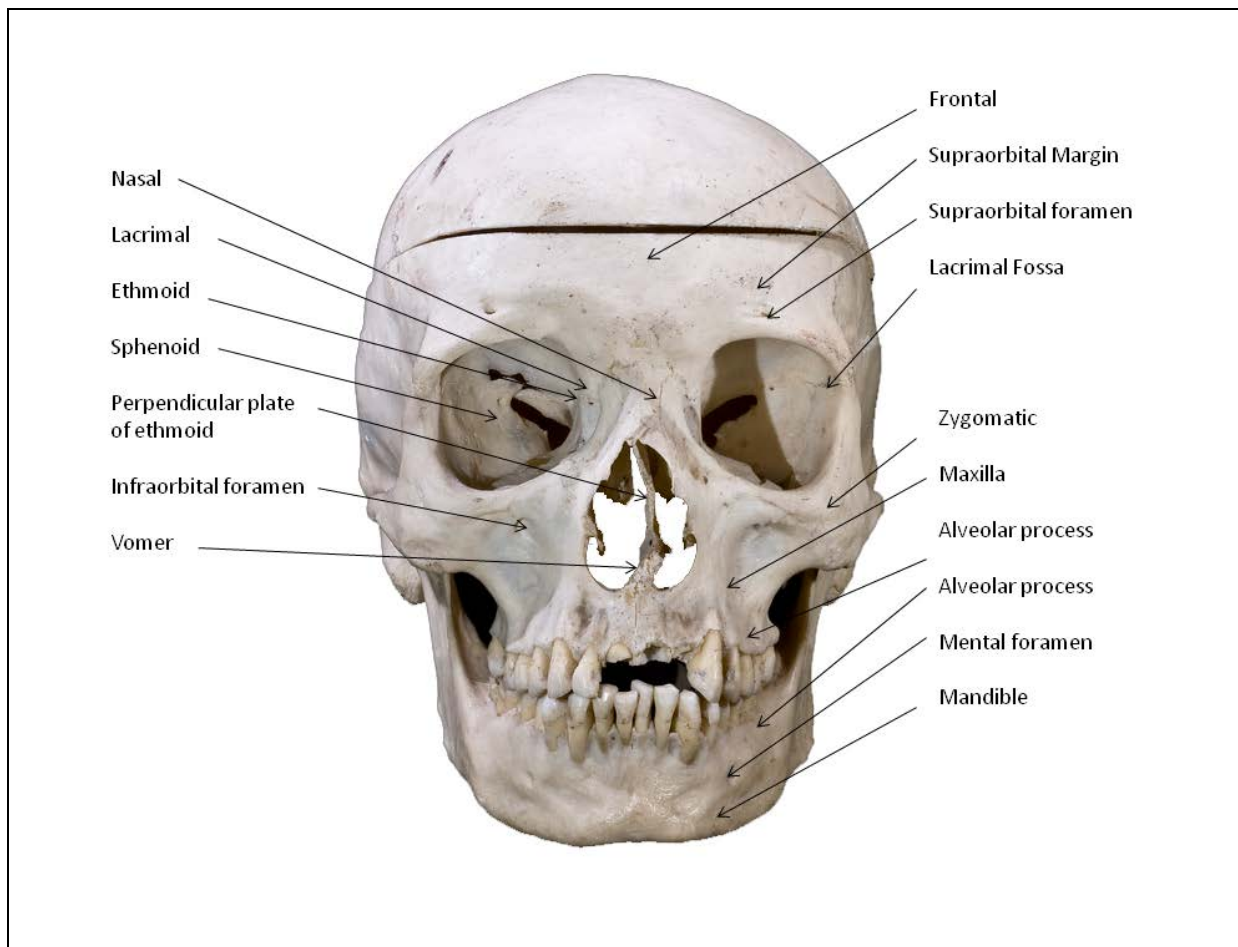


Figure 7.14 Anterior photograph of the skull.

Bruce Forciea



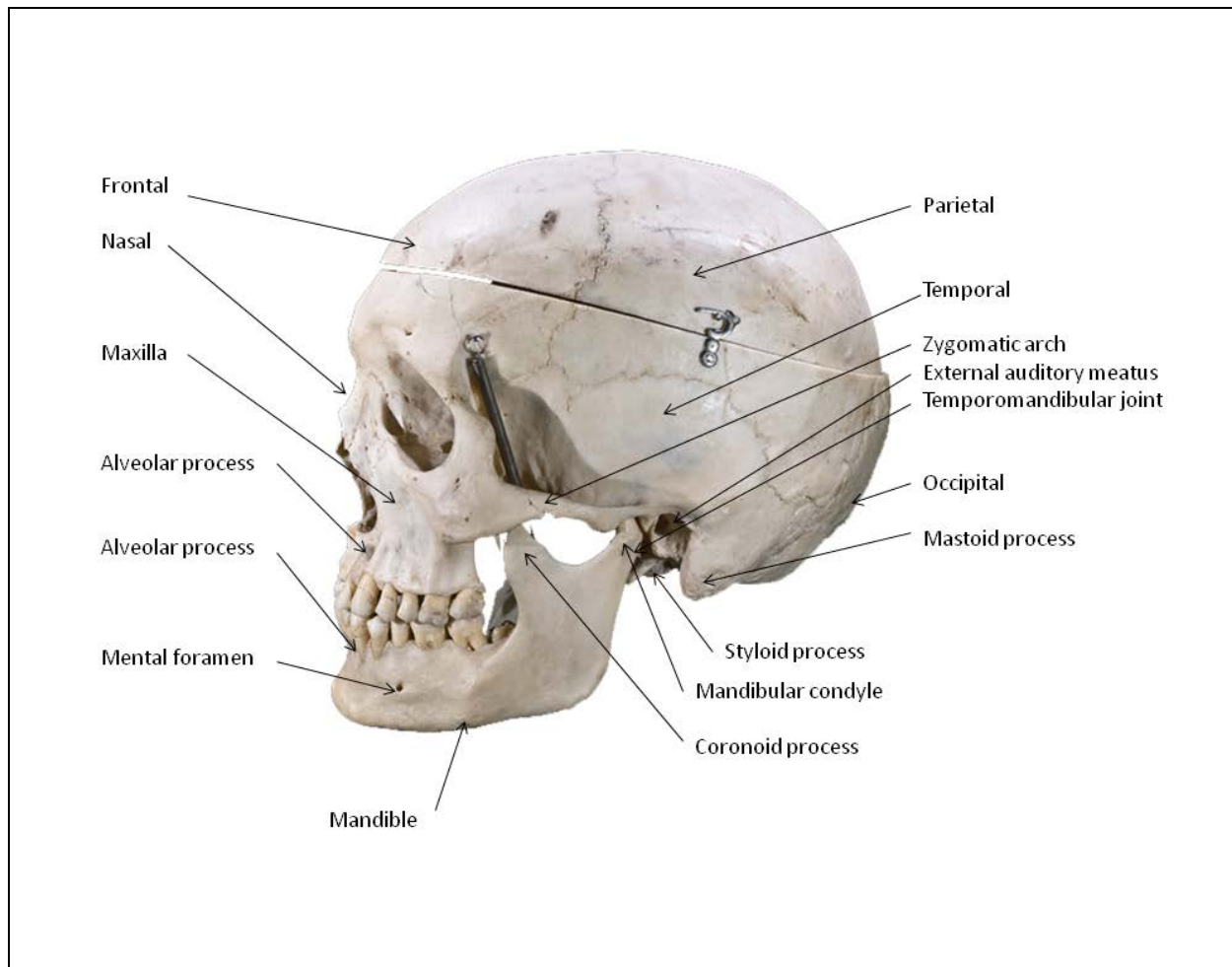


Figure 7.15. Photograph of lateral skull.

Bruce Forciea

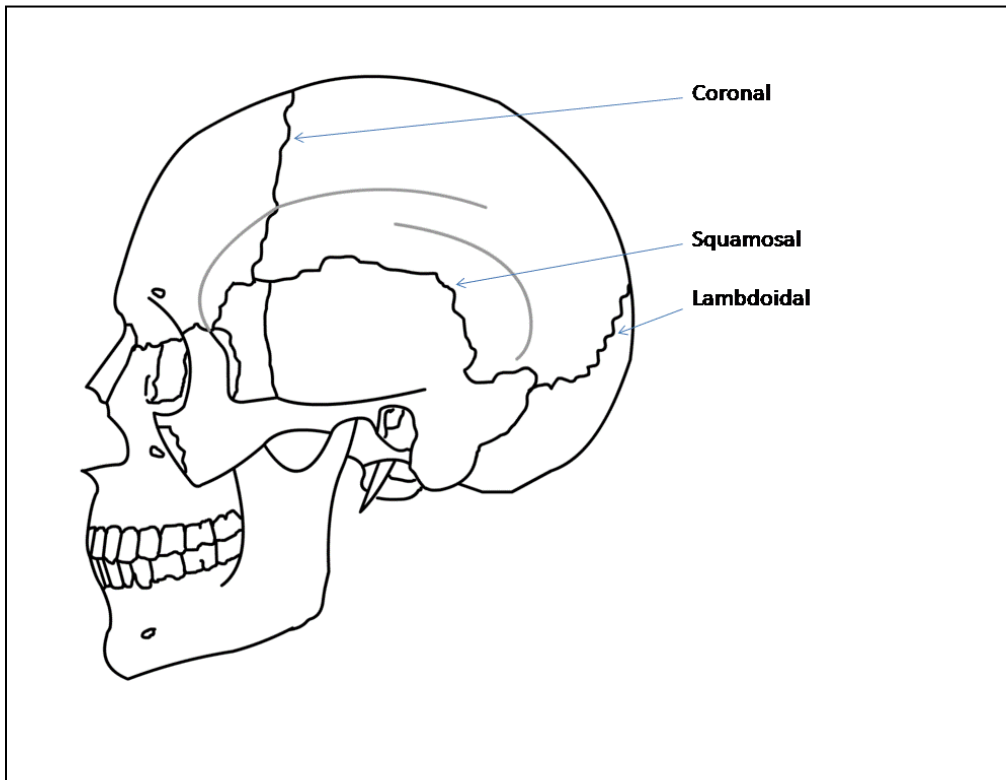


Figure 7.16. Sutures of skull.

<http://commons.wikimedia.org/wiki/Image:SkullSchaedelSeitlich1.png>

Original Author: [RosarioVanTulpe](#)  
Modified by Dr. Bruce Forciea

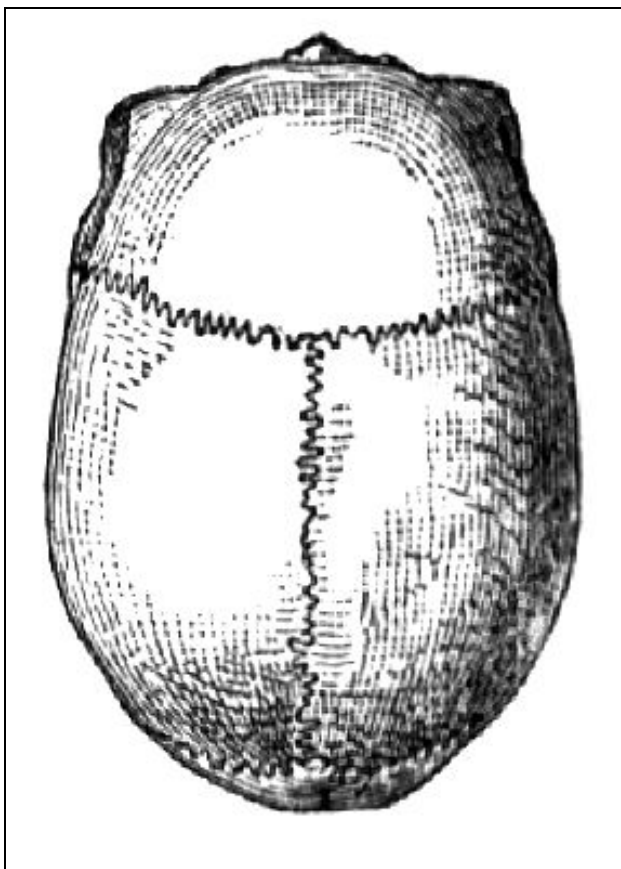


Figure 7.17. The coronal suture unites the frontal and parietal bones. The sagittal suture unites both parietal bones. Both sutures run in their respective planes.

<http://commons.wikimedia.org/wiki/Image:Dolichocephalie.jpg>

## **Bony Landmarks**

There are a myriad of landmarks located on the skull. We will just examine a sampling of these landmarks. These structures include bumps, ridges, grooves and holes.

A tubercle is a rounded bump or process. Most of these bumps are sites for muscle and ligament attachments.

A tuberosity is a rounded bump that has a more gradual slope.

A styloid process is a pointy process.

A trochanter is a very large bump. These are found on the femur bones.

A condyle is a large rounded process.

A foramen is a hole for arteries, veins and nerves.

A nutrient foramen does not go all the way through a bone. This is where blood vessels enter the bone to provide substances for maintenance, growth and repair.

A suture is a joint uniting at least 2 bones.

A sinus is a hollow cavity within a bone.

## **Bones of the skull**

### **Frontal Bone**

The frontal bone is located on the anterosuperior aspect of the skull. It forms the anterior portion of the cranium and the superior portion of the orbits. It also contains sinuses (frontal sinuses) that secrete mucous to help flush the nasal cavity (fig. 7.18).

#### **Landmarks**

The supraorbital margin which is a thickened process above the orbits that helps to protect the eye.

The lacrimal fossa located on the superior and lateral aspect of the orbit is a small landmark for the lacrimal (tear) gland.

The suprorbital foramen is a passageway for blood vessels supplying the frontal sinus, eyebrow, and eyelid.

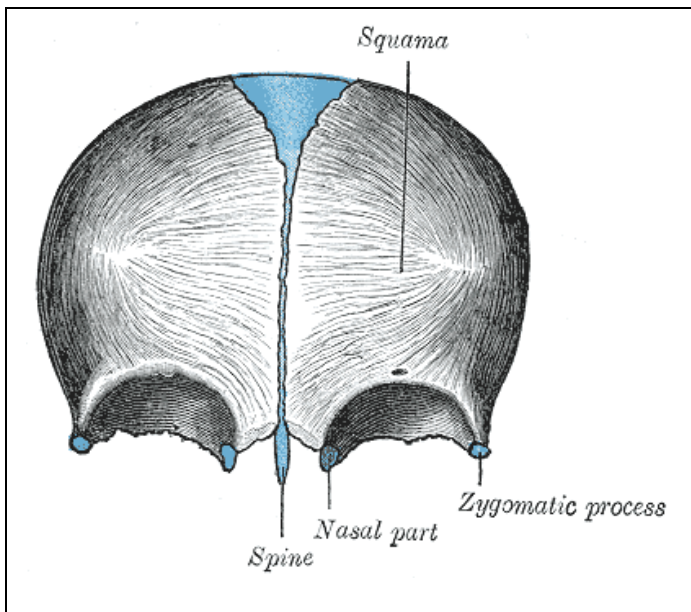


Figure 7.18. Frontal Bone

<http://commons.wikimedia.org/wiki/Image:Gray136.png>

## Parietal Bones

The parietal bones are paired bones that form the lateral margins of the cranium. They articulate with the frontal bone via the coronal suture. The right and left parietal bones also connect via the sagittal suture. Both parietal bones connect with the occipital bone via the lambdoidal suture and with the temporal bones via the squamosal sutures (fig. 7.19).

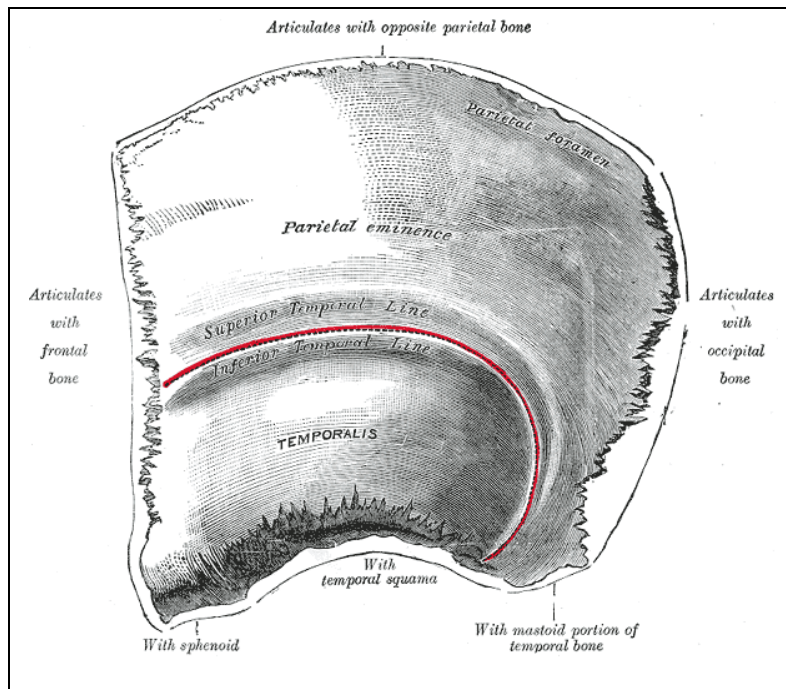


Figure 7.19. Parietal Bone

<http://commons.wikimedia.org/wiki/Image:Gray132.png>

## Occipital Bone

The occipital bone forms the posterior and posteroinferior margins of the cranium. The occipital bone articulates with the parietal, temporal, sphenoid and first cervical vertebra (fig. 7.20).

### Landmarks

The occipital condyles are rounded processes that articulate with the first cervical vertebra (atlas) of the neck.

The foramen magnum is a passageway for the spinal cord.

The jugular foramen lies between the occipital and temporal bones and provides a passageway for the internal jugular vein.

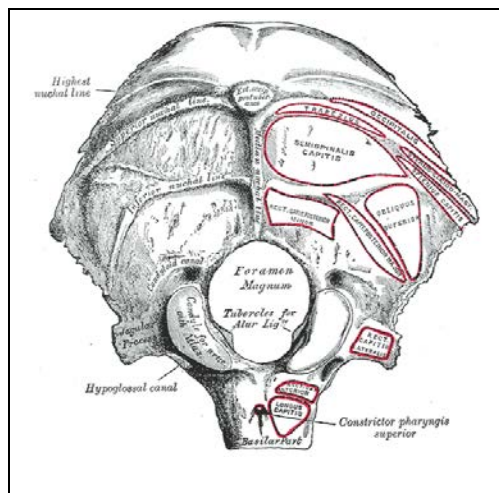


Figure 7.20. Occipital Bone

<http://commons.wikimedia.org/wiki/Image:Gray129.png>

## Temporal Bones

The temporal bones form the inferior-lateral margins of the cranium. They house the inner ear structures and articulate with the mandible (fig. 7.21).

### Landmarks

The zygomatic process forms the posterior portion of the zygomatic arch. It articulates with the temporal process of the zygomatic bone.

The mastoid process is a site of muscle attachments for some of the neck muscles. It also contains small air cavities called air cells that connect with the middle ear. These can be a site of infection called mastoiditis.

The styloid process is a pointed process that attaches to ligaments that support the hyoid bone.

The external auditory meatus (canal) is a tubelike structure that houses structures for the external and middle ear.

The carotid canal is a passageway for the internal carotid artery that supplies the brain.

The foramen lacerum is a narrow slit-like structure located between the temporal and sphenoid bones. It carries small blood vessels that supply the inner portion of the cranium.

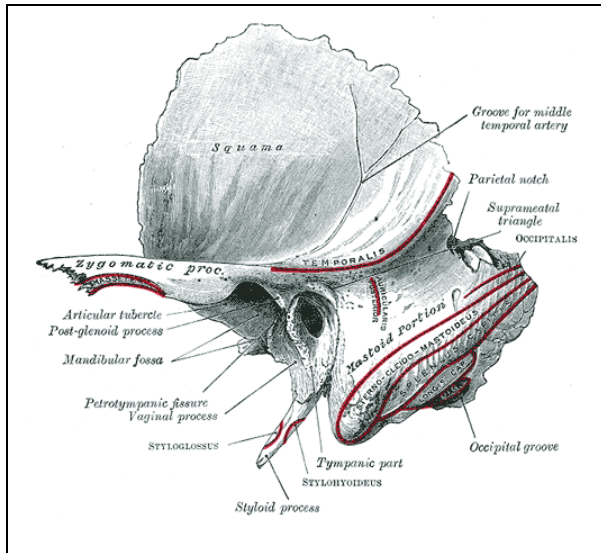


Figure 7.21. Temporal Bone

<http://commons.wikimedia.org/wiki/Image:Gray137.png>

## Sphenoid

The sphenoid bone forms part of the inferior portion of the cranium. It is visible on the lateral aspect of the skull although most of the bone resides inside of the skull (figs. 7.22-7.24).

### Landmarks

The sella turcica (Turkish saddle) is a groove in the central region of the sphenoid. The pituitary gland resides in the sella turcica.

The lesser wings extend laterally and are anterior to the sella turcica.

The greater wings are lateral to the sella turcica and form part of the floor of the cranium.

The optic canals are a passageway for the optic nerves.



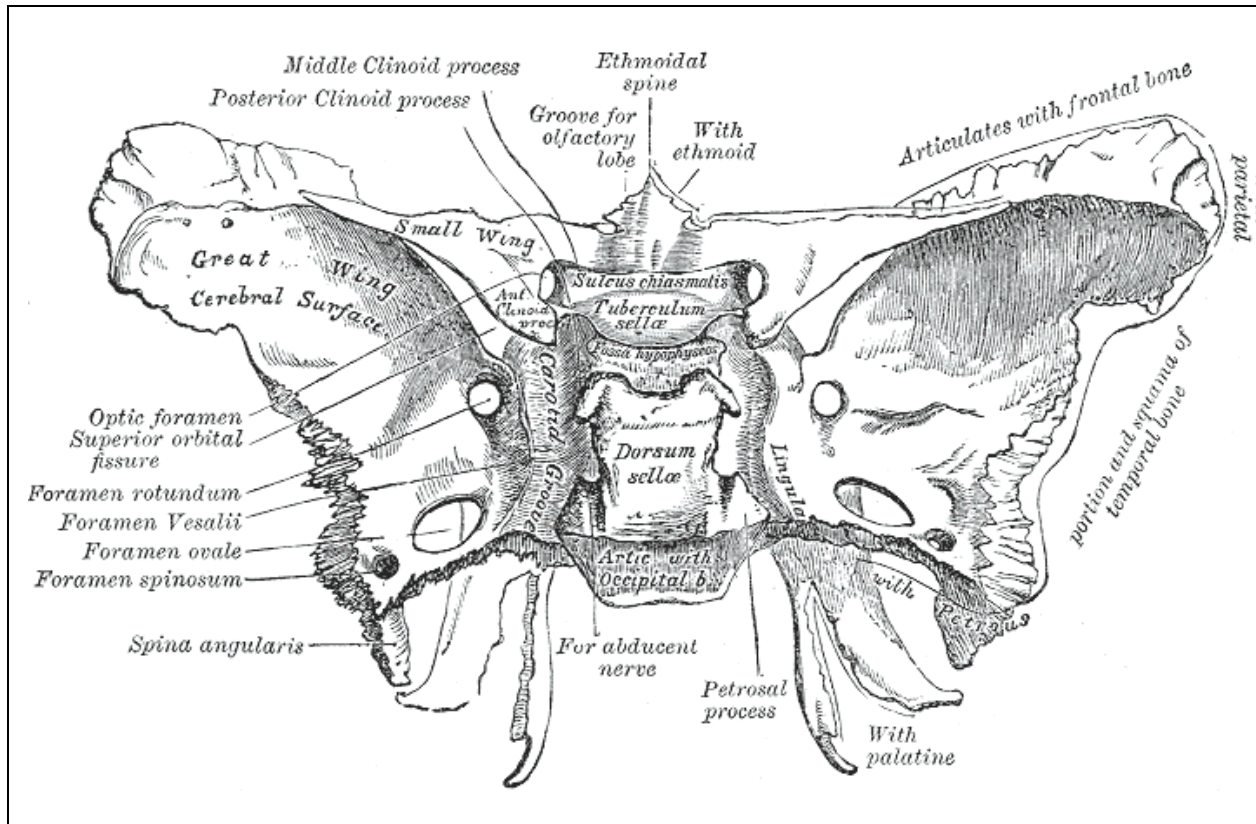


Figure 7.22. The Sphenoid bone. The sella turcica is labeled “dorsum sella” in this picture.

<http://commons.wikimedia.org/wiki/Image:Gray145.png>

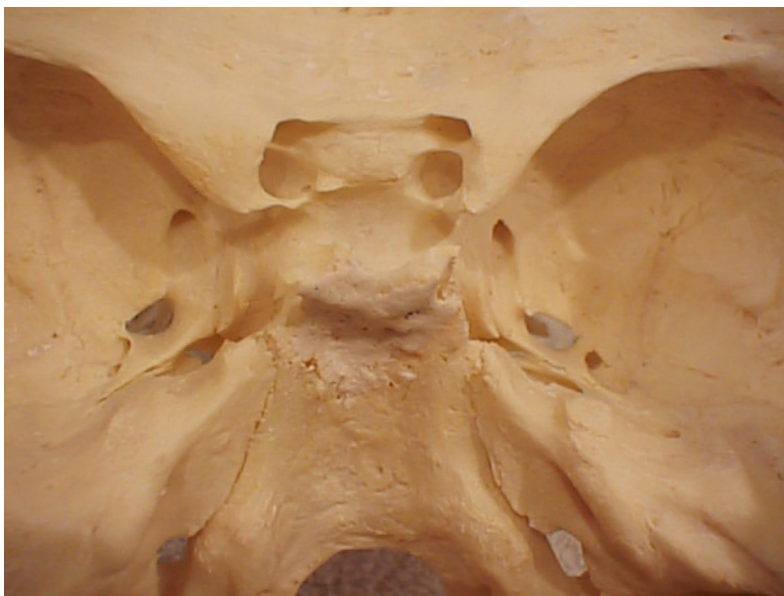

Figure 7.23. The sella turcica (Turkish saddle) is located in the central region of the sphenoid bone.

[http://commons.wikimedia.org/wiki/Image:Sella\\_turcica.jpg](http://commons.wikimedia.org/wiki/Image:Sella_turcica.jpg)

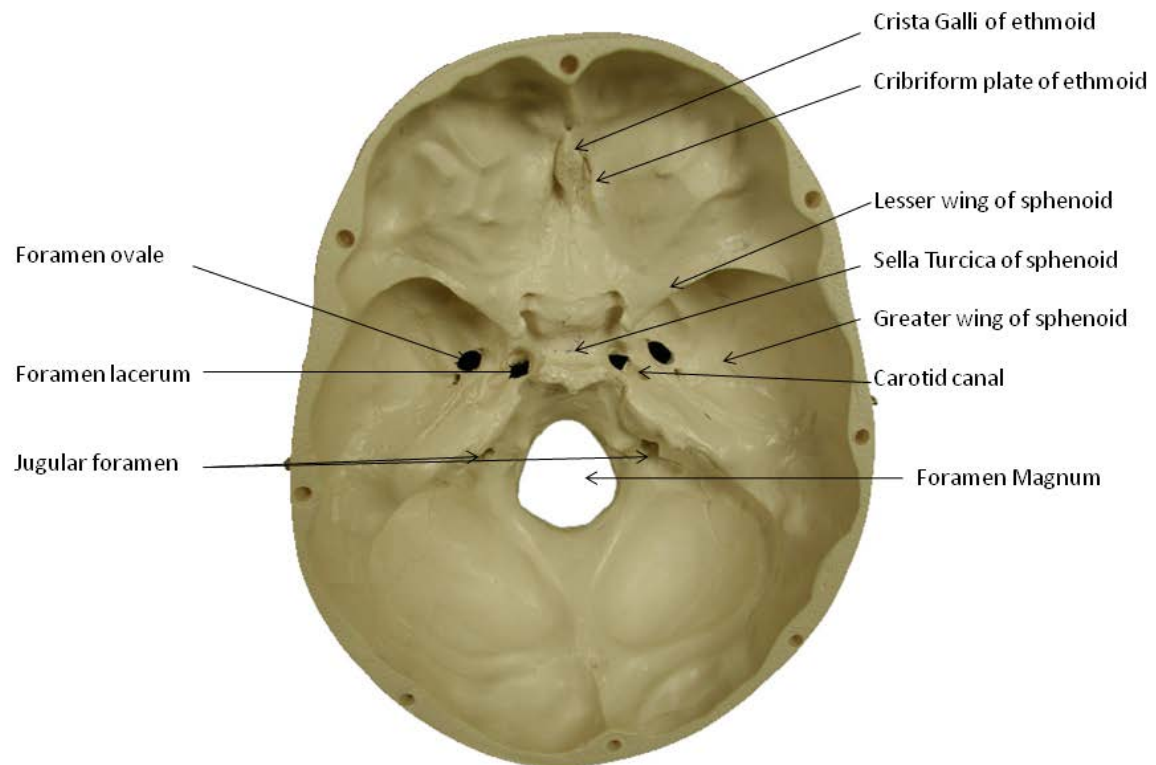


Figure 7.24. Internal view of the skull.

Bruce Forciea



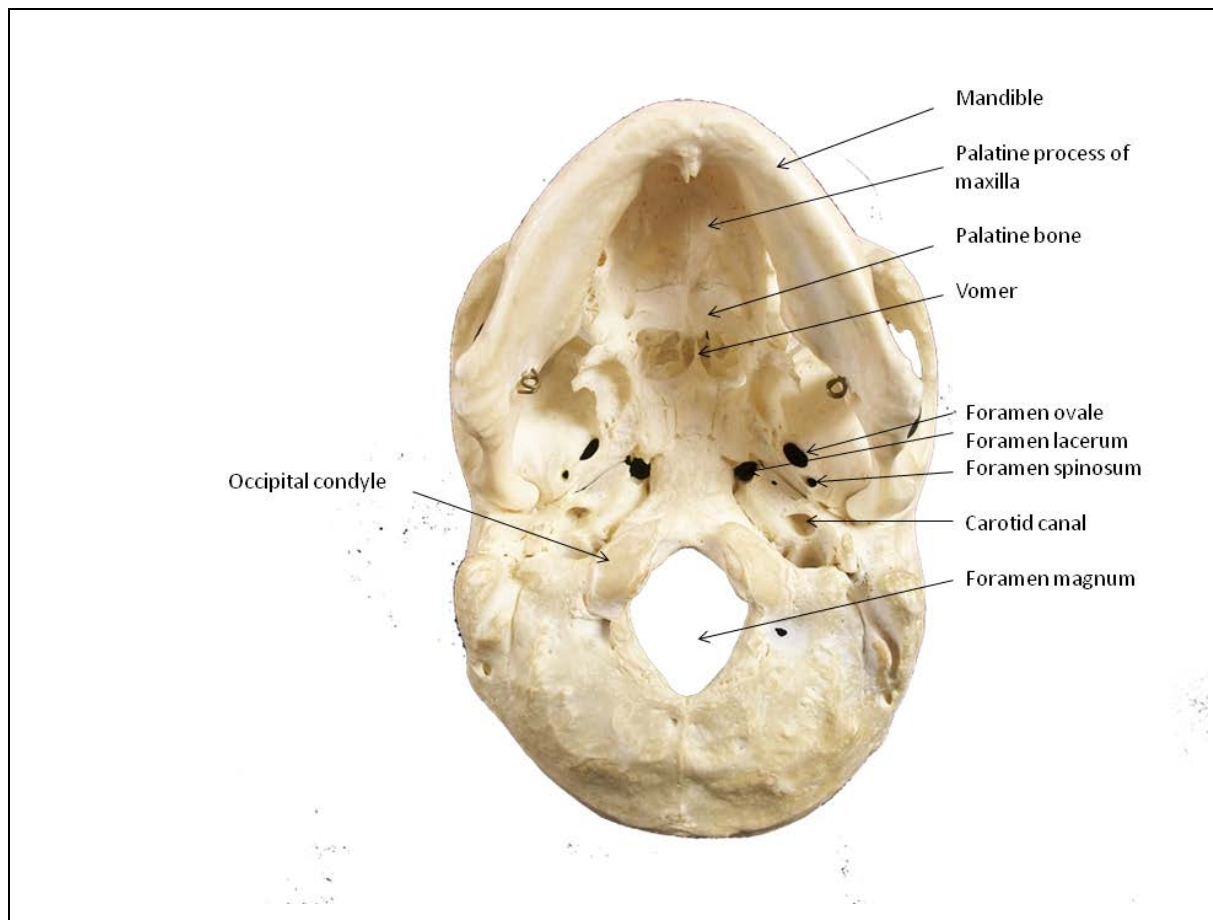


Figure 7.25. Inferior view of skull.

Dr. Bruce Forciea

## Ethmoid

The ethmoid bone is located in the anterior and medial cranium. The ethmoid bone also forms the roof of the nasal cavity and the superior portion of the nasal septum. It contains sinuses that secrete mucous to help flush the nasal cavity (figs. 7.26, 7.27).

### Landmarks

The crista galli is a ridge of bone that extends superiorly. A portion of the membrane that surrounds the brain called the dura mater attaches to this ridge.

The cribriform plate is a perforated section of bone. Fibers from the olfactory nerve pass through these holes on their way to the frontal lobe of the brain.

The perpendicular plate is a ridge of bone extending inferiorly and forming the superior portion of the nasal septum.

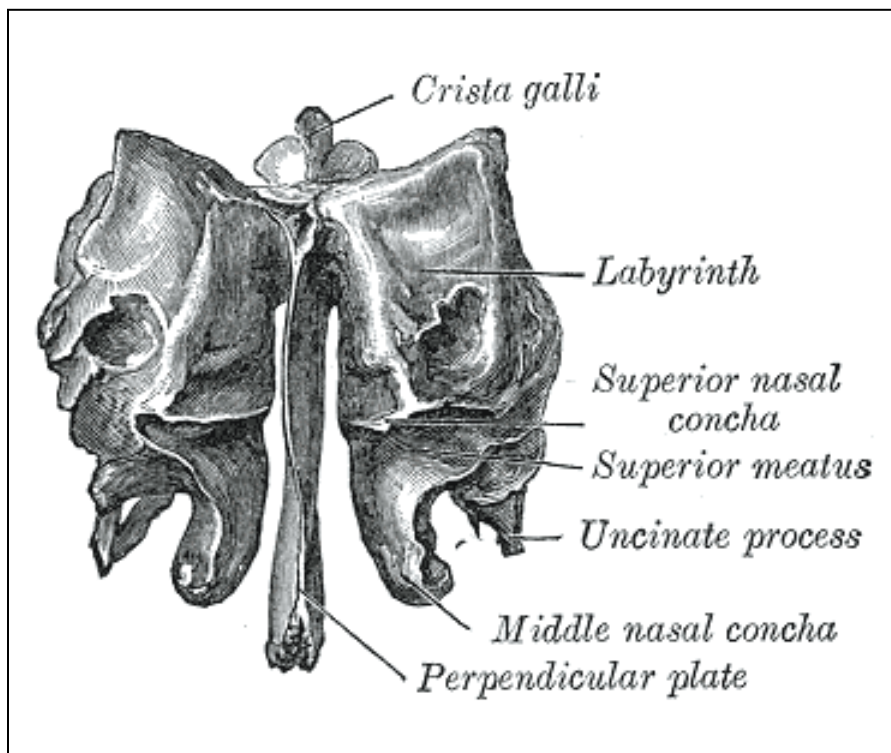


Figure 7.26. Ethmoid bone.

<http://commons.wikimedia.org/wiki/Image:Gray151.png>

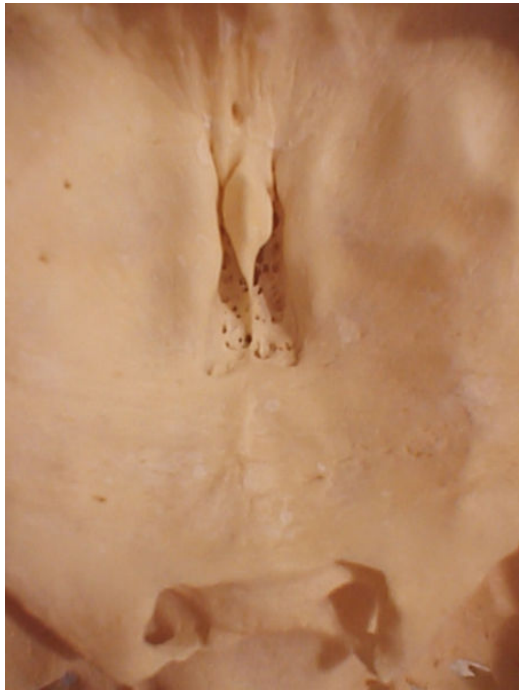

Figure 7.27. The cribriform plate and crista galli of the ethmoid bone.

[http://commons.wikimedia.org/wiki/Image:Ethmoid\\_crista\\_galli.jpg](http://commons.wikimedia.org/wiki/Image:Ethmoid_crista_galli.jpg)

## Maxilla

The maxilla is located on the anterior aspect of the skull. It is superior to the mandible and inferior to the frontal bone. It forms the upper jaw. The maxilla is actually 2 bones that have fused (fig. 7.28).

### Landmarks

The alveolar process holds the upper teeth.

The infraorbital foramen provides passage for the infraorbital artery and nerve.

The palatine process forms the anterior portion of the hard palate.

The maxillary sinus is a hollow area lined with a mucous membrane. This cavity opens to the nasal passages.

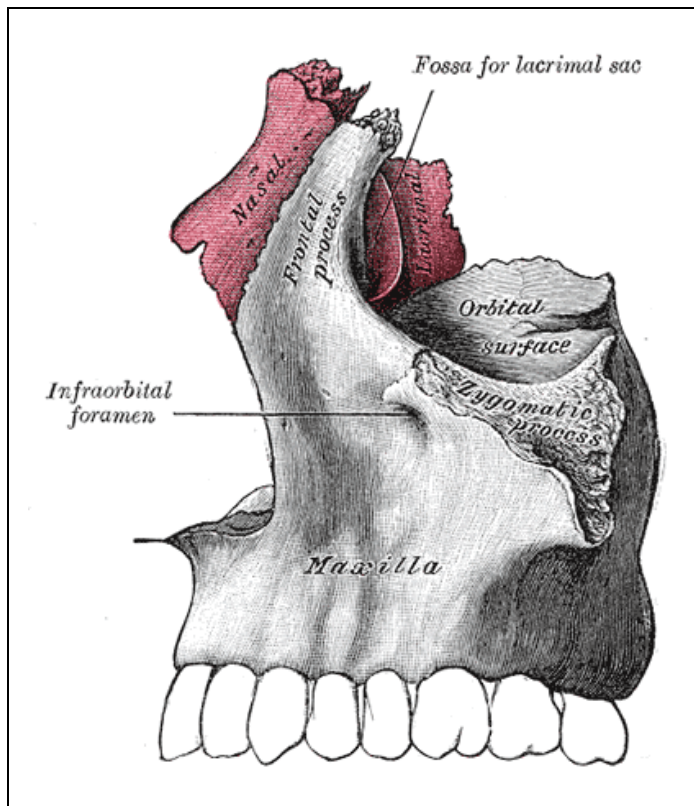


Figure 7.28. Maxilla

<http://commons.wikimedia.org/wiki/Image:Gray154.png>

## Mandible

The mandible forms the lower jaw. It is actually 2 bones that have fused.

### Landmarks

The alveolar process holds the lower teeth.

The mandibular foramen provides passage for the inferior alveolar nerve (a division of the trigeminal nerve). It is located on the medial aspect (inside) of the mandible.

The mental foramen contains fibers of the inferior alveolar nerve.

The condyles form the lateral part of the temporomandibular joint (TMJ). They articulate with the temporal bone.

The mental protuberance is a ridge of bone that extends anteriorly and is located in the central region of the mandible. It forms the chin.

## Zygomatics

The zygomatic bones are located in the anterior portion of the skull. They connect with the maxilla, frontal and temporal bones and form the cheeks.

### Landmarks

The temporal process is an extension of bone that connects with the zygomatic process of the temporal bone to form the zygomatic arch.

## Palatine

The palatine bone is one of the bones that forms the hard palette. It connects with the palatine process of the maxilla to form the posterior portion of the hard palette. It is located between the maxilla and sphenoid bones.

## Vomer

The vomer bone forms the inferior aspect of the nasal septum. It articulates with the ethmoid, sphenoid, palatines and maxillary bones (fig. 7.29).

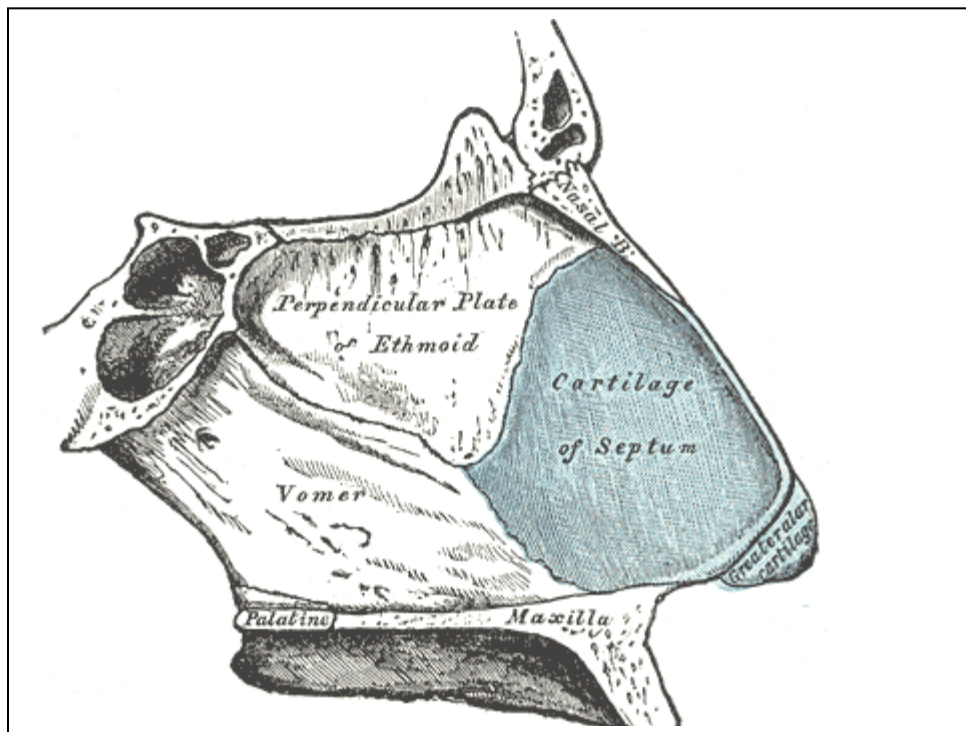


Figure 7.29 Vomer Bone.

<http://en.wikipedia.org/wiki/File:Gray854.png>

## Bones of the Orbit

The orbit is formed by the following bones (fig. 7.30):

- Frontal
- Lacrimal
- Maxilla
- Zygomatic
- Palatine
- Sphenoid
- Ethmoid

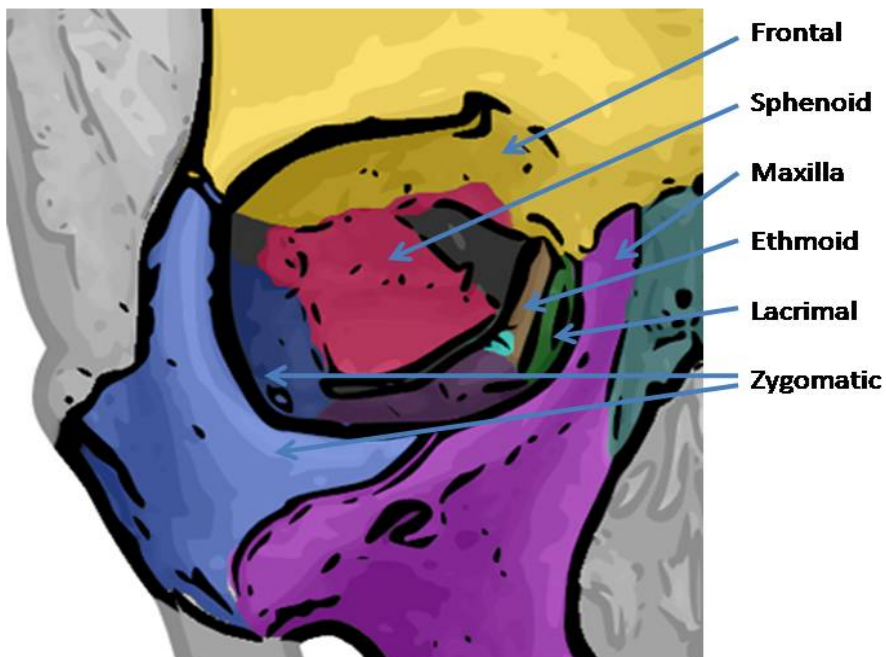


Figure 7.30. Bones of the orbit.

[http://commons.wikimedia.org/wiki/Image:Orbital\\_bones.png](http://commons.wikimedia.org/wiki/Image:Orbital_bones.png)

Original author: [Je at uwo](#), Modified by Bruce Forciea



## Fontanels

The skeletal system does not completely ossify until the mid-twenties. This is most evident in the bones that form from intramembranous ossification in the skull. The membrane from which the skull bones form is palpable in the infant skull and is called a fontanel. The fontanels serve a useful purpose in allowing for compression of the fetal skull during birth (fig. 7.31).

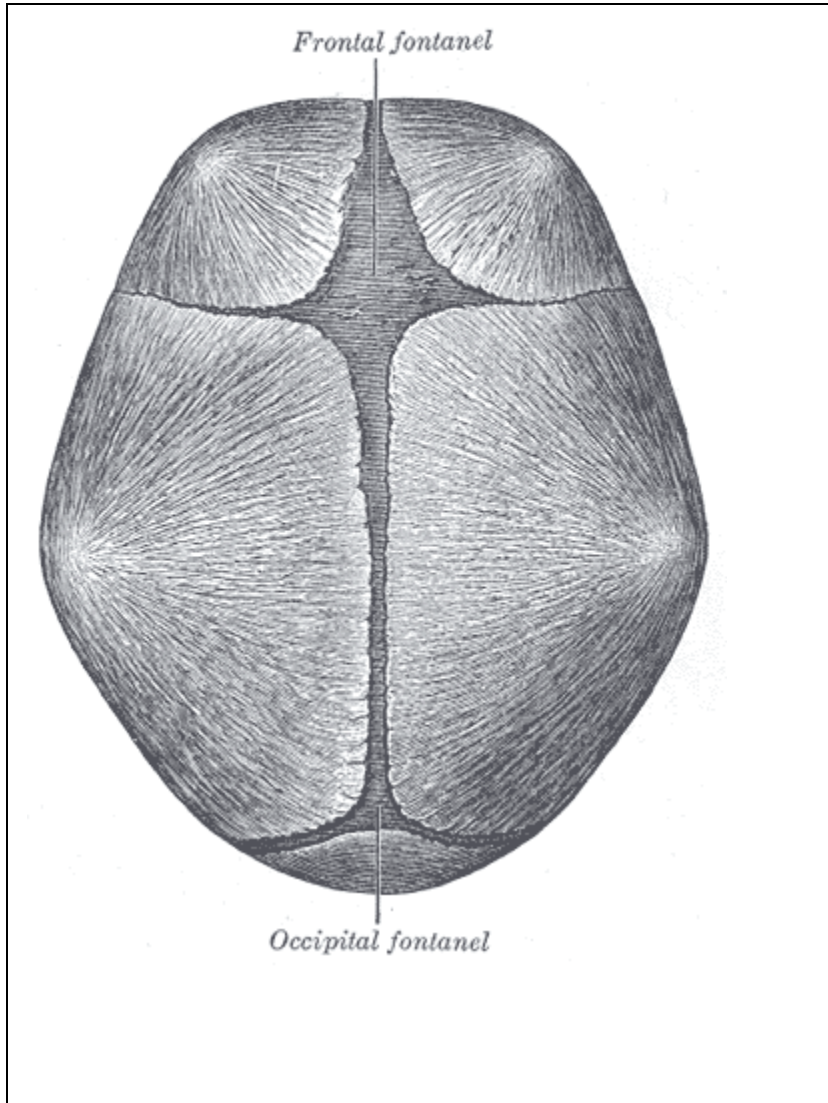


Figure 7.31. Superior view of fontanels.

<http://commons.wikimedia.org/wiki/File:Gray197.png>

The anterior fontanel is located at the junction of the developing frontal and parietal bones. The anterior fontanel can be palpated for up to age 2 years. The posterior or occipital fontanel is located at the junction of the parietal and occipital bones. There are also sphenoidal and mastoid fontanel on the lateral sides of the skull. The sphenoidal fontanel is located at the junction of the frontal, parietal, temporal and sphenoid bones. The mastoid fontanel is located at the junction of the parietal, temporal and occipital bones. The remaining fontanel usually ossify by the end of the first year.



## **The Spine**

The spine consists of 25 vertebra “stacked” one on the other forming a column. The spine provides support for the head and trunk and houses the spinal cord. It articulates superiorly with the head and inferiorly with the sacrum. There are 3 basic sections of the spine. The cervical spine consists of 7 vertebrae and has 2 very unique vertebrae called the atlas and axis. The thoracic spine consists of 12 vertebrae that articulate with ribs. The lumbar spine consists of 5 large vertebrae. The vertebrae are numbered according to their location from top to bottom. For example C2 is the second cervical vertebra, T5 is the fifth thoracic vertebra and L5 is the fifth lumbar vertebra (fig. 7.32).

### **Distinguishing Morphology**

Most vertebrae have a similar construction with some slight differences. Vertebrae generally consist of a body with 2 strut-like structures called pedicles extending laterally connecting to transverse processes. Structures called lamina complete the ring and fuse at the spinous processes.

Bones of the cervical spine have small bodies and large appearing spinal canals. They have foramen in their transverse processes that contain the vertebral artery and vein. They also have a forked or bifid spinous process. The atlas appears as a ring of bone. The axis has a large process extending superiorly called the dens or odontoid process.

The thoracic vertebrae are larger than the cervical vertebrae. Their bodies are larger and contain flat spots known as articulating facets which serve as connection points for ribs.

The lumbar vertebrae are the largest because they bear the most weight. Their spinal canals appear smaller.

### **Curves of the spine**

There are actually 4 spinal curves. These include cervical, thoracic, lumbar and pelvic curves. The cervical and lumbar curves are both known as lordotic curves (example = cervical lordosis). A lordotic curve is characterized by having its convexity anterior. Lordotic curves are considered secondary curves because they develop after birth when humans begin to hold their heads up, sit up and walk. The cervical and lumbar areas of the spine are considerably more mobile than the thoracic or a pelvic area because of the latter’s connection to the bony pelvis and ribs. The thoracic and pelvic curves are called kyphotic curves (example = thoracic kyphosis). Kyphotic curves are characterized as being concave anteriorly. The kyphotic curves are considered primary curves because they are present at birth (fig. 7.33).

An increased curvature of the cervical or lumbar spine is called a hyperlordosis. A decreased curvature is called a hypolordosis.

An increased curvature of the thoracic spine is called a hyperkyphosis and a decreased curvature is called a hypokyphosis.

A lateral curvature is called a scoliosis. Sometimes, if the curve is not severe the curves are described as increased lateral convexities or concavities (fig. 7.34).

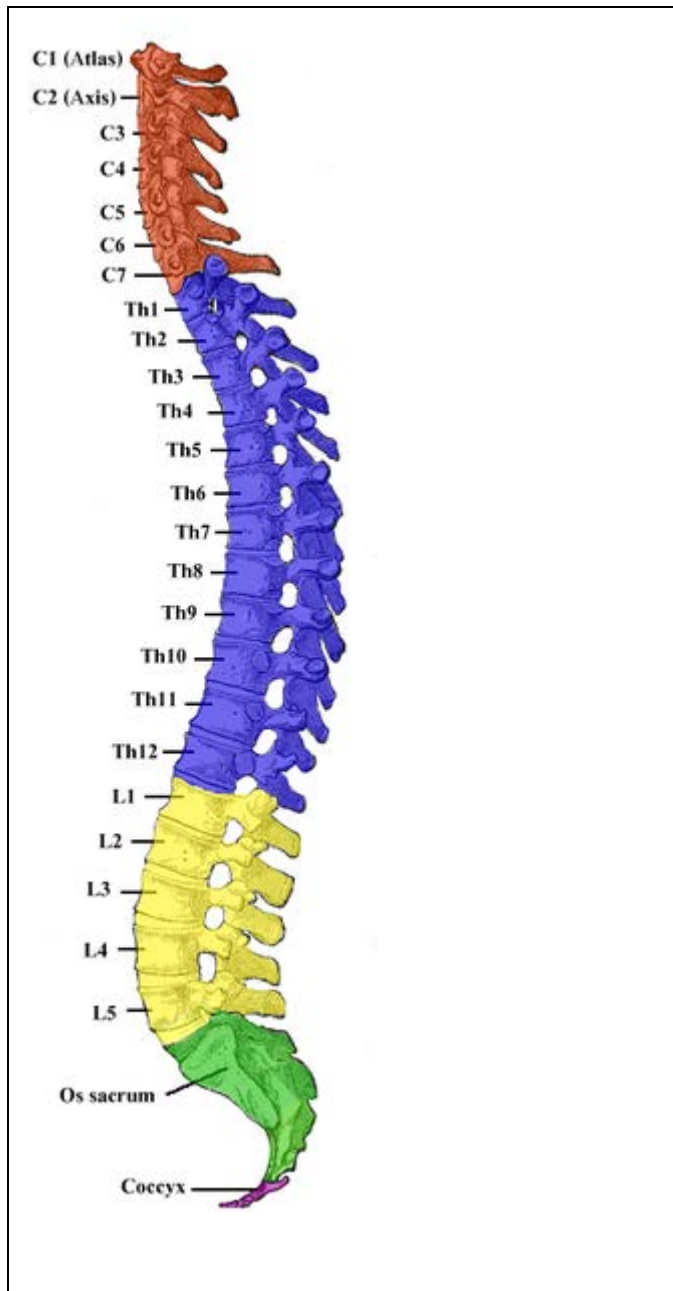


Figure 7.32. The spine.

[http://en.wikipedia.org/wiki/Image:Gray\\_111\\_-\\_Vertebral\\_column-coloured.png](http://en.wikipedia.org/wiki/Image:Gray_111_-_Vertebral_column-coloured.png)

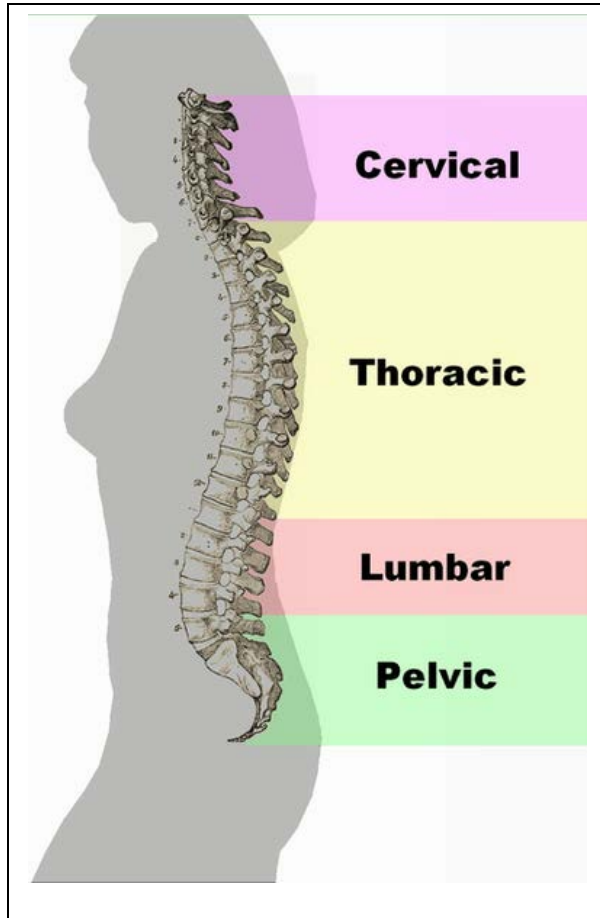


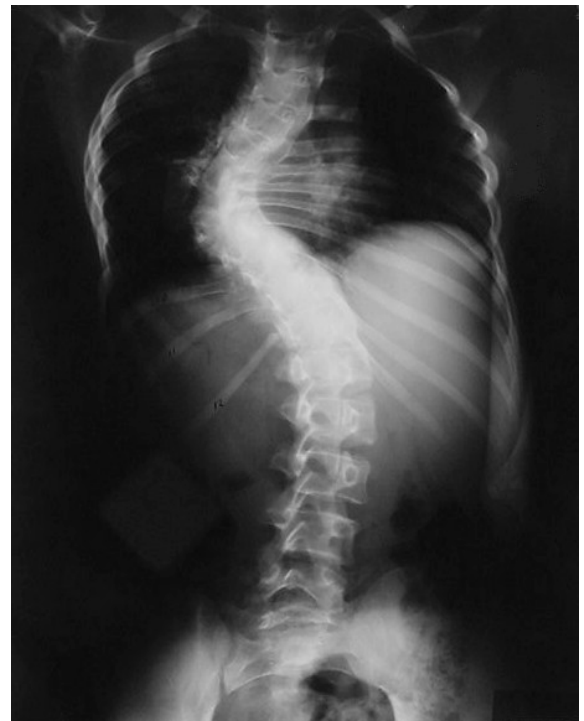Figure 7.33. The spine is divided into cervical, thoracic, lumbar and pelvic sections.

[http://commons.wikimedia.org/wiki/Image:Spinal\\_column\\_curvature.png](http://commons.wikimedia.org/wiki/Image:Spinal_column_curvature.png)

Figure 7.34. A scoliosis is characterized by the presence of lateral curves in the spine.

[http://commons.wikimedia.org/wiki/Image:Scoliosis\\_recklinghausen.jpg](http://commons.wikimedia.org/wiki/Image:Scoliosis_recklinghausen.jpg)

Authors: Gkiokas A, Hadzimichalis S, Vasiliadis E, Katsalouli M, Kannas G.



## Individual Bones of the Spine

### Atlas (C2)

The atlas or C1 is the most superior vertebra. It appears as a ring of bone and articulates with the occipital condyles of the occipital bone superiorly and C2 inferiorly. The atlas contains foramen in the transverse processes that extend laterally (fig. 7.35).

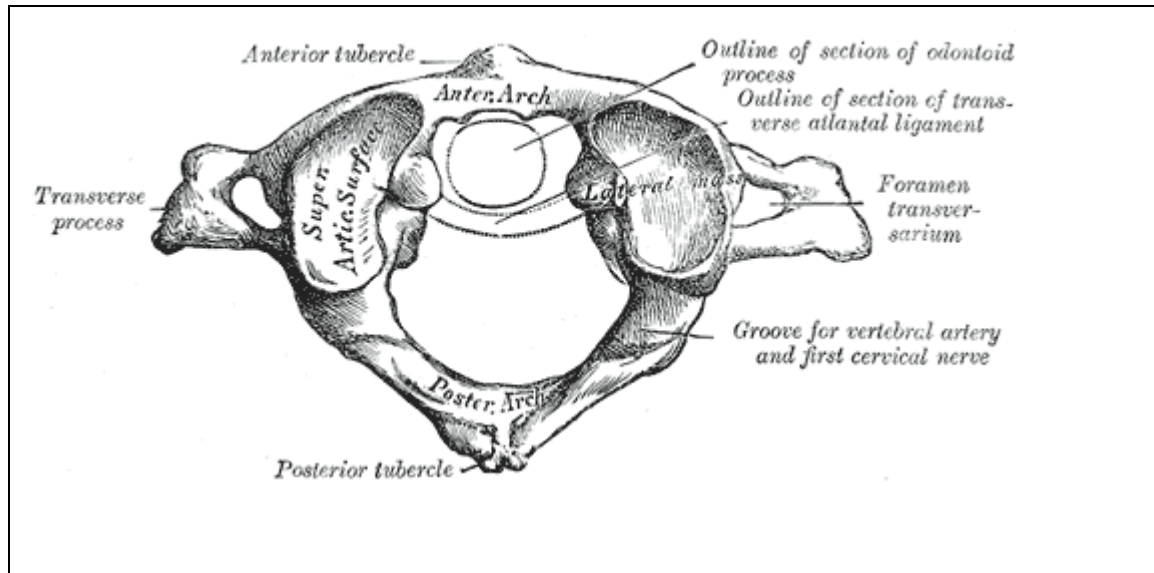


Figure 7.35. The atlas looks like a ring of bone. Notice the transverse foramen (Foramen transversarium).

<http://upload.wikimedia.org/wikipedia/commons/1/19/Grav86.png>

### Axis (C2)

The axis is a uniquely shaped vertebra. It has a small body, transverse foramen and a large superior extending process known as the dens or odontoid process (fig. 7.36).

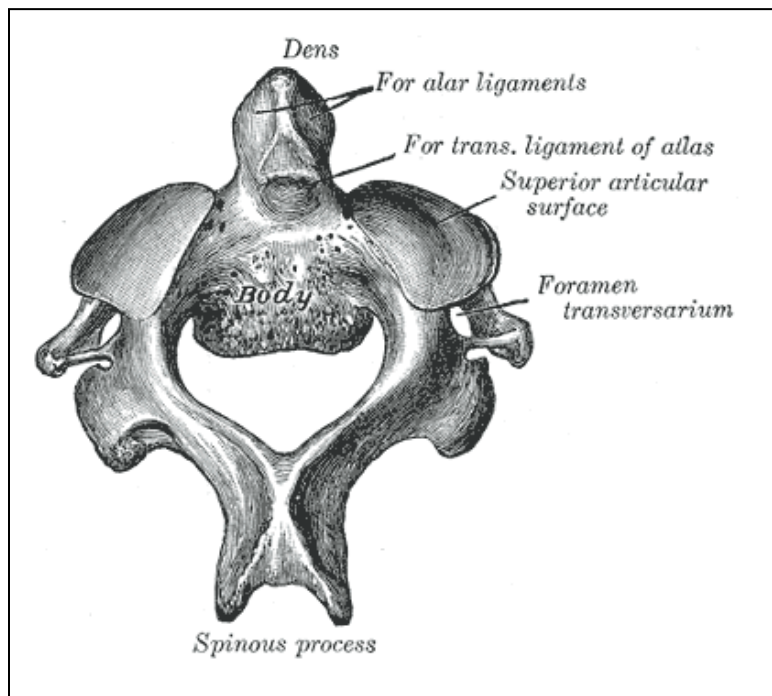


Figure 7.36. The axis (C2) has a small body and large process called the dens that articulates with the atlas.

<http://commons.wikimedia.org/wiki/Image:Gray87.png>

### C3-7

The remaining cervical vertebrae are similar to one another. They contain bodies, pedicles, lamina, transverse processes with foramen, articulating facets and bifid spinous processes (fig. 7.37).

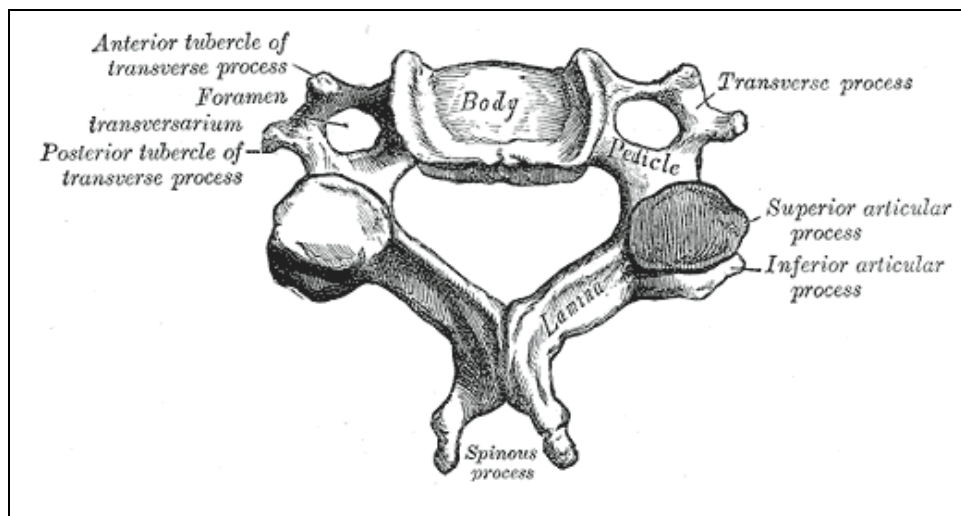


Figure 7.37. Typical cervical vertebra.

<http://commons.wikimedia.org/wiki/Image:Gray84.png>

T1-12

The thoracic vertebrae contain bodies, pedicles, articulating facets, transverse processes and spinous processes. They are larger than the cervical vertebra and connect with the ribs (fig. 7.38).

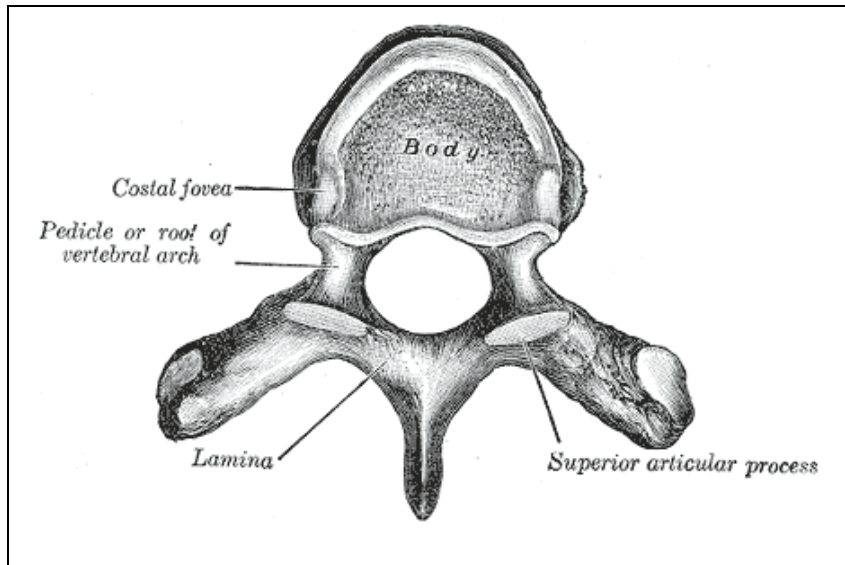


Figure 7.38. Typical thoracic vertebra.

<http://commons.wikimedia.org/wiki/Image:Gray82.png>

L1-5

The lumbar vertebrae contain bodies, pedicles, lamina, articulating facets and mamillary processes. They are the largest vertebrae (fig. 7.39).

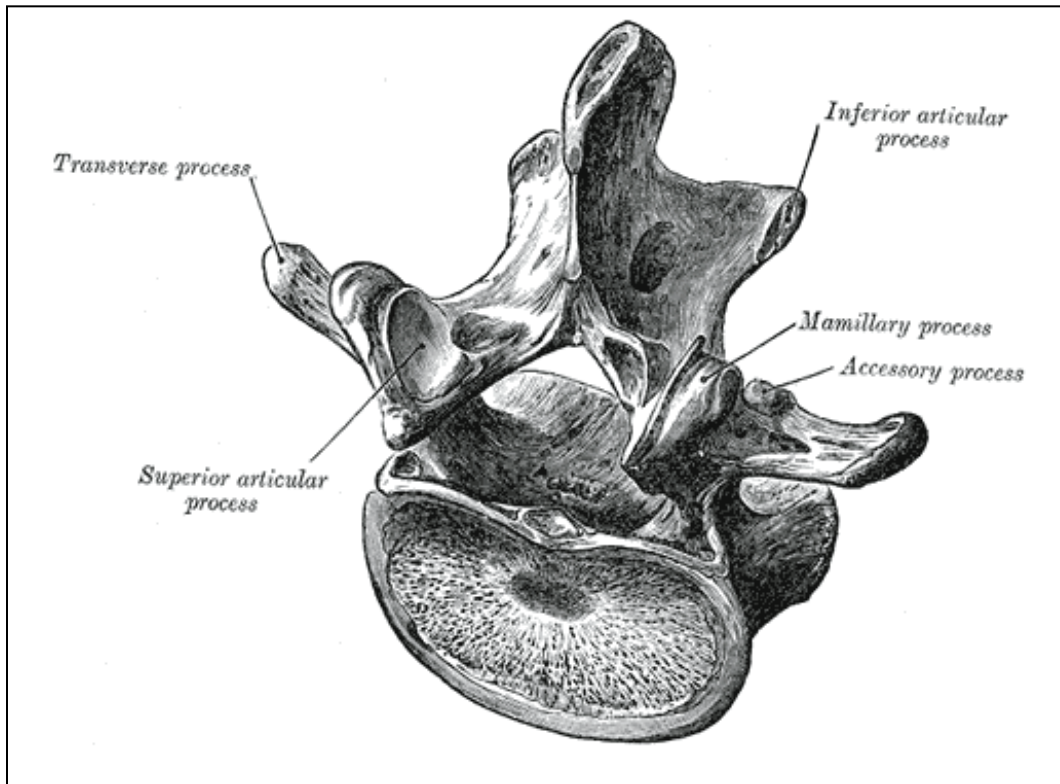


Figure 7.39. Typical Lumbar Vertebra.

<http://commons.wikimedia.org/wiki/Image:Gray93.png>

### Sacrum/Coccyx

The sacrum is a triangular curved bone located at the base of the spine. It is actually a series of 5 small vertebral bones that have fused. These bones begin to fuse at puberty and complete their fusion by around age 26. The sacrum articulates via articular processes with the 5<sup>th</sup> lumbar vertebra. The sacrum also articulates with the ilium of the coxal bones forming the sacroiliac joints. Along the central posterior surface lies a ridge of bone from the fusion of the spinous processes of the sacral vertebrae. This ridge is called the medial sacral crest. There are also a series of eight paired holes called the sacral foramen. The sacrum is hollow forming a sacral canal that opens inferiorly with the sacral hiatus. The curvature is convex posteriorly and is more pronounced in males. The superior portion of the sacrum is called the base and contains a flat area called the sacral promontory (figs. 7.40, 7.41).

The coccyx is another series of very small fused vertebral segments (3-5). These vertebrae do not completely fuse until late in adulthood.



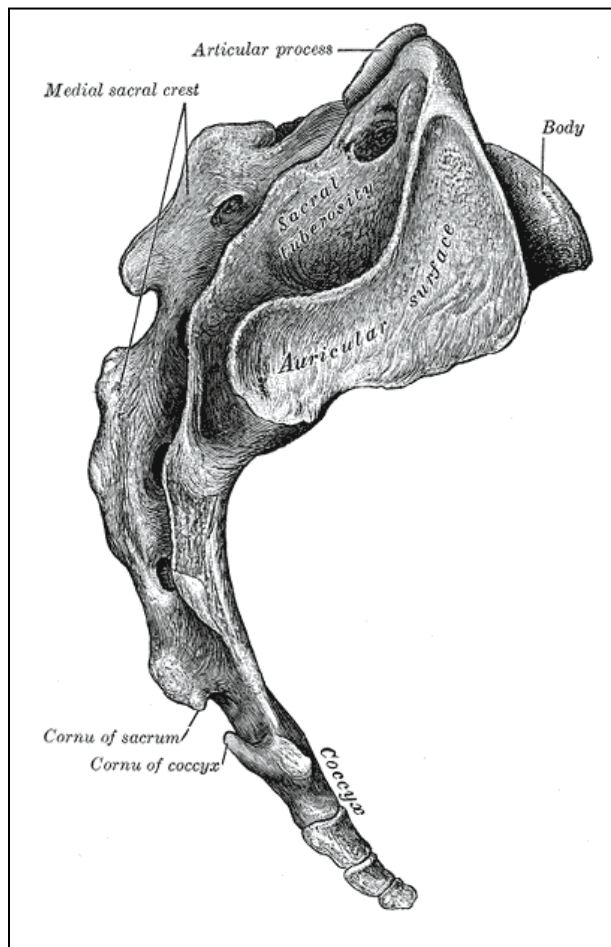


Figure 7.40. A lateral view of the sacrum showing the convex curvature on the posterior side.

<http://commons.wikimedia.org/wiki/Image:Gray97.png>



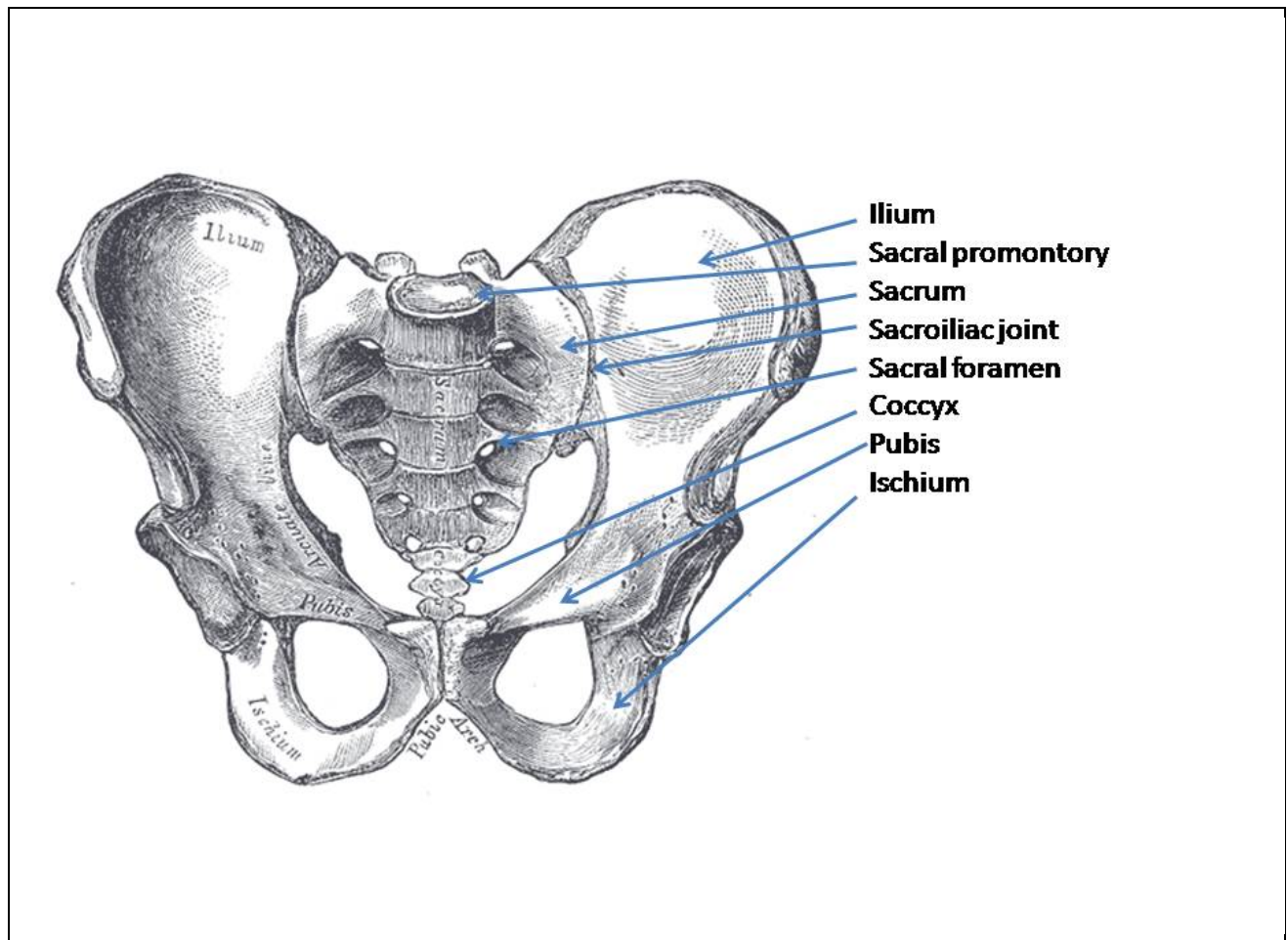


Figure 7.41. Pelvis and sacrum (anterior view).

<http://commons.wikimedia.org/wiki/Image:Gray241.png>

## The Ribcage

The ribcage consists of 12 pairs of ribs. There are true, false and floating ribs. Usually ribs 1-7 are true ribs with ribs 8-10 being false ribs. Ribs 11-12 are floating ribs. The ribs attach to the vertebra in the back and the sternum in the front by way of cartilage connections (costochondral cartilage). True ribs connect directly to the sternum by way of their cartilage connections. False ribs connect to the cartilage of true ribs and floating ribs only connect to the vertebrae in the back. There is no anterior connection to floating ribs (fig. 7.42).

## Sternum

The sternum has 3 parts. The most superior portion is called the manubrium. Just inferior to this is the body and the most inferior portion is called the xiphoid process which consists of cartilage. The sternum also articulates with the clavicle.

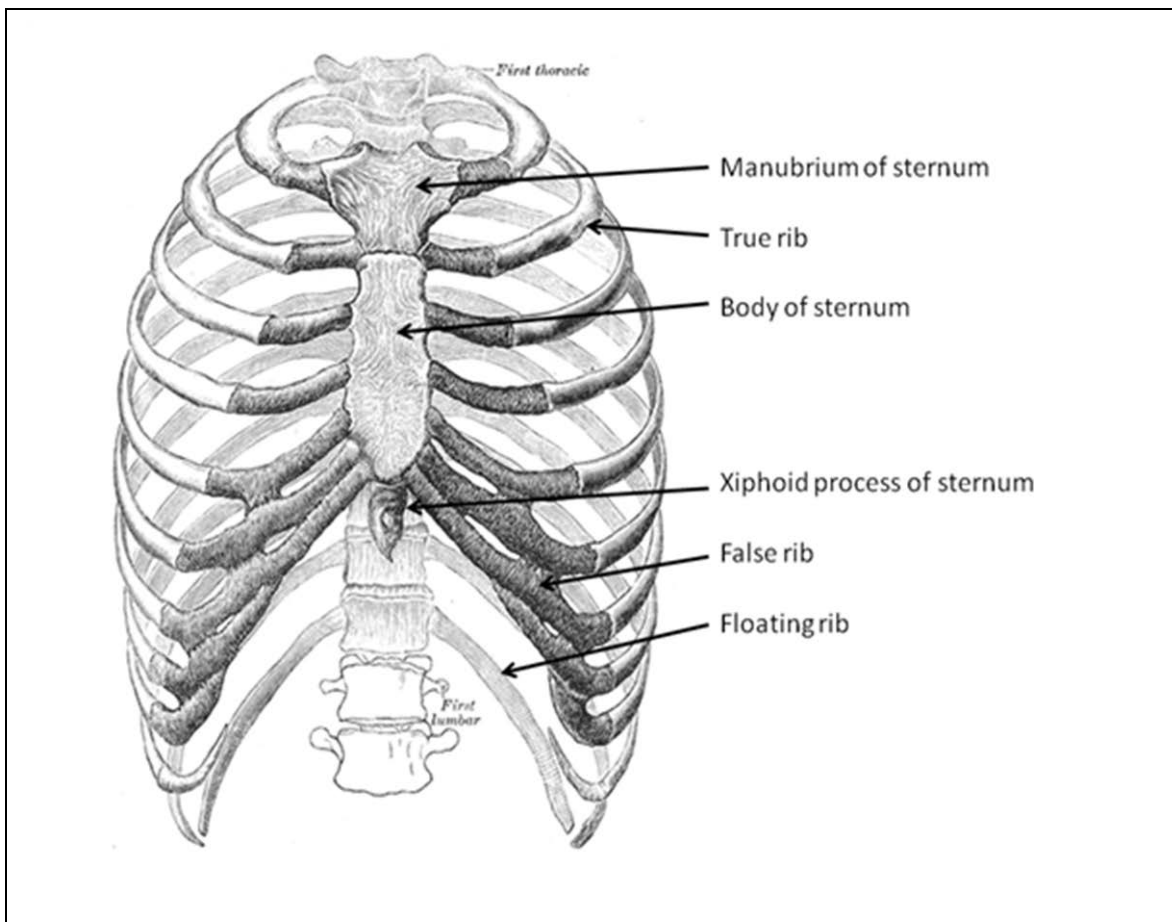


Figure 7.42. Ribcage

<http://commons.wikimedia.org/wiki/Image:Gray112.png>

## Hyoid Bone

The hyoid bone is located in the anterior region of the throat. It supports the larynx. A number of muscles that extend to the larynx, pharynx and tongue attach to the hyoid bone (fig. 7.43).

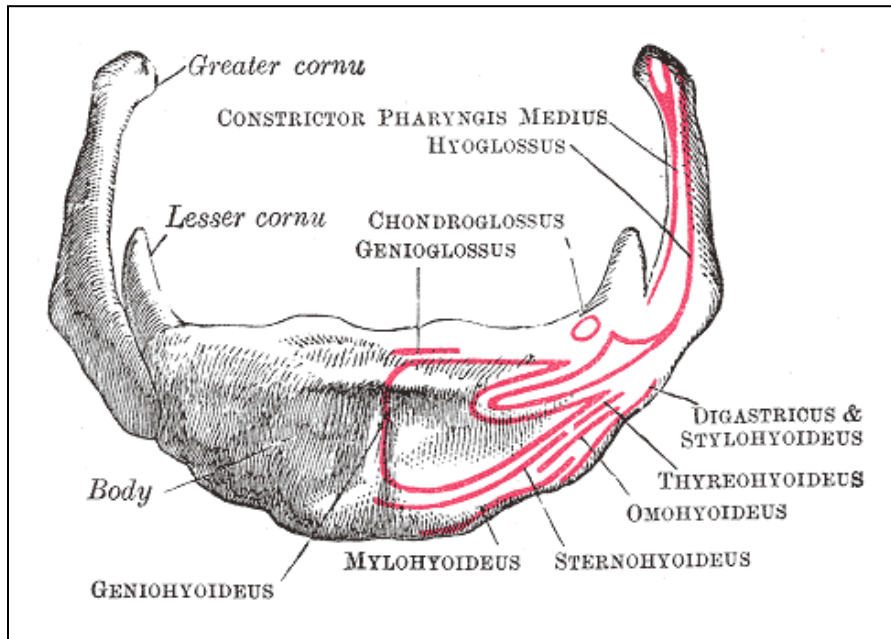


Figure 7.43 Hyoid bone.

A number of muscles attach to the hyoid bone.

<http://commons.wikimedia.org/wiki/Image:Gray186.png>

## The Appendicular Skeleton

The appendicular skeleton consists of the arms and legs (upper and lower extremities). The bones of the appendicular skeleton include:

- Clavicle
- Scapula
- Humerus
- Radius
- Ulna
- Carpals
- Metacarpals
- Phalanges
- Coxal
- Femur
- Patella
- Tibia
- Fibula
- Calcaneus
- Talus
- Cuboid
- Navicular
- Cuneiforms
- Metatarsals
- Phalanges

The upper extremity begins with what is called the pectoral girdle (aka shoulder girdle). This consists of the clavicle and scapula. The pectoral girdle acts as a support for the arms. The pectoral girdle attaches to the axial skeleton where the clavicle attaches to the sternum (sternoclavicular joint)(fig. 7.44). This is the only direct attachment of the arm to the body. However there are a number of muscles that also help to stabilize the connection.

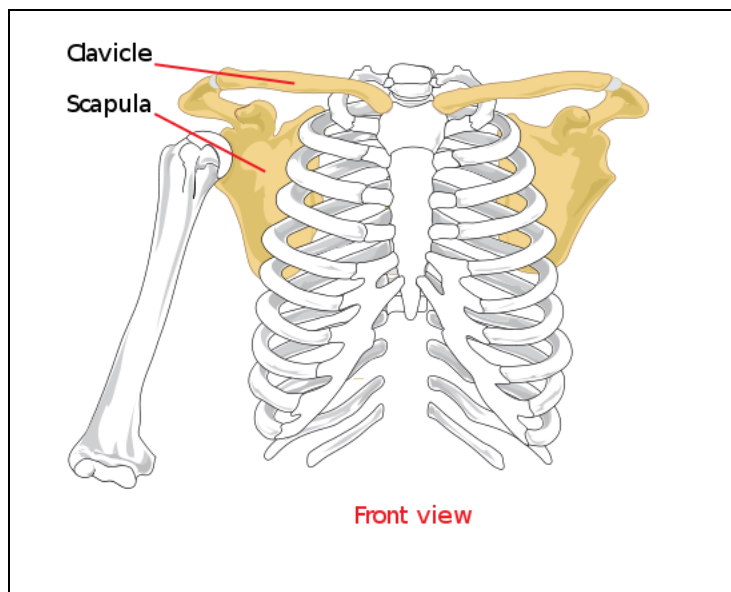


Figure 7.44. The pectoral girdle consists of the clavicle and scapula.

[http://commons.wikimedia.org/wiki/Image:Pectoral\\_girdle\\_front\\_diagram.svg](http://commons.wikimedia.org/wiki/Image:Pectoral_girdle_front_diagram.svg)

## Clavicles

The clavicles are located on the anterior portion of the thorax. They are the only S-shaped bones in the body. The clavicle articulates with the manubrium of the sternum and the acromion process of the scapula (fig. 7.45).

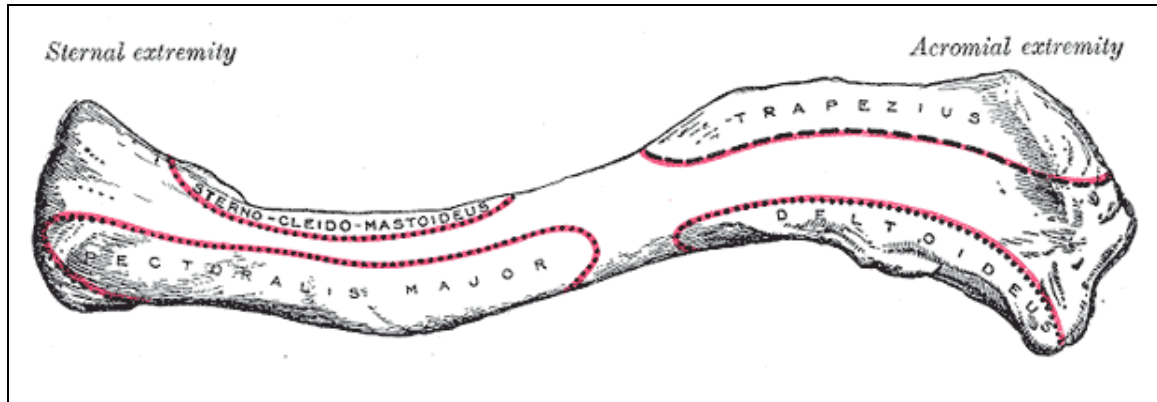


Figure 7.45. Clavicle

<http://upload.wikimedia.org/wikipedia/commons/b/b9/Gray200.png>

## Scapula

The scapula is a triangular bone located in the posterior portion of the thoracic area. It articulates with the clavicle and the humerus. The borders of the scapula include superior, medial and lateral borders. It is important to study the scapula from both posterior and anterior sides (figs. 7.46, 7.47).

### Landmarks

The glenoid cavity (fossa) is a concave surface on the lateral aspect of the scapula. It forms the “socket” of the ball and socket joint of the shoulder.

The spine of the scapula is located on the posterior surface. It is a ridge of bone extending superiorly from medial to lateral.

The acromion process is the terminal end of the spine of the scapula. It is a large process and articulates with the clavicle. The acromion process marks the highest point of the shoulder.

The coracoid process is located on the anterior aspect of the scapula. This process is smaller than the acromion process and is located anterior and inferior to it.

The supraspinous fossa is an indentation on the posterior portion of the scapula. It lies just above the spine.

The infraspinous fossa is located just inferior to the spine of the scapula.

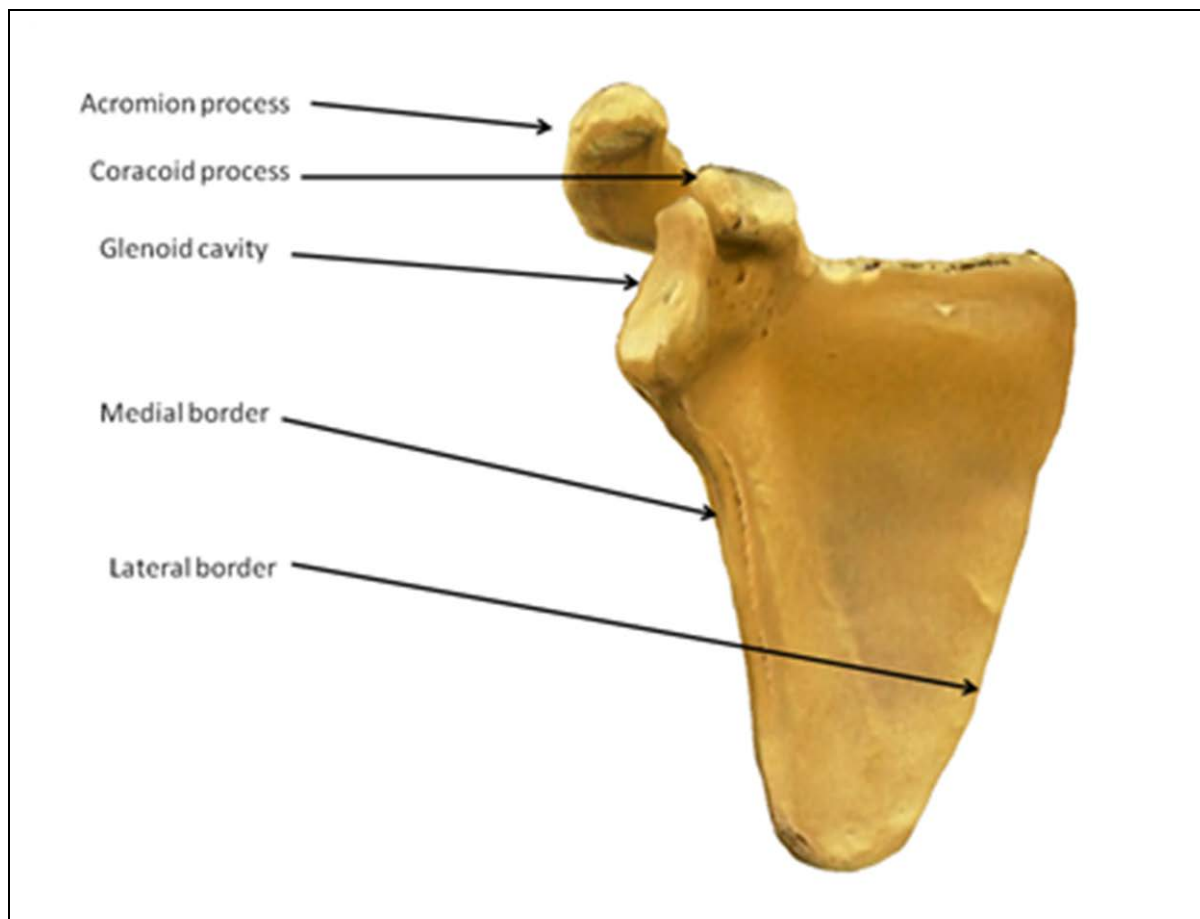


Figure 7.46. Anterior view of scapula.

Bruce Forciea

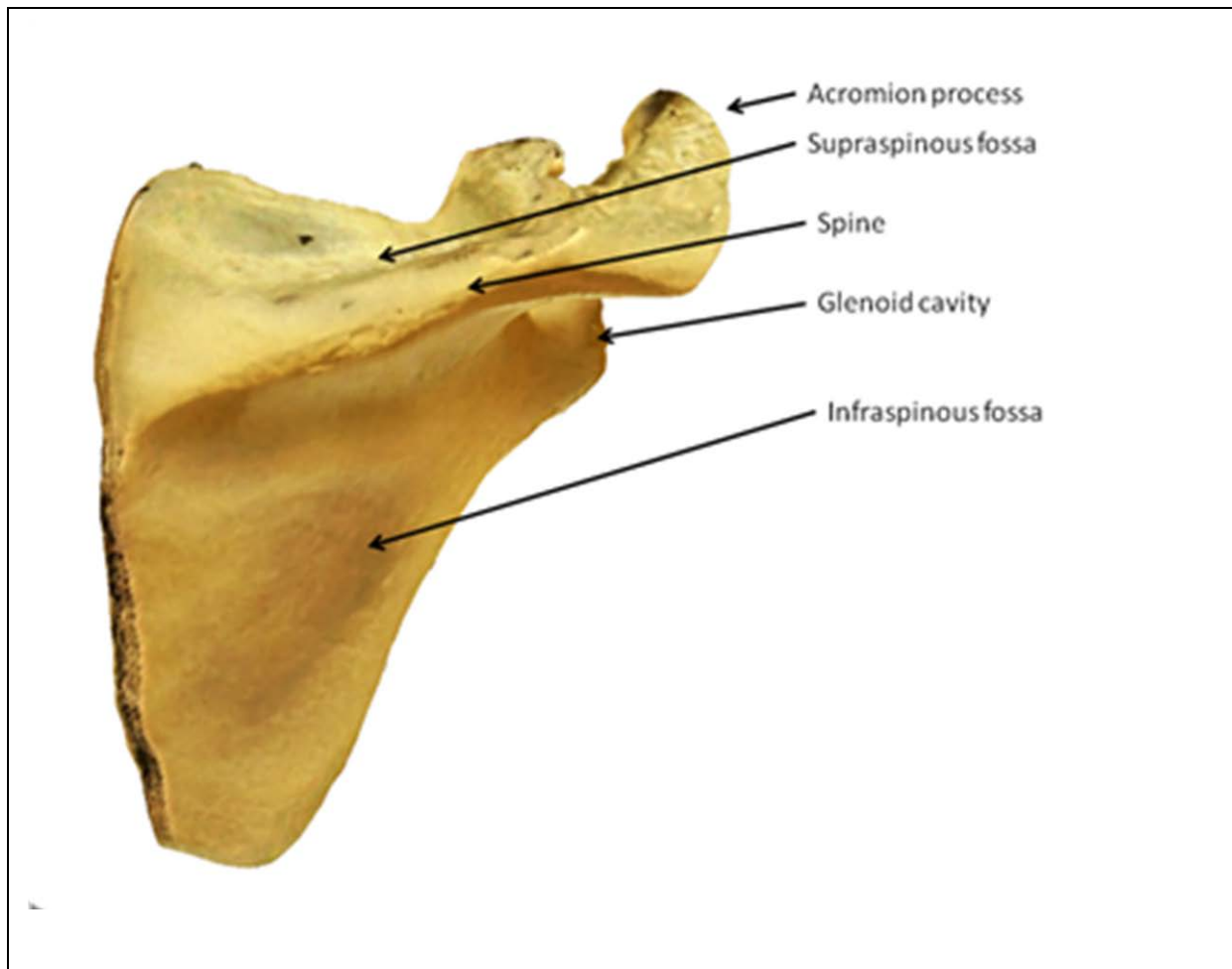


Figure 7.47. Posterior view of scapula.

Bruce Forciea

### Bones of the Upper Extremity

The upper extremity consists of the arm, forearm, wrist and hand. The bones of the upper extremity include:

- Humerus
- Radius
- Ulna
- Carpals
- Metacarpals
- Phalanges

## **Humerus**

The humerus is the proximal bone of the arm. It is a long tubular bone that articulates proximally with the scapula and distally with the radius and ulna (figs. 7.48, 7.49).

### **Landmarks**

The head of the humerus is the proximal rounded end of the bone.

The anatomical neck of the humerus is a small region that marks the end of the joint capsule between the humerus and the scapula.

The surgical neck marks the beginning of the diaphysis.

The greater tubercle is a rounded process on the lateral aspect of the proximal humerus.

The lesser tubercle is a smaller rounded process on the medial aspect of the proximal humerus.

The intertubercular groove (sulcus) is a groove between the greater and lesser tubercles.

The deltoid tuberosity is a bump with a gradual slope on the lateral aspect of the humerus and is the site of attachment of the deltoid muscle.

The lateral epicondyle is a widened area on the lateral aspect of the distal humerus. It is an important site of muscle attachments for the wrist extensor muscles.

The medial epicondyle is a widened area on the medial aspect of the distal humerus. It is a site of attachment for wrist flexor muscles.

The capitulum is a small rounded process at the distal end of the humerus on the lateral side. It articulates with the radius.

The trochlea is a small spool shaped process at the distal medial end of the humerus. It articulates with the ulna.

The olecranon is an indentation on the posterior distal aspect of the humerus.

The coronoid fossa is a small indentation on the anterior distal aspect.



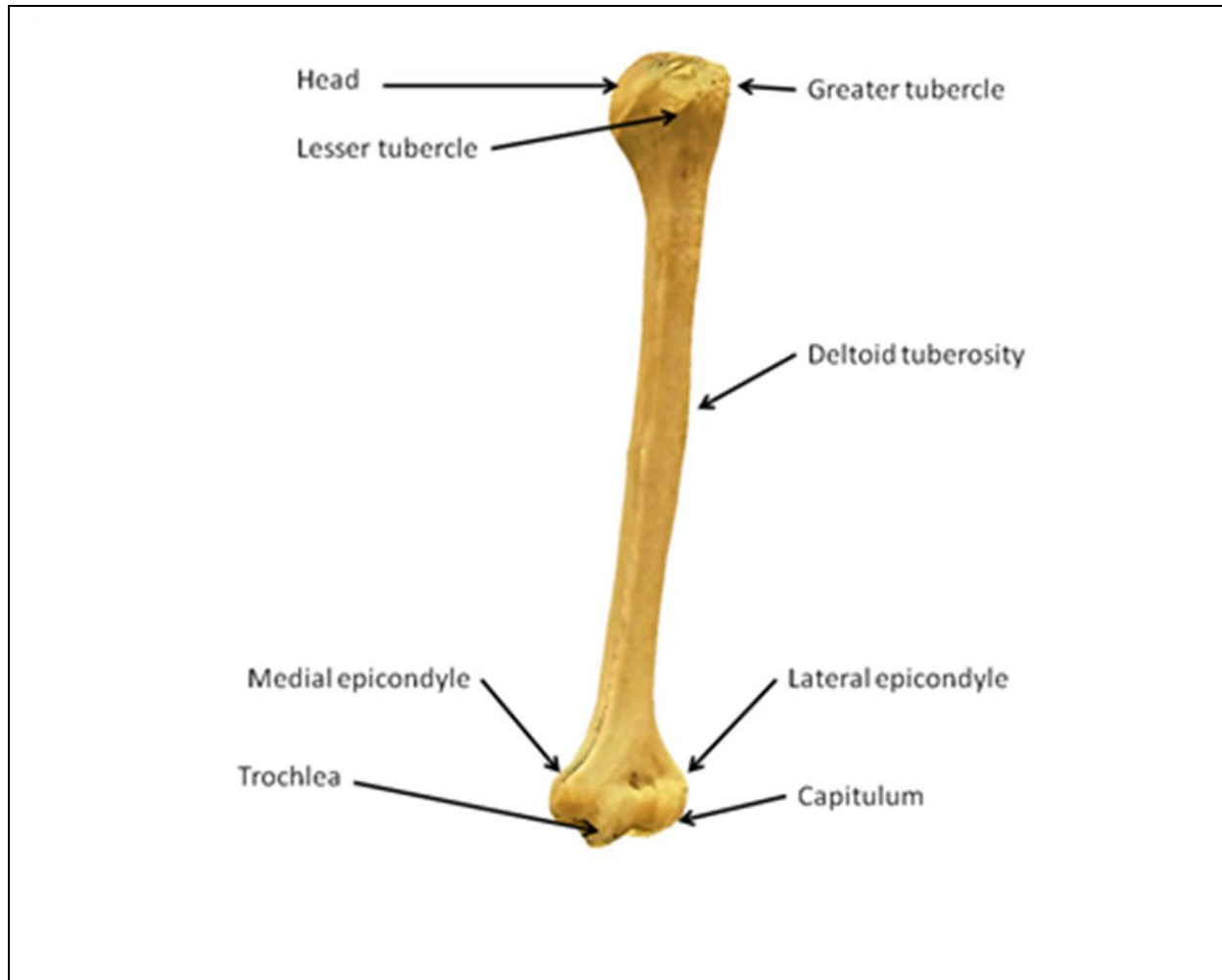


Figure 7.48. Anterior humerus

Bruce Forciea

## Ulna

The ulna and radius both support the forearm (antebrachium). The ulna is on the medial side of the forearm. The bump on your elbow is actually the olecranon process of the ulna. The ulna articulates with the trochlea of the humerus and forms a hinge joint (figs. 7.50, 7.51).

### Landmarks

The olecranon process is a rounded process on the proximal end of the ulna.

The trochlear notch of the ulna articulates with the trochlea of the humerus.

The radial notch is a flat spot that articulates with the radius.

The styloid process of the ulna is a needle-like process at the distal end.

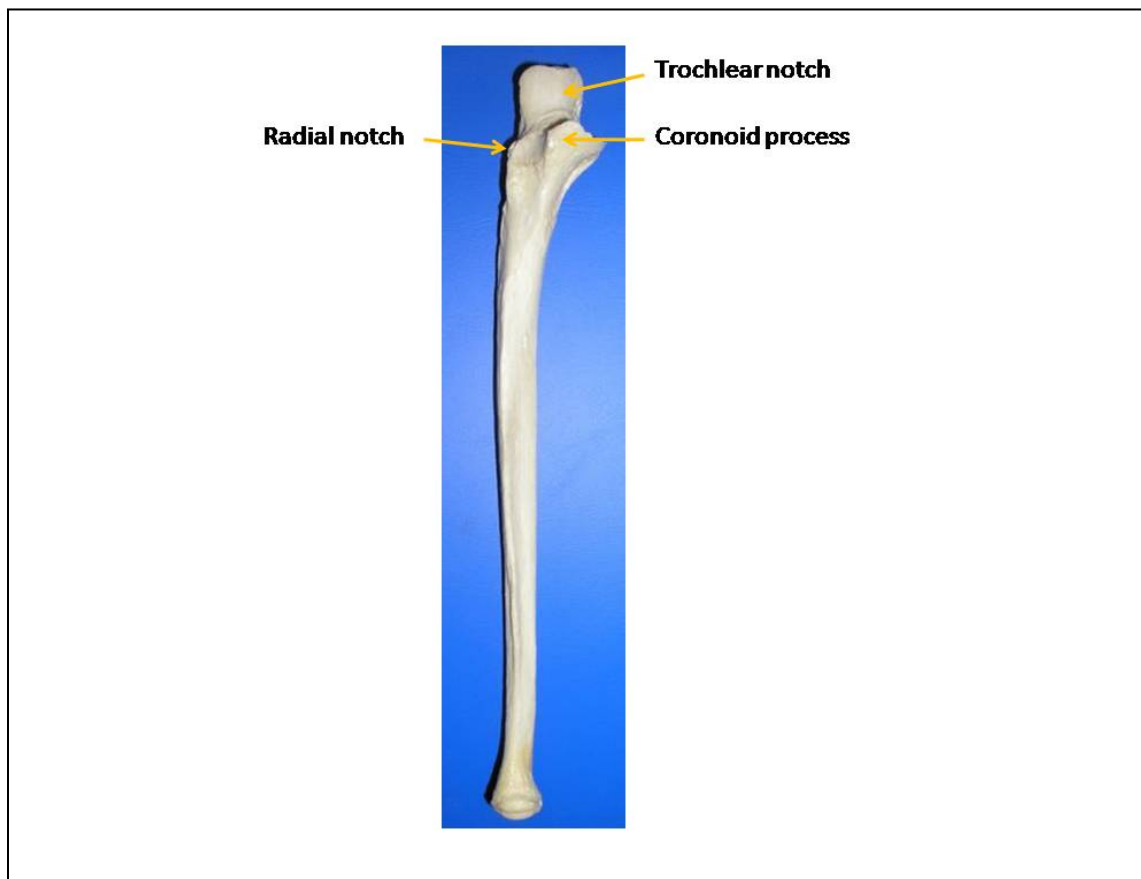


Figure 7.50. Anterior view of the ulna.

[http://commons.wikimedia.org/wiki/Image:Ulna\\_ant.jpg](http://commons.wikimedia.org/wiki/Image:Ulna_ant.jpg) Original author:

<http://commons.wikimedia.org/wiki/User:Palica>

Modified by Bruce Forciea

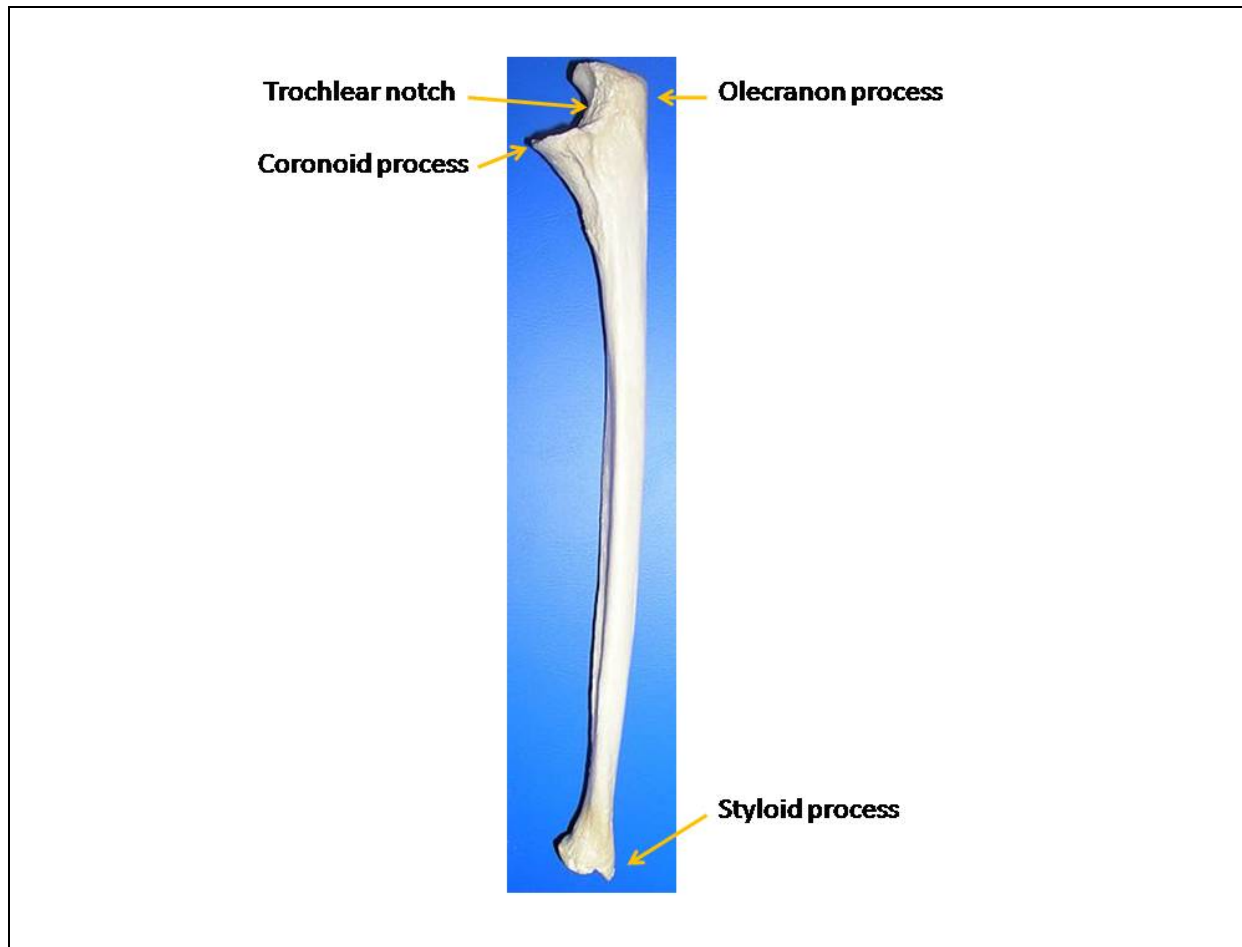


Figure 7.51. Medial view of the ulna.

[http://commons.wikimedia.org/wiki/Image:Ulna\\_med.jpg](http://commons.wikimedia.org/wiki/Image:Ulna_med.jpg)

Original author: <http://commons.wikimedia.org/wiki/User:Palica> Modified by Bruce Forciea

## Radius

The radius is also located in the forearm. It articulates with the ulna and carpal bones. The radius allows for rotation of the forearm (figs. 7.52, 7.53).

### Landmarks

The head of the radius articulates with the capitulum of the humerus. This joint can rotate.

The radial tuberosity is a bump on the proximal aspect of the radius. The biceps muscle attaches there.

The styloid process is a needle-like process on the distal aspect of the radius.

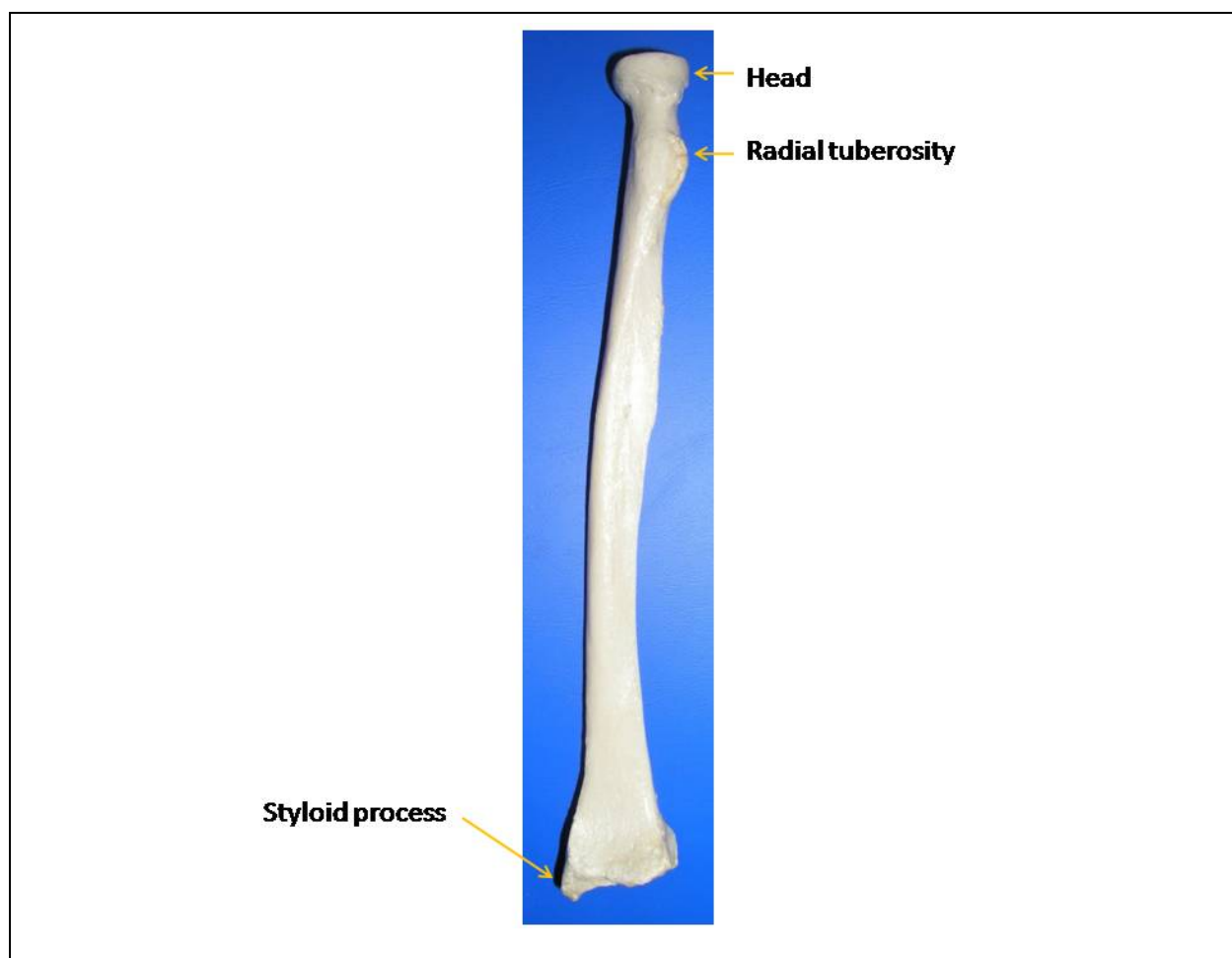


Figure 7.52. Anterior Radius

[http://commons.wikimedia.org/wiki/Image:Radius\\_ant.jpg](http://commons.wikimedia.org/wiki/Image:Radius_ant.jpg)

Original author: <http://commons.wikimedia.org/wiki/User:Palica>

Modified by Bruce Forciea

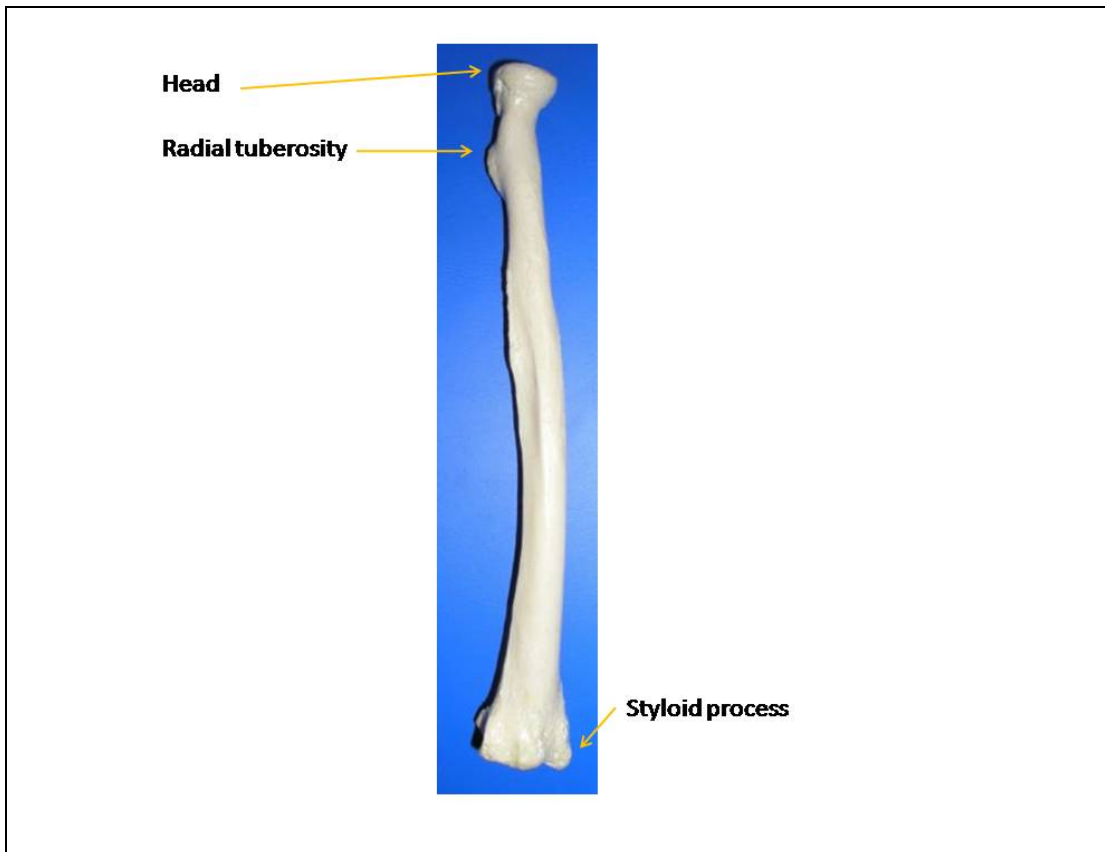


Figure 7.53. Posterior Radius

[http://commons.wikimedia.org/wiki/Image:Radius\\_post.jpg](http://commons.wikimedia.org/wiki/Image:Radius_post.jpg)

Original author: <http://commons.wikimedia.org/wiki/User:Palica>

Modified by Bruce Forciea

## Carpals

The carpal bones are located in the wrist. They consist of 8 bones that articulate with the radius and ulna proximally and the metacarpals distally (fig. 7.54).

The 8 carpal bones:

- Scaphoid
- Lunate
- Triquetrum
- Pisiform
- Trapezium
- Trapezoid
- Capitate
- Hamate

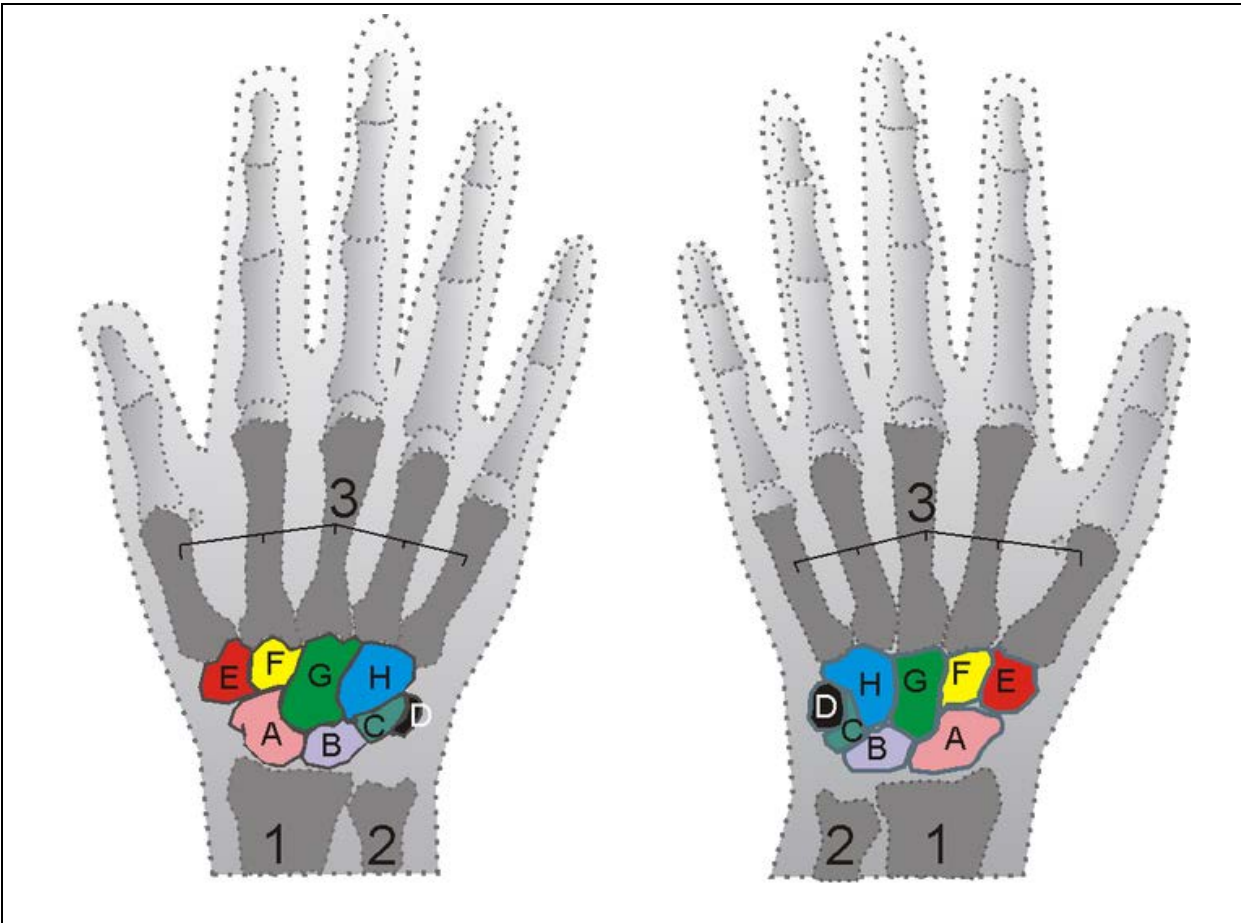


Figure 7.54. Carpals of the right hand.

- A. Scaphoid
- B. Lunate
- C. Triquetrum
- D. Pisiform
- E. Trapezium
- F. Trapezoid
- G. Capitate
- H. Hamate

<http://commons.wikimedia.org/wiki/Image:Carpus.png>

Author: Benutzer Zoph

## Metacarpals

The metacarpals are tubular shaped bones that lie distal to the carpals. There are 5 metacarpals numbered accordingly from the thumb (1) to the little finger (5) (fig. 7.55).

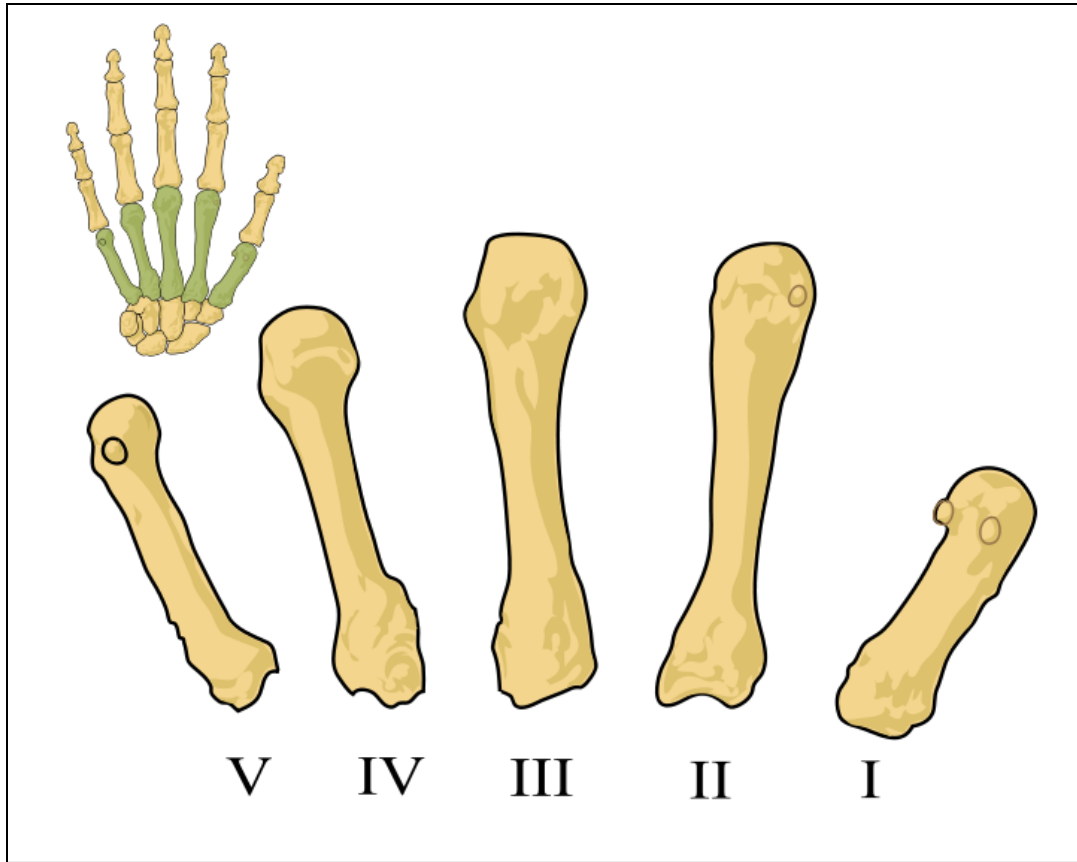


Figure 7.55. Metacarpals

[http://commons.wikimedia.org/wiki/Image:Metacarpals\\_numbered-en.svg](http://commons.wikimedia.org/wiki/Image:Metacarpals_numbered-en.svg)

### Phalanges

The phalanges comprise the fingers. They are numbered the same as the metacarpals and named for their location. The thumb has only a proximal and distal phalanx. The remaining fingers have proximal, middle and distal phalanges (fig. 7.56).

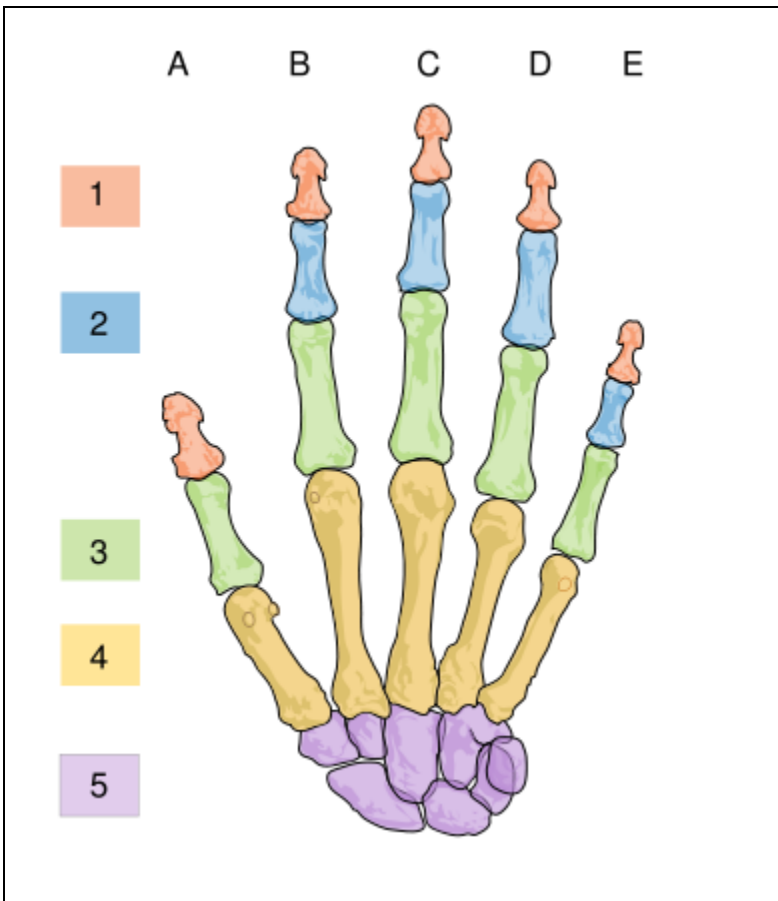


Figure 7.56. Bones of the hand.

1. Distal phalanx
  2. Middle phalanx
  3. Proximal phalanx
  4. Metacarpals
  5. Carpals
- A. First  
B. Second  
C. Third  
D. Fourth  
E. Fifth

Notice the thumb only has proximal and distal phalanges. The remaining fingers have proximal, middle and distal phalanges.

[http://commons.wikimedia.org/wiki/Image:Scheme\\_human\\_hand\\_bones-numbers.svg](http://commons.wikimedia.org/wiki/Image:Scheme_human_hand_bones-numbers.svg)

### Bones of the Lower Extremity

The lower extremity consists of the pelvis, leg, ankle and foot. The bones of the lower extremity are as follows:

- Coxal
- Femur
- Patella
- Tibia
- Fibula
- Talus
- Calcaneus
- Tarsals
- Metatarsals
- Phalanges

The pelvic girdle consists of the 2 coxal bones.



## **Coxal Bone**

The pelvis consists of the sacrum and 2 coxal bones. The coxal bones are actually 3 bones fused together. The 3 bones are the ilium, ischium and pubis. The coxal bones articulate with the sacrum at the sacroiliac joints and the femurs at the hip joints (figs. 7.57, 7.58, 7.59).

### **Landmarks**

The acetabulum is a socket-like concave structure that articulates with the head of the femur to form the hip joint.

The iliac crest is the most superior structure of the coxal bone. It is a ridge of bone that extends along the superior margin of the ilium.

The anterior superior iliac spine is a bump on the anterior portion of the ilium. The iliac crest terminates here. This is an important site of muscle attachments.

The posterior superior iliac spine is a bump on the posterior aspect of the ilium. The iliac crest terminates here posteriorly.

The obturator foramen is a space that is formed by the pubis and ischium.

The symphysis pubis is a fibrocartilaginous disc that forms a fibrous joint between the 2 pubic bones.

The pubic tubercle resides on the anterior superior aspect of the pubis.

The ischial tuberosity is a thickened area of bone located on the posterior aspect of the ischium. The hamstring muscles attach here.

The pubic arch is the angle between the pubic bones.

## **Male and Female Differences**

Generally the differences between male and female pelves are due to functions of childbirth. The pubic arch is greater in females and the ilia may be more flared. The sacrum tends to be more curved in males. The female pelvis is wider in all directions.

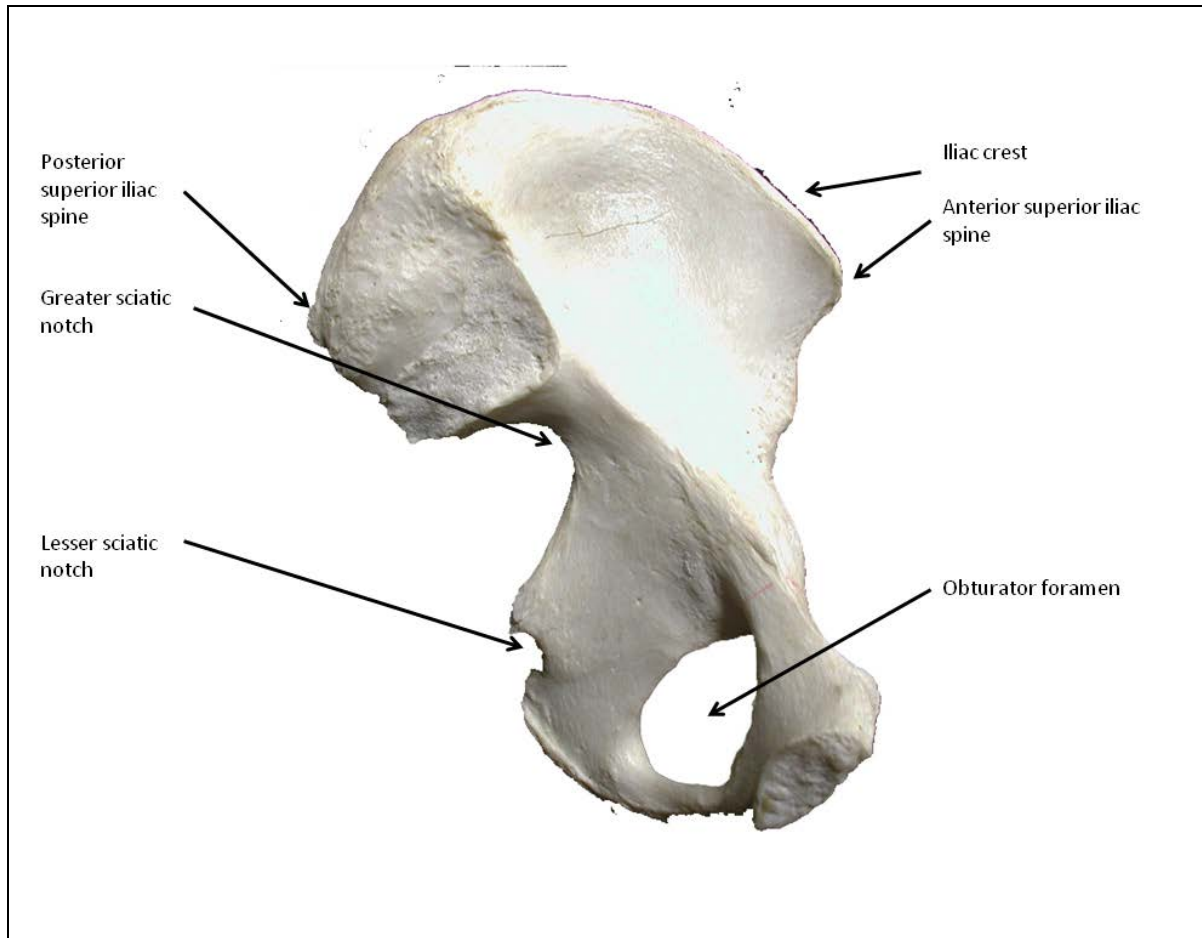


Figure 7.57. Coxal bone. Medial view.

Bruce Forciea

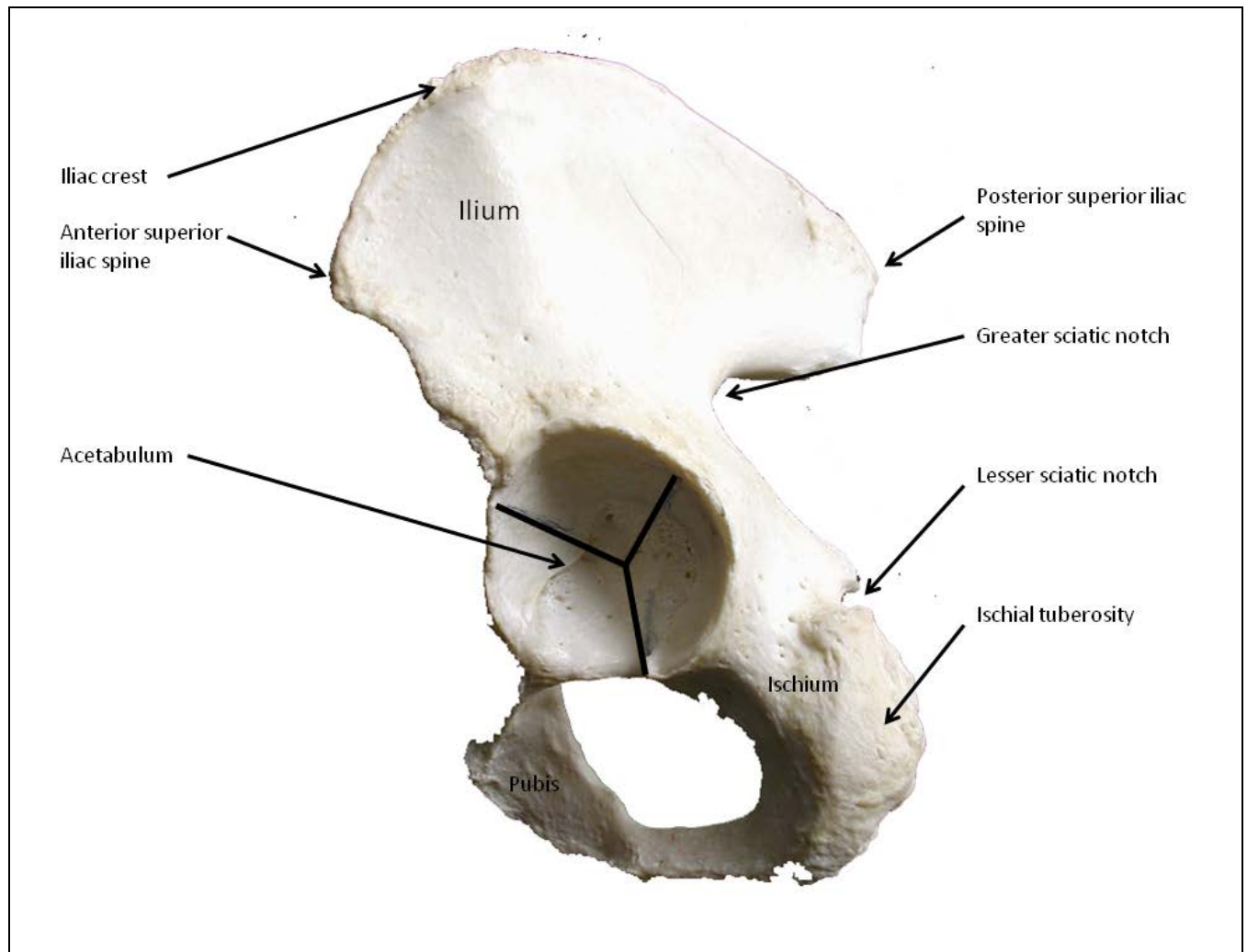


Figure 7.58. Coxal bone. Lateral view.

Bruce Forciea

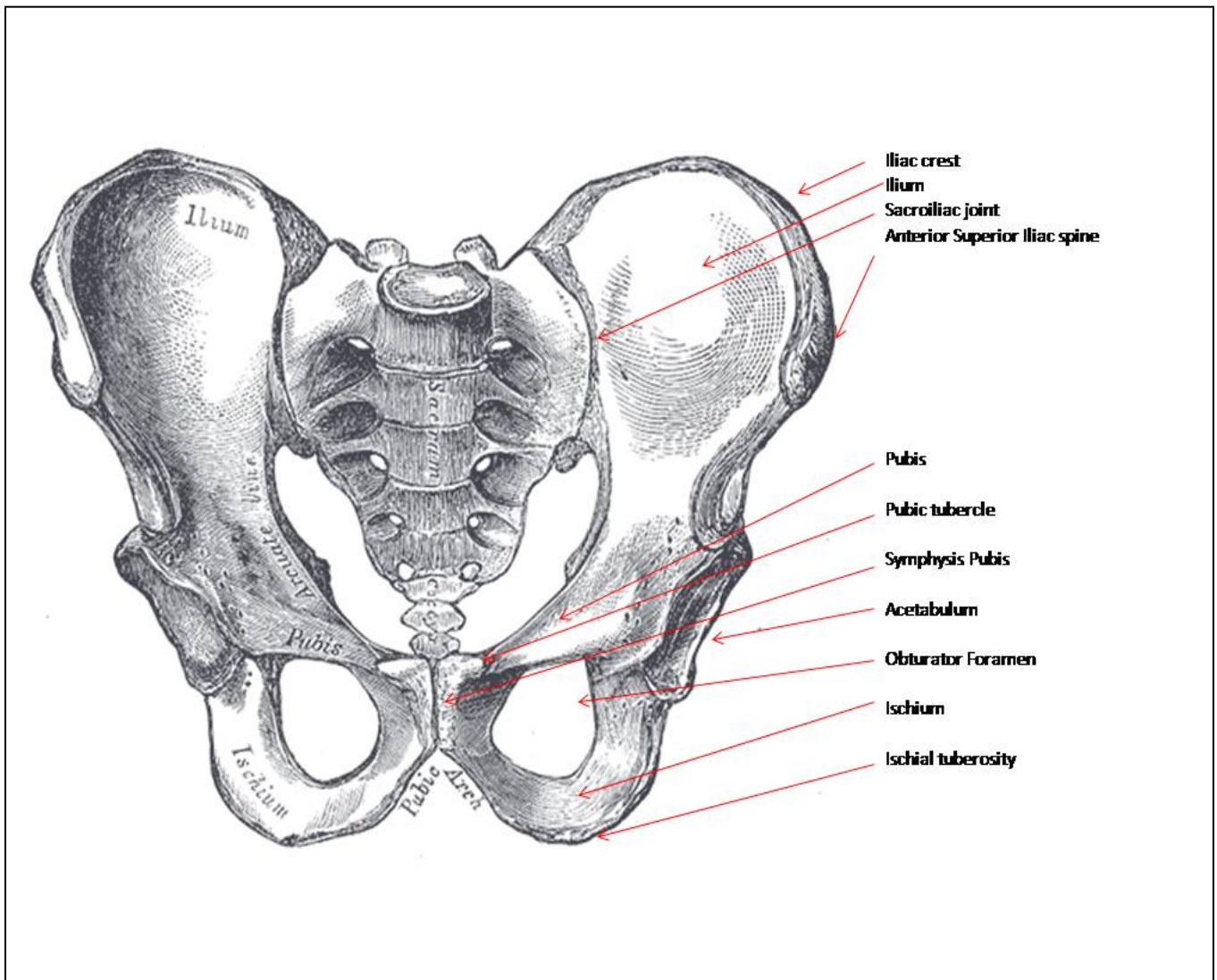


Figure 7.59. Coxal bones of the pelvis. The coxal bones are 3 fused bones consisting of the ilium, ischium and pubis.

<http://commons.wikimedia.org/wiki/Image:Gray241.png>

## Femur

The femur is the longest bone in the body. It articulates with the acetabulum of the coxal bone proximally and with the patella and tibia distally (figs. 7.60, 7.61).

### Landmarks

The head of the femur is a rounded process on the proximal end.

The neck of the femur is the area that connects the head with the shaft.

The greater trochanter is a large process located on the proximal lateral aspect of the femur.

The lesser trochanter is a smaller process located on the proximal medial aspect.

There are 2 large rounded processes on the distal aspect of the femur called the medial and lateral condyles.

The linea aspera is a roughened area on the posterior aspect. It is a site of muscle attachments.

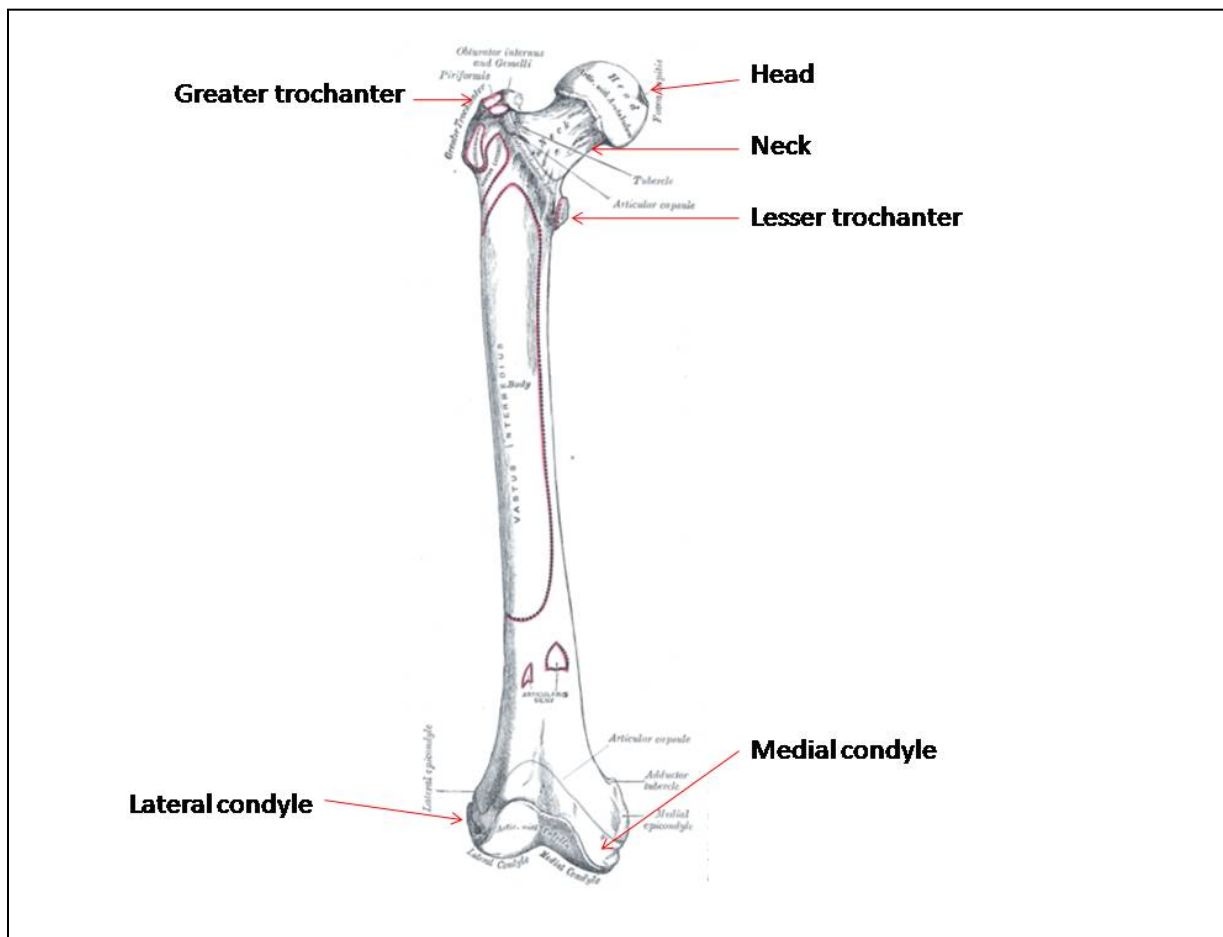


Figure 7.60. Anterior Femur.

[http://commons.wikimedia.org/wiki/Image:Femur\\_front.png](http://commons.wikimedia.org/wiki/Image:Femur_front.png)

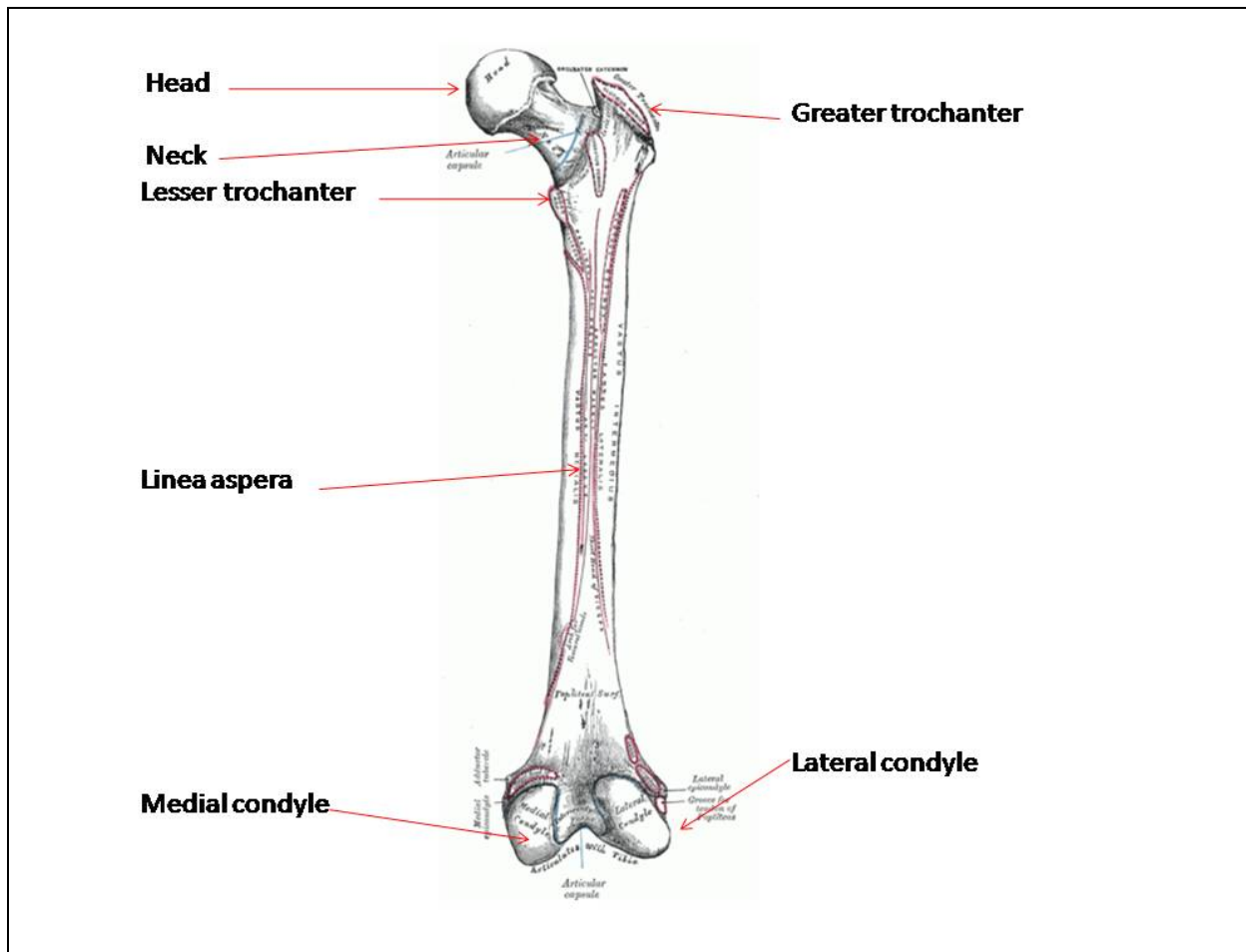


Figure 7.61. Posterior view of femur.

[http://commons.wikimedia.org/wiki/Image:Femur\\_back.png](http://commons.wikimedia.org/wiki/Image:Femur_back.png)

## Tibia

The tibia is the larger of 2 bones of the lower leg. It articulates with the femur, fibula, patella and talus bones (fig. 7.62).

### Landmarks

The tibial condyles are large rounded processes on the proximal aspect of the tibia. The 2 condyles are named medial and lateral.

The tibial tuberosity is a broad bump on the anterior aspect of the tibia.

The medial malleolus is a rounded process on the distal medial aspect of the tibia. It is the bump on the inside of the ankle.

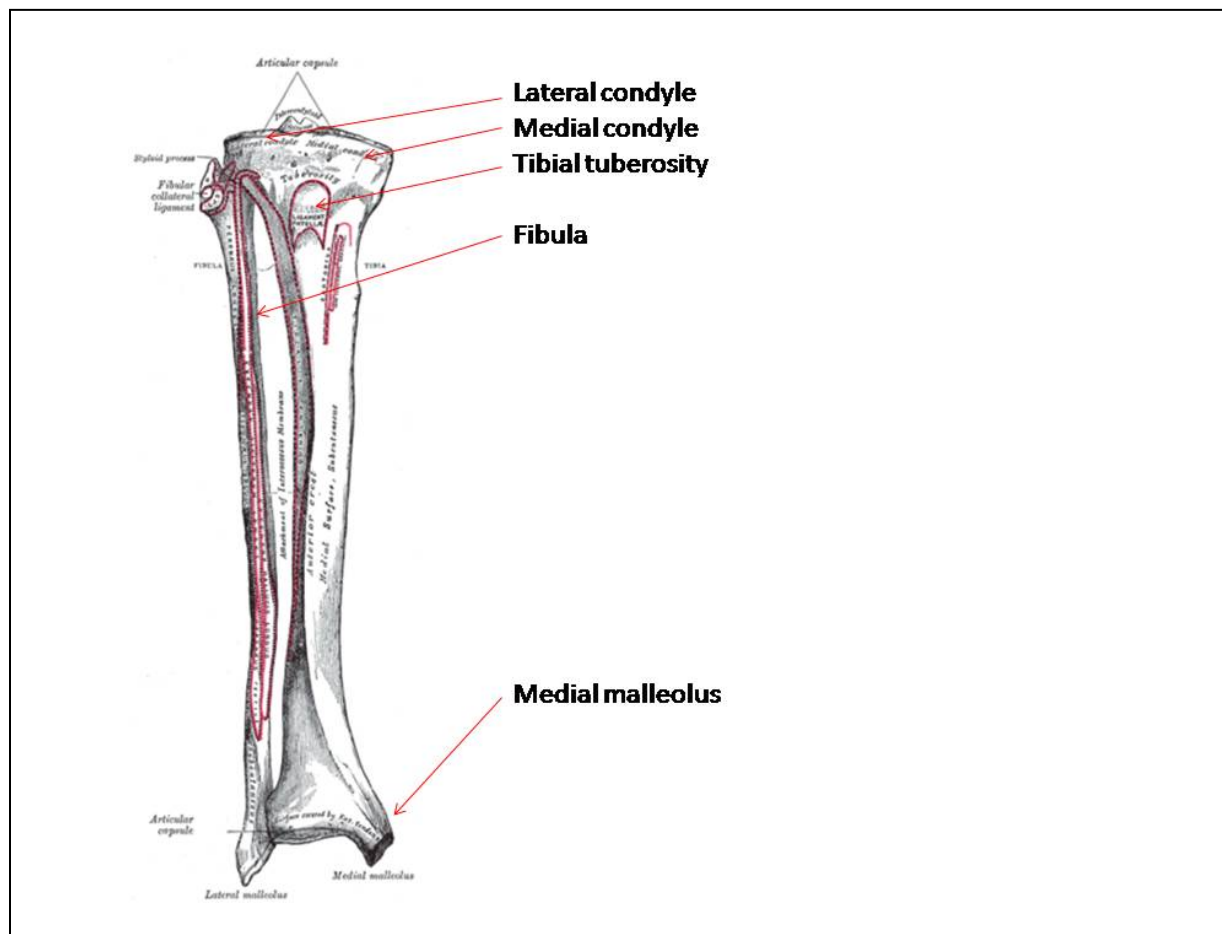


Figure 7.62. Anterior view of the tibia

<http://commons.wikimedia.org/wiki/Image:Gray258.png>

## Fibula

The fibula is the lateral bone in the lower leg. It forms the lateral ankle and articulates with the tibia and talus bones (fig. 7.63).

### Landmarks

The fibular head is a rounded process on the proximal end of the bone.

The lateral malleolus is a rounded process on the distal end of the bone. It forms the lateral ankle.

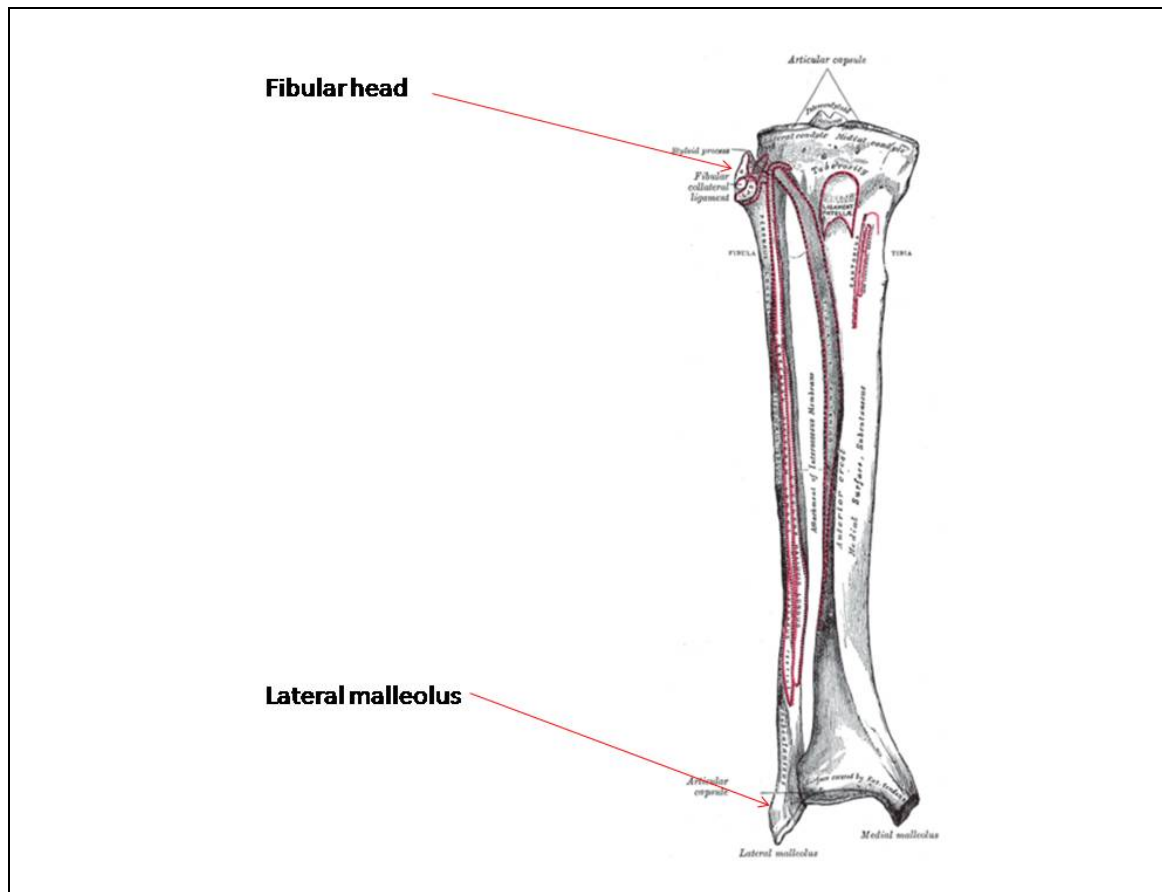


Figure 7.63. Anterior view of fibula.

<http://commons.wikimedia.org/wiki/Image:Gray258.png>



## **The Ankle**

The ankle and foot consist of the tarsals, metatarsals and phalanges and has a similar construction to the wrist and hand (figs. 7.64, 7.65).

Tarsals:

- Calcaneus
- Talus
- Navicular
- Cuboid
- Lateral cuneiform
- Intermediate cuneiform
- Medial cuneiform

### **Calcaneus and Talus**

The calcaneus or heel bone is the largest of the tarsals. The talus forms the ankle joint with the tibia and fibula. These bones articulate with the navicular and cuboid bones. There are 3 cuneiform bones named for their position which articulate with the metatarsals.

### **Metatarsals and Phalanges**

There are 5 tubular metatarsals that are named for their position (1-5). The phalanges are similar to those in the fingers. The big toe only has proximal and distal phalanges while the remaining toes have proximal, middle and distal phalanges.

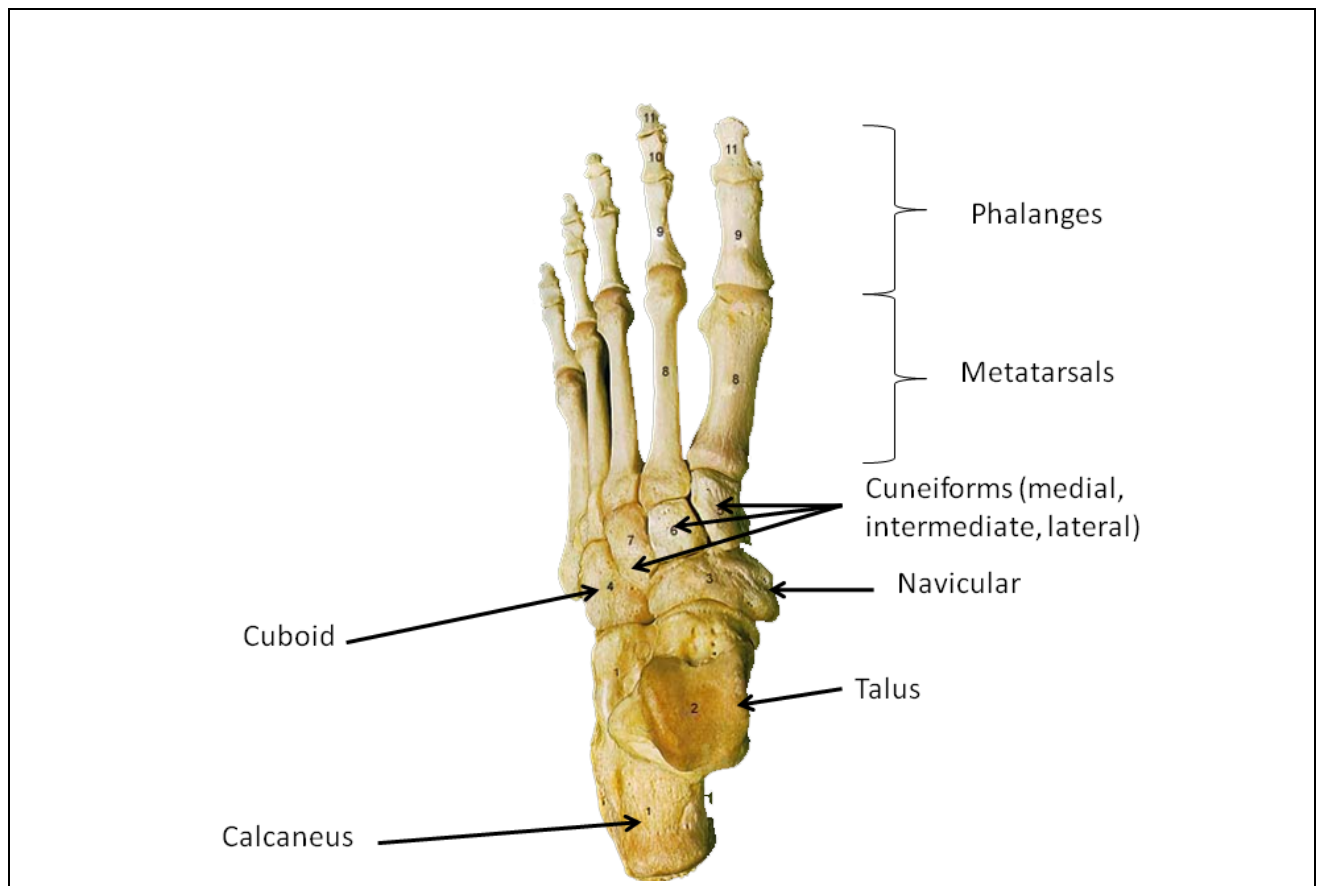


Figure 7.64. Foot and Ankle

[http://commons.wikimedia.org/wiki/Image:Skeleton\\_foot.JPG](http://commons.wikimedia.org/wiki/Image:Skeleton_foot.JPG)

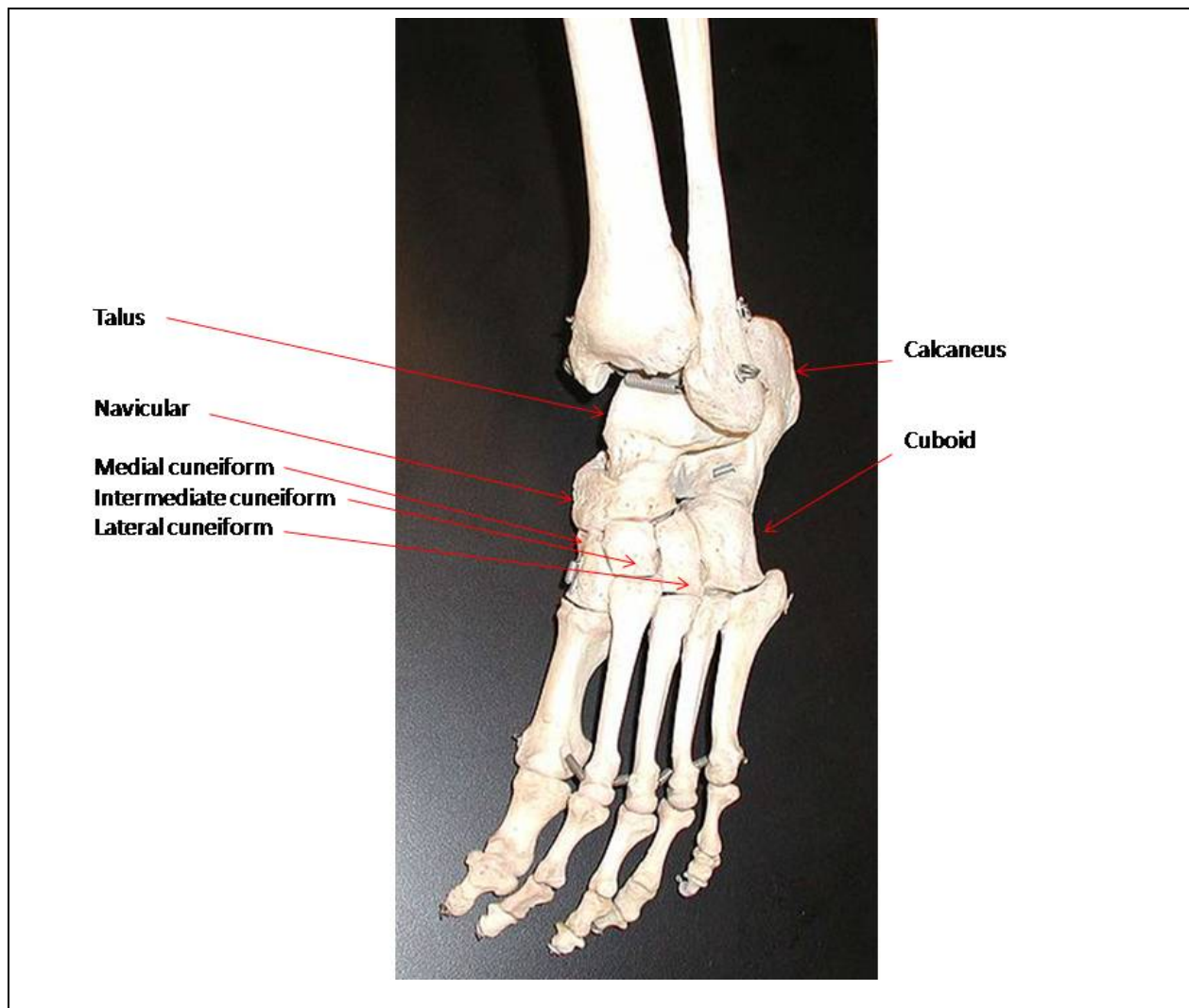


Figure 7.65. Foot and Ankle

[http://commons.wikimedia.org/wiki/Image:Foot\\_bones.jpg](http://commons.wikimedia.org/wiki/Image:Foot_bones.jpg)

## **Real World A&P**

### **Osteoporosis**

Osteoporosis is a condition where the bones become fragile and brittle and can fracture. It is estimated that as many as 44 million Americans are at risk of developing osteoporosis. Osteoporosis is more prevalent in women who count for 80% of those who develop the disease.

According to the National Osteoporosis Foundation the risk factors include:

1. Small, thin frame
2. Caucasian or Asian descent
3. Postmenopausal
4. Surgically induced menopause
5. High doses of thyroid medication or steroids (prednisone)
6. Immune system drugs or chemotherapy
7. Diet low in calcium
8. Sedentary lifestyle
9. Smoke cigarettes or drink alcohol in excess

The more risk factors you have the greater your risk of developing osteoporosis.

Osteoporosis is diagnosed with tests performed by your medical doctor such as a bone density test.

People with osteoporosis should avoid smoking, coffee, and alcohol because they induce a negative calcium balance. Smokers have a 15-30% lower bone mineral content than non-smokers. Weight bearing exercise also helps to inhibit the disease.

## Review Question Chapter 7

1. Which of the following is not a part of an endochondral bone:
  - a. Epiphysis
  - b. Diaphysis
  - c. Condyle
  - d. Suture
2. Which of the following is not a stage in endochondral ossification:
  - a. Ossification of a cartilage template
  - b. Secondary ossification center forms
  - c. Medullary cavity forms
  - d. Bone grows from osteocytes in all directions
3. Which of the following bones is an intramembraneous bone:
  - a. Femur
  - b. Radius
  - c. Metacarpal
  - d. Parietal
4. Where is trabeculated bone found:
  - a. Epiphysis
  - b. Diaphysis
  - c. Medullary cavity
  - d. Growth plate
5. Which of the following bones is not part of the axial skeleton:
  - a. Rib
  - b. Humerus
  - c. Frontal
  - d. Cervical vertebra
6. Which bone contains the external auditory meatus:
  - a. Frontal
  - b. Temporal
  - c. Parietal
  - d. Sphenoid

7. The foramen magnum is located in which bone:
- Occipital
  - Parietal
  - Temporal
  - Frontal
8. The sella turcica is located in which bone:
- Ethmoid
  - Frontal
  - Sphenoid
  - Occipital
9. Fibers from the olfactory nerves pass through this skeletal structure:
- Sella turcica
  - Cribriform plate
  - Foramen magnum
  - Foramen ovale
10. The coronal suture unites which bones:
- Frontal, parietal
  - Parietal, temporal
  - Temporal, occipital
  - Parietal, occipital
11. Which of the following is not usually present in a typical cervical vertebra:
- Transverse foramen
  - Bifid spinous process
  - Large vertebral canal
  - Large body
12. The dens is found on which vertebra:
- C1
  - C2
  - T1
  - L5
13. Which 3 bones unite to form the coxal bone:
- Ilium, pubis, sacrum
  - Ilium, ischium, pubis
  - Pubis, coccyx, sacrum
  - Ischium, ilium, sacrum

14. Where is the greater trochanter located:

- a. Tibia
- b. Humerus
- c. Femur
- d. Sacrum

15. Which bony process is the sharpest:

- a. Tubercle
- b. Tuberosity
- c. Styloid
- d. Trochanter

16. The head of the radius articulates with the:

- a. Trochlea
- b. Coronoid process
- c. Coracoids process
- d. Capitulum

17. The acromion process is located on which bone:

- a. Humerus
- b. Scapula
- c. Sternum
- d. Femur

18. The medial malleolus is part of which bone:

- a. Tibia
- b. Fibula
- c. Humerus
- d. Ulna

19. The most superior portion of the sternum is known as:

- a. Body
- b. Xiphoid
- c. Head
- d. Manubrium

20. The zygomatic arch consists of which 2 bones:

- a. Zygomatic and parietal
- b. Zygomatic and temporal
- c. Zygomatic and maxilla
- d. Zygomatic and mandible

# Chapter 8

## Joints



## **Joints**

This chapter focuses on the joints of the body. Joints connect the bones of the body and allow it to move and grow. Joints are called articulations and can be classified according to the tissue that connects the bones. Joints can also be classified according to their degree of movement.

Synarthrotic joints are immovable. Examples include the sutures of the skull.

Amphiarthrotic joints are slightly moveable. Examples include interosseous ligaments that connect some of the long bones such as the radius and ulna.

Diarthrotic joints are freely moveable such as the shoulder or hip.

There are three basic categories of joints:

1. Fibrous
2. Cartilagenous
3. Synovial

### **Fibrous Joints**

Fibrous joints are held together by dense connective tissue. There are three types of fibrous joints:

1. Syndesmosis
2. Suture
3. Gomphosis

A syndesmosis is a slightly movable joint formed by dense connective tissue between two bones. An example is called an interosseous ligament that connects the radius and ulna together. An interosseous ligament also connects the tibia and fibula.

A suture is a joint between the flat bones of the skull. The bones are united by a band of dense connective tissue called a sutural ligament. Sutures are considered synarthrotic or immovable.

A gomphosis is a joint in which a cone-shaped process is united with a cone-shaped socket. A tooth is a good example of a gomphosis. The tooth unites with the bone via a periodontal ligament.

### **Cartilagenous Joints**

In cartilaginous joints hyaline or fibrous cartilage unites the bones. There are two types of cartilaginous joints; symphysis and synchondrosis.

A symphysis consists of areas of hyaline cartilage on the ends of the bones connected to a section of fibrocartilage. The intervertebral disc is an example of a symphysis. These are classified as amphiarthrotic or slightly movable. Another example is the symphysis pubis that connects the right and left pubic bones of the pelvis.

A synchondrosis consists of hyaline cartilage uniting bones. An example of a synchondrosis is the cartilage between the ribs and the sternum often referred to as the costochondral cartilage. Another example is the epiphyseal plate located in the epiphysis of a long bone.

## Synovial Joints

Most of the joints in the body are synovial joints. Synovial joints are complex joints that consist of a number of parts. Synovial joints are freely movable or diarthrotic. Synovial joints are encapsulated by a synovial membrane. They contain fluid (synovial fluid) and cartilage on the ends of the bones. Strong bands of dense connective tissue called ligaments connect the bones together. Some synovial joints contain discs of fibrocartilage called menisci that act as small cushions to help dissipate force from the bones. Small sacs called bursa contain synovial fluid that helps to cushion the area around the joints and reduce friction.

### Types of Synovial Joints

There are a number of types of synovial joints named for their shape. The shape of the joint determines its movement (fig. 8.1).

Ball and socket joints consist of a rounded process and rounded socket. These include the hip and shoulder and allow for a variety of movements.

Hinge joints consist of a convex surface and concave socket. Examples include the joint between the humerus and ulna as well as in some of the phalanges. Hinge joints only move in one plane.

Condylloid joints consist of oval processes fitting into elliptical sockets. An example of this joint is the metacarpal phalangeal joint.

Gliding joints consist of flattened surfaces connected together. Examples include the carpal bones of the wrist.

Pivot joints consist of a cylinder fitting into a ring of bone. Examples include the joint between the atlas and axis of the spine and the joint between the radius and humerus.

Saddle joints consist of two bones having both concave and convex surfaces. An example is the carpal-metacarpal joint of the hand.

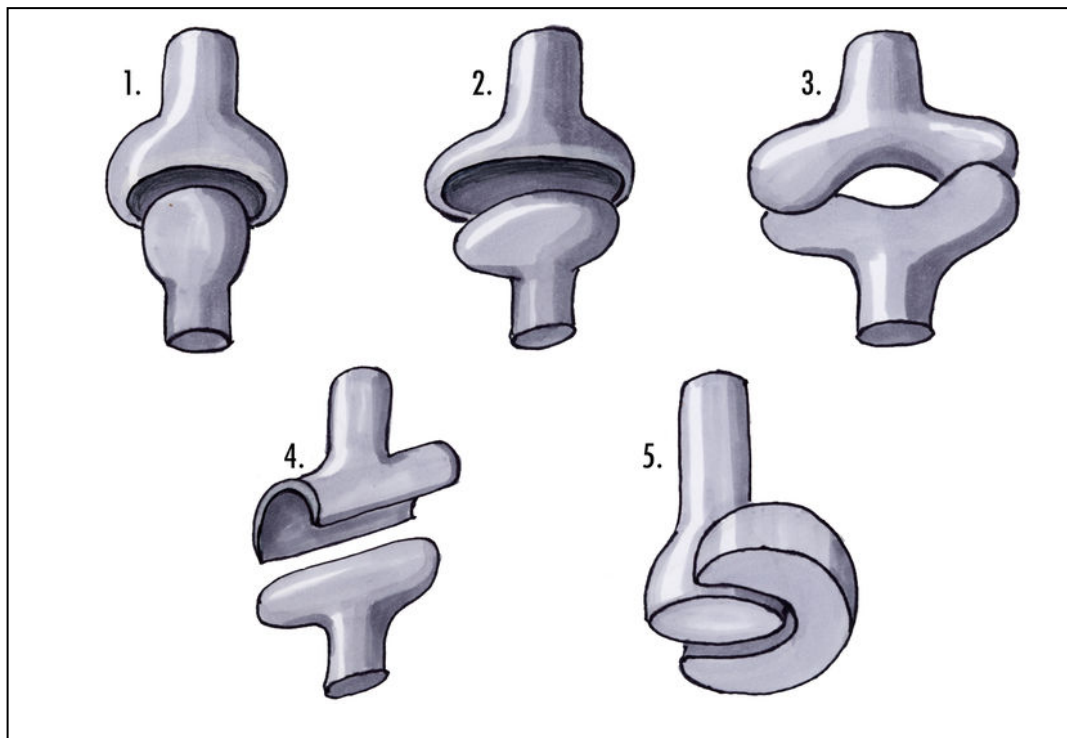


Figure 8.1. Types of synovial joints.

1. Ball and socket
2. Condylloid
3. Saddle
4. Hinge
5. Pivot

[http://commons.wikimedia.org/wiki/Image:Gelenke\\_Zeichnung01.jpg](http://commons.wikimedia.org/wiki/Image:Gelenke_Zeichnung01.jpg)

Author: [Produnis](#)

## **Joint Movements**

Joints move according to their shapes. The following movements are organized according to their respective joints.

### **Shoulder**

The shoulder joint consists of the scapula and humerus.

Flexion consists of the humerus moving anterior in a sagittal plane.

Extension consists of the humerus moving posterior in a sagittal plane.

Abduction is the movement of the humerus away from the body in a coronal plane.

Adduction is moving the humerus toward the body in a coronal plane.

Internal rotation is moving the humerus along its long axis toward the body.

External rotation is moving the humerus along its long axis away from the body.

### **Elbow**

The elbow is formed by the connection between the humerus, radius and ulna.

Flexion is the anterior movement of the forearm in a sagittal plane.

Extension is the posterior movement of the forearm in a sagittal plane.

Supination is a rotational movement of the radius so that the palm faces upward.

Pronation is a rotational movement of the radius so that the palm faces downward.

### **Wrist**

The wrist is formed by the connection between the radius, ulna and carpals and metacarpals.

Flexion is the anterior movement of the carpals in a sagittal plane.

Extension is the posterior movement of the carpals in a sagittal plane.

Ulnar deviation is the lateral movement of the carpals toward the body in a coronal plane.

Radial deviation is the lateral movement of the carpals away from the body in a coronal plane.

### **Fingers**

The fingers are formed by the metacarpals and phalanges.

Flexion is the anterior movement of the fingers in a sagittal plane.

Extension is the posterior movement of the fingers in a sagittal plane.

Abduction is the spreading apart of the fingers.

Adduction is bringing the fingers together.

### **Hip**

The hip joint consists of the coxal and femur bones.

Flexion is the anterior movement of the femur in a sagittal plane.

Extension is the posterior movement of the femur in a sagittal plane.

Abduction is the lateral movement of the femur in a coronal plane away from the body.

Adduction is the lateral movement of the femur in a coronal plane toward the body.

Internal rotation is the movement of the femur along its long axis toward the body.  
External rotation is the movement of the femur along its long axis away from the body.  
Circumduction is the movement of the femur in a circular motion so that its distal end traces a circle.

## **Knee**

The knee joint movements occur at the femur and tibia.  
Flexion is the anterior movement of the tibia in a sagittal plane.  
Extension is the posterior movement of the tibia in a sagittal plane.

## **Ankle**

The ankle is formed by the tibia, fibula, talus and metatarsals.  
Dorsiflexion is the upward movement of the foot (as if walking on the heels) in a sagittal plane.  
Plantarflexion is the downward movement of the foot (as if walking on the toes) in a sagittal plane.  
Inversion is the movement of the foot so the sole of the foot points medially.  
Eversion is the movement of the foot so the sole of the foot points laterally.

## **Spine**

The spine is divided into cervical, thoracic and lumbar areas. The movements are the same in all of these areas.

Flexion is the anterior movement of the spine in a sagittal plane.  
Extension is the posterior movement of the spine in a sagittal plane.  
Right lateral flexion is lateral bending of the spine toward the right side.  
Left lateral flexion is the lateral bending of the spine toward the left side.  
Right rotation is the twisting of the spine toward the right.  
Left rotation is the twisting of the spine toward the left.

## **Other movements**

Protraction is the forward movement of a part along a transverse plane.  
Retraction is the backward movement of a part along a transverse plane.  
Elevation is the upward movement of a part.  
Depression is the downward movement of a part.

## **Joint Examples**

### **Shoulder**

The shoulder consists of the scapula, humerus and clavicle (figs. 8.2, 8.3). The joint between the scapula and humerus is a synovial ball and socket joint. As in all joints the shoulder joint is held together by ligaments. Some of the important ligaments include:

#### **Glenohumeral**

These ligaments exist as three bands extending from the anterior wall of the glenoid fossa and attaching to the anatomical neck and lesser tubercle of the humerus.

#### **Coracohumeral**

This ligament extends from the coracoid process of the scapula to the greater tubercle of the humerus.

#### **Transverse humeral**

This ligament forms a band of connective tissue between the greater and lesser tubercles of the humerus. The long head of the biceps brachii is found in this groove.

#### **Glenoid Labrum**

This is a rim of fibrocartilage that attaches to the glenoid fossa.

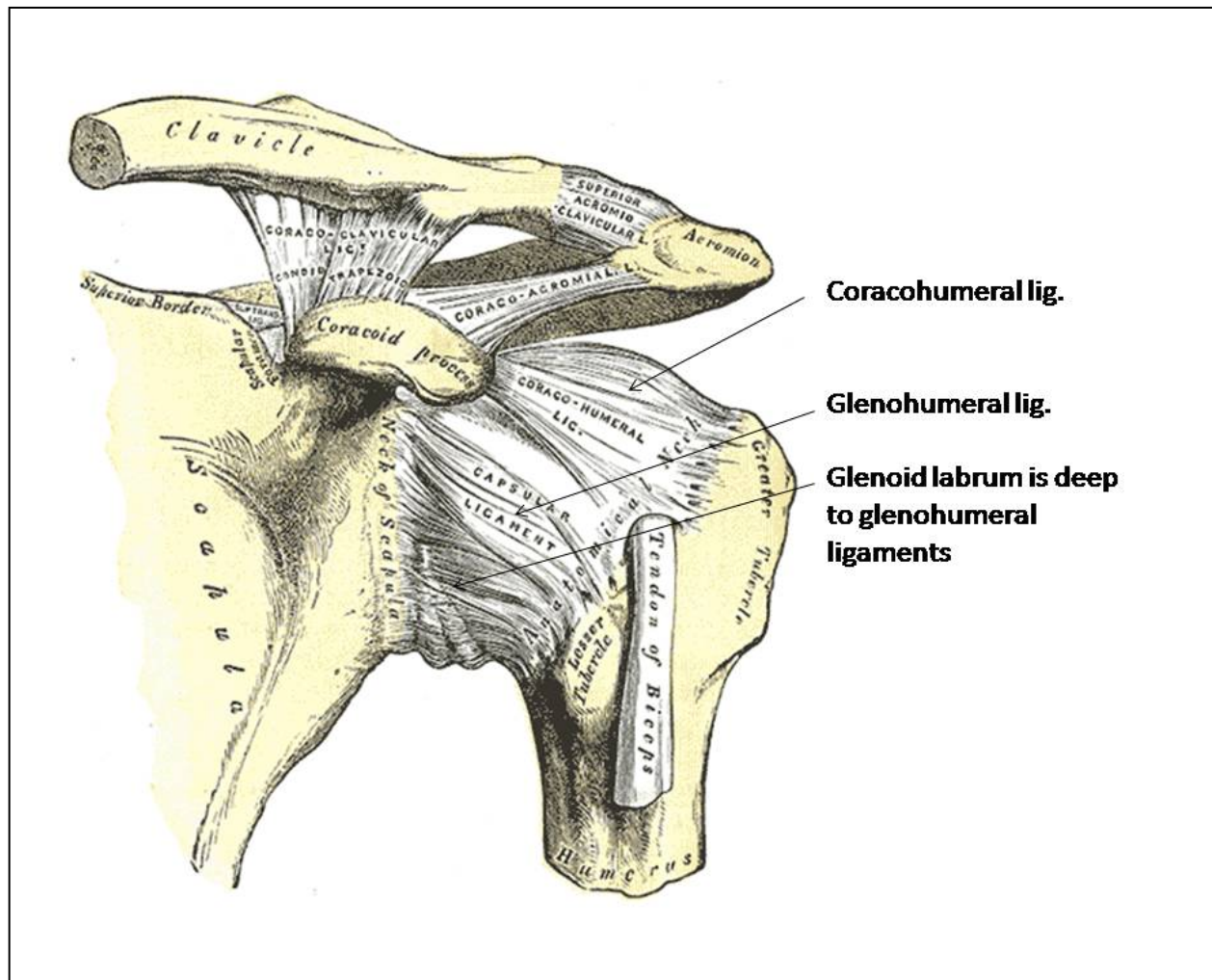


Figure 8.2. Shoulder

<http://commons.wikimedia.org/wiki/Image:Gray326.png>

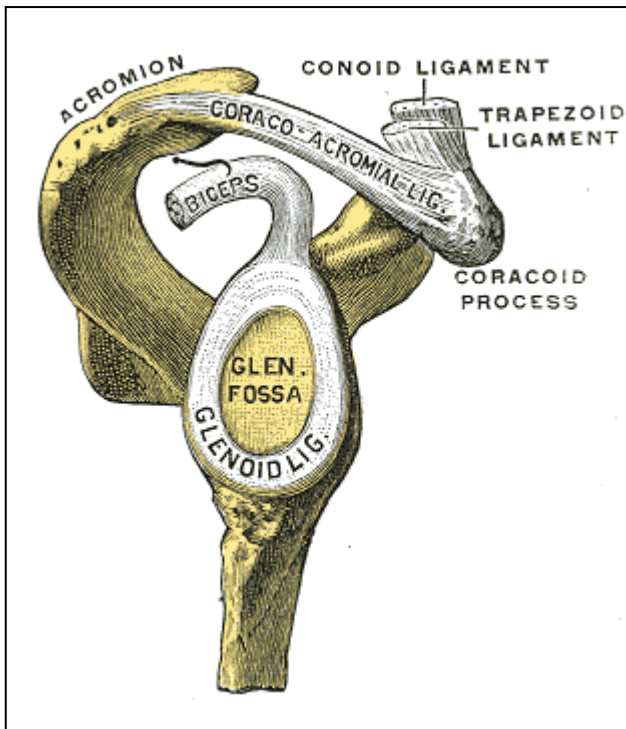


Figure 8.3. The glenoid labrum (labeled as the glenoid ligament).

<http://commons.wikimedia.org/wiki/Image:Gray328.png>

### Shoulder Separation and Dislocation

Shoulder separation occurs when the ligaments between the clavicle and scapula are torn. The lateral end of the clavicle often moves superiorly and protrudes (fig. 8.4).

A shoulder dislocation occurs between the scapula and humerus. Here the ligaments holding the humerus in the glenoid fossa are torn and the humerus comes out of the fossa.



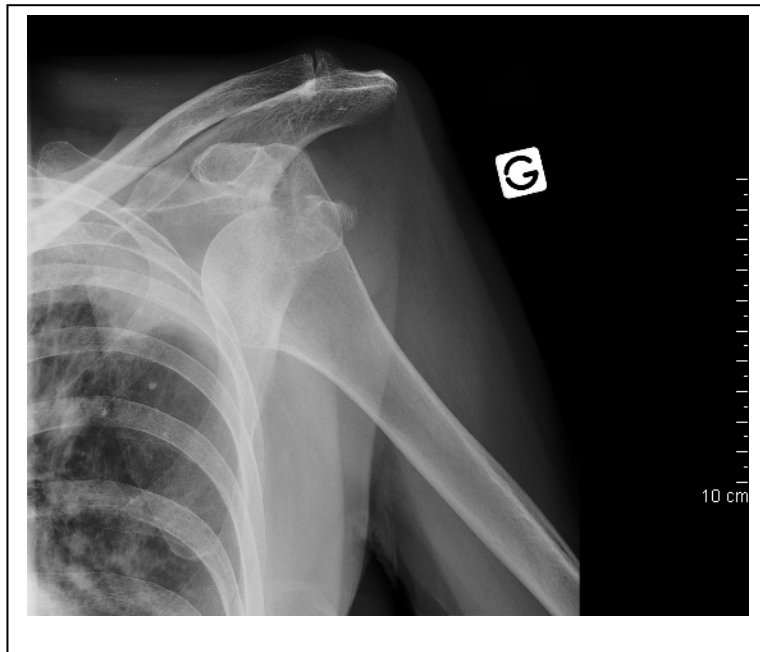

Figure 8.4. Dislocated shoulder

Notice the misalignment between the head of the humerus and glenoid fossa.

[http://commons.wikimedia.org/wiki/Image:Luxation\\_epaule.PNG](http://commons.wikimedia.org/wiki/Image:Luxation_epaule.PNG)

## Elbow

The elbow contains two articulations. One involves the humerus and ulna. The other involves the humerus and radius. The humeralulnar joint is formed by the trochlea of the humerus and the proximal portion of the ulna (figs. 8.5, 8.6). This joint can only flex and extend. The humeralradial joint is formed by the capitulum of the humerus and the radial head. This joint can rotate. Some of the important ligaments include:

### Ulnar and Radial Collaterals

The ulnar collaterals connect the medial aspect of the medial epicondyle to the medial aspect of the coronoid process of the ulna.

The radial collaterals connect the lateral epicondyle to the annular ligament of the radius.

### Annular

The annular ligament encircles the radial head and attaches to the trochlear notch of the ulna. This ligament can be prone to dislocation in children.



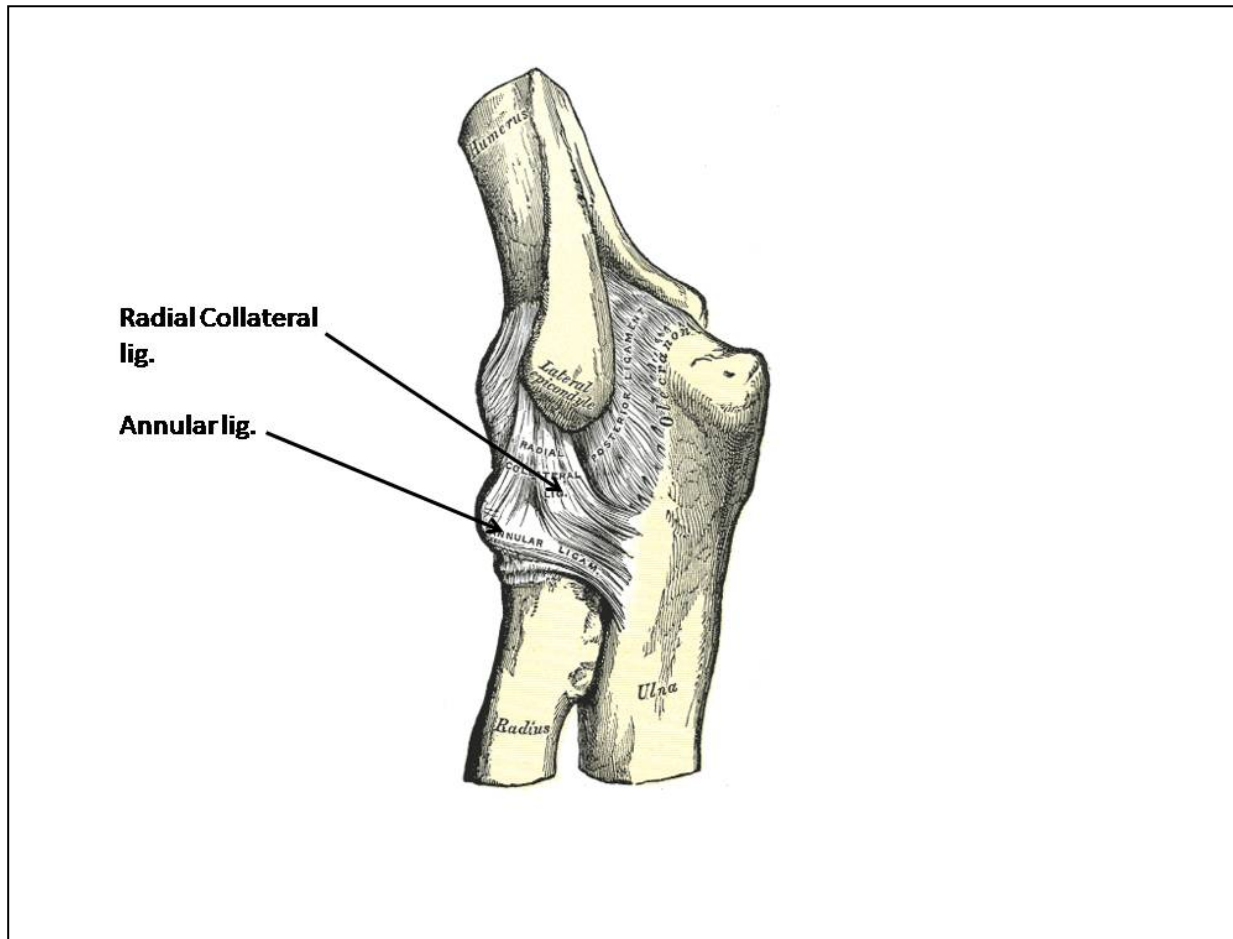


Figure 8.6. Elbow (lateral projection)

<http://commons.wikimedia.org/wiki/Image:Gray330.png>

## Hip

The hip joint consists of the femur and coxal bones. The head of the femur fits into the acetabulum of the coxal bone (figs. 8.7, 8.8). The hip joint has the same motions as the shoulder. The ligaments include:

The iliofemoral ligament extends from the ilium to the greater and lesser trochanters of the femur. It is Y-shaped and is considered the strongest ligament in the body.

The ischiofemoral ligament extends from the ischium to the joint capsule of the femur.

The pubofemoral ligament extends from the pubis to the joint capsule of the femur.

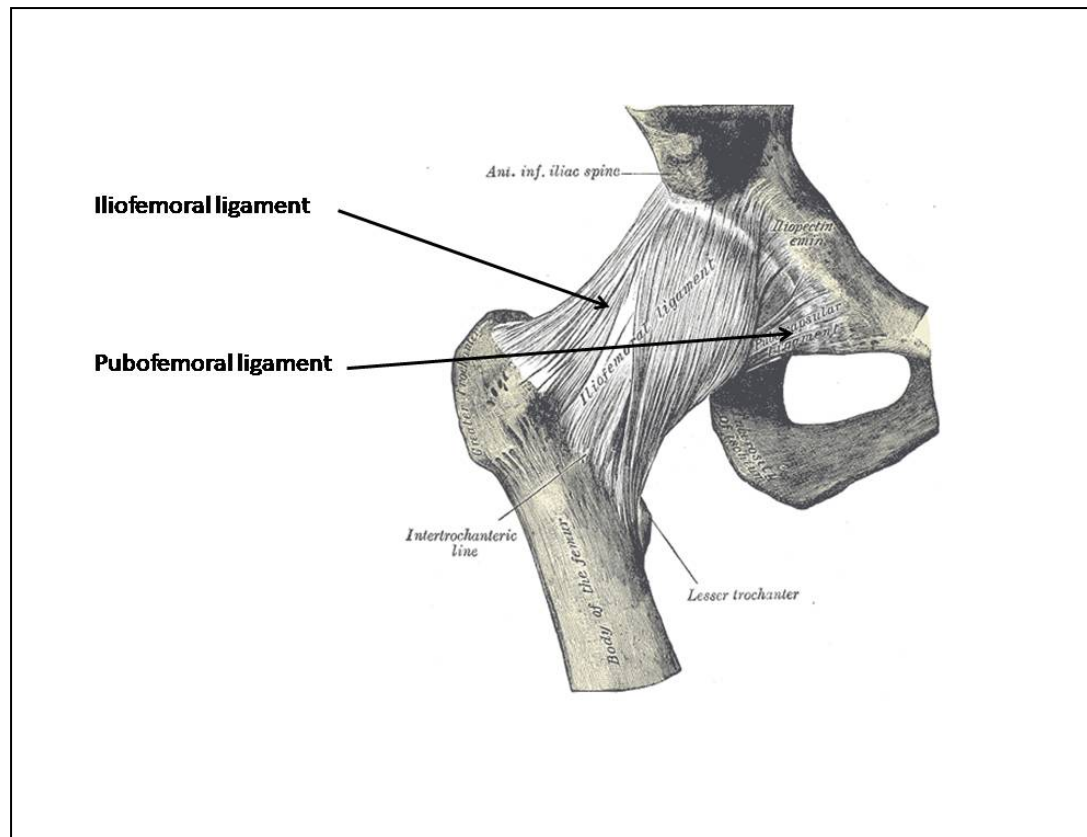


Figure 8.7. Hip (anterior view)

<http://commons.wikimedia.org/wiki/Image:Gray339.png>

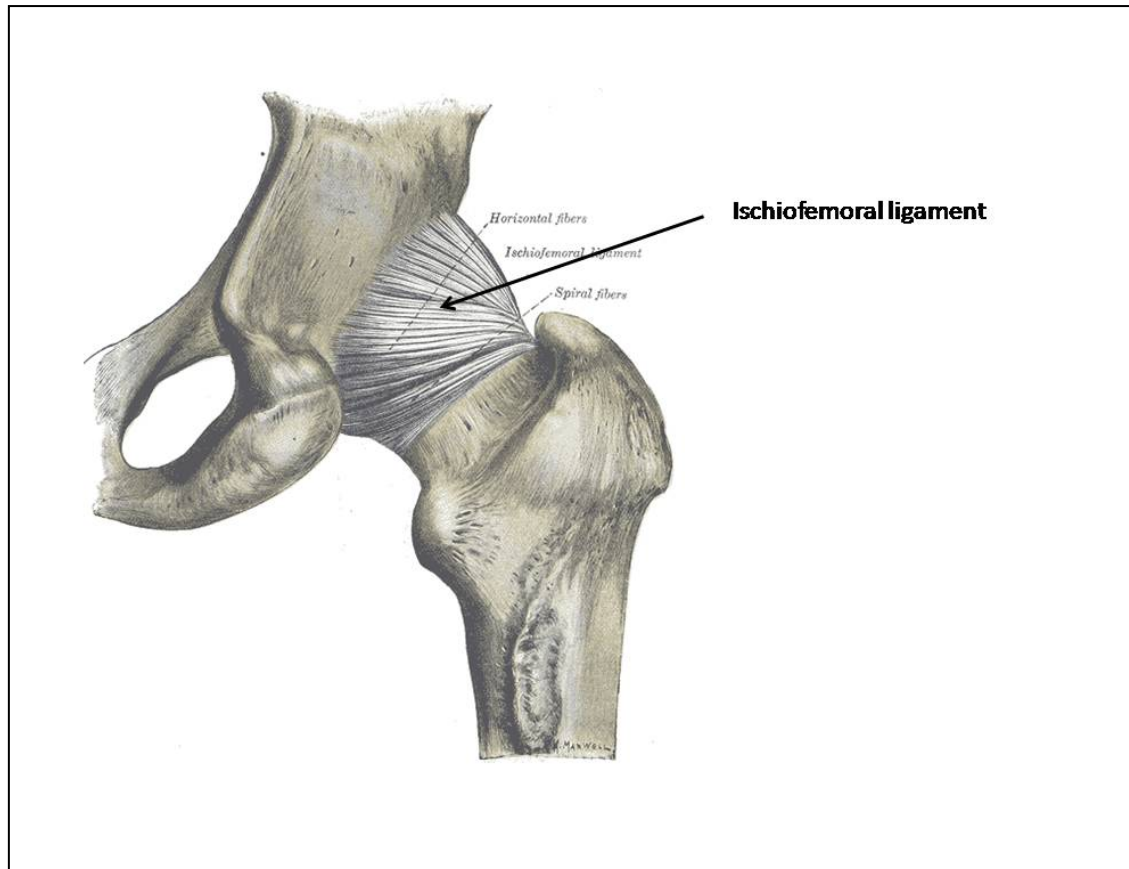


Figure 8.8. Hip (posterior view)

<http://upload.wikimedia.org/wikipedia/commons/3/33/Gray340.png>

## Knee

The knee is the most complex joint in the body. It is also the largest. It consists of the condyles of the femur articulating with the condyles of the tibia (fig. 8.9). The patella also articulates with the femur. The knee flexes and extends as well as rotates. It forms a locked position when extended. Some of the knee ligaments include:

The medial collateral ligament extends from the medial condyle of the femur to the medial condyle of the tibia.

The lateral collateral ligament extends from the lateral condyle of the femur to the head of the fibula.

The anterior cruciate ligament is inside the knee and extends from the posterior femur to the anterior tibia. The anterior cruciate (ACL) works to stop forward translation of the tibia on the femur.

The posterior cruciate ligament is also inside the knee and extends from the anterior femur to the posterior tibia. It works to stop backward translation of the tibia on the femur.

The arcuate popliteal ligament is on the posterior aspect of the knee. It is Y-shaped and extends from the lateral condyle of the femur to the fibular head.

The patellar ligament extends from the inferior aspect of the patella to the tibial tuberosity. It is an extension of the common quadriceps tendon.

The oblique popliteal is located in the posterior aspect of the knee and extends from the lateral condyle of the femur to the head of the fibula.

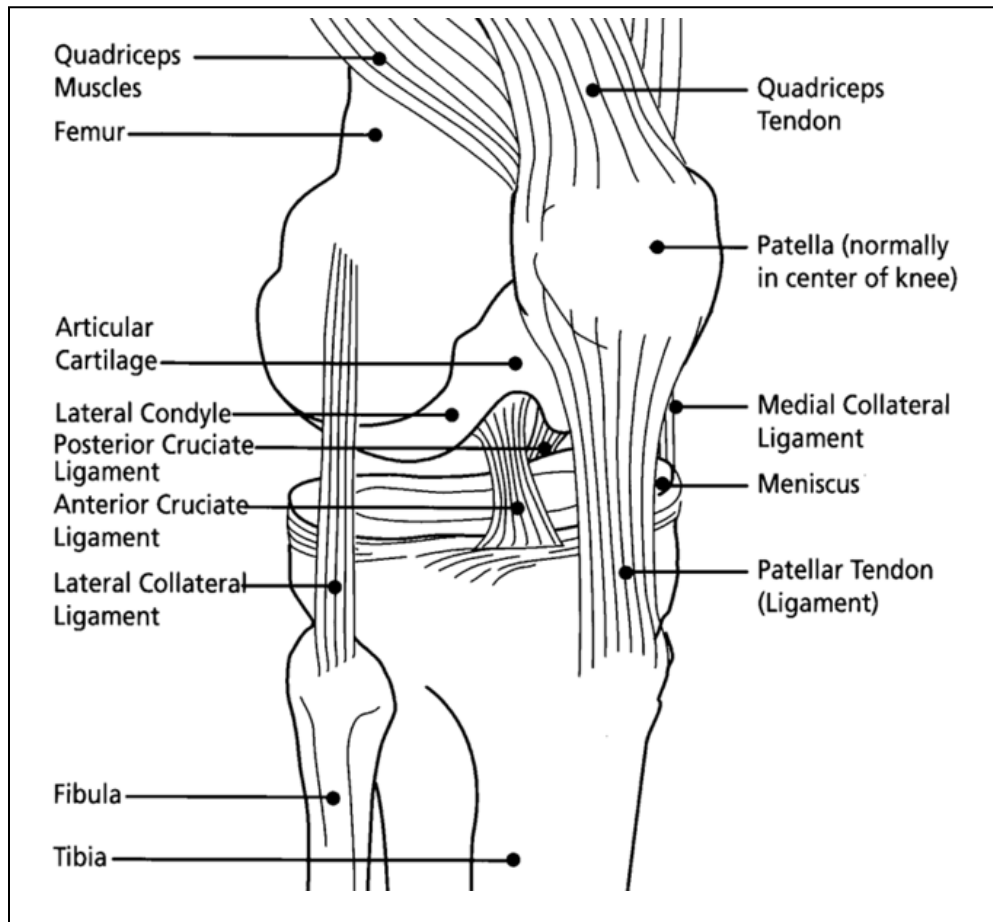


Figure 8.9. Knee ligaments.

[http://commons.wikimedia.org/wiki/Image:Knee\\_diagram.png](http://commons.wikimedia.org/wiki/Image:Knee_diagram.png)

### Knee Menisci

The knee also contains two fibrocartilage pads called menisci that help to cushion the joint. The medial and lateral menisci are located on top of the tibial condyles (fig. 8.10). Occasionally a meniscus can become injured and tear. The medial meniscus is more prone to tearing. In sports the “terrible triad” is known as tears to the medial collateral ligament, medial meniscus and anterior cruciate ligament.

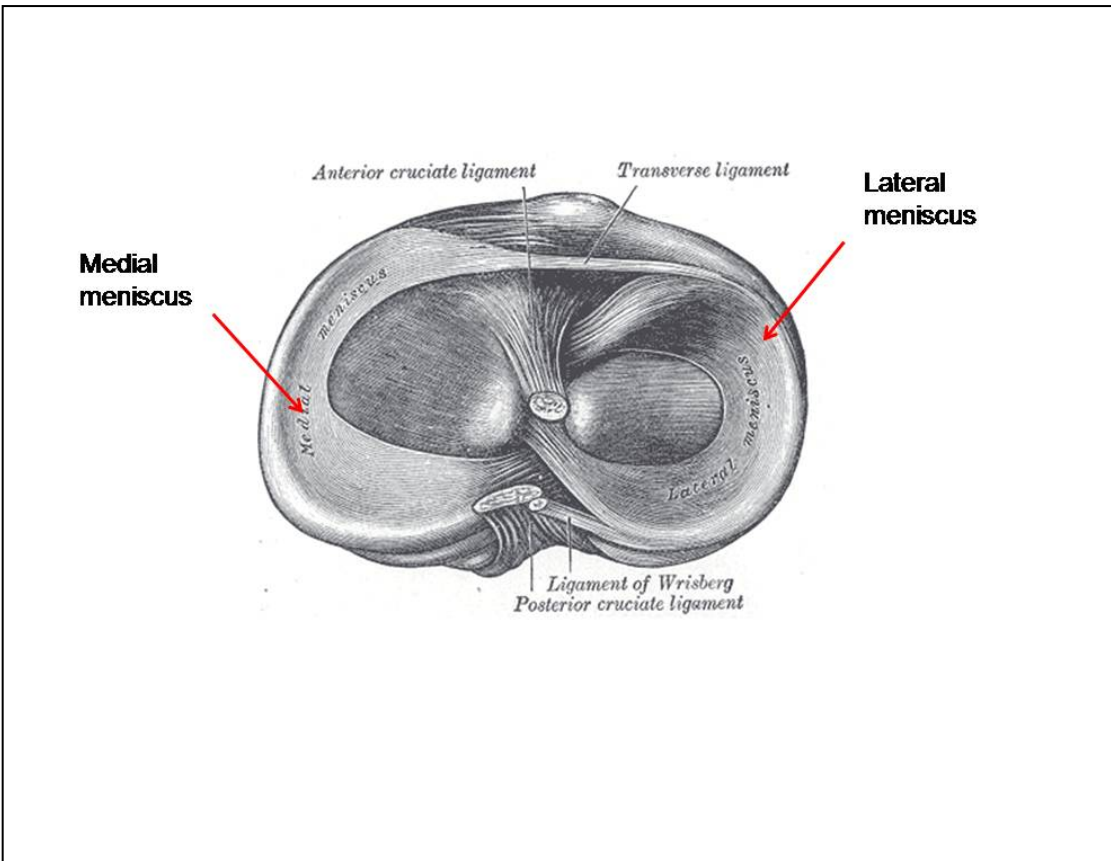


Figure 8.10. Medial and lateral menisci of the knee.

<http://commons.wikimedia.org/wiki/Image:Gray349.png>

## Joint Injuries

### Sprains and Strains

When the force exceeds what the tissue can handle the tissue becomes damaged. Common injuries include tears to the muscles (sprains) and tears to the ligaments (sprains).

Both sprains and strains are graded 1, 2, or 3. In a first degree injury 0 to 25% of the fibers are torn. These injuries typically take 1-2 weeks to heal.

A second degree injury is characterized by 25% to 50% of the fibers torn. These usually take from 2-4 weeks to heal.

Third degree injuries are the most severe with greater than 50% of the fibers torn. These injuries take at least 12 weeks to heal.

The body reacts to these injuries by producing inflammation. The joint will appear red and swollen and cause pain. Healing depends on the severity of the injury as well as the health of the subject. In severe sprains the joint will become unstable due to the torn ligaments. In some cases the joint must be stabilized with splints, supports or casts.

### **Osteoarthritis**

Osteoarthritis is characterized by the breakdown of cartilage. It is the most common form of arthritis and tends to affect people in middle age and beyond. Osteoarthritis commonly affects the hands, knees, hips and spine. In osteoarthritis the normal cartilage repair mechanisms malfunction and the cartilage begins to wear out. The joint space will become smaller and may progress to the point of bone rubbing on bone. The joint surfaces become roughened and cause pain and inflammation. There is no cure for osteoarthritis however severe cases are treated with joint replacement (fig. 8.11).

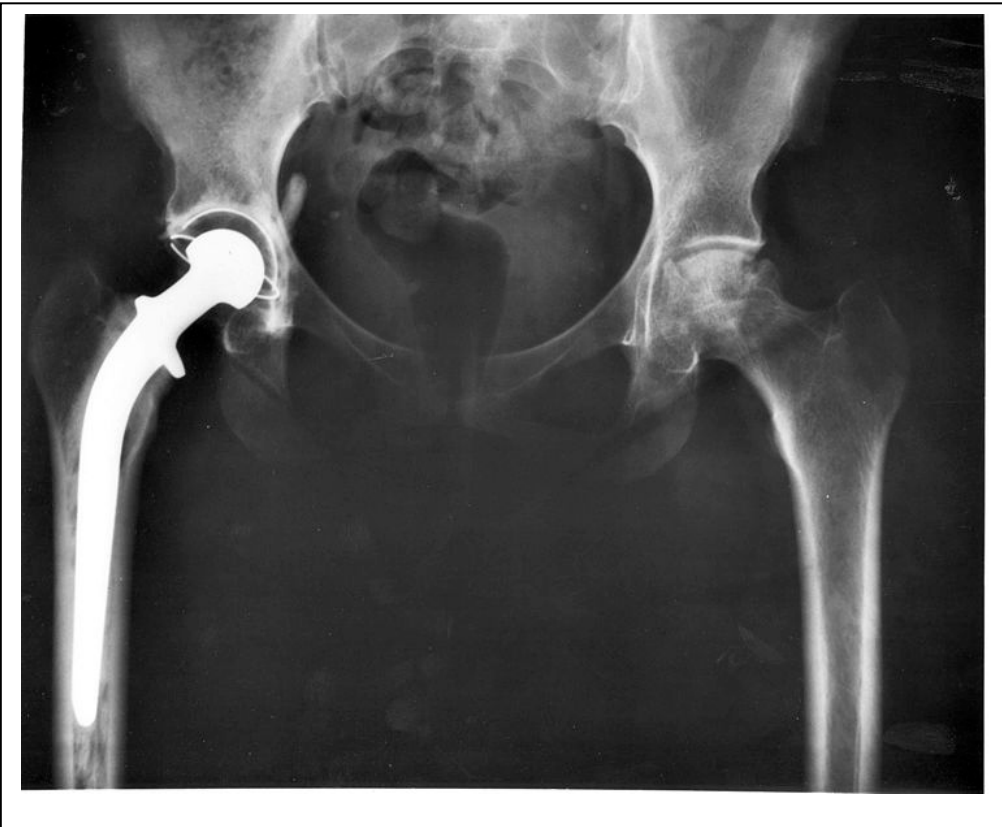

Figure 8.11. Osteoarthritis can result in a total hip replacement.

[http://commons.wikimedia.org/wiki/Image:746px-Hip\\_replacement\\_Image\\_3684-PH.jpg](http://commons.wikimedia.org/wiki/Image:746px-Hip_replacement_Image_3684-PH.jpg)



## Chapter 8 Review Questions

1. Which of the following is not a joint category:
  - a. Cartilaginous
  - b. Fibrous
  - c. Synovial
  - d. Bony
2. A tooth is an example of which of the following types of joints:
  - a. Cartilaginous
  - b. Gomphosis
  - c. Synchondrosis
  - d. Amphiarthrosis
3. An epiphyseal plate is an example of which type of joint:
  - a. Cartilaginous
  - b. Synchondrosis
  - c. Synovial
  - d. Fibrous
4. Most of the joints in the body are which type:
  - a. Fibrous
  - b. Cartilaginous
  - c. Synovial
  - d. Amphiarthroses
5. Which of the following is not a synovial joint:
  - a. Shoulder
  - b. Knee
  - c. Ankle
  - d. Intervertebral disc
6. The shoulder joint is which type:
  - a. Hinge
  - b. Modified hinge
  - c. Condylar
  - d. Ball and socket
7. The structures that hold joints together are called:
  - a. Loose connective tissue
  - b. Tendons
  - c. Fibers
  - d. Ligaments

8. Which joint motion is not performed at the hip:
  - a. Flexion
  - b. Extension
  - c. Abduction
  - d. Supination
  
9. Rotating the forearm so the palm of the hand points upward is called:
  - a. Internal rotation
  - b. Supination
  - c. Lateral flexion
  - d. Pronation
  
10. When standing on your toes your ankle joint performs this motion:
  - a. Extension
  - b. Dorsiflexion
  - c. Eversion
  - d. Plantar flexion

# Chapter 9

## Muscular System Anatomy

## **Muscular System Anatomy**

So far we've examined supportive structures of the body such as bones and cartilage as well as how these structures are connected by ligaments forming joints. Next we will study how these supportive structures move. Muscles move bones by contracting and relaxing. Muscles are also important in keeping us alive. The heart is largely composed of muscles and the blood vessels contain a layer of muscles. The diaphragm that keeps us breathing is also a muscle. There are muscles that move our eyes, tongue and food through our digestive tract.

We will begin our exploration of muscles by looking at some general information that applies to all muscles then we will examine skeletal muscles. In later chapters we will cover the muscles associated with various organs.

### **Muscle Tissue Types**

Muscle tissue largely consists of protein. Tiny protein filaments are bundled together in muscle. These filaments slide past each other causing muscles to contract. Muscles contract in response to a signal from the nervous system.

There are three basic types of muscle tissue. Skeletal muscle is characterized by densely packed protein filaments. Cardiac muscle is only found in the heart and also has densely packed protein filaments. Skeletal and cardiac muscle appears striated because of these filaments. Smooth muscle is found in the walls of the arteries and digestive system. It also consists of protein filaments but these are not as dense as skeletal or cardiac muscle. Smooth muscle does not appear striated because it is less organized.

### **General Muscle Terms**

When we describe the locations of skeletal muscles we use the terms origin and insertion. The origin of a muscle is the less mobile end of a joint. The insertion is the more mobile end of a joint. Think of how the body is structured. Joints need to be anchored on one end and more mobile on the other. Generally there is more mobility at the distal ends of joints.

Muscles connect to bones through dense connective tissue structures called tendons. Sometimes the tendons are broad and flattened. These are called aponeuroses. An example of an aponeurosis is a flat tendon on the lateral aspect of the thigh known as the iliotibial band.

Think of how muscles move joints. In order to move a joint in one direction you have to have at least one muscle on that side of the joint. To bring the joint back to its original position you need to have at least one muscle on the opposite side of the joint. When the first muscle contracts the other relaxes. The first muscle that produced the movement is called the agonist. The second muscle on the opposite side of the joint that opposes the movement is called the antagonist.

Let's look at an example to illustrate this. The elbow can move into flexion or extension. The elbow has a muscle on the anterior side called the biceps. It also has a muscle on the posterior side called the triceps. Elbow flexion (bending the elbow) is caused by contraction of the biceps muscle. In this case we can say that the biceps muscle is the agonist. Since the triceps muscle opposes this movement it is called the antagonist.

Now if we straighten the elbow the muscle that produces this movement is the triceps. So now the triceps is considered the agonist and since the biceps opposes this movement it is considered the antagonist.

So, when determining agonist and antagonist muscles we first have to consider the specific movement of the joint.

Muscles also tend to work together. However there is usually one muscle that is most responsible for the movement. This muscle is called the prime mover.

For example there are a number of abdominal muscles. The rectus abdominus (known as the six pack) runs right down the middle of the abdominals. The external obliques are located on the sides of the abdomen. During a situp (or crunch) the rectus abdominus muscle is most responsible for producing the movement. The rectus then is called the prime mover. The external obliques help out so they are known as synergists.

Some muscles are involved in holding bones in place. These muscles are called fixators or stabilizers. For example when you move your shoulder there are muscles attached to your scapula that hold it in place.

### Shapes of Muscles

The shape of a muscle helps to determine how forcefully it can contract. There are three basic muscle shapes (fig. 9.1).

In some muscles the fibers are arranged in a feather-like arrangement. These muscles are called pennate or bipennate. Some pennate muscles have all of their fibers arranged on one side. These are called unipennate. If the fibers are arranged at various places around a central tendon the muscle is called multipennate. In straight muscles fibers are arranged along or parallel to the long axis of the muscle. Circular muscles are called orbicular muscles.

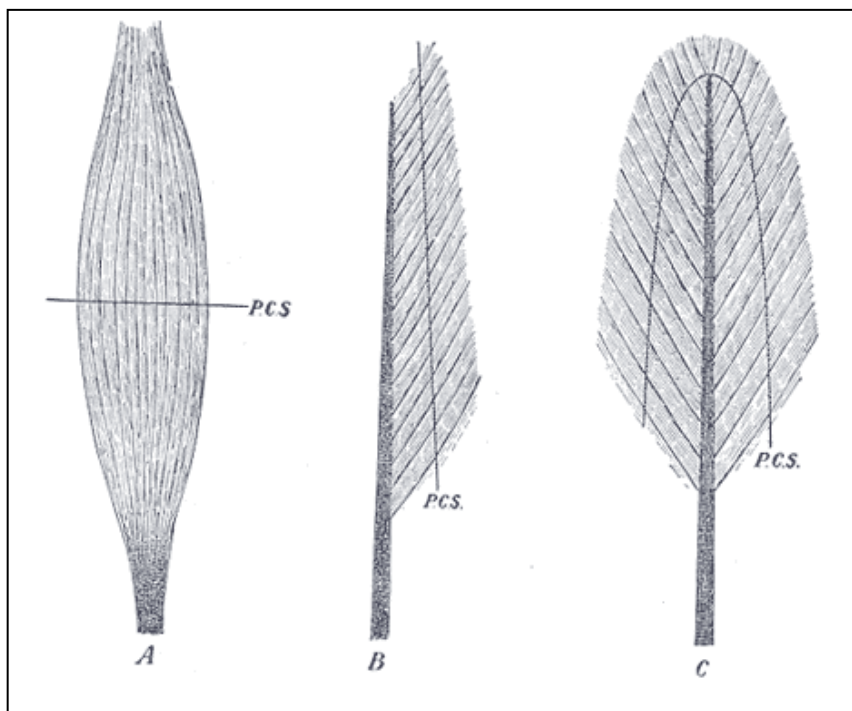


Figure 9.1. Muscle Shapes

- A. Straight
- B. Unipennate
- C. Bipennate

<http://commons.wikimedia.org/wiki/Image:Gray365.png>

Muscles run over bones that act as pulleys and levers. There are three types of levers that involve muscle contraction. Muscles exert a force called a pull on a weight (fig. 9.2).

In class 1 levers the fulcrum is located between the pull and the weight. In class 2 levers the weight is located between the fulcrum and the pull. In class 3 levers the pull is located between the fulcrum and the weight.

An example of a class 1 lever is the atlanto-occipital joint in the spine. The joint acts as a fulcrum while the posterior back muscles exert a pull on the skull. The joint lies between the muscles and the skull.

An example of a class 2 lever is the temporomandibular joint. When the mouth opens the weight or mandible is located between the fulcrum (TMJ) and the pull from muscles in the throat.

Most muscles are arranged in a class 3 lever system. Our example involving the biceps muscle is a class 3 lever.

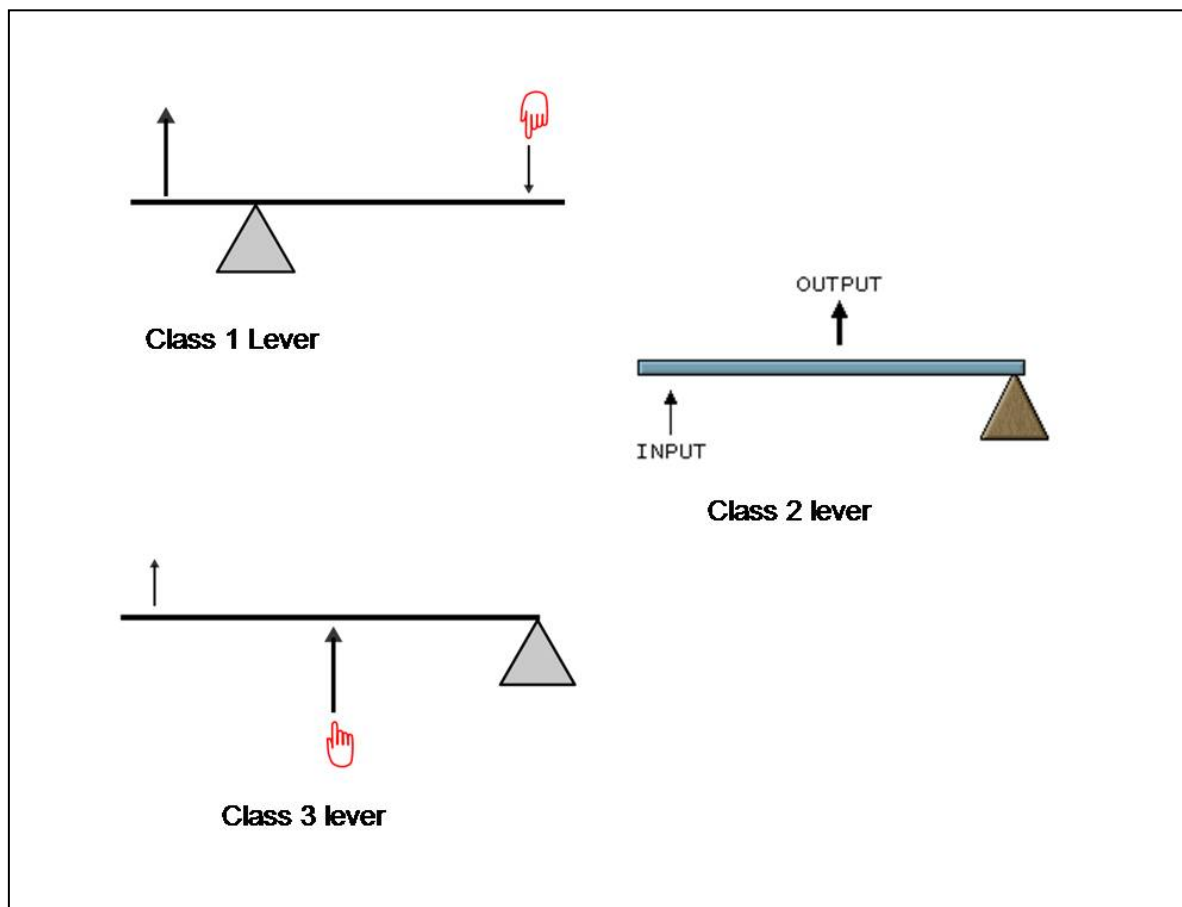


Figure 9.2. Three classes of levers.

<http://commons.wikimedia.org/wiki/Image:ThirdClassLever.svg>

## Muscle Contractions

There are three types of muscle contractions. All three are used in treating injuries in rehabilitation and physical therapy settings (fig. 9.3).

In isotonic contractions (iso = equal, tonic = tone) the force remains the same but the length of the muscle changes. An example of an isotonic contraction is the classic biceps curl with a barbell. The force exhibited by the barbell does not change. However the length of the bicep muscle can change by shortening during elbow flexion and lengthening during extension. Isotonic exercises are used in many gym settings in which participants use barbells and selectorized weight equipment.

In isometric contractions (iso = equal, metric = length) the force can change but the length of the muscle remains the same. In isometric contractions there is no movement of the joint since the muscle length does not change. An example of an isometric contraction would be to push against an object that cannot be moved such as a wall. The participant can push with a little amount of force or a lot of force (force can change) but there is no movement of the joint. Isometric exercises are used in rehabilitation settings for the strengthening of damaged muscle tissue. They are relatively safe because the damaged area can be omitted during the exercises. For example let's say an athlete injured her shoulder. Upon examination she was able to abduct her arm about 30 degrees before she experienced severe pain. Isometric exercises could then be used up to about 30 degrees of abduction. She would begin with using low amounts of force and then progress to higher amounts of force until the tissue healed.

In isokinetic contractions (iso = equal, kinetic = motion) both the force and length of the muscle can vary but the contraction happens at a fixed speed. Isokinetic exercises are primarily used in rehabilitation settings. Sophisticated machines are used to control the speed of the exercise while allowing varying resistance. However a simple treadmill is a good example of isokinetic exercise. The participant can exercise at a fixed speed with varying degrees of force provided by the different incline angles of the treadmill.

Many exercises consist of two phases. There is a phase in which the muscle shortens during contraction and a phase in which the muscle lengthens during relaxation. During the shortening phase the muscle performs a concentric contraction. Concentric contractions are characterized by muscles shortening against a load. During the lengthening phase the muscle performs an eccentric contraction. Eccentric contractions are characterized by muscles lengthening against a load.

Concentric contractions are primarily used to move a load while eccentric contractions are used to slow down or stop a load. An example would be the biceps curl exercise. During the flexion phase of the exercise the biceps muscle shortens against the load. The biceps is said to perform a concentric contraction. When the weight is lowered during elbow extension the biceps is lengthening against the load. Now the biceps is performing an eccentric contraction.

Muscles are generally not well suited for eccentric contractions and can be more prone to injury during eccentric contractions. An example of this is the tear of rotator cuff muscles in the shoulder during throwing a baseball. The rotator cuff muscles work to internally rotate the shoulder. The throwing motion however consists of external rotation. The rotator cuff muscles work to decelerate the arm at the end of the throw. The rotator cuff muscles do this by performing eccentric contractions. If the force is too great and exceeds the capabilities of the muscles then the muscles can become torn or strained.



Figure 9.3. Exercise machines called selectorized weight machines incorporate isotonic muscle contractions.

[http://commons.wikimedia.org/wiki/Image:Exercise\\_machines\\_\(284617740\).jpg](http://commons.wikimedia.org/wiki/Image:Exercise_machines_(284617740).jpg)



**Overview of the Muscular System (figs. 9.4, 9.5)**

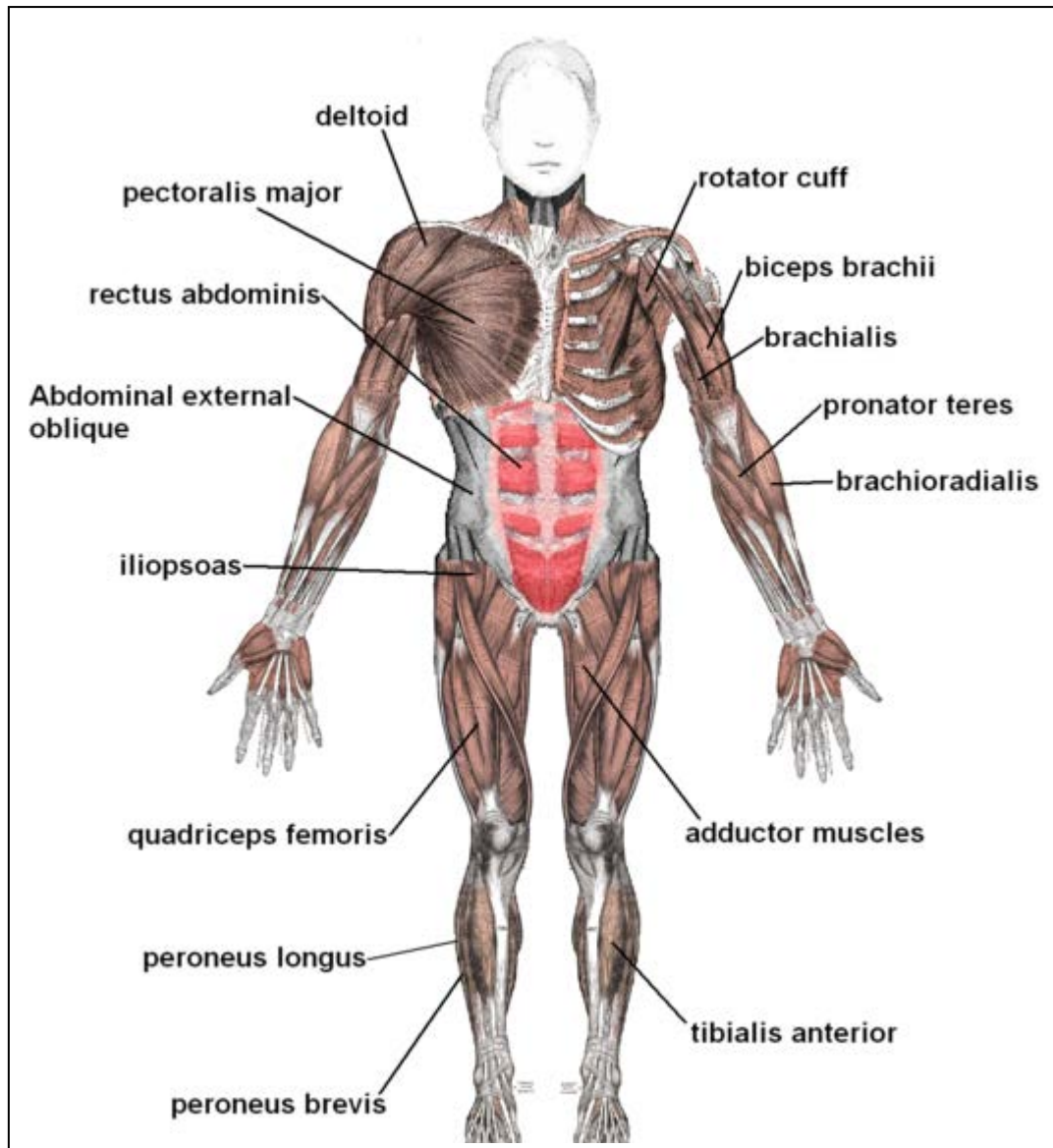


Figure 9.4. Overview of anterior muscles.

[http://commons.wikimedia.org/wiki/Image:Muscles\\_anterior\\_labeled.png](http://commons.wikimedia.org/wiki/Image:Muscles_anterior_labeled.png)

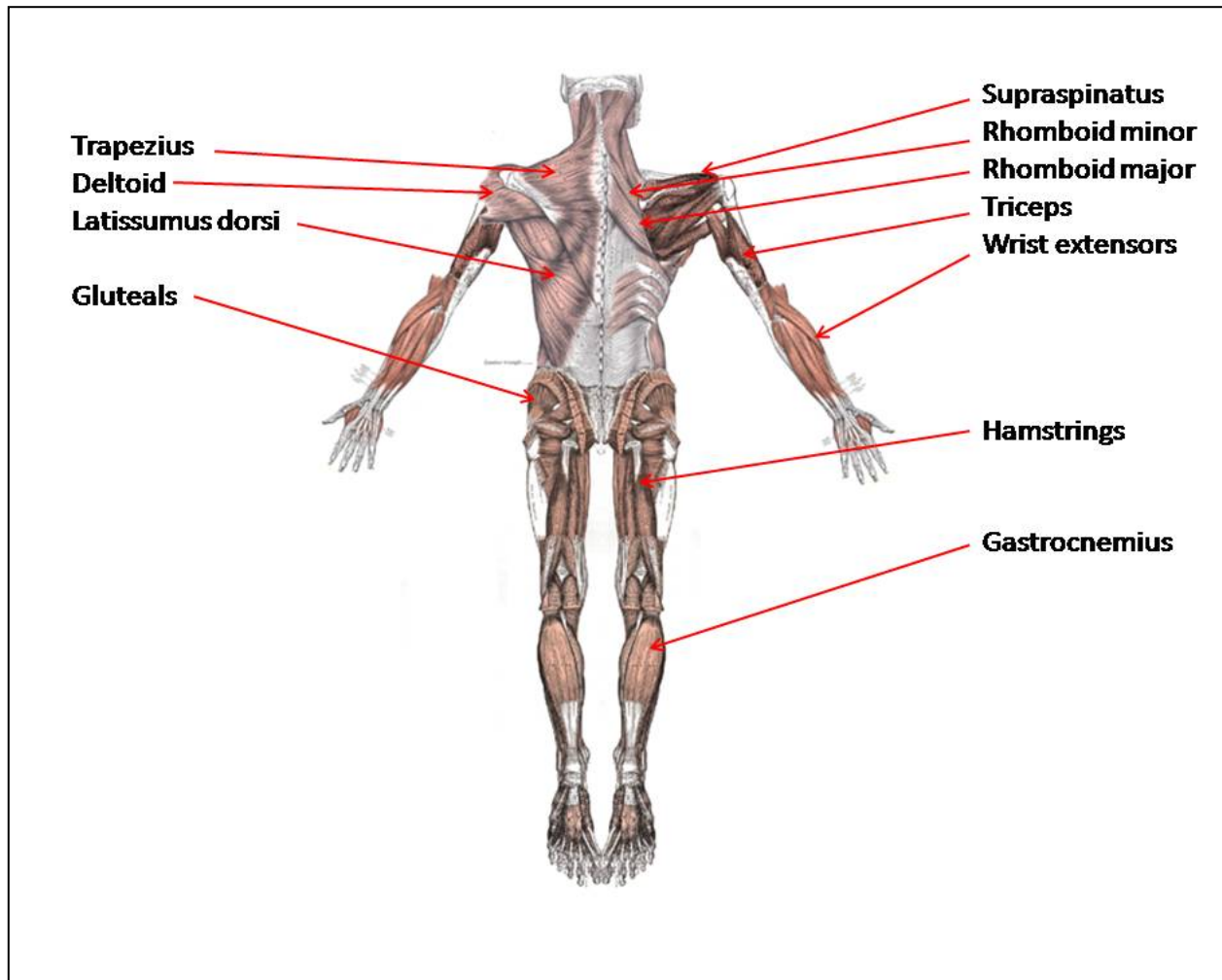


Figure 9.5. Overview of posterior muscles.

[http://commons.wikimedia.org/wiki/Image:Muscles\\_posterior.png](http://commons.wikimedia.org/wiki/Image:Muscles_posterior.png)

**Note:** There are many muscles in the human body. This work will only describe a sample of muscles.

## **Muscles of the Head and Neck**

The muscles of the head and neck move the face, larynx and tongue. A sample of muscles of facial expression follows.

### **Muscles of facial expression (figs. 9.6, 9.7)**

Located on top of the head is a broad flat tendon called the epicranial aponeurosis. There is one muscle with two parts attached to the anterior and posterior sections of this tendon. The muscle is called the occipitofrontalis. The anterior portion lifts the eyebrows. The posterior is a weak head extensor and can cause headaches.

There are two circular muscles called sphincters. The orbicularis oculi encircles the eye. It compresses the lacrimal gland and closes the eye. The orbicularis oris encircles the mouth. It causes the lips to pucker.

The buccinator is located in the cheek. It compresses the cheek against the teeth. The zygomaticus muscle has major and minor divisions and attaches to the orbicularis oris and zygomatic bone. It raises the lateral ends of the mouth when smiling. The platysma is a very thin and superficial muscle located under the chin. It causes the action of frowning when contracted.

### **Muscles of Mastication**

The muscles of mastication (chewing) include the masseter, temporalis, medial and lateral pterygoids (figs. 9.6, 9.9). The masseter muscles attaches to the mandible and allows for closing the jaw. The temporalis is located in the lateral skull and attaches to the temporal bone. The temporalis aids in closing the jaw. In fact you can feel your temporalis muscle contract when touching the sides of your head when clenching your jaw. The medial and lateral pterygoids are deep muscles in the jaw. These can elevate, depress, protract and cause lateral movement of the mandible. These muscles are often involved in temporomandibular joint (TMJ) disorder.

### **Head and Vertebral Column**

There are a number of muscles that attach to the vertebral column and move the head (figs. 9.8, 9.10). The sternocleidomastoid (SCM) attaches to the mastoid process of the temporal bone as well as the clavical and sternum. It produces contralateral rotation when one muscle contracts and neck flexion when both muscles contract.

The splenius capitis is located in the posterior portion of the neck. It helps bring head into an upright position (head extension). It also causes ipsilateral rotation and lateral flexion when one muscle contracts.

The semispinalis capitis also produces head extension as well as lateral flexion and rotation. It connects to the occipital bone and vertebra of the cervical and thoracic spines.

The erector spinae group of muscles consists of several muscles running up and down the spine. These consist of the spinalis, longissimus, iliocostalis and semispinalis muscles. They are located in the cervical, thoracic and lumbar spines. The names of these muscles give you a good clue as to their

locations. For example the spinalis muscles are located medially attaching directly to the spinal segments. The iliocostalis muscles attach to the ribs (iliocostalis thoracis) (costal = ribs). The longissimus muscles have long fibers and the semispinalis muscles run just lateral to the spinal segments.

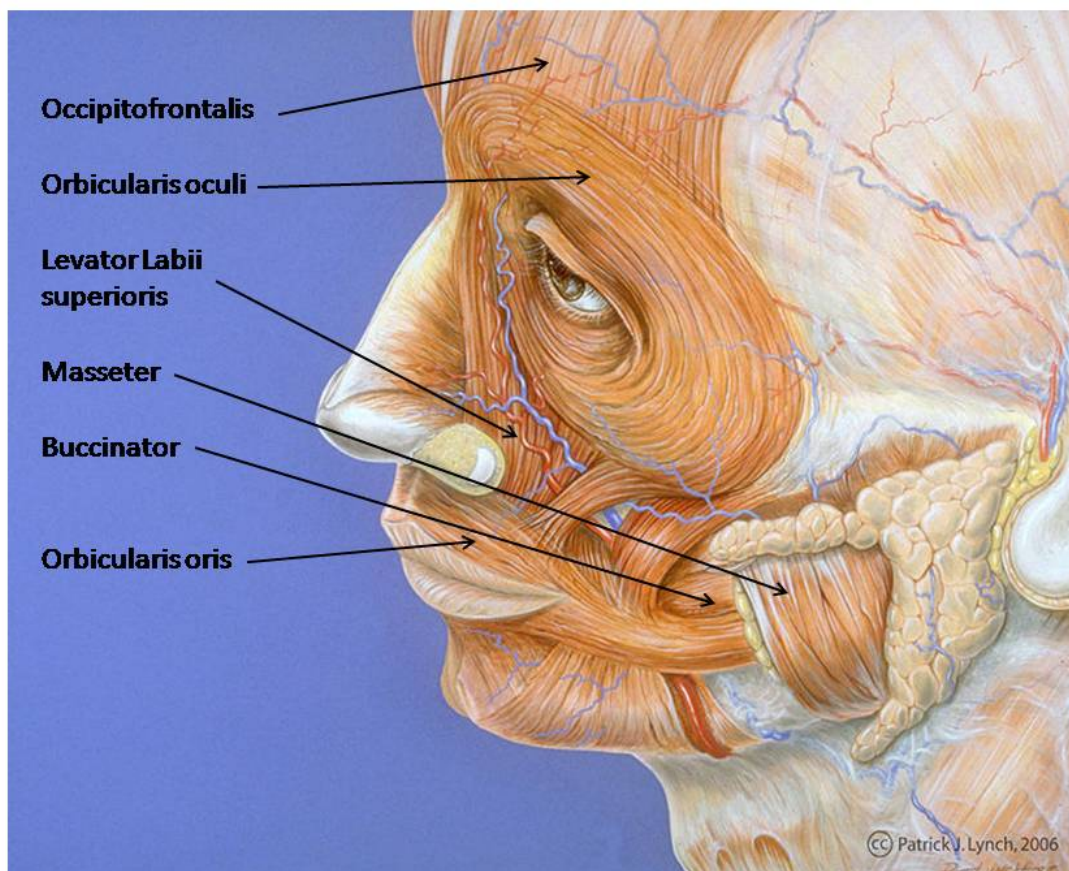


Figure 9.6. Muscles of facial expression.

[http://commons.wikimedia.org/wiki/Image:Face\\_anatomy\\_superficial.jpg](http://commons.wikimedia.org/wiki/Image:Face_anatomy_superficial.jpg)

Author: Patrick J. Lynch

Labelled by Bruce Forciea

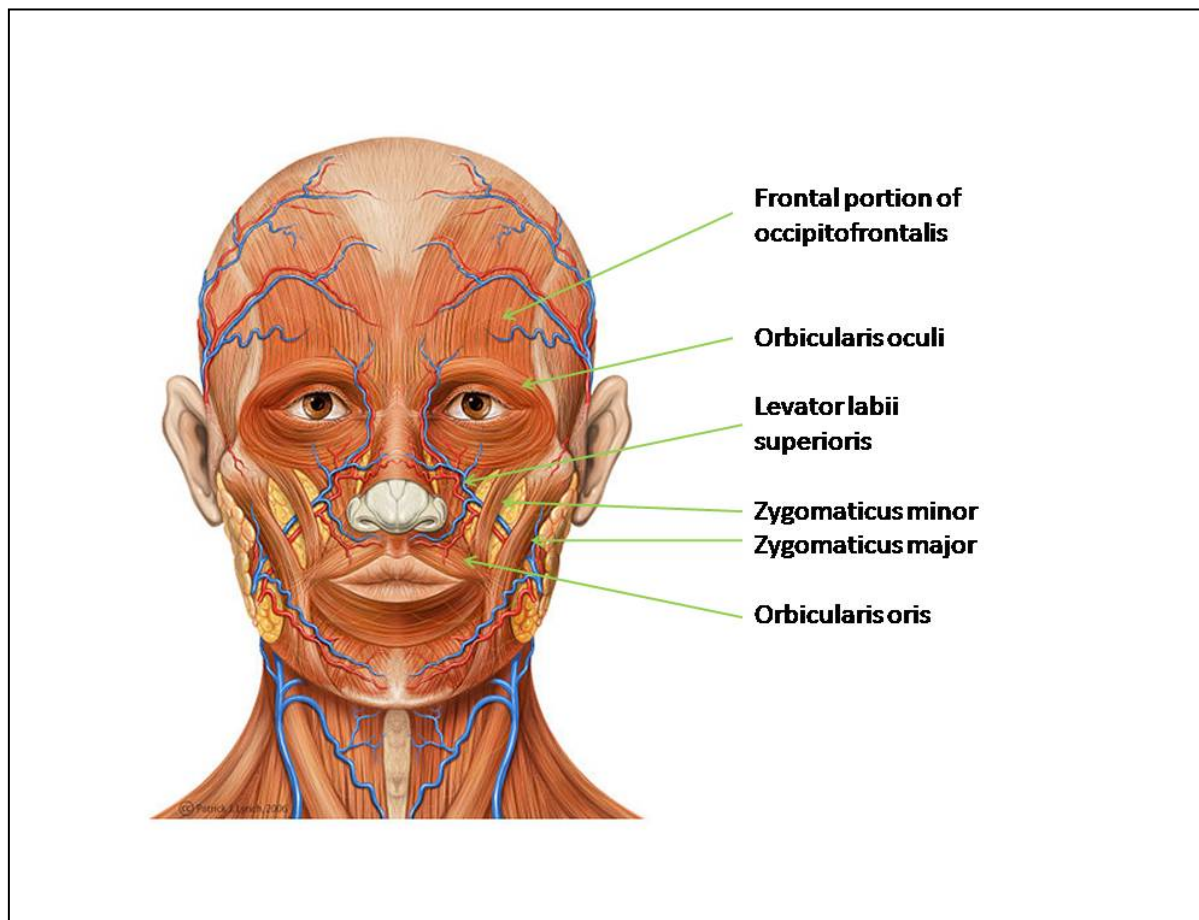


Figure 9.7. Facial muscles.

[http://commons.wikimedia.org/wiki/Image:Head\\_ap\\_anatomy.jpg](http://commons.wikimedia.org/wiki/Image:Head_ap_anatomy.jpg)

Author: Patrick J. Lynch

Labelled by Bruce Forciea



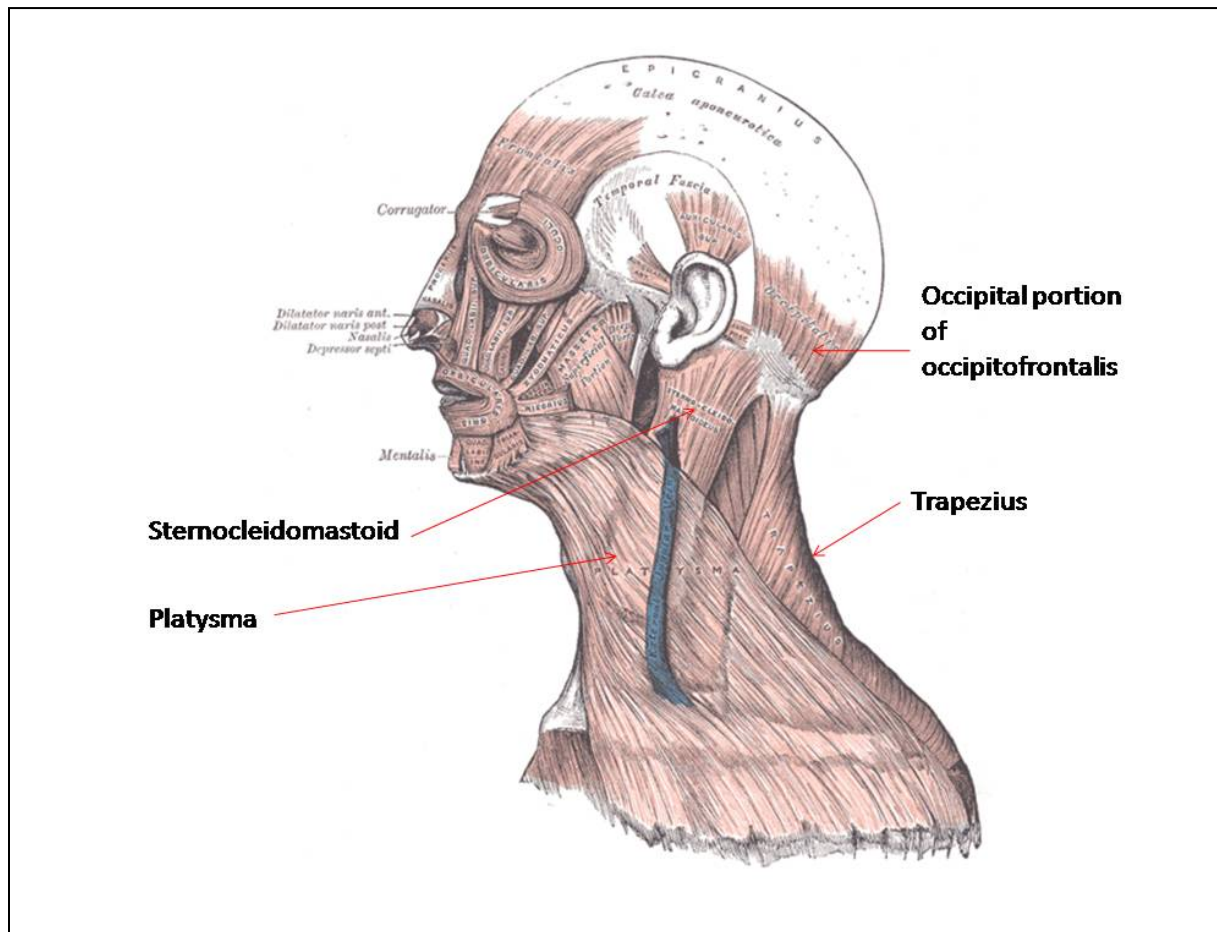


Figure 9.8. Lateral view of neck muscles.

<http://commons.wikimedia.org/wiki/Image:Gray378.png>

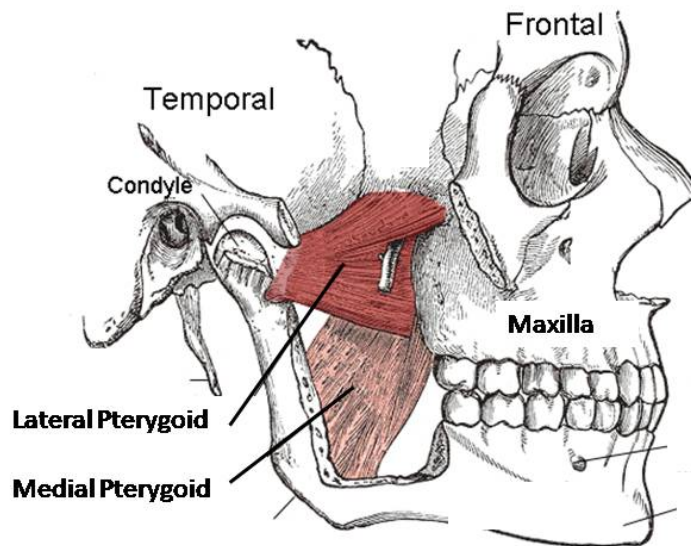


Figure 9.9. Medial and lateral pterygoids.

[http://commons.wikimedia.org/wiki/Image:Muscle\\_pterygoidien\\_lateral.png](http://commons.wikimedia.org/wiki/Image:Muscle_pterygoidien_lateral.png)

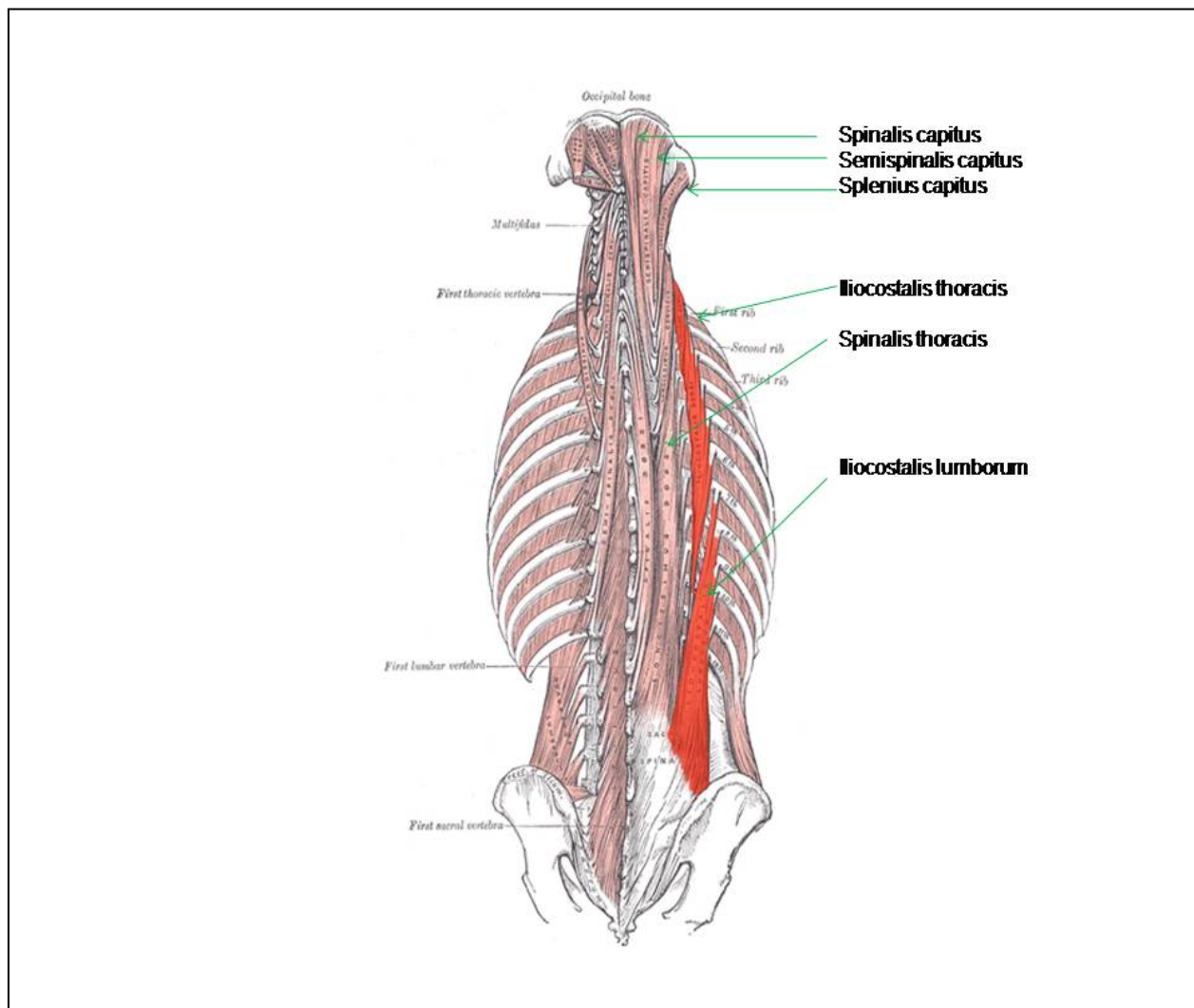


Figure 9.10. Erector spinae muscles

<http://commons.wikimedia.org/wiki/Image:Iliostalis.png>



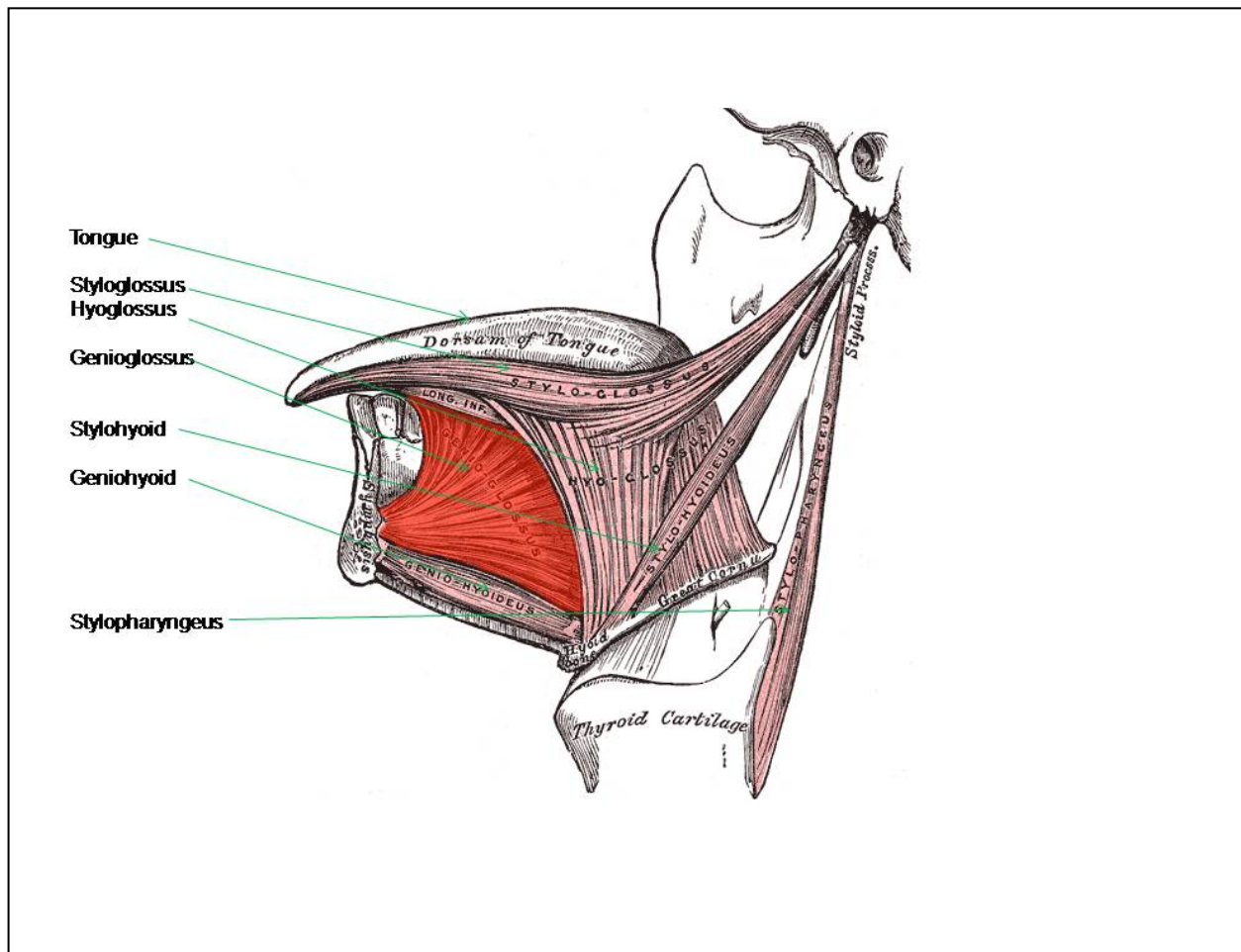


Figure 9.11. Muscles of the tongue.

<http://commons.wikimedia.org/wiki/Image:Genioglossus.png>

## Muscles of the Tongue

The muscles of the tongue include the genioglossus that pulls the tongue to one side when one side contracts and protrudes the tongue when both sides contract (fig. 9.11). The hyoglossus depresses the tongue while the styloglossus pulls the tongue superior and posterior.

## **Shoulder/Pectoral Girdle**

The shoulder is anchored by the pectoral girdle. The arm and scapula work together to allow the arm to move. The muscles of the pectoral girdle work to move the scapula in concert with the arm (figs. 9.12, 9.13, 9.14).

The trapezius has upper, middle and lower divisions. The trapezius attaches to the thoracic and cervical vertebrae and extends upward to the occipital bone and laterally to the scapula. The upper portion raises the shoulder and scapula. The middle portion pulls the scapula toward the vertebral column and the lower portion pulls the scapula downward. The divisions of the scapula are evidenced by the direction of the fibers.

There are two rhomboid muscles that pull the scapula upward and medially. The larger rhomboid major is the inferior muscle of the two. The smaller rhomboid minor is superior to the major.

The levator scapula is a long thin muscle that attaches to the superior border of the scapula and extends upward to the occipital bone. As its name implies, the levator scapula works to elevate the scapula.

The serratus anterior attaches to the anterior surface of the scapula and extends to the ribs. The serratus anterior works to hold or stabilize the scapula against the ribcage.

The pectoralis minor muscle is located deep to the major. It attaches to the upper ribs and extends to the coracoid process of the scapula. It works to pull the scapula anterior and inferior. The pectoralis minor is also an accessory muscle of inspiration.

The deltoid is located on top of the humeral head. It attaches to the spine of the scapula and acromion process and extends to the deltoid tuberosity of the humerus. The deltoid works to flex, abduct and extend the arm.

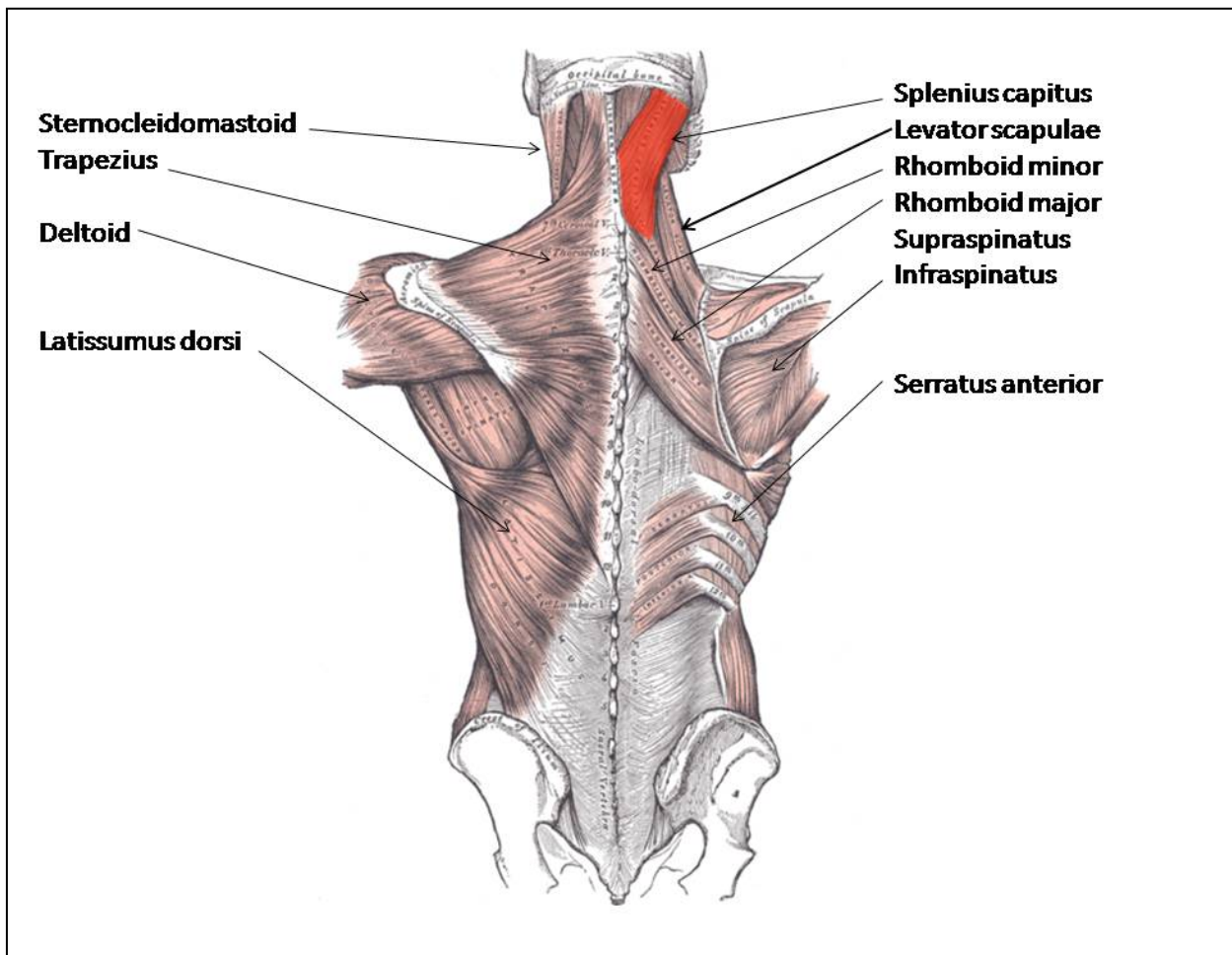


Figure 9.12. Posterior muscles of the thorax.

<http://commons.wikimedia.org/wiki/Image:Splenius.png>

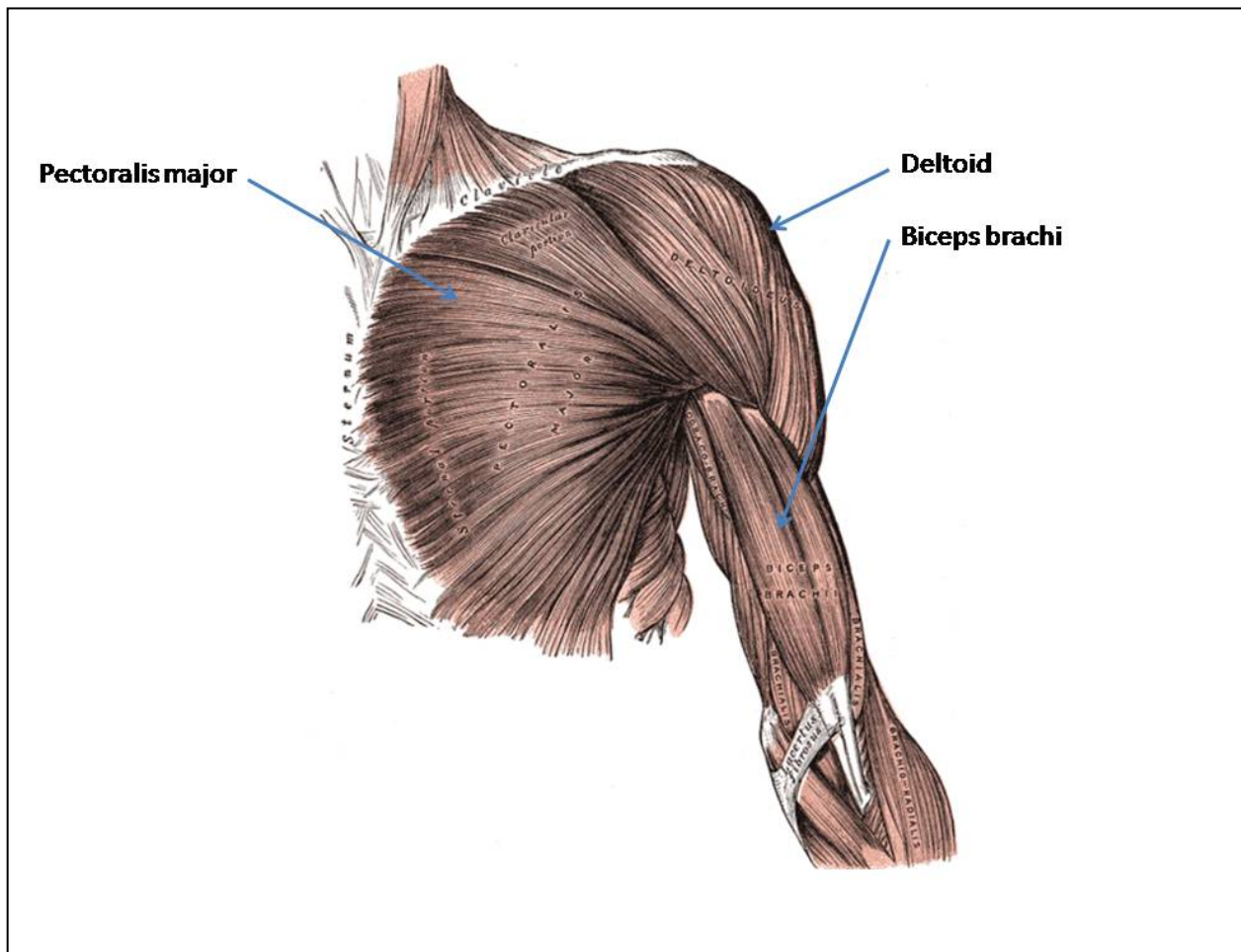


Figure 9.13. Muscles of anterior thorax and arm.

[http://commons.wikimedia.org/wiki/Image:Arm\\_muscles\\_front\\_superficial.png](http://commons.wikimedia.org/wiki/Image:Arm_muscles_front_superficial.png)

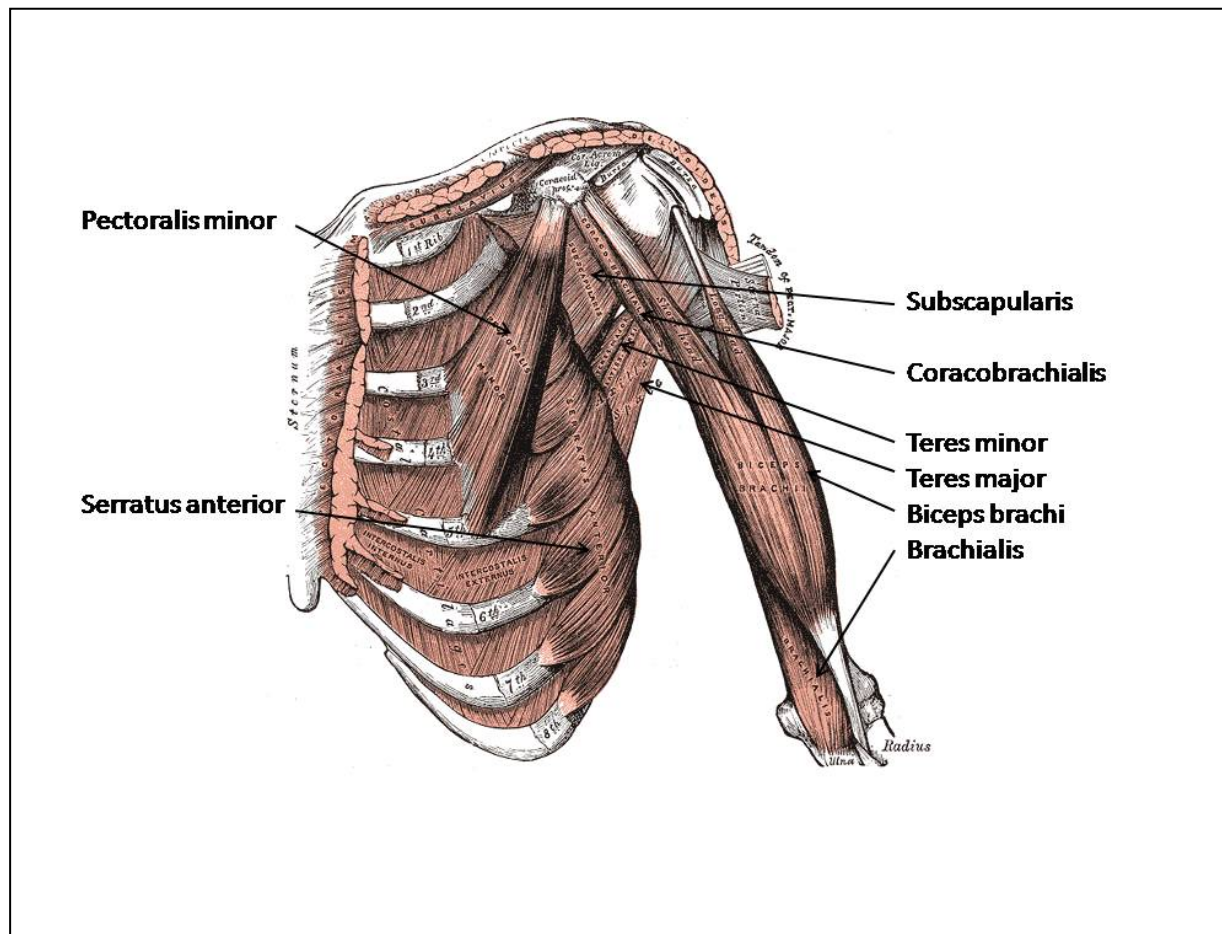


Figure 9.14. Deep muscles of the thorax and shoulder.

[http://commons.wikimedia.org/wiki/Image:Arm\\_muscles\\_front\\_deep.png](http://commons.wikimedia.org/wiki/Image:Arm_muscles_front_deep.png)

### Muscles that Move the Arm

The arm can move into flexion, extension, adduction and abduction, and internal and external rotation as well as combinations of these movements.

The flexors include the coracobrachialis, pectoralis major, and deltoid.

The coracobrachialis attaches to the coracoid process of scapula and extends to the shaft of the humerus. It runs deep to the deltoid and biceps muscles. The pectoralis major attaches to the clavicle, sternum and costal cartilages of ribs and extends to the intertubercular groove of the humerus.

The arm extensors include the teres major and latissimus dorsi. The teres major attaches to the lateral border of the scapula and extends to the intertubercular groove of the humerus. The

latissimus dorsi attaches to the lower thoracic area to the iliac crest and extends to the intertubercular groove of humerus.

The arm abductors include the supraspinatus and deltoid. The supraspinatus attaches to the posterior surface of scapula above spine of scapula and extends to the greater tubercle of the humerus. The deltoid was mentioned earlier.

### **The Rotator Cuff**

The rotator cuff consists of four muscles three of which are external rotators and one being an internal rotator. The first letter of each muscle can be taken to spell the acronym SITS which stands for supraspinatus, infraspinatus, teres minor and subscapularis (fig. 9.15).

The supraspinatus attaches to the superior portion of the scapula at the suprascapular fossa and extend to the greater tubercle of the humerus. It abducts as well as externally rotates the arm.

The infraspinatus attaches to the posterior portion of the scapula at the subscapular fossa and extends to the greater tubercle of the humerus. It externally rotates the arm.

The subscapularis attaches on the anterior surface of the scapula and extends to the lesser tubercle of the humerus. It is the only rotator cuff muscle that provides internal rotation.

The teres minor attaches to the lateral border of the scapula and extends to the greater tubercle of the humerus. It externally rotates the arm.

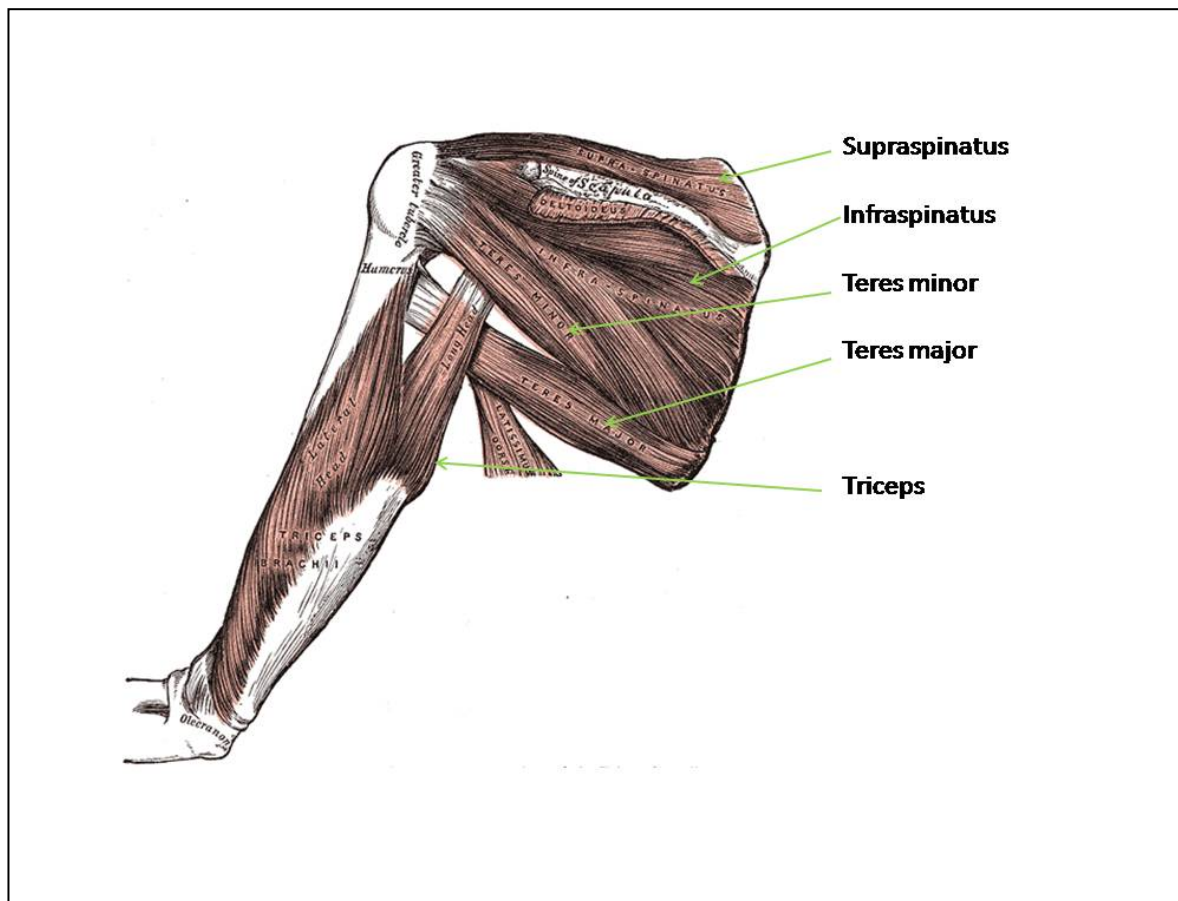


Figure 9.15. Posterior muscles of the arm.

[http://commons.wikimedia.org/wiki/Image:Arm\\_muscles\\_back.png](http://commons.wikimedia.org/wiki/Image:Arm_muscles_back.png)

## Muscles That Move the Lower Arm

The forearm or antebrachium can move into flexion, extension and rotation.

The flexors include the biceps brachii, brachioradialis and brachialis.

The biceps brachii attaches to the scapula and extends to the radial tuberosity. This muscle has two heads at its proximal region. It works to flex the elbow.

The brachialis lies deep to the biceps brachii and extends to the ulna.

The brachioradialis attaches to the humerus and extends to the radius.

There is only one muscle that functions in elbow extension. This muscle is the triceps brachii.



This muscle is a large three headed muscle that attaches to the scapula and humerus and extends to the ulna. It is the only muscle on the posterior side of the arm.

The rotators of the forearm include the supinator, pronator teres and pronator quadratus.

The supinator attaches to the ulna and extends to the lateral aspect of the humerus. It works to move the wrist into supination.

The pronator teres attaches to the humerus and ulna and extends to the radius. It works to move the wrist into pronation.

The pronator quadratus attaches to the distal ulna and radius. It also works to pronate the wrist.

### **Hand/Wrist Muscles**

The flexors of the hand and wrist include the flexor carpi radialis longus, flexor carpi ulnaris, palmaris longus, flexor digitorum superficialis and flexor digitorum profundus.

The wrist area contains a large number of tendons from muscles that move the wrist and hand. There is a large flat tendon on the palmar aspect of the wrist known as the flexor retinaculum. A few muscles travel through this structure on their way to the metacarpals and phalanges of the hand (fig. 9.16).

The flexor carpi radialis longus attaches to the medial epicondyle and extends to the metacarpals. The flexor carpi ulnaris also attaches to the medial epicondyle and extends to the metacarpals. The palmaris longus muscle lies between the flexor carpi radialis longus and flexor carpi ulnaris and extends to the flexor retinaculum of the wrist.

The group of wrist flexors attach on the medial epicondyle. Sometimes tendonitis can develop in this area known as golfer's elbow.

The flexor digitorum superficialis lies deep to the flexor carpi radialis longus and flexor carpi ulnaris and extends to the proximal phalanges. The flexor digitorum profundus lies deep to the flexor digitorum superficialis and extends to the distal phalanges (fig. 9.17).

Some muscles extend through the flexor retinaculum and are prone to carpal tunnel syndrome which is an inflammation of the median nerve. These muscles include:

- Flexor carpi radialis longus and brevis
- Flexor digitorum profundus
- Flexor digitorum superficialis



The wrist and hand extensors are located on the posterior portion of the forearm (figs. 9.18, 9.19). The wrist extensors have a common origin on the lateral epicondyle. Wrist extensor tendonitis known as tennis elbow or lateral epicondylitis can develop here.

The wrist and hand extensors include the extensor carpi radialis longus, extensor carpi radialis brevis, extensor carpi ulnaris, extensor digitorum and extensor digiti minimi.

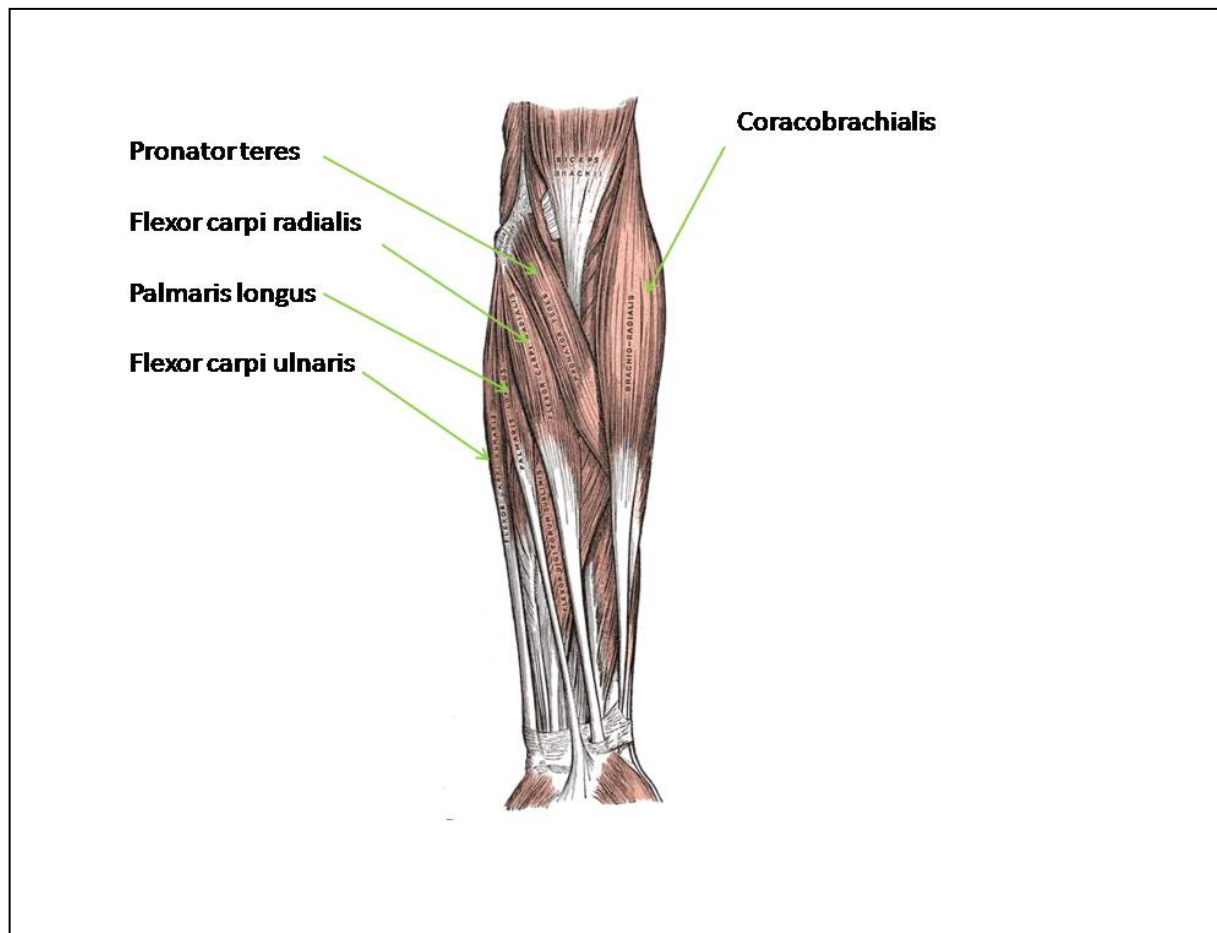


Figure 9.16. Anterior forearm muscles.

[http://commons.wikimedia.org/wiki/Image:Forearm\\_muscles\\_front\\_superficial.png](http://commons.wikimedia.org/wiki/Image:Forearm_muscles_front_superficial.png)

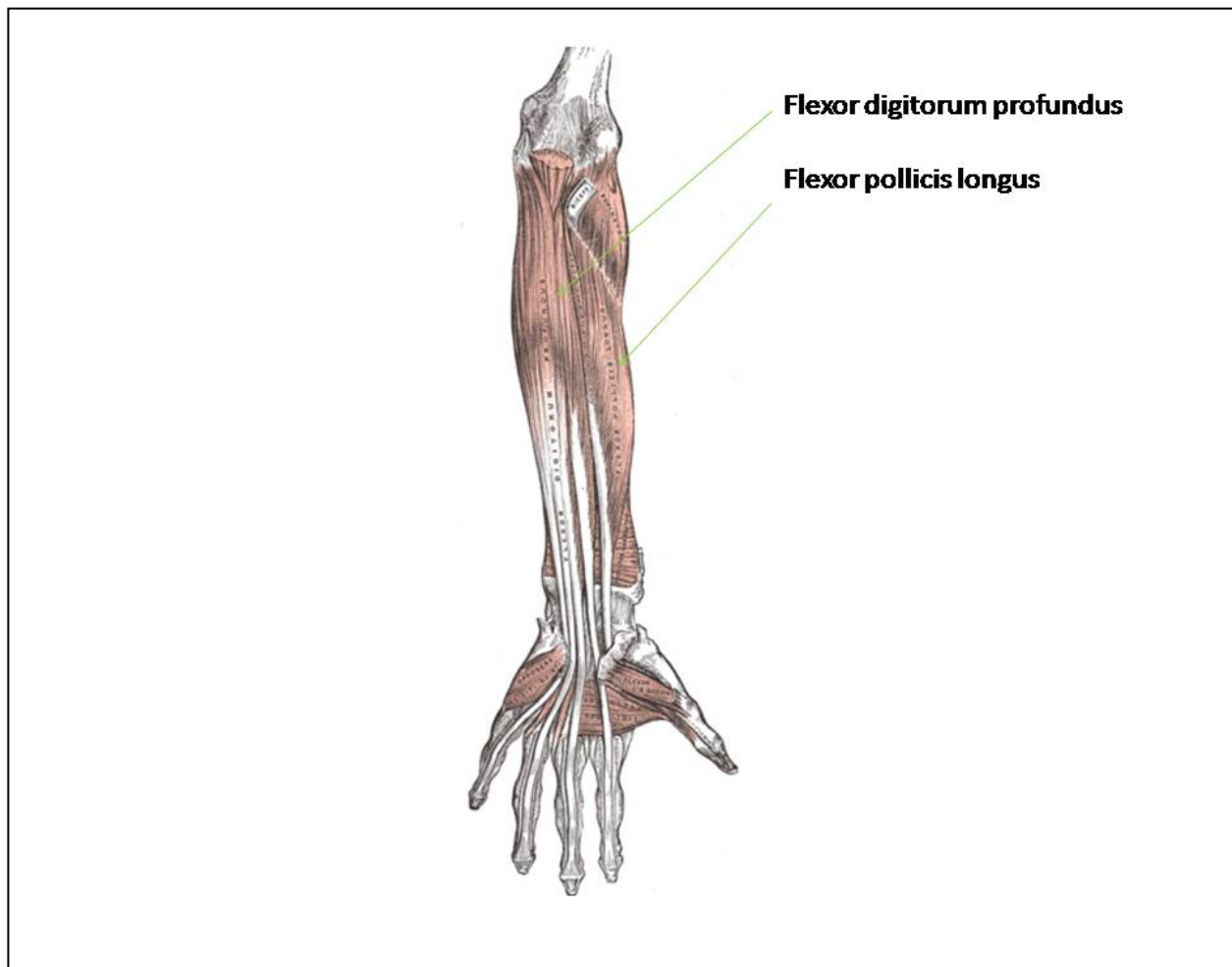


Figure 9.17. Deep anterior forearm muscles.

[http://commons.wikimedia.org/wiki/Image:Forearm\\_muscles\\_front\\_deep.png](http://commons.wikimedia.org/wiki/Image:Forearm_muscles_front_deep.png)

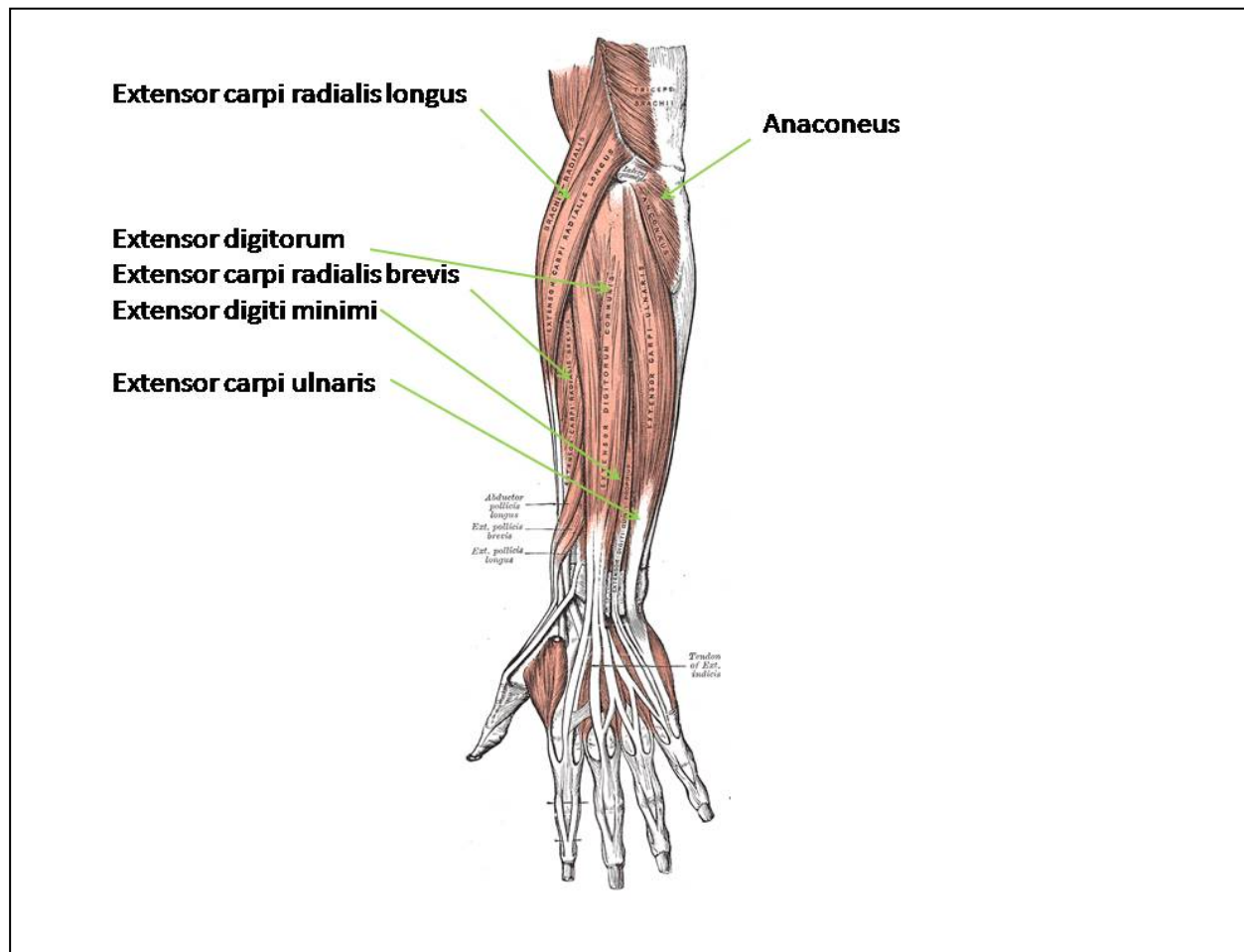


Figure 9.18. Posterior forearm muscles.

[http://upload.wikimedia.org/wikipedia/commons/3/3e/Forearm\\_muscles\\_back\\_superficial.png](http://upload.wikimedia.org/wikipedia/commons/3/3e/Forearm_muscles_back_superficial.png)

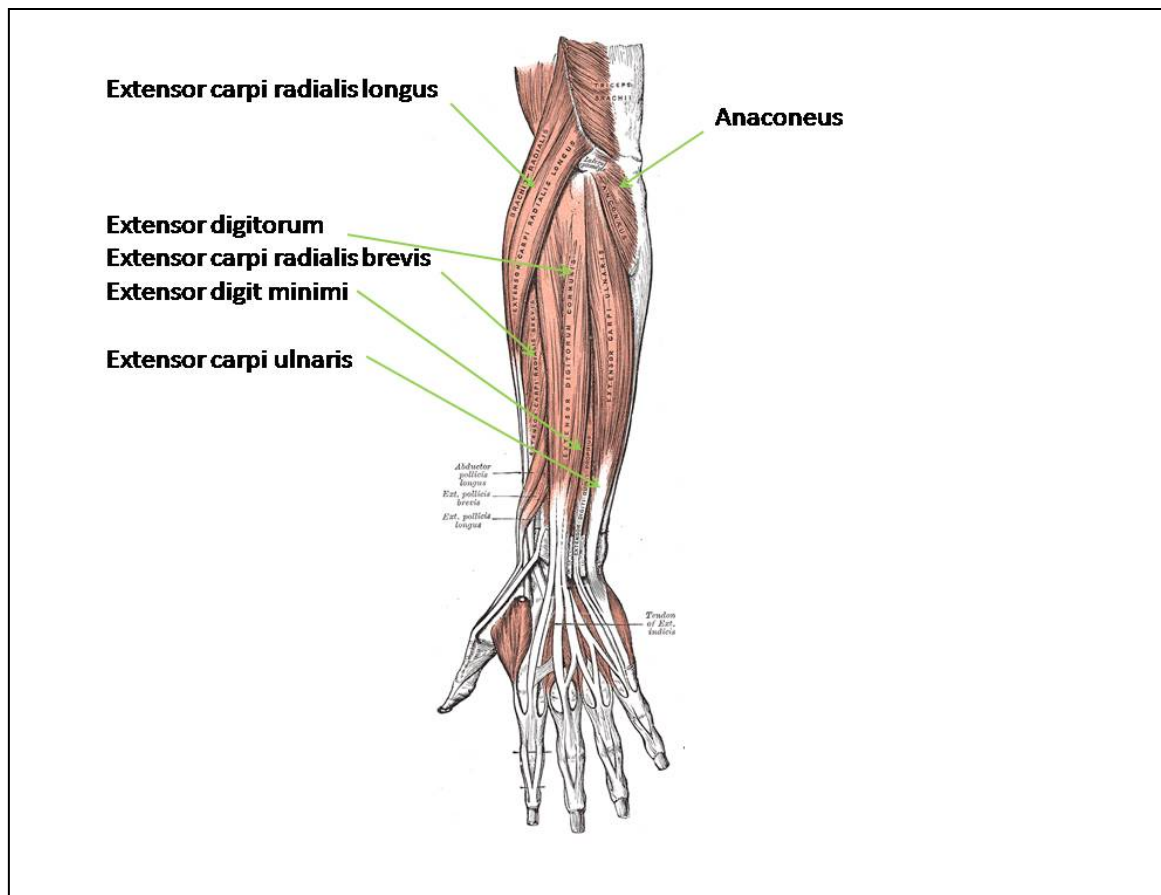


Figure 9.19. Posterior forearm muscles deep.

[http://commons.wikimedia.org/wiki/Image:Forearm\\_muscles\\_back\\_deep.png](http://commons.wikimedia.org/wiki/Image:Forearm_muscles_back_deep.png)

## **Abdominal Wall Muscles**

The contents of the abdomen are protected by a band of muscles (figs. 9.20, 9.21, 9.22). There are three layers of abdominal muscles that include four muscles. The first layer consist of the rectus abdominus which lies in the anterior and medial aspect of the abdomen and the external oblique which is located on the sides of the abdomen. The second layer consists of the internal obliques which lie deep to the external obliques and the third layer consists of the transverse abdominus.

Some of the abdominal muscles attach to a broad dense band of connective tissue known as the linea alba. The linea alba extends from the xiphoid process to the symphysis pubis.

The abdominal muscles aid in trunk flexion. They also compress the contents of the abdominal cavity, increase intra-abdominal pressure and help to transmit force through trunk to protect the spine and contents of the abdominal cavity.

The transverse abdominus muscle is becoming a very important muscle in rehabilitation of low back injuries. This muscle acts as a natural back brace since its fibers run in a transverse plane.

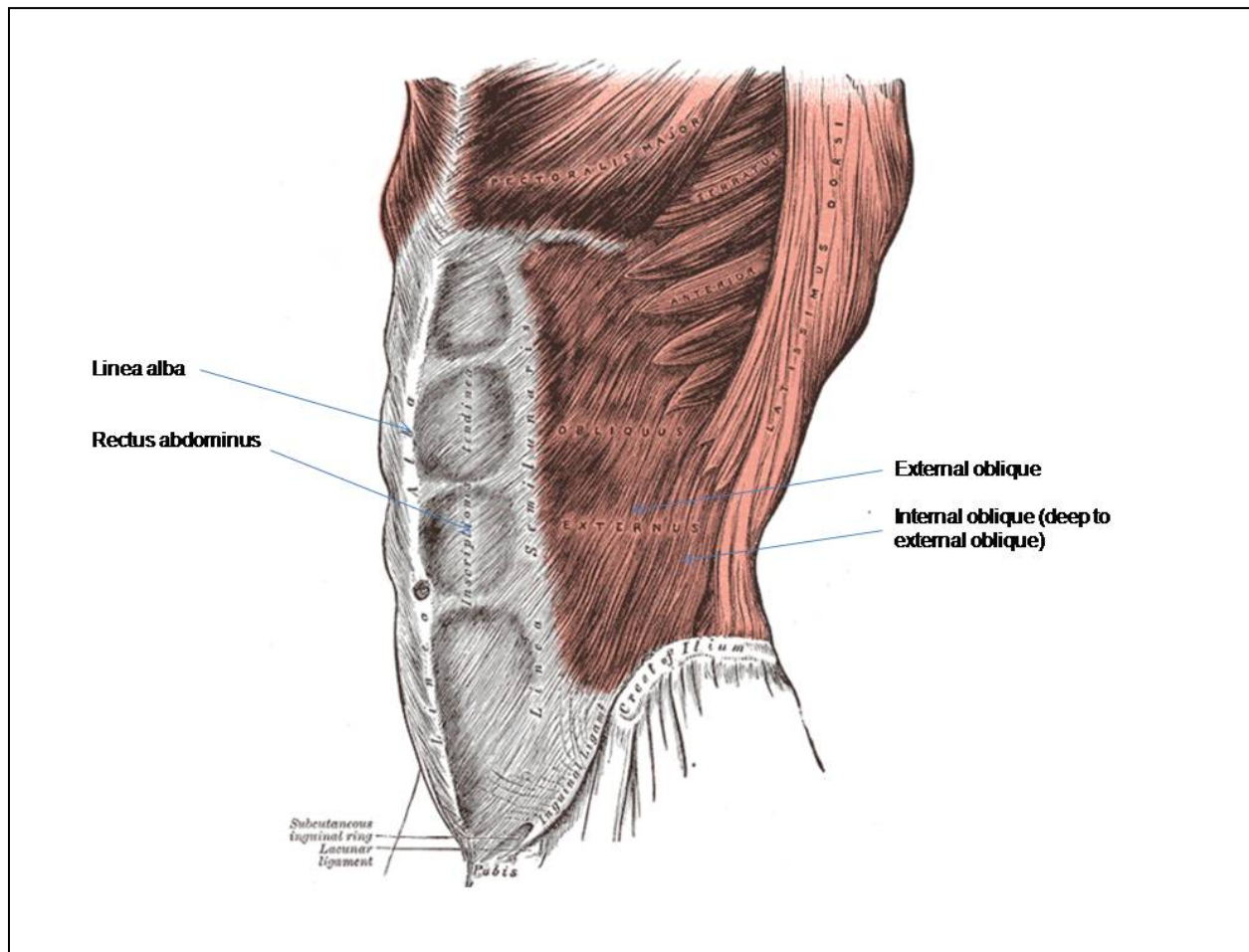


Figure 9.20. Superficial Abdominal Muscles

[http://commons.wikimedia.org/wiki/Image:Grays\\_Anatomy\\_image392.png](http://commons.wikimedia.org/wiki/Image:Grays_Anatomy_image392.png)

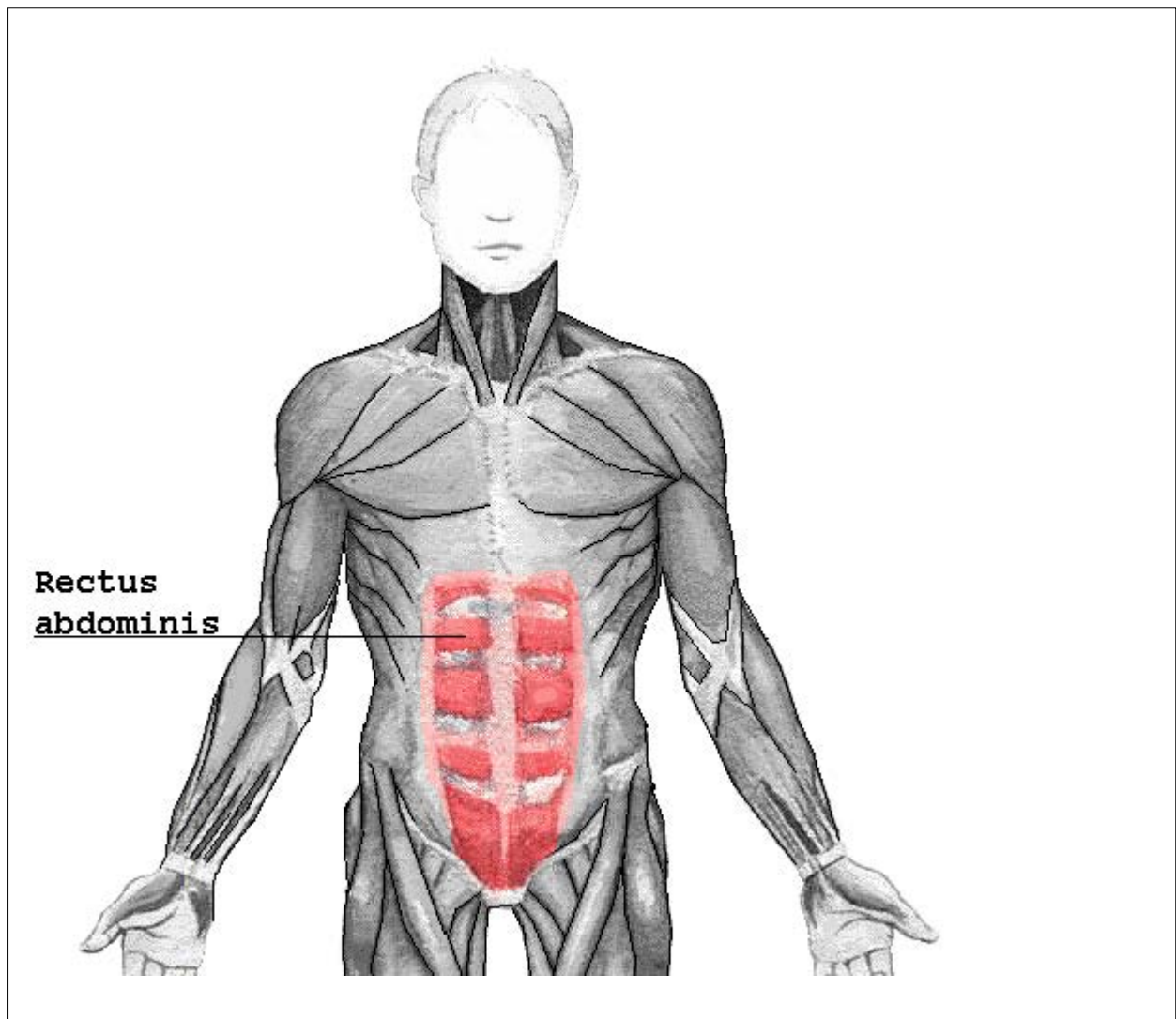


Figure 9.21. Rectus Abdominus

[http://commons.wikimedia.org/wiki/Image:Rectus\\_abdominis.png](http://commons.wikimedia.org/wiki/Image:Rectus_abdominis.png)

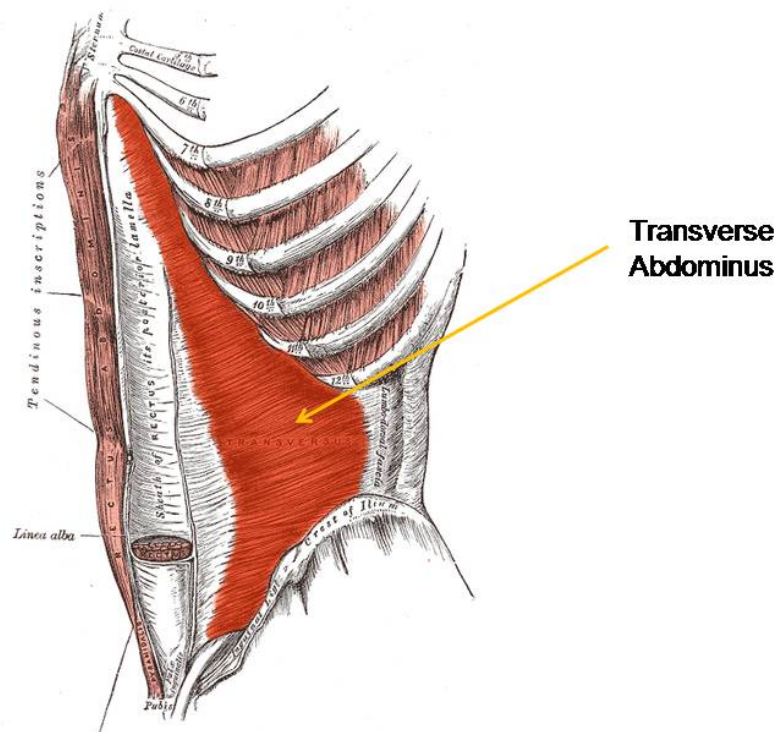


Figure 9.22. The transverse abdominus is the deepest abdominal muscle.

[http://commons.wikimedia.org/wiki/Image:Transversus\\_abdominis.png](http://commons.wikimedia.org/wiki/Image:Transversus_abdominis.png)



## Muscles of the Pelvic Outlet

The pelvic diaphragm which consists of a layer of muscles (figs. 9.23, 9.24) forms the floor of the pelvic cavity. The urogenital diaphragm lies superficial to this layer and forms a second layer. The pelvic diaphragm consists of the levator ani and coccygeus muscles. The urogenital diaphragm consists of the superficial transverse perinea, bulbospongiosus (males only), ischiocavernosus and the sphincter urethrae.

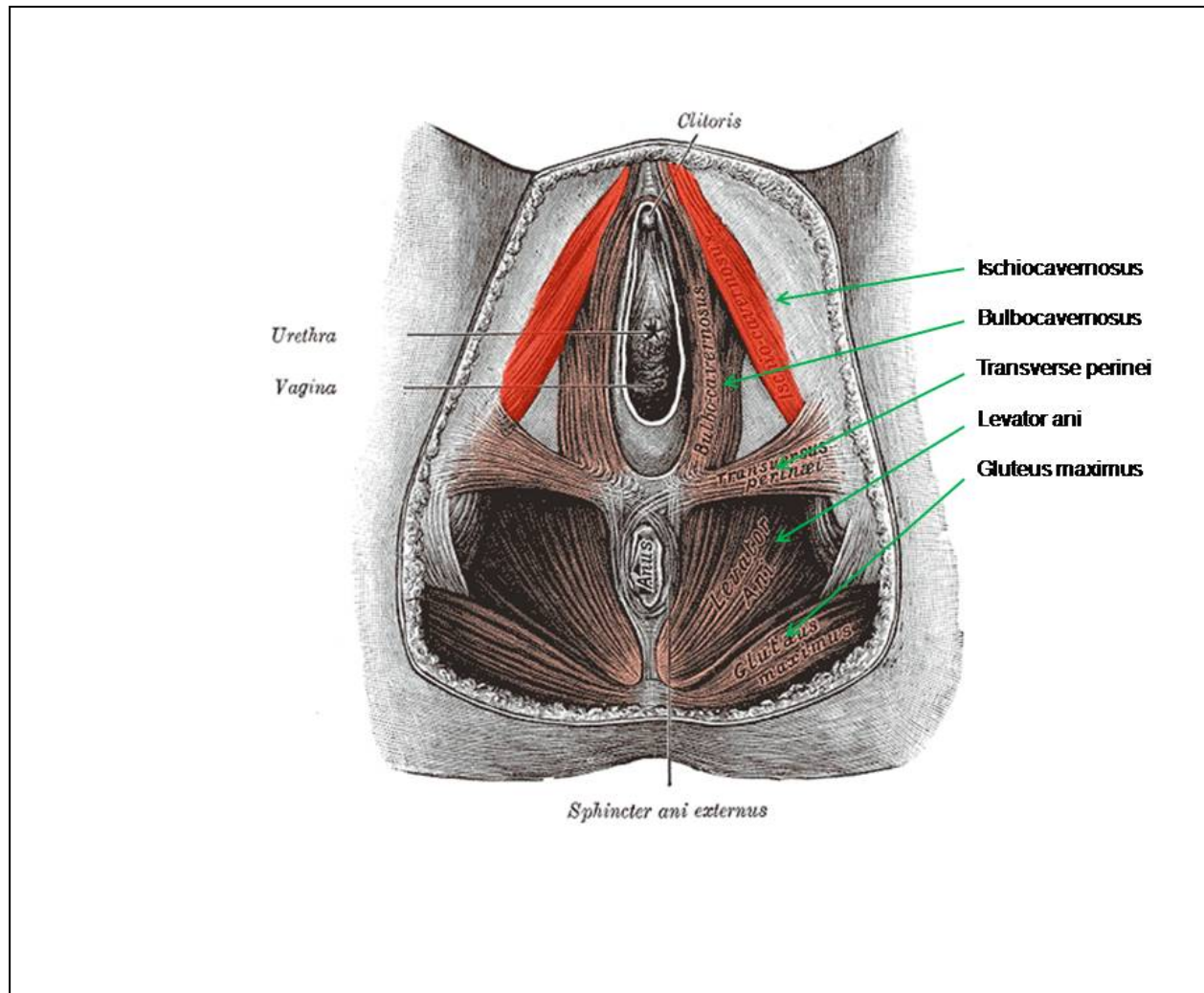


Figure 9.23. Muscles of the pelvic outlet (female).

<http://commons.wikimedia.org/wiki/Image:Ischiocavernosus-female.png>

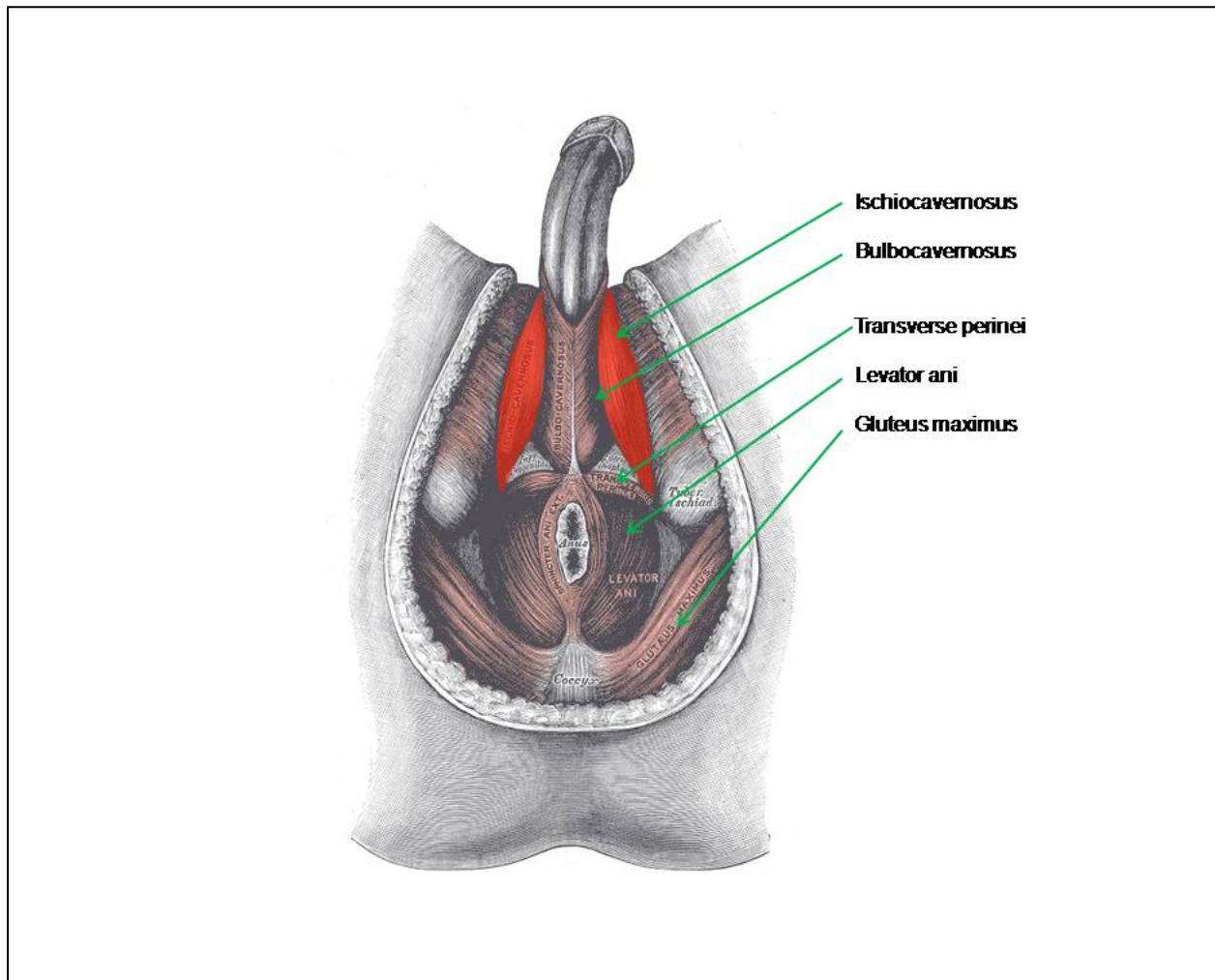


Figure 9.24. Pelvic outlet muscles (male).

<http://commons.wikimedia.org/wiki/Image:Ischiocavernosus-male.png>

## Pelvic and Upper Thigh Muscles

Muscles that move the thigh connect to the pelvis and femur. The anterior muscles include the iliopsoas and iliacus and the posterior muscles include the gluteus maximus, gluteus medius, gluteus minimus, and tensor fascia latae.

The psoas portion of the iliopsoas muscle actually has two divisions. The psoas major attaches to the lower lumbar vertebra and extends to the lesser trochanter of the femur. The psoas minor muscle is smaller and inserts on the pubic bone. The Iliacus muscle attaches to the ilium and also extends to the lesser trochanter of the femur. Since both the psoas major and iliacus share a common insertion point they are often referred to as the iliopsoas. The iliopsoas works to flex the hip.

The gluteus maximus is one of the strongest and largest muscles of the body (fig. 9.25). It attaches to the iliac crest, sacrum, coccyx and the aponeurosis of the sacrospinalis. It extends to the linea aspera of the femur and the iliotibial band. It works to produce hip extension.

The gluteus medius lies deep to the gluteus maximus. It attaches to the ilium and extends to the greater trochanter of the femur. It works to produce hip abduction and extension.

The gluteus minimus is lies deep to the gluteus medius. It is the smallest gluteal muscle.

The tensor fascia latae is located on the lateral aspect of the thigh. It attaches to the iliac crest and extends to a band of dense connective tissue called the iliotibial tract or band. The iliotibial band extends down the lateral aspect of the femur to the tibia. It is a flat tendon or aponeurosis. Tendonitis can develop in this tendon in a condition known as iliotibial band syndrome.

Deep muscles in the posterior pelvic area include the piriformis, obturator internus, obturator externus, superior and inferior gemellus and quadratus femoris muscles. All of these muscles work to externally rotate and abduct the hip (figs. 9.26, 9.27).

Muscles on the proximal medial aspect of the thigh include the adductor longus, adductor brevis, adductor magnus, pectineus and gracilis. These muscles attach to the pubic bone and extend down the thigh to various insertion points on the femur. They work to adduct the hip.

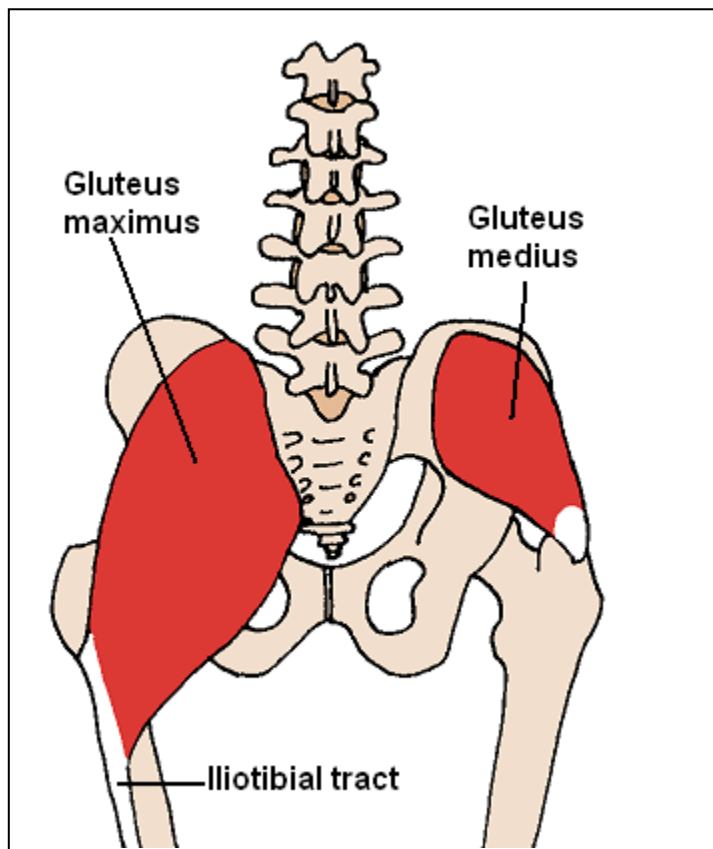


Figure 9.25. Gluteal muscles. The gluteus medius is deep to the gluteus maximus.

[http://commons.wikimedia.org/wiki/Image:Posterior\\_Hip\\_Muscles\\_3.PNG](http://commons.wikimedia.org/wiki/Image:Posterior_Hip_Muscles_3.PNG)

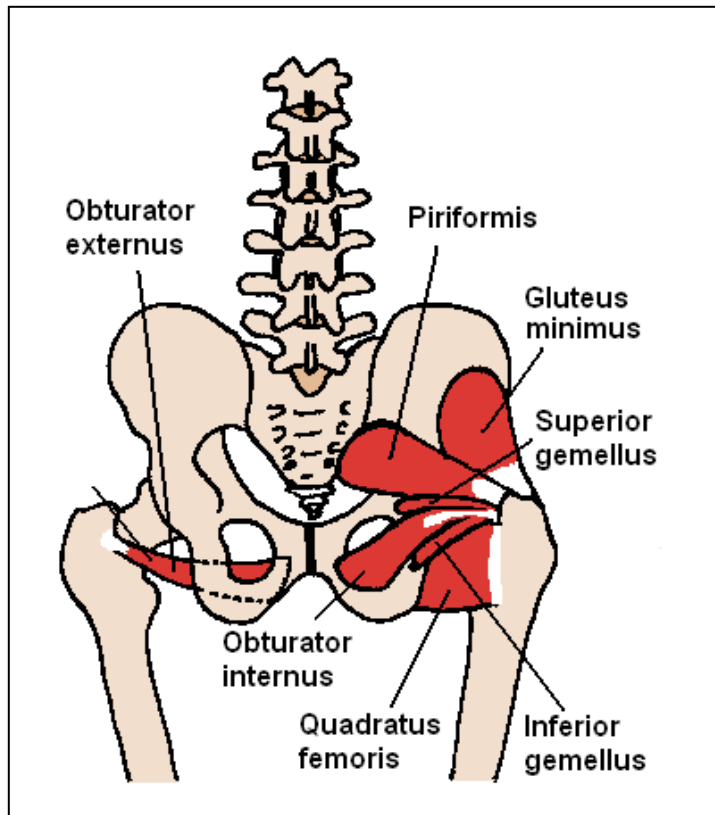


Figure 9.26. Deep muscles of the posterior pelvis.

[http://commons.wikimedia.org/wiki/Image:Posterior\\_Hip\\_Muscles\\_1.PNG](http://commons.wikimedia.org/wiki/Image:Posterior_Hip_Muscles_1.PNG)

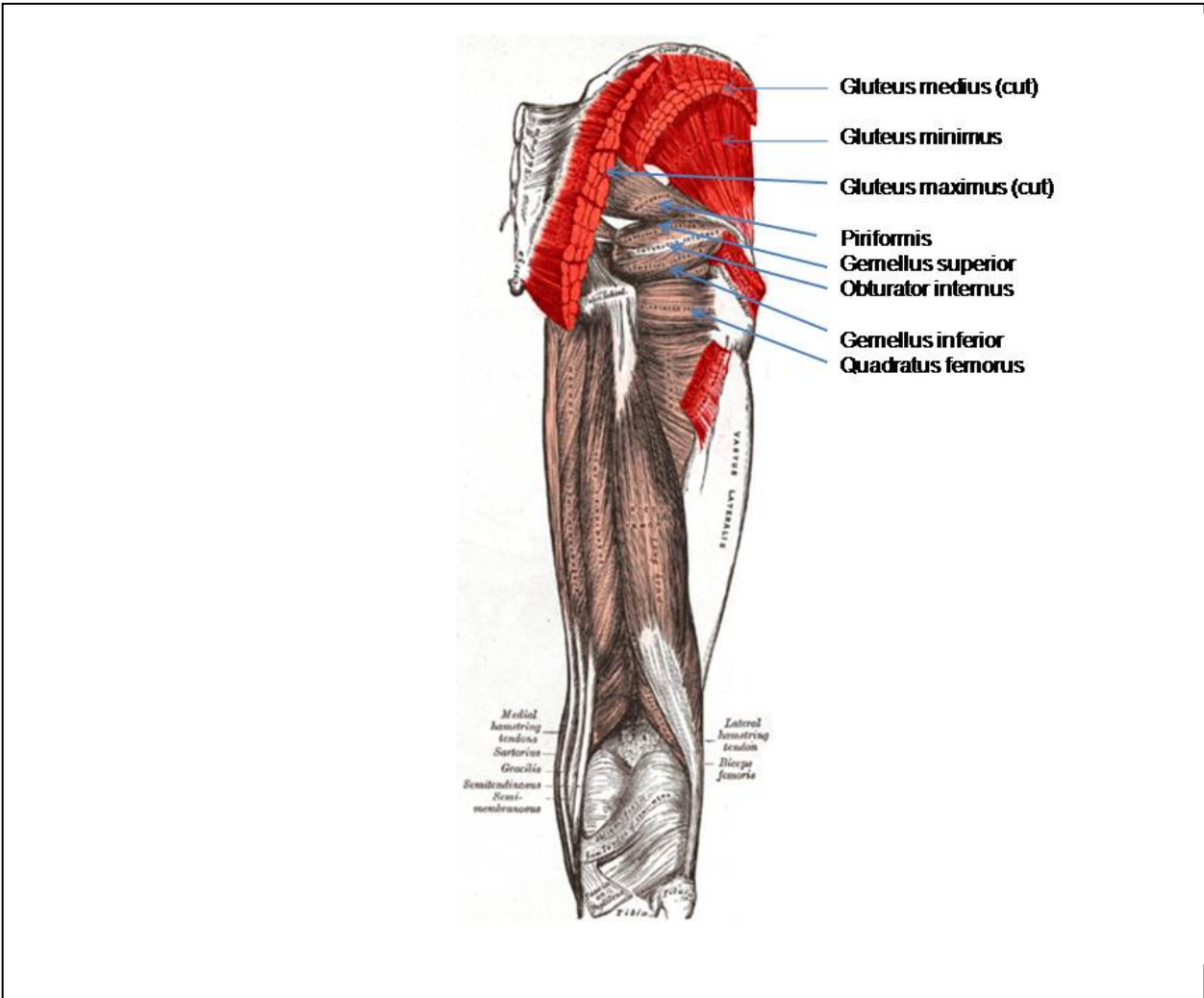


Figure 9.27. Deep muscles of the posterior pelvis.

[http://commons.wikimedia.org/wiki/Image:Gluteus\\_muscles.PNG](http://commons.wikimedia.org/wiki/Image:Gluteus_muscles.PNG)

## **Anterior Thigh Muscles**

The large muscles on the anterior portion of the thigh include the sartorius and quadriceps group (fig. 9.28).

The sartorius (tailor's muscle) attaches to the anterior superior iliac spine and extends from lateral to medial across the thigh to insert on the medial aspect of the upper tibia. This muscle has multiple actions including flexion, abduction and external rotation of the hip.

The quadriceps group consists of the rectus femoris, vastus medialis, vastus lateralis, and vastus intermedius. The quadriceps muscles work together to produce knee extension.

The rectus femoris is located in the middle of the thigh. It attaches to the anterior superior iliac spine and extends inferiorly to the patella.

The vastus medialis is located in the medial aspect of the thigh. It attaches to the linea aspera of the femur and extends to the patella.

The vastus lateralis is located in the lateral aspect of the thigh. It attaches to the greater trochanter of the femur and extends to the patella.

The vastus intermedius lies deep to the rectus femoris. It attaches to the femur and extends to the patella.

All of the quadriceps muscles have a common insertion point on the patellar ligament. The patellar ligament inserts on the tibial tuberosity.

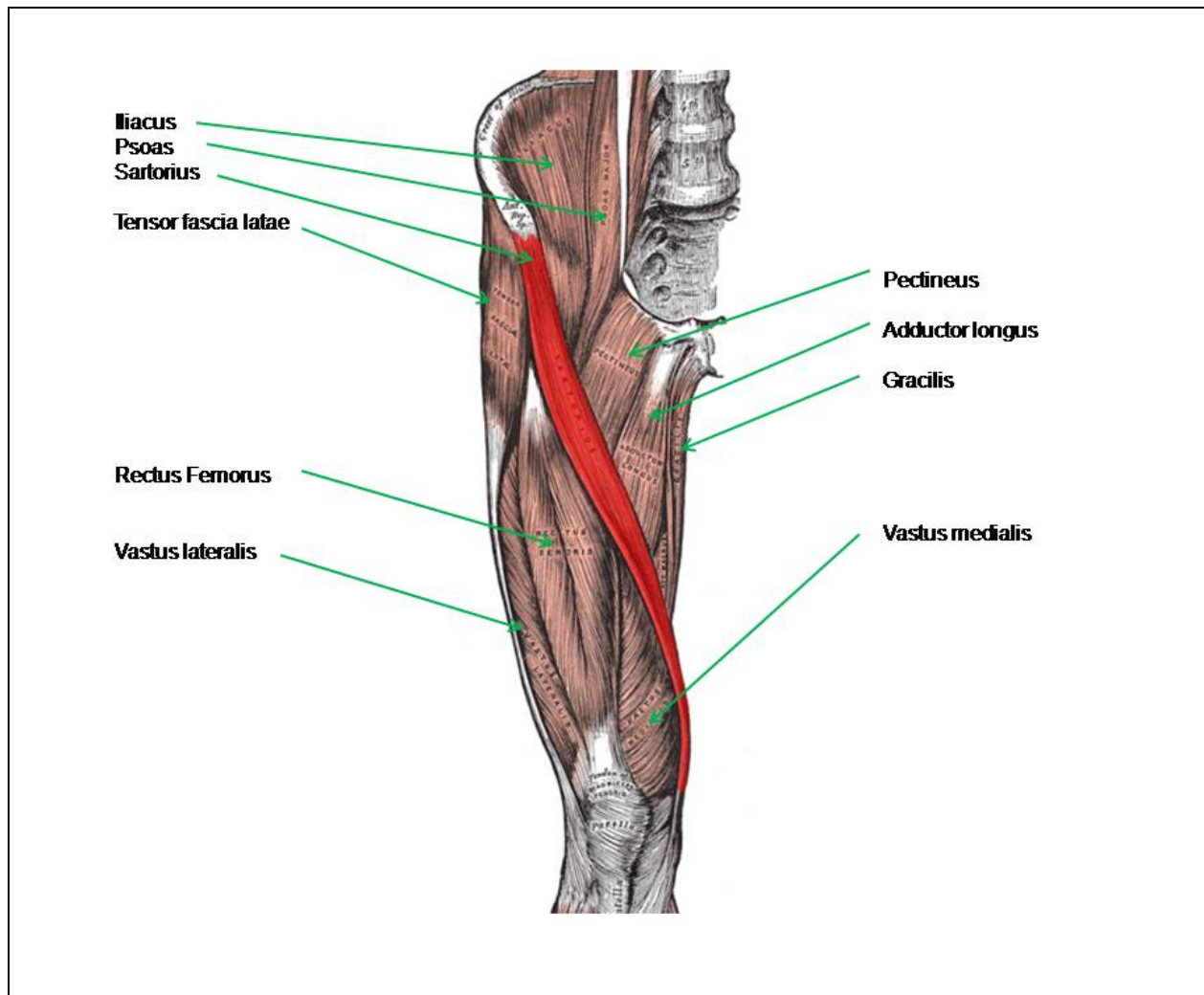


Figure 9.28. Muscles of the anterior thigh.

[http://commons.wikimedia.org/wiki/Image:Sartorius\\_muscle.png](http://commons.wikimedia.org/wiki/Image:Sartorius_muscle.png)

## **Posterior Thigh Muscles**

The posterior thigh muscles include the hamstring group (fig. 9.29). The hamstrings consist of three muscles which include the biceps femoris, semimembranosus, and semitendinosus. The hamstrings work to produce knee flexion.

The biceps femoris is a two-headed muscle. The long head attaches to the ischial tuberosity and the short head attaches to the linea aspera and lateral supracondylar line of the femur. The muscle then extends inferiorly to attach to the head of the fibula.

The semimembranosus attaches to the ischial tuberosity and extends inferiorly to attach to the medial condyle of the tibia and lateral condyle of the femur.

The semitendinosus attaches to the ischial tuberosity and extends inferiorly to attach to the medial aspect of the upper tibia.

## **Posterior Knee**

Located in the posterior portion of the knee is the popliteus muscle. If the femur is fixed the popliteus works to internally rotate the tibia. If the tibia is fixed it works to externally rotate the femur.



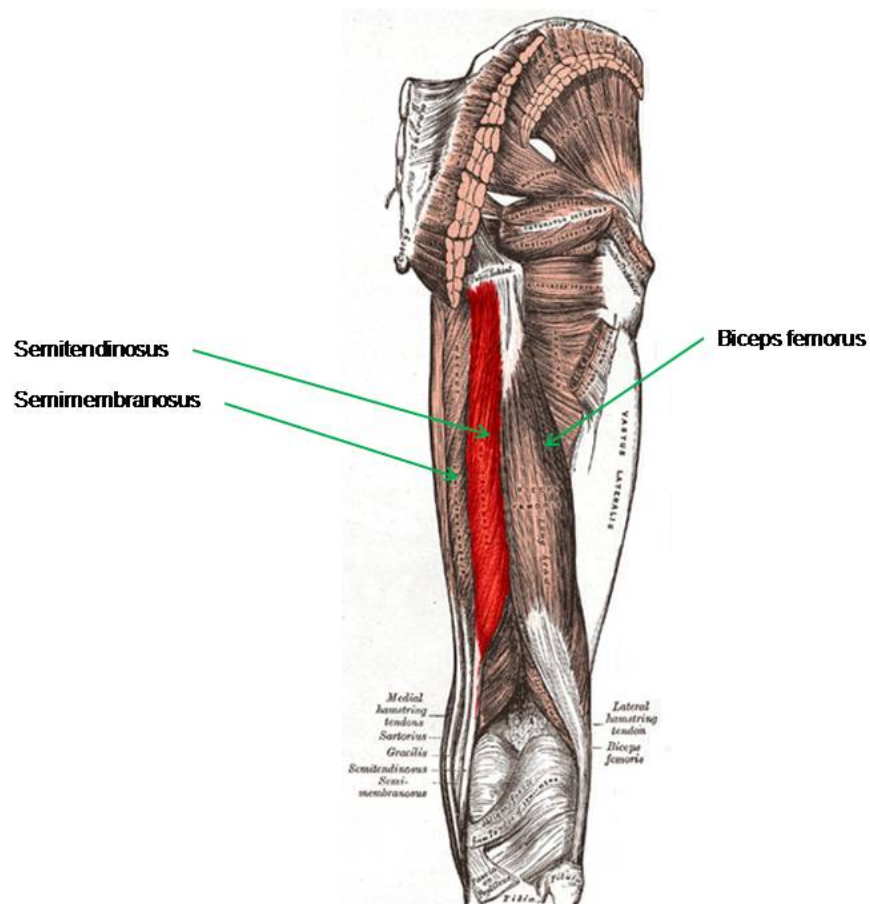


Figure 9.29. Muscles of the posterior thigh.

[http://commons.wikimedia.org/wiki/Image:Semitendinosus\\_muscle.PNG](http://commons.wikimedia.org/wiki/Image:Semitendinosus_muscle.PNG)

## **Muscles of the Anterior Leg**

The muscles of the anterior portion of the leg work to dorsiflex the foot (fig. 9.30). These include the tibialis anterior, extensor hallucis longus, extensor digitorum longus, and peroneus tertius.

The tibialis anterior is located just lateral to the tibia. It attaches to the lateral condyle of the tibia, the lateral aspect of the proximal portion of the tibia and the interosseous membrane that connects the tibia and fibula. It extends downward to attach to the medial cuneiform and first metatarsal. The tibialis anterior is involved in shin splints.

The extensor hallucis longus lies deep to the tibialis anterior. It attaches to the anterior aspect of the fibula and interosseous membrane and extends downward to attach to the first distal phalanx. Besides being a synergist for dorsiflexion of the foot it also extends the big toe.

The extensor digitorum longus also lies deep to the tibialis anterior. It attaches to the lateral condyle of the tibia, shaft of the fibula and interosseous membrane. It works as a synergist in dorsiflexion of the foot and extends the toes. It also works to tighten the plantar aponeurosis.

The peroneus tertius is part of the peroneal group that includes the peroneus longus and peroneus brevis. This muscle works to dorsiflex and evert the foot. It attaches to the medial surface of the lower portion of the fibula and extends to the fifth metatarsal. The peroneal group works together to evert the foot.

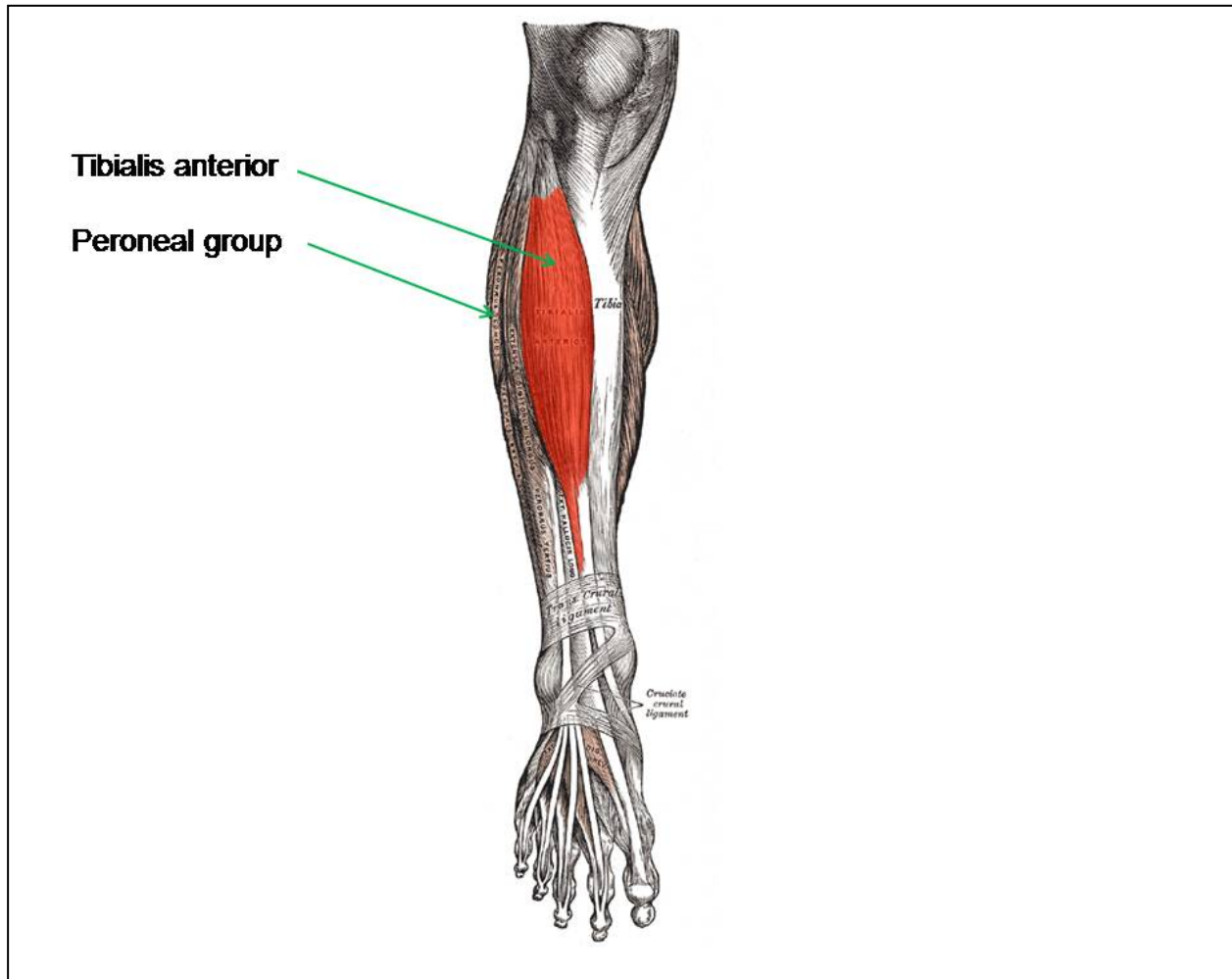


Figure 9.30. Anterior lower leg muscles.

[http://upload.wikimedia.org/wikipedia/commons/6/64/Tibialis\\_anterior\\_2.png](http://upload.wikimedia.org/wikipedia/commons/6/64/Tibialis_anterior_2.png)

## **Muscles of the Posterior and Lateral Leg**

The muscles of the posterior leg work to plantarflex the foot (fig. 9.31). These include the gastrocnemius, soleus, flexor digitorum longus and tibialis posterior.

The gastrocnemius is a two-headed muscle that crosses both the knee and ankle joints. Its action in the knee is to help with knee flexion. It also works to produce ankle plantarflexion. It attaches to the femoral condyles and posterior surface of the distal femur and extends downward to attach to the calcaneus.

The soleus lies deep to the gastrocnemius. It attaches to the posterior aspect of the proximal fibula and tibia and extends downward to attach to the calcaneus. The soleus only crosses the ankle joint and produces ankle plantarflexion.

The gastrocnemius and soleus both insert on the large Achilles (calcaneal) tendon and are known collectively as the triceps surae.

The tibialis posterior is also a deep muscle of the posterior leg. It attaches to the posterior proximal surface of the tibia and fibula and extend downward to attach to the navicular, medial cuneiform and second to fourth metatarsals. It works to produce plantarflexion and also helps to control pronation of the foot while walking.

The flexor digitorum longus is a deep muscle of the posterior leg. It attaches to the posterior surface of the tibia and extends downward to attach to the second through fifth distal phalanges. It works to flex the toes and stabilizes the metatarsal heads.

The peroneus longus is located on the lateral aspect of the lower leg. It attaches to the tibia and fibula and extends to the medial cuneiform and first metatarsal.

The flexor hallucis longus is a deep muscle on the lateral aspect of the leg. It attaches to the distal portion of the fibula and interosseous membrane and extends to attach to the big toe. It works to flex the big toe.

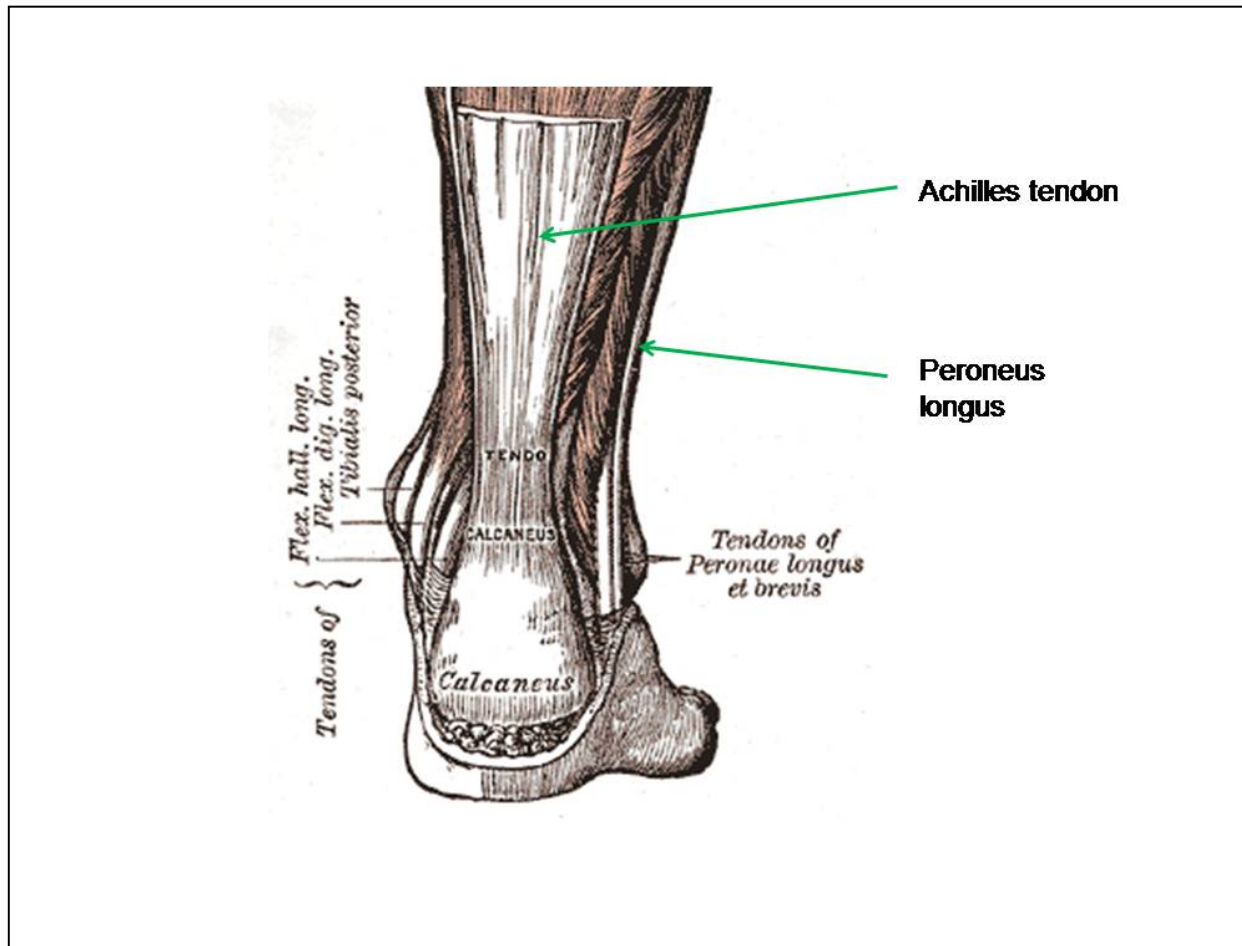


Figure 9.31. The gastrocnemius and soleus attach to the Achilles tendon. The peroneus longus is on the lateral aspect of the leg.

<http://commons.wikimedia.org/wiki/Image:Gray438-cropped.png>

## Muscles of the Foot

The top of the foot is known as the dorsum of the foot (figs. 9.32, 9.33). The only muscle located exclusively on the dorsum of the foot is the extensor digitorum brevis. This muscle attaches to the calcaneus and extensor retinaculum of the ankle and extends to the big toe and tendons of the extensor digitorum longus. It works to produce extension of the toes.

The bottom or sole of the foot is known as the plantar region of the foot. This area contains four layers of muscles.

The layers from superficial to deep include:

Layer 1:

- Flexor digitorum brevis
- Abductor hallucis
- Abductor digiti minimi

Layer 2:

- Quadratus plantus
- Lumbricales

Layer 3:

- Adductor hallucis
- Flexor digiti minimi brevis
- Flexor hallucis brevis

Layer 4:

- Dorsal interossei
- Plantar interossei



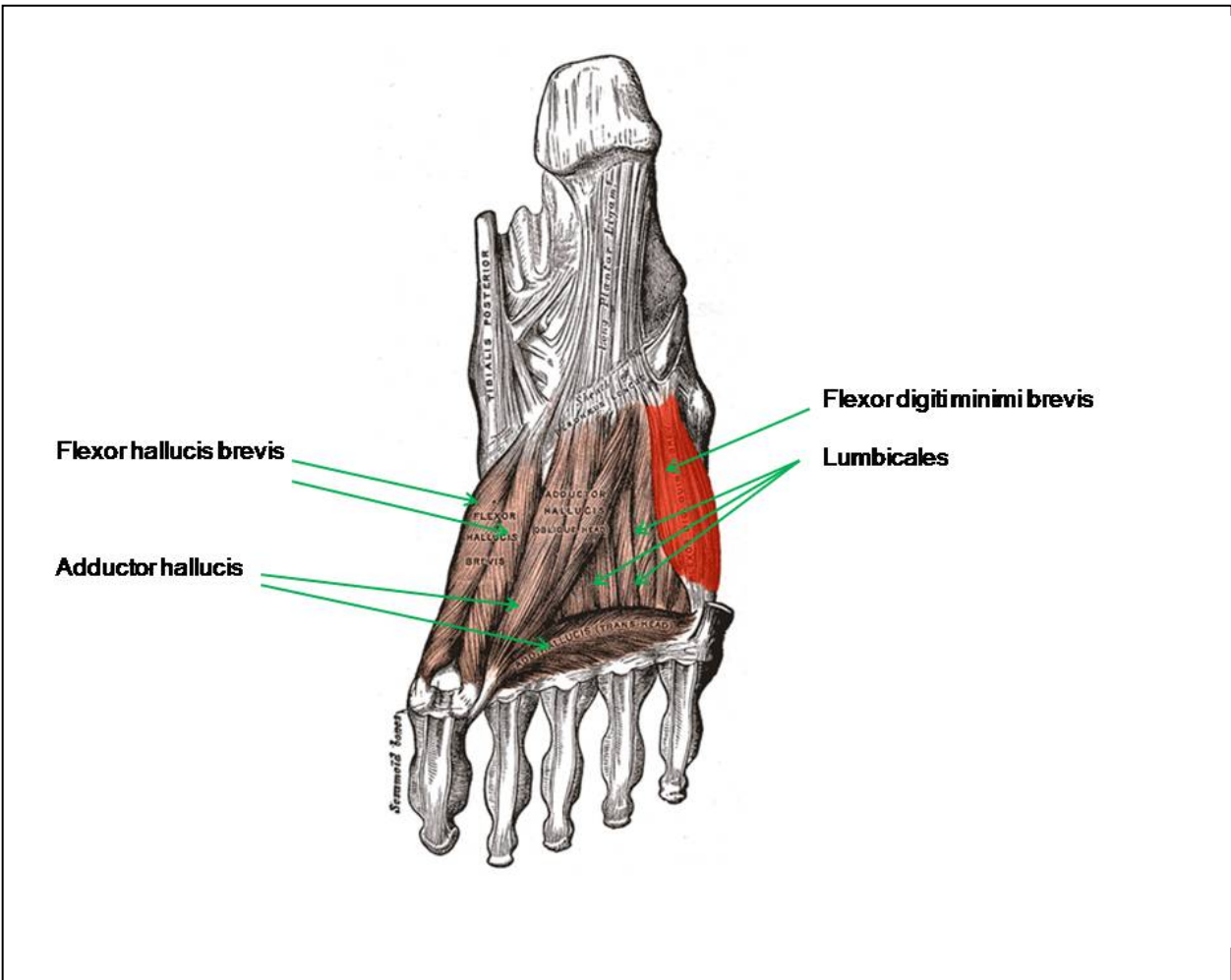


Figure 9.33. Deep muscles of dorsum of foot.

[http://commons.wikimedia.org/wiki/Image:Musculus\\_flexor\\_digiti\\_minimi\\_brevis\\_\(foot\).png](http://commons.wikimedia.org/wiki/Image:Musculus_flexor_digiti_minimi_brevis_(foot).png)



**Table of Select Muscles**

<b>Muscle</b>	<b>Origin</b>	<b>Insertion</b>	<b>Action</b>
Trapezius	Occipital bone, spines of C7 and all T vertebrae	spine and acromion of scapula	Extends head; elevates, depresses, rotates and retracts scapula
latissimus dorsi	lower vertebrae, iliac crest	intertubercular groove of humerus	Extends, adducts and medially rotates arm
serratus anterior	upper 8 ribs	anterior aspect of medial border of scapula	Protracts and rotates scapula
rhomboides	spinous process of C1-T5	medial border of scapula	Retracts and rotates scapula
pectoralis major	clavicle, sternum, costal cartilages	greater tubercle of humerus	Flexes, adducts and medially rotates arm
pectoralis minor	ribs 3,4,5	coracoid process of scapula	Draws scapula anteriorly and inferiorly
acromiodeltoideus, spinodeltoideus and clavodeltoideus (deltoids)	clavicle, acromion and scapular spine	deltoid tuberosity of humerus	abducts arm
supraspinatus	supraspinous fossa of scapula	greater tubercle of the humerus	abducts and stabilizes humerus
infraspinatus	infraspinous fossa	greater tubercle of the humerus	lateral rotation of humerus
triceps brachii	axillary border of scapula, posterior humerus	olecranon process of the ulna	extends forearm, stabilizes shoulder
biceps brachii	coracoid process, intertubercular groove of the humerus	radial tuberosity	flexes arm and forearm, supinates hand
brachialis	distal anterior humerus	coronoid process of ulna	flexes forearm

flexor carpi ulnaris	medial epicondyle of humerus, olecranon process	base of 5th metacarpal, pisiform and hamate	flexes wrist, adducts hand
palmaris longus	medial epicondyle of humerus	palmar aponeurosis	flexes wrist
flexor carpi radialis	medial epicondyle of humerus	base of 2nd and 3d metacarpals	flexes wrist, abducts hand
pronator teres	medial epicondyle of humerus	lateral radius	pronates and flexes forearm
brachioradialis	distal humerus	styloid process of radius	flexes forearm
extensor carpi radialis	lateral epicondyle of humerus	metacarpals II and III	extends and abducts wrist
extensor digitorum communis	lateral epicondyle of the humerus	posterior surfaces of distal phalanges of digits 2-5	Extends fingers and wrist, abducts fingers
extensor digitorum minimi	--	--	extends 5th digit
extensor carpi ulnaris	lateral epicondyle of humerus	metacarpal V	extends and adducts wrist
masseter	zygomatic arch	angle and ramus of mandible	elevates mandible
mylohyoideus	mandible	Hyoid	elevates hyoid
digastricus	mandible and mastoid process	hyoid bone	elevates hyoid and depress mandible (open mouth)
sternohyoideus	manubrium and clavicle	hyoid bone	depresses hyoid and larynx
sternomastoideus	manubrium, clavicle	mastoid process	singly, rotates head to opposite shoulder; together, flexes head

external oblique	lower 8 ribs	iliac crest and linea alba	flexion and rotation at waist
internal oblique	lumbodorsal fascia	lower 4 ribs	flexion and rotation at waist
transverse abdominis	iliac crest, cartilages of lowest ribs	linea alba and pubic crest	compresses abdominal wall
rectus abdominis	pubic crest and pubic symphysis	ribs 5-7 and xiphoid process	flexion at waist
tensor fascia latae	iliac crest and anterior superior iliac spine	iliotibial tract	flexes, abducts and medially rotates thigh
gluteus medius	ilium	greater trochanter of the femur	abduction and medial rotation of thigh
gluteus maximus	ilium, sacrum, coccyx	iliotibial tract, gluteal tuberosity of femur	extension and lateral rotation of thigh
sartorius	anterior superior iliac spine	tibia	flexes, abducts and laterally rotates thigh; flexes lower leg
gracilis	pubis	medial tibia	adducts thigh, flexes and medially rotates leg
adductor femoris	ischium and pubis	linea aspera of femur	adducts, flexes and laterally rotates thigh
biceps femoris	ischial tuberosity and femur	tibia and fibula	extends thigh and flexes lower leg
semitendinosus	ischial tuberosity	medial aspect of proximal tibia	extends thigh, flexes lower leg
semimembranosus	ischial tuberosity	medial condyle of tibia	extends thigh, flexes lower leg
vastus lateralis	linea aspera	patella and tibial tuberosity	extends lower leg, stabilizes knee
vastus medialis	linea aspera	patella and tibial	extends lower leg

		tuberosity	
vastus intermedius	proximal femur	patella and tibial tuberosity	extends lower leg
rectus femoris	anterior inferior iliac spine	patella and tibial tuberosity	extends knee, flexes thigh
gastrocnemius	medial and lateral condyles of femur	via achilles tendon onto calcaneal tendon	flexes lower leg, plantarflexes foot
tibialis anterior	lateral condyle and tibial shaft	first cuneiform and first metatarsals	dorsiflexes and inverts foot
soleus	head of fibula and tibia	calcaneal tendon onto calcaneus	plantarflexes foot
fibularis longus	head of fibula	first metatarsal	plantar flexion
extensor digitorum longus	posterior tibia	distal phalanges of toes 2-5	Extend toes 2 - 5 and dorsiflexes ankle

## Review Questions Chapter 9

1. The temporomandibular joint is an example of which type of lever:
  - a. First class
  - b. Second class
  - c. Third class
  - d. Fourth class
  
2. Which best describes a first class lever:
  - a. Fulcrum is between pull and weight
  - b. Weight is between pull and fulcrum
  - c. Pull is between weight and fulcrum
  - d. Weight and pull are next to fulcrum
  
3. My car was stuck. I tried to push it but it wouldn't budge an inch. This is an example of which type of contraction:
  - a. Isotonic
  - b. Isometric
  - c. Isokinetic
  - d. Isoisonic
  
4. Which of the following is not an arm muscle:
  - a. Brachioradialis
  - b. Triceps
  - c. Sartorius
  - d. Flexor carpi radialis
  
5. This muscle is located on the side of the neck:
  - a. Erector spinae
  - b. Trapezius
  - c. Sternocleidomastoid
  - d. Latissimus dorsi
  
6. Which of the following is a muscle of facial expression:
  - a. Trapezius
  - b. Platysma
  - c. Orbicularis oculi
  - d. Levator scapula

7. Which of the following is not a hamstring muscle:
- a. Rectus femoris
  - b. Semitendinosus
  - c. Biceps femoris
  - d. Semimembranosus
8. Which muscle works to flex the hip:
- a. Tibialis anterior
  - b. Iliopsoas
  - c. Rectus abdominus
  - d. Soleus
9. Which of the following is the deepest abdominal muscle:
- a. Transverse abdominus
  - b. External oblique
  - c. Internal oblique
  - d. Rectus abdominus
10. The latissimus dorsi muscle inserts:
- a. On the thoracic wall
  - b. On the humerus
  - c. On the scapula
  - d. On the cervical spine

# Chapter 10

## Muscular System Physiology

## Physiology of the Muscular System

Muscles move the body. During a visit to a health club we can see people lifting weights, stretching, doing Pilates exercises, riding stationary bikes, walking on treadmills and swimming. All of these activities are the result of muscular contraction. In this chapter we will explore the physiology of muscles. We will take a deeper look into how they are put together and how they contract and we will apply these concepts to our everyday experiences.

At our health club we might see someone lifting a weight. In order to perform this activity muscles must respond to commands from the nervous system. We can say that muscles then exhibit the properties of excitability (muscles can respond to stimulus) and contractility (muscles can contract). As we walk through the club we may also see someone stretching. In order to perform this activity muscles must have some elastic properties (elasticity). We may also see someone reach out to pick up a barbell. Muscles must also be able to contract while extended. We can say that muscles have the property of extensibility.

### Muscle Physiology: The Big Picture

So how does a muscle contract? In order to answer this question we must first examine what *tells* a muscle to contract. Let's say that I am sitting here writing and want to pick up a cup of coffee. In order to do so I must send a command to the muscles in my arm. The command comes from a thought generated in my nervous system. The command travels from my brain to my spinal cord to a nerve that attaches to a muscle in my arm. The command tells my muscle to contract and my arm dutifully responds by moving closer to the coffee.

Muscles are made of protein. If we were to examine a skeletal muscle under a microscope we would see that it is composed of tiny protein fibers or filaments. When a muscle receives a command from the nervous system to contract the protein filaments slide past each other. In fact one of the filaments connects to the other and drags it along. Think of thousands of overlapping filaments sliding past each other as the muscle contracts.

The command to contract must somehow get from the outside of the muscle to the inside. Tiny messengers called neurotransmitters bring the message from the nerve to the muscle. Other chemical messengers that tell the protein filaments to contract then pass on the message.

Muscles need energy to contract. Muscles must have some sort of power source in order to power the sliding filaments. The energy comes from ATP. ATP connects to one type of filament and extracts the energy so that it can pull the other filament along.

### Muscle Structure

Before we can get into the details of how muscles contract we must examine the microscopic structure of muscles. If we look at muscle tissue under a microscope we will see that it consists of long cells and has light and dark areas. We say that the muscle has a striated appearance. The striations actually denote contractile units. (fig. 10.1).



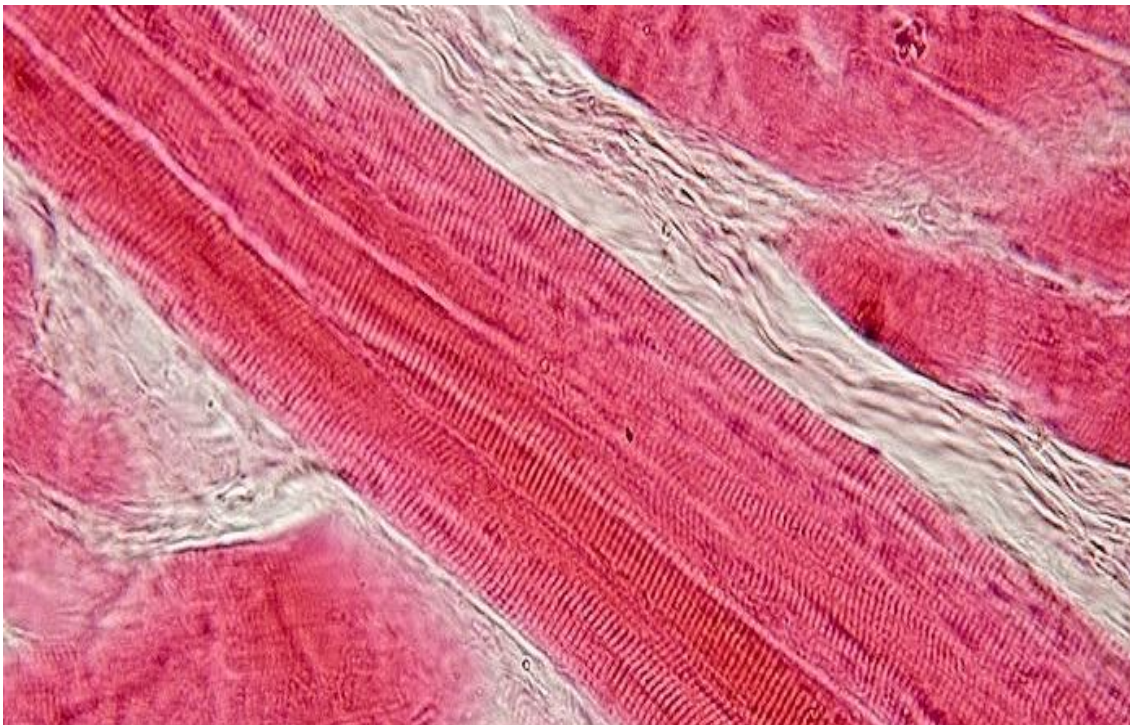


Figure 10.1. Skeletal muscle is characterized by long cells and has a striated appearance.

[http://commons.wikimedia.org/wiki/Image:Skeletal\\_muscle\\_-\\_longitudinal\\_section.jpg](http://commons.wikimedia.org/wiki/Image:Skeletal_muscle_-_longitudinal_section.jpg)

If we look at the muscle down its long axis we see that it consists of bundles within bundles. The most outer layer consists of connective tissue called fascia. The fascia continues along muscle to become tendons. The tendons connect the muscle to the bone.

Deep to the fascia we see a layer of dense connective tissue covering the entire muscle. This layer is called the epimysium. Deep to the epimysium we see structures that look like bundles. These bundles are known as fascicles. Each fascicle consists of an outer connective tissue layer called the perimysium. Inside the perimysium are even smaller bundles of muscle fibers. Surrounding each muscle fiber is a layer of connective tissue called the endomysium. The muscle fibers consist of smaller protein filaments surrounded by plasma membrane known as a sarcolemma (fig. 10.2).

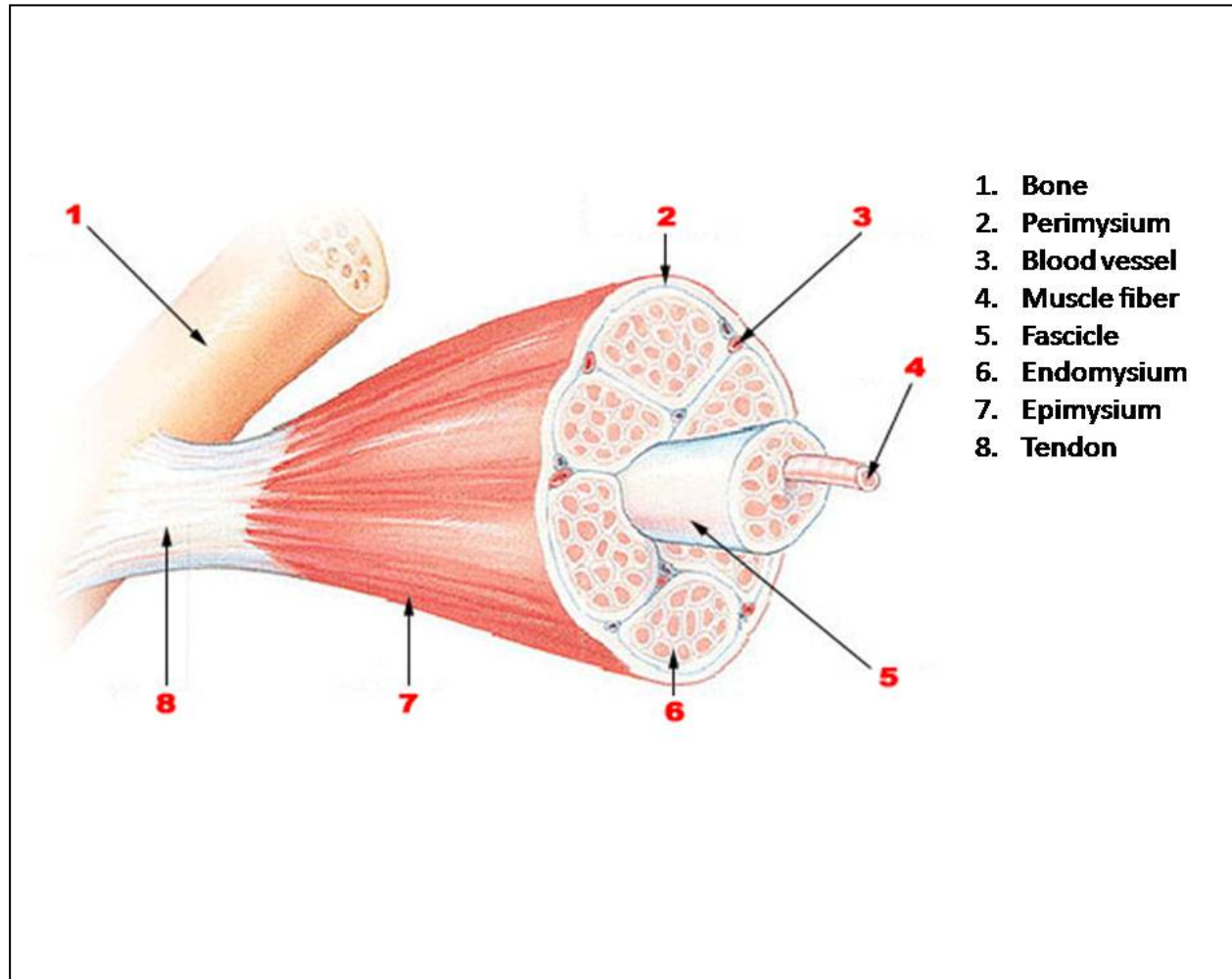


Figure 10.2. Structure of skeletal muscle.

[http://commons.wikimedia.org/wiki/Image:Skeletal\\_muscle.png](http://commons.wikimedia.org/wiki/Image:Skeletal_muscle.png)

## The Muscle Fiber

Skeletal muscle cells are surrounded by a membrane called the sarcolemma and contain many nuclei. Inside the membrane are myofibrils packed with protein filaments. The myofibril extends along the entire length of the muscle. The myofibrils contain two types of myofilaments known as actin and myosin that overlap each other (fig. 10.7).

The actin or thin filament consists of a core fibrous protein called F actin twisted into a double helix arrangement. The actin contains a binding site consisting of a polymer called G actin for the other protein filament called myosin. Surrounding each actin molecule is a complex of troponin and tropomyosin molecules. The tropomyosin covers the myosin binding sites on the actin.

Myosin molecules are known as thick filaments. Myosin contains a double helix shaft portion and two globular protein heads. The heads can attach to the myosin binding sites on the actin as well as use ATP. The myosin heads have ATPase activity and can liberate the phosphate from ATP to release energy. The myosin heads also have a region that acts like a hinge allowing myosin to bend (fig. 10.3).

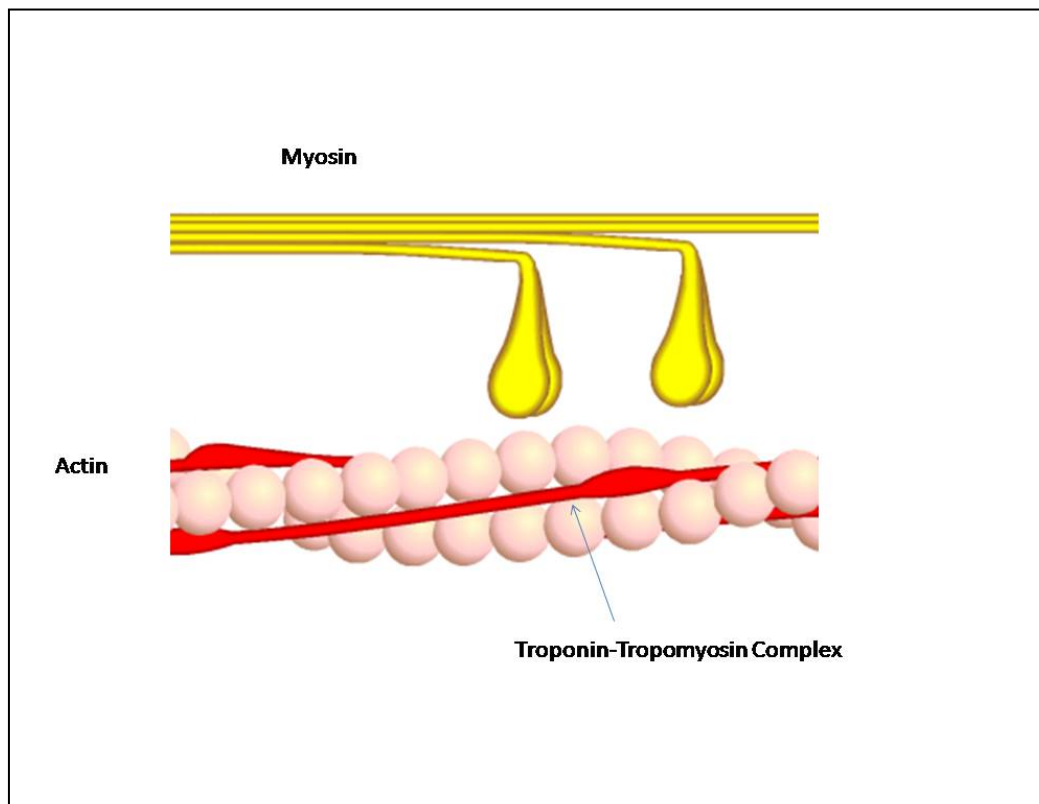


Figure 10.3. Actin and myosin

[http://commons.wikimedia.org/wiki/Image:Querbr%C3%BCckenzyklus\\_4.png](http://commons.wikimedia.org/wiki/Image:Querbr%C3%BCckenzyklus_4.png)

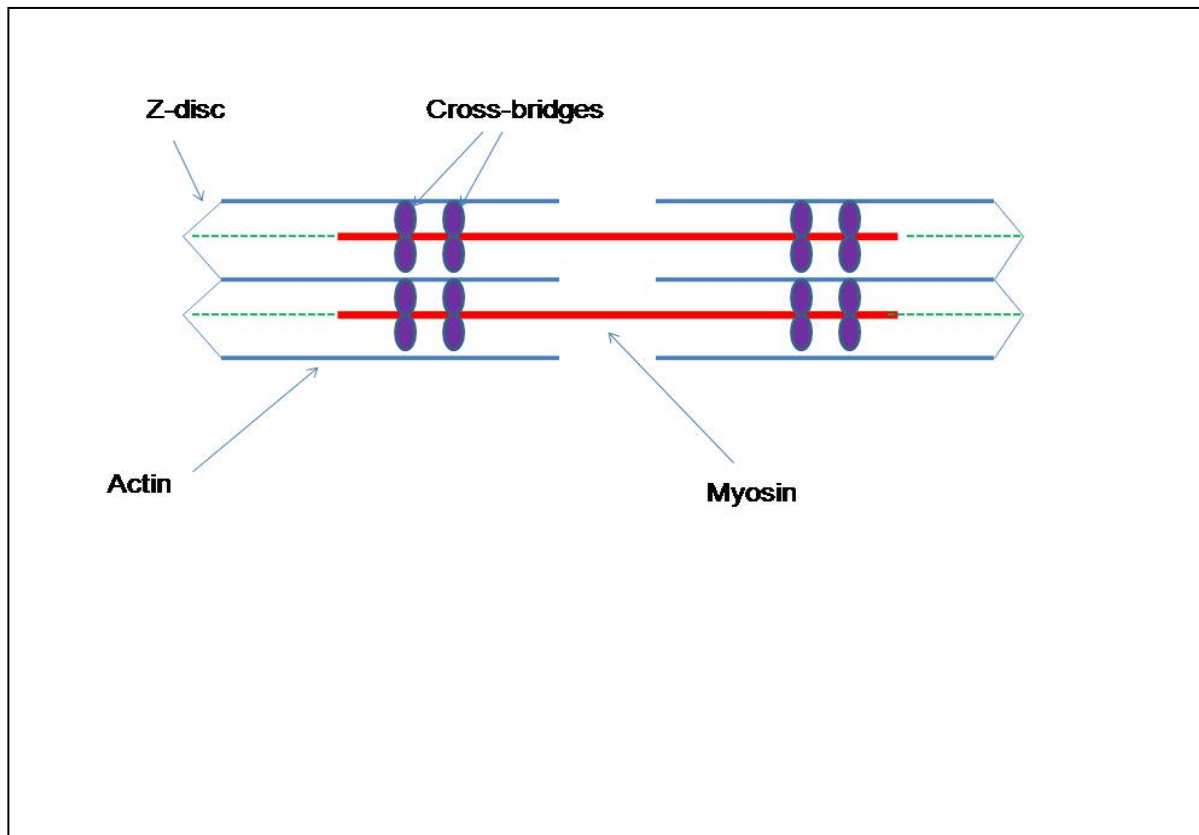


Figure. 10.4. Actin and myosin overlap.

Bruce Forciea

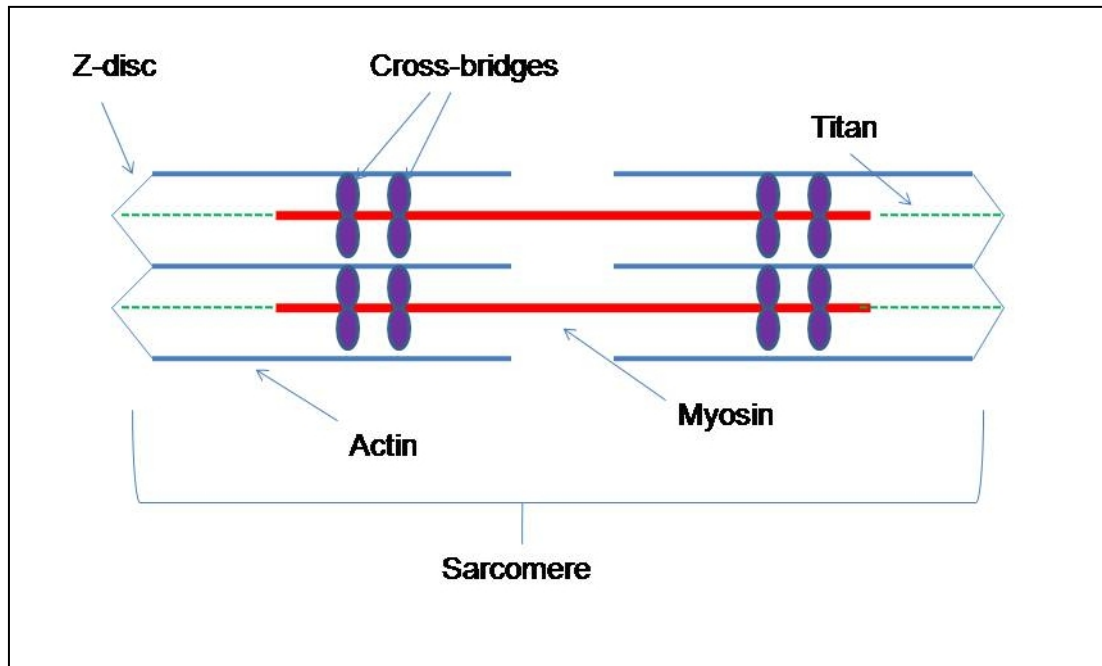


Figure 10.5. The sarcomere extends from z-disc to z-disc.

Bruce Forciea

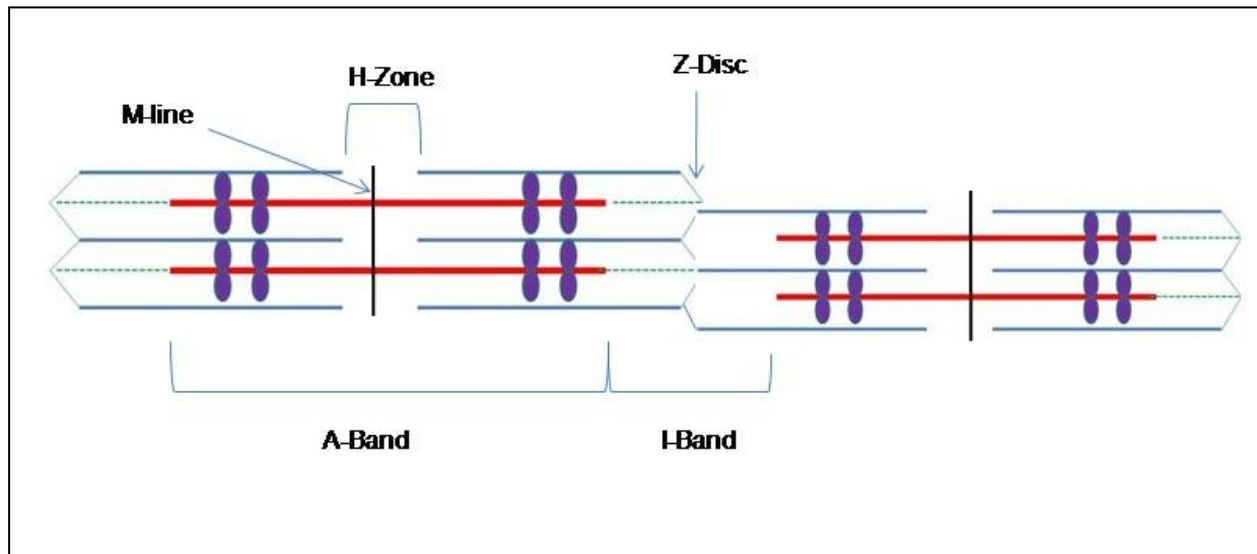


Figure 10.6 The sarcomere.

Bruce Forciea

The contractile unit in muscle is known as the sarcomere. Protein connects the actin and myosin filaments together. This protein located at the ends of the filaments is called a Z-disc. The actin filaments directly attach to the Z-disc while the myosin attaches via titin protein. The arrangement of overlapping actin and myosin creates a number of bands. The I-band extends from the end of one myosin filament to the other including the Z-disc. The I-bands are also called light bands and are considered isotropic (equal in all directions). The A-bands extend the length of the myosin filaments. A-bands or dark bands are considered to be anisotropic (unequal in all directions). In the center of each A-band lies an area consisting only of myosin. This area is called the H-zone. The H-zone also contains a dark line running down the middle called the M-line. The M-line consists of protein that helps to hold the myosin filaments in place (figs. 10.4, 10.5, 10.6).

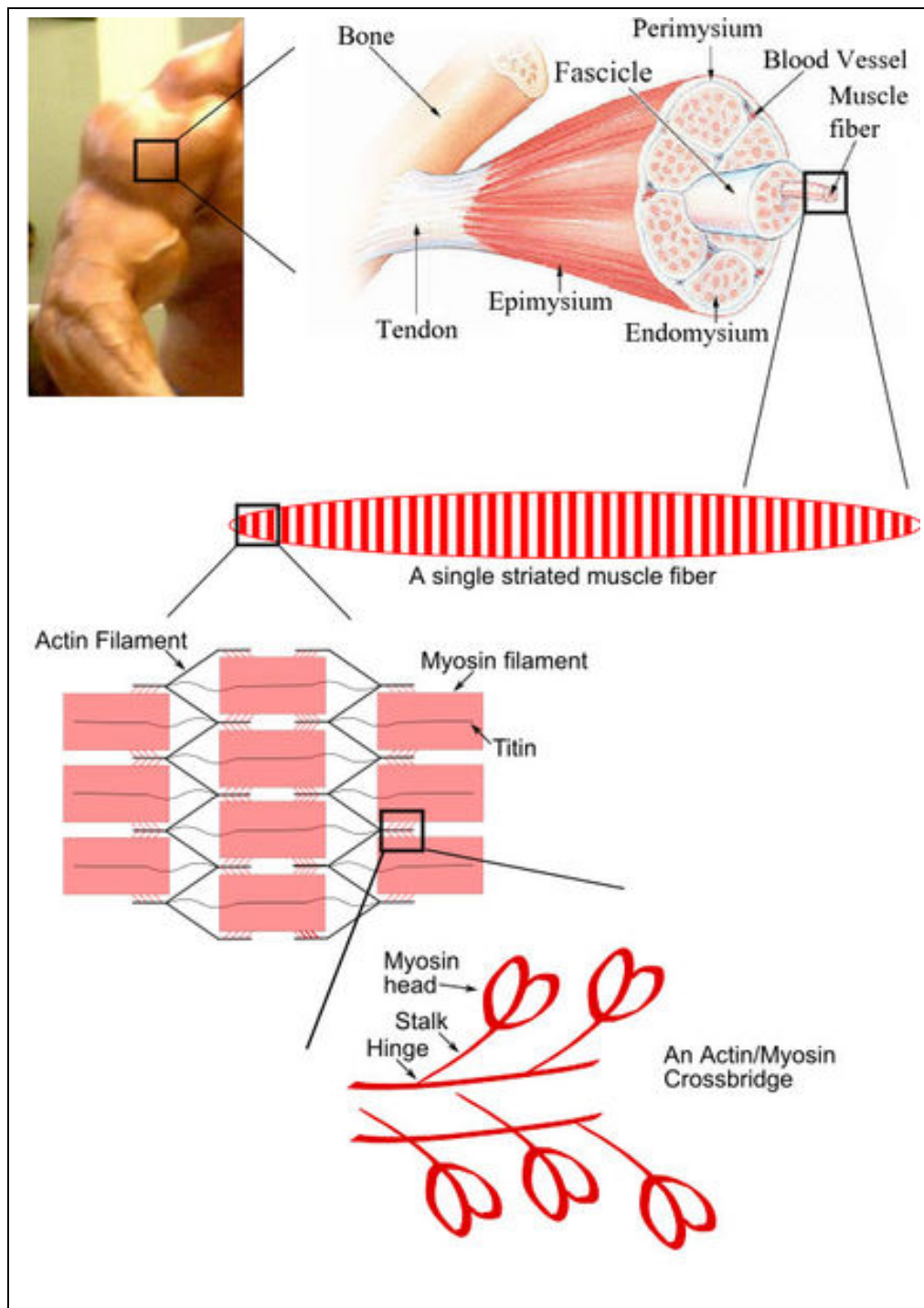


Figure 10.7. Skeletal Muscle Structure.

[http://commons.wikimedia.org/wiki/Image:Skeletal\\_muscle\\_diagram.jpg](http://commons.wikimedia.org/wiki/Image:Skeletal_muscle_diagram.jpg)



## The Sliding Filament Model of Muscle Contraction

The essence of the sliding filament model of muscle contraction is the action of actin and myosin sliding past each other. When this happens the sarcomere shortens and the muscle contracts. The process begins when a command or impulse is sent down a neuron that connects to muscle called a motor neuron.

### Step 1 Motor Neuron Sends Message to Muscle to Contract

The motor neuron releases a message in the form of a neurotransmitter to the muscle to tell it to contract. The neurotransmitter floats across an area between the neuron and muscle called the synaptic cleft (fig. 10.8). The muscle side of the synaptic cleft is called the motor end plate. The sarcolemma is enfolded at the motor end plate in order to increase the surface area. The neurotransmitter involved in skeletal muscle contraction is acetylcholine (fig. 10.9).

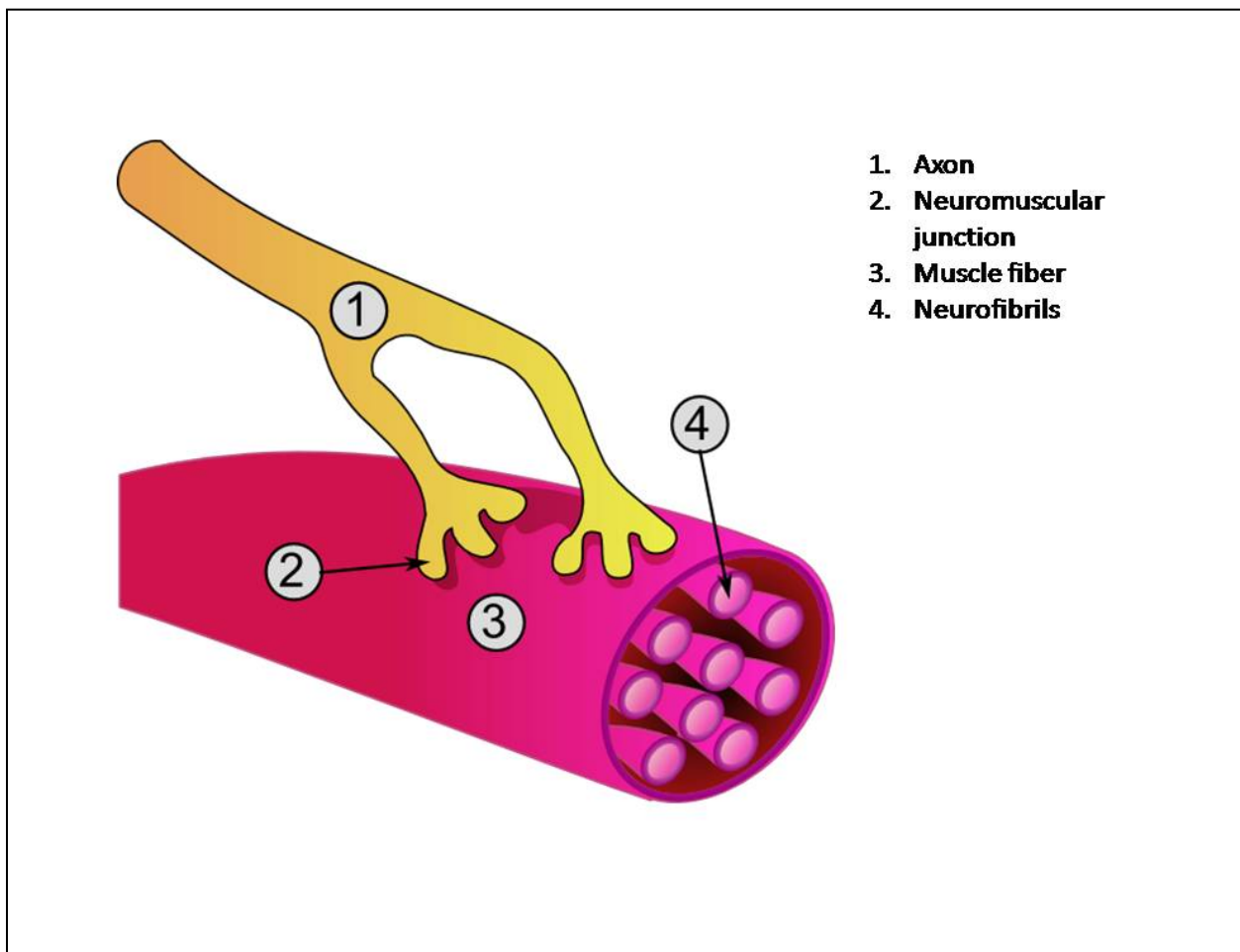


Figure 10.8. Motor Neuron and Muscle

[http://commons.wikimedia.org/wiki/Image:Synapse\\_diag3.png](http://commons.wikimedia.org/wiki/Image:Synapse_diag3.png)

Author: [fr:Utilisateur:Dake](#)



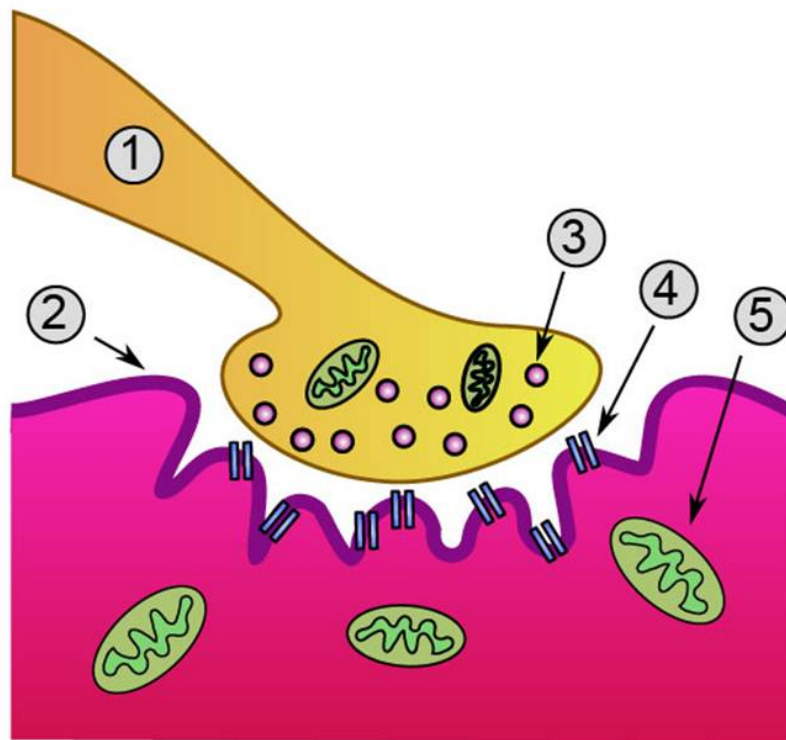


Figure 10.9. Neuromuscular junction

1. Presynaptic terminal
2. Sarcolemma
3. Synaptic vesicles
4. Acetylcholine receptors
5. Mitochondrion

[http://commons.wikimedia.org/wiki/Image:Synapse\\_diag4.png](http://commons.wikimedia.org/wiki/Image:Synapse_diag4.png)  
Author: [fr:Utilisateur:Dake](#)

## **Step 2 Muscle Depolarizes**

Muscle cells exist at a negative membrane potential or voltage. This negative potential in muscle cells is called resting membrane potential. Resting membrane potential is established by the various concentration gradients of electrolytes. The resting membrane potential of muscle (and nerve) cells is between -70mV and -90mV (mV = millivolts or one thousandth of a volt).

When the acetylcholine floats across the synaptic cleft to the motor end plate it attaches to receptors on transport proteins on the motor end plate. The transport proteins are sodium channels that are controlled by the acetylcholine. These are called ligand gated channels because when the ligand (acetylcholine) attaches to the channel the channel responds by opening and letting sodium into the cell. Since there is more sodium outside the cell than inside, opening the channel causes sodium to rush into the cell. This causes the voltage to change since sodium is positively charged. The cell's potential changes and becomes less negative (more positive). We say the cell is depolarizing.

## **Step 3 Release of Calcium by the Sarcoplasmic Reticulum**

The sarcolemma surrounding the muscle cell contains tube like structures called T-tubules. The T-tubules reach into the muscle fiber and encircle the sarcomere. Since the T-tubule connects to the outside of the cell it is filled with extracellular fluid. Between T-tubules lies a specialized type of endoplasmic reticulum called the sarcoplasmic reticulum. The sarcoplasmic reticulum is a network of membranous channels called cisternae. Cisternae near the T-tubules are wider and called terminal cisternae. A tubule and the two adjacent terminal cisternae are called a triad.

The sarcoplasmic reticulum actively transports calcium so it contains a high concentration of calcium. The concentration of calcium inside the sarcoplasmic reticulum is 2000 times greater than inside the muscle cell. So a significant calcium gradient exists between the sarcoplasmic reticulum and the inside of the muscle cell (fig. 10.10).

The sarcoplasmic reticulum responds to the depolarization of the muscle cell by opening calcium channels in the terminal cisternae of the sarcoplasmic reticulum. When these channels open calcium rushes into the sarcoplasm of the muscle cell. This process is called excitation-contraction coupling.

## **Step 4 Calcium Binds to the Troponin on the Actin**

Calcium rushes into the sarcoplasm of the muscle cell and attaches to the troponin on the troponin-tropomyosin complex wrapped around the actin. This causes a change in the position of the troponin that exposes the myosin binding site on the actin. The myosin can now bind with actin forming what is known as a cross-bridge (figs. 10.11, 10.12).

## **Step 5 Myosin Pulls Actin Along**

Myosin can now move at its hinge region and subsequently move the actin along (fig. 10.13). This results in actin and myosin sliding past each other. At the end of a cycle of movement the myosin must release from actin and return to its original position. It can now repeat the cycle and bind with another site on the actin. The cycle consists of cross-bridge formation, movement, release and myosin's return to its original position. This cycle is called cross-bridge cycling (fig. 10.14).

The energy needed for one cross-bridge cycle is provided by one ATP molecule. ATP binds to the myosin head which has ATPase activity. The ATP decomposes into ADP and a phosphate. Once the calcium attaches to troponin and exposes the binding site the myosin moves and binds to actin while releasing

the phosphate and extracting the energy from the phosphate bond. ADP is released from the myosin head when myosin pulls actin along. Another ATP must again bind to the myosin head to allow for release of the myosin head from actin. ATP binds to the myosin head and decomposes into ADP and phosphate which remain on the myosin head. The myosin head now releases from actin and resumes its resting position with the ADP and phosphate still on it. The energy from the ATP is stored in the myosin head (fig. 10.15).

Movement of the myosin head while it is attached to actin is called the power stroke while movement of the myosin head back to its original position is called the recovery stroke.

Resting muscles store energy from ATP in the myosin heads while they wait for another contraction.

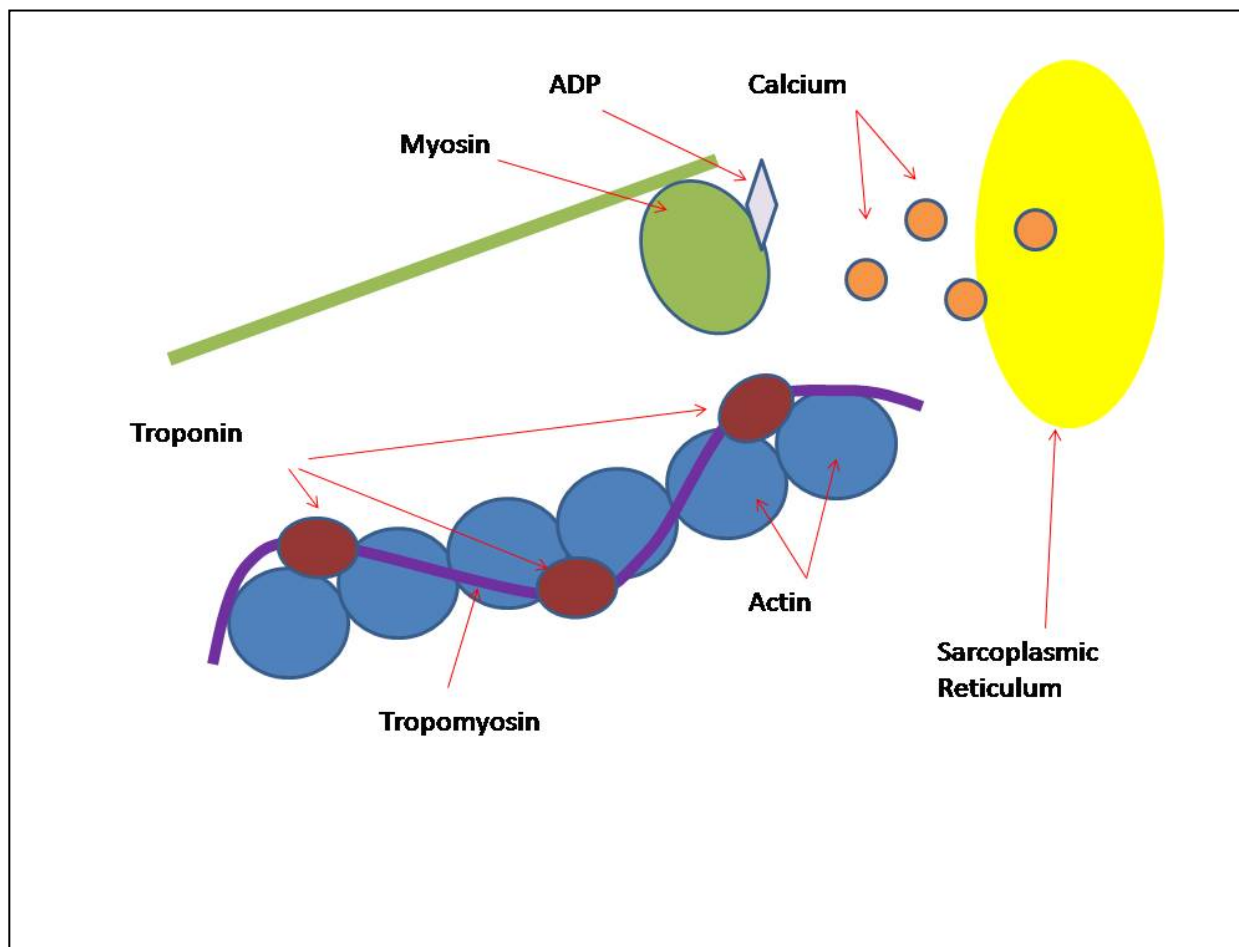


Figure 10.10. Muscle Contraction Physiology. The sarcoplasmic reticulum responds to muscle fiber depolarization by releasing calcium.

Bruce Forciea

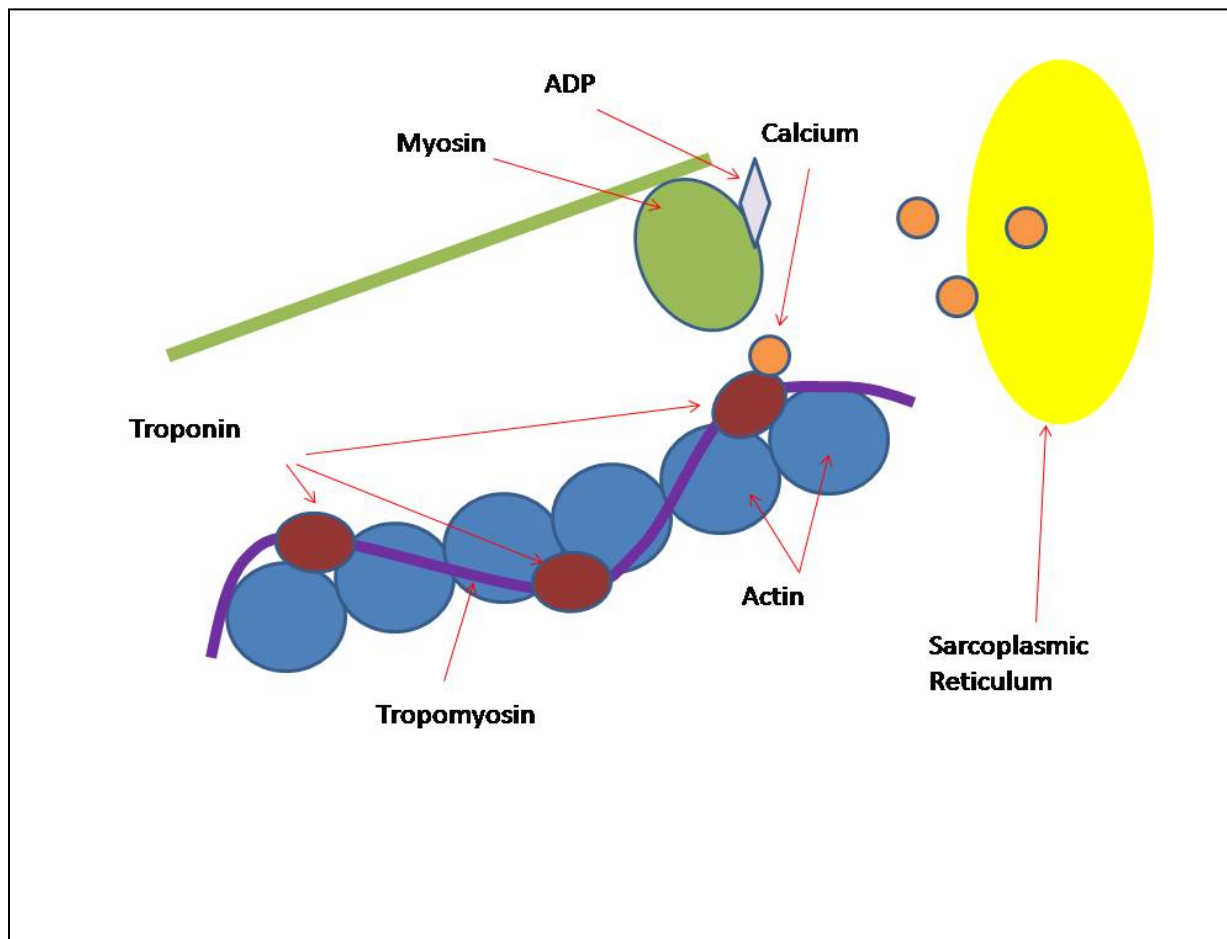


Figure 10.11. Muscle Contraction Physiology. Calcium attaches to troponin on the tropomyosin surrounding the actin. ADP is attached to myosin.

Bruce Forciea

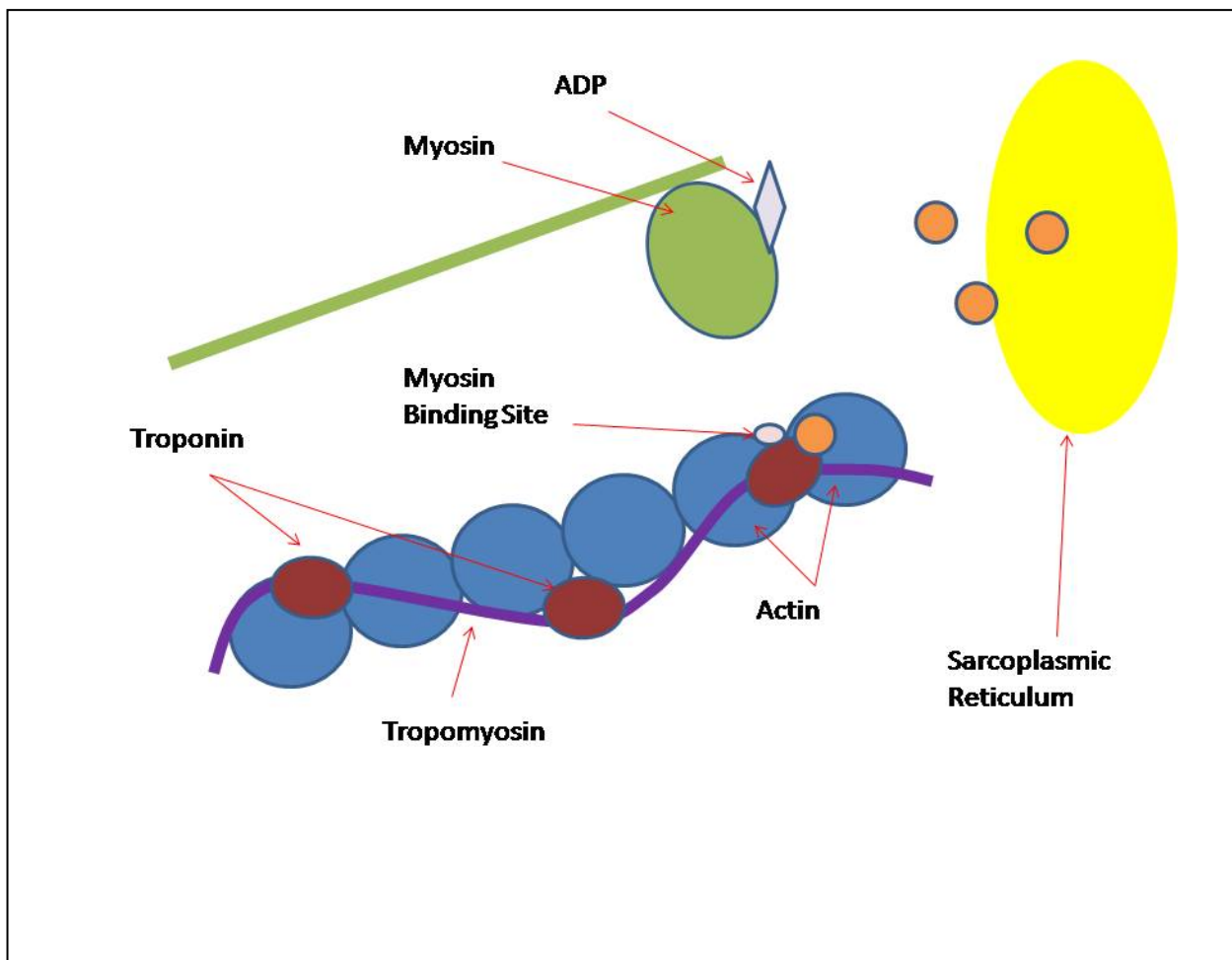


Figure 10.12. Muscle Contraction Physiology. Troponin-tropomyosin responds to the attachment of calcium by changing its shape and exposing myosin binding sites on actin.

Bruce Forciea

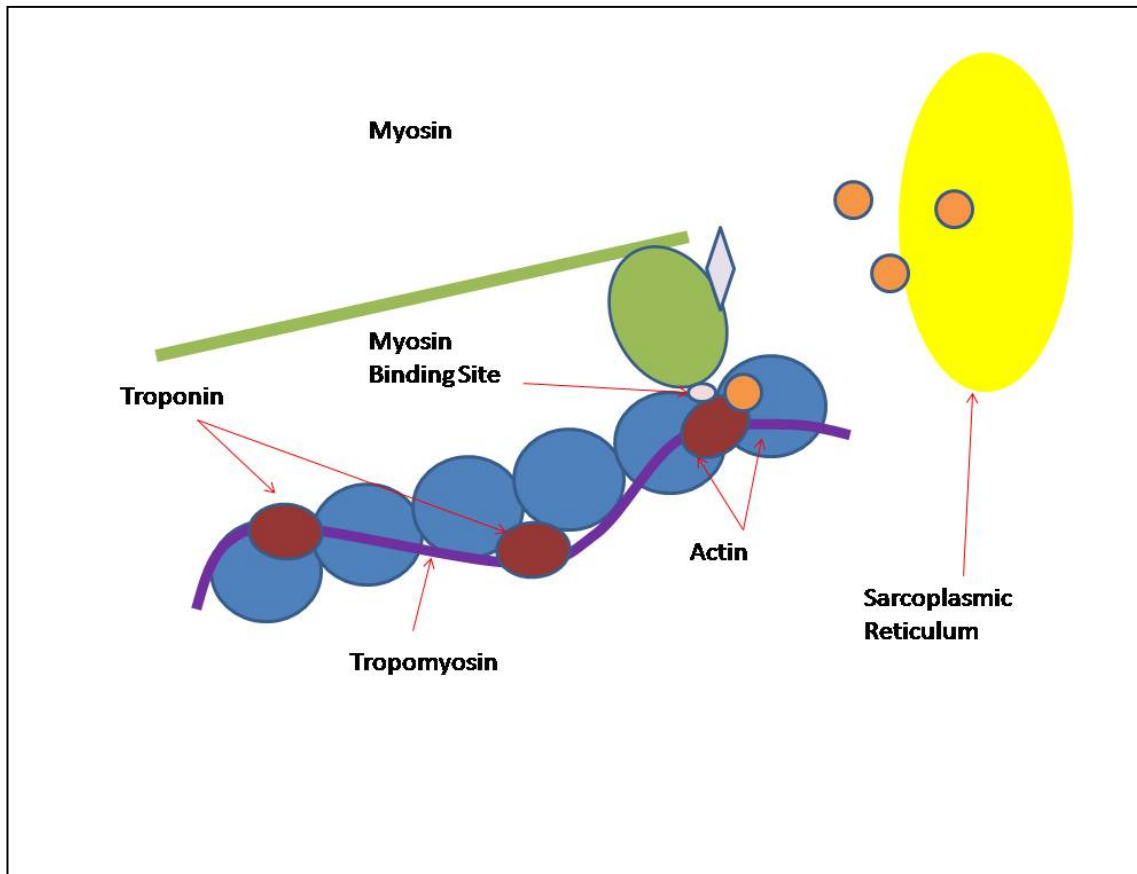


Figure 10.13. Muscle Contraction Physiology. Myosin binds to actin forming a cross-bridge.

Bruce Forciea

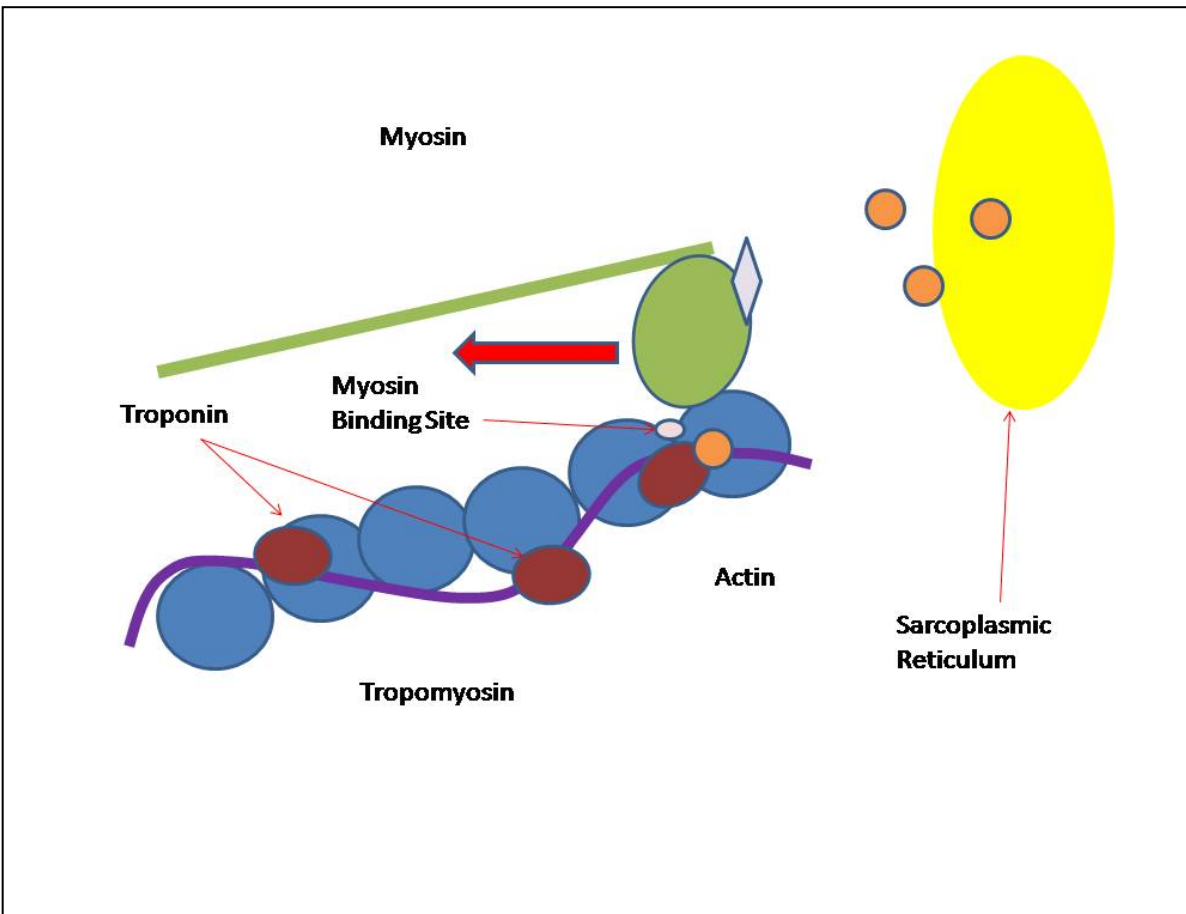


Figure 10.14. Muscle Contraction Physiology. Myosin can now bend and pull actin along causing muscle contraction and shortening the sarcomere.

Bruce Forciea

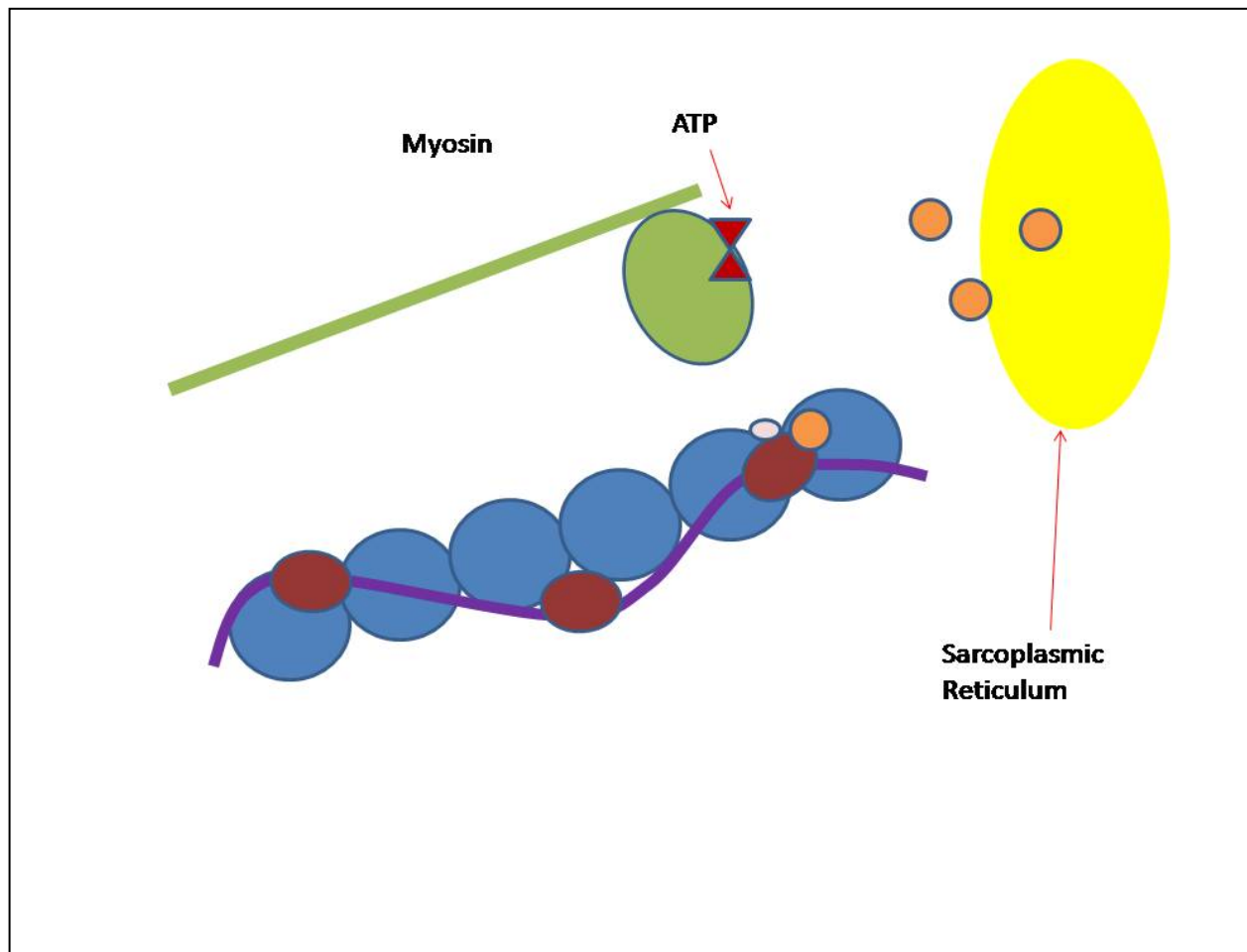


Figure 10.15. Muscle Contraction Physiology. Myosin releases from actin when a second ATP attaches to myosin. Myosin is now available for another cross-bridge formation.

Bruce Forciea

### Muscle Twitch

We can improve our understanding of muscle contraction by examining the contraction of one muscle fiber. A twitch occurs when one muscle fiber contracts in response to a command (stimulus) by the nervous system. The time between the activation of a motor neuron until the muscle contraction occurs is called the lag phase (sometimes called the latent phase). During the lag phase a signal called an action potential moves to the end of the motor neuron (axon terminal). This results in release of acetylcholine and depolarization of the motor end plate. The depolarization results in the release of calcium by the sarcoplasmic reticulum and subsequent binding of calcium to troponin which causes the myosin binding site to be exposed (fig. 10.16).

This is followed by the actual muscle contraction that develops tension in the muscle. This next phase is called the contraction phase. During the contraction phase the cross-bridges between actin and myosin form. Myosin moves actin, releases and reforms cross-bridges many times as the sarcomere shortens and the muscle contracts. ATP is used during this phase and energy is released as heat.



When the muscle relaxes the tension decreases. This phase is called the relaxation phase. During this phase calcium is actively transported back into the sarcoplasmic reticulum using ATP. The troponin moves back into position blocking the myosin binding site on the actin and the muscle passively lengthens.

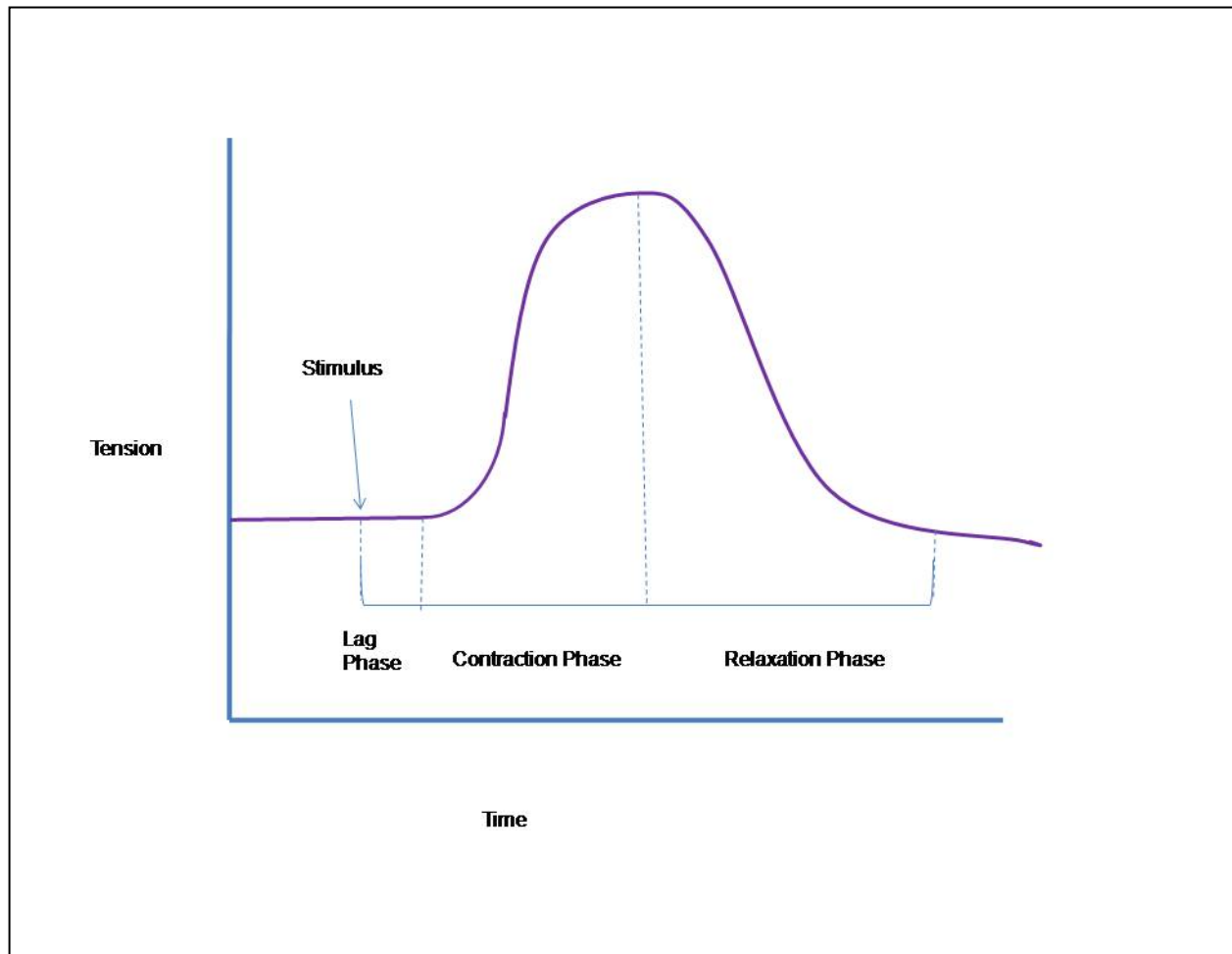


Figure 10.16. Muscle Twitch Phases.

Bruce Forciea

## **Muscle Stimulus and Contraction Strength**

A skeletal muscle fiber will produce a given amount of force if the stimulus is strong enough to reach the threshold for muscle contraction. This is called the all or none law. Let's say that we are electrically stimulating a muscle fiber. We begin with a low amount of stimulation that does not reach the threshold to produce a contraction. The muscle fiber will respond by remaining relaxed, it will not contract. Now if we increase the stimulation so that enough is produced to reach the threshold the muscle fiber will respond by contracting. Finally if we continue to increase the stimulus so that it well exceeds the threshold the fiber will respond by contracting with the same force as when we just reached the stimulus. The muscle will not contract with greater force if the stimulus is greater. The muscle responds to stronger stimuli by producing the same force.

In skeletal muscles a motor neuron can innervate many muscle fibers. This is called a motor unit. There are numerous motor units throughout skeletal muscles. Motor units act in a coordinated fashion. One stimulus will affect all of the muscle fibers innervated by a given motor unit.

Whole muscles containing many motor units can contract with different amounts of force. More motor units are recruited to increase the force of contraction when needed. This phenomenon is called summation. In other words increasing numbers of motor units are activated in order to increase the muscle's force of contraction.

Let's look at an example. Let's say that I am helping a friend move to a new house. I am holding an empty box while my friend fills it up with various items. The weight of the box or "load" is increasing. My biceps muscles must respond by increasing their force of contraction so that I will avoid dropping the box. As the load increases more motor units are recruited and the force of contraction increases to accommodate the load.

Nerves contain many axons of neurons that innervate many motor units. If a nerve is stimulated to produce a stimulus that is below the threshold, no action potential is generated in the neurons and there is no muscle contraction. This is called a subthreshold stimulus. If the stimulus is strong enough to produce an action potential we say that the stimulus is a threshold stimulus. As the stimulus increases more motor units are recruited. We call this stimulus a submaximal stimulus. When the stimulus is strong enough to cause activation of all of the motor units associated with the nerve we say that the stimulus is a maximal stimulus. A stimulus greater than a maximal stimulus (supramaximal stimulus) will not have any additional effect on the motor units.

The ratio of neurons to muscle fibers differs in various muscles. Muscles involved in more precise movements such as in the hands have a smaller ratio of neurons to muscle fibers whereas muscles involved in gross movements such as the muscles in the thigh have a higher number of fibers innervated by one neuron.

## **Muscle Contraction Frequency**

When a muscle is stimulated by an action potential it will contract. The time it takes for an action potential to occur is much shorter than the time it takes to contract a muscle. This means that another action potential can produce another contraction. As the frequency of action potentials increases the frequency of muscle contraction also increases. There is a maximal frequency of action potentials that will cause a sustained contraction of a muscle. We call this phenomenon tetanus. Muscles in tetanus will not demonstrate even a partial relaxation. The tension produced by muscles increases along with the frequency of stimulation by action potentials. This phenomenon is known as multiple-wave summation.

During muscle contraction calcium is released by the sarcoplasmic reticulum in response to depolarization of the sarcolemma. If a high frequency of action potentials is administered to the muscle the calcium levels inside the cell remain high and the muscle responds by remaining in a contracted state. This allows for more cross-bridge formation and subsequent increase in tension of the muscle.

If a muscle is stimulated by an action potential and then allowed to relax, the next stimulus will produce a stronger contraction. This will continue for a few contractions then the strength of contraction will level out. This phenomenon is called treppe.

### **Muscle Length-Tension Relationship**

The length of a muscle is related to the tension generated by the muscle. Muscles will generate more force when stretched beyond their resting length to a point. Muscles stretched beyond this point will produce less tension.

If the muscle is at its resting length it will not produce maximal tension because the actin and myosin filaments excessively overlap. Myosin filaments can extend into the Z-discs and both filaments interfere with each other limiting the number of cross-bridges that can form.

If the muscle is stretched to a point the tension will increase in the muscle. The actin and myosin filaments can now optimally overlap so that the greatest number of cross-bridges can form.

If the muscle is overstretched the tension will decrease. The actin and myosin filaments do not overlap causing a decrease in the number of cross-bridges that can form.

### **Types of Muscle Fibers**

There are three major types of skeletal muscle fibers. These are called fast twitch, slow twitch and intermediate.

Generally, fast twitch fibers generate high force for brief periods of time. Slow twitch fibers generate lower amounts of force but can do so for longer periods of time. Intermediate fibers have some characteristics of both fast and slow twitch fibers. Fast twitch fibers are also called Type II fibers.

Fast twitch fibers are the predominant fibers in the body. They respond quickly to stimuli and can generate a good deal of force. They have a large diameter due to the large amount of myofibrils. Their activity is fueled by ATP generated from anaerobic metabolism.

Slow twitch fibers respond much more slowly to stimuli than fast twitch fibers. They are smaller in diameter and contain a large number of mitochondria. They are capable of sustaining long contractions and obtain their ATP from aerobic metabolism.

Slow twitch fibers are surrounded by capillary networks that supply oxygenated blood for use in the aerobic energy systems. They also contain a red pigment called myoglobin. Myoglobin can bind oxygen (like hemoglobin) and provide a substantial oxygen reserve. Because of the reddish color of myoglobin these fibers are often called red muscle fibers. Slow twitch fibers are also called Type I fibers.

Intermediate fibers resemble fast twitch fibers because they contain small amounts of myoglobin. They also have a capillary network around them and do not fatigue as readily as fast twitch fibers. They

contain more mitochondria than fast twitch but not as many as slow twitch fibers. The speed of contraction and endurance also lie between fast and slow twitch fibers. Intermediate fibers are also called Type IIa fibers.

Muscles that have a predominance of slow fibers are sometimes referred to as red muscles such as in the back and areas of the legs. Likewise muscles that have a predominance of fast fibers are referred to as white muscles. It is interesting to note that there are no slow twitch fibers in the eye muscles or muscles of the hands.

The ratio of fast-slow-intermediate fibers is determined genetically. However training can change the ratio of these fibers in skeletal muscles that contain all three types. For example training for endurance can cause some fast twitch fibers to become more like intermediate fibers.

### **Muscles Response to Exercise**

There are three basic ways the muscular system responds to exercise. Let's look at this in the context of Sally who is beginning an exercise program.

Sally is starting an exercise program. She has never been in a gym before and is excited to see the results of her efforts. Part of her program is weight lifting. Her trainer tests her on the first day and finds that she can lift 20 lbs. in a biceps curl. She then begins exercising three times per week. After about two weeks she finds that she can now lift 25 lbs. She is excited about her improvement in just two weeks of training. Sally asks her trainer to measure her biceps and they find that there is no difference in size. If the muscle size has not changed, then what is responsible for Sally's increase in strength?

One of the first ways muscles respond to training is to increase synchronous contraction of motor units. When motor units contract at different points in time (asynchronous contraction) then they cannot generate as much force as when they contract together. Training increases synchronous contraction so that the motor units work together to generate higher amounts of force.

Sally continues her program and finds that after about 8-10 weeks there is some increase in her biceps circumference. This is primarily due to hypertrophy or an increase in the cross-sectional diameter of muscles fibers. The number of muscle fibers does not change but the size of the fibers increases. The number of protein filaments, mitochondria, enzymes, and glycogen reserves increases.

Sally may also experience some small amount of hyperplasia. Hyperplasia is an increase in the number of muscle fibers resulting from mitosis. The increase is slight as most of the increase in size is attributed to hypertrophy.

### **Cardiac Muscle**

Cardiac muscle is only found in the heart. Like skeletal muscle it has a high concentration of myofilaments and is striated. However, there are also a number of structural differences between skeletal and cardiac muscle.

Cardiac muscles are smaller and generally contain one nucleus whereas skeletal muscles are multinucleated. They have a different arrangement of T-tubules and no triads. The sarcoplasmic reticulum does not have a terminal cisternae. Cardiac muscle fibers are powered by aerobic metabolism and contain energy reserves in the form of glycogen and lipids. Cardiac muscle cells contain large numbers of mitochondria to utilize aerobic energy systems.

Cardiac muscle cells also contain a specialized kind of cell junctions called intercalated discs that allow the flow of chemicals between cells and help to maintain the structure of the muscle. This allows for a greater transmission of electrical signals across large areas of cardiac muscles. The discs also allow adjacent fibers to pull together in a more coordinated contraction. Instead of motor units working separately in skeletal muscle, intercalated discs allow cardiac muscle to contract in large uniform segments.

Cardiac muscle can also contract without a stimulus from the nervous system. Cardiac muscle contains self-generating action potential cells called pacemaker cells or nodes. The pacemaker cells however can respond to the nervous system by changing the rate and force of contraction of cardiac muscle cells.

Cardiac muscle cannot undergo tetanic contractions due to the structure of the cell membrane.

### **Smooth Muscle**

Smooth muscle cells are found throughout the body in organs, blood vessels and tubelike structures. Smooth muscles contain actin and myosin and are long spindle shaped cells. Actin and myosin are not arranged in sarcomeres so smooth muscle is not striated. Instead the actin and myosin are scattered about throughout the muscle. Smooth muscle has no T-tubules and the myosin has a larger number of globular protein heads.

Smooth muscle contraction differs from skeletal or cardiac contraction in that when calcium is released by the sarcoplasmic reticulum it binds with a calcium-binding protein called calmodulin that activates an enzyme called myosin light chain kinase. This enzyme allows for the formation of cross-bridges. Because of the structure of smooth muscle, length and tension are not related. When smooth muscle is stretched it adapts to its new resting length and can continue to contract.

Smooth muscle cells are classified as multiunit or visceral. Multiunit smooth muscle is organized into motor units that are innervated by the nervous system. However, each cell can be connected to more than one motor unit. Visceral cells do not connect directly with motor neurons and are arranged in layers. Gap junctions connect layers of smooth muscle so that one area can influence others when contracting. This can produce a wave-like contraction called peristalsis.

## Chapter 10 Review Questions

1. Which of the following consists of a connective tissue layer that covers the entire muscle:
  - a. Fascicle
  - b. Epimysium
  - c. Endomysium
  - d. Perimysium
  
2. The “thick” filament in muscle is known as:
  - a. Actin
  - b. Myosin
  - c. Troponin
  - d. Tropomyosin
  
3. The troponin-tropomyosin complex covers\_\_\_\_\_ on the actin.
  - a. Sarcolemma
  - b. Sarcoplasmic reticulum
  - c. Calcium
  - d. Myosin binding site
  
4. Which of the following binds to the troponin-tropomyosin complex causing a conformational change:
  - a. Potassium
  - b. Calcium
  - c. Sodium
  - d. Magnesium
  
5. Which neurotransmitter is released by the axon terminal and propagates to the motor end plate:
  - a. Dopamine
  - b. Acetylcholine
  - c. Norepinephrine
  - d. Serotonin
  
6. Which of the following consists of thin threads that hold the myosin in place:
  - a. Actin fibers
  - b. Troponin
  - c. Titin protein
  - d. Tropomyosin

7. A sarcomere extends from \_\_\_\_ to \_\_\_\_:
- a. Z-line, Z-line
  - b. I-band, I band
  - c. A-band, I-Band
  - d. I-band, H-zone
8. Which of the following electrolytes is responsible for depolarization of the motor end plate:
- a. Sodium
  - b. Potassium
  - c. Calcium
  - d. Magnesium
9. Increasing the stimulation to a muscle fiber until it contracts is known as:
- a. Fiber contraction hypothesis
  - b. Sliding filament theory
  - c. All or none law
  - d. Invoked potential law
10. A motor neuron and all of the muscle fibers it innervates is called:
- a. Motor unit
  - b. Contractile element
  - c. Sarcomere
  - d. A-band contraction
11. Which type of muscle fiber would be working harder in a marathon runner:
- a. Slow twitch
  - b. Fast twitch
  - c. Intermediate
  - d. Secondary
12. Which of the following is the first muscular response to exercise:
- a. Hypertrophy
  - b. Atrophy
  - c. Hyperplasia
  - d. Synchronous contraction of motor units

13. Which type of muscle can perform a contraction known as peristalsis:
- a. Cardiac
  - b. Skeletal
  - c. Smooth
  - d. All can perform this contraction



# Chapter 11

## Nervous System Anatomy

## Nervous System Anatomy

In this chapter we will begin to discover one of the most complex systems in your body. The nervous system consists of a vast interconnection of cells. In fact, your brain has on the order of one hundred billion neurons. Each of these can connect with up to 10,000 other neurons. This means the total number of connections can exceed the known number of particles in the universe. No wonder some people spend their lives studying the complexities of the nervous system.

We will begin by looking at some gross structure of the nervous system. Then we will look at a bit more detail. The next chapter will cover some physiology.

### The Big Picture

The nervous system is divided into two large units (fig. 11.1). The central nervous system consists of the brain and spinal cord. The peripheral nervous system consists of nerves and a group of neurons known as the autonomic nervous system.

We can understand a good deal of how the nervous system works by examining how information flows through it. Let's say that I have reached for a hot cup of coffee and have moved it slightly, spilling coffee on my hand. I must make the decision to let go of the cup and move my hand away.

The sensation of touch, heat and pain are first processed by sensory receptors located in my skin. All sensory receptors take information from the environment and convert it into a form that can be processed by the nervous system. The environment can be internal (inside the body) or external (outside the body). The information going into the receptor can be in many forms. For example light rays enter the eye, sound waves enter the ear, pressure is sensed by receptors that are deformed by either light or heavy pressure in the skin. Heat is also sensed by temperature receptors in the skin. The information coming out of the receptor is in the form of electrochemical impulses called action potentials (more about these later).

The impulses from the sensory receptor then travel to the central nervous system via afferent pathways. These pathways generally consist of sensory nerves that attach to the receptors. The pathway continues to the spinal cord which is part of the central nervous system.

The impulse then travels upward toward the brain via a special pathway in the spinal cord called a spinal tract. Since the tract travels upward to the brain it is called an ascending tract. The impulse then travels to the brain where the sensation of pressure and heat are processed. A decision is made in the brain to move the muscles of my arm and hand to let go of the cup. The impulse is now a motor impulse and it travels down the spinal cord following a spinal tract (this time a descending tract) and moves along an efferent (away from) pathway consisting of a motor nerve(s) to the muscles of my hand and arm. My hand lets go of the cup and moves away.

We can think of the nervous system then in terms of stimulus (hot coffee) and response (move hand). Many nervous system functions occur this way. But before we go deeper into how the nervous system works we need to examine some structures.

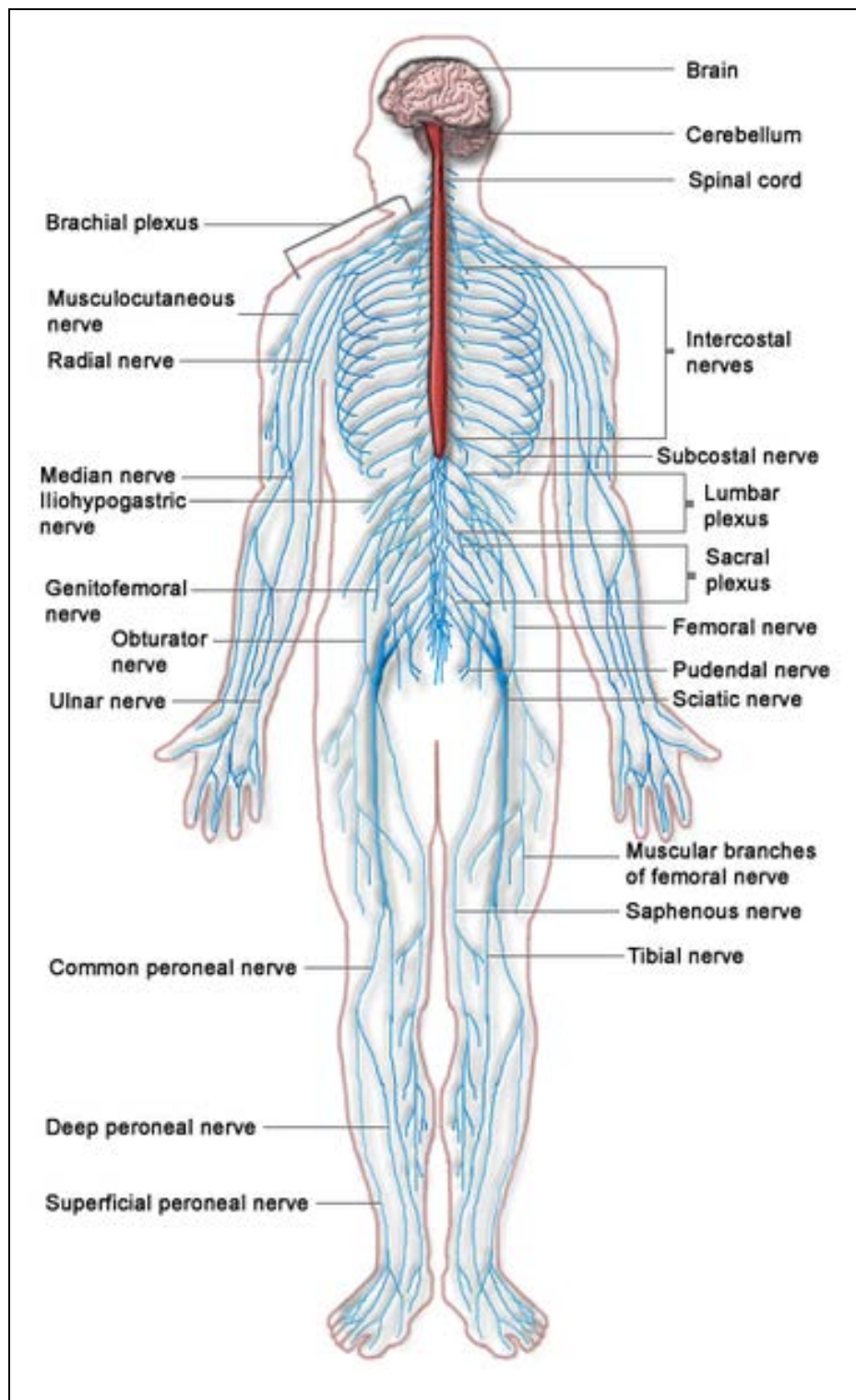


Figure 11.1. The nervous system.

[http://commons.wikimedia.org/wiki/File:Nervous\\_system\\_diagram.png](http://commons.wikimedia.org/wiki/File:Nervous_system_diagram.png)

## Gross Structure of the Spinal Cord

The spinal cord begins at the foramen magnum of the occipital bone and extends to the second lumbar vertebra. It ends in a cone-like structure called the conus medullaris (fig. 11.2). A structure known as the cauda equina extends from the inferior end of the spinal cord. The cauda equina (horse's tail) consists of nerves that extend downward to exit the foramen of the lumbar and sacral vertebrae (fig. 11.3). The spinal cord consists of cervical, thoracic, lumbar and sacral segments.

The spinal cord is also thicker in the cervical and lumbar areas. These areas are called the cervical and lumbar enlargements. The cord is thicker due to the larger numbers of nerves accommodating the upper and lower extremities. The spinal cord is anchored in place inferiorly by a thin ligament called the filum terminale that extends from the conus medullaris to the sacrum.

The spinal cord is covered by a connective tissue covering called the meninges (fig. 11.4). The meninges also cover the brain. The meninges consist of three layers. The dura mater is the most superficial layer. It forms a sac known as the thecal sac that encases the spinal cord. The thecal sac extends from the foramen magnum to the second sacral vertebra and is continuous with the brain.

The space between the dura mater and the vertebrae is called the epidural space. Anesthetics are sometimes injected into this space (epidural injection).

The middle layer of the meninges is known as the arachnoid mater. This is a thin layer consisting of simple squamous epithelium. The arachnoid mater adheres to the inner portion of the dura mater.

The pia mater is the innermost membrane. It is closely attached to the spinal cord as a thin membrane. It continues inferiorly to produce the filum terminale. The pia mater also extends laterally to the dura mater at points along the spine to produce the dentate ligaments. These tiny ligaments work to anchor the cord in place.

The space between the arachnoid and pia mater is known as the subarachnoid space. This space is filled with cerebral spinal fluid.

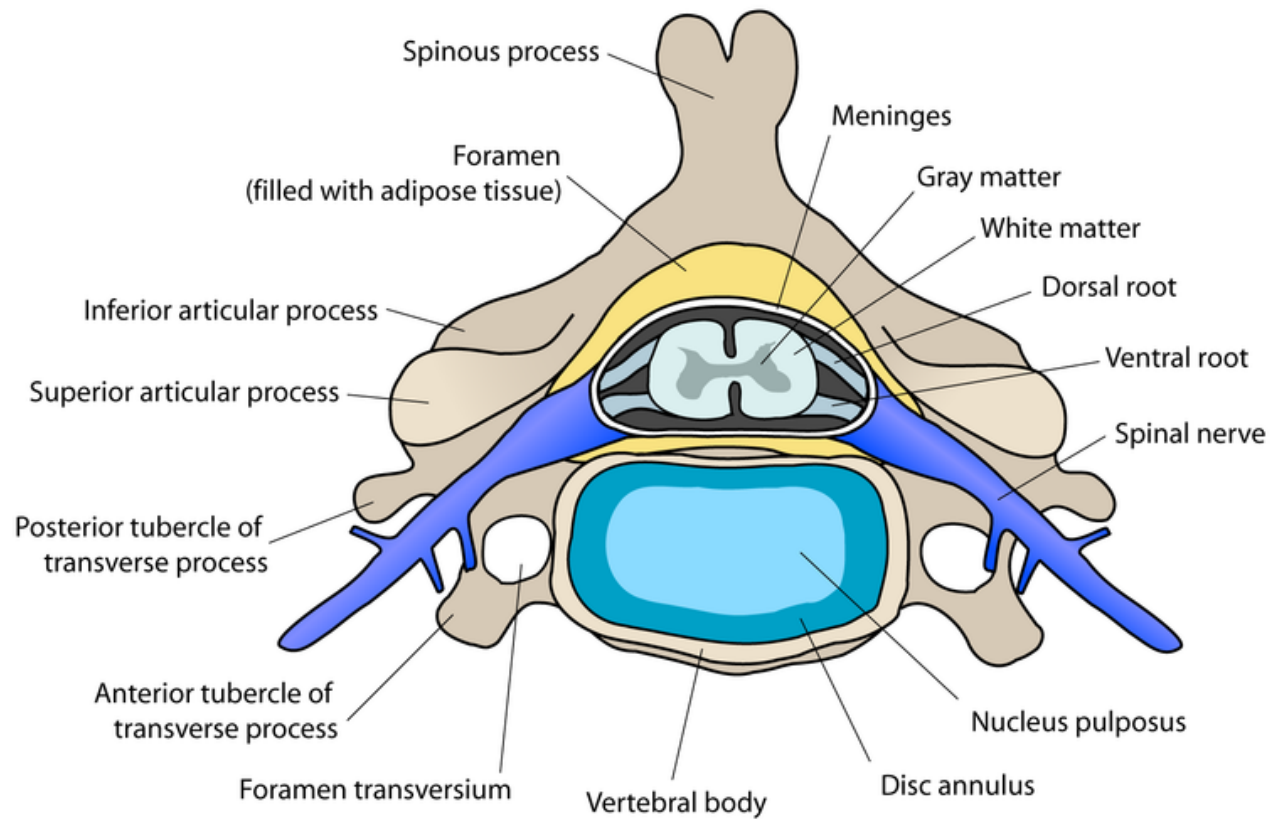


Figure 11.2. Spinal cord anatomy.

[http://commons.wikimedia.org/wiki/File:Cervical\\_vertebra\\_english.png](http://commons.wikimedia.org/wiki/File:Cervical_vertebra_english.png)

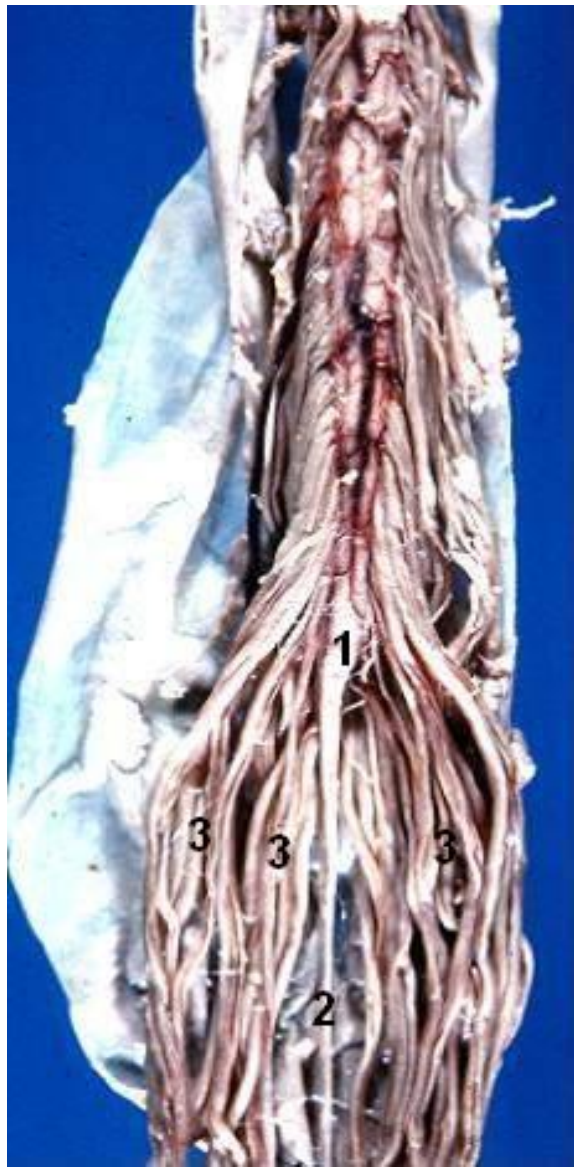

Figure 11.3. The cauda equina consists of nerves that travel inferiorly to exit at the lumbar and sacral vertebrae.

[http://commons.wikimedia.org/wiki/Image:Human\\_caudal\\_spinal\\_chord\\_anterior\\_view\\_description.JPG](http://commons.wikimedia.org/wiki/Image:Human_caudal_spinal_chord_anterior_view_description.JPG)

Author: John A Beal, PhD

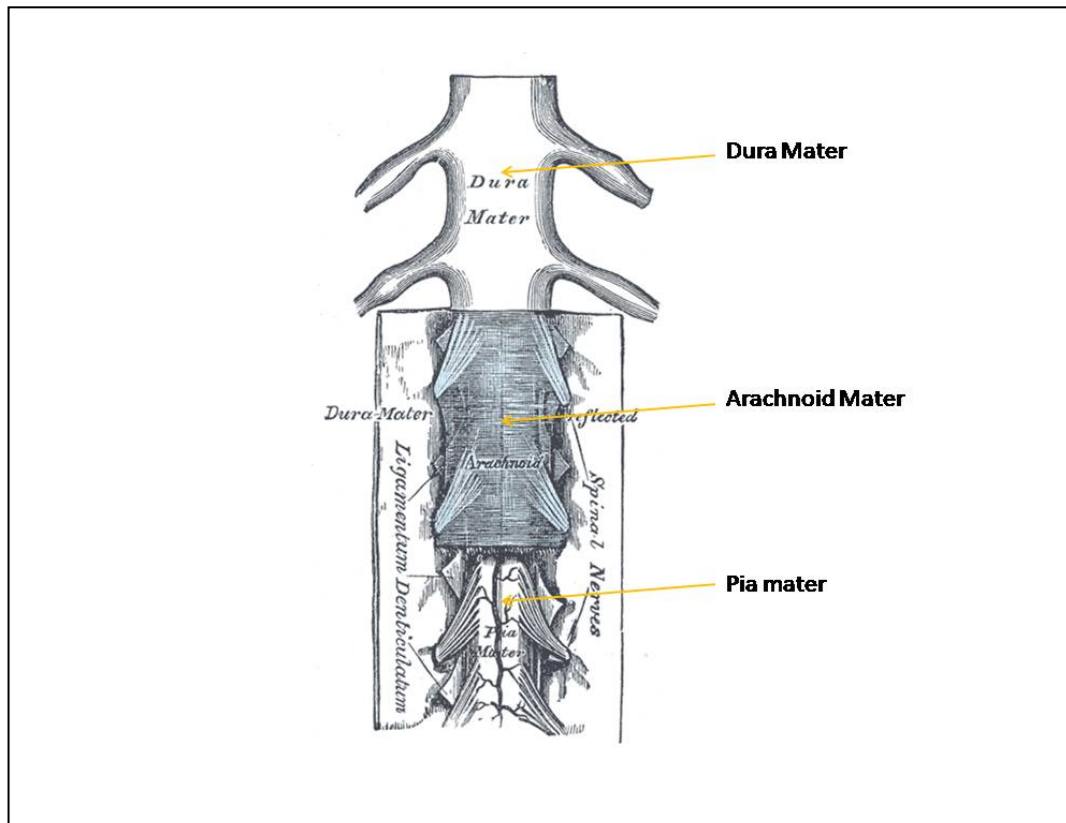


Figure 11.4. Meninges covering spine.

<http://commons.wikimedia.org/wiki/Image:Gray767.png>

The central structure of the spinal cord consists of an area of white matter surrounding a core of gray matter (fig. 11.5). White matter consists of myelinated axons. Myelin is a lipid substance that helps to insulate the axons. The white matter consists of pathways called spinal tracts that carry information to and from the brain. The gray matter contains unmyelinated axons as well as other parts of neurons giving it a darker color. In the center of the gray matter is the central canal. This long tubular structure carries CSF and is typically closed in many areas of the adult spinal cord.

The white matter is divided into areas called funiculi. There are posterior, anterior and two lateral funiculi. The funiculi contain the ascending and descending spinal tracts that carry information to and from the brain.

The gray matter is divided into horns. There are anterior, posterior and two small lateral horns. Like the white matter, the gray matter is symmetrically distributed on the right and left sides of the cord. The right and left sides of the gray matter are connected by the gray commissure.

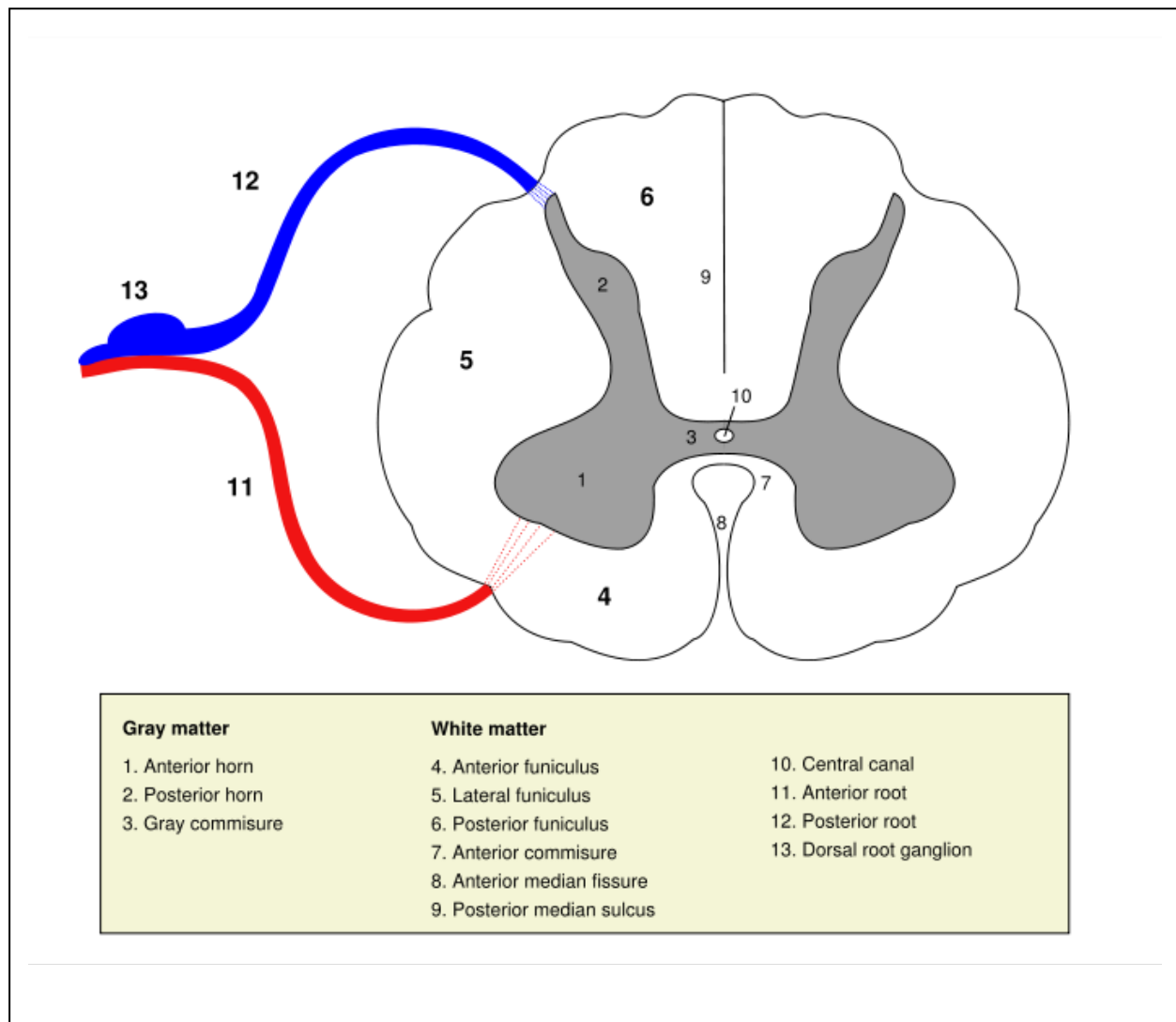


Figure 11.5. Transverse section of spinal cord.

[http://commons.wikimedia.org/wiki/Image:Medulla\\_spinalis\\_-\\_Section\\_-\\_English.svg](http://commons.wikimedia.org/wiki/Image:Medulla_spinalis_-_Section_-_English.svg)

## Spinal Cord Tracts

One major function of the spinal cord is to carry information to and from the brain (fig. 11.6). This information is carried by areas in the white matter called spinal tracts. Sensory information is carried to the brain by ascending tracts and motor information is carried from the brain by descending spinal tracts. Some tracts cross over (decussate—undergo decussation) to the contralateral side. The right side of the brain processes sensory information and sends motor information to the left side of the body and vice versa.



## Important Tracts

Some important ascending tracts include the fasciculus gracilis, fasciculus cuneatus, spinothalamic and spinocerebellar. There are generally three neurons that carry information from the stimulus to the brain. The first-order neuron carries information from the sensory receptor to the spinal cord. The second-order neuron carries the information to the thalamus and the third-order neuron carries the information to the cortex of the brain.

The fasciculus gracilis is located in the posterior funiculus. This tract carries information related to discriminative touch, visceral pain, vibration, and proprioception. The tract carries this information from the middle thoracic and lower areas of the body. The fasciculus gracilis is part of the posterior spinal cord called the dorsal column. At the middle thoracic region (about T6) it combines with the fasciculus cuneatus. It contains first order neurons that travel up the ipsilateral side of the cord and cross over at the brainstem in an area known as the medulla oblongata (gracile nucleus).

The fasciculus cuneatus is also located in the posterior funiculus. It carries the same type of information as the fasciculus gracilis from the middle to upper areas of the body (T6 and above). It is also part of the dorsal column and its fibers cross over in the medulla (cuneate nucleus) as well.

The second order fibers of the fasciculus gracilis and cuneatus combine to form the medial lemniscus from the medulla oblongata to the thalamus.

The spinothalamic tract consists of two portions. The anterior spinothalamic and lateral spinothalamics are located in the anterior and lateral funiculi. The spinothalamics are sometimes referred to as the anterolateral system.

The anterior spinothalamic tract carries information related to light touch and pain. Light touch is clinically defined as perceived sensation from stroking an area of the skin without hair. The fibers from the anterior spinothalamic tract cross at one to two segments above their entry point in the spine.

The lateral spinothalamic tract is an important clinical tract because it carries information related to pain and temperature. Its fibers also cross in a similar way to the anterior spinothalamic tract. Lesions of the lateral spinothalamic tract will result in loss of pain and temperature. For example in a Brown-Sequard lesion (sometimes called a hemisection of the spinal cord) there is a contralateral loss of pain and temperature below the level of the lesion as well as a bilateral loss of pain and temperature at the segmental level of the lesion.

The spinocerebellar tract also consists of two portions. The anterior and posterior spinocerebellar tracts are both located in the lateral funiculus. The fibers in the posterior tracts do not cross while the anterior fibers cross at the medulla oblongata. The spinocerebellar tracts carry information related to coordination of muscles from the lower limbs and trunk to the cerebellum.

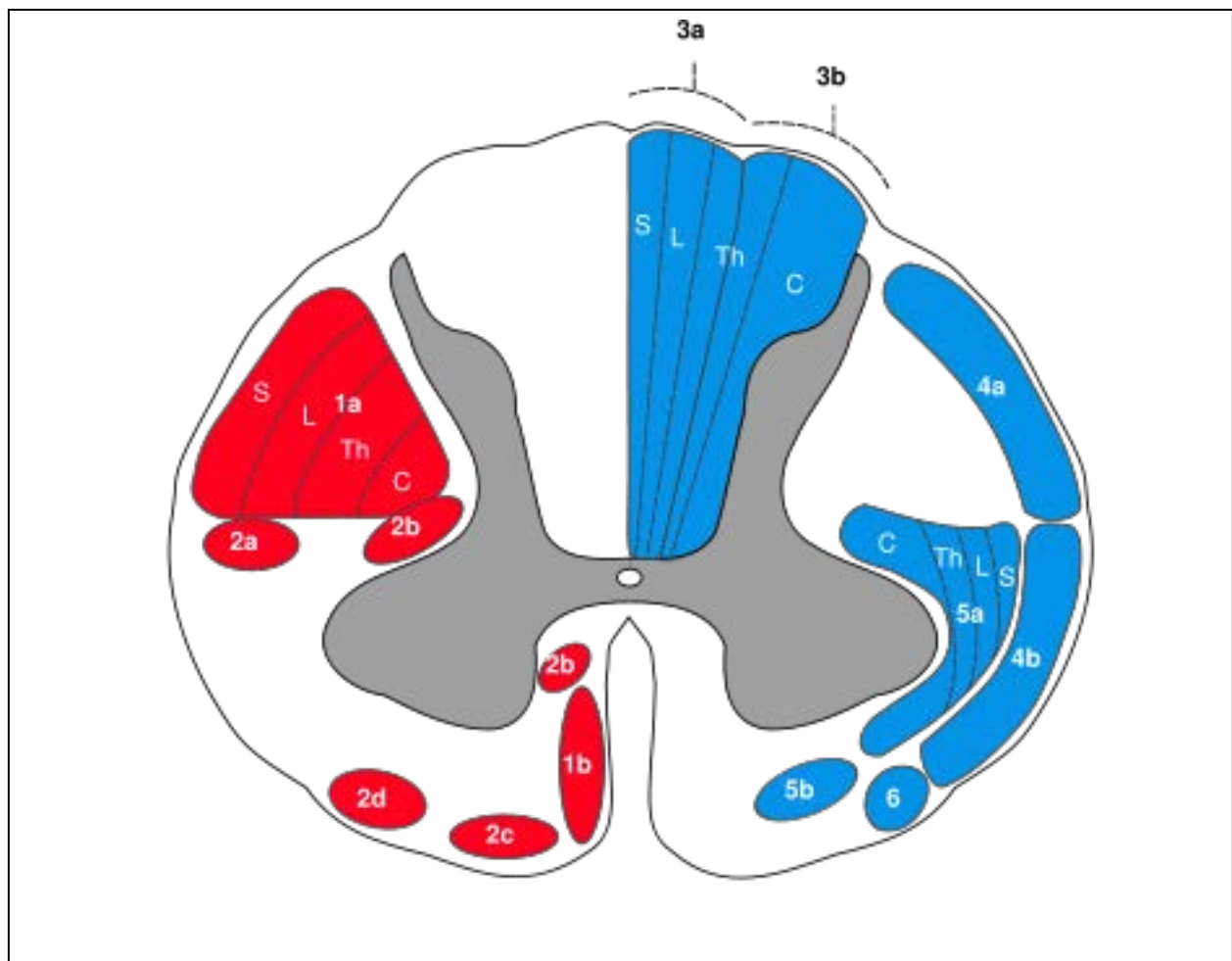


Figure 11.6. Spinal Tracts

**1. Pyramidal**

- 1a. Lateral Corticospinal
- 1b. Anterior Corticospinal

**2. Extrapyramidal**

- 2a. Rubrospinal
- 2b. Reticulospinal
- 3. Dorsal Column
- 3a. Fasciculus Gracilis
- 3b. Fasciculus Cuneatus

**4. Spinocerebellars**

- 4a. Posterior Spinocerebellar
- 4b. Anterior Spinocerebellar

**5. Spinothalamics**

- 5a. Lateral Spinothalamic
- 5b. Anterior Spinothalamic

[http://commons.wikimedia.org/wiki/Image:Medulla\\_spinalis\\_-\\_Querschnitt\\_-\\_Bahnen\\_-\\_German.svg](http://commons.wikimedia.org/wiki/Image:Medulla_spinalis_-_Querschnitt_-_Bahnen_-_German.svg)

Important descending tracts include the corticospinal, reticulospinal and rubrospinal. All of these tracts carry motor information from the brain to the spinal cord.

The corticospinal tract consists of anterior and lateral portions located in the anterior and lateral funiculi. These tracts are sometimes referred to as the pyramidal tracts. Fibers in the lateral tract cross over at the medulla oblongata. Fibers in the anterior portion cross at various levels in the spinal cord. Both tracts convey motor information to skeletal muscles.

The rubrospinal tracts are located in the lateral funiculi. The fibers from these tracts cross over in the brain and descend through the lateral funiculi. The rubrospinal tracts also carry motor information to skeletal muscles. They also carry information about posture and coordination.

The reticulospinal tracts consist of anterior and lateral tracts. They are located in the anterior and lateral funiculi. Some of the fibers cross while others do not. These tracts carry information related to muscular tone and activity of sweat glands.

## **Nerves**

Nerves are bundles of nerve fibers. It is important to realize that since nerves contain numerous fibers some of these fibers can carry sensory information while others carry motor information. Therefore one nerve can carry both sensory and motor information. This type of nerve is known as a mixed nerve. A nerve can also carry sensory information only (sensory nerve) or motor information only (motor nerve)(fig. 11.7).

The outer layer of a nerve consists of the epineurium. The epineurium consists of dense connective tissue that surrounds and protects the nerve. Inside the nerve the fibers are bundled in fascicles with each fascicle surrounded by a sheath called a perineurium. Inside the fascicles are bundles of neurons each surrounded by a thin layer of loose connective tissue called the endoneurium.

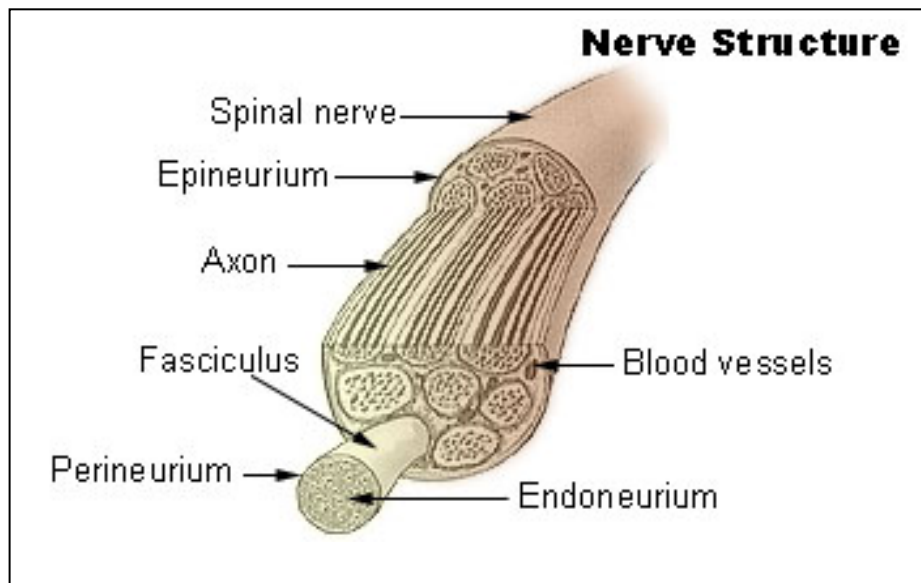


Figure 11.7. Nerve Structure.

[http://commons.wikimedia.org/wiki/Image:Illu\\_nerve\\_structure.jpg](http://commons.wikimedia.org/wiki/Image:Illu_nerve_structure.jpg)

## Spinal Nerves

There are 31 pairs of spinal nerves. They are named after their attachment point in the spine. For example cervical nerves are named C1-C8, thoracic T1-T12, lumbar L1-5, and sacral S1-S5. All spinal nerves are mixed nerves and carry both sensory and motor information (fig. 11.8).

Spinal nerves consist of two nerve roots that exit the spine. The dorsal root carries sensory afferent information and divides into eight small rootlets that enter the spine. Lateral to the rootlets lays a structure called the dorsal root ganglion. A ganglion is a collection of cell bodies. The ventral root consists of six to eight rootlets that exit the spine and combine. The ventral root carries motor information to muscles.

After exiting the spinal canal the spinal nerve forms several branches sometimes called rami. The posterior branch (ramus) innervates the back. It carries sensory information from the central region of the back as well as motor information to the muscles of the spine. The ventral branch (ramus) innervates the sides and anterior trunk. The ventral rami form intercostal nerves that run between the ribs. Some ventral rami form complicated networks of nerves called plexi (plexus). Nerves containing input from several spinal nerves exit a plexus and continue to the skin and muscles of a specific part of the body. The meningeal branch courses back into the spinal canal and innervates the vertebrae, meninges, and spinal ligaments. The visceral branch becomes part of the autonomic nervous system.

Spinal nerves carry sensory information from the surface of the body. Each nerve carries sensation from a specific area of the body called a dermatome (fig. 11.9).

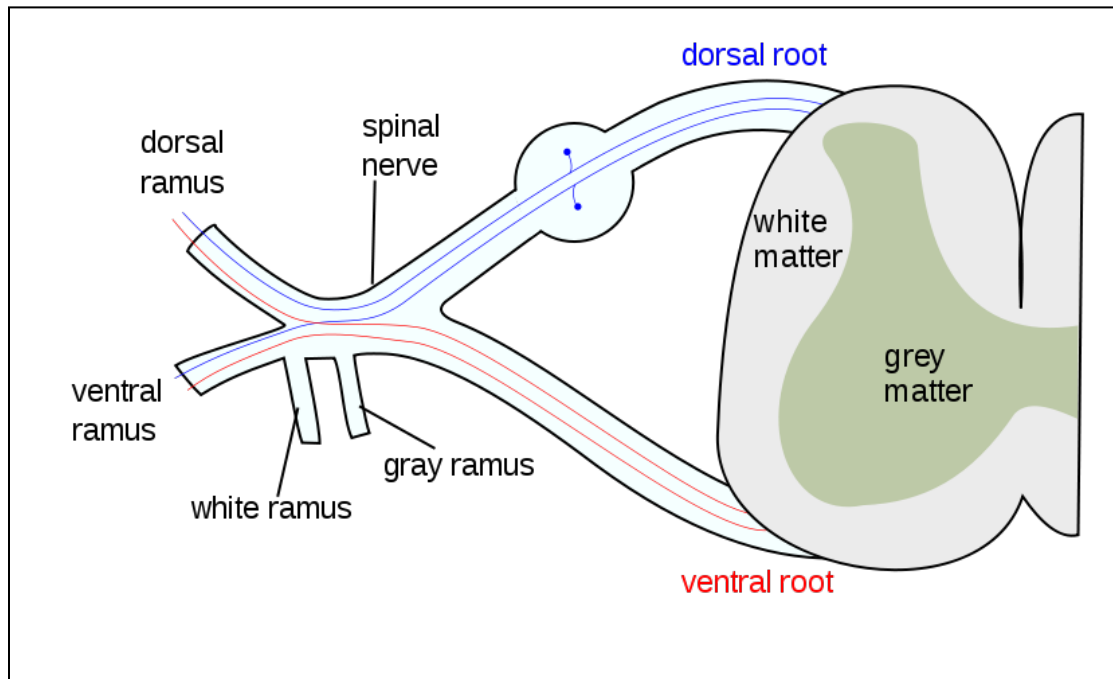


Figure 11.8. Spinal Nerve

[http://commons.wikimedia.org/wiki/Image:Spinal\\_nerve.svg](http://commons.wikimedia.org/wiki/Image:Spinal_nerve.svg)

## Plexi

There are four major plexi in the human body. The cervical plexus (C1-C4)(fig. 11.11) innervates the posterior head and skin of the neck. The phrenic nerve (C3-4-5) emerges from the cervical and brachial plexi and runs through the thorax to innervate the diaphragm.

The brachial plexus (C5-T1) consists of the ventral rami from spinal nerves C5-T1 (fig. 11.10). The rami form three trunks and the trunks become six divisions which again join to form three cords. Five branches emerge from the three cords which constitute the major nerves of the upper extremity. These include the axillary, radial, musculocutaneous, ulnar and median nerves.

The axillary nerve carries sensory information from the shoulder and motor information to the deltoid and teres minor muscles. The radial nerve carries sensory information from the posterior portion of the arm and hand and motor information to the supinator, brachial and extensor muscles of the upper extremity. The musculocutaneous nerve carries sensory information from the forearm and motor information to the anterior muscles of the upper extremity. The ulnar nerve carries sensory information

from the medial two fingers and medial wrist as well as motor information to the hand muscles and the flexor carpi ulnaris and flexor digitorum profundus. The median nerve carries sensory information from the lateral fingers, thumb and wrist as well as motor information to the wrist flexor and thenar muscles.

The lumbar plexus consists of the ventral rami from spinal nerves L1-L4 (fig. 11.12). The sacral plexus consists of the ventral rami from spinal nerves L4-S4. Sometimes both plexi are referred to as the lumbosacral plexus. The major nerves exiting the lumbosacral plexus include the obturator, femoral, and sciatic. The obturator nerve carries sensory information from the medial thigh and motor information to the hip adductor muscles. The femoral nerve carries sensory information from the anterior and lateral thigh and motor information to the iliopsoas, Sartorius, and quadriceps muscles. The sciatic nerve is the largest nerve in the body. It runs down the posterior portion of the leg and splits into two division in the popliteal area (tibial and common peroneal). It carries sensory information from the posterior portion of the leg as well as the anterior and lateral portions of the area below the knee. It carries motor information to the posterior thigh and leg muscles.

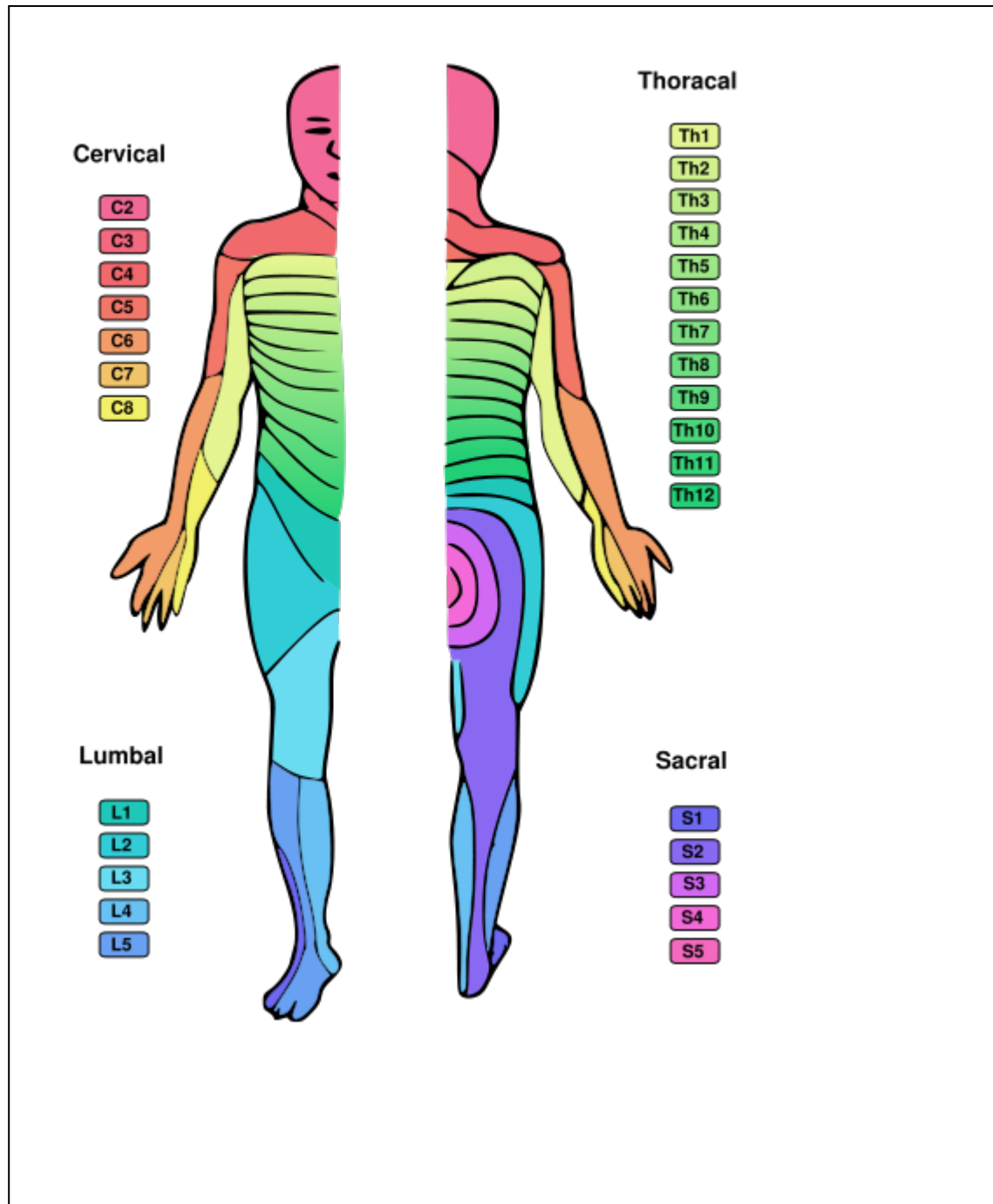


Figure 11.9. Dermatomes are specific areas of the body that carry sensation by spinal nerves.

<http://commons.wikimedia.org/wiki/Image:Dermatomes.svg>

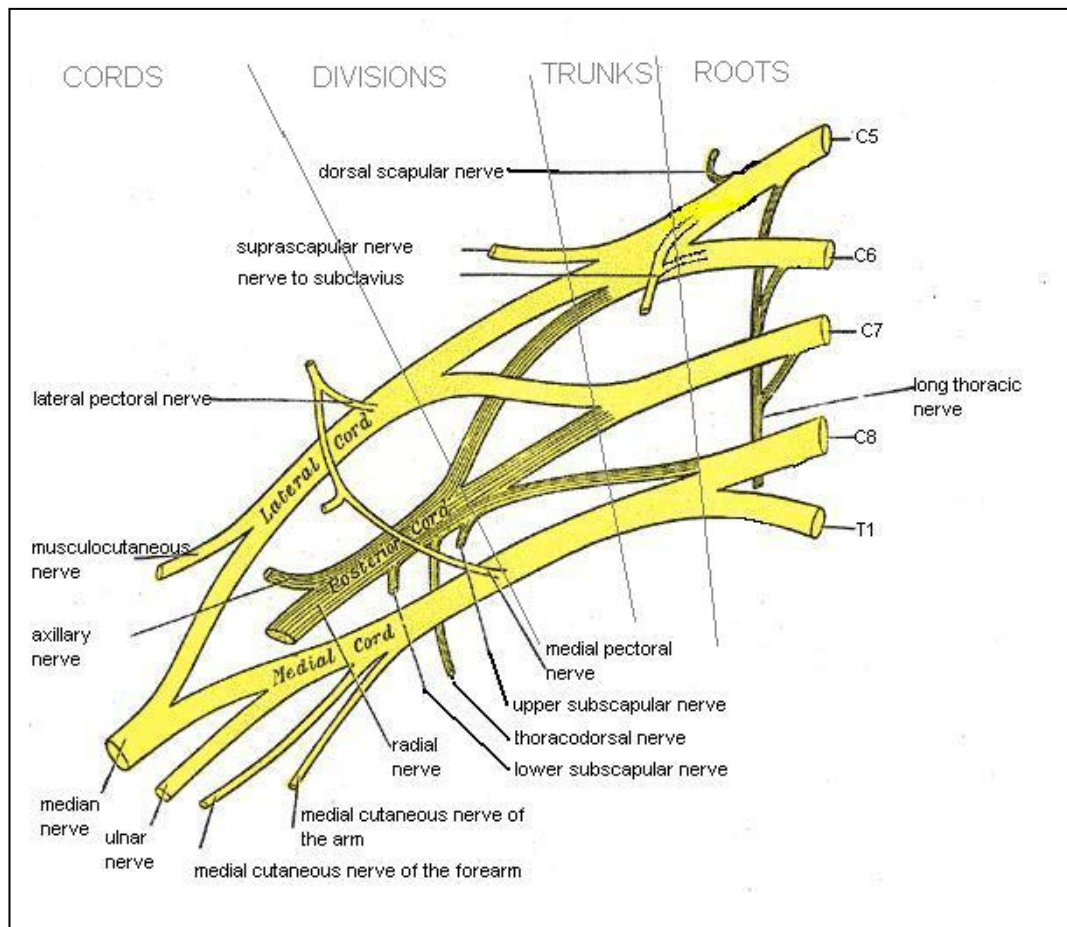


Figure 11.10. Brachial plexus.

[http://commons.wikimedia.org/wiki/Image:Brachial\\_plexus.jpg](http://commons.wikimedia.org/wiki/Image:Brachial_plexus.jpg)



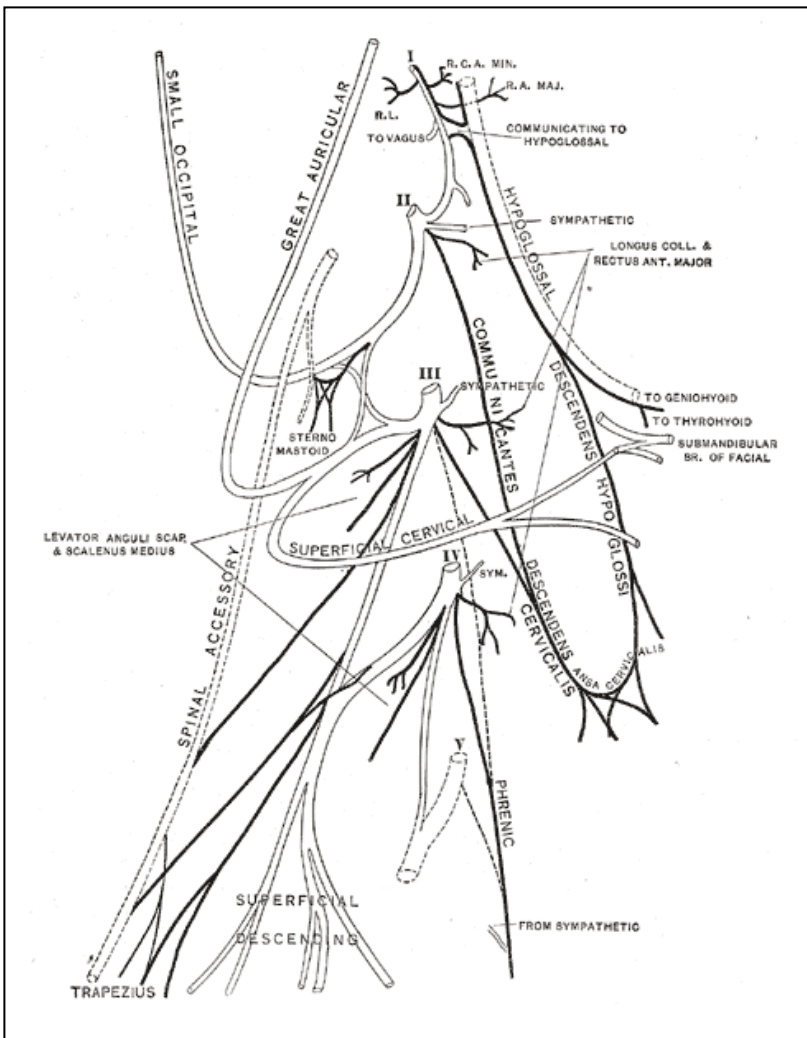


Figure 11.11. Cervical plexus.

<http://commons.wikimedia.org/wiki/Image:Gray804.png>

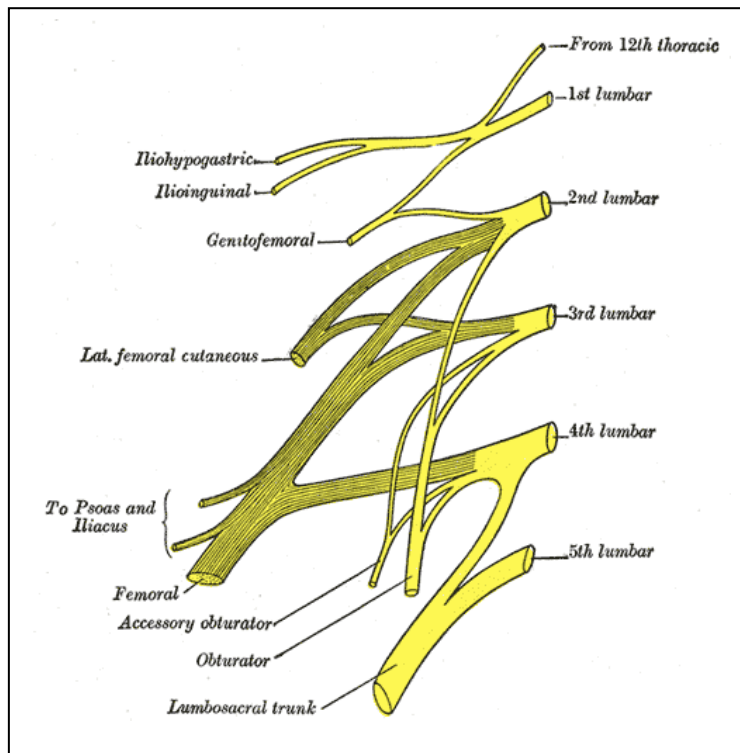


Figure 11.12. Lumbar plexus.

<http://commons.wikimedia.org/wiki/Image:Gray822.png>

## The Brain

The brain consists of four major structures. These include the cerebral cortex, diencephalon, brainstem and cerebellum.

### Fetal Development of the CNS

The central nervous system (CNS) develops from a flat tissue structure called the neural plate (figs. 11.13, 11.14). The neural plate forms neural folds on the lateral sides. The neural folds contain elevated portions called neural crests. At the center of the neural plate lies the neural groove. During fetal development the neural folds move toward each other and meet in the midline forming a neural tube. The superior portion of the neural tube becomes the brain and the inferior portion becomes the spinal cord. The neural crest contains neural crest cells that eventually separate from the neural crest and develop into the autonomic and sensory neurons of the peripheral nervous system. A series of pouch-like structures also develop from the anterior portion of the neural tube. The walls of these structures become parts of the brain while the hollow areas become the ventricles.

The developing brain can be divided into three main regions. These are the forebrain (prosencephalon), midbrain (mesencephalon) and hindbrain (rhombencephalon). The forebrain divides into the telencephalon and diencephalon. The midbrain remains as one structure and the hindbrain divides into the myelencephalon which eventually becomes the medulla oblongata and the pons and cerebellum.

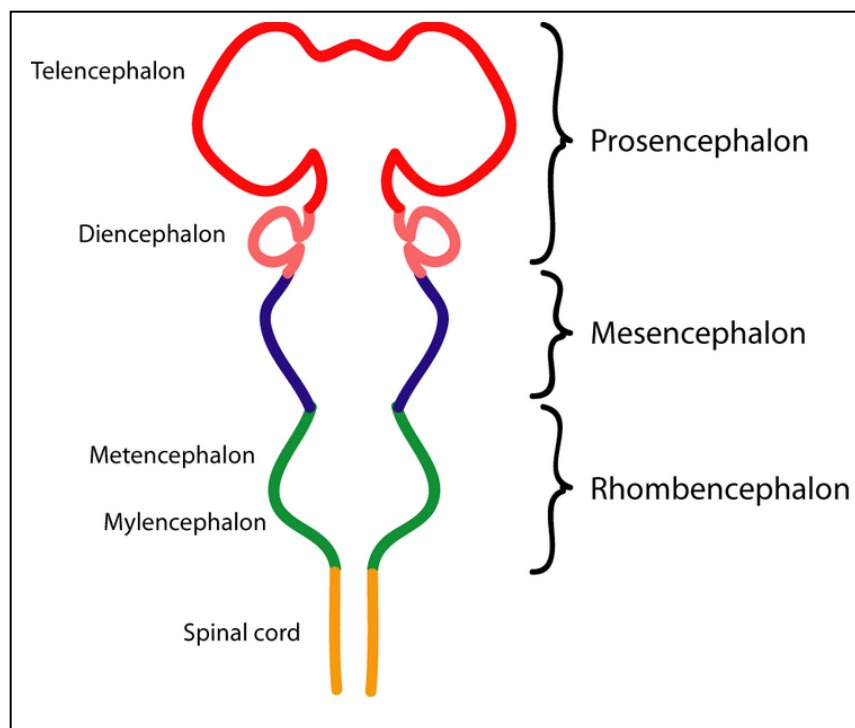


Figure 11.13. Developing CNS

<http://commons.wikimedia.org/wiki/Image:Encephalon.png>

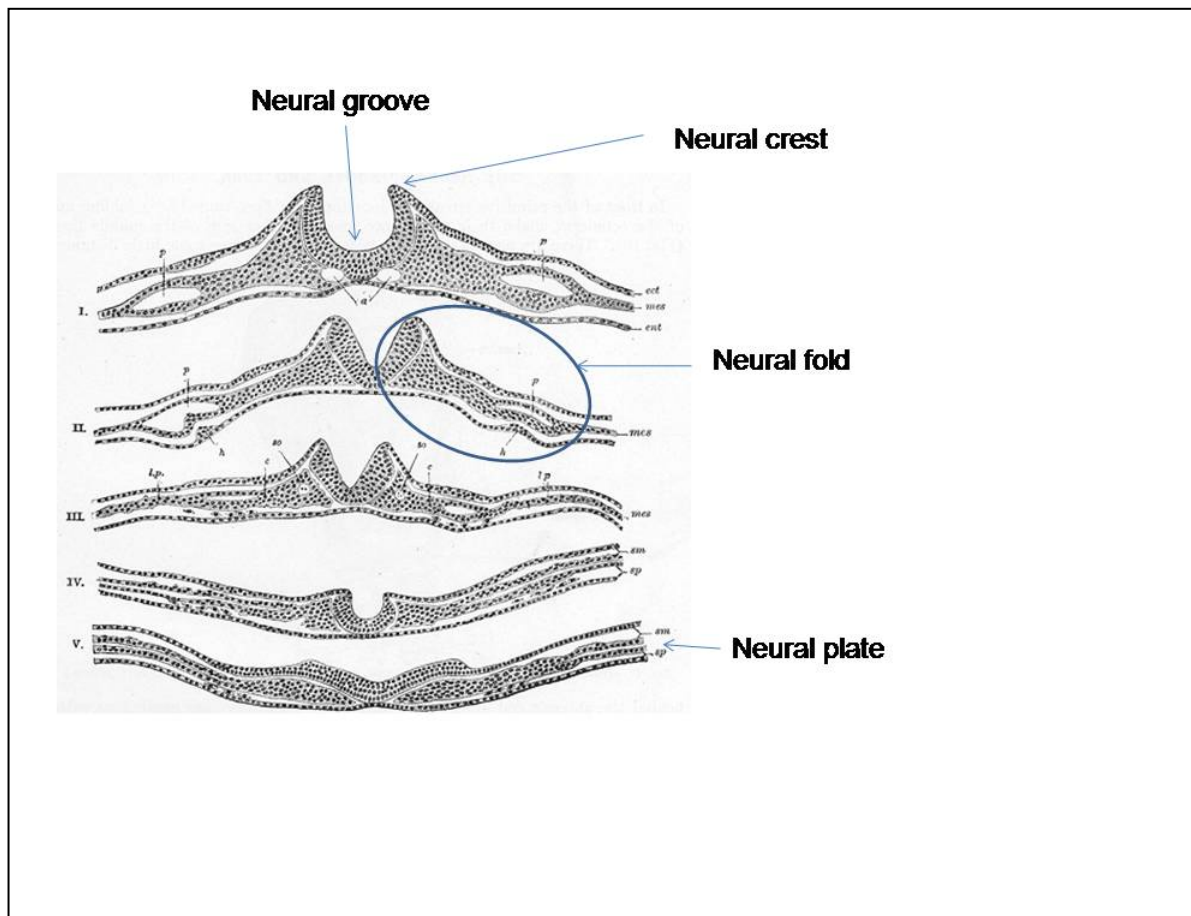


Figure 11.14. The neural plate develops folds that unit in the center to produce the neural tube.

<http://commons.wikimedia.org/wiki/Image:Gray16.png>

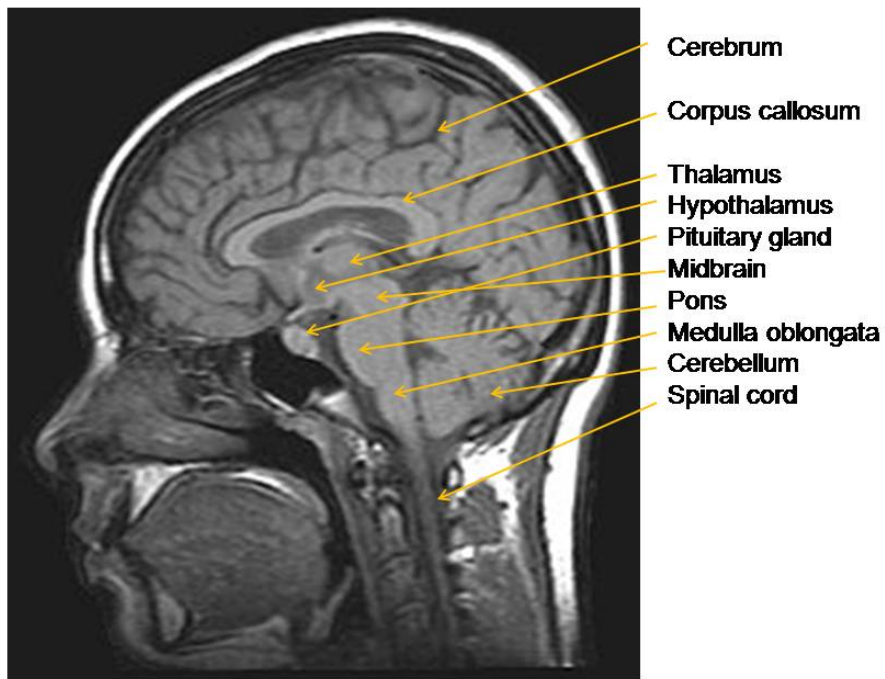


Figure 11.15. MRI of brain.

[http://commons.wikimedia.org/wiki/Image:MRI\\_brain.jpg](http://commons.wikimedia.org/wiki/Image:MRI_brain.jpg)

Courtesy of NASA

## The Brainstem

The brainstem lies between the cerebral cortex and the spinal cord. It consists of the midbrain, pons and medulla oblongata (figs. 11.15, 11.16, 11.17, 11.19, 11.20). The medulla oblongata is the most inferior portion of the brainstem and contains a number of centers for controlling heart rate, respiration, swallowing, vomiting and blood vessel diameter. These centers consist of nuclei which are clusters of neuron cell bodies. The spinal tracts also continue through the medulla connecting the spinal cord with the brain. The medulla contains two rounded structures called olives which consist of nuclei that help to control balance, coordination and sound information. On the anterior surface of the medulla lie two enlargements called pyramids. The pyramids consist of the descending spinal cord tracts.

The pons is the middle section of the brainstem. The pons also contains spinal cord tracts as well as nuclei that help to control respiration and sleep. A number of cranial nerve nuclei are located in the pons (CN V, VI, VII, VIII, IX).

The midbrain is the most superior portion of the brainstem. It contains the nuclei of cranial nerves III, IV, and V. The roof or tectum of the midbrain contains the corpora quadrigemina which consist of four nuclei (fig. 11.18). The two superior nuclei are called the superior colliculi while the inferior are called the inferior colliculi. The superior colliculi help to control the movement of the head toward stimuli including visual, auditory, or touch. The superior colliculi receive input from the eyes. The inferior colliculi help to process hearing and also receive input from the skin and cerebrum. The floor of the midbrain is called the tegmentum. It contains two reddish colored structures called the red nuclei that process information for unconscious motor movements. The midbrain also contains the cerebral peduncles that carry motor information from the cerebrum to the spinal cord. The substantia nigra resides in the midbrain and processes information relating to tone and coordination of muscles.

The reticular formation is located throughout the brainstem and is primarily concerned with regulating sleep-wake cycles.

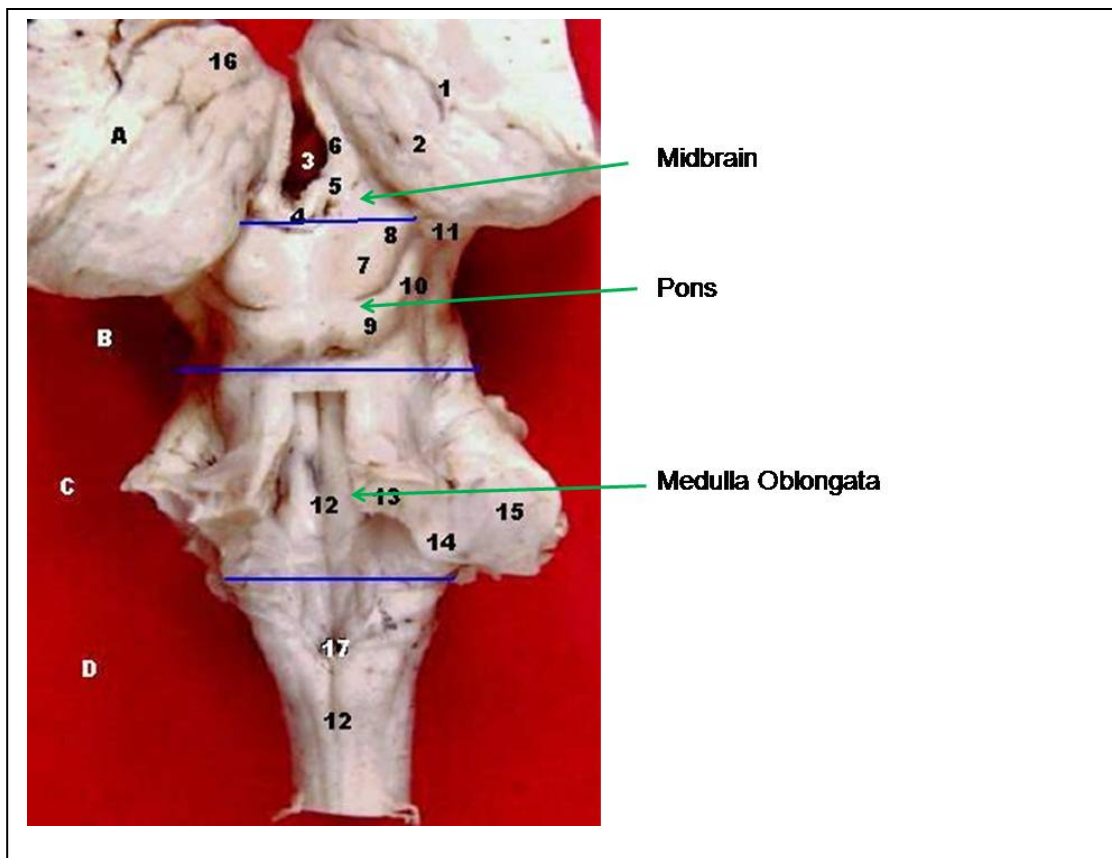
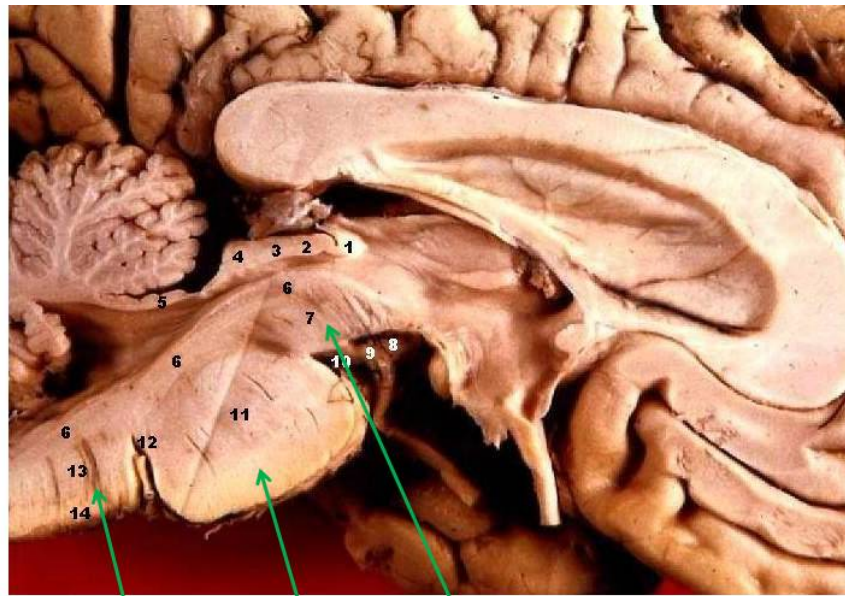


Figure 11.16. Brainstem, posterior view.

[http://commons.wikimedia.org/wiki/Image:Human\\_brainstem-thalamus\\_posterior\\_view\\_description.JPG](http://commons.wikimedia.org/wiki/Image:Human_brainstem-thalamus_posterior_view_description.JPG)

Author: John A Beal, PhD Labelled by Bruce Forciea



**Medulla oblongata**

**Pons**

**Midbrain**

Figure 11.17. Brainstem, lateral view.

[http://commons.wikimedia.org/wiki/Image:Human\\_brain\\_left\\_midsagitttal\\_view\\_closeup\\_description\\_3.JPG](http://commons.wikimedia.org/wiki/Image:Human_brain_left_midsagitttal_view_closeup_description_3.JPG)

John A Beal, PhD Labelled by Bruce Forciea



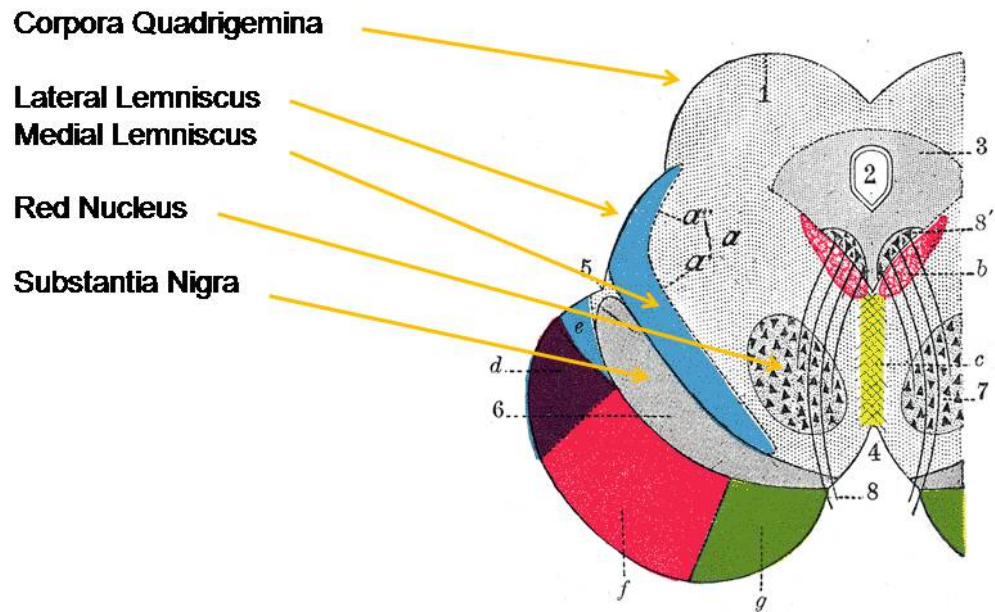


Figure 11.18. Coronal section of brainstem.

<http://commons.wikimedia.org/wiki/Image:Gray710.png>

Labelled by Bruce Forciea

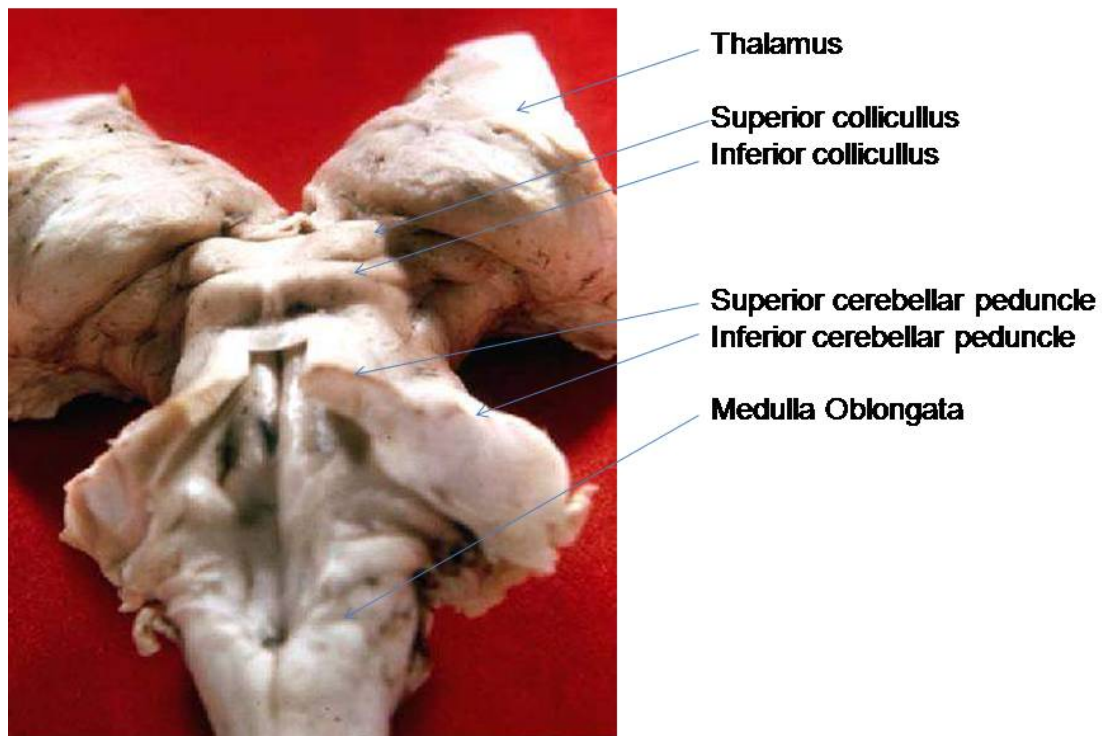


Figure 11.19. Brainstem, posterior view.

[http://commons.wikimedia.org/wiki/Image:Human\\_brainstem-thalamus\\_posterior-inferior\\_view.JPG](http://commons.wikimedia.org/wiki/Image:Human_brainstem-thalamus_posterior-inferior_view.JPG)

John A Beal, PhD Labelled by Bruce Forciea

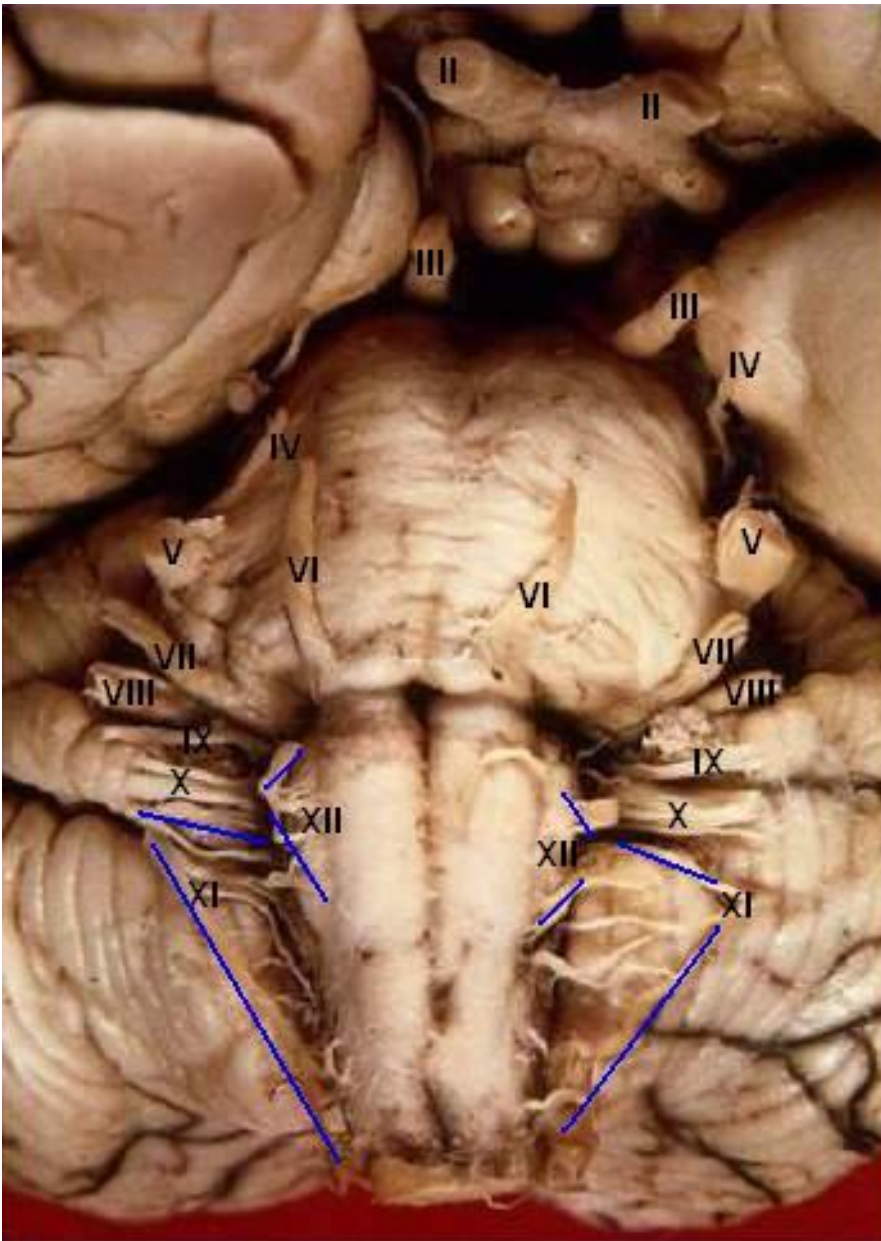


Figure 11.20. Brainstem, anterior view showing locations of cranial nerves.

<http://commons.wikimedia.org/wiki/index.php?title=Special:Search&limit=20&offset=0&ns0=1&ns6=1&ns9=1&ns12=1&ns14=1&redirs=1&search=brainstem>

## The Cerebellum

The cerebellum is located posterior and inferior to the cerebrum (fig. 11.21, 11.22, 11.24). It is connected to the brainstem via three cerebellar peduncles (superior, middle and inferior peduncles). The cerebellum contains both gray and white matter. The white matter branches much like a tree and is called the arbor vitae. The cerebellum contains a number of different types of neurons but one in particular; the Purkinje cell is the largest cell in the brain. These cells have very intricate dendritic networks that can synapse with as many as 200,000 other fibers. Purkinje cells are inhibitory cells and function in processing motor information (fig. 11.23).

The cerebellum can be divided into three parts. The flocculonodular lobe is the inferior portion. The vermis constitutes the middle portion and the two lateral hemispheres make up the remaining portion.

The cerebellum functions in processing information related to complex movements, coordination and unconscious proprioception.

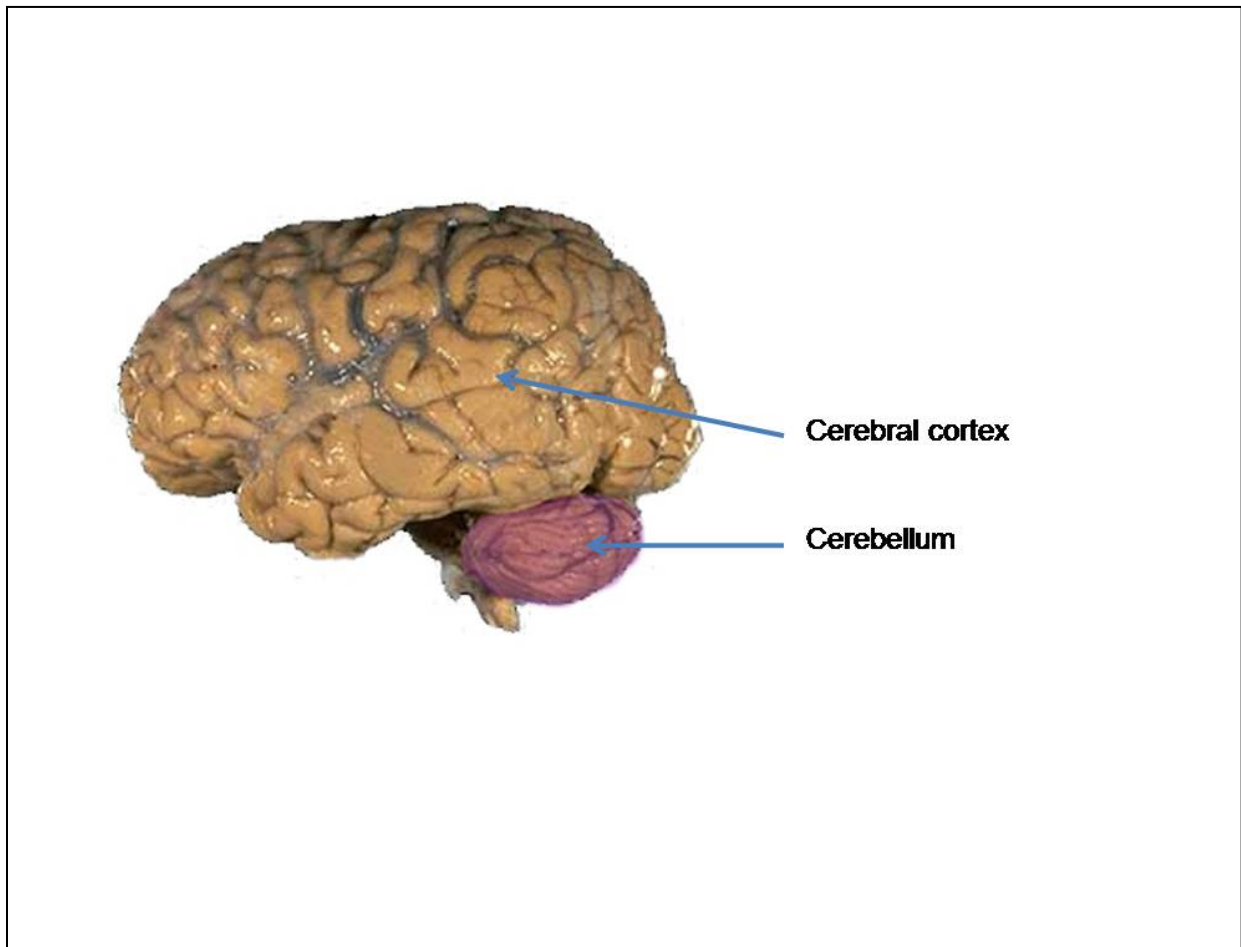
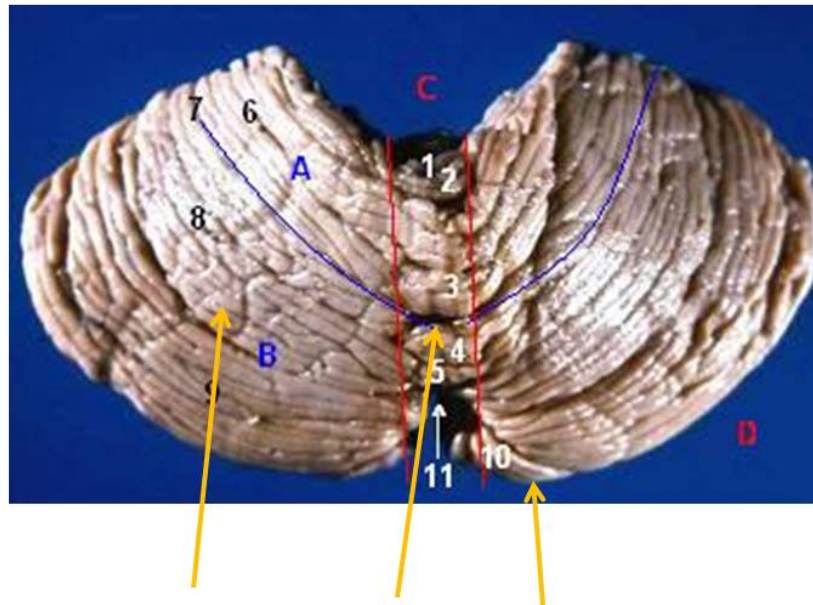


Figure 11.21. The cerebellum lies inferior to the cerebrum.

[http://commons.wikimedia.org/wiki/Image:Cerebellum\\_NIH.png](http://commons.wikimedia.org/wiki/Image:Cerebellum_NIH.png)

Labelled by Bruce Forciea



Lateral hemisphere

Vermis

Flocculonodular node

Figure 11.22. Cerebellum, inferior view.

Modified by Dr. Bruce Forciea from:

[http://commons.wikimedia.org/wiki/Image:Human\\_cerebellum\\_posterior\\_view\\_description.JPG](http://commons.wikimedia.org/wiki/Image:Human_cerebellum_posterior_view_description.JPG)

Original author: John A Beal, PhD



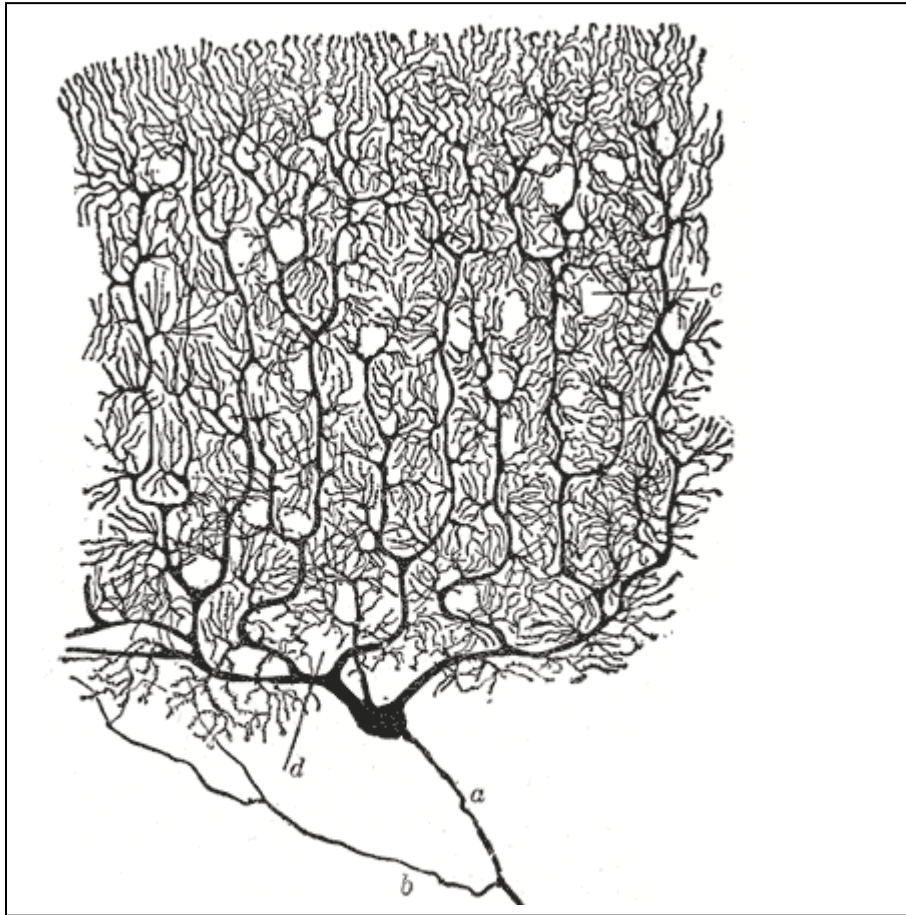


Figure 11.23. Highly branching Purkinje cells are found in the cerebellum.

<http://commons.wikimedia.org/wiki/Image:PurkinjeCellCajal.gif>

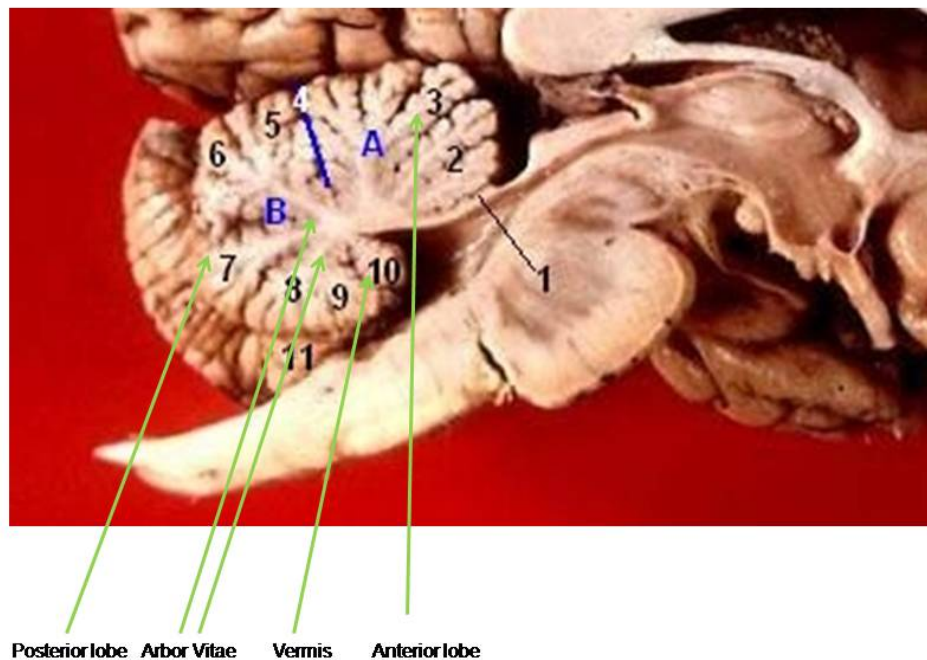


Figure 11.24. Cerebellum, sagittal view.

Modified by Dr. Bruce Forciea from:

[http://commons.wikimedia.org/wiki/Image:Human\\_brain\\_midsagittal\\_view\\_description.JPG](http://commons.wikimedia.org/wiki/Image:Human_brain_midsagittal_view_description.JPG)

Original author: John A Beal, PhD

## The Diencephalon

The diencephalon lies between the brainstem and cerebrum. It consists of the thalamus, hypothalamus, subthalamus and epithalamus (fig. 11.25).

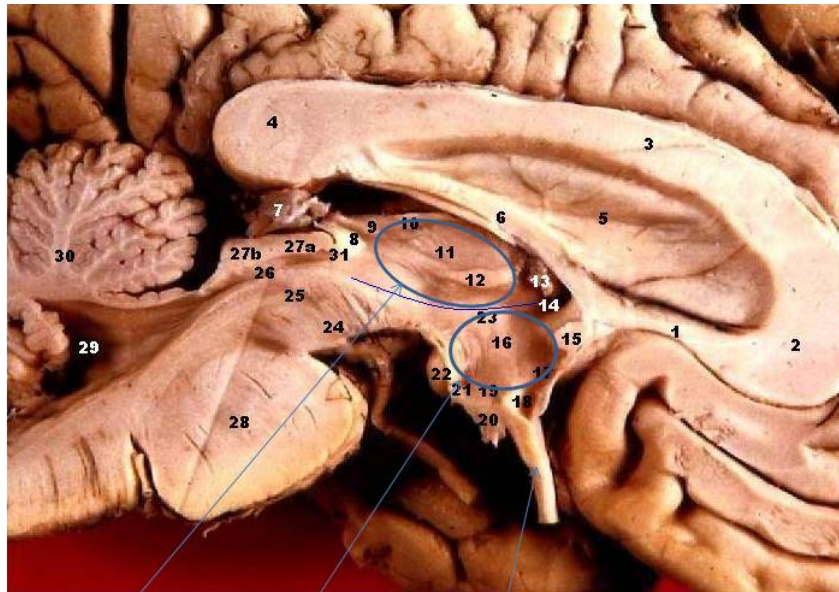
The thalamus is the largest part of the diencephalon (figs. 11.27, 11.28). It consists of two lateral portions connected by a stalk called the interthalamic adhesion sometimes referred to as the intermediate mass. The thalamus carries all sensory information to the cerebral cortex with the exception of the sense of smell which is carried directly to the frontal lobe of the cerebral cortex by the olfactory nerves. The thalamus is sometimes referred to as a relay station for sensory information. Examples of sensory information include auditory information that synapses in the medial geniculate nucleus, visual information that synapses in the lateral geniculate nucleus, and motor information from the basal nuclei, motor cortex and cerebellum synapsing in the ventral anterior and lateral nuclei. The thalamus is also intimately involved in emotions due to its connections to the limbic system.

The hypothalamus lies inferior and anterior to the thalamus. It contains the mamillary bodies on its anterior surface. The mamillary body processes information associated with the sense of smell and emotions. A stalk-like projection called the infundibulum projects anterior and inferior and connects to the pituitary gland. The hypothalamus is intimately connected with the endocrine system and helps to regulate hormones. The hypothalamus also regulates body temperature, thirst, hunger and sexual drive and is involved in processing emotions, mood, and sleep along with the reticular activating system.

The epithalamus is located posterior and superior to the thalamus. It is a small area that works to process the sense of smell and emotional responses. The pineal body (gland) is also located in this area. It is a pine shaped structure that helps to regulate sleep-wake cycles by secreting the hormone melatonin (fig. 11.26).

The subthalamus is located inferior to the thalamus. It contains nuclei that are involved in controlling motor information.





Thalamus    Hypothalamus    Infundibulum

Figure 11.25. Diencephalon, thalamus and hypothalamus.

Modified by Dr. Bruce Forciea from:

[http://commons.wikimedia.org/wiki/Image:Human\\_brain\\_left\\_midsagitttal\\_view\\_closeup\\_description\\_2.JPG](http://commons.wikimedia.org/wiki/Image:Human_brain_left_midsagitttal_view_closeup_description_2.JPG)

Original author: John A Beal, PhD

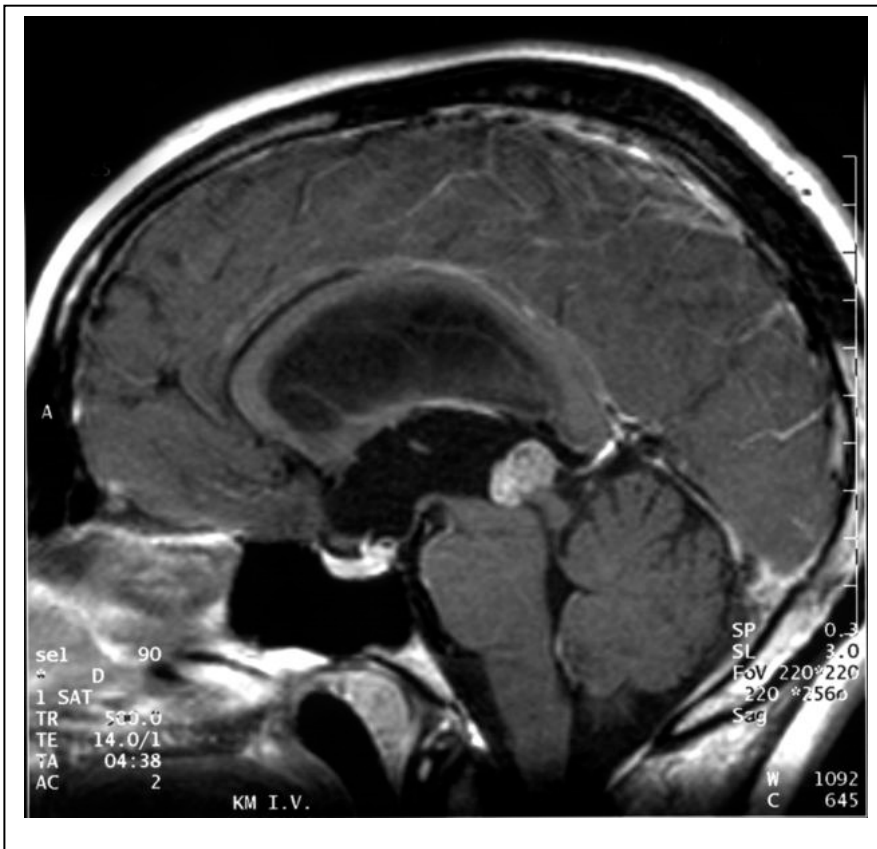

Figure 11.26. The pineal gland (highlighted area) is located in the posterior region of the diencephalon.

[http://commons.wikimedia.org/wiki/Image:PTPR\\_MRI.jpg](http://commons.wikimedia.org/wiki/Image:PTPR_MRI.jpg)

Author: Martin Hasselblatt MD

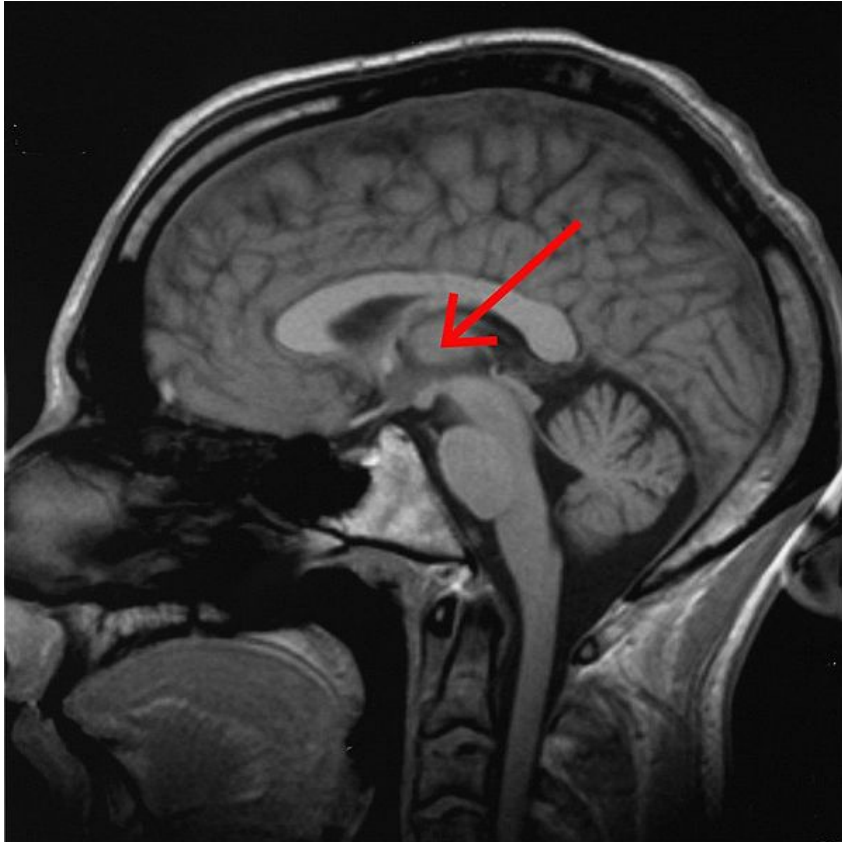

Figure 11.27. MRI showing location of thalamus.

[http://commons.wikimedia.org/wiki/Image:Brain\\_chrischan\\_thalamus.jpg](http://commons.wikimedia.org/wiki/Image:Brain_chrischan_thalamus.jpg)

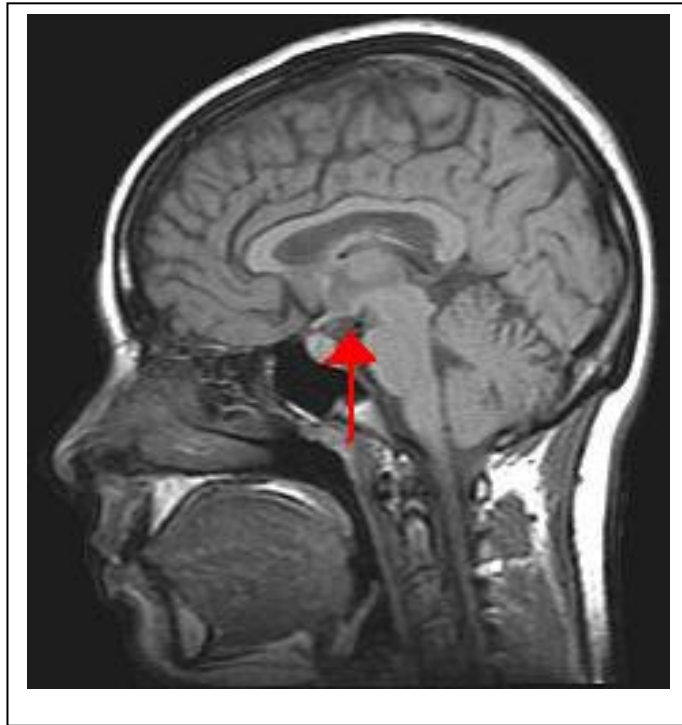

Figure 11.28. MRI showing location of hypothalamus.

<http://commons.wikimedia.org/wiki/Image:Hypothalamus.jpg>

## The Cerebrum

The cerebrum is largest portion of the nervous system (fig. 11.29, 11.30). The cerebrum consists of two hemispheres (right and left) connected by a white matter bridge called the corpus callosum. On the surface of the cerebrum are folds called gyri and grooves called sulci. Deep grooves are known as fissures. Each hemisphere is divided into lobes. The lobes are the frontal, parietal, temporal and occipital.

The frontal lobe processes information involving motor movements, concentration, planning and problem solving as well as the sense of smell and emotions. The parietal lobes process sensory information with the exception of hearing, smell and vision. The temporal lobes process information related to hearing, smell and memory as well as abstract thought and making judgments. The occipital lobe processes visual information.

Some lobes are divided by fissures. Along the superior aspect of the cerebrum lies the longitudinal fissure that divides the parietal lobes. The lateral fissure (Sylvian fissure) is located on the lateral aspect and separates the temporal from parietal lobes. One sulcus called the central sulcus is located midway on the lateral aspect of the cerebrum and extends from superior to inferior. The central sulcus separates the frontal from parietal lobes.

Deep in the lateral fissure is the insula which is often referred to as a fifth lobe of the cerebrum.

The cerebrum also has a medulla that consists of white matter tracts. Association fibers connect regions of the cerebral cortex to other regions within the same hemisphere. Commissural fibers interconnect both hemispheres. The corpus callosum is the largest group of commissural fibers. Projection fibers connect the cerebrum to other portions of the brain and spinal cord and form the internal capsule.

The basal nuclei are located in the inferior portion of the cerebrum as well as the diencephalon and midbrain. The cerebral basal nuclei consist of the caudate and lentiform nuclei. The lentiform nuclei divide into the putamen laterally and globus pallidus medially. These nuclei work to control motor information along with the subthalamic nuclei and substantia nigra.

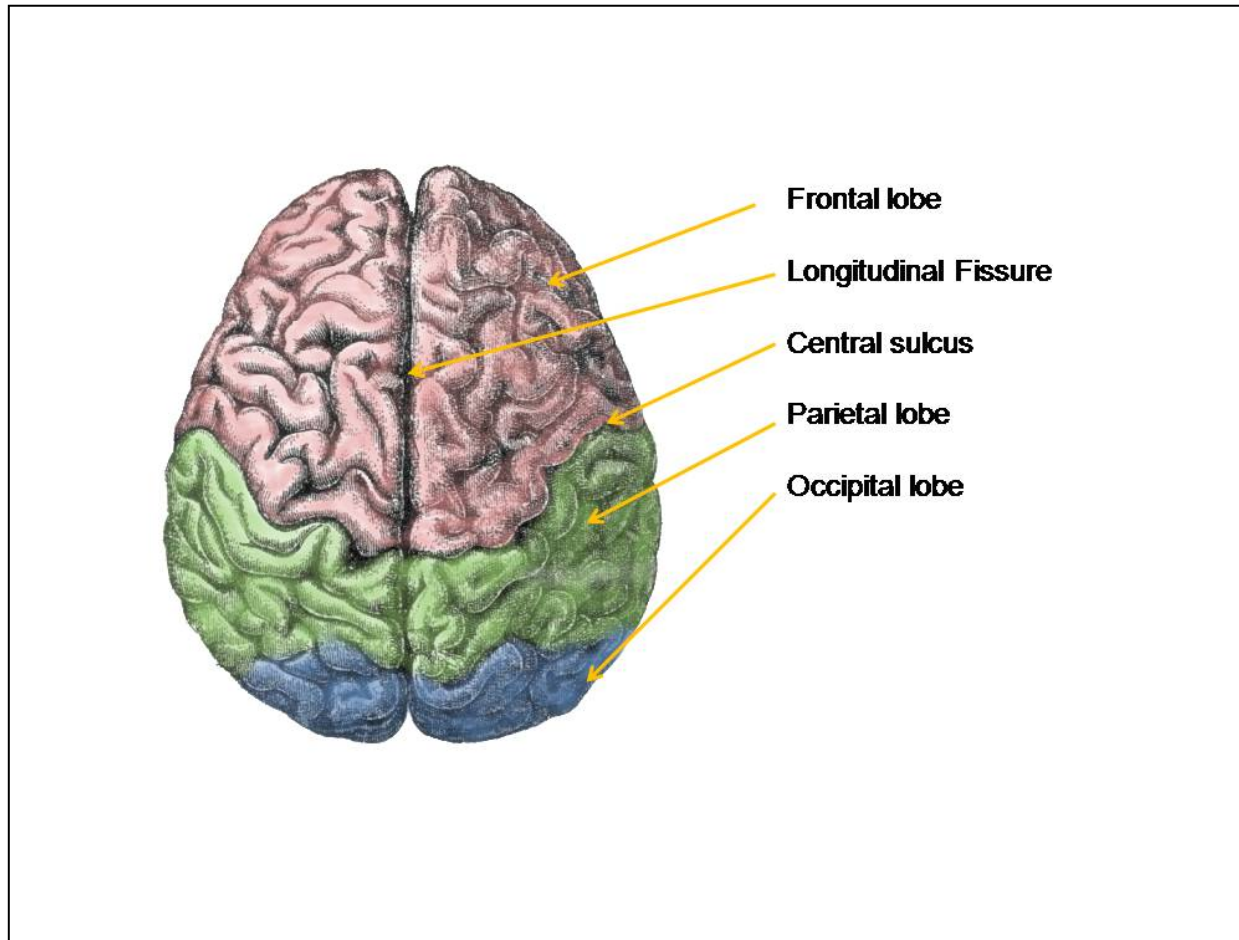


Figure 11.29. Cerebrum superior view.

[http://commons.wikimedia.org/wiki/Image:Cerebral\\_lobes.png](http://commons.wikimedia.org/wiki/Image:Cerebral_lobes.png)

## Lobes of the brain

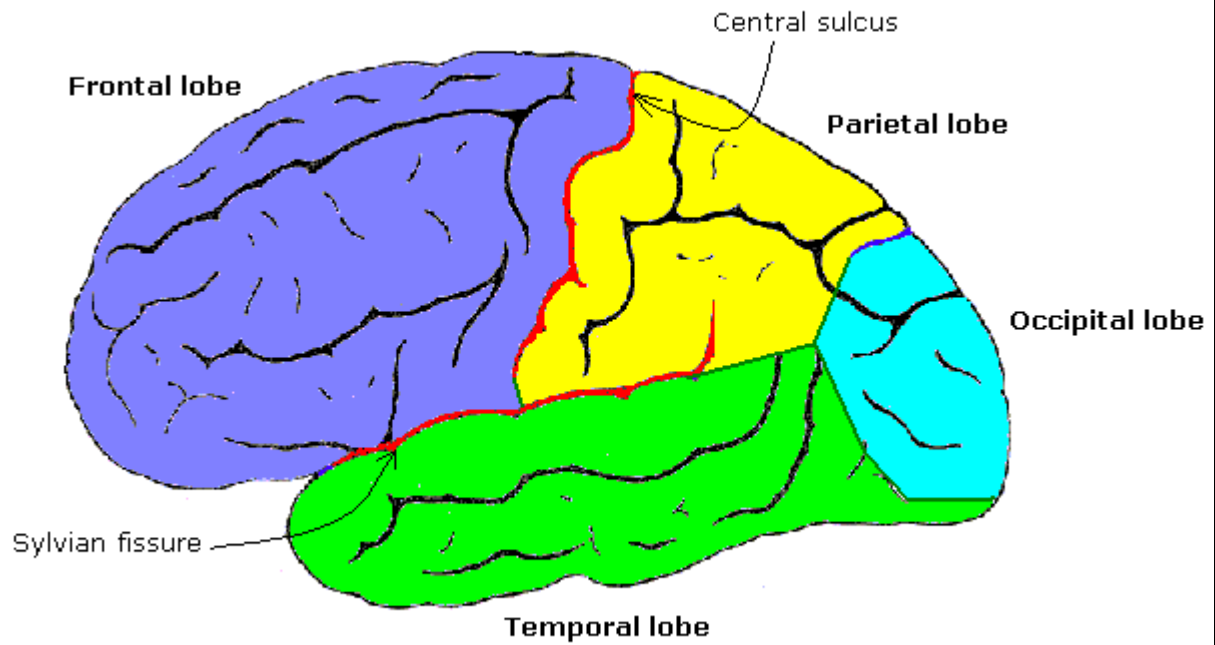


Figure 11.30. Lobes of cerebrum, lateral view.

[http://commons.wikimedia.org/wiki/Image:Main\\_brain\\_lobes.gif](http://commons.wikimedia.org/wiki/Image:Main_brain_lobes.gif)

## Limbic System

The limbic system consists of portions of both the cerebrum and diencephalon and is involved in the emotions as well as reproduction and memory (fig. 11.31). The limbic system contains the cingulate gyrus located just superior to the corpus callosum and the parahippocampal gyrus located on the medial aspect of the temporal lobe. The limbic system also contains nuclei including the dentate nucleus, amygdala, mammillary bodies of the hypothalamus, the olfactory cortex and the fornix.

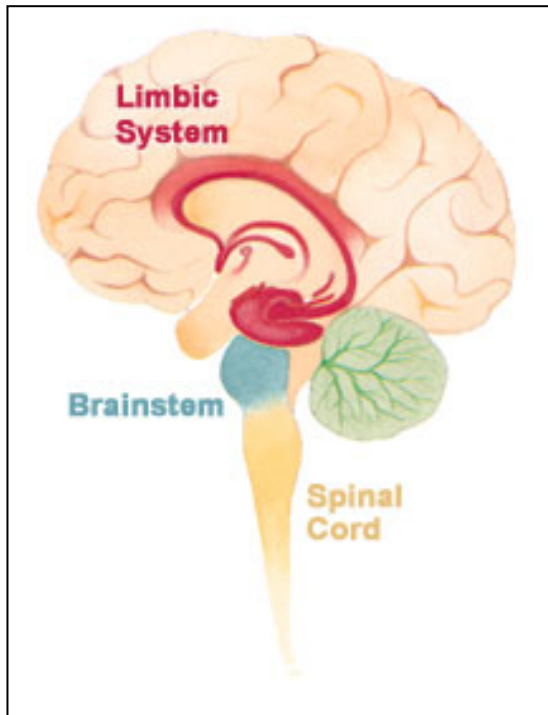


Figure 11.31. Limbic system.

[http://commons.wikimedia.org/wiki/Image:Brain\\_limbicsystem.jpg](http://commons.wikimedia.org/wiki/Image:Brain_limbicsystem.jpg)

## The Cerebral Spinal Fluid System

We investigated the meninges of the spinal cord earlier in this chapter. These coverings are consistent with the brain. The meninges cover both the brain and spinal cord (fig. 11.32). However there are some differences in how the membranes are structured in the brain. The dura mater in the brain adheres to the inner portions of the bones of the skull. The dura also produces folds that extend into some of the brain's fissures. The falx cerebri is a fold of dura mater that extends into the longitudinal fissure. It connects to the crista galli of the ethmoid bone. The tentorium cerebelli lies between the cerebrum and cerebellum in a transverse plane. The falx cerebelli lies between the cerebellar hemispheres.

The dura mater in the brain also forms sinuses which are hollow areas that contain venous blood and cerebral spinal fluid. The superior sagittal sinus lies between falx cerebri and periosteum of the skull. The inferior sagittal sinus lies deep within the falx cerebri and superior to the corpus callosum.

The arachnoid mater is the middle layer of meninges. The pia mater makes a very close connection to the surface of the brain. The subarachnoid space exists between the pia and arachnoid mater.

Cerebral spinal fluid (CSF) is derived from the plasma of the blood. It contains none of the large elements of the blood such as plasma proteins. It acts as a shock absorber and cushions the brain and



spinal cord. CSF is produced by small vascular structures called choroid plexi. A choroid plexus contains ependymal cells that produce CSF. These cells actively transport sodium to the outside of the cells creating a gradient that pulls fluid out of the blood vessels. The blood vessels in a choroid plexus form a blood-brain barrier between the blood and CSF. The capillaries inside of the brain also form a blood-brain barrier. These cells are surrounded by nervous system cells called astrocytes. These cells work to form tight junctions that help to regulate the substances passing into the brain. Examples of substances that can pass through the blood-brain barrier include lipid soluble drugs and alcohol. Water soluble substances can also enter the brain via transport proteins.

CSF not only circulates in the subarachnoid space but also within hollow chambers located in the brain. These chambers are called ventricles (11.33). There are two lateral ventricles separated by a fibrous membrane called the septum pellucidum, a third and fourth ventricle. The lateral ventricles are located within the cerebral hemispheres. The third ventricle lies between the two halves of the thalamus in the diencephalon. The fourth ventricle lies between the brainstem and the cerebellum (figs. 11.34, 11.35).

The ventricles are all connected via foramen (holes) or tubular passages. The lateral ventricles connect to the third ventricle via the interventricular foramen. The third ventricle connects to the fourth via a tube passing through the midbrain called the cerebral aqueduct (aqueduct of Sylvius). The fourth ventricle connects with the central canal of the spinal cord. The fourth ventricle also connects with the subarachnoid space via lateral and medial apertures. The median aperture is called the foramen of Magendie and the two lateral apertures are called the foramen of Luschka.

CSF is produced by the choroid plexi that make about 500 ml/day. However some of the CSF is absorbed so there is only about 140 ml in the system at any one time. This is due to the CSF being absorbed by arachnoid granulations. Arachnoid granulations are masses of arachnoid tissue located in the dural venous sinuses. CSF can move into the blood at these locations.

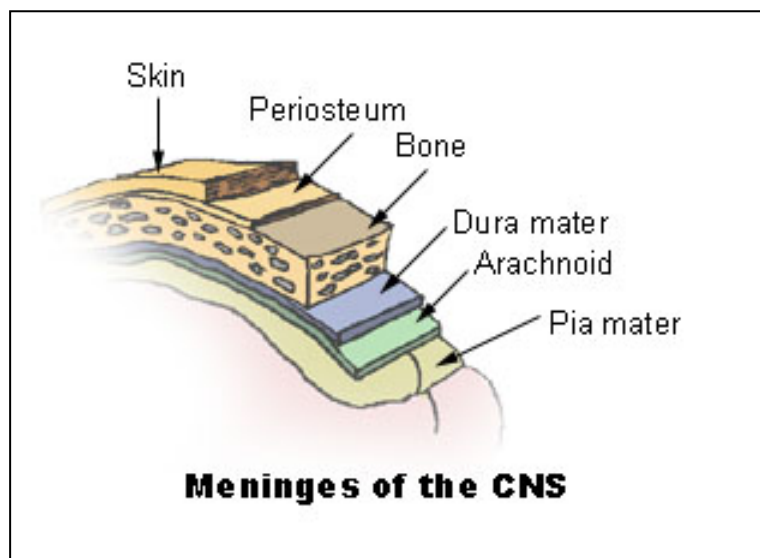


Figure 11.32. The brain has 3 layers of meninges.

[http://commons.wikimedia.org/wiki/Image:Illu\\_meninges.jpg](http://commons.wikimedia.org/wiki/Image:Illu_meninges.jpg)



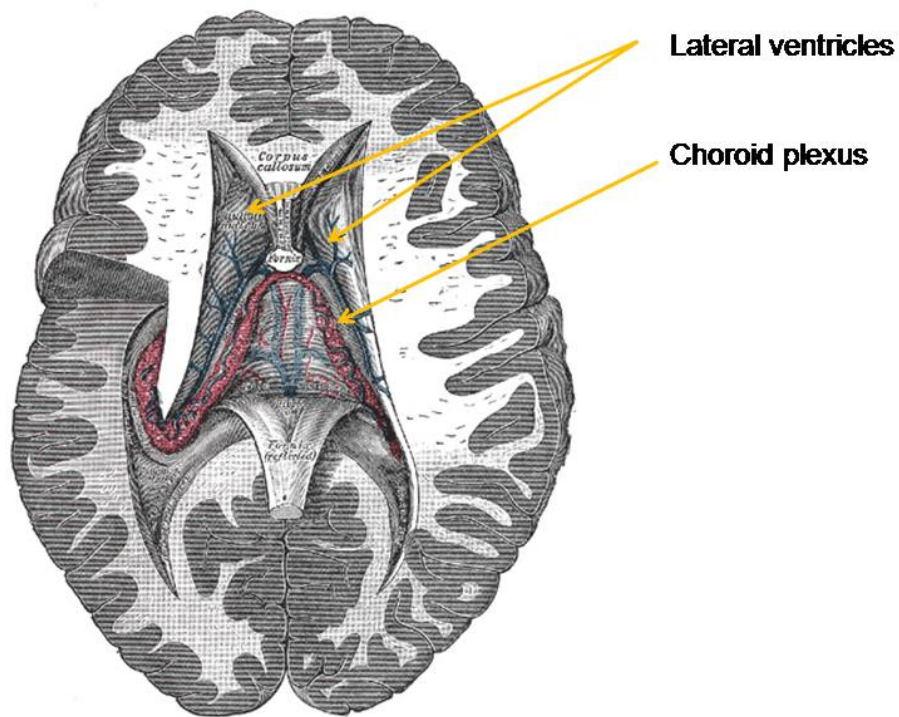


Figure 11.33. Lateral ventricles of brain.

Modified by Dr. Bruce Forciea from: <http://commons.wikimedia.org/wiki/Image:Gray750.png>

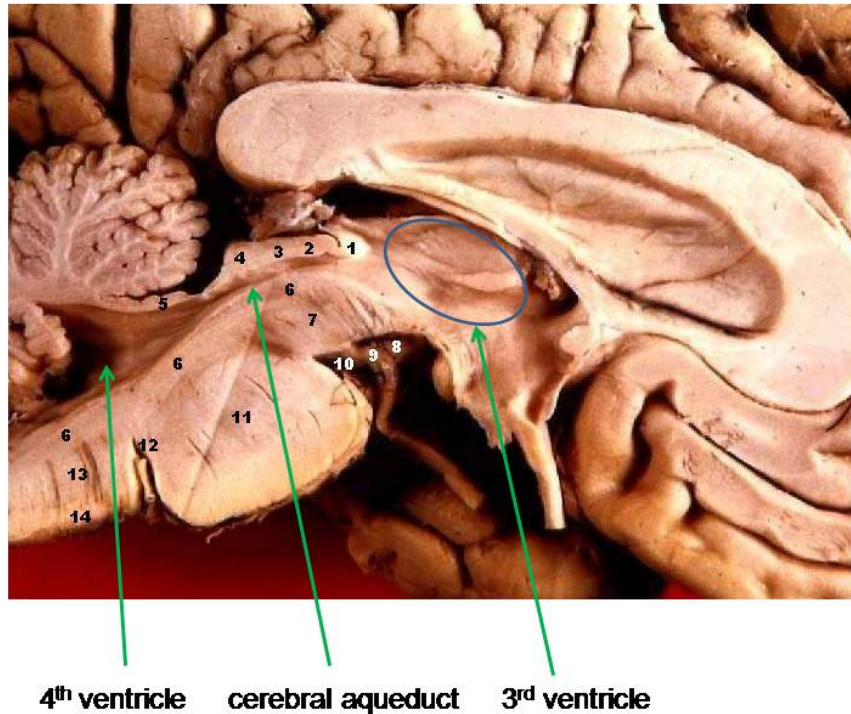
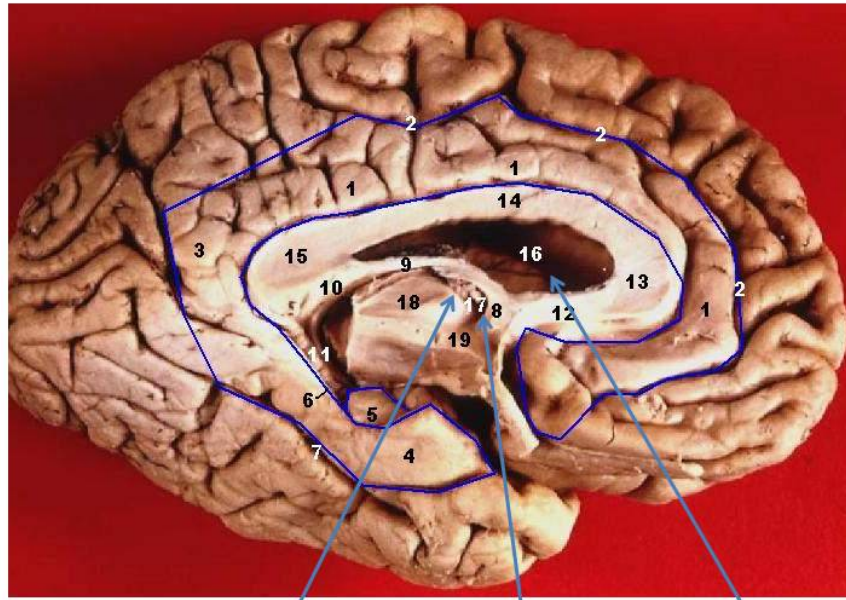


Figure 11.34. Third and fourth ventricles of brain.

Modified by Dr. Bruce Forciea from:

[http://commons.wikimedia.org/wiki/Image:Human\\_brain\\_left\\_midsagittal\\_view\\_closeup\\_description\\_3.JPG](http://commons.wikimedia.org/wiki/Image:Human_brain_left_midsagittal_view_closeup_description_3.JPG)

Original author: John A Beal, PhD



choroid plexus of third ventricle

interventricular foramen

lateral ventricle

Figure 11.35. CSF circulatory structures.

Modified by Dr. Bruce Forciea from:

[http://commons.wikimedia.org/wiki/Image:Human\\_brain\\_inferior-medial\\_view\\_description\\_3.JPG](http://commons.wikimedia.org/wiki/Image:Human_brain_inferior-medial_view_description_3.JPG)

Original author: John A Beal, PhD

## The Cranial Nerves

There are 12 pairs of cranial nerves. Eleven of these originate in the diencephalon or brainstem while one pair originates in the frontal lobe of the brain. The cranial nerves can carry sensory information, motor information or both. The sensory information consists of touch, pain and vision. Motor information controls skeletal muscles. Some cranial nerves also carry information for the parasympathetic nervous system. The cranial nerves are usually designated as Roman numerals (I—XII).

### Cranial Nerve I Olfactory

The olfactory nerve is a sensory nerve. It carries the information for the sense of smell (fig. 11.36, 11.37). The olfactory nerve is the only nerve that originates in the frontal lobe of the brain and its fibers pass through the cribriform plate of the ethmoid bone to reach the upper nasal passages. There its receptors collect sensory information in the form of changes in chemical concentrations of substances that are interpreted by the cerebral cortex as smell. The olfactory nerves enter the olfactory bulbs located near the crista galli of the ethmoid bone before entering the cerebrum.

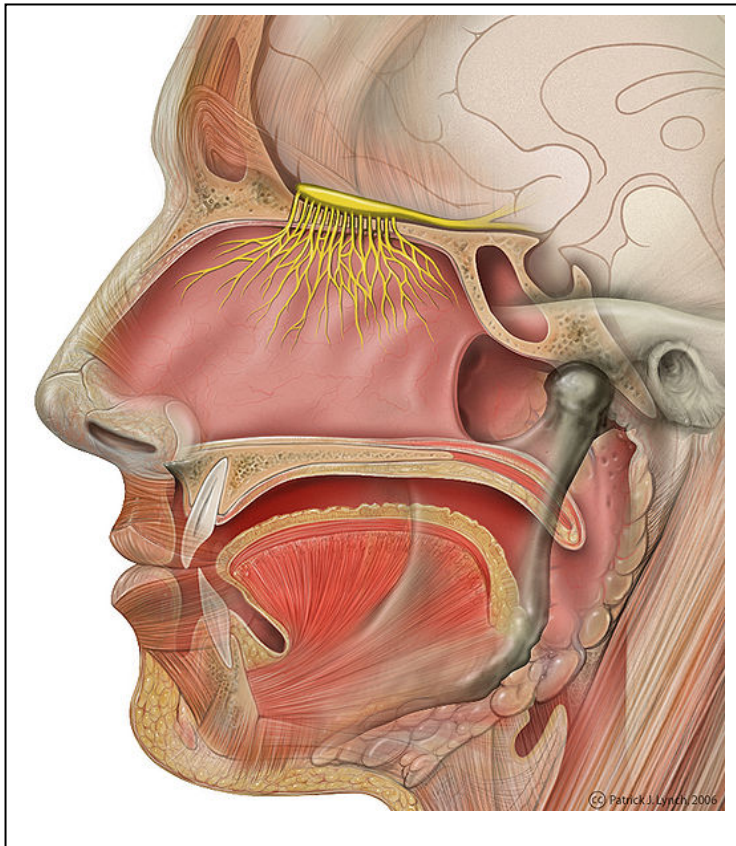


Figure 11.36. Olfactory nerve.

[http://commons.wikimedia.org/wiki/Image:Head\\_olfactory\\_nerve.jpg](http://commons.wikimedia.org/wiki/Image:Head_olfactory_nerve.jpg)

Author: Patrick J. Lynch

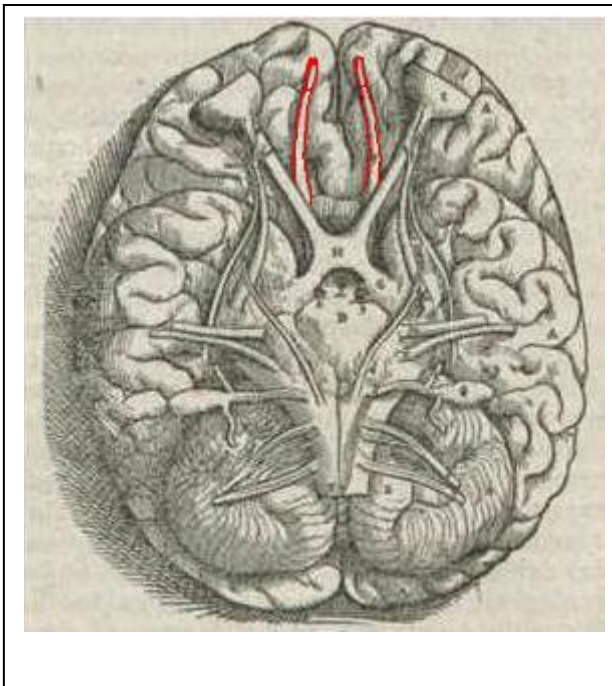


Figure 11.37. Olfactory bulb (highlighted in red). The olfactory fibers travel to the olfactory bulb.

<http://upload.wikimedia.org/wikipedia/commons/7/7c/1543%2CVesalius%27OlfactoryBulbs.jpg>



## Cranial Nerve II Optic

The optic nerves are sensory nerves. They carry information relating to vision from the retina of the eyes and pass through the optic canals of the sphenoid bone (fig. 11.38). They then form the optic chiasm before entering the lateral geniculate nuclei of the thalamus. There they synapse with projection fibers that carry the information to the occipital lobe. At the optic chiasm the medial half of the fibers cross over to the opposite side of the brain. A few fibers bypass the lateral geniculate and synapse in the superior colliculus of the midbrain in the brainstem.

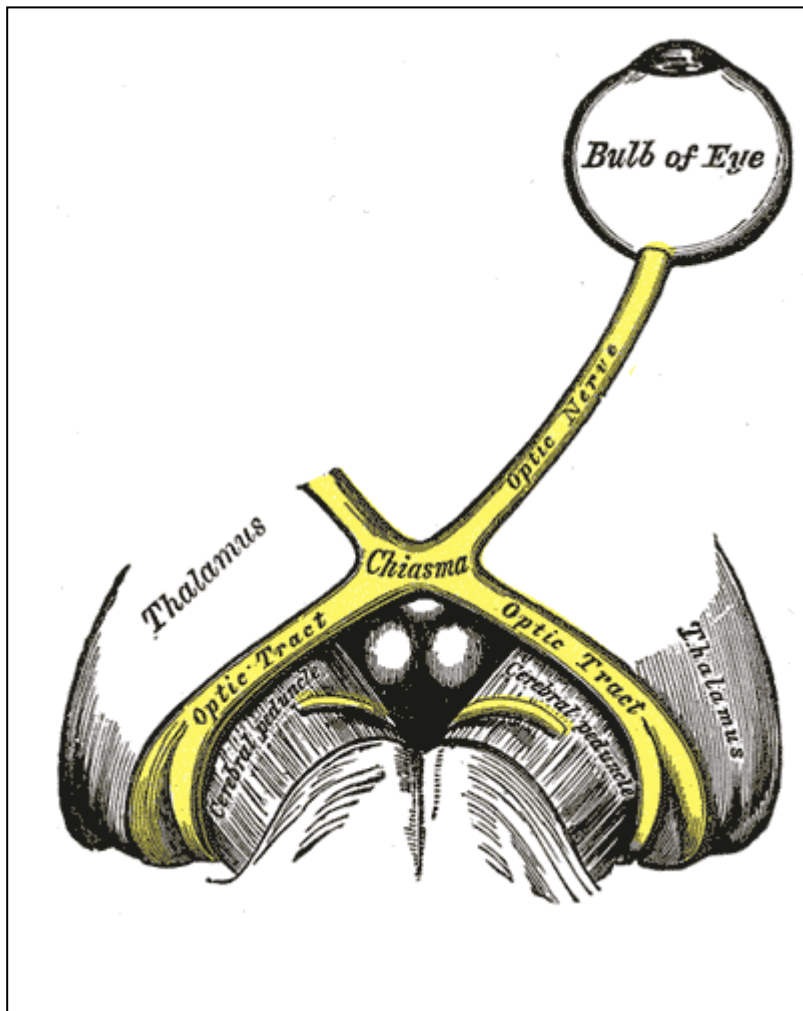


Figure 11.38. Optic Nerve.

<http://commons.wikimedia.org/wiki/Image:Gray773.png>

### Cranial Nerve III Oculomotor

The oculomotor nerves are motor nerves that innervate some of the muscles of the eye including the superior and inferior rectus, medial rectus and inferior oblique (fig. 11.39). They also innervate the levator palpebrae superioris muscles that move the eyelids. When these nerves are damaged patients will experience an inability to track objects with their eyes (strabismus) which can lead to double vision (diplopia). The oculomotor nerves also carry information for the autonomic nervous system that changes the pupil size. These fibers synapse in the ciliary ganglion.

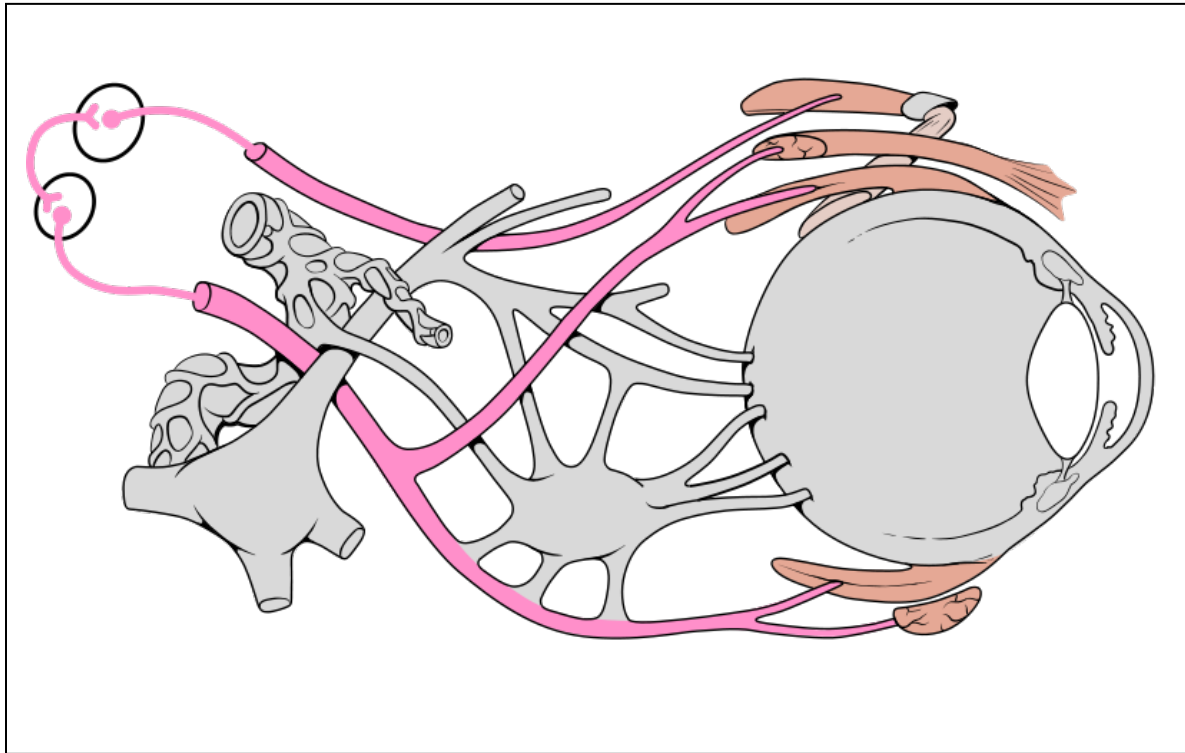


Figure 11.39. Oculomotor Nerve.

[http://commons.wikimedia.org/wiki/Image:Cranial\\_Nerve\\_III\\_somatic.svg](http://commons.wikimedia.org/wiki/Image:Cranial_Nerve_III_somatic.svg)

Author: Patrick J. Lynch

### Cranial Nerve IV Trochlear

The trochlear nerves are motor nerves that innervate the superior oblique muscles of the eyes. The nerves derive their names from their location near a ligamentous structure called the trochlea. The trochlea connects to the superior oblique muscle and acts as a pulley.

### Cranial Nerve V Trigeminal

The trigeminal nerves are mixed nerves carrying both sensory and motor information. The trigeminal nerves originate in the pons. They form a large semilunar ganglion before splitting into three divisions. The superior ophthalmic branch carries sensory information from the upper portion of the face above the eyelids. The middle maxillary branch carries sensory information from the middle portion of the face from below the lower eyelid to the upper lip. The lower mandibular branch carries sensory information from the mandible. The mandibular branch also carries motor information to the muscles of mastication including the masseter and temporalis.

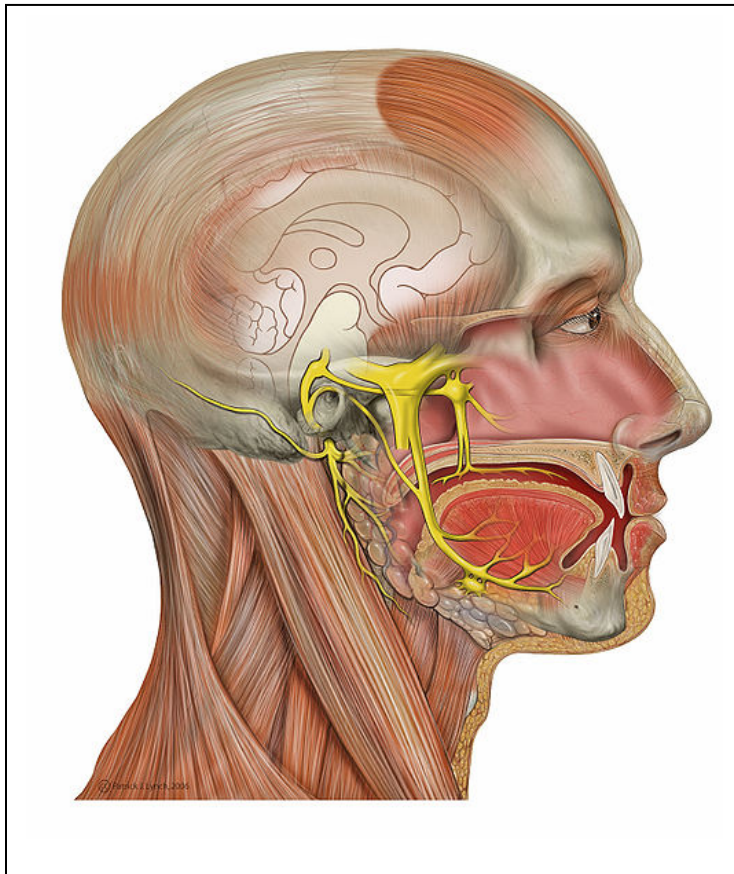


Figure 11.40. Trigeminal Nerve.

[http://commons.wikimedia.org/wiki/Image:Head\\_deep\\_facial\\_trigeminal.jpg](http://commons.wikimedia.org/wiki/Image:Head_deep_facial_trigeminal.jpg)

Author: Patrick J. Lynch



### Cranial Nerve VI Abducens

The abducens nerves are motor nerves carrying information to the lateral rectus muscles of the eyes. If the abducens nerve is damaged the eye will move inward.

### Cranial Nerve VII Facial

The facial nerves are mixed nerves. They carry motor information to the muscles of the face and are responsible for producing facial expressions (fig. 11.41). The sensory information consists of taste from the anterior two-thirds of the tongue along with proprioception of the facial muscles and deep pressure in the face.

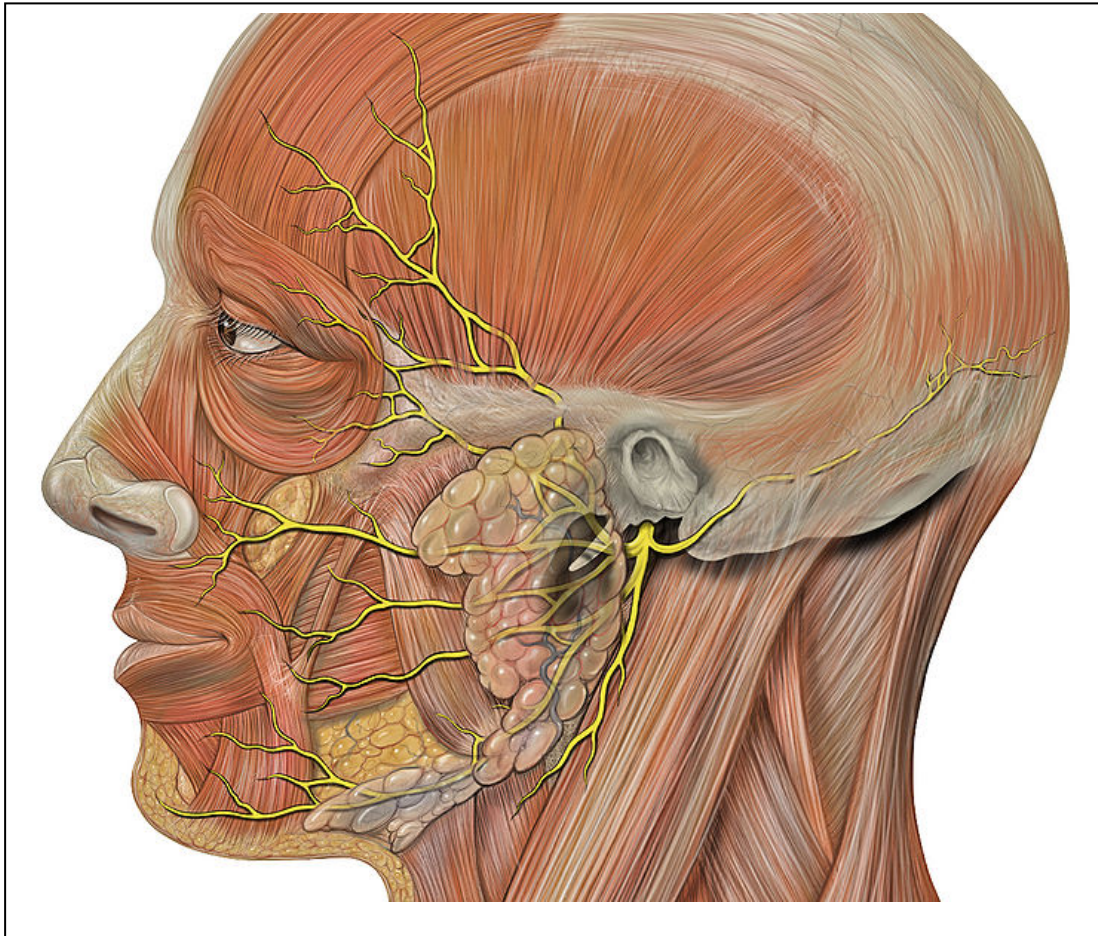


Figure 11.41. Facial Nerve.

[http://commons.wikimedia.org/wiki/Image:Head\\_facial\\_nerve\\_branches.jpg](http://commons.wikimedia.org/wiki/Image:Head_facial_nerve_branches.jpg)

Author: Patrick J. Lynch

### Cranial Nerve VIII Vestibulocochlear

The vestibulocochlear nerves are sensory nerves. They carry sensory information regarding hearing, balance and equilibrium from the inner ear. The nerves form two branches. A vestibular branch innervates the vestibule and semicircular canals of the ear and carries information related to balance and equilibrium. A cochlear branch carries hearing information from the cochlea of the inner ear.

### Cranial Nerve IX Glossopharyngeal

The glossopharyngeal nerves are mixed nerves (fig. 11.42). They carry sensory information regarding taste from the posterior one-third of the tongue as well as motor information to the muscles in the pharynx for swallowing.

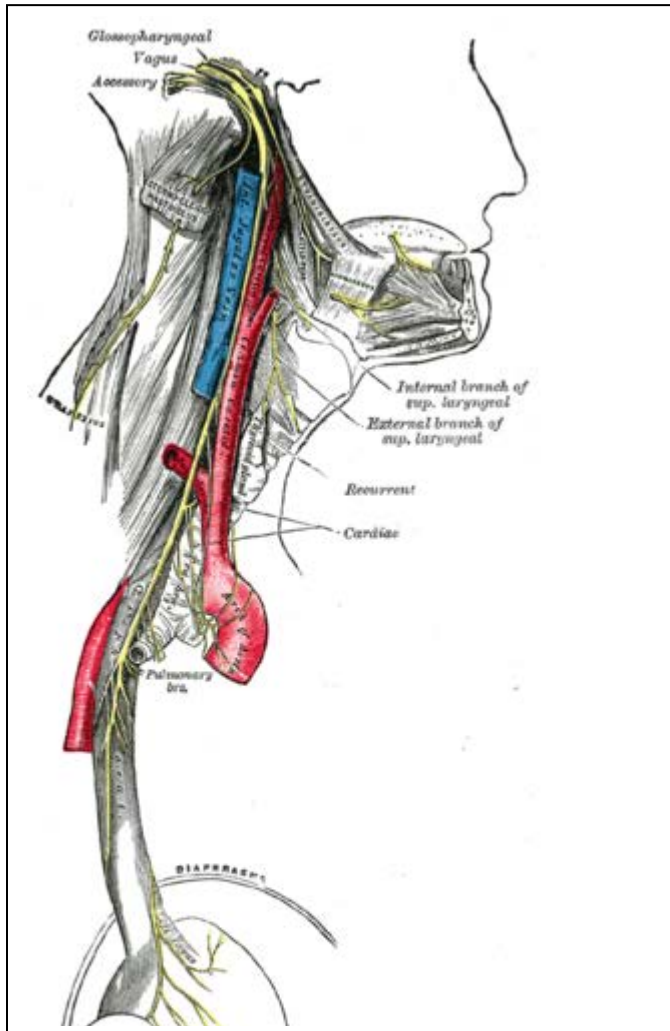


Figure 11.42. Glossopharyngeal nerve (yellow).

<http://commons.wikimedia.org/wiki/Image:Gray793.png>

### Cranial Nerve X Vagus

The vagus nerves are mixed nerves. They carry sensory information from the viscera of the esophagus, respiratory tract and abdomen. They carry motor information to the heart, stomach, intestines, and gallbladder. The vagus nerves also carry information for coordination of swallowing. The vagus nerves are important autonomic nervous system nerves.

### Cranial Nerve XI Spinal Accessory

The spinal accessory nerves are motor nerves. They carry information to the muscles of the neck and upper back including the sternocleidomastoid and trapezius. What is unique about the spinal accessory nerves is that some of the motor fibers originate in the anterior gray horns of the first five cervical segments of the spinal cord. These fibers enter the foramen magnum and join fibers originating in the medulla oblongata. The combined fibers then exit the cranium at the jugular foramen and divide into two branches. The internal branch joins the vagus nerve and innervates the vocal cords, pharynx and soft palate, The external branch controls the sternocleidomastoid and trapezius muscles.

### Cranial Nerve XII Hypoglossal

The hypoglossal nerves are motor nerves. They primarily carry motor information to the muscles that move the tongue. One way to check the hypoglossal nerves is to ask the patient to stick their tongue out. Deviation of the tongue from one side to the other indicates a problem with the hypoglossal nerve.

## **The Autonomic Nervous System**

The autonomic nervous system can be thought of as an “automatic” system because it works to maintain homeostasis in the body even when it is in an unconscious state (fig. 11.43). The autonomic nervous system (ANS) can control respiratory, cardiovascular, urinary, digestive and reproductive functions. It works to maintain balance of fluids, electrolytes, blood pressure, nutrients, and blood gasses. The ANS does this by sending motor impulses to viscera, cardiac and smooth muscle. Since it sends motor impulses to viscera, the ANS is also known as a visceral motor system.

The ANS is divided into two subdivisions. The sympathetic is often referred to as the “fight or flight” system. It is located in the thoracic and lumbar spines and sends fibers to the viscera. The parasympathetic division begins in the cervical and lower lumbar spines and sends fibers to the same viscera as the sympathetic. The sympathetic and parasympathetic divisions typically have the opposite effect on organs and thus work to maintain balance based on the body’s needs. For example the sympathetic system can increase heart rate while the parasympathetic system decreases it.

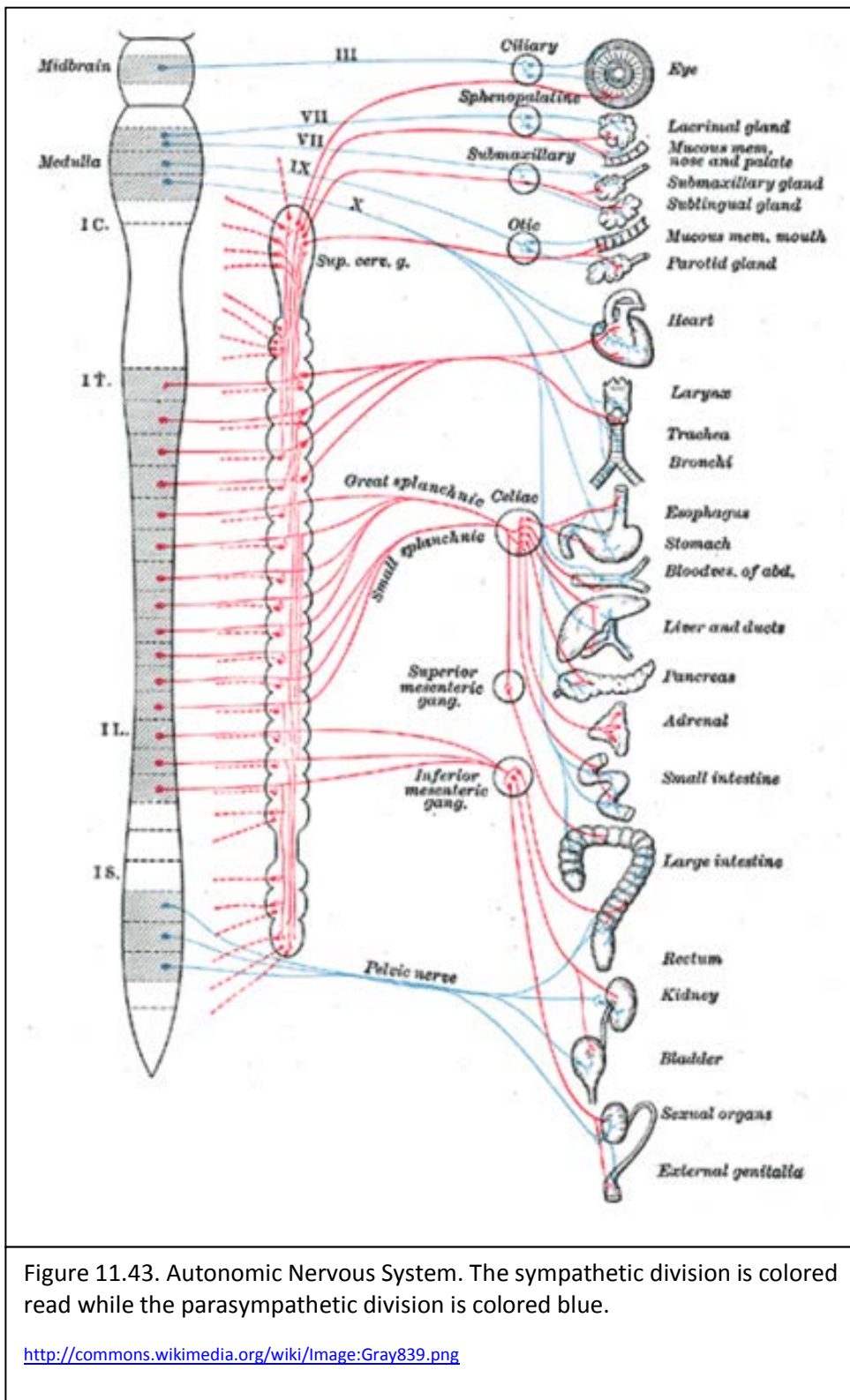


Figure 11.43. Autonomic Nervous System. The sympathetic division is colored read while the parasympathetic division is colored blue.

<http://commons.wikimedia.org/wiki/Image:Gray839.png>

## Sympathetic Nervous System

The sympathetic nervous system works to increase heart rate, dilate air passages, increase activity of sweat glands, increase glucose levels in the blood, dilate the pupils, and decrease digestive activity. It can increase the amount of blood moving to the cardiac and skeletal systems while decreasing blood flow to the skin. It also decreases urinary activity.

The sympathetic nervous system must send two neurons to the viscera. The first neuron has its cell body in the brainstem or spinal cord. Its axon extends from the ventral roots of the spinal nerves to the paravertebral ganglia (sometimes called the sympathetic chain) of the spinal cord. The sympathetic chains are located on either sides of the spinal cord. Each sympathetic chain consists of 3 cervical, 10-12 thoracic, 4-5 lumbar and 4-5 sacral ganglia. These fibers are known as preganglionic fibers. They synapse with fibers in the ganglia that are postganglionic. The preganglionic fibers then are short while the postganglionic fibers are long.

The spinal nerves send two branches to the paravertebral ganglia. One branch contains fibers from the spinal nerve traveling to the ganglia. This branch is called the white communicating ramus. It is white due to the myelinated neurons. The other branch carries unmyelinated fibers from the ganglion to the viscera. This branch is called the gray communicating ramus.

Once the preganglionic fibers reach the paravertebral ganglia they synapse with a postganglionic neuron at that level, synapse with a postganglionic neuron at another level, or don't synapse with another neuron but exit the ganglia as splanchnic nerves.

The splanchnic nerves synapse with postganglionic neurons at ganglia called the prevertebral ganglia. The prevertebral ganglia are located near the abdominal aorta and form a plexus there (fig. 11.45). There are three ganglia associated with the abdominal aortic plexus which include the superior mesenteric, inferior mesenteric and celiac. The celiac ganglion is sometimes called the solar plexus.

It is important to understand the role of the adrenal gland in the sympathetic nervous system. The adrenal glands are pyramid shaped glands that sit on top of the kidneys (fig. 11.44). They consist of two parts; an outer cortex and an inner medulla. The adrenal medulla contains neurons that secrete epinephrine, norepinephrine and dopamine. Preganglionic sympathetic fibers synapse with neurons in the adrenal medulla.

Preganglionic fibers of the sympathetic nervous system are classified as cholinergic. This means that they respond to the neurotransmitter acetylcholine. Postganglionic sympathetic fibers are classified as adrenergic which means they respond to adrenaline. There are exceptions and these include the postganglionic fibers that innervate sweat glands and some superficial blood vessels. These structures respond to acetylcholine and are therefore considered cholinergic.



### **Adrenal Gland**

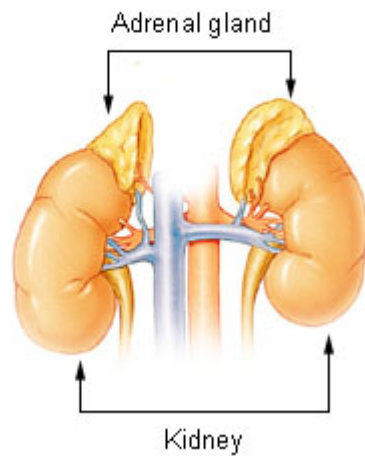


Figure 11.44. Adrenal Glands.

[http://commons.wikimedia.org/wiki/Image:Illu\\_adrenal\\_gland.jpg](http://commons.wikimedia.org/wiki/Image:Illu_adrenal_gland.jpg)

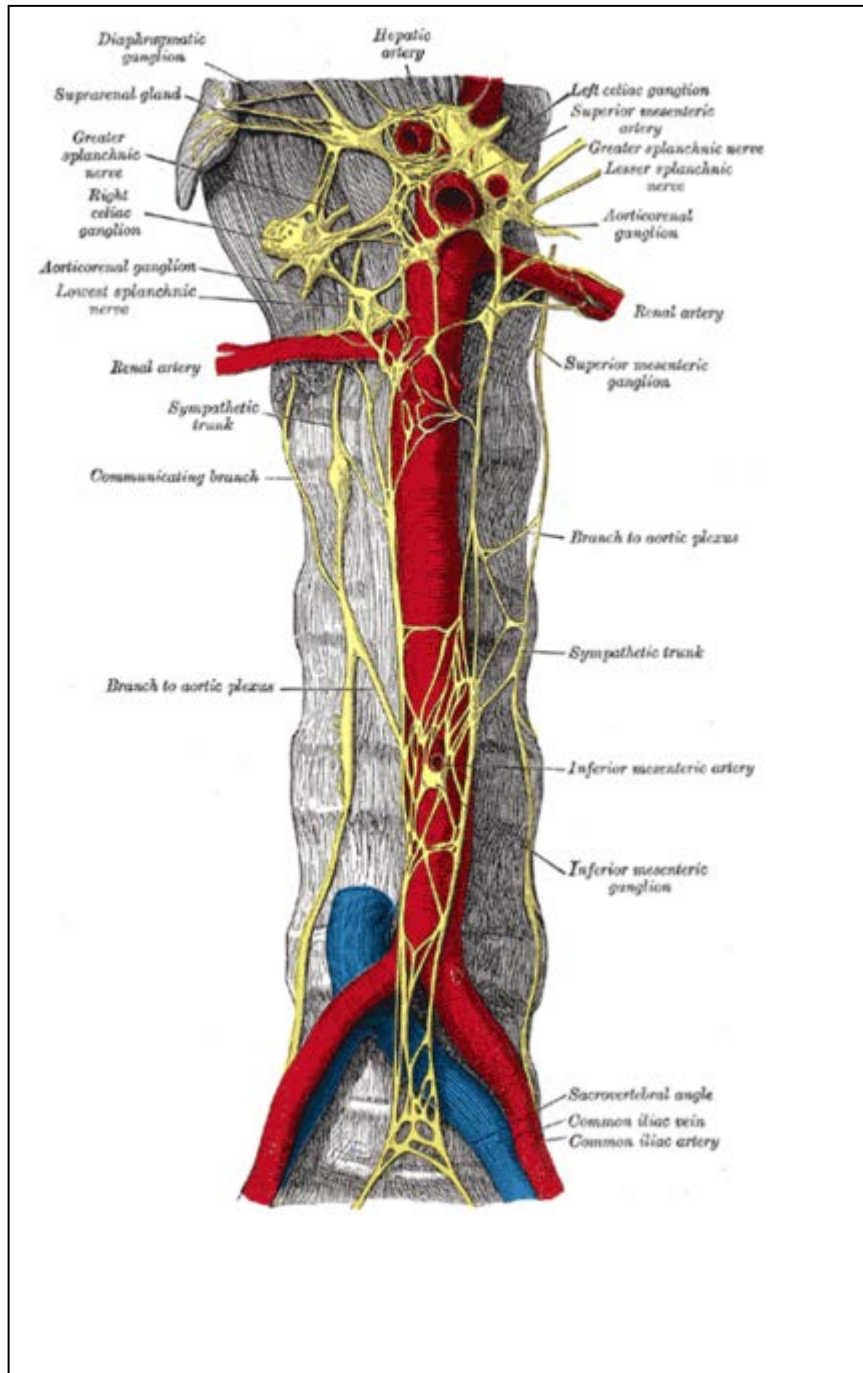


Figure 11.45. The abdominal aortic plexus contains the celiac and mesenteric ganglia.

<http://commons.wikimedia.org/wiki/Image:Gray847.png>

## **Parasympathetic Nervous System**

The parasympathetic division of the ANS originates in the brain and sacral region of the spinal cord. It is sometimes referred to as the craniosacral division of the ANS. The cell bodies lie in the brainstem (midbrain, pons, medulla oblongata) as well as in sacral segments 2-4 of the spinal cord. The preganglionic neurons are much longer than those in the sympathetic nervous system. They synapse at terminal ganglia near the target organs.

The parasympathetic nervous system fibers in the brain exit via cranial nerves. The oculomotor nerve carries parasympathetic fibers that control the lens and pupil of the eye. Preganglionic fibers enter the ciliary ganglion (behind the eye) and synapse with postganglionic fibers that innervate the ciliary and pupillary constrictor muscles. The facial nerve also carries parasympathetic fibers. These fibers control the tear, salivary and nasal glands. The glossopharyngeal nerve carries fibers that control salivation. The vagus nerve carries a large number of preganglionic fibers. These fibers travel to plexi including the cardiac, esophageal and pulmonary plexus. The fibers emerge from the plexi and continue through the diaphragm to innervate organs in the abdominal cavity such as the pancreas, stomach, intestines, kidney, ureter, liver and part of the colon.

Parasympathetic fibers from the sacral segments form pelvic splanchnic nerves that continue to the inferior hypogastric plexus. Most of these become pelvic nerves that innervate the reproductive organs, rectum, urinary bladder, and the remainder of the colon.

Preganglionic and postganglionic parasympathetic fibers are considered cholinergic.

## **Autonomic Neurotransmitters**

There are two types of adrenergic receptors; alpha and beta. Both of these respond to adrenaline but can elicit different effects in different organs. Norepinephrine is broken down by monoamine oxidase via the process of reuptake.

Alpha adrenergic receptors are generally excitatory while beta receptors are inhibitory. However it is a good idea not to generalize as there are exceptions due to subclasses of receptors such as alpha 1, alpha 2, beta 1, beta 2.

For example, if norepinephrine (NE) stimulates alpha receptors on blood vessels they vasoconstrict. However if NE stimulates beta receptors on blood vessels in skeletal and cardiac muscle they vasodilate.

There are also two types of cholinergic receptors. Muscarinic receptors are located in the membranes of target tissue of postganglionic parasympathetic neurons. Nicotinic receptors are located between pre and post ganglionic neurons. Acetylcholine is degraded by acetylcholinesterase located in the post-synaptic membrane.



Organ	Autonomic Innervation	Type of Receptor	Action
Eye : pupil	sympathetic	alpha	dilation of the pupil
	parasympathetic	muscarinic	constriction of the pupil
Eye : ciliary muscle	sympathetic	beta	allows far vision
	parasympathetic	muscarinic	allows near vision
Tear glands	sympathetic	beta	vasoconstriction
	parasympathetic	muscarinic	secretion of tears
Salivary glands	sympathetic	alpha	vasoconstriction and secretion of mucous with a low enzyme count
	parasympathetic	muscarinic	secretion of watery saliva with a high enzyme count
Heart	sympathetic	beta alpha	dilation of coronary arteries, increased heart rate, increased force of contraction, increased rate of pacemaker conduction
	parasympathetic	muscarinic	coronary artery constriction slows, heart rate, reduces contraction and conduction, constricts coronary arteries
Bronchii	sympathetic	beta	dilation
	parasympathetic	muscarinic	constriction and mucous secretion
Esophagus	sympathetic	alpha	vasoconstriction
	parasympathetic	muscarinic	peristalsis, secretion of mucous
Stomach and Intestines	sympathetic	beta alpha	inhibition of peristalsis and secretion vasoconstriction, spinctre contraction
	parasympathetic	muscarinic	peristalsis and secretion
Spleen	sympathetic	alpha	contraction
Adrenal medulla	sympathetic	-	adrenaline and noradrenaline secreted into the bloodstream

Liver	sympathetic	beta	break down of glycogen (glycogenolysis)
Gall Bladder	sympathetic parasympathetic	beta muscarinic	relaxation contraction
Pancreas	sympathetic	alpha beta	inhibition of insulin secretion stimulation of insulin secretion
Descending colon	sympathetic  parasympathetic	alpha beta muscarinic	vasoconstriction inhibition of peristalsis and secretion peristalsis and secretion
Sigmoid colon, rectum and anus	sympathetic  parasympathetic	alpha beta muscarinic	constriction of sphincter muscles inhibition of peristalsis and secretion peristalsis and secretion
Bladder	sympathetic  parasympathetic	alpha beta muscarinic	contraction of sphincter relaxation of detrusor muscle contraction of detrusor muscle
Penis	sympathetic parasympathetic	- muscarinic	ejaculation erection
Clitoris	parasympathetic	muscarinic	erection
Uterus	sympathetic	alpha beta	contraction relaxation
Blood vessels in:			
Skin	sympathetic	alpha	constriction
Muscle	sympathetic	cholinergic	dilation
Sweat glands except palm of hands	sympathetic	muscarinic	sweating
sweat glands on palms of hands	sympathetic	alpha	sweating

Arector pili muscles at root of body hair	sympathetic	alpha	piloerection (making hair "stand on end")
Adipose tissue	sympathetic	beta	lipolysis (break down of fat to release energy)

## Review Questions Chapter 11

1. The middle layer of meninges is called:
  - a. Pia mater
  - b. Dura mater
  - c. Arachnoid mater
  - d. Visceral mater
2. This structure lies between the arachnoid and pia mater:
  - a. Epidural space
  - b. Spinal cord
  - c. Subarachnoid space
  - d. Choroid plexus
3. White matter in the spinal cord is divided into:
  - a. Triangles
  - b. Funiculi
  - c. Horns
  - d. Dendrites
4. Which spinal tract carries pain and temperature information:
  - a. Spinocerebellar
  - b. Fasciculus gracilis
  - c. Lateral spinothalamic
  - d. Rubrospinal
5. Which of the following tracts carry fibers that do not cross in the spinal cord:
  - a. Spinothalamic
  - b. Fasciculus cuneatus
  - c. Spinocerebellar
  - d. Fasciculus gracilis
6. Which of the following tracts carries motor information for posture and coordination:
  - a. Corticospinal
  - b. Spinothalamic
  - c. Rubrospinal
  - d. Reticulospinal
7. Which branch of a spinal nerve is considered the autonomic nervous system branch:
  - a. Dorsal
  - b. Visceral
  - c. Ventral
  - d. Recurrent menigeal

8. Which of the following brain structures helps to regulate sleep/wake cycles:
  - a. Superior colliculus
  - b. Pons
  - c. Reticular formation
  - d. Medulla oblongata
9. Which is the most superior portion of the brainstem:
  - a. Pons
  - b. Midbrain
  - c. Medulla oblongata
  - d. Cerebral aqueduct
10. Which of the following is considered the middle portion of the cerebellum:
  - a. Vermis
  - b. Flocculonodular lobe
  - c. Lateral hemispheres
  - d. Arbor vitae
11. This structure consists of a tree-like arrangement of white matter:
  - a. Vermis
  - b. Flocculonodular lobe
  - c. Lateral hemispheres
  - d. Arbor vitae
12. This structure is a stalk-like projection that connects the hypothalamus with the pituitary gland:
  - a. Mamillary body
  - b. Superior colliculi
  - c. Infundibulum
  - d. Inferior colliculi
13. Folds on the surface of the cerebrum are known as:
  - a. Sulci
  - b. Gyri
  - c. Rugae
  - d. Cerebri
14. Which of the following lobes primarily processes information related to concentration, planning and problem solving:
  - a. Temporal
  - b. Occipital
  - c. Frontal
  - d. Parietal

15. Which lobe primarily processes information related to vision:
- Temporal
  - Occipital
  - Frontal
  - Parietal
16. The central sulcus divides which 2 lobes:
- Frontal, occipital
  - Parietal, temporal
  - Both parietal
  - Frontal, parietal
17. Which structure connects the 3<sup>rd</sup> and 4<sup>th</sup> ventricles of the brain:
- Cerebral aqueduct
  - Interventricular foramen
  - Choroid plexus
  - Arachnoid villi
18. Which structure reabsorbs CSF:
- Choroid plexus
  - Cerebral aqueduct
  - Arachnoid villi
  - Pia mater
19. Which cranial nerve is responsible for moving facial muscles:
- Trigeminal
  - Facial
  - Spinal accessory
  - Hypoglossal
20. Which cranial nerve carries information for taste from the anterior 2/3 of the tongue:
- Vagus
  - Facial
  - Hypoglossal
  - Trigeminal
21. Which cranial nerve carries information regarding balance and equilibrium:
- Vagus
  - Trigeminal
  - Vestibulocochlear
  - Spinal accessory

22. Which cranial nerve is motor to the trapezius muscle:

- a. Trigeminal
- b. Spinal accessory
- c. Facial
- d. Vagus

23. Which cranial nerve is motor to the tongue:

- a. Spinal accessory
- b. Facial
- c. Hypoglossal
- d. Vagus

24. Most post-ganglionic parasympathetic neurons secrete the neurotransmitter:

- a. Norepinephrine
- b. Acetylcholine
- c. Epinephrine
- d. Dopamine

25. Which of the following is not an effect of the sympathetic nervous system:

- a. Pupils dilate
- b. Heart rate increases
- c. Respiration increases
- d. Digestion increases

# Chapter 12

## Nervous System Physiology



## **Nervous System Physiology**

The nervous system is incredibly complex. It controls an astronomical number of functions including the majority of body systems, emotions and cognitive processes such as memory, learning, thinking and decision making.

You may think that learning about how the nervous system works is a daunting task and it can be depending on how deep you go. But it is important to first understand the basics. That's where we will begin this chapter.

### **The Big Picture**

In the last chapter we presented a story about spilling coffee on my hand. We can learn a lot about the nervous system by examining just how my nervous system processes the information about spilling coffee.

Let's review the story and embellish it a bit. I am happily driving my car during my morning commute. It is a cold morning and I decide that I would like to get a nice warm cup of coffee. I pull up to the drive through window of a local fast food establishment and order my coffee. The attendant hands the cup to me as I reach out my driver's side window. As I pull the cup toward me the lid pops off and the coffee spills on my hand and wrist. I quickly put the cup down and nurse my slightly burnt hand. I feel slightly panicked as well.

### **Flow of Information through the Nervous System**

We need to think of the nervous system in terms of information flow. Information about the temperature of the coffee and pressure of the cup are collected by sensory receptors in the skin of my hand and wrist. The information is converted to electrochemical impulses that flow via afferent pathways to the spinal cord. The information flows through the spinal cord to my brain where I realize that my hand is burning. I make a decision in my brain to set the cup down. The information flows from my brain to my spinal cord and back out via an efferent pathway to the muscles of my arm and hand. I then set the cup down.

### **Information Flows from Neuron to Neuron**

The primary cell that carries information in the nervous system is called the neuron (fig. 12.1). The basic parts of a neuron include the cell body, dendrites and the long axon. There are a number of different types of neurons. The main neuron we will be concerned with is the multipolar neuron (figs. 12.2, 12.3). This neuron has a number of processes extending from the cell body with one being the axon. Other types of neurons include bipolar and unipolar neurons (figs. 12.4).

Bipolar neurons have two processes extending from their cell bodies. One is a dendrite and the other an axon. These are found in the special senses such as the eye, ear and nose.

Unipolar neurons have one process extending from their cell bodies. On one side the process branches into dendrites. The other side enters the brain or spinal cord. The cell bodies sometimes reside in ganglia.

## Structure of a Typical Neuron

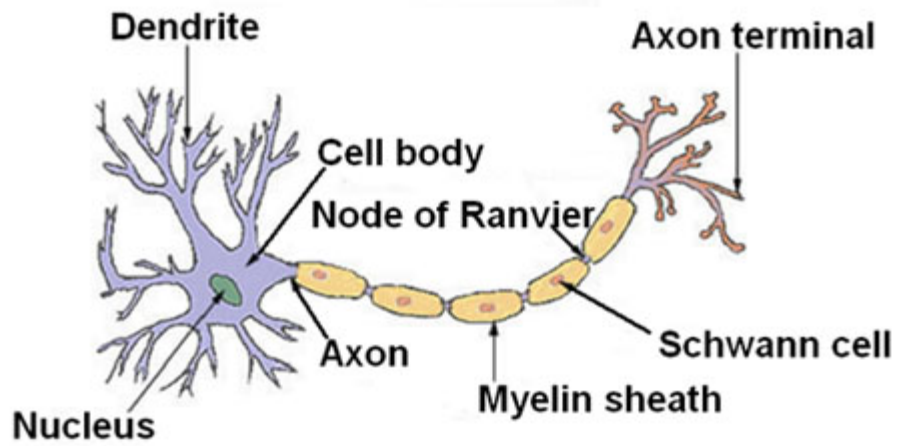


Fig. 12.1 Neuron

<http://commons.wikimedia.org/wiki/File:Neuron.jpg>

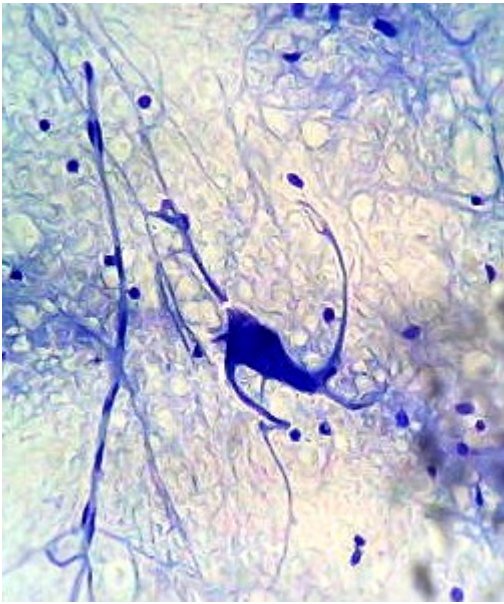

Figure 12.2. Multipolar Neuron.

<http://commons.wikimedia.org/wiki/Image:Neuronehisto.jpg>

Author: Fanny CASTETS

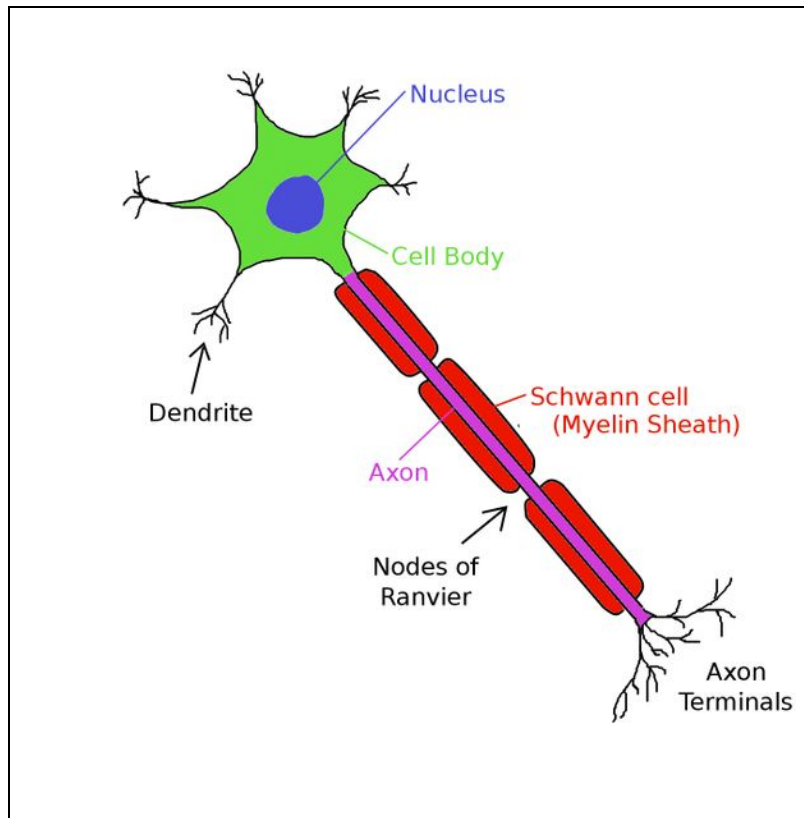


Figure 12.3. Multipolar neuron.

<http://commons.wikimedia.org/wiki/Image:Neuron1.jpg>

Author: [Nick Gorton](#)

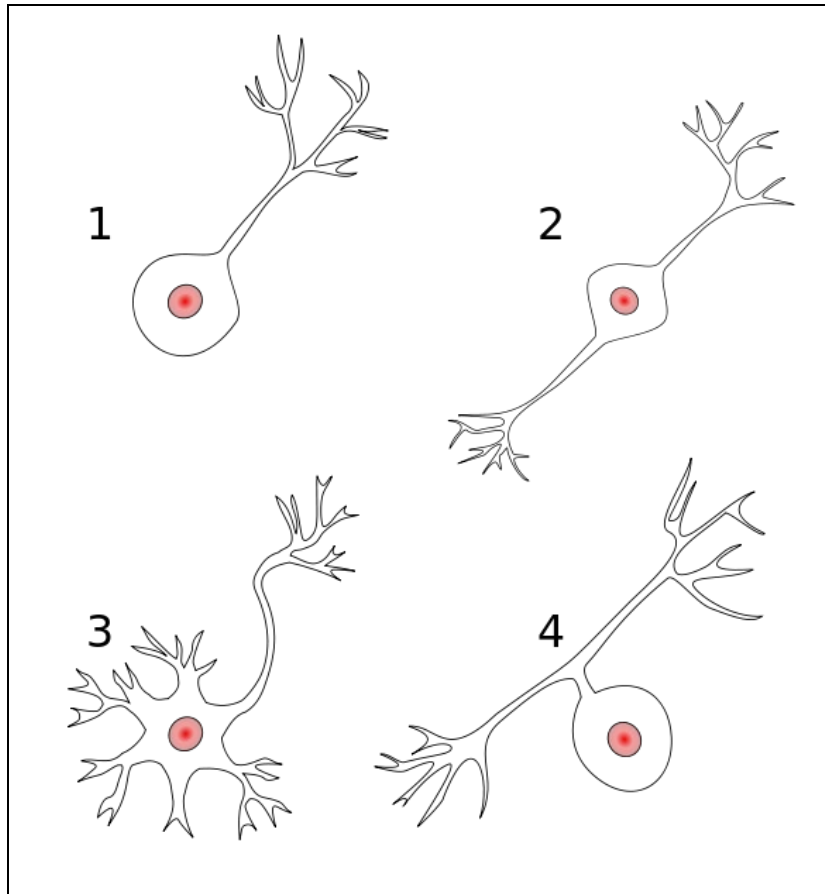


Fig. 12.4 Types of Neurons

1: Unipolar neuron

2: Bipolar neuron

3: Multipolar neuron

4: Pseudounipolar neuron

[http://commons.wikimedia.org/wiki/File:Neurons\\_uni\\_bi\\_multi\\_pseudouni.svg](http://commons.wikimedia.org/wiki/File:Neurons_uni_bi_multi_pseudouni.svg)

Neurons have a number of other parts. The cell body or perikaryon contains many of the cell organelles we described in chapter bk. These include mitochondria, microtubules, Golgi apparatus, and a granular cytoplasm. The cell body also contains Nissl Bodies which are membranous packets of chromatophilic substance consisting of rough endoplasmic reticulum (remember, this makes proteins).

Some neurons are myelinated (white matter). Their axons are surrounded by a covering of myelin. In the peripheral nervous system a type of cell called a Schwann cell is responsible for producing the myelin sheath.

Axons connect to the cell bodies of neurons via the axon hillock. The axon hillock is important in the process of producing an electrical stimulus called an action potential. The axon hillock has a large number of sodium and potassium gated channels. Axon terminals are located at the distal ends of axons. The axon terminals contain synaptic vesicles containing neurotransmitter.

### Neuroglia

The nervous system also contains cells that support neurons called neuroglia. There are a few different types of neuroglia that have a number of important functions.

Astrocytes work to provide structural support and may also help in regulating electrolytes within the interstitium (fig. 12.6). They are star shaped and can be found between neurons and blood vessels. Astrocytes help to maintain the blood-brain barrier. They also help to repair damaged areas in the central nervous system by forming scar tissue.

Oligodendrocytes produce the myelin that surrounds white matter axons in the brain and spinal cord.

Ependymal cells form the lining of the central canal and ventricles in the spinal cord and brain. They are also found in the choroid plexi of the brain. They help to produce CSF by providing a porous membrane for blood plasma to pass through.

Microglia are very small cells that are located throughout the central nervous system. They provide support and help to clean up debris through phagocytosis.

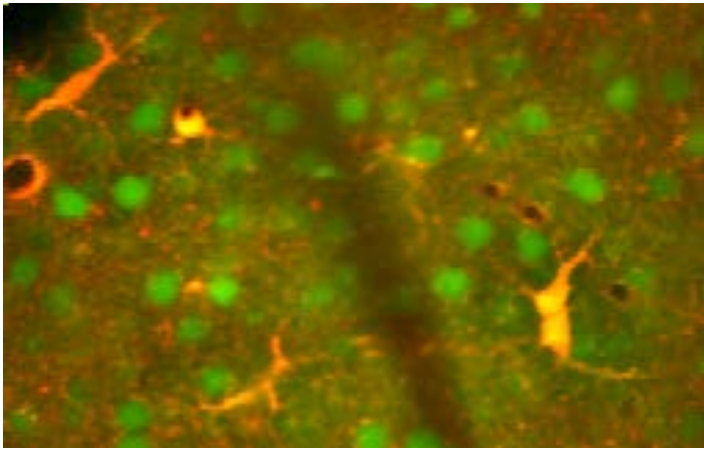


Figure 12.6. Astrocytes (green) in a mouse cortex.

<http://commons.wikimedia.org/wiki/Image:Astrocytes-mouse-cortex.png>

Author: Mark Histed

## Real World A&P Blog Post

### Glial Cells May be More than Mere Support Cells

The lowly glial cell may soon shed its title as a “support cell” to the mighty neuron. For many years anatomy and physiology texts relegated the glial cells to servant status. They performed basic functions such as repairing damaged areas of the nervous system, producing myelin, regulating electrolytes and so on.

Glial cells have recently generated interest as they are involved in many brain tumors and degenerative diseases such as Alzheimers. Now scientists are unraveling a complex relationship between glial cells and neurons. Glial cells may be more involved in processing information than previously thought. Since glial cells make up 90% of all of the cells of the brain this may present a whole new dimension of complexity.

Areas of research include how glial cells modulate neuronal activity, signaling between glial cells, and glial regulation of blood flow. Recently research conducted at Rockefeller University demonstrated that neurons developed abnormally in the absence of glial cells. In fact when deprived of glial cells, a *C. elegans* (worm) entire brain developed abnormally. Glial cells may play an important role in the development of the nervous system.

Reference:

Yoshimura et al. **mls-2 and vab-3 control glia development, hlh-17/Olig expression and glia-dependent neurite extension in *C. elegans*.** *Development*, 2008; 135 (13): 2263 DOI: [10.1242/dev.019547](https://doi.org/10.1242/dev.019547)

## How Neurons Communicate

### Resting Membrane Potential

The nervous system is one vast information network. Neurons send messages to others that can either stop the message or pass it along. Next we will examine how neurons communicate. We will begin by learning about a concept known as resting membrane potential.

Neurons, like many other cells in the body, do not exist at equilibrium with their surroundings. In fact there is a net negative charge on the inside of the neuron with respect to the outside. This negative charge exists mostly because of differences in membrane permeability to different electrolytes. It turns out that the cell membranes of neurons are slightly permeable to sodium and potassium. Although they are permeable to both sodium and potassium they are slightly more permeable to potassium.

There are also a number of negatively charged ions inside of the neuron's cell membrane. These include phosphates, sulfates, ATP, RNA and proteins. These negatively charged ions cannot leave the cell. So if potassium (which is positively charged) is allowed to move out of the cell, then the inside of the cell becomes more negative (due to the presence of the negative ions) than the outside of the cell.

As this ionic gradient increases some positive ions are attracted back into the cell. Eventually the cell reaches a steady state by which potassium diffuses out of the cell at the same rate that it moves into the cell via the ionic gradient.

There is much more sodium outside of the cell than inside. The neuron's cell membrane is not very permeable to sodium so just a little sodium moves into the cell via its concentration gradient. We also have the sodium-potassium pump working to maintain both sodium and potassium gradients by moving sodium out of the cell and potassium into the cell.

Remember that the sodium-potassium pump requires energy in the form of ATP. The nervous system has a lot of these pumps in order to function. In fact about 70% of the energy used by the nervous system is used by the sodium-potassium pumps.

So, if we put all of these effects together we end up with a net negative charge on the inside of the cell with respect to the outside. This negative charge is approximately -70 millivolts (mV) and is called resting membrane potential.

### Depolarization

Neurons communicate by sending chemical messages from one neuron to another. These chemicals are called neurotransmitters. The neurotransmitters move from one neuron to another across an area known as the synaptic cleft. The neuron sending the message is called the presynaptic neuron. The neuron receiving the message is called the post-synaptic neuron.

Once the neurotransmitter floats across the synaptic cleft it attaches to a receptor on the post-synaptic neuron. There are two possible messages carried by neurotransmitters. One is to trigger the post-synaptic neuron to send another message. This essentially moves the information forward. The other possible message is to inhibit the post-synaptic neuron (hold the information back).

In order to trigger the post-synaptic neuron the neurotransmitter will cause the opening of sodium gates on the post-synaptic neuron. In other words the presynaptic neuron is said to be excitatory. When the sodium gates open sodium rushes into the neuron. This changes the potential by making it less negative



due to the positive sodium ions rushing into the cell. We say the cell is depolarizing. Remember that the resting membrane potential is negative (-70mV). In other words the cell is polarized to begin with. Once the sodium gates open causing the cell to become less negative there is less polarization. So the cell is depolarizing with the opening of sodium gates.

### **Threshold**

If the stimulus is strong enough to cause enough of a change in potential to reach a certain level the neuron will react by opening more sodium gates and depolarizing at a rapid rate. In neurons the level is at about -55mV. In other words if a stimulus is great enough to cause a neuron to depolarize to -55 mV then we say that it has reached the threshold. Once the neuron reaches the threshold it will continue to depolarize to about +30 mV. The rapid change in potential from -55 mV to +30mV is called an action potential. This is called the all or none principle which means that once the threshold is reached the neuron continues through the cycle of depolarization and repolarization to resting membrane potential (fig. 12.7).

### **Action Potentials**

Action potentials are generated at the axon hillock of neurons. There are a large number of sodium gates that react to changes in membrane potential. These sodium gates are called voltage-gated sodium channels because they open in response to a change in membrane potential. When a stimulus causes depolarization to the threshold the voltage-gated sodium channels open causing more voltage-gated channels to open resulting in a large influx of sodium into the cell. The action of sodium channels causing more sodium channels to open is a positive feedback system.

Voltage-gated potassium channels also open at the same time as the sodium channels. The potassium channels work more slowly than the sodium channels. The result is that some potassium diffuses out of the cell but much more sodium diffuses in.

After the maximum depolarization is reached at about +30mV-+40mV the sodium gates close and the potassium gates remain open allowing potassium to diffuse out of the cell. This causes the membrane potential to become more negative. This occurs until the resting membrane potential is reached.

### **Afterpotential**

Some neurons become slightly more negative for a brief time after an action potential. This is due to the voltage-gated potassium channels remaining open beyond the normal resting membrane potential. Once the potassium channels close the cell returns to resting membrane potential. The sodium-potassium pump also helps to restore and maintain resting membrane potential.

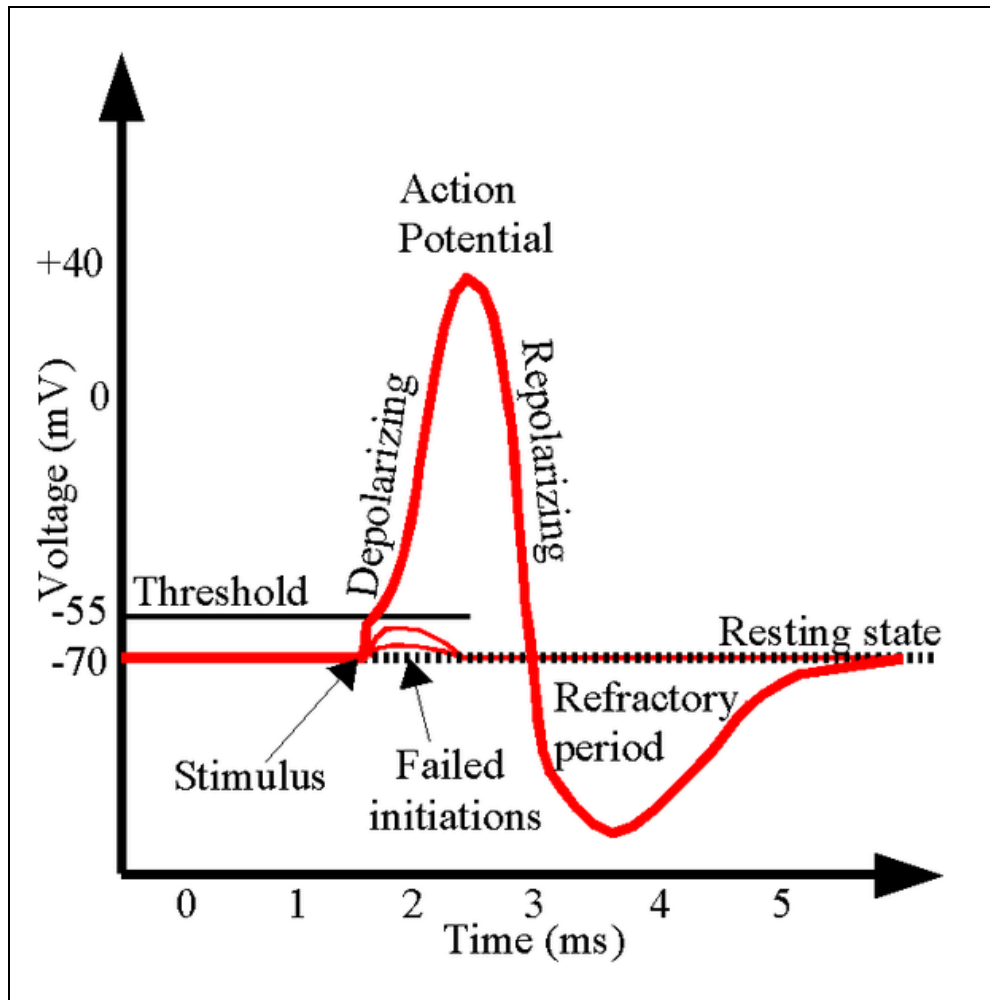


Figure 12.7. Events of an action potential.

<http://commons.wikimedia.org/wiki/Image:ActionPotential.png>

### Refractory Periods

Once an action potential is generated the neuron will not respond to further stimuli for a period of time. This is known as the refractory period. There are two parts to this period. The first part is known as the absolute refractory period. During this time the neuron will not respond to any additional stimulus. The absolute refractory period occurs when the neuron is depolarizing due to the opening of sodium gates and continues to near the end of the repolarization phase. The second part is known as the relative refractory period. During this time the neuron will respond to a strong stimulus. Potassium channels are open during this time.

The absolute refractory period ensures that neurons will not enter a state of continuous depolarization. It also sets a limit as to the frequency of action potentials generated.

## **Stimuli**

Neurons are stimulated by neurotransmitters. The secretions of neurotransmitters can cause a graded response in membrane potentials. In other words one neuron may send a certain amount of neurotransmitter to another neuron that is not strong enough to depolarize the second neuron to the threshold. This is called a subthreshold stimulus. If the same neuron continues to secrete more neurotransmitter the second neuron may reach threshold and stimulate an action potential. This is called a threshold stimulus. The second neuron will respond to a threshold stimulus by generating one action potential. If the first neuron continues to secrete more neurotransmitter the second neuron will continue to generate action potentials at a maximal frequency. This is called a maximal stimulus. If the stimulus is even stronger the second neuron will respond by continuing to generate action potentials at the maximal frequency. This is known as a supramaximal stimulus. A stimulus between the threshold and maximal stimulus is known as a submaximal stimulus.

The action potential frequency and strength of stimuli are thus related.

## **Propagation of Action Potentials**

Once an action potential is generated at the axon hillock it will be transmitted by the axon to the end of the axon terminals at the end of the axon. We say the action potential propagates down the axon. This occurs much like a row of dominos falling over. One section of the axon stimulates the next causing another action potential which stimulates the next section and so on. Another way to think of this process is as a wave of depolarization that moves down the axon. The process of propagation occurs because of local currents generated in adjacent sections of the axon. The outside of the axon's membrane becomes more negative as positive ions move inside the cell. At the same time the inside of the cell becomes more positive. The adjacent section has the opposite characteristics setting up a current that influences it. The action potential only moves in one direction because of the absolute refractory period. This method of propagation occurs in unmyelinated axons (fig. 12.8).

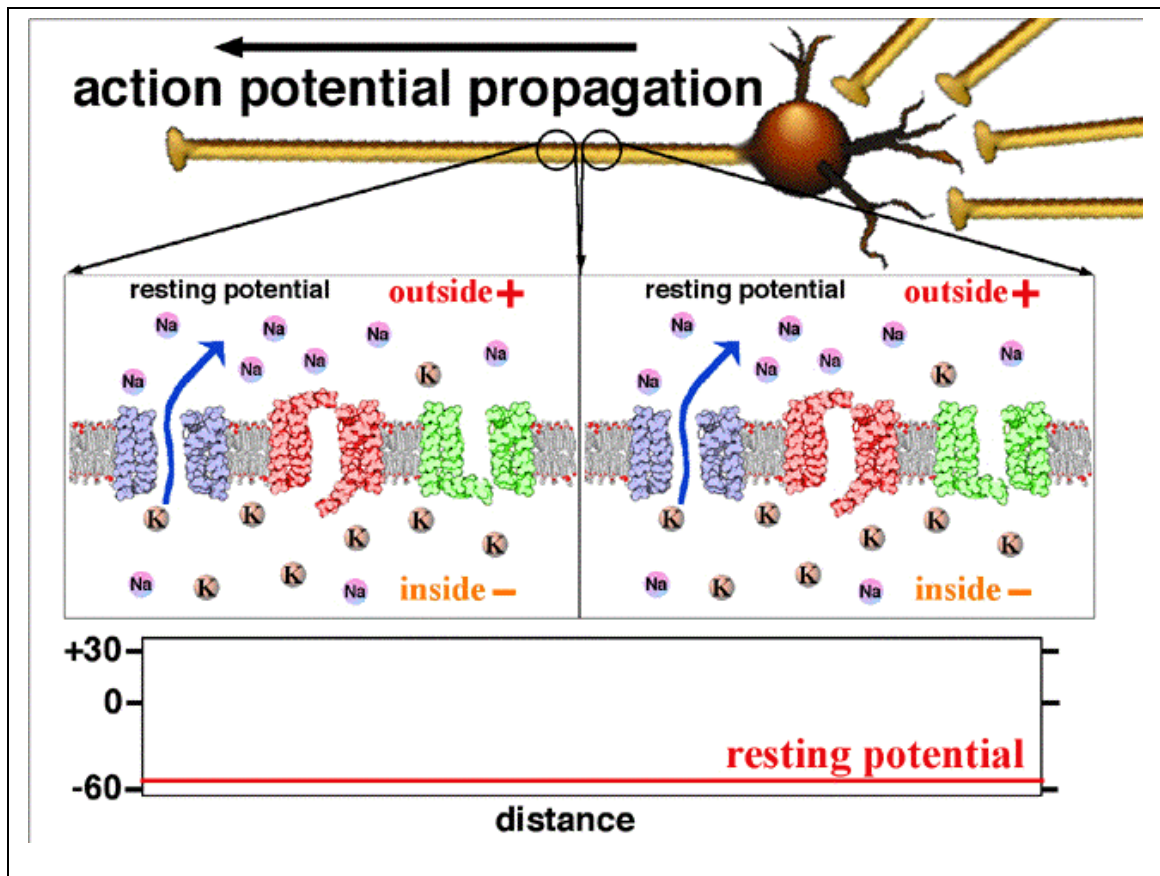


Figure 12.8. Propagation occurs from local currents.

[http://commons.wikimedia.org/wiki/Image:Action\\_potential\\_propagation\\_animation.gif](http://commons.wikimedia.org/wiki/Image:Action_potential_propagation_animation.gif)

Author: John Schmidt

## Saltatory Conduction

Myelinated axons contain Schwann cells that produce myelin. The myelin is discontinuous with gaps called Nodes of Ranvier. Myelin is a lipid substance that acts as an insulator. This causes the action potential to move from one Node of Ranvier to the next. The nodes contain a high concentration of sodium gates. The action potential then appears to jump from node to node. This type of conduction is called saltatory conduction (fig. 12.9).

Action potentials move much faster in myelinated versus unmyelinated axons. Let's illustrate this with an analogy. We have two rows of students with 12 students in each row. The student at the end of each row has a ball and has to get it to the student to the other end of the row as quickly as possible. The first row is given instructions to pass the ball from one student to the next until reaching the last student. The second row is told to throw the ball to the 4<sup>th</sup> student who then throws it to the 8<sup>th</sup> student and so on until reaching the 12<sup>th</sup> student at the end of the row. The instructor tells the students to begin at the same time. Which row will win the race? Obviously the second row wins because time is lost with the handling of the ball by every single student in the row versus every 4<sup>th</sup> student. The first row then represents an unmyelinated axon while the second row represents a myelinated axon.

The speed of conduction also relies on the thickness of the myelin sheath as well as the diameter of the axon. Greater myelination and larger diameter axons conduct action potentials faster. Nerve fibers are classified according to their size. Type A fibers are large diameter myelinated fibers that quickly conduct action potentials (15-120 meters/second). Examples of type A fibers include sensory neurons and motor neurons to skeletal muscles.

Type B fibers are medium diameter myelinated fibers that conduct action potentials more slowly than Type A fibers. Type B fibers can conduct action potentials from 5-15 meters/second. Type C fibers have a small diameter and are unmyelinated fibers that conduct action potentials at 2 meters/second or less. Type B and C fibers are found in the autonomic nervous system.

# Saltatory Conduction

Action potential appears to jump from node to node.

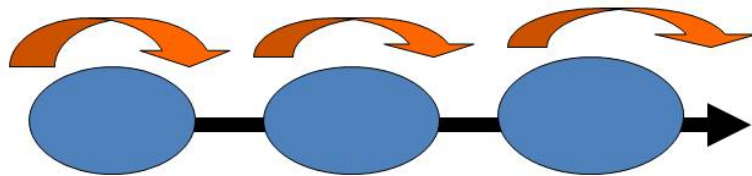


Figure 12.9. Saltatory conduction.

Bruce Forciea

## Release of Neurotransmitter

The result of an action potential is the release of a neurotransmitter from a neuron. This occurs at the distal end of the axon at an area called the axon terminal. Axon terminals contain small packets of neurotransmitters called synaptic vesicles. Action potentials cause voltage-gated calcium channels to open allowing calcium to diffuse into the axon terminal. Calcium causes the synaptic vesicles to attach to the cell membrane and release their neurotransmitters via exocytosis. The neurotransmitters are released into the synaptic cleft or space between the presynaptic and post-synaptic neurons. They diffuse into the cleft and attach to receptors on the membrane of the post-synaptic membrane.

Once neurotransmitters attach to the post-synaptic membrane they can elicit one of two responses. They can either depolarize the post-synaptic membrane by causing sodium gates to open or hyperpolarize the membrane by causing potassium or chloride gates to open.

After neurotransmitters attach to receptors on post-synaptic membranes they are quickly degraded. There are two primary methods of degradation. One method involves enzymes in the post-synaptic membrane breaking down the neurotransmitter and allowing it to be recycled. For example

acetylcholine is broken down by acetylcholinesterase in the post-synaptic membrane into choline and acetic acid. Choline is transported back to the presynaptic membrane and combines with acetyl coenzyme A to form acetylcholine. Acetic acid is used to synthesize acetyl coenzyme A.

The other method of degradation involves the neurotransmitter moving back to the presynaptic axon terminal where it is recycled. This method is called reuptake. Norepinephrine is transported back into the presynaptic terminal and is recycled or degraded by the enzyme monoamine oxidase (fig. 12.10).

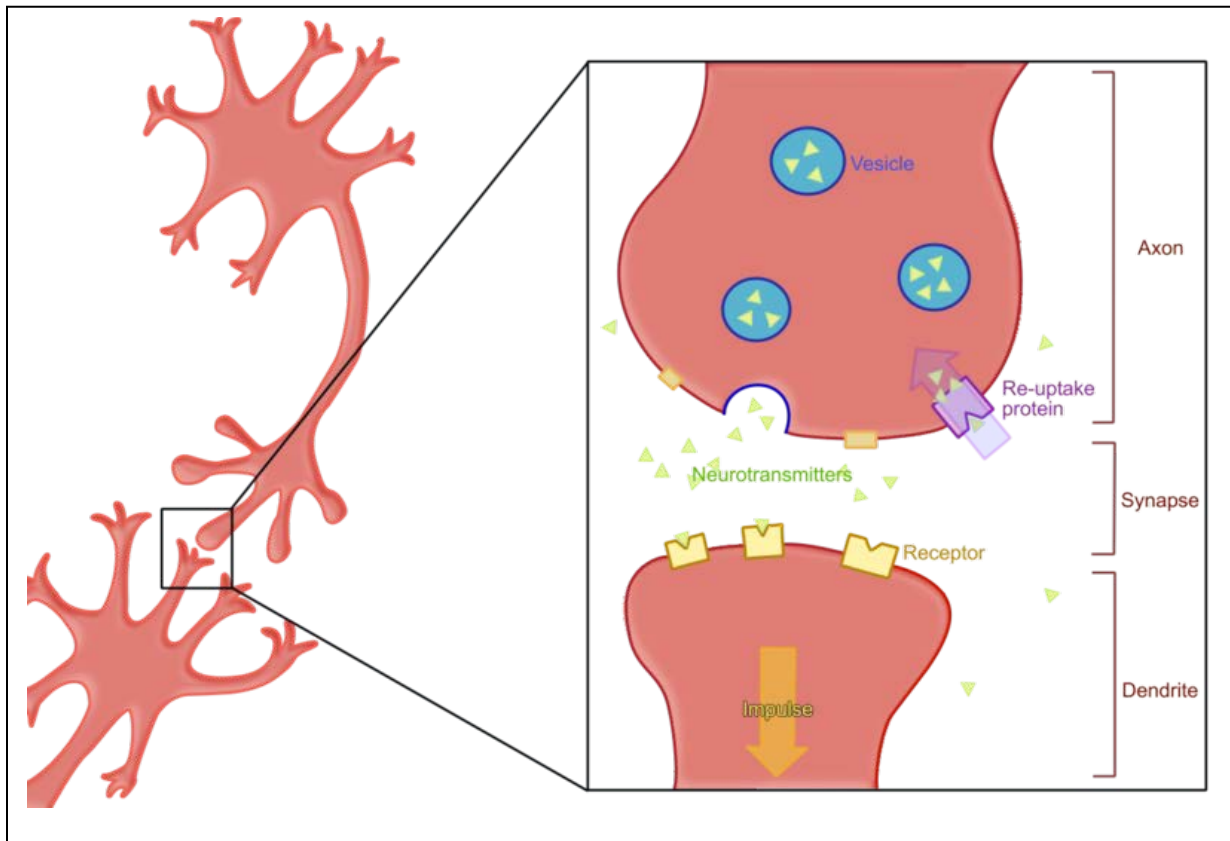


Figure 12.10. Reuptake of a Neurotransmitter.

[http://commons.wikimedia.org/wiki/Image:Reuptake\\_both.png](http://commons.wikimedia.org/wiki/Image:Reuptake_both.png)

It is important not to generalize the effects of neurotransmitters. There are a variety of receptors that can either depolarize or hyperpolarize membranes for a given neurotransmitter. For example norepinephrine can attach to one type of receptor that causes depolarization or a different type of receptor that causes hyperpolarization. Receptors can also exist on presynaptic membranes. For example norepinephrine receptors on the presynaptic membrane can inhibit the release of more neurotransmitter. This allows some neurotransmitters like norepinephrine to control its own release.

### **Excitatory and Inhibitory Potentials**

There are only two responses a post-synaptic neuron can elicit from neurotransmitters. It can either depolarize or hyperpolarize. Depolarization leads to the production of an action potential so we say the post-synaptic potential is excitatory (excitatory post-synaptic potential EPSP). Likewise if the post-synaptic neuron becomes hyperpolarized in response to a neurotransmitter there is a less likelihood that an action potential will be generated. We say the potential is inhibitory (inhibitory post-synaptic potential IPSP).

Many presynaptic neurons can synapse with one post-synaptic neuron. The effects of these multiple inputs sum to either facilitate or inhibit the production of an action potential. There are two ways in which summation occurs. Spatial summation occurs when multiple presynaptic neurons synapse with one post-synaptic neuron at the same time. Temporal summation occurs when multiple presynaptic neurons synapse with one post-synaptic neuron in a short amount of time. The first neurotransmitter may cause sodium gates to open on the post-synaptic membrane to allow it to depolarize. The second neuron then continues to stimulate the same post-synaptic neuron to depolarize.

### **Neuron Pathways and Networks**

The nervous system is immensely complex. One neuron can have input from thousands of other neurons to form complex networks. There are however three basic structures that are formed.

One structure consists of many neurons synapsing with fewer and fewer neurons. This is known as a convergent network. Think of how many neurons it takes to make a decision to contract a muscle. The many neurons involved in making the decision converge to a few neurons that control the muscle.

Another structure consists of smaller numbers of neurons synapsing with larger numbers. This is known as a divergent network. An example would be how sensory input from a sensory receptor can synapse with multiple neurons in the central nervous system that produce the sensation and may involve decision making.

Some networks involve feedback systems where the outputs feed back into inputs. These are known as oscillating networks. Oscillating networks help to prolong an action caused by a stimulus. Actions that are cyclical such as respiration may be controlled by oscillating circuits.

### **Reflexes**

The nervous system is capable of performing extremely complex processing of information. Thought processes can take millions or billions of synapses. The nervous system can also perform very simple processes using just a few neurons. These reflexes are automatic responses to stimuli. They can be classified as either somatic or autonomic. Somatic reflexes protect the body from painful stimuli by causing movement away from it. Autonomic reflexes support homeostasis by maintaining body



processes such as blood pressure, heart rate, respiration and urine formation. We will begin by examining somatic reflexes.

Health care providers will often use reflexes in assessing the nervous and muscular systems. The quintessential knee jerk reflex is an example of a simple reflex used to check the neural pathway between the muscle, spinal cord and brain. The knee jerk reflex is often referred to as a deep tendon reflex (DTR). There are many DTRs and they can be understood by examining one in detail.

### **The Reflex Arc**

Reflexes are involuntary responses to stimuli that occur unconsciously. The deep tendon reflex consists of a muscle, nerve pathway and the spinal cord. The muscle contains a sensory receptor that senses changes in stretch of the muscle. This receptor is called a muscle spindle. The muscle spindle contains motor neurons called gamma motor neurons. These neurons begin in the spinal cord and extend to the muscle spindle.

When the tendon of the muscle is tapped by a reflex hammer the muscle spindle senses the change in length of the muscle and sends a message via a sensory neuron (usually in a spinal nerve) to the spinal cord. There it synapses with a motor neuron (again in a spinal nerve) that sends a message to the muscle to contract (fig. 12.11).

Spinal reflexes are also influenced by the central nervous system. Upper motor neurons extend from the brain to the spinal cord. These neurons have an inhibitory effect on reflexes. Lower motor neurons extend from the spinal cord to the muscle. One reason for eliciting reflexes is to differentiate an upper motor neuron versus lower motor neuron problem.

If the nervous system is intact then the reflex will look normal. This means the brain is providing an inhibitory effect on the reflex. In other words the brain is inhibiting the reflex so it appears normal. The reflex will look exaggerated with damage to upper motor neurons. This occurs in stroke victims.

Diminished or absent reflexes will result from problems with lower motor neurons. In other words the pathway between the spinal cord and muscle is damaged so the signal cannot get through. This occurs in peripheral nerve problems such as spinal disc ruptures, spinal stenosis and demyelinating disorders.

### **More Complex Reflexes**

Reflexes that respond to painful stimuli are more complex due to the involvement of additional neurons in the spinal cord called interneurons. Examples of these include the withdrawal and crossed extensor reflexes.

The withdrawal reflex incorporates additional interneurons that stimulate the ipsilateral flexor muscles in response to a painful stimulus. For example, touching a hot stove will cause the upper extremity flexors to contract causing the arm to withdraw from the burner.

The crossed extensor reflex also involves additional interneurons that stimulate the contralateral extensors as well as the ipsilateral flexor muscles. For example stepping on a nail will cause the lower extremity flexors as well as the contralateral extensor muscles to contract. This allows for further movement away from a painful stimulus.

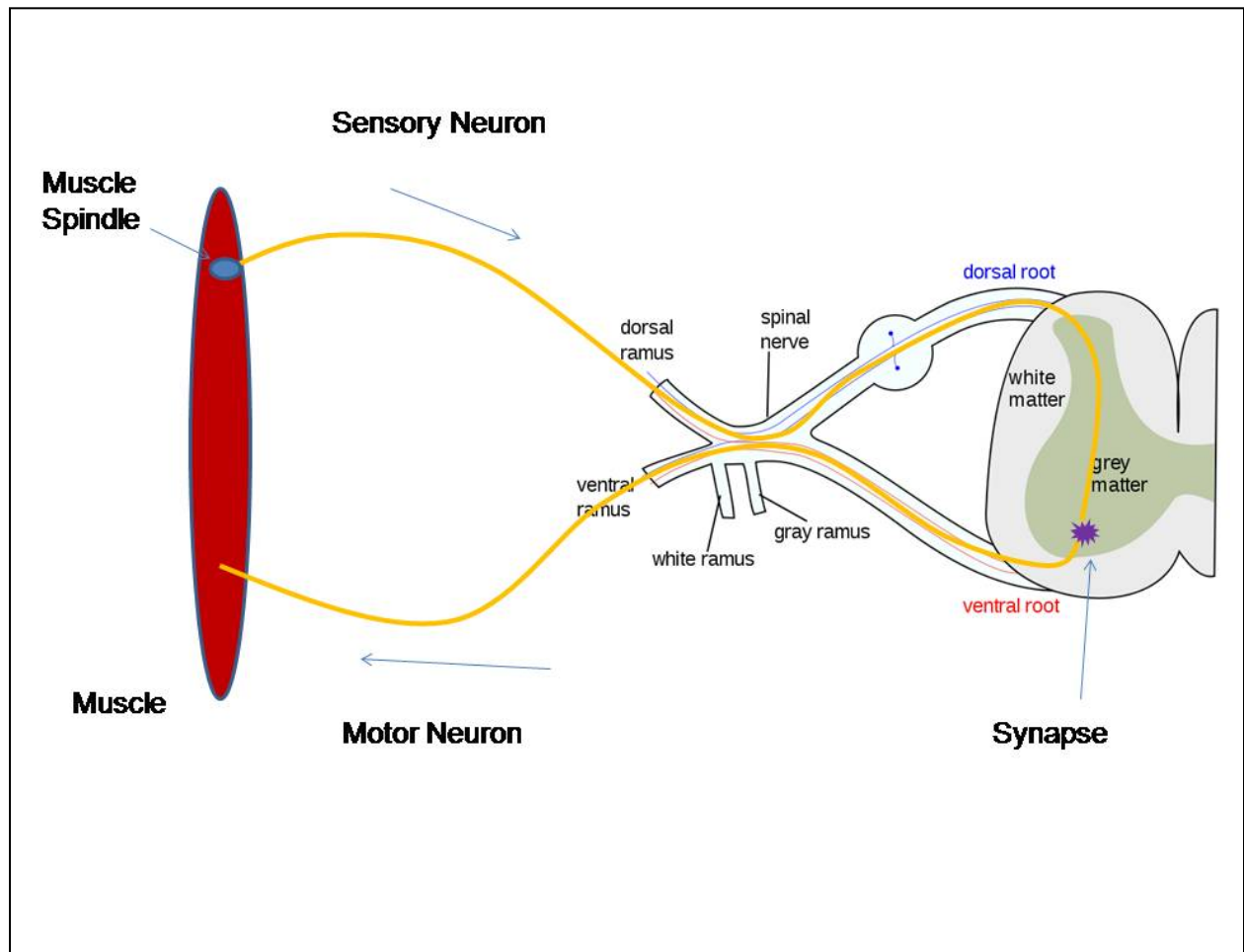


Figure 12.11. Reflex Arc.

Modified by Bruce Forciea from: [http://commons.wikimedia.org/wiki/Image:Spinal\\_nerve.svg](http://commons.wikimedia.org/wiki/Image:Spinal_nerve.svg)  
 Original authors: [Mysid](#) (original by [Tristanb](#))

## Functional Areas of the Cerebral Cortex

More complex information processing occurs in the cerebral cortex. We can now revisit the cerebrum to investigate some of the sensory, motor and association areas.

The cerebrum is divided into lobes. The frontal lobe is separated from the parietal lobe by the a groove on the lateral aspect of the cerebrum called the central sulcus. The cerebrum also consist of folds called gyri. The first gyrus just anterior to the central sulcus on the frontal lobe is called the precentral gyrus. The gyrus just posterior to the central sulcus is called the post-central gyrus on the parietal lobe. The precentral gyrus is also the primary motor area. The post-central gyrus is called the general sensory area.

## **General Sensory Area**

The general sensory area on the parietal lobe processes information about pressure, pain, and temperature. This information comes from neurons synapsing in the thalamus bringing information from spinal tracts to the post-central gyrus.

The general sensory area on the post-central gyrus is organized so that the information coming from the feet is processed on the superior aspect of the gyrus while information from the face is processed on the inferior aspect. The information comes from the contralateral side of the body. A map of the gyrus is called a homunculus (fig. 12.12).

## **Other Sensory Areas**

The taste area is located at the inferior end of the post-central gyrus and base of the frontal lobe. The sense of smell or olfactory area is located on the inferior aspect of the frontal lobe. The sense of hearing (auditory cortex) is located in the superior aspect of the temporal lobe. The sense of vision (visual cortex) is located in the occipital lobe.

## **Association Areas**

Information about recognition is processed in association areas near the sensory areas. Wernicke's area is located in the lateral parietal and temporal lobes. This area performs speech recognition (fig. 12.13).

## **Primary Motor Area**

The primary motor area is located on the precentral gyrus of the frontal lobe. The neurons are arranged in much the same way as the postcentral gyrus with motor information going to the feet in the superior aspect and motor information going to the face in the inferior aspect. The neurons can be functionally mapped on a homunculus as well.

It is important to note the areas on either pre or postcentral gyri are not symmetrical. In other words there are larger areas corresponding to more complex processing. For example the motor area for the hands is much larger than the motor area for the knee. This is due to the amount of information processing needed for fine motor movements of the hand versus the knee.

There is also a premotor area located anterior to the primary motor area. This area works with the primary motor area and works to integrate and organize motor information before sending it to the primary motor area. The premotor area also works with decision making occurring in other parts of the frontal lobe. For example, the decision to pick up an object will be made in the frontal lobe and sent to the premotor area where information about various muscle movements is organized. The premotor area then sends the information to the primary motor area in order to stimulate the precise muscles needed to complete the task. The information is then sent bypassing the thalamus to the descending motor tracts of the spinal cord and consequently out to the muscle effectors via spinal nerves.

Broca's area is located in the left cerebral hemisphere. This area helps to coordinate movements of the mouth, larynx and tongue for speech.

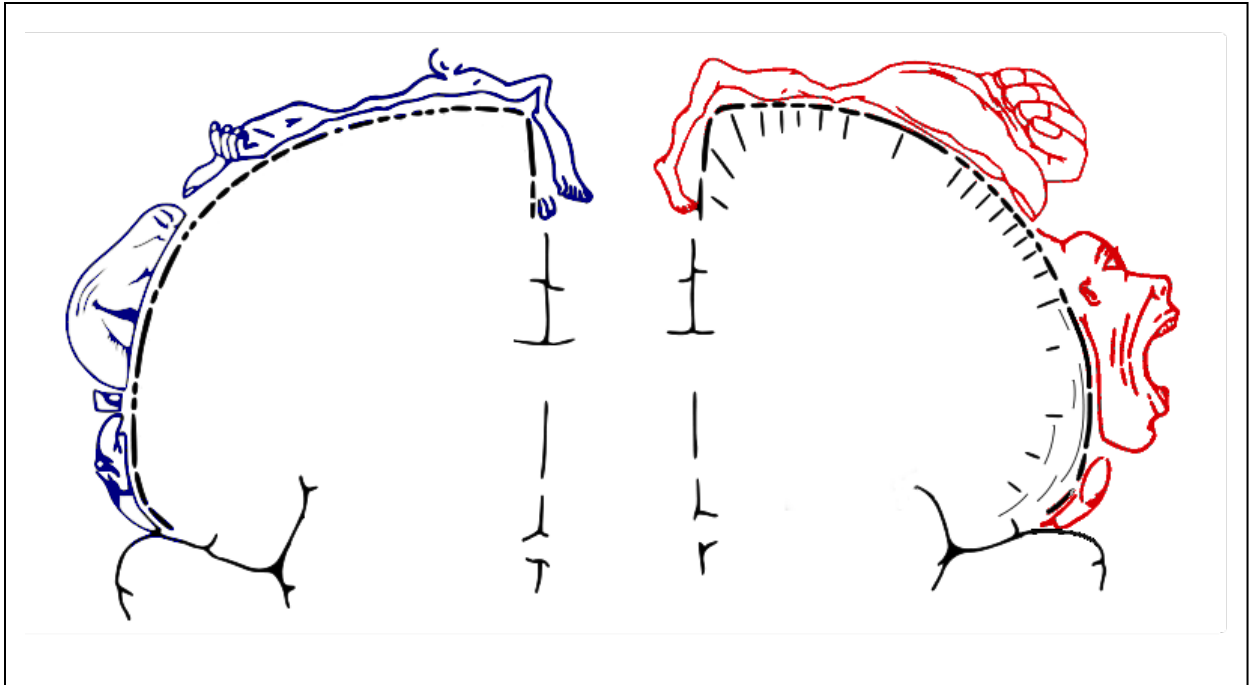


Figure 12.12. Homunculus showing both sensory (blue) and motor (red) areas.

<http://commons.wikimedia.org/wiki/Image:Homunculus.png>

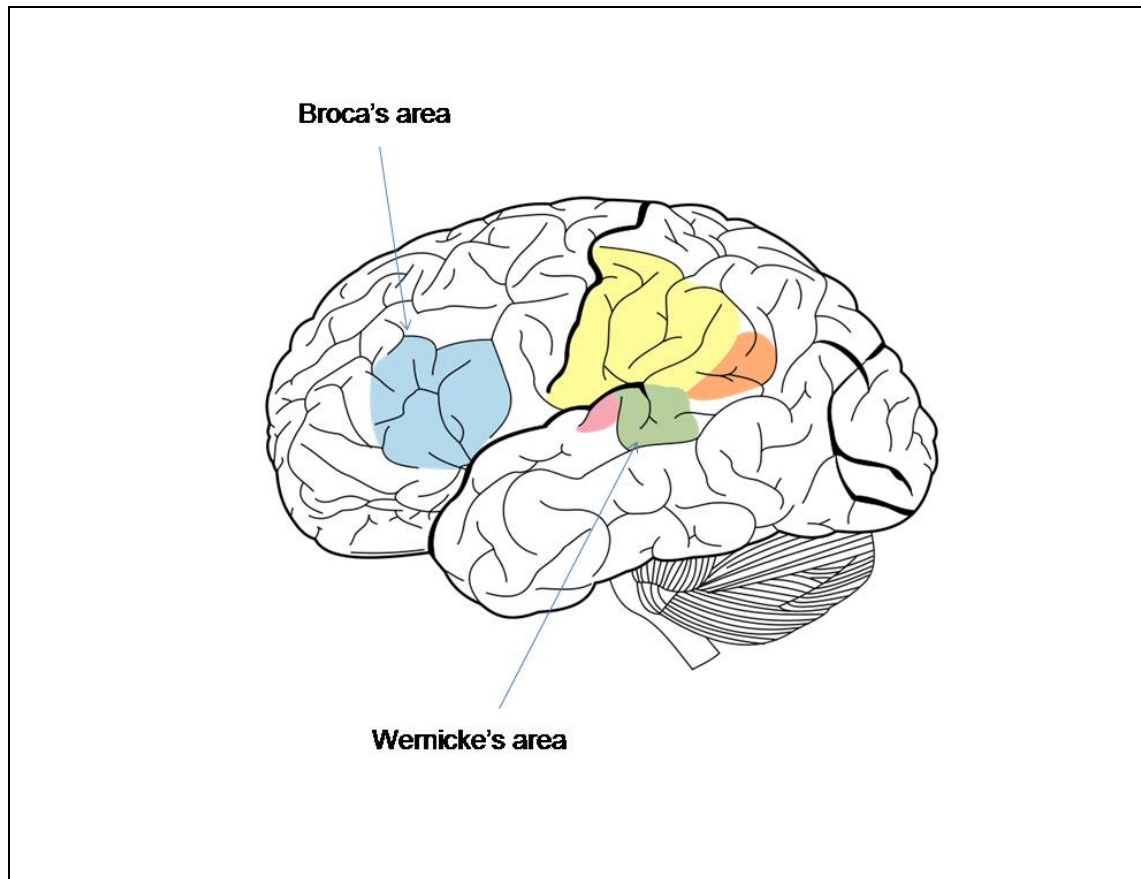


Figure 12.13. Broca's and Wernicke's areas.

[http://commons.wikimedia.org/wiki/Image:Brain\\_Surface\\_Gyri.SVG](http://commons.wikimedia.org/wiki/Image:Brain_Surface_Gyri.SVG)

Modified by Bruce Forciea

## **A Detailed Look at a Sensory Motor Pathway**

### **Spilled Coffee Revisited**

At this point we can take a detailed look at how information flows through the nervous system when spilling a cup of hot coffee on my hand and deciding to put it down.

I pull up to the drive through and reach for the cup of hot coffee. As I grab the cup the lid pops off and hot coffee spills on my hand. The sensory information was picked up by temperature and pressure receptors in my hand. The information was converted to electrochemical information called action potentials by the sensory receptors and sent along afferent pathways called nerve to the spinal cord. The spinal nerves transmit the sensory information via the dorsal roots to the posterior portion of the spinal cord so that it can travel via ascending tracts to the brain.

The first neuron to carry the information from sensory receptor to the spinal cord is called a primary neuron. This neuron synapses with a secondary neuron that carries the information from the spinal cord to the brain.

The temperature information travels via the lateral spinothalamic tract in a secondary neuron. This tract is located in the lateral funiculus of the spinal cord and crosses at cord level to the contralateral side. So if I am holding the cup in my left hand (which I frequently do) then the information travels via a cervical spinal nerve (or nerves) to the spinal cord via the dorsal roots to the spinothalamic tract that crosses over to the right side of the cord.

The information then ascends to the brainstem (medulla oblongata, pons, midbrain) and synapses with a tertiary neuron in the thalamus. The information then goes to the post-central gyrus of the parietal lobe for processing. The parietal lobe sends the information to other areas of the cortex for interpretation and decision making.

The pressure information is picked up by sensory receptors in the skin (Meissner's and Pacinian corpuscles) and sent via a primary neuron to the spinal cord as well. There it synapses with a secondary neuron in the cord and is carried to the thalamus via the dorsal column pathway consisting of the fasciculus gracilis/cuneatus located in the posterior funiculus of the spinal cord. These tracts cross over (decussate) in the medulla oblongata and synapse in the thalamus with a tertiary neuron. This neuron carries the information to the post-central gyrus as well.

Now aside from any reflex activity (withdrawal or crossed extensor) I must interpret the sensory information using association areas in the cortex and make a decision using my frontal lobe to set the cup down. The premotor areas will process the decision and work to coordinate the actions of moving the appropriate muscles of my arm to set the cup down. They will send the information to the precentral gyrus of the frontal lobe.

The information then reaches the prefrontal gyrus (on the right side) of the frontal lobe and travels toward the brain stem bypassing the thalamus. The primary or upper motor neuron here begins in the precentral gyrus and travels via descending spinal tracts after crossing in the medulla oblongata. The descending tracts include the corticospinal tract. The neurons synapse with lower motor neurons in the anterior horn of the spinal cord.

The lower motor neurons carry the information to the skeletal muscles via the ventral root of spinal nerves to spinal nerves to the brachial plexus to terminal nerves to the muscles of my arm and hand. I then can set the cup down.

### Processing in the Brainstem

In addition to carrying impulses to and from the brain the brainstem also processes information. A number of control centers are located in the brainstem. These include centers for controlling heart rate, respiration, digestion, blood gases and electrolytes. The brainstem also contains the nuclei of all of the cranial nerves with the exception of the first cranial nerve (olfactory) and eleventh cranial nerve (spinal accessory). One other important function includes modulating sleep and wakefulness. This occurs in the reticular activating system (RAS) (fig. 12.1).

A number of cranial nerves feed information to the RAS including cranial nerves II, V, and VIII. Information from the cerebrum and limbic system also travels to the RAS as well as ascending sensory information. All of these inputs help to arouse consciousness.

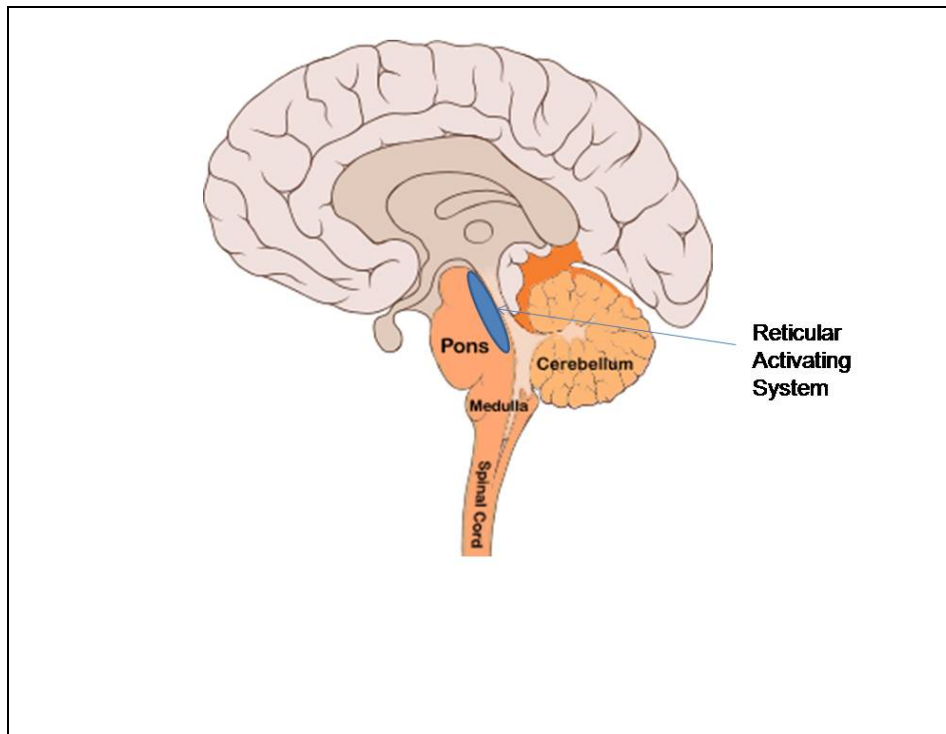


Figure 12.14. The Reticular Activating System

Modified by Dr. Bruce Forciea from: [http://commons.wikimedia.org/wiki/File:Brain\\_bulbar\\_region.PNG](http://commons.wikimedia.org/wiki/File:Brain_bulbar_region.PNG)

## Brain Waves

Clusters of axons produce action potentials that can be observed with an electronic recording device known as an electroencephalogram or EEG. These waves are not regular but do have some distinguishing characteristics such as amplitude that can be used to identify different types of brain waves. The different types of waves are known as alpha, beta, theta and delta (fig. 12.15).

Alpha waves occur during normal waking hours when subjects are alert. Beta waves occur during concentration or intense thought. Theta waves occur in children or in adults who have brain disorders. Delta waves occur during deep sleep.

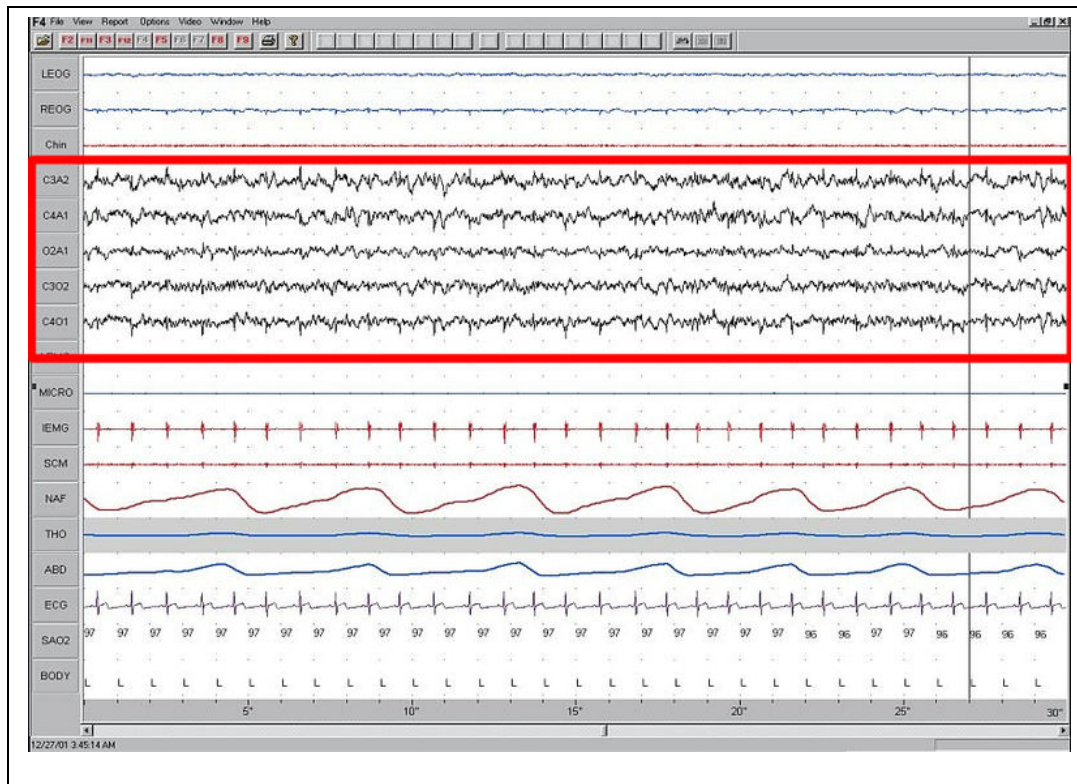


Figure 12.15. An EEG displays brain waves.

[http://commons.wikimedia.org/wiki/Image:Sleep\\_EEG\\_Stage\\_1.jpg](http://commons.wikimedia.org/wiki/Image:Sleep_EEG_Stage_1.jpg)



## **Memory**

The brain is capable of storing vast amounts of information in its memory. There are two basic types of memory. Short-term memory stores 6-8 pieces of information for brief periods. For example a telephone number is 7 pieces of information long and can be stored for a short amount of time until the person is asked to remember something else. Long-term memory as its name implies allows for storage of information for much longer periods of time (as long as a lifetime). Types of long-term memory include declarative and procedural. Declarative is sometimes referred to as explicit and procedural is referred to as implicit.

Declarative memory occurs in part of the temporal lobes and the hippocampus and amygdala. The hippocampus is involved in retrieving stored memories whereby the amygdala stores emotions associated with memories. Declarative memory is also stored in various parts of the cerebrum. Memories are grouped together as well. For example, faces may be stored in a different location than names. Retrieving a memory involves accessing various components and assembling them. Over time memories decay and can lead to false memories.

Procedural memory involves storing skills such as playing an instrument or driving a car. Procedural memories are stored in the premotor area of the cerebrum and cerebellum.

Information to be remembered moves from short-term to long-term memory. Neurons in long-term memory actually change in response to storing information. The phenomenon of long-term potentiation occurs when memories are stored. This involves changes in neurotransmitter storage and release as well as protein synthesis. New connections are made and maintained between neurons. This flexible and adaptive characteristic of the brain is known as neural plasticity.

## **Testing Spinal Nerves**

An important part of assessing the nervous system is to assess the function of spinal nerves. There are three primary ways to assess spinal nerves. These include reflexes, sensory testing and muscle testing. An overview of assessing a few spinal nerves follows.

Spinal nerves are named for the level at which they exit the spine. For example the C5 spinal nerve exits between vertebral segments C4 and C5.

## **Testing Dermatomes**

Spinal nerves carry sensation from various parts of the body to the spinal cord. These areas are called dermatomes and are named for the spinal nerve associated with that region of the body.

Dermatomes are typically assessed by testing pain, light touch, temperature and discrimination. Pain is tested using sharp and blunt devices touched lightly to the skin. Light touch is tested with a wisp of cotton touched to the skin. Discrimination is often tested with a device that contains two contact points that can be made further apart or closer together.

## **Reflexes**

Deep tendon reflexes associated with a specific spinal nerve are tested with a reflex hammer. Reflexes are graded as:

0 = absent

1+ = hypoactive

2+ = normal

3+ = hyperactive without clonus

4+ = hyperactive with clonus

Right and left symmetry is also observed and noted. Remember that upper motor neurons have an influence on spinal reflexes so hyperactive reflexes indicated upper motor neuron problems. Clonus is an involuntary contraction of a muscle when stimulated by reflex testing. Hypoactive reflexes indicate problems with the pathway between the spinal cord and the muscle.

## **Muscle Testing**

Muscle testing (motor strength testing) can be performed by having the subject resist certain movements. The resistance is provided by the examiner. Muscle strength is assessed for symmetry and graded using the following scale:

0/5 no movement

1/5 muscle contraction but no joint movement

2/5 joint movement but not against gravity

3/5 joint movement against gravity but not against resistance

4/5 movement against resistance but not normal

5/5 normal

## **Real World A&P**

### **Depression**

Depression can be a debilitating problem. It is caused by a number of factors including a low amount of a neurotransmitter in the brain called serotonin. Depression is not a rare disease as about 14 million Americans suffer from it.

Here are some of the things that can contribute to depression:

- Stress and trauma: such as a breakup, divorce, serious illness, and financial problems.
- Family history: there may be a strong genetic influence on depression.
- Negative personality: pessimism, low self-esteem and a negative outlook on life can contribute to depression.
- Psychological Disorders: having other psychological problems like anxiety, eating disorders and schizophrenia can contribute to depression.

Some of the signs of depression include:

- Feelings of hopelessness
- Inability to concentrate
- Low energy
- Low self-esteem
- Loss of enjoyment from hobbies or other activities that used to bring enjoyment

In order to increase the level of serotonin in the brain, physicians may prescribe a drug known as a selective serotonin reuptake inhibitor. These drugs block the reuptake of serotonin. Since serotonin is not broken down as readily, its concentration in the synaptic cleft increases.

Patients taking antidepressants should never abruptly discontinue taking their medications as this can lead to withdrawal symptoms. Patients wanting to discontinue therapy should work with their physicians so that they can gradually wean off of the medication.

## Chapter 12 Review Questions

1. Which type of neuron secretes myelin in the central nervous system:
  - a. Bipolar neuron
  - b. Schwann cell
  - c. Oligodendrocyte
  - d. Multipolar neuron
2. The resting membrane potential of a neuron is typically:
  - a. +30 mV
  - b. -70 mV
  - c. -55 mV
  - d. Neutral
3. Which of the following best describes depolarization of a neuron:
  - a. Sodium gates open and sodium enters the cell
  - b. Potassium gates open and potassium enters the cell
  - c. Sodium gates open and sodium leaves the cell
  - d. Calcium gates open and calcium enters the cell
4. The afterpotential is caused by:
  - a. Sodium gates remaining open
  - b. Potassium gates remaining open
  - c. Calcium gates remaining open
  - d. Potassium gates closing
5. Which best describes saltatory conduction:
  - a. Action potential moves down the axon in a wavelike fashion.
  - b. Action potential appears to jump from node to node
  - c. Action potential moves down a section then stops for a brief period
  - d. Action potential resets midway down an axon
6. Which gate is responsible for releasing the neurotransmitter:
  - a. Sodium
  - b. Calcium
  - c. Potassium
  - d. Chloride
7. An inhibitory post-synaptic potential is characterized by the opening of:
  - a. Potassium gates
  - b. Sodium gates
  - c. Calcium gates
  - d. Acetylcholine gates

8. The withdrawal reflex incorporates the use of neurons called:
- a. Neuroglia
  - b. Oligodendrocytes
  - c. Astrocytes
  - d. Interneurons
9. The sense of smell is processed in which part of the brain:
- a. Temporal lobe
  - b. Parietal lobe
  - c. Occipital lobe
  - d. Frontal lobe
10. Which specialized area of the brain has to do with speech recognition:
- a. Parietal lobe
  - b. Broca's area
  - c. Occipital lobe
  - d. Wernicke's area
11. Short-term memory can handle about \_\_\_\_ pieces of information:
- a. 4-6
  - b. 6-8
  - c. 8-10
  - d. 10-12
12. A normal reflex is graded:
- a. 1+
  - b. 2+
  - c. 3+
  - d. 4+

# Chapter 13

## The Senses

## The Senses

The senses are our windows to reality. They allow us to perceive our environments by gathering information and converting it to action potentials so that the nervous system can process it. The sensory system is divided into two areas. The somatic sensory system is the system responding to information from the skin, muscles and viscera (organs). The special senses include taste, smell, vision and hearing.

The sensory system relies on specialized structures called sensory receptors. All sensory receptors essentially do the same thing. They collect information in various forms from the environment and convert it to electrochemical impulses (action potentials) for processing by the central nervous system. The environment can be external (outside the body) or internal (inside the body).

There are a variety of sensory receptors and they include the following:

- Chemoreceptors that sense changes in chemical concentration.
- Pain receptors (nociceptors) that sense tissue damage.
- Thermoreceptors that sense changes in temperature.
- Mechanoreceptors that sense mechanical deformation of tissue.
- Proprioceptors that sense changes in position of joints.
- Stretch receptors that sense changes in tissue length.
- Photoreceptors that sense changes in light intensity.

Once receptors pick up information and send it to the brain for processing the brain interprets the information and projects it to the area of stimulation. For example, even though the brain processes information regarding pain the brain will project the pain to the area of the body that is stimulated.

Some receptors can adapt to stimuli. For example touch receptors in your skin will adapt to the pressure from your clothing so you are not constantly aware of clothing touching every part of your body. Also, the heat felt from entering a hot tub soon diminishes as temperature receptors adapt.

### Somatic Sensory System

The somatic senses consist of sensory receptors associated with skin, muscles, joints and viscera. The somatic senses include touch, pressure, temperature, pain, and stretch.

Touch and pressure are sensed by free nerve endings and Merkel's discs located between epithelial cells as well as Meissner's, Pacinian, and Ruffini corpuscles. Meissner's corpuscles are located in hairless portions of skin (lips, finger tips, palms, soles, nipples, external genitals). They are small oval masses of flattened connective tissue that primarily sense light touch (fig. 13.1).

Pacinian corpuscles are located in deeper subcutaneous tissues of hands, feet, genitalia, urethra, breasts, tendons of muscles and ligaments of joints. They detect heavy pressure and vibration (fig. 13.2).

Ruffini corpuscles are also located in the dermis and are sensitive to pressure and skin movement. Merkel's discs sense fine touch and pressure and are located in the stratum germinativum of the epidermis.

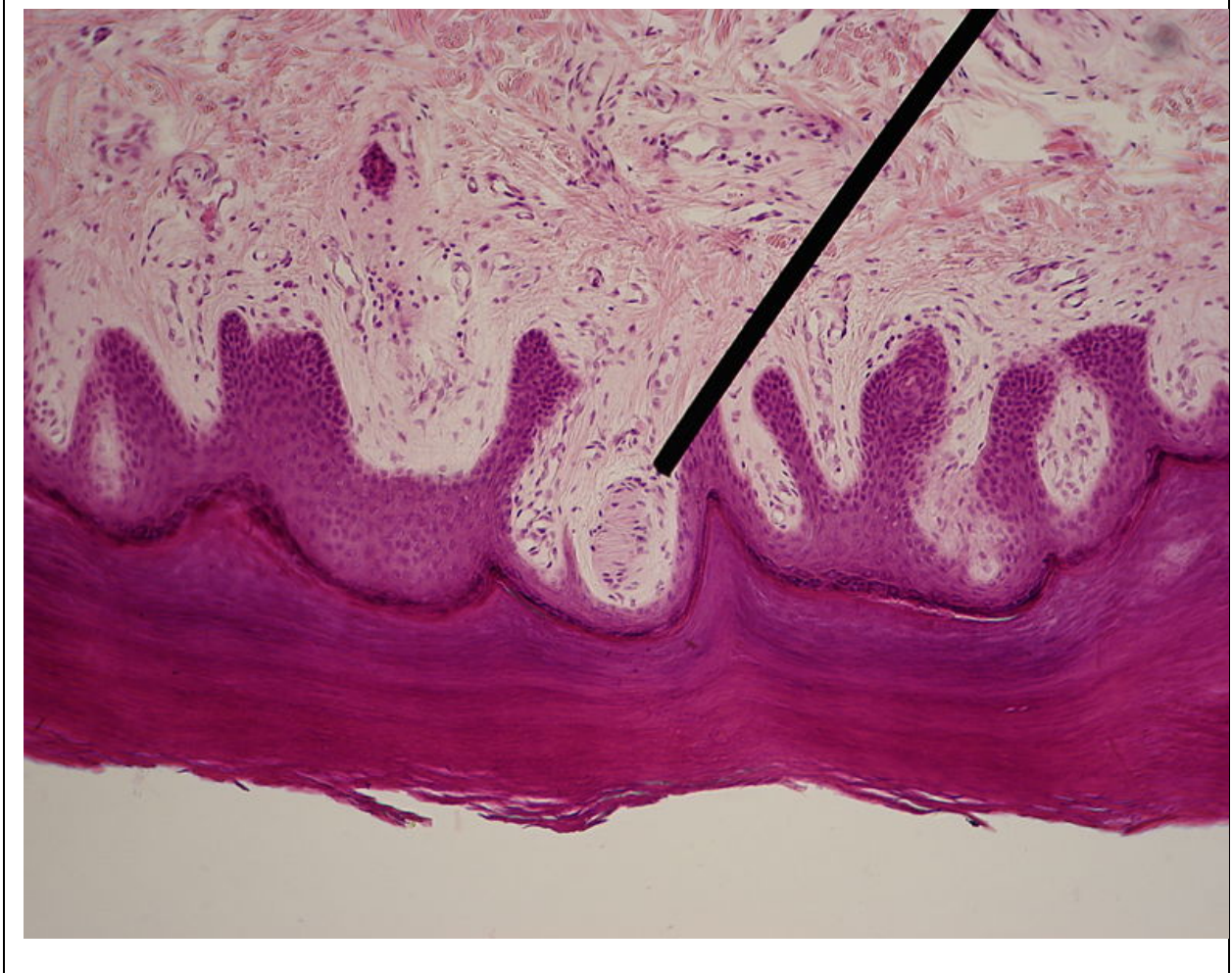


Figure 13.1. Meissner's corpuscle located in the superficial dermis (the superficial layers of the skin are at the bottom of the slide).

[http://commons.wikimedia.org/wiki/Image:WVSOM\\_Meissner%27s\\_corpuscle.JPG](http://commons.wikimedia.org/wiki/Image:WVSOM_Meissner%27s_corpuscle.JPG)



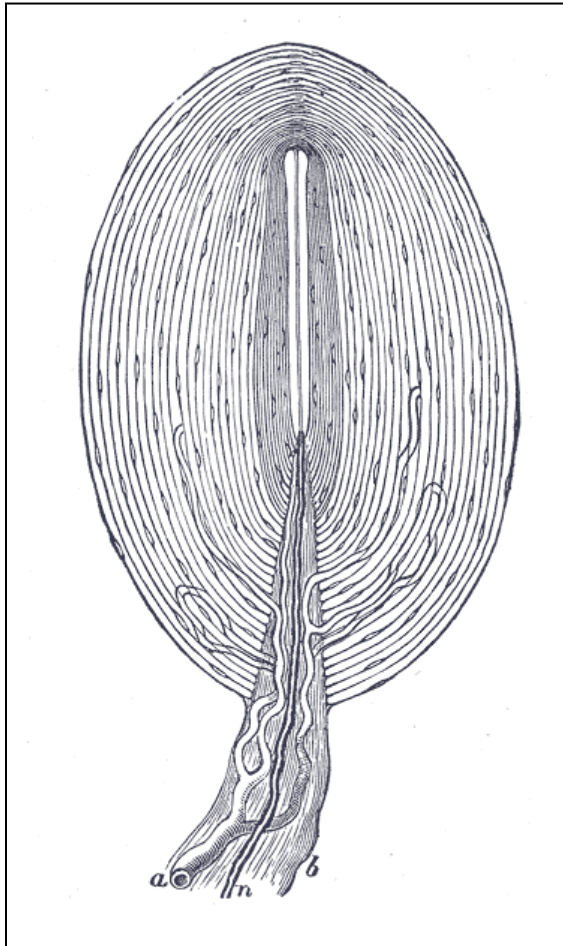


Figure 13.2. Pacinian corpuscles are located in the deeper areas of the dermis.

<http://commons.wikimedia.org/wiki/Image:Gray935.png>

There are also warm and cold receptors. Warm receptors are receptive to temperatures greater than 25 degrees Centigrade (77 deg F). Cold receptors are receptive to temperatures between 10 degrees Centigrade (50 deg F) and 20 degrees Centigrade (68 deg F). Pain is experienced if the temperature drops below 10 degrees Centigrade.

The pain receptors or nociceptors are the free nerve endings. There are no pain receptors in brain. Pain receptors do not adapt to stimuli.

Pain from organs or visceral pain can cause the phenomenon of referred pain. In referred pain the sense of pain is coming from other areas than the location of viscera. A classic example of referred pain is the pain in the left arm or jaw felt during a heart attack. Referred pain comes from nerve pathways shared by visceral and skin pain receptors.

There are two types of pain nerve fiber pathways. A-delta fibers or acute pain fibers are thin myelinated fibers that rapidly conduct pain. The information they carry is interpreted as sharp pain. The sensation

of sharp pain tends to not persist after the painful stimulus is removed. Chronic pain fibers or C- fibers are slower than acute fibers and carry information that is interpreted as the sensation of a dull ache. The sensation can be intense, long-lasting and resists relief. After reaching the central nervous system, pain follows a specific pathway in spinal cord tracts and is processed in the brain. Pain is processed by the gray matter of the posterior horn of the spinal cord. Pain signals cross over in spinal cord and travel to the brain via the lateral spinothalamic tracts. The pain signals are then processed in the reticular formation, thalamus, hypothalamus and cerebral cortex. Areas of gray matter in midbrain, pons, and medulla oblongata also regulate pain impulses from cord. The impulses travel in the spinal cord via lateral funiculus. The neurons in lateral funiculus can block pain impulses through the secretion of inhibiting neurotransmitters.

Some important pain inhibiting neurotransmitters include enkephalins, endorphins and serotonin. Enkephalins inhibit acute and chronic pain impulses. Serotonin works by stimulating neurons to release enkephalins. Endorphins are effective in inhibiting chronic pain impulses. Remember, your body is capable of producing the pain-inhibiting neurotransmitters. Some pain controlling therapies are aimed at increasing the amount of these neurotransmitters. These include some of the electrical therapies such as interferential current found in physical therapy clinics.

### **Sensory Receptors in Muscle**

We will examine two types of sensory receptors found in muscle tissue. These include the Golgi tendon organs and muscle spindles.

Muscle spindles are located near the origin and insertions of muscles (fig. 13.3.). They consist of modified skeletal muscle fibers (intrafusal fibers) enclosed in connective tissue sheath. A nerve fiber wraps around the intrafusal fiber and sends information about muscle tone to the central nervous system. Larger extrafusal fibers surround the intrafusal fibers.

Muscle spindles are involved in the stretch reflex. If a muscle is stretched the spindle is also stretched and sends signals to CNS. The signals oppose muscle lengthening. So if the muscle is stretched or lengthened, signals are sent to CNS telling the muscle to shorten. This produces the muscle jerk in the deep tendon reflex.

Golgi tendon organs (GTOs) are located at the muscle-tendon junction. They monitor tension of the muscles generated during muscle contraction. Golgi tendon organs can act as a protective mechanism to overloaded muscles. When muscles become overloaded the Golgi tendon organs function to inhibit muscle contraction in what is known as “weightlifting failure. “

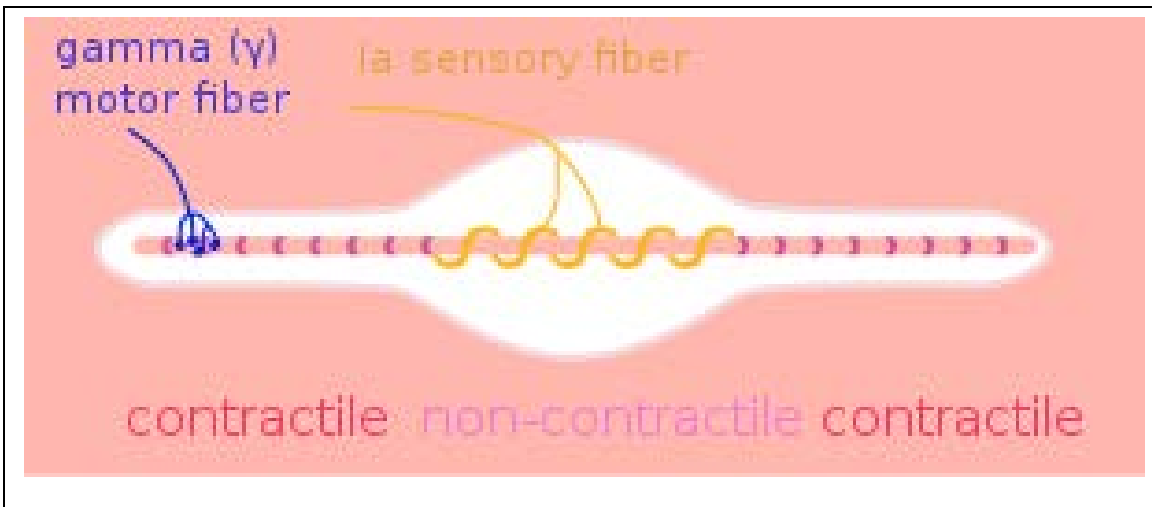


Figure 13.3. Muscle Spindle

<http://commons.wikimedia.org/wiki/File:MuscleSpindle.svg>

## The Special Senses

The special senses include smell, taste, hearing and vision.

### Olfaction (smell)

The senses of smell and taste work together. Both are sensed as changes in chemical concentration by chemoreceptors. Olfactory organs located on both sides of the nasal septum in the nasal cavity pick up water and lipid soluble substances that diffuse in the mucous of the nasal cavity (fig. 13.4). The information is then converted to action potentials and sent via afferent neurons through the cribriform plate of the ethmoid bone to the olfactory bulbs. The information then leaves the olfactory bulbs and travels via the olfactory tract to the olfactory cortex of the frontal lobe, hypothalamus and limbic system (fig. 13.5). The processing of olfactory information by the hypothalamus and limbic system results in a close relationship between the sense of smell and emotions.

We can sense between 2000-4000 different chemical substances with our olfactory systems. The system is incredibly sensitive and can sense concentrations as small as a few parts per billion.

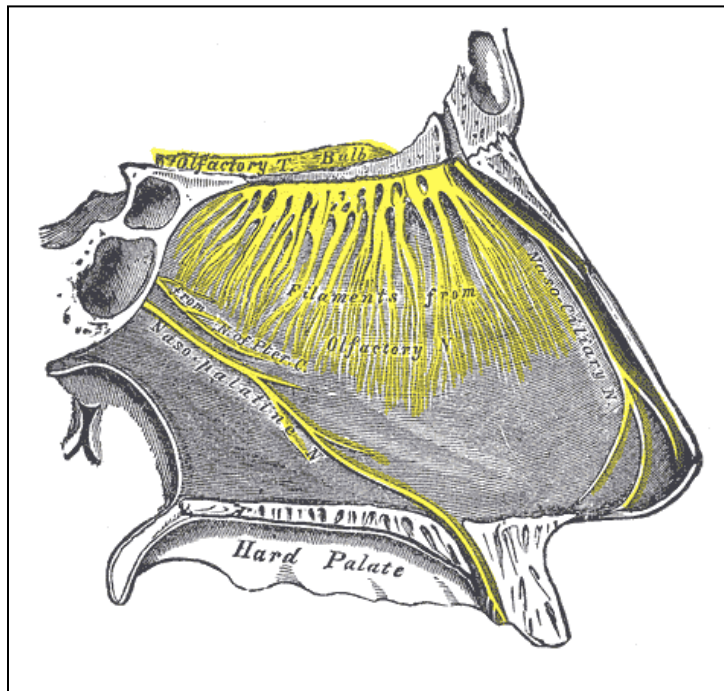


Figure 13.4. Olfactory nerve fibers.

<http://commons.wikimedia.org/wiki/Image:Gray858.png>

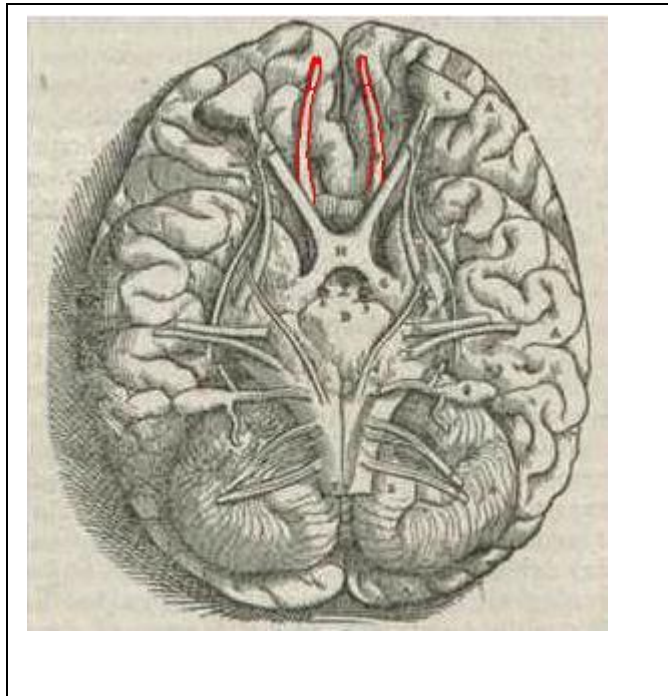


Figure 13.5. Olfactory bulbs (red)

<http://commons.wikimedia.org/wiki/Image:1543,Vesalius%27OlfactoryBulbs.jpg>

## Taste

Taste is also sensed as changes in chemical concentration by taste receptors. These receptors are located on the surface of tongue (papillae), on the roof of the mouth, linings of cheeks and walls of the pharynx (fig. 13.6). The taste receptors form structures called taste buds. The adult human has about 3000 taste buds. Each taste bud contains different types of cells. Basal cells are the stem cells that mature into gustatory cells that contain microvilli. The microvilli extend into fluid collected in the taste pores which are small openings in the taste buds (fig. 13.7). Gustatory cells are replaced frequently and typically last only 10 days.

Taste sensation is carried by cranial nerves VII (facial), IX (glossopharyngeal) and X (vagus). The facial nerve receives information from receptors on the anterior two thirds of the tongue. The posterior one third of the tongue is innervated by the glossopharyngeal nerve. The vagus nerve innervates the taste buds located on the epiglottis.

Taste information is sent to the medulla oblongata and then to the thalamus where it is routed to portions of the primary sensory cortex.

There are 5 primary taste sensations. Tastes are combinations of these 5 primary sensations.

1. Sweet
2. Sour
3. Salty
4. Bitter
5. Umami

Umami is a hearty, meaty taste that is produced by L-glutamate (think monosodium glutamate). Taste receptors are more sensitive to unpleasant stimuli. For example we are about a thousand times more sensitive to acids than sweet tastes.

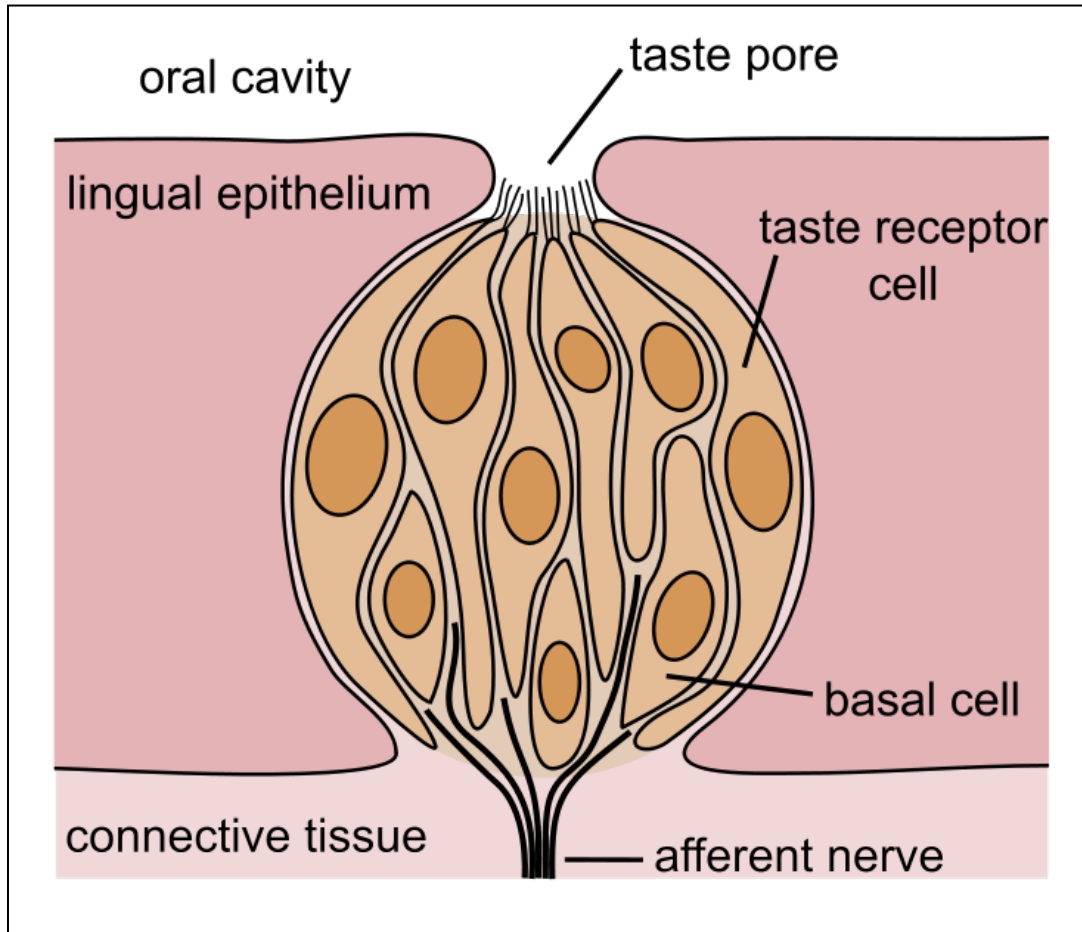


Figure 13.6. Taste bud

[http://commons.wikimedia.org/wiki/Image:Taste\\_bud.svg](http://commons.wikimedia.org/wiki/Image:Taste_bud.svg)

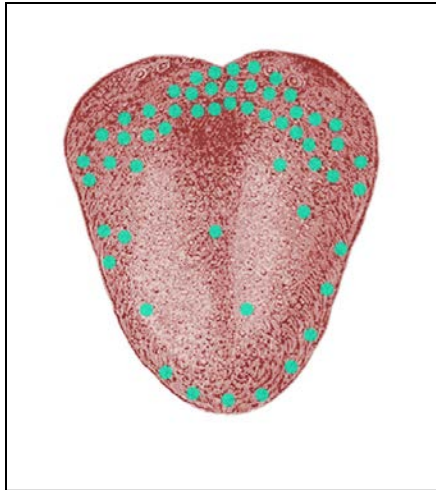


Figure 13.7a. Taste buds for bitter.

[http://commons.wikimedia.org/wiki/Image:Tongue\\_bitter.jpg](http://commons.wikimedia.org/wiki/Image:Tongue_bitter.jpg)

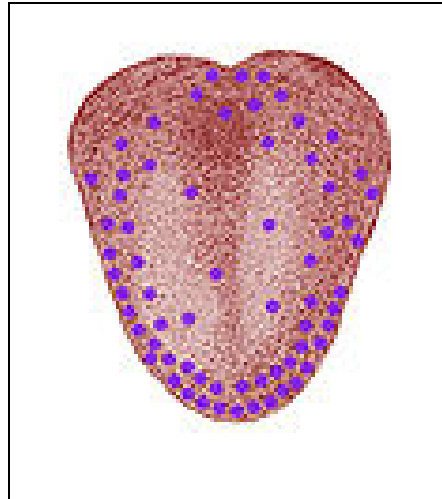


Figure 13.7b. Taste buds for salty.

<http://commons.wikimedia.org/wiki/Image:Tongue-salty.jpg>

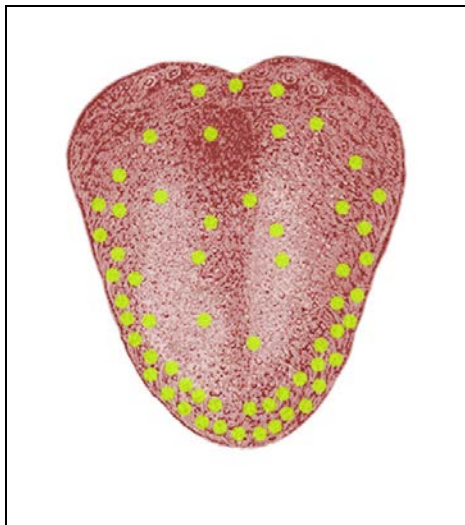

Figure 13.7c. Taste buds for sour.

<http://commons.wikimedia.org/wiki/Image:Tongue-sour.jpg>

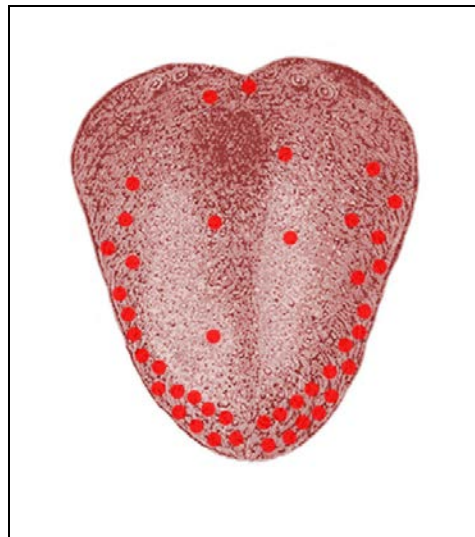

Figure 13.7d. Taste buds for sweet.

<http://commons.wikimedia.org/wiki/Image:Tongue-sweet.jpg>



## Vision

### External and Supportive Structures of the Eye

The eyes are surrounded by a series of supportive structures that protect and move the eye as well as produce secretions. These structures are often referred to as accessory structures.

The eyelids (palpebrae) are continuous with the skin. They help to remove debris and allow tears to lubricate the surface of the eye. When closed they protect the eye. The upper and lower eyelids are separated via a gap called the palpebral fissure. The upper and lower lids are connected via the medial and lateral canthus. Sebaceous glands called tarsal glands are located at the inner margins of the eyes. The secretions from these glands help to keep the eyelids from sticking together.

The lacrimal caruncle is located at the medial canthus. This structure contains glands that secrete thick mucous.

A thin layer of mucous secreting epithelium covers the inner portion of the eyelids and extends to the outer portion of the eyes. This layer is called the conjunctiva. There are two parts to the conjunctiva. The palpebral conjunctiva is located on the inner surface of the eyelid while the ocular conjunctiva is located on the eyeball. The ocular conjunctiva extends to the margins of the cornea.

An inflammation or infection of the conjunctiva is known as conjunctivitis (pinkeye). This is caused by infection, irritation, or allergies (fig. 13.8).

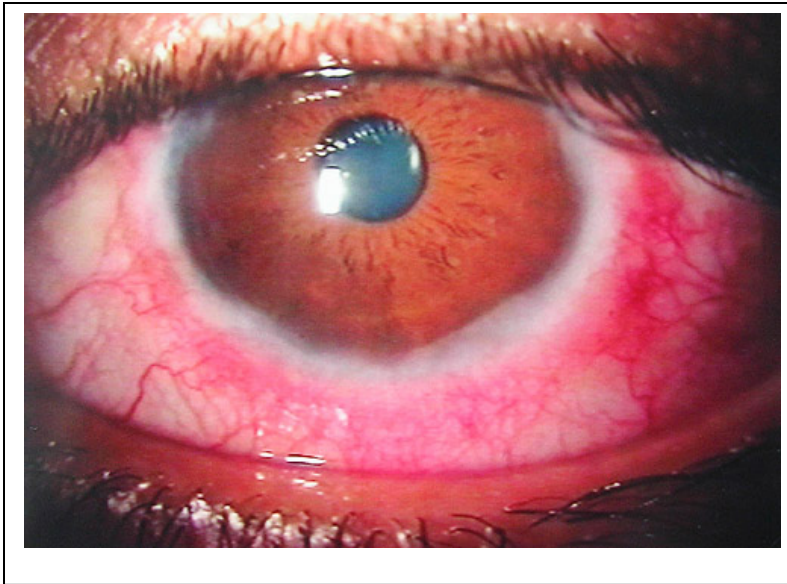


Figure 13.8. Conjunctivitis

<http://commons.wikimedia.org/wiki/Image:Vernal.jpg>



## Lacrimal Apparatus

The lacrimal apparatus produces tears. It consists of a lacrimal gland, lacrimal canaliculi, and a lacrimal sac (fig. 13.9).

The lacrimal glands secrete tears that function to clean and lubricate the surface of the eye. Tears contain an enzyme called lysozyme that helps to kill bacteria. Tears are spread across the surface of the eye and drained by the lacrimal canals that lead to the nasolacrimal duct.

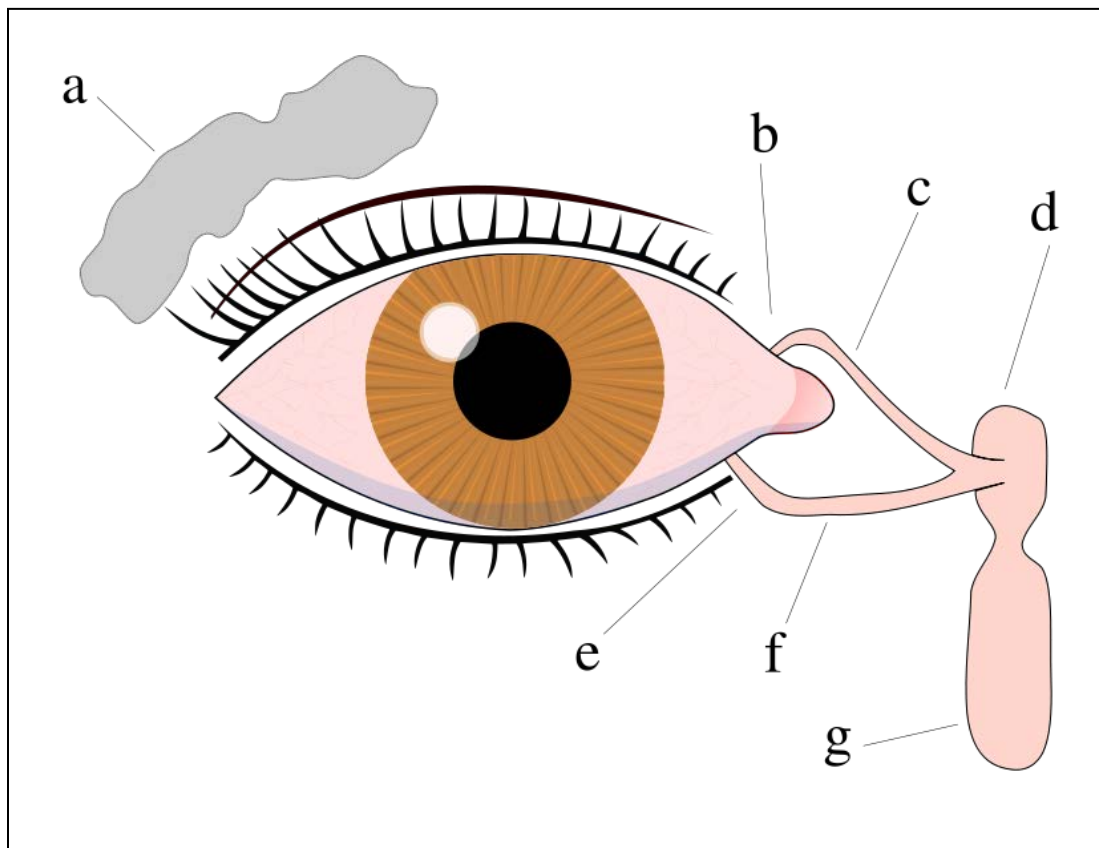


Figure 13.9. Lacrimal Apparatus

- a = tear gland / lacrimal gland
- b = superior lacrimal punctum
- c = superior lacrimal canal
- d = tear sac / lacrimal sac
- e = inferior lacrimal punctum
- f = inferior lacrimal canal
- g = nasolacrimal canal

[http://commons.wikimedia.org/wiki/Image:Tear\\_system.svg](http://commons.wikimedia.org/wiki/Image:Tear_system.svg)

## Eye Muscles

There are six extrinsic eye muscles that move the eyeball (fig. 13.10). There are four rectus (straight fibers) muscles and two obliques. The four rectus muscles are the superior, inferior, medial and lateral. The two obliques are the superior oblique and inferior oblique.

The rectus muscles all originate on the posterior surface of the bony orbit and extend to the surface of the eyeball. The superior oblique attaches to the medial surface of the orbit. Its tendon passes through a fibrocartilagenous pulley called the trochlea. The tendon then attaches to the superolateral surface of the eyeball. The inferior oblique extends from the medial wall of the orbit to its attachment on the inferolateral aspect of the eyeball.

The eye muscles are innervated by cranial nerves III, IV, and VI. Cranial nerve III innervates the superior rectus, inferior rectus, medial rectus and inferior oblique. Cranial nerve IV innervates the superior oblique and cranial nerve VI innervates the lateral rectus.

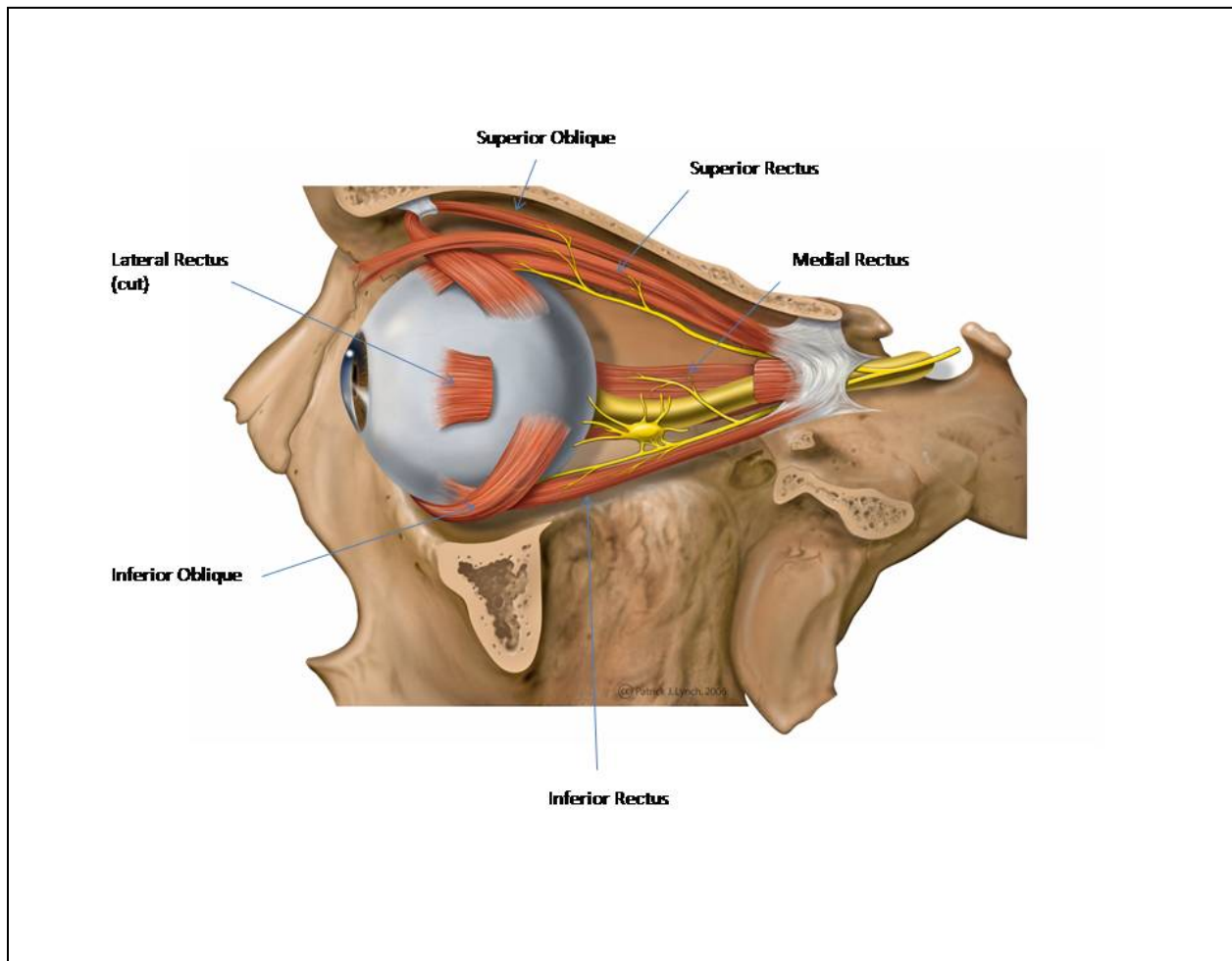


Figure 13.10. Eye Muscles

Patrick J. Lynch, medical illustrator; C. Carl Jaffe, MD, cardiologist. <http://creativecommons.org/licenses/by/2.5/>

Labelled by Bruce Forciea

## Structures of the Eye

The eye consists of three layers or tunics. These are the outer fibrous tunic, the middle vascular tunic and the inner tunic (fig. 13.11).

The outer fibrous tunic consists of the cornea and sclera. The sclera (white portion) consists of dense connective tissue containing blood vessels and nerves. The cornea is the transparent portion on the anterior aspect of the eye.

The middle vascular tunic consists of the choroid coat, ciliary body and iris. The middle tunic is also called the uvea because of its similarity to a peeled grape. The choroid coat is a pigmented (dark) layer just deep to the retina. The ciliary body is an extension of the choroid coat. It surrounds the lens and contains smooth muscles that attach to the lens via suspensory ligaments. The ciliary body secretes a watery fluid called aqueous humor. The iris contains smooth muscle that controls the diameter of the pupil. The iris contains chromatophores that contain melanin that gives the iris its color.

The inner layer contains the retina and a portion of the optic nerve.

Additional structures of the eye that are not part of the tunics help to direct and focus light to the retina. These include aqueous humor, lens, and vitreous body (humor).

The aqueous humor is a watery serous fluid secreted by the ciliary body into a space between the iris and lens called the posterior chamber. The fluid flows to the anterior chamber which lies between the cornea and the iris. The fluid is then absorbed by the Canal of Schlemm (sclera venous sinus).

The lens connects to the ciliary body by means of a series of fibers called the suspensory ligament. The suspensory ligament changes the shape of the lens. When the ligament is taught the lens flattens. Likewise when the ligament relaxes the lens retains its spheroid shape.

The vitreous body is a clear, jellylike fluid that resides in a large hollow area just posterior to the lens.

The retina attaches to the eye at only two points; the optic disc and the ora serrata. The optic disc is the area of attachment of the optic nerve. The ora serrata is the anterior margin of the retina. The vitreous body helps to maintain the shape of the retina by pushing against it. The retina can detach from blows to the head.

The retina is actually nervous tissue that is consistent with the brain. It develops in utero from the diencephalon.

A group of cells that contain a high concentration of photoreceptors is located in the posterior retina. This structure is called the macula lutea and is about 3mm-5mm in diameter. The fovea centralis is located at the center of the macula lutea. The fovea centralis produces the sharpest vision.

The optic nerve lies just medial to the fovea centralis. Nerve fibers from the eye converge and exit the eye at the optic disc. Blood vessels also travel through the optic disc. The optic disc contains no photoreceptors and thus produces a blind spot. The brain compensates for the blind spots in each visual field by filling in the field with images similar to the surroundings.

The pupil is surrounded by smooth muscles that allow for it to constrict or dilate. The pupillary constrictor muscle narrows the pupil to decrease the amount of light entering the eye. This muscle is

innervated by the parasympathetic nervous system. The pupillary dilator does the opposite function and opens the pupil to let in more light in response to stimulation from the sympathetic nervous system.

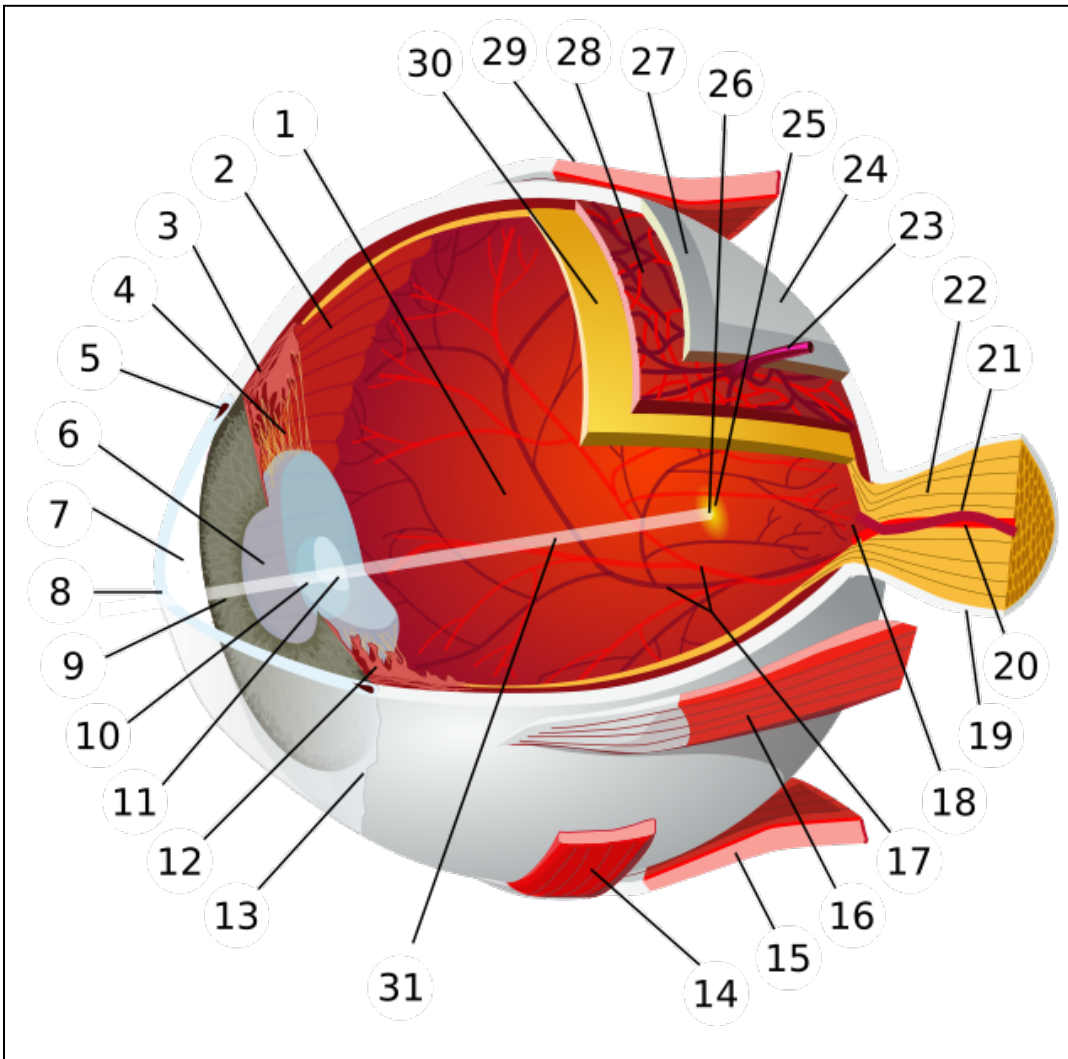


Figure 13.11. Structures of the eye.

1:posterior chamber 2:ora serrata 3:ciliary muscle 4:suspensory ligaments 5:canal of Schlemm 6:pupil 7:anterior chamber 8:cornea 9:iris 10:lens cortex 11:lens nucleus 12:ciliary process 13:conjunctiva 14:inferior oblique muscle 15:inferior rectus muscle 16:medial rectus muscle 17:retinal arteries and veins 18:optic disc 19:dura mater 20:central retinal artery 21:central retinal vein 22:optical nerve 23:vorticose vein 24:bulbar sheath 25:macula 26:fovea 27:sclera 28:choroid 29:superior rectus muscle 30:retina

[http://commons.wikimedia.org/wiki/Image:Eye-diagram\\_no\\_circles\\_border\\_1.svg](http://commons.wikimedia.org/wiki/Image:Eye-diagram_no_circles_border_1.svg)

## Refraction

Light travels at 300,000 meters per second in a vacuum but will slow down when traveling through other media. As light travels through the eye it passes through transparent structures that change its speed. The result is a convergence or divergence of light rays. This phenomenon is known as refraction.

As light travels through the eye it passes through the cornea, aqueous humor and pupil to the lens. The pupil will change its diameter to help the lens focus. For example, the pupil will constrict when looking at objects nearby. This helps to reduce the phenomenon of spherical aberration that occurs from an unequal amount of refraction by the lens. Objects are not refracted as well from the margins of the lens as in the middle regions. The result is a blurry image. The pupil constricts to reduce spherical aberration by focusing the light rays on the center of the lens.

The lens can change its shape to adjust its curvature. This is called accommodation (fig. 13.15). For example contraction of the ciliary muscle occurs when looking at objects close by. This allows the suspensory ligament to relax which causes the lens to produce a more convex shape. Likewise when you look at objects far away the ciliary body relaxes allowing the suspensory ligament to contract. This changes the shape of the lens to be less convex. The more convex the lens, the more it causes light rays to converge. The lens loses its flexibility with age and focusing becomes more difficult. Bifocals are used to correct for the loss of accommodation.

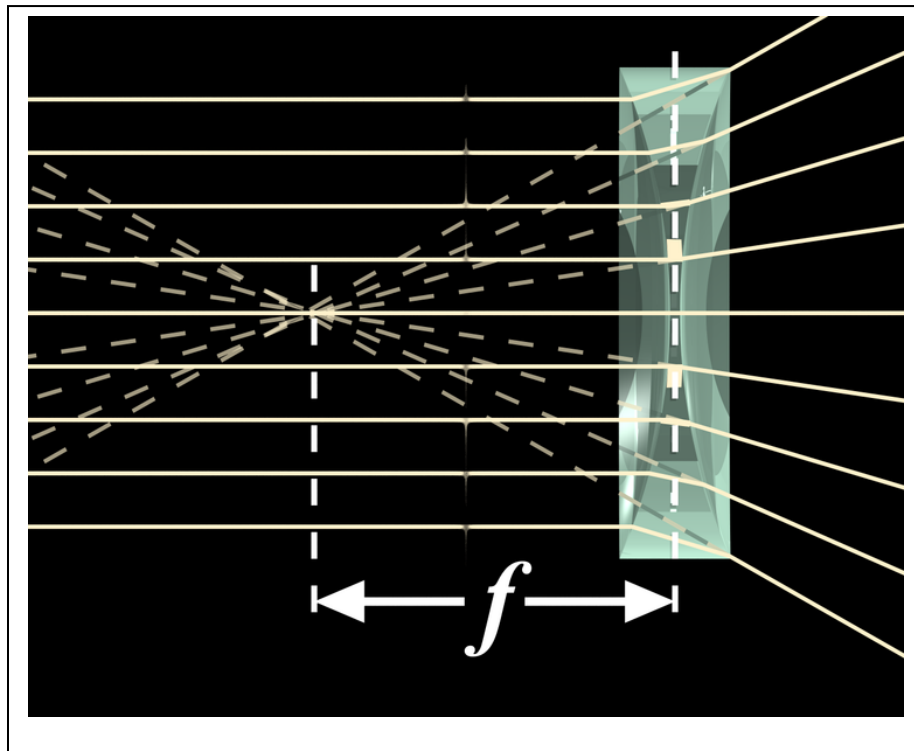


Figure 13.12. A concave lens causes light rays to diverge.

<http://commons.wikimedia.org/wiki/Image:ConcaveFocalLength.png>

Author: Søren Peo Pedersen

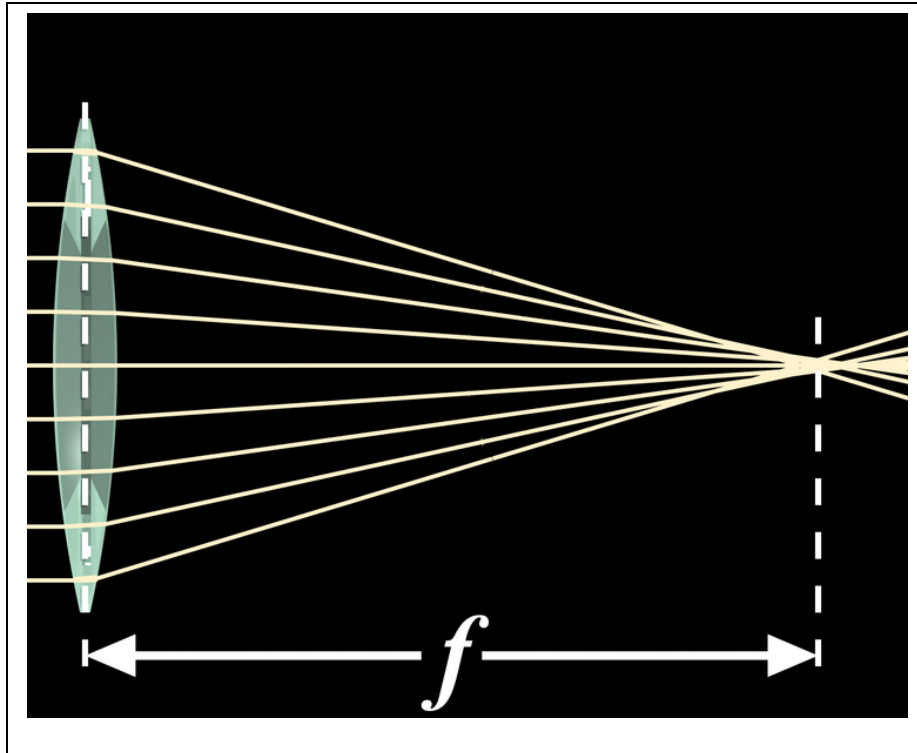


Figure 13.13. A convex Lens causes light rays to converge.

<http://commons.wikimedia.org/wiki/Image:FocalLength.png>

Author: Søren Peo Pedersen

Lenses are used to correct for refraction disorders of the eye (figs. 13.12, 13.13). Myopia or nearsightedness results from an eyeball that is too long. In this case images focus in front of the retina. A corrective concave lens is needed to push the images back (fig. 13.14). Hyperopia or farsightedness results from the eyeball that is too short. This causes images to focus behind the eyeball. A convex lens is needed to pull the images forward.

An astigmatism is caused by irregularly shaped cornea or lens. This can cause blurred vision, eyestrain or headaches. Astigmatisms are corrected by lenses or refractive surgery.

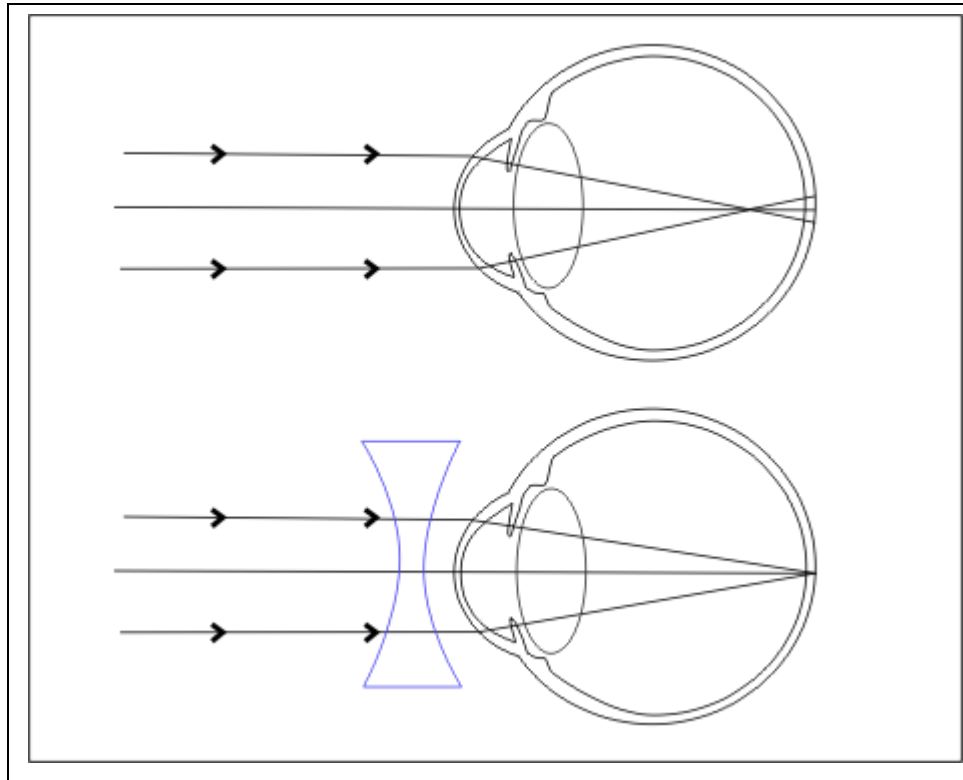


Figure 13.14. Myopia is corrected with a concave lens.

<http://commons.wikimedia.org/wiki/Image:Myopia.png>

Author: A. Baris Toprak MD

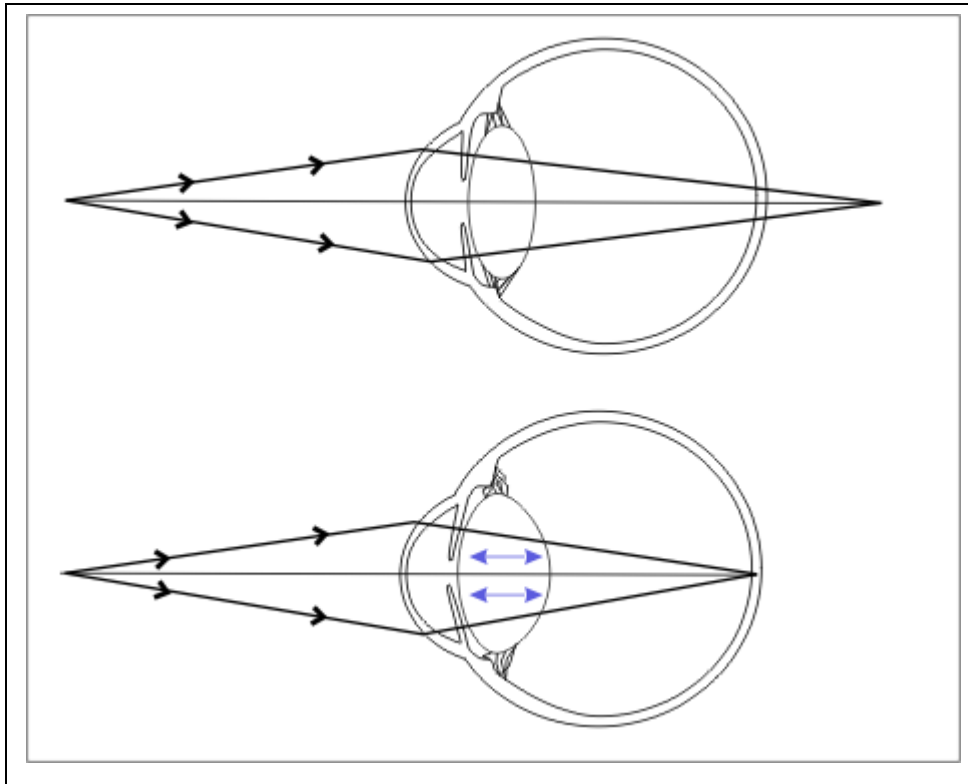


Figure 13.15. Accommodation is the change in shape of the lens.

<http://commons.wikimedia.org/wiki/File:Accomodation.png>

Author: A. Baris Toprak MD



## Photoreceptors of the Retina

Light travels through the transparent structures of the eye (cornea, aqueous humor, lens, vitreous humor) and enters the retina. The retina contains photoreceptors, ganglion cells and bipolar neurons (fig. 13.17). Light passes through the retina until it reaches the photoreceptors. Images are sensed by the photoreceptors that transmit impulses to the bipolar neurons that in turn transmit impulses to the ganglion cells. The ganglion cells generate action potentials that travel through cranial nerve II to the occipital lobe.

There are two types of photoreceptors called rods and cones. Rods are more numerous and work to produce black and white vision. Both types of photoreceptors have inner and outer segments joined by cilia. The inner segment joins with the cell body while the outer segments contain pigments (visual pigments) that respond to light. Rods have a rod-shaped outer segment while cones have a cone-shaped outer segment.

Photoreceptors are able to maintain themselves by continually replenishing their outer segments. Rods are replenished during the day while cones are replenished at night. Rods and cones have different visual pigments that absorb light at different wavelengths. Rods are more sensitive and respond to gray colors better than cones making them better able to produce black and white vision at night. Rods are also more sensitive to peripheral vision.

Rods also connect with convergent neural pathways. Many rods will innervate fewer ganglion cells resulting in loss of sharpness of vision. Rods contain one type of visual pigment.

Cones absorb light at a wider range of wavelengths than rods. They also contain three visual pigments and are less sensitive to dim light. Cones function better in daylight and are better able to produce color vision. Cones also have a one-to-one relationship with ganglion cells. This allows cones to provide sharper color vision.

Visual pigments undergo a chemical reaction in order to produce impulses that send visual information. Retinal is a molecule that absorbs light. Retinal is made from vitamin A and is able to change its shape in response to light. Retinal binds with proteins called opsins to make the different types of visual pigments (fig. 13.16).

Rods contain the pigment rhodopsin (visual purple). Rhodopsin forms in dim light or darkness. Retinal undergoes oxidation and combines with opsin to produce rhodopsin. Retinal begins in one configuration known as the 11-cis retinal form. Once exposed to light, retinal changes to an alternate configuration known as the all-trans configuration. Retinal now separates from opsin. This change in configuration of retinal produces a cascade of reactions ending with the generation of action potentials.

Cones require a higher intensity of light in order to trigger action potentials. Cones use different opsins corresponding to the primary colors they absorb (blue, green, red). The reaction of retinal and opsins is essentially the same as in rods.

In dim or dark conditions molecules of cGMP bind to protein channels in the photoreceptor's cell membrane. The channels open and allow calcium and sodium to continuously enter the cell. This holds the membrane potential to around -40mV and holds the cell in a steady state of depolarization. This keeps the calcium channels at the synaptic terminals open and produces a continuous flow of the neurotransmitter glutamate. The glutamate stimulates receptors on the bipolar neurons.

When light reaches the photoreceptors a series of reactions occur that breaks down the cGMP. The protein channels subsequently close. Potassium channels also located in the membrane remain open and potassium moves out of the cell causing it to be in a hyperpolarized state of about -70mV. This inhibits the release of glutamate.

Bipolar cells do not produce action potentials but do produce graded potentials (local currents). These potentials are picked up by the ganglion cells that are able to produce action potentials.

The ganglion cells carry the visual information to the optic nerve and on to the optic chiasma and optic tracts. Fibers from the medial side of each eye cross over in the optic chiasma to the contralateral side to the optic tract. Each optic tract contains fibers from the lateral side of the ipsilateral eye and fibers from the medial side of the contralateral eye. Remember that the visual image on the retinal is reversed and upside down. In essence each optic tract ends up carrying the visual information for one half of the visual field.

The optic tracts synapse with neurons in the lateral geniculate body of the thalamus. The neurons from the thalamus project back to the primary visual cortex via the optic radiation.

Some optic tract fibers are sent to the superior colliculi for control of visual reflexes.

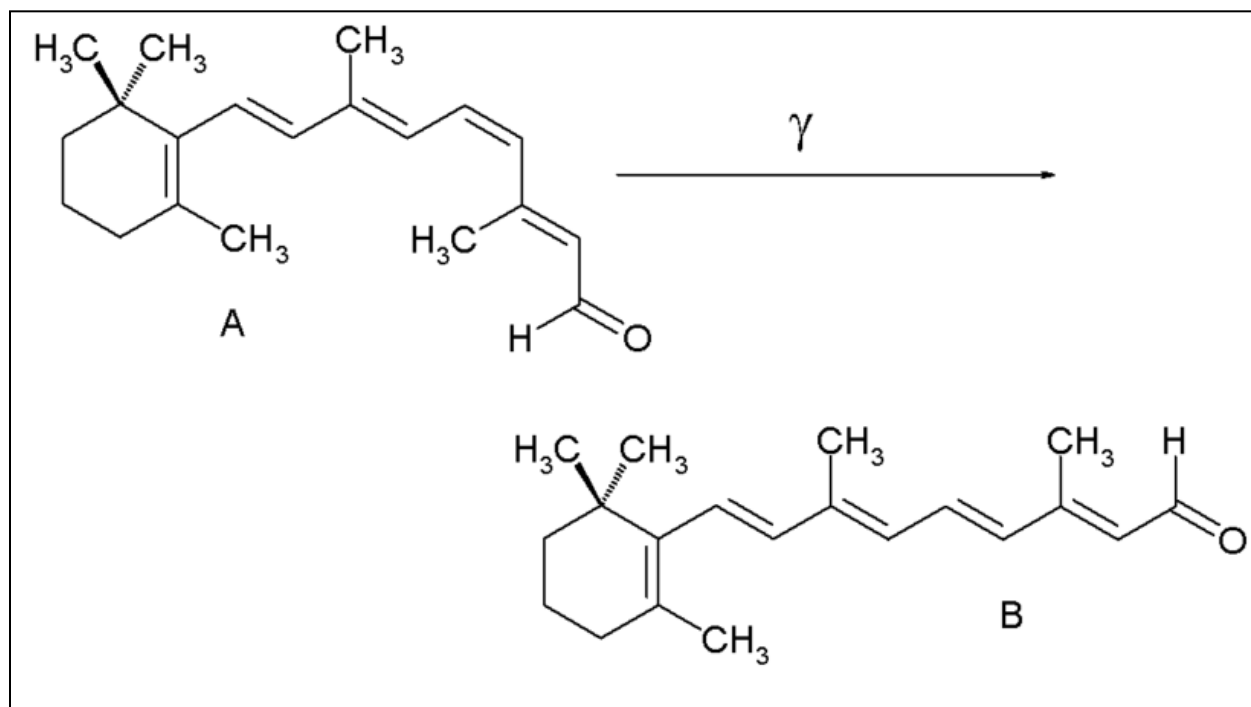


Figure 13.16. Retinal cis (top) and trans (bottom) configurations.

<http://commons.wikimedia.org/wiki/File:RetinalCisandTrans.png>

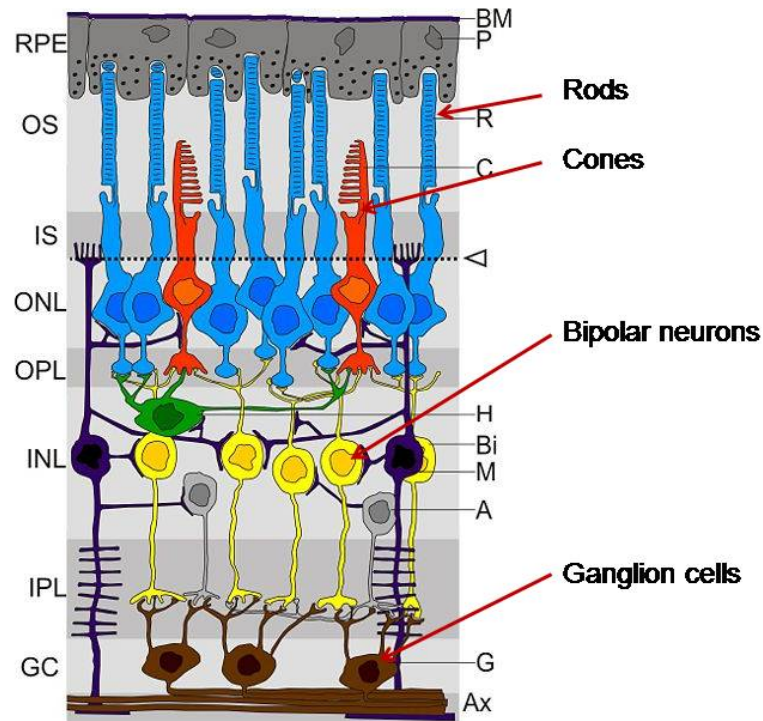


Figure 13.17. Layers of the retina.

<http://commons.wikimedia.org/wiki/File:Retina.jpg>

Author: [Peter Hartmann](#)

## Adaptation

The eyes are capable of adapting to varying intensities of light. You may notice this when walking outdoors on a bright summer day or walking into a dark theater. It takes a few seconds for your eyes to adapt.

When we walk from an area of darkness to an area of light the retina adapts by turning off the rods and decreasing its sensitivity to light. Likewise when we move into areas of darkness rhodopsin builds up and the rods take over. It is interesting to note that peripheral vision is more acute in dark conditions because of the rods.

### Stereoscopic Vision

Both right and left visual fields overlap by about 170 degrees. Each eye has a slightly different perspective of the environment. The neurocortex combines the images and produces depth perception.

### Color Blindness

Color blindness results from a lack of one or more types of cones. Since the abnormality is linked to the X chromosome it is more prevalent in males. The most common type is red-green color blindness in which red and green are seen as the same color. Up to 8-10% of the male population may have some degree of color blindness (fig. 13.18).




Figure 13.18. Ishihara color blindness test object.

[http://commons.wikimedia.org/wiki/File:Ishihara\\_1.PNG](http://commons.wikimedia.org/wiki/File:Ishihara_1.PNG)

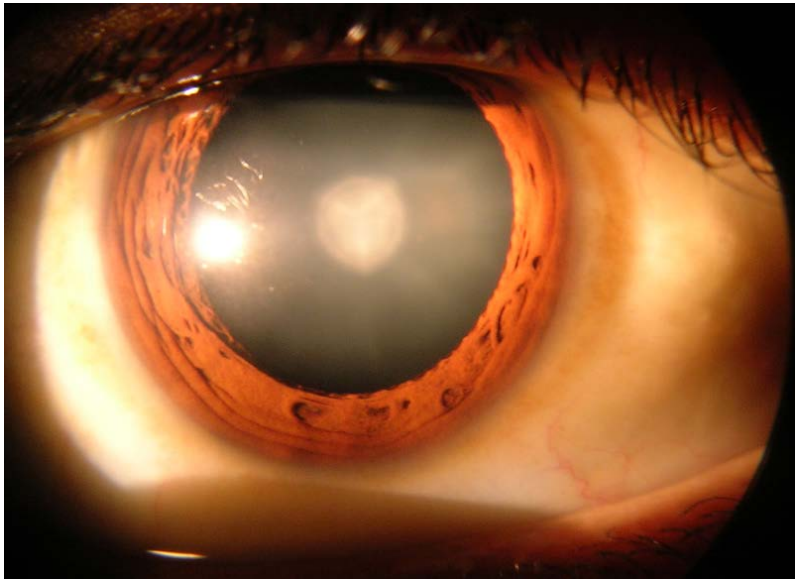


Figure 13.19. Cataract.

[http://commons.wikimedia.org/wiki/File:Cataract\\_in\\_human\\_eye.png](http://commons.wikimedia.org/wiki/File:Cataract_in_human_eye.png)

Author: Rakesh Ahuja, MD

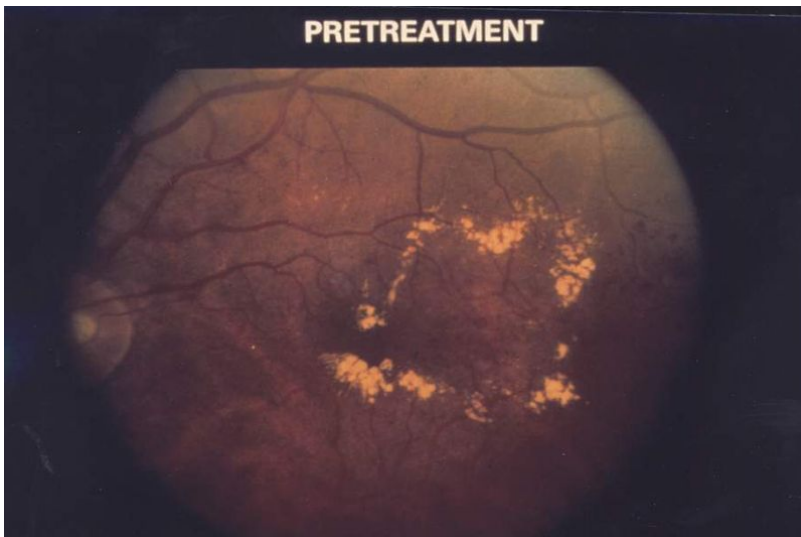

Figure 13.20. Diabetic macular edema.

[http://commons.wikimedia.org/wiki/File:Fundus\\_Diabetic\\_macular\\_edema\\_EDA04.JPG](http://commons.wikimedia.org/wiki/File:Fundus_Diabetic_macular_edema_EDA04.JPG)

Author: Rakesh Ahuja, MD

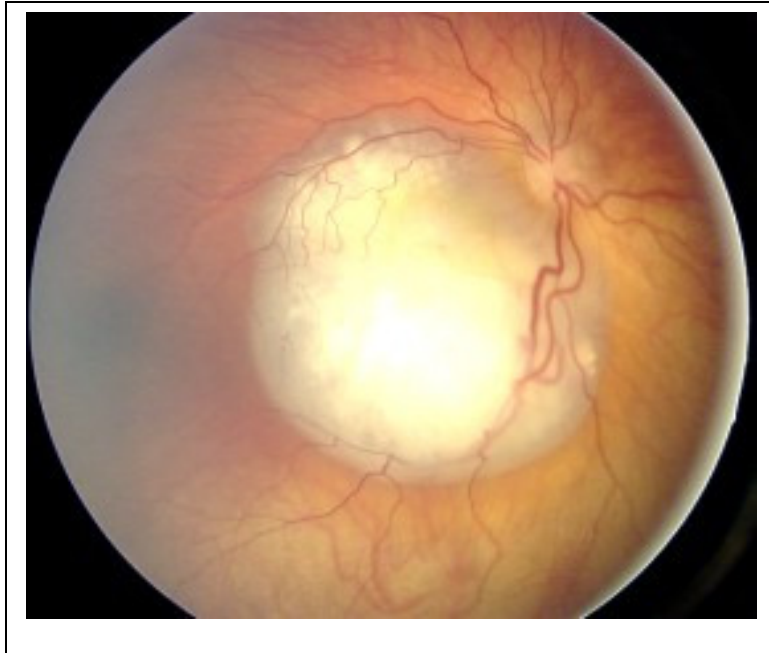


Figure 13.21. Retinoblastoma.

[http://commons.wikimedia.org/wiki/File:Fundus\\_retinoblastoma.jpg](http://commons.wikimedia.org/wiki/File:Fundus_retinoblastoma.jpg)

## **The Ear**

The ear is divided into three areas: external, middle and inner ear (fig. 12.22).

### **External Ear**

The external ear consists of the auricle (pinna) and the external auditory meatus (canal). The auricle is the outer portion of the ear consisting of elastic cartilage covered by skin. Its oval rim is called the helix and the earlobe is also known as the lobule. The external auditory meatus is a canal that extends from the outside to the tympanic membrane. It is lined with skin containing sebaceous glands, hair and ceruminous glands that secrete a waxy substance called cerumen (ear wax). Cerumen traps foreign particles and helps to protect the canal.

### **Middle Ear**

The tympanic membrane is the boundary between the external and middle ear. It consists of a thin layer of connective tissue. It has a layer of skin on its external surface and a mucous membrane on its internal surface. It is slightly cone-shaped with the apex pointing toward the middle ear.

The middle ear resides in a hollow chamber called the tympanic cavity. The cavity is lined with a mucous membrane. The cavity contains a canal called the Eustachian tube (pharyngotympanic tube) that connects with the nasopharynx. The tube is normally closed but opens with chewing, yawning or swallowing. The tube opens briefly to equalize pressure between the tympanic cavity and the outside. Changes in pressure can disrupt the vibrations of the tympanic membrane and produce muffled sounds.

Three small bones called auditory ossicles transmit vibrations from the tympanic membrane to the oval window of the inner ear. These are the malleus, incus and stapes (hammer, anvil, stirrup). The ossicles also magnify the vibrations from the tympanic membrane by their leverage.

Two small muscles, the stapedius and tensor tympani connect to the ossicles and work to maximize the vibrations carried to the oval window. The stapedius connects to the stapes and the tensor tympani connects to the malleus. These muscles also work to protect the ear from loud noises (tympanic reflex). This works much like putting pressure on the head of a drum while someone is beating it. The effect is to dampen the sound.

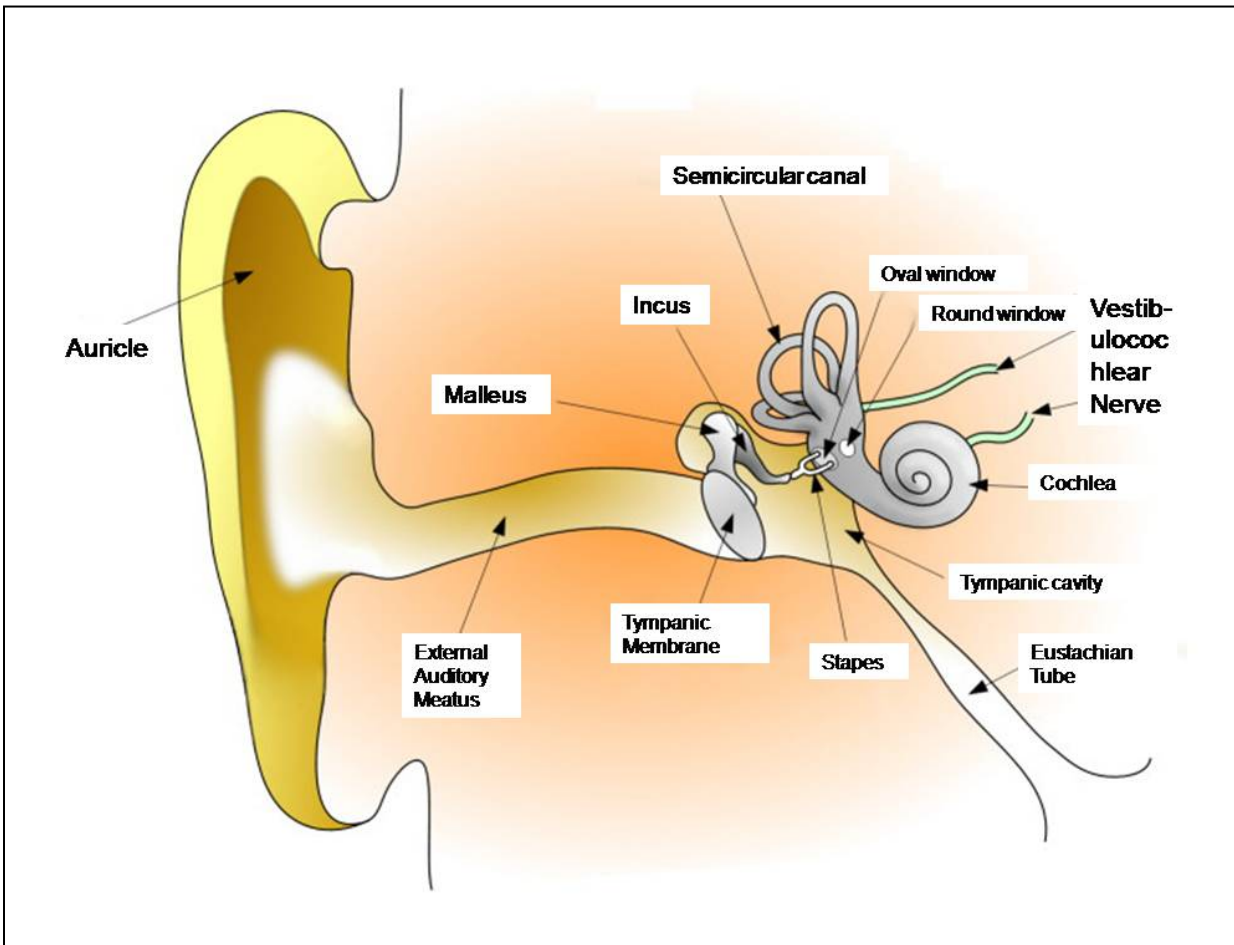


Figure 13.22. Ear anatomy

[http://commons.wikimedia.org/wiki/File:HumanEar\\_svenska.png](http://commons.wikimedia.org/wiki/File:HumanEar_svenska.png)

Author: Dan Pickard



## Inner Ear

The inner ear resides within a cavity inside of the temporal bone. It consists of the cochlea, vestibule and semicircular canals. The inner ear is sometimes referred to as the bony labyrinth. On the inside of the bony labyrinth resides a membranous labyrinth that contains fluid (fig. 13.23).

The cochlea is a spiral shaped structure that connects to the anterior portion of the vestibule. The cochlea winds around a bony structure called the modiolus. The cochlea contains three hollow chambers filled with fluid (figs. 13.24, 13.25). The innermost chamber is known as the cochlear duct (scala media) and contains the organ of Corti (spiral organ) which senses hearing. The scala vestibule is a chamber that lies superior to the cochlear duct and the scala tympani lies inferior to the cochlear duct. The scala tympani ends at the round window. The scala vestibule and scala tympani connect with each other at a point called the helicotrema which is located at the apex of the cochlear duct.

The cochlear duct also contains the vestibular membrane which is a thin fluid secreting membrane that produces a fluid called endolymph. The vestibular membrane is located on the superior aspect of the cochlear duct. The inferior aspect contains another membrane called the basilar membrane which is important in producing hearing.

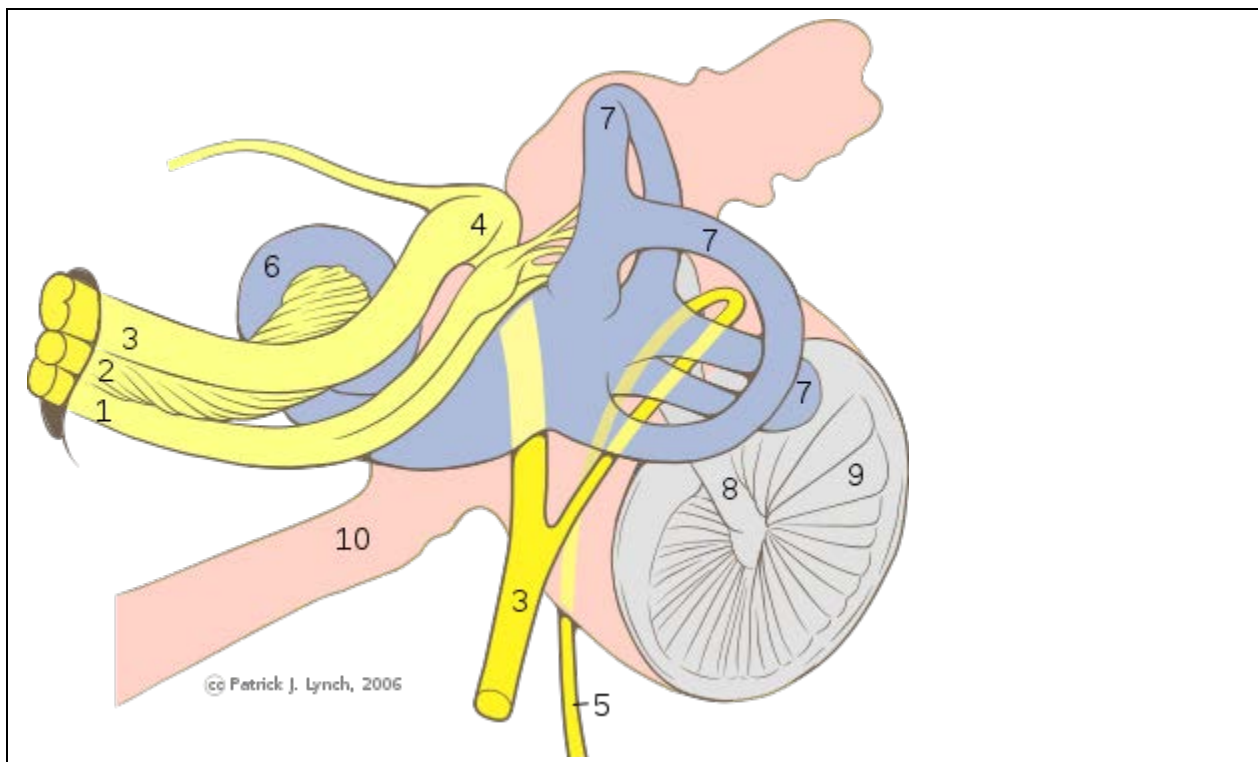


Figure 13.23. Structures of the inner ear.

1 Vestibular portion of CN VIII, 2 Cochlear portion of CN VIII, 3 Intermediate portion of CN VIII, 4 Ganglion geniculi, 5 Chorda tympani, 6 Cochlea, 7 Semicircular canals, 8 Malleus, 9 Tympanic membrane, 10 Eustachian tube

[http://commons.wikimedia.org/wiki/File:Ear\\_internal\\_anatomy\\_numbered.svg](http://commons.wikimedia.org/wiki/File:Ear_internal_anatomy_numbered.svg) Author: Patrick J. Lynch

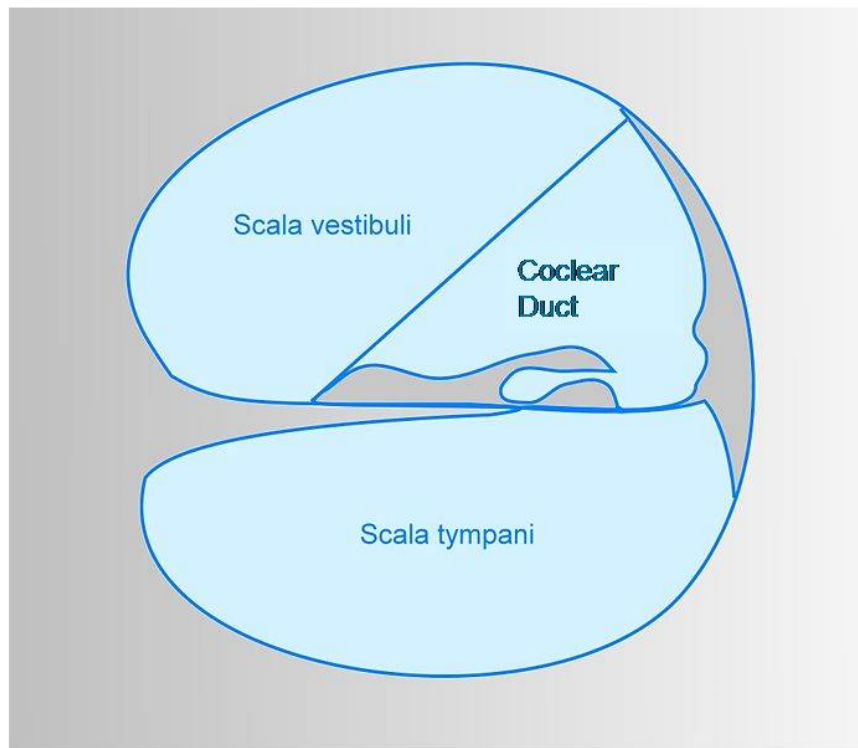


Figure 13.24. Chambers of the cochlea.

[http://commons.wikimedia.org/wiki/File:Ductus\\_cochlearis\\_schema.jpg](http://commons.wikimedia.org/wiki/File:Ductus_cochlearis_schema.jpg)

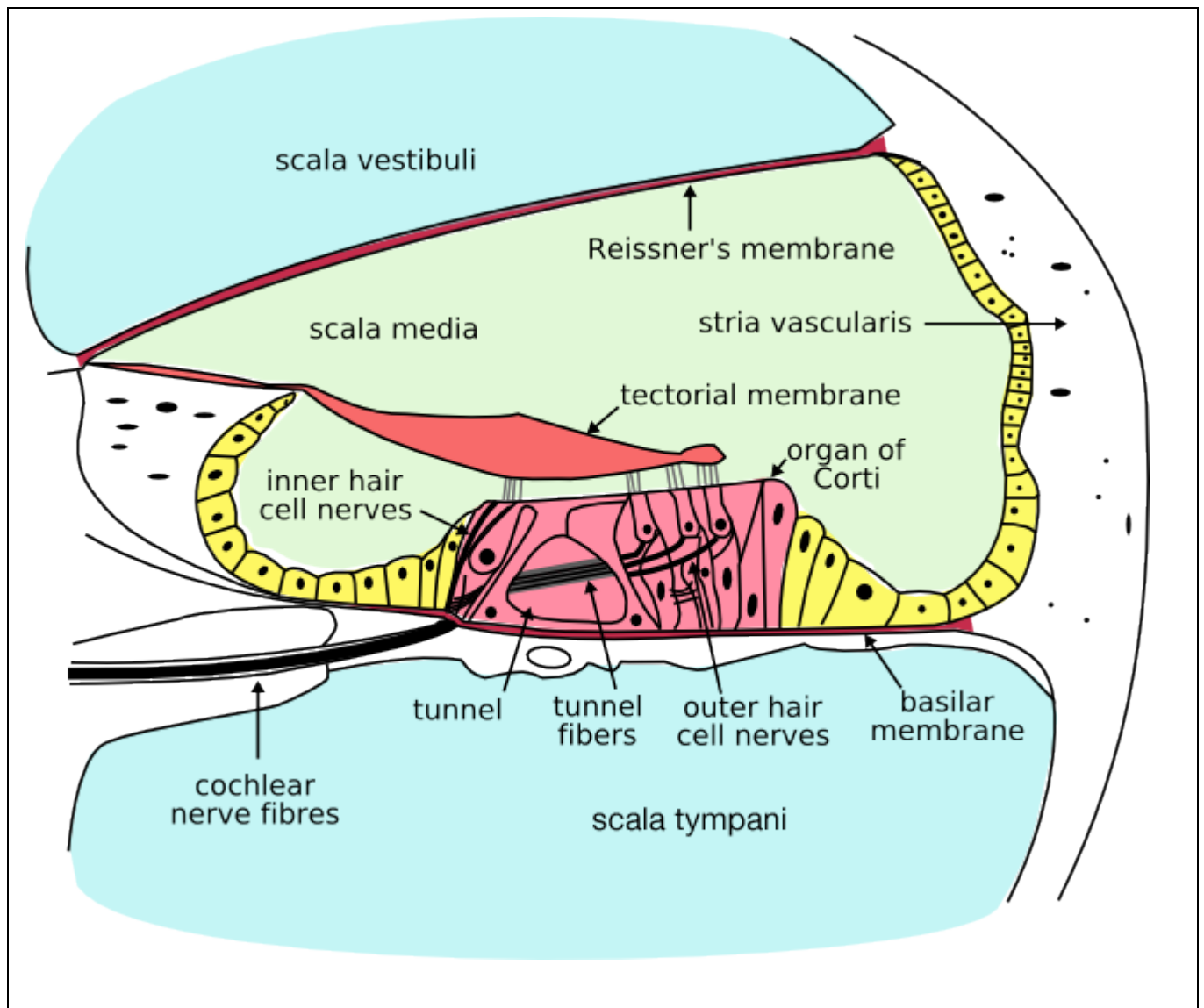


Figure 13.25 Inner ear structures.

<http://commons.wikimedia.org/wiki/File:Cochlea-crosssection.png>

## How the Ear Processes Hearing

We must remember that sound consists of changes in air pressure or vibrations in other media (figs. 13.26, 13.27). Sound waves consist of areas of high and low pressure that move (propagate) through the air. Sound can be represented as waves such as sine waves (fig. 13.26). The peaks of the wave represent areas of high pressure while the valleys represent low pressure areas.

If you were to measure the distance from one wave to another you would have what is called the wavelength. If you were to count the number of waves passing a point in one second you would have the frequency. The shorter the wavelength the higher the frequency. Higher frequency sounds are higher pitched sounds and vice versa.

The amplitude or height of the wave represents the intensity or volume of the sound. Intensity or loudness is measured in decibels (dB). The decibel scale is a logarithmic scale so a 10dB sound is 100 times more intense than a 0dB sound. The threshold of pain is 130dB.

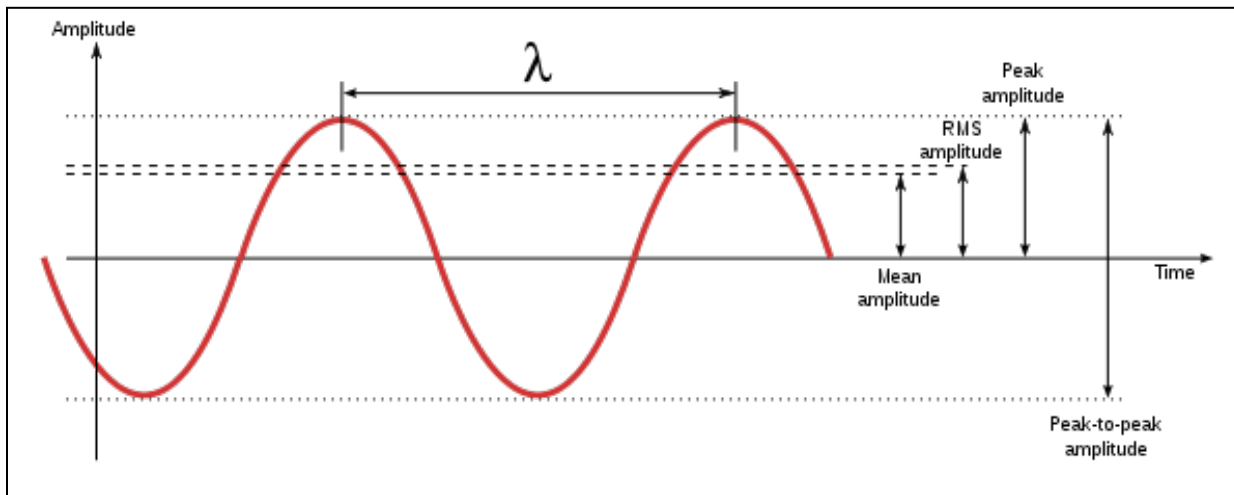


Figure 13.26. Pure tones are sine waves.

[http://commons.wikimedia.org/wiki/File:Sinus\\_amplitude\\_en.svg](http://commons.wikimedia.org/wiki/File:Sinus_amplitude_en.svg)

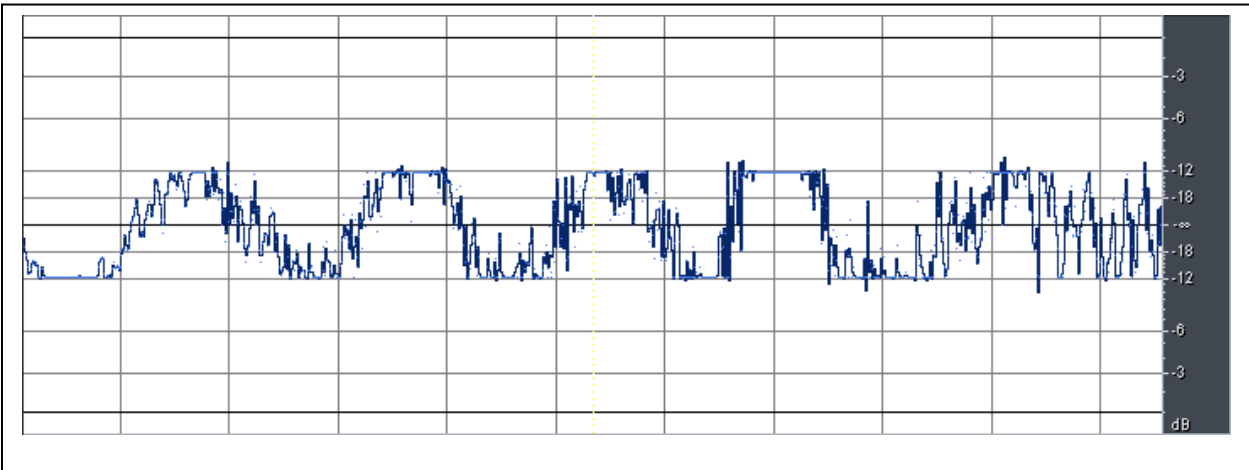


Figure 13.27. Sound is a complex wave consisting of areas of high and low pressure.

[http://commons.wikimedia.org/wiki/File:ALC\\_-12dB\\_clipped\\_closeup.png](http://commons.wikimedia.org/wiki/File:ALC_-12dB_clipped_closeup.png)

Sound waves enter the external ear and are picked up by the tympanic membrane. The tympanic membrane vibrates much like the head of a drum when struck. The vibrations are picked up by the auditory ossicles (malleus, incus and stapes) and transmitted to the oval window of the inner ear. The vibrations are actually amplified at this point.

The fluid filled chambers of the inner ear pick up the vibrations. The perilymph in the scala vestibule then carries the vibrations toward the helicotrema. Vibrations within the audible range of human hearing (20 frequencies per second to 20,000 frequencies per second) move through the cochlear duct and into the perilymph of the scala tympani.

As vibrations move through the cochlear duct they move the basilar membrane. Different portions of the basilar membrane respond or resonate to different frequencies. For example areas near the oval window resonate with higher frequency sounds while areas near the helicotrema resonate with lower frequency sounds.

The organ of Corti contains specialized hair cells (cochlear hair cells) that are located between the tectorial and basilar membranes. There are three rows of outer hair cells and one row of inner hair cells. The hair cells directly connect with the cochlear portion of the vestibulocochlear nerve (cranial nerve VIII). The hair cells also contain cilia that bend in accordance to vibrations of the basilar membrane. Bending of the cilia of the hair cells in one direction causes depolarization and subsequent release of glutamate. Bending the cilia in the other direction inhibits depolarization.

The impulses generated in the cochlea travel to the spiral ganglion and to the superior olivary nucleus where they synapse with neurons from the lateral lemniscus. The information is then carried to the inferior colliculus and then to the auditory cortex in the temporal lobe. Auditory reflexes are also processed in the medial geniculate body of the thalamus and superior colliculus.

## Balance and Equilibrium

The ear also senses changes in position (static equilibrium) and motion (dynamic equilibrium). This processing occurs in the vestibule and semicircular canals collectively called the vestibular apparatus.

### Static Equilibrium

Static equilibrium is sensed by the vestibule. Inside the vestibule are two structures called the utricle and saccule (fig. 13.28). The utricle and saccule both contain another structure called a macula that contains hair cells much like those of the cochlea. The hairs of the hair cells are connected to the otolithic membrane. The otolithic membrane contains tiny stones called otoliths (otoconia).

In the utricle the macula is in the horizontal plane with the hairs extending vertically when the head is in an upright position. As the head moves in the horizontal plane or tilts the otoliths pull on the membrane which in turn bends the hair cells. The bending of the hair cells generates impulses that are transmitted to the vestibular portion of the vestibulocochlear nerve (cranial nerve VIII).

The macula in the saccule operates the same way but is oriented in the vertical plane. Thus the saccular macula responds more to vertical motion.

This system only responds to changes in motion.

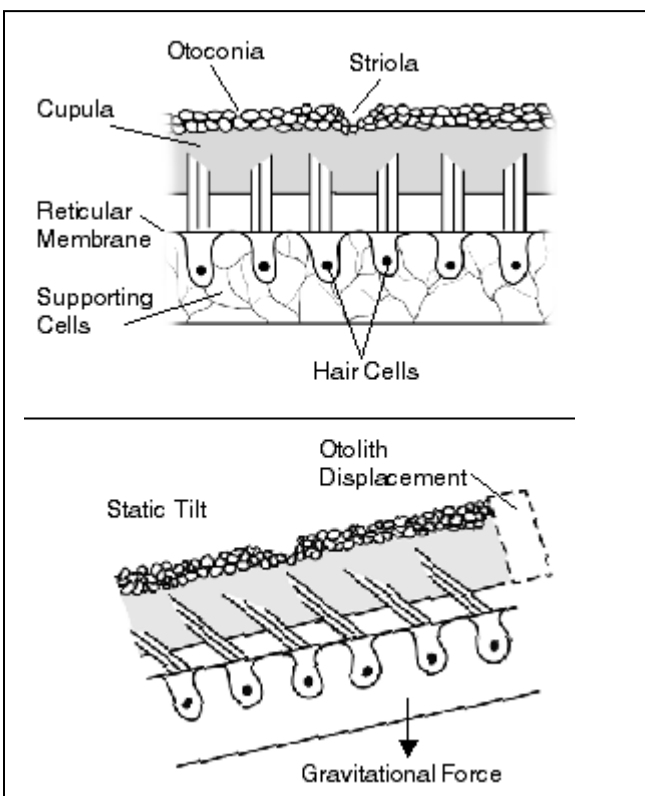


Figure 13.28. Vestibule

[http://commons.wikimedia.org/wiki/File:Balance\\_Disorder\\_Illustration\\_B.png](http://commons.wikimedia.org/wiki/File:Balance_Disorder_Illustration_B.png)

## Dynamic Equilibrium

The semicircular canals sense changes in motion. At the base of each semicircular canal is a bulge called an ampulla. Inside the ampulla is a structure called the crista ampullaris. The crista ampullaris also contains hair cells that attach to a gel-like membrane called a cupula (fig. 13.29).

Movement of the head causes fluid (endolymph) inside the semicircular canals to move in the opposite direction. The fluid moves over the cupula bending the cilia of the hair cells. The hair cells then depolarize or hyperpolarize in response to the bending. Impulses are sent to the vestibulocochlear nerve (cranial nerve VIII) which carries them to the vestibular nuclear complex in the brainstem or the cerebellum.

It is important to note that balance and vision are closely related. A reflex movement of the eyes called nystagmus can be created by impulses from the semicircular canals. Let's say that you were sitting on a movable chair and rotating. During the rotation your eyes move in the opposite direction. When you stop they will continue to look in the same direction for a few moments then quickly look in the opposite direction. These movements are caused by impulses from endolymph movement in the semicircular canals.

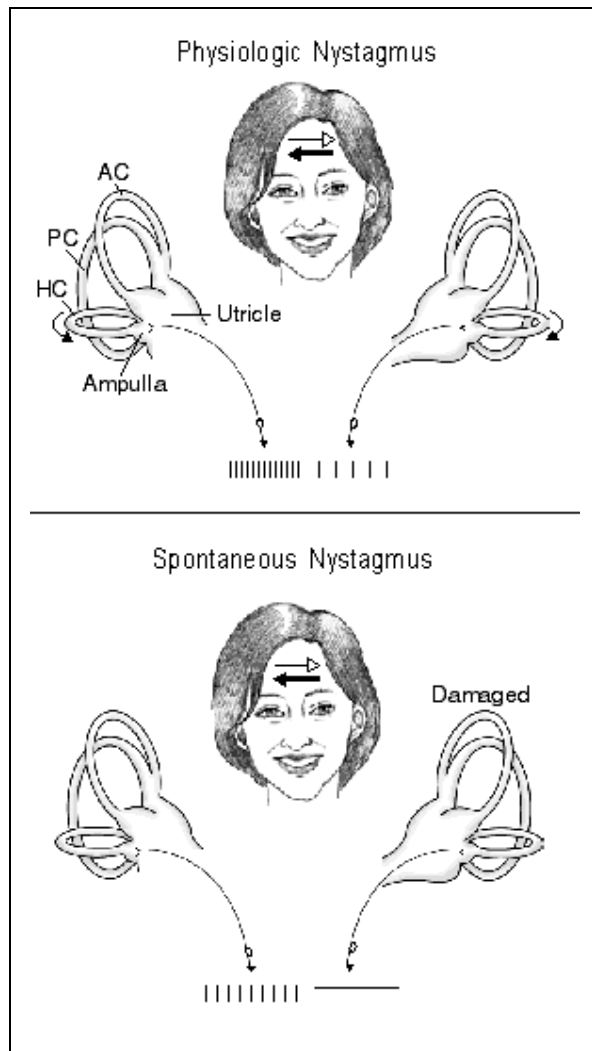


Figure 13.29. Nystagmus is caused by endolymph movement in the semicircular canals.

[http://commons.wikimedia.org/wiki/File:Balance\\_Disorder\\_Illustration\\_C.png](http://commons.wikimedia.org/wiki/File:Balance_Disorder_Illustration_C.png)

## Ear Disorders

### Otitis Media

Otitis media is an inflammation of the middle ear (fig. 13.30). The middle ear can become infected causing the tympanic membrane to become red and swollen. This condition is typically treated with antibiotics. Chronic conditions may be treated with small tubes inserted in the tympanic membranes to equalize the pressure between the middle ear and outside.

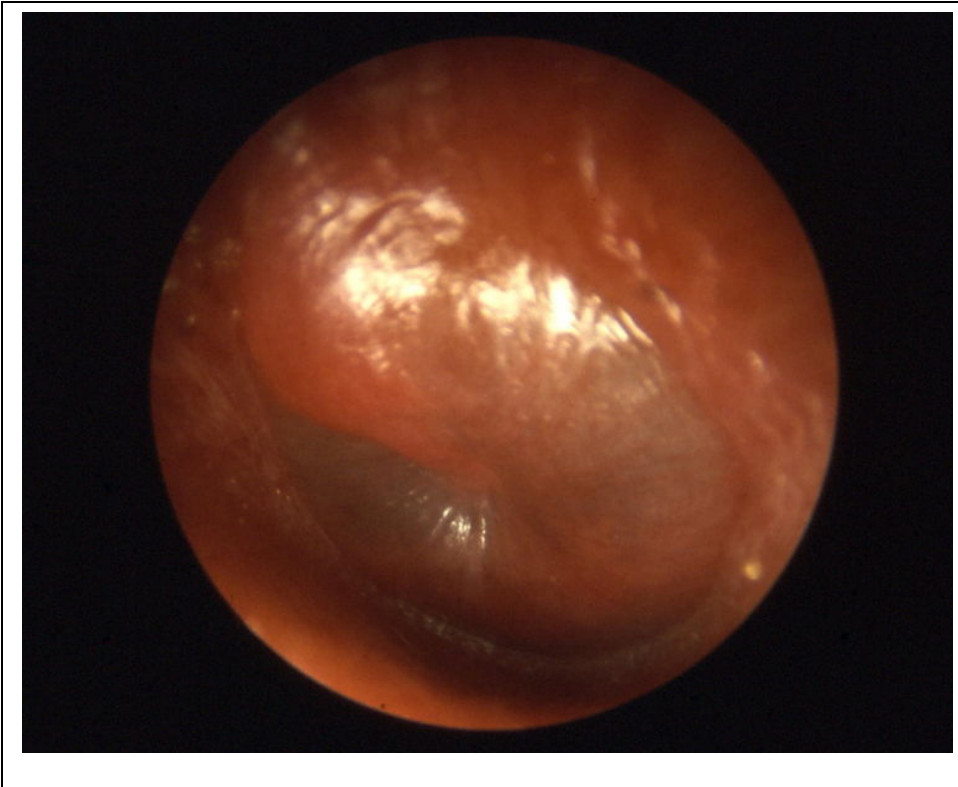

Figure 13.30. Acute otitis media. Note the bulging, red, inflamed eardrum.

[http://commons.wikimedia.org/wiki/File:Otitis\\_media\\_entdifferenziert2.jpg](http://commons.wikimedia.org/wiki/File:Otitis_media_entdifferenziert2.jpg)

Author: B. Welleschik



**Conduction Hearing Loss**

Conduction hearing loss results from a blockage somewhere in the ear canal that prevents vibrations from getting to the inner ear. This can result from earwax, ruptured eardrum, or degeneration of the auditory ossicles called otosclerosis.

**Sensorineural Hearing Loss**

Sensorineural hearing loss results from damage to the neural structures of the inner ear. This could include the cochlear hair cells (from exposure to loud sounds) or portions of the vestibulocochlear nerve. Besides loud sounds, sensorineural loss results from tumors in the nerve, degeneration of the nerve or congenital problems.

## Chapter 13 Review Questions

1. Which sensory receptor senses changes in joint position:
  - a. Chemoreceptor
  - b. Osmoreceptor
  - c. Baroreceptor
  - d. Proprioceptor
2. Which of the following receptors senses heavy pressure:
  - a. Meissner's corpuscles
  - b. Merkel's discs
  - c. Pacinian corpuscles
  - d. Ruffini corpuscles
3. Which of the following produces a protective mechanism in muscles:
  - a. Golgi tendon organs
  - b. Meissner's corpuscles
  - c. Muscle spindles
  - d. Ruffini corpuscles
4. How many different types of chemical substances can we sense with our sense of smell:
  - a. 500-1000
  - b. 1000-2000
  - c. 2000-4000
  - d. 4000-6000
5. Which of the following is not a primary taste:
  - a. Bitter
  - b. Water
  - c. Sweet
  - d. Salty
6. Which of the following is not an eye muscle:
  - a. Superior rectus
  - b. Inferior oblique
  - c. Lateral rectus
  - d. Medial oblique
7. As light passes through the eye which structure will it not pass through:
  - a. Cornea
  - b. Sclera
  - c. Pupil
  - d. Vitreous humor

8. Which structure contains the photoreceptors in the eye:
- Choroid coat
  - Ciliary body
  - Retina
  - Optic nerve
9. In myopia the images focuses:
- In front of the retina
  - On the retina
  - Behind the retina
  - None of the above
10. Which best describes the function of rods:
- Work better in dim light
  - Sense color
  - Work better in daylight
  - Produce sharp central vision
11. Which is the most common form of color blindness:
- Red-orange
  - Red-green
  - Blue-green
  - Green-yellow
12. Which structure forms the boundary between the outer and middle ear:
- Pinna
  - Tympanic membrane
  - Oval window
  - Round window
13. Which structure is in the inner ear:
- Vestibule
  - Stapes
  - Tensor tympani
  - Eustachian tube
14. Which part of the ear senses static equilibrium:
- Cochlea
  - Semicircular canals
  - Vestibule
  - Tympanic membrane

15. Which of the following is sensed by otoliths pulling on a membrane:

- a. Sound
- b. Static equilibrium
- c. Proprioception
- d. Dynamic equilibrium

16. Which cranial nerve carries the sensation of hearing:

- a. Hypoglossal
- b. Spinal accessory
- c. Vestibulocochlear
- d. Trigeminal

# Chapter 14

## The Endocrine System

## Endocrine System

The endocrine system controls many functions of the human body much like the nervous system. The endocrine system can be considered a “link” between organs and cells. In past sections we saw other similar links between systems. For example, in the nervous system, we examined a number of chemicals called neurotransmitters that were released by neurons that affected other neurons. In the muscular section we saw neurotransmitters affecting muscular contraction. These and other links exist largely to support homeostasis. In homeostasis, changes in the internal or external environment of the body are sensed invoking some sort of correcting mechanism to keep the system in “balance.” This is what the endocrine system does.

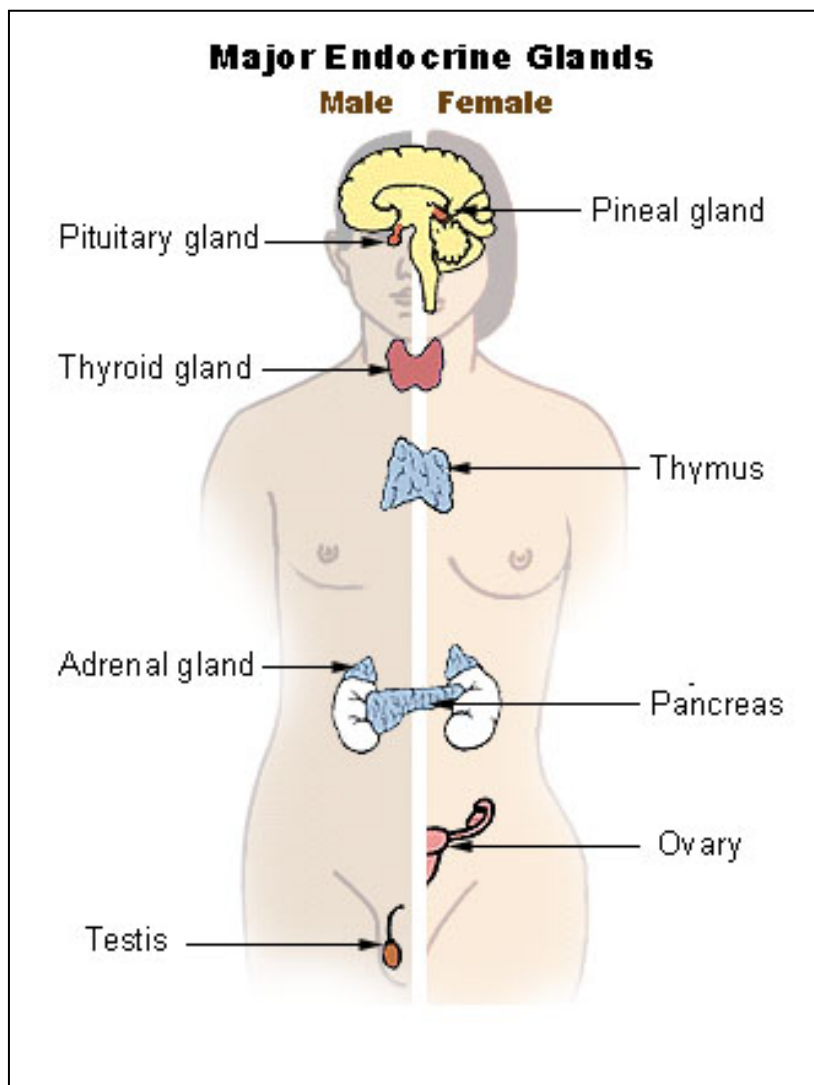


Figure 14.1. Endocrine System

[http://commons.wikimedia.org/wiki/File:Illu\\_endocrine\\_system.jpg](http://commons.wikimedia.org/wiki/File:Illu_endocrine_system.jpg)

## **General Overview of Endocrine Function**

The endocrine system senses changes in the internal or external environment and responds by secreting hormones. The hormones travel to target cells containing specific receptors for hormones. The target cells then respond by altering function (fig. 14.1).

Target cells undergo a variety of changes in response to stimulation from hormones. Examples include controlling rates of certain chemical reactions, transporting substances through membranes, regulating fluid and electrolyte balance and controlling reproduction, development and growth.

### ***What are Hormones?***

The glands of the endocrine system secrete hormones. Hormones are largely proteins. There are a number of classifications of hormones. Amines are derived from amino acids and are synthesized in the adrenal medulla. Peptides are short-chained amino acids found in the posterior pituitary gland and hypothalamus. Steroids are derived from cholesterol and are lipid soluble. Proteins are very long chains of amino acids found in the parathyroid glands and anterior pituitary gland. Prostaglandins have a local effect and only affect nearby cells.

Hormones are very powerful in that they can invoke major changes in the body in very small amounts.

Hormones travel via three major routes. Hormones can travel through the bloodstream, to nearby cells or even to other locations within the same cell.

### ***How do hormones affect cells?***

Simplest case: Prostaglandins

Prostaglandins are secreted by cells and have a local effect. This means that they only travel to nearby cells. This is known as a paracrine secretion. Once the hormone reaches the target cell, it can use the second messenger system. Prostaglandins help to control smooth muscle contraction and relaxation. Prostaglandins also help to promote inflammation.

More Complicated: Steroid Hormones

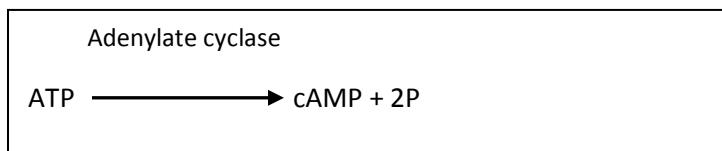
Steroid hormones are transported in the blood. They connect with a special transport protein known as a carrier protein. Once reaching the target cell, the hormone disassociates from the carrier protein.

Remember that lipid soluble substances can diffuse through a cell membrane. Since steroid hormones are considered lipids, they can diffuse through the cell membrane and enter the cell. Once inside the cell, steroid hormones combine with specialized receptors located within the cytoplasm of the cell. Once the hormone combines with the receptor, the receptor-hormone complex moves into the nucleus of the cell. There it invokes changes in DNA transcription that in turn cause changes in the metabolism of the cell characteristic of the hormone.

Most Complex: Non-steroid Hormones

Non-steroidal hormones enter the cell differently than steroids. Non-steroidal hormones are not lipid soluble, since they cannot diffuse directly into the cell and must enter via a different process. Non-steroid hormones enter the cell by using what are known as second messengers. Receptors for non-steroidal hormones are located in the cell walls of the target cells. When the hormone connects to the

receptor on the outside of the cell membrane, a protein known as a G-protein is activated and moves down the membrane into the cell. The G-protein binds to an enzyme known as adenylate cyclase and activates it. Adenylate cyclase then becomes involved in the reaction:



cAMP is known as cyclic adenylate monophosphate and is considered the second messenger in the system. cAMP in turn activates another inactive enzyme called protein kinase. Protein kinase facilitates the phosphorylation of various proteins. Phosphorylation occurs when phosphates are attached to a molecule. The phosphorylated proteins then activate some enzymes and inactivate others inside the cell. This alters the metabolic activity of the cell and the cell responds in accordance with the intended action of the hormone.

Results of second messenger activation include altered membrane permeability, activation of enzymes, protein synthesis, modulation of metabolic pathways, promoting movement of cells and causing secretion of other hormones .

cAmp works with a variety of hormones including those from:

- Hypothalamus
- Anterior pituitary
- Posterior pituitary
- Parathyroid
- Adrenals
- Thyroid
- Pancreas

There are other second messengers besides cAMP. These include:

- Diacylglycerol (DAG)
- Inositol triphosphate (IP3)
- Cyclic guanosine monophosphate (cGMP)

Hormones operating via 2<sup>nd</sup> messengers have a much greater response. Many 2<sup>nd</sup> messengers can be activated by one hormone.

### **Pituitary Gland**

The pituitary gland sits in the sella turcica of the sphenoid bone. It is positioned in close proximity to the hypothalamus and is connected to the hypothalamus by a stalk-like structure called the infundibulum.



The pituitary gland is divided into 2 sections. The anterior pituitary (aka adenohypophysis) and the posterior pituitary (aka neurohypophysis) each secrete different hormones.

Other chemicals secreted by the hypothalamus known as “releasing factors” influence hormones secreted by the anterior pituitary. Thus the nervous system exhibits some control over secretions of the anterior pituitary.

The hypothalamus communicates with the anterior pituitary gland via a capillary network that interconnects the two structures. Blood levels of hormones are monitored by the hypothalamus causing the secretion of releasing factors that control release of anterior pituitary hormones.

The communication between the hypothalamus and posterior pituitary is somewhat different than in the case of the anterior pituitary. The hypothalamus and posterior pituitary connect through a series of specialized nerve cells called neurosecretory cells. The hypothalamus produces the hormones secreted by the posterior pituitary.

### **Anterior Pituitary Hormones**

#### **Growth Hormone (aka somatotropin)**

Growth hormone secretion occurs in response to two secretions by the hypothalamus: Growth hormone releasing hormone (GHRH) and somatostatin (SS). Growth hormone affects cellular metabolism by promoting the movement of amino acids into cells for protein synthesis which affects the overall growth of the organism. Growth hormone releasing hormone secreted by the hypothalamus stimulates the release of growth hormone by the anterior pituitary. Somatostatin inhibits the release of growth hormone.

Growth hormone stimulates cells to enlarge and undergo mitosis as well as increasing the rate of protein synthesis and increasing the cellular use of carbohydrates and fats.

#### **Prolactin (PRL)**

Prolactin secretion occurs in response to two secretions by the hypothalamus. Prolactin releasing factor (PRF) stimulates secretion of prolactin by the anterior pituitary. Prolactin inhibiting hormone (PIH) from the hypothalamus inhibits secretion of prolactin by the anterior pituitary.

The function of prolactin is to stimulate milk production in females. In males, prolactin decreases the secretion of luteinizing hormone which facilitates production of the primary male sex hormones or androgens. Too much prolactin secretion in males can cause infertility.

#### **Thyroid Stimulating Hormone (TSH) (aka thyrotropin)**

Thyroid stimulating hormone secretion by the anterior pituitary occurs in response to the release of thyrotropin releasing hormone from the hypothalamus. Thyroid stimulating hormone causes the thyroid gland to release the thyroid hormones triiodothyronine and tetraiodothyronine (T3 and T4). The blood concentration of thyroid hormones provides a negative feedback mechanism to the hypothalamus to help control the release of thyroid stimulating hormone. Secretion of T3 and T4 is also affected by stress.

Thyroid stimulating hormone also stimulates growth of the thyroid gland.

#### **Real World A&P**

Normal TSH levels range from 1-4U/ml. The TSH test is important in differentiating primary from secondary hypothyroidism (low thyroid hormone levels). If TSH levels are increased, primary hypothyroidism is indicated. This means that anterior pituitary continues to secrete larger amount of TSH in response to low levels of the hormones produced by the thyroid gland itself. This indicates that there is a problem with the thyroid gland producing thyroid hormones. In secondary hypothyroidism, both TSH and thyroid hormone levels are decreased. Causes include pituitary dysfunction and hyperthyroidism.

#### **Adrenocorticotrophic Hormone (ACTH)**

Adrenocorticotrophic hormone is secreted by the anterior pituitary in response to secretion of corticotrophic releasing hormone (CRH) by the hypothalamus. ACTH is picked up by the adrenal cortex and stimulates secretion of hormones by the adrenal cortex. Adrenal cortex hormones then provide feedback to the hypothalamus and anterior pituitary to help regulate secretion of ACTH. Stress also affects secretion of ACTH.

#### **Follicle Stimulating Hormone (FSH)**

Follicle stimulating hormone is secreted by the anterior pituitary partly in response to the secretion of a releasing factor known as gonadotropin releasing hormone (GnRH). In females, FSH stimulates growth and development of egg-cell containing follicles in ovaries and stimulates follicular cells to produce estrogen. In males, FSH stimulates the production of sperm cells in the testes when the male reaches puberty.

#### **Luteinizing Hormone (LH)**

Luteinizing hormone secretion is controlled in part by the release of gonadotropin releasing hormone by the hypothalamus. Luteinizing hormone stimulates the glands of the reproductive system to produce sex hormones.

#### **Posterior Pituitary Hormones**

The posterior pituitary contains specialized nerve cells called neurosecretory cells that originate in the hypothalamus. The secretions of these cells function as hormones rather than neurotransmitters in that the target tissues are contained in glands outside of the nervous system.

#### **Antidiuretic hormone (ADH)**

Antidiuretic hormone secretion by the posterior pituitary occurs in response to concentration changes sensed by osmoreceptors located in the hypothalamus. The action of ADH is to cause the kidneys to conserve water. The target tissue of this hormone lies in the kidney, particularly the distal convoluted

tubule. ADH acts to make the distal convoluted tubule more permeable to water which, in turn, causes conservation of fluids and decreased urine output.

Remember, a diuretic increases urine output and consequently decreases overall blood volume. Antidiuretic hormone has the opposite effect in an effort to conserve fluids and blood volume. If blood solute concentration increases, ADH is released in an attempt to conserve water and produce a more dilute blood. If blood solute concentration decreases, the release of ADH is inhibited.

### **Oxytocin (OT)**

Oxytocin helps to stimulate uterine contractions during labor by causing the smooth muscles in the uterine wall to contract. During pregnancy, the uterus becomes more sensitive to oxytocin. Oxytocin also helps to stimulate release of milk from mammary glands. Although oxytocin is produced in males, its function is not well understood.

#### **Real World A&P**

Oxytocin is sometimes injected into women to stimulate contractions and induce labor. Besides stimulating contractions, oxytocin also causes vasoconstriction of the uterine blood vessels and causes the uterus to shrink. This helps to reduce bleeding.

### **The Thyroid Gland**

The thyroid gland is located in the anterior portion of the throat just inferior to the thyroid cartilage (Adam's apple) (figs. 14.2, 14.3). It contains distinct regions of tissues known as follicles. The structure of thyroid tissue produces two main cell types: those located within the follicle structure known as follicular cells, and those not located in the follicle known as extrafollicular or parafollicular cells. Both cell types secrete hormones. The follicular cells secrete triiodothyronine (T3) and tetraiodothyronine (T4). These hormones are secreted in response to the secretion of thyroid stimulating hormone from the anterior pituitary gland. Both of these hormones affect overall metabolism by increasing the cellular metabolism of carbohydrates, proteins and lipids. Both T3 and T4 require the presence of iodine in order to be produced. Iodine and thyronine (an amino acid) are joined in the follicular cells. Triiodothyronine has 3 iodines and Tetraiodothyronine has 4 iodines.

Thyroxine (T4) is the most abundant thyroid hormone. It works to increase metabolism and stimulates the cardiovascular system. It also works to differentiate cells. T3 (Triiodothyronine) is secreted in smaller amounts but is the more active form. Most of the T4 converts to T3.

### **Real World A&P**

A benign tumor of the thyroid gland called a goiter can develop from the lack of dietary iodine. In this case, since iodine is not present in the diet, TSH continues to be released by the anterior pituitary in an effort to produce T3 and T4. But since there is insufficient iodine to produce T3 and T4, the levels of T3 and T4 decrease. The thyroid gland enlarges or hypertrophies due to the continuous stimulation by the action of TSH. Often, the inclusion of dietary iodine can counteract this phenomenon.

### **Real World A&P**

#### **Hyperthyroidism**

Typical T4 levels range from 4-11 g/dl and T3 levels range from 110-230 ng/dl. An increase in T3/T4 indicates hyperthyroidism. In infants this is known as Cretinism. In adults it is known as Grave's disease. Cretinism is characterized by mental retardation, low body temperature and growth abnormalities. Grave's disease is characterized by exophthalmos (protruding eyes), high metabolic rate, heat sensitivity, restlessness and weight loss.

An increase in thyroid hormone levels can also occur in thyroiditis (an inflammation of the thyroid gland, thyrotoxicosis and tumors.

#### **Hypothyroidism**

Low T3/T4 levels indicate hypothyroidism known as myxedema. Signs of myxedema include a rounded face, swelling of the hands, feet and periorbital tissue. If left untreated, myxedema can lead to coma and death.

A rare form of hypothyroidism is called Hashimoto's hypothyroidism. This is an autoimmune disorder where the patient's own antibodies bind to receptors on the thyroid and mimic the action of TSH.

## Calcitonin

The other thyroid hormone has an effect on blood calcium levels and is called calcitonin. Calcitonin is secreted by the extrafollicular cells (aka C-cells). Calcitonin decreases blood calcium levels by decreasing osteoclastic activity and increasing osteoblastic activity. Osteoclasts work to release calcium and other minerals from bone into the blood stream. Osteoblasts work to build up bone by storing these minerals into bone. Calcitonin also affects calcium reabsorption in the kidneys by inhibiting it thereby causing increased calcium excretion in the urine. It is said that calcitonin works to “tone down” the calcium levels in blood.

Calcitonin is released in response to increases in blood calcium levels. This happens for example in pregnancy when an increase in blood calcium is needed for the development of the fetus.

### Real World A&P

Typical calcitonin levels are less than 50 pg/ml. Increased calcitonin levels occur in medullary carcinoma of the thyroid gland, oat cell carcinoma of the lung, breast and pancreatic cancers, thyroiditis and pernicious anemia.

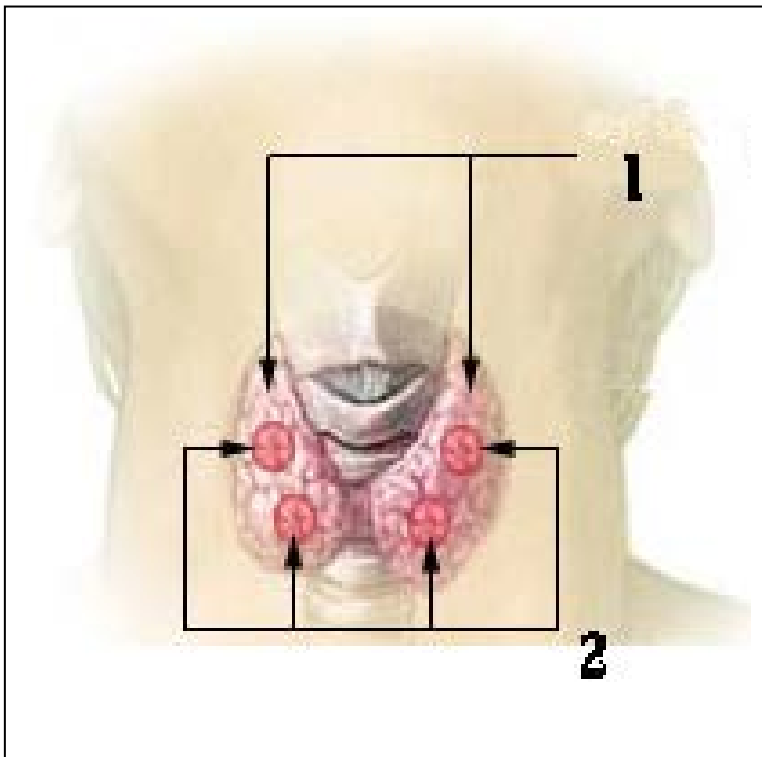


Figure 14.2. Location of the thyroid gland.

1. Thyroid. 2. Parathyroids

<http://commons.wikimedia.org/wiki/File:Thyroidgland-intl.png>

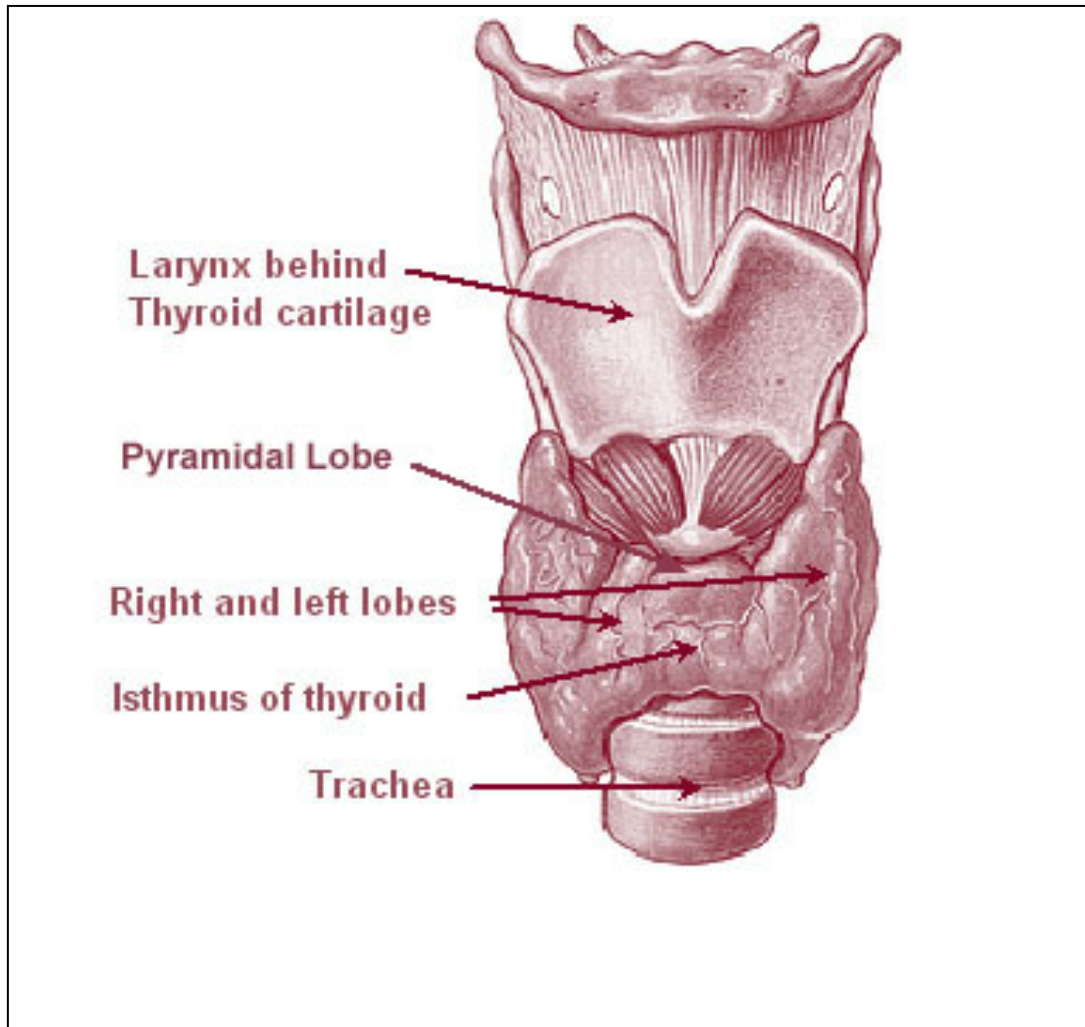


Figure 14.3. Thyroid gland.

[http://commons.wikimedia.org/wiki/File:Illu08\\_thyroid.jpg](http://commons.wikimedia.org/wiki/File:Illu08_thyroid.jpg)

## Parathyroid Glands

The parathyroid glands are four small masses of glandular tissue located on the posterior surface of the thyroid gland (fig. 14.2). These small glands contain secretory cells as well as capillaries. The parathyroid glands secrete one hormone aptly called parathyroid hormone (PTH). Parathyroid hormone works to increase blood calcium levels and decreases blood phosphate levels. PTH does this by stimulating osteoclastic activity to release calcium and other bone minerals into the bloodstream and inhibiting osteoblastic activity. Remember osteoblasts work to store minerals in bone (fig. 14.4).

PTH also stimulates the production of vitamin D which in turn facilitates the absorption of calcium in the intestine. Vitamin D (aka cholecalciferol) is produced by converting provitamin D stored in the skin to vitamin D. This is done with the help of ultraviolet radiation from the sun. Vitamin D is also stored in tissues after it is converted to a storage form known as dihydroxycholecalciferol by the liver. PTH changes dihydroxycholecalciferol to the active form of vitamin D (cholecalciferol) which facilitates calcium absorption in the intestines. PTH also stimulates the release of the phosphate ion in the kidneys. All of these actions work to increase calcium concentration in the blood. Thus calcium levels are controlled by both calcitonin from the thyroid and parathyroid hormone.

### Real World A&P

#### Parathyroid Scan.

The parathyroid scan is a procedure using radioactive materials (radionucleotides) injected into the patient. The material is absorbed by both the thyroid and parathyroid glands and a subsequent scan can detect the concentration of the radioactive material. Information such as the location, position and size of the parathyroids can be interpreted from the scan. Normal parathyroid function is indicated if the material is absorbed by the glands. Abnormal function is indicated by an adenoma (a benign tumor).



Calcium regulation in the blood.

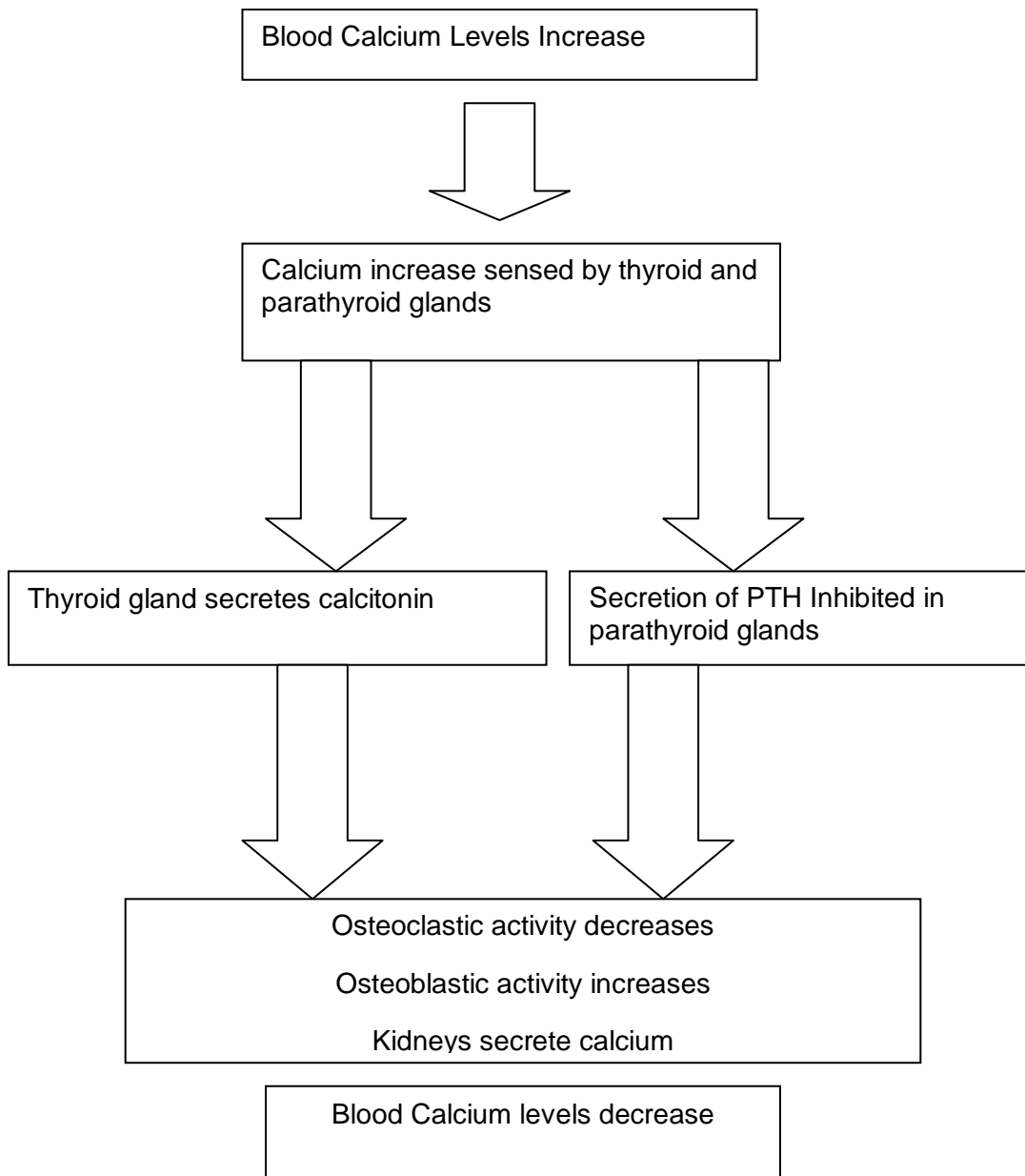


Figure 14.4. Hormonal regulation of calcium.

Bruce Forciea

## The Adrenal Glands

The adrenal glands are two small pyramid shaped glands located on top of the kidneys (superior aspect) (fig. 14.5). They consist of 2 functional areas: an outer cortex and an inner medulla. The cortex consists of 3 layers: zona glomerulosa, zona fasciculate and zona reticularis. The adrenal cortex produces a number of steroids as well as some other hormones. The hormones of the adrenal cortex and medulla are required by the body to sustain life.

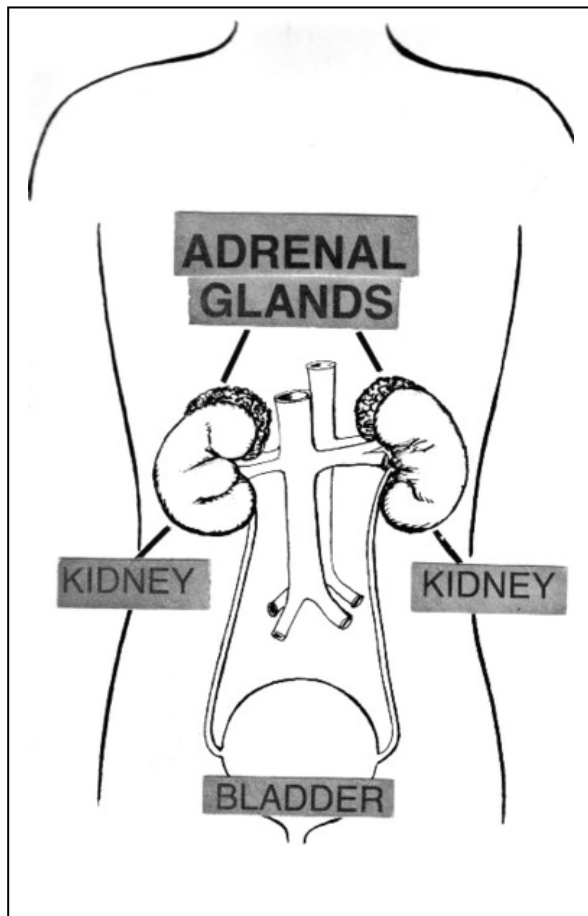


Figure 14.5. Adrenal Glands

[http://commons.wikimedia.org/wiki/File:Adrenal\\_gland\\_\(PSF\).png](http://commons.wikimedia.org/wiki/File:Adrenal_gland_(PSF).png)

## **Adrenal Cortex Hormones**

### **Aldosterone**

Aldosterone is produced by cells of the zona glomerulosa of the adrenal cortex. Aldosterone acts to regulate electrolytes such as magnesium and potassium. These are known as mineral electrolytes, thus aldosterone is known as a mineralcorticoid.

Aldosterone causes the kidney to conserve sodium and excrete potassium. The release of aldosterone is more strongly facilitated by the increase in plasma potassium concentration. The decrease in plasma sodium concentration does not affect the secretion of aldosterone as strongly. However, the decrease in sodium concentration can affect the renin-angiotensin system in the kidneys (see urinary system) and stimulates the release of aldosterone. Both aldosterone and the renin-angiotensin system work together to conserve blood volume and sodium. Aldosterone works by inhibiting the release of sodium by the kidney and the renin-angiotensin system works by causing vasoconstriction.

Aldosterone is also released via stimulation of the adrenal cortex by ACTH.

### **Cortisol (aka cortisone)**

Cortisol is also secreted by the adrenal cortex, specifically by the cells of the zona fasciculata. Cortisol has an effect on glucose metabolism, thus it is called a glucocorticoid. Cortisol secretion increases glucose levels in the blood. It does this by stimulating the liver to convert non-carbohydrates into glucose. This process is called gluconeogenesis. It also stimulates the release of fatty acids for use as an energy source. These processes help to regulate the level of blood glucose between meals.

Cortisol is released in response to the release of ACTH by the anterior pituitary gland. Remember that ACTH is released in response to release of CRH by the hypothalamus. This system provides a negative feedback mechanism to help control the level of cortisol in the blood.

#### **Real World A&P**

Cortisol is sometimes used to control inflammation. It is injected into the body (cortisone injection). Cortisol works by inhibiting prostaglandin synthesis (prostaglandins work to increase inflammation) and increasing local vasoconstriction of the damaged tissue.

## Sex Hormones

The inner layer of the adrenal cortex (zona reticularis) secretes sex hormones. The secretion of sex hormones from the adrenal glands helps contribute to the supply of hormones from the reproductive glands. These hormones are male hormones known as androgens but may be converted to estrogen in the female. These hormones help to develop the primary sex characteristics.

## Adrenal Medulla

The adrenal medulla, or inner portion of the adrenal gland is closely connected to the sympathetic nervous system. The adrenal medulla contains specialized cells called chromaffin cells that secrete chemicals called catecholamines. The catecholamines that are produced are norepinephrine and epinephrine. These chemicals should sound familiar because they were introduced as neurotransmitters in the sympathetic nervous system. Therefore, norepinephrine (NE) and epinephrine (E) have both neurotransmitter and hormonal actions.

NE and E are secreted by the adrenal medulla in response to impulses produced by the sympathetic nervous system (SNS). The SNS is connected via nerve fibers to the adrenal medulla. The actions of NE and E from the adrenal medulla are similar to the actions of the (SNS). Thus secretion of NE and E will cause an increase in heart rate, blood pressure, respiration, and a decrease in digestion. The hormonal action of NE and E lasts longer than neurotransmitter action because it takes longer to remove NE and E from the endocrine system. Both the adrenal glands and the SNS work together to provide the sympathetic response.

## The Pancreas

The pancreas is located in the abdominal cavity at the flexure of the proximal portion of the small intestine called the duodenum (fig. 14.6). It is connected to the duodenum by ducts. It produces both digestive and hormonal secretions and performs a dual role in these systems. Our focus in the section will be on the hormonal secretions of the pancreas.

The internal structure of the pancreas consists of groupings of cells around capillary beds. The groupings of cells are called Islets of Langerhans and consist of 3 distinct types of cells: alpha, beta and delta cells. Each cell type produces a different secretion. Alpha cells secrete glucagons, beta cells secrete insulin and delta cells secrete somatostatin.

Glucagon (alpha cells) works to increase the level of glucose in the blood. It does this by stimulating the liver to convert the storage form of glucose (glycogen) into glucose via a process known as glycogenolysis. Glucagon also stimulates the process of gluconeogenesis, which converts non-carbohydrates substances into glucose in the liver and breaks down fats into fatty acids and glycerol.

Glucagon is secreted when glucose levels are diminished in the blood. Secretion of glucagon is inhibited by high glucose blood levels.

Insulin (beta cells) works to decrease the levels of glucose in the blood. It does this by reversing the processes stimulated by glucagon. Insulin facilitates the storage of glucose in the liver by stimulating the production of glycogen from glucose. Insulin also inhibits the process of gluconeogenesis, stimulates protein synthesis and increases the storage of lipid in adipose tissue.

Insulin also facilitates the release of glucose into body tissues by stimulating facilitative diffusion of glucose carriers in cell membranes.

Insulin is secreted when blood glucose levels are high and inhibited when blood glucose levels are low.

Somatostatin (secreted by the delta cells) inhibits both glucagon and insulin secretion. Thus it also works to control glucose levels in the blood.

### **Real World A&P**

#### **Diabetes**

Diabetes is a disease that affects insulin production in the pancreas. There are 2 types. Type I diabetes is caused by an autoimmune disorder in which the body's own immune cells attack the cells in the Islets of Langerhans in the pancreas (the beta cells that produce insulin). Type I diabetes is also known as Juvenile onset diabetes because it manifests before the early 20's. Symptoms of Type I diabetes include weight loss, glucose in the urine (glucosuria), and poor wound healing or ulcers. If untreated, a buildup of ketone bodies occurs as a result of excess fat metabolism. This can lower pH causing metabolic acidosis. The lowered pH can adversely affect neurons causing coma and death. Treatment includes daily insulin injections.

Type II diabetes, also known as adult onset diabetes, develops in middle-aged adults from loss of insulin receptors in the cell membranes. Risk factors include weight gain and sedentary lifestyle. Treatment includes weight loss and exercise.

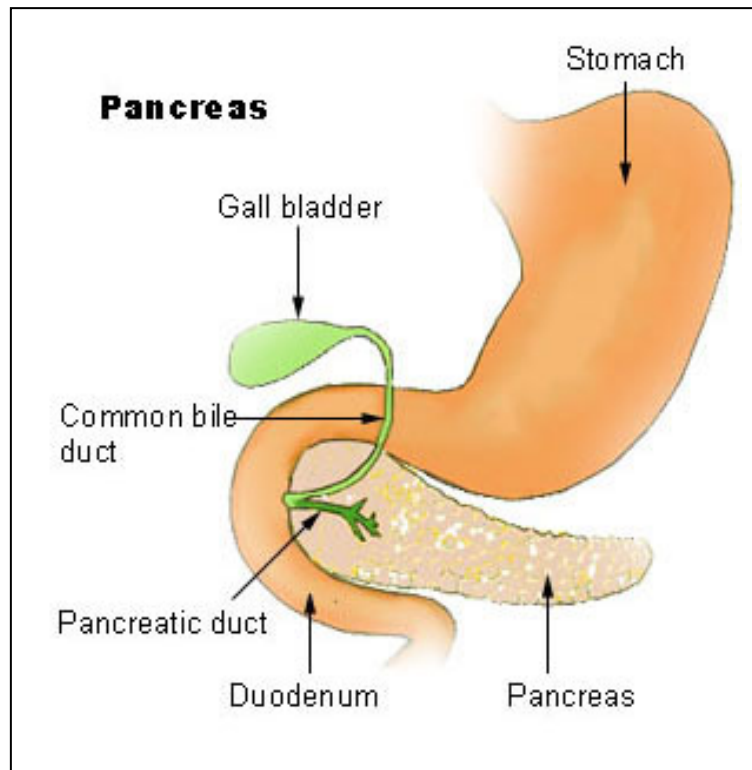


Figure 14.6. Pancreas

[http://commons.wikimedia.org/wiki/File:Illu\\_pancrease.jpg](http://commons.wikimedia.org/wiki/File:Illu_pancrease.jpg)

## The Pineal Gland

The pineal gland is a small pinecone shaped gland located between the cerebral hemispheres (fiig. 14.7). It attaches to the posterior portion of the thalamus. The pineal gland secretes melatonin. Melatonin is synthesized from the neurotransmitter serotonin and is involved in the regulation of sleep-wake cycles known as circadian rhythms. Melatonin secretion increases with a decrease in light. Melatonin also helps to regulate the menstrual cycle.

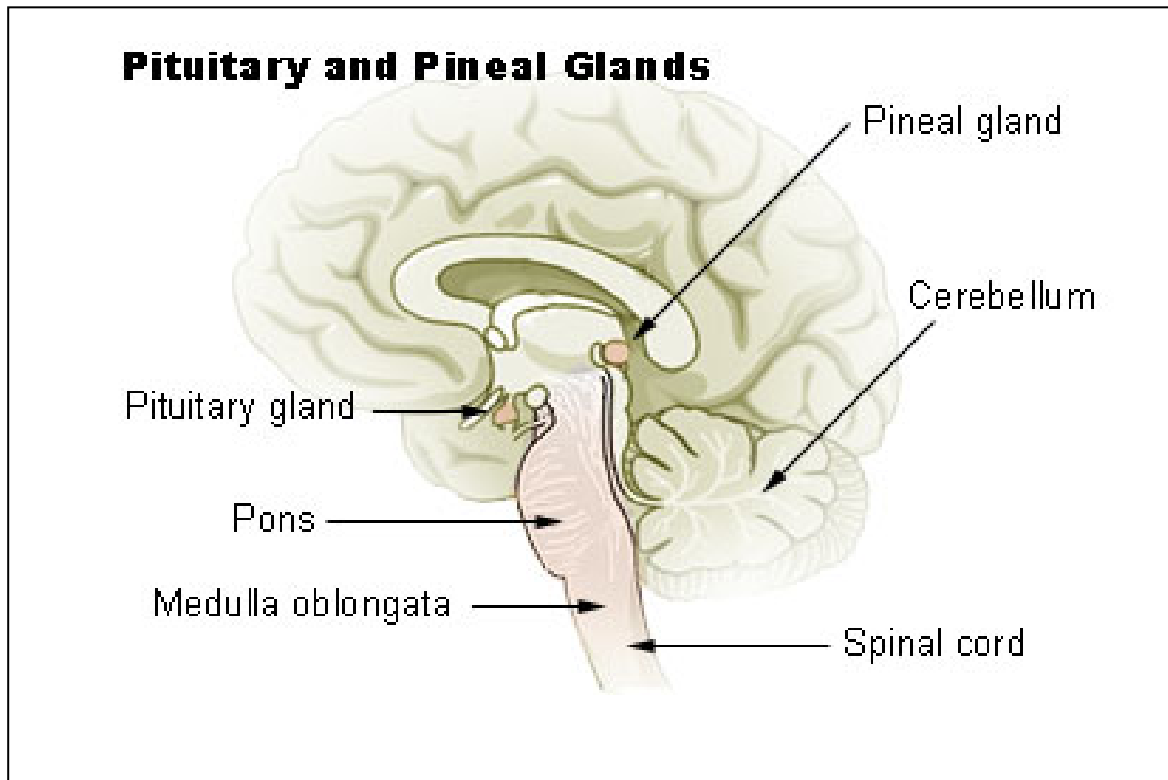


Figure 14.7. Pineal Gland

[http://commons.wikimedia.org/wiki/File:Illu\\_pituitary\\_pineal\\_glands.jpg](http://commons.wikimedia.org/wiki/File:Illu_pituitary_pineal_glands.jpg)

## The Thymus Gland

The thymus gland is located posterior to the sternum. It is larger at birth and shrinks throughout adulthood (fig. 14.8). The thymus gland secretes thymosins. Thymosins function in facilitating the production of a type of white blood cell known as a T-lymphocyte which functions in immunity.

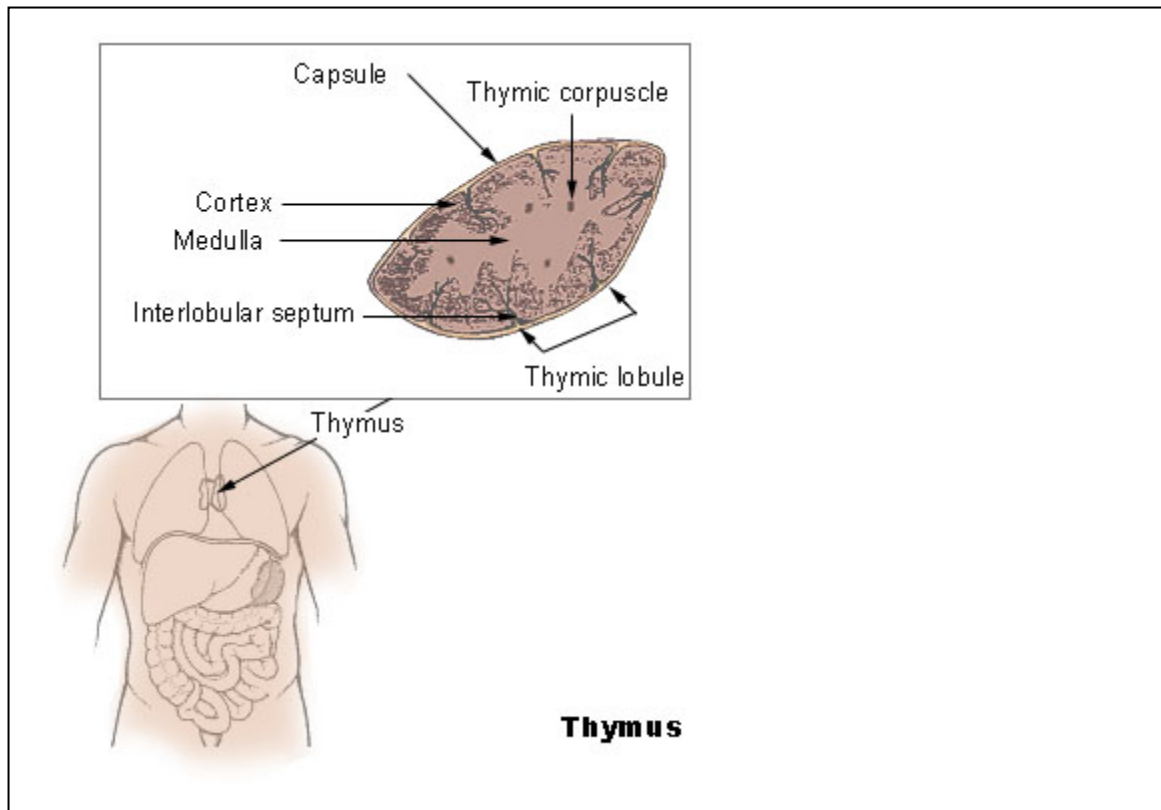


Figure 14.8. Thymus Gland

[http://commons.wikimedia.org/wiki/File:Illu\\_thymus.jpg](http://commons.wikimedia.org/wiki/File:Illu_thymus.jpg)



## The Reproductive Glands

The ovaries and placenta in the female as well as the testes in the male secrete hormones that have a role in the endocrine system. The ovaries and placenta secrete estrogen and progesterone. The placenta also secretes a gonadotropin. The testes secrete testosterone. These hormones and glands will be discussed in more detail in the reproductive system section.

### Real World A&P

#### Metabolic Syndrome

Before developing diabetes many people develop a condition known as metabolic syndrome or syndrome X. Eating foods high in sugar can lead to this. People first develop metabolic syndrome and this eventually develops into diabetes.

**Here are some of the signs of metabolic syndrome:**

- *High blood pressure (135/85 or greater)*
- *Central obesity—waist circumference 40 inches or more for men and 35 inches or more for women*
- *Low HDL levels (good cholesterol) less than 40 mg/dL*
- *High fasting blood glucose levels of 110 mg/dL or greater*
- *High triglycerides (150 mg/dL or greater)*

**According to the National Cholesterol Education Program if you have any three of the above signs you have metabolic syndrome.**

*Source: National Cholesterol Education Program, Third Report of the Expert Panel on Detection, Evaluation, and Treatment of High Blood Cholesterol in Adults (Adult Treatment Panel III), National Heart, Lung, and Blood Institute, National Institutes of Health, May 2001.*

## Real World A&P Blog Post

### Beating Metabolic Syndrome

It turns out that too many simple carbohydrates can have an adverse effect on our cells. To be more specific food such as high fructose corn syrup tend to down regulate our cells' insulin receptors. This leads to what is called insulin resistance. Insulin is what helps to regulate the amount of glucose in our bodies. If our receptors aren't responding the insulin can't work and we end up with more glucose in our system that is stored as fat. This leads to weight gain--middle aged spread and eventually to type II diabetes. It also contributes to the buildup of plaque in arteries.

It is better to choose foods that get converted into glucose at a slower pace. Bacon n eggs fit the bill but are too high in cholesterol. What are left are lower fat foods like most fruits, veggies, soy protein, nuts, bran.

The key is to use the glycemic index of foods. That tells how fast the food gets converted into glucose. You need to choose foods with a low (<10 is ideal) glycemic index.

Exercise also helps decrease the glucose and fat in our bodies. We don't have to get in shape to run that marathon, but 30 minutes of brisk walking can provide some nice benefits. If you need a treadmill or exercise bike just go to any neighborhood rummage sale. Walking in your local mall works too but this can get expensive.

It is important to watch your cholesterol levels but it turns out that cholesterol is not the whole story when it comes to plaquing up the arteries. For years the medical establishment touted that we get our total cholesterol under control, first below 220, then 200. Now in some cases cardiologists are comparing cholesterol lowering to the limbo game; "how low can you go?"

What may be more important than total cholesterol are those little packages of fat that your liver makes to send it around your body. There are good packages (HDLs) and bad boys (LDLs). Also, those LDLs can be big or small and it's the small ones that can deposit on the inner walls of the arteries and build up. This is kind of the like the plumbing in an old house. We used to live in one and you couldn't flush the toilet when taking a shower without reducing the comforting warm embrace of the water to a cold trickle.

So how can we keep the pipes from blocking up short of hiring Roto Rooter (in cardiology language that spells angioplasty) or rebuilding the plumbing (bypass, saw the sternum, spread those ribs--ouch!). Well statins are a start but there is more we can do by taking some important nutritional substances. Hey I know this is more pills but nutrition is good, right?

There are a few and I will start with one superstar for the heart--Co enzyme Q10 or CoQ10. This has been shown to help lower blood pressure as well as reduce the muscles aches and pains associated with statins. The recommended form is an oil-based pill and the dose is 100mg-300mg daily.

Fish are full of those amazing omega 3 fatty acids. Now there are also omega 3 eggs, cooking oils and spreads for those who are not akin to eating those scaly creatures. You have to take a pretty good dose of a high-quality capsule--3000 to 4000 mg/day with at least 30% of the capsule containing EPA and DHA.

Get in the sun, or, take vitamin D. Vitamin D helps by reducing inflammation in the plaque. There is a marker of inflammation called C-reactive protein and vitamin D has been shown to lower this. The recommended dose depends on how much sunlight you get but can range from 1000-6000 units per day for those with coronary artery disease.

There are a few more but these seem to be the main nutritional weapons that help in the fight against coronary artery disease.

## Chapter 14 Review Questions

1. Which of the following is not an endocrine gland:
  - a. Hypothalamus
  - b. Pineal
  - c. Thyroid
  - d. Ileum
2. Which of the following class of hormones is lipid soluble and derived from cholesterol:
  - a. Amines
  - b. Steroids
  - c. Peptides
  - d. Carbohydrates
3. Cyclic adenylyate monophosphate is commonly known as:
  - a. Peptide
  - b. Second messenger
  - c. Neurotransmitter
  - d. Hormone
4. Somatostatin elicits the following effect:
  - a. Facilitates secretion of growth hormone
  - b. Facilitates secretion of prolactin
  - c. Inhibits secretion of growth hormone
  - d. Inhibits secretion of prolactin
5. Which of the following hormones is not secreted by the hypothalamus:
  - a. Thyrotropin releasing hormone
  - b. Growth hormone releasing hormone
  - c. Prolactin inhibiting hormone
  - d. Adrenocorticotropin hormone
6. Which hormone is secreted in response to an increase in solute concentration of the blood:
  - a. ACTH
  - b. ADH
  - c. Insulin
  - d. Oxytocin
7. If blood calcium levels increase, which hormone will be secreted:
  - a. Oxytocin
  - b. Parathyroid hormone
  - c. Calcitonin
  - d. ACTH

8. Which of the following is a hormone of the adrenal cortex:

- a. Aldosterone
- b. Norepinephrine
- c. Insulin
- d. Corticotropin releasing hormone

9. Which hormone is secreted by the beta cells in the pancreas:

- a. Somatostatin
- b. ACTH
- c. Insulin
- d. Glucagon

10. Which hormone helps to regulate sleep wake cycles:

- a. Aldosterone
- b. Melatonin
- c. ACTH
- d. Insulin

# Chapter 15

## The Blood

## **The Blood**

Learning about the blood is our first step in studying the cardiovascular system. Blood is a very important and dynamic tissue. It carries nutrients, ions, gases, and a number of chemicals as well as specialized cells. It is capable of producing important reactions in stopping bleeding and fighting infection.

Blood is considered a connective tissue. Its primary constituents include specialized cells such as red blood cells (RBCs), white blood cells (WBCs), cell fragments known as platelets, and a straw colored liquid called plasma. The cells are known as the formed elements of blood and each has specialized functions.

The volume of blood in the typical adult is approximately five liters. Besides containing the formed elements, plasma contains vitamins, amino acids, proteins, carbohydrates, lipids, cellular wastes and hormones.

### **Cells and Plasma**

If we were to separate the solid from the liquid portion of blood we would see that it is about 45% cells and 55% plasma by volume. This separation is done in clinical laboratories and is called a hematocrit.

The fluid portion of blood is known as plasma. Plasma contains a variety of substances including water, proteins, carbohydrates, lipids, amino acids, vitamins, hormones, electrolytes and waste products.

The solid portion consists of cells. All blood cells come from the same cell of origin known as a hemocytoblast (stem cell)(fig. 15.1). The hemocytoblast can differentiate into any of the mature blood cells by responding to factors called colony stimulating factors.

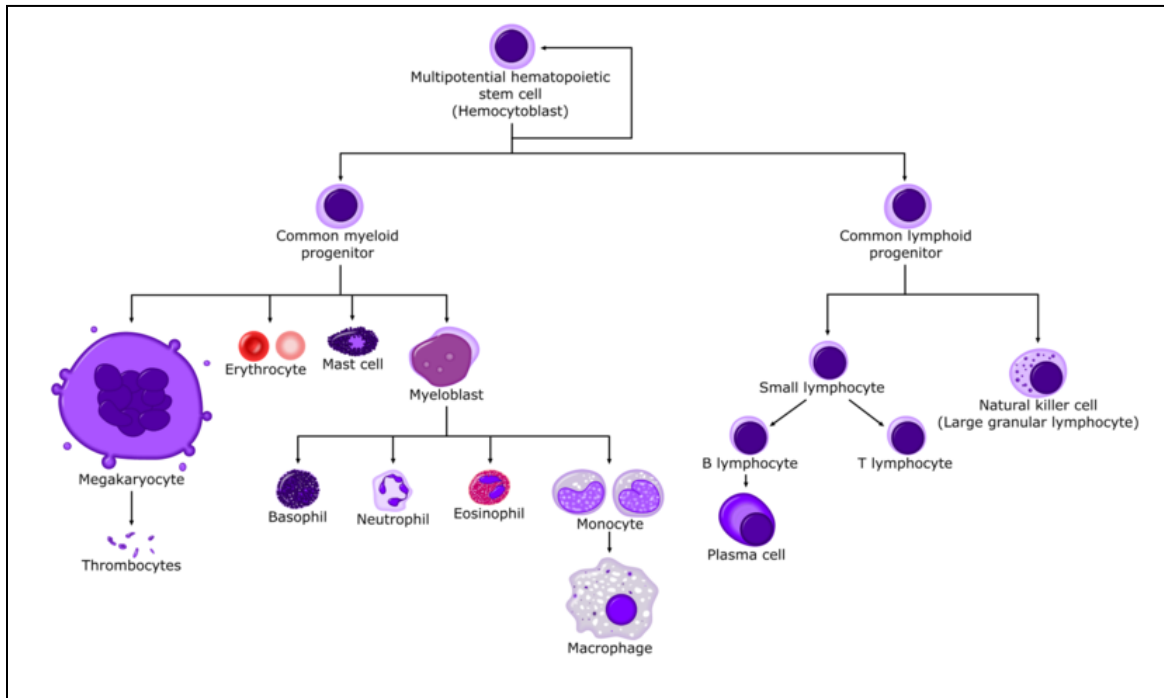


Figure 15.1. Hematopoiesis.

[http://commons.wikimedia.org/wiki/File:Hematopoiesis\\_simple.png](http://commons.wikimedia.org/wiki/File:Hematopoiesis_simple.png)

Author: [Mikael Häggström](#)

## Red Blood Cells

Red blood cells (aka erythrocytes) make up the largest percentage of the formed elements of blood. The red blood cell's primary function is to transport oxygen and carbon dioxide. They have a unique biconcave disc shape that functions to increase the surface area of the cell in order to allow a greater amount of oxygen binding (fig. 15.2). The red color of the cell is due to the presence of a protein molecule called hemoglobin. Hemoglobin makes up about one third of the cell's volume.

Hemoglobin is the transport molecule for oxygen and carbon dioxide. Oxyhemoglobin is formed when oxygen combines with hemoglobin. Oxyhemoglobin is a bright red color.

Deoxyhemoglobin is formed when oxygen is released from hemoglobin. Deoxyhemoglobin is a dull red color. Deoxygenated blood looks bluish under the skin because the skin filters out some of the light.

Hemoglobin also transports carbon dioxide (fig. 15.3). Carbaminohemoglobin is formed when carbon dioxide combines with hemoglobin. A small amount of carbon dioxide is transported this way.

Since the main function of red blood cells is to transport gasses, there is no need for a nucleus or mitochondria.

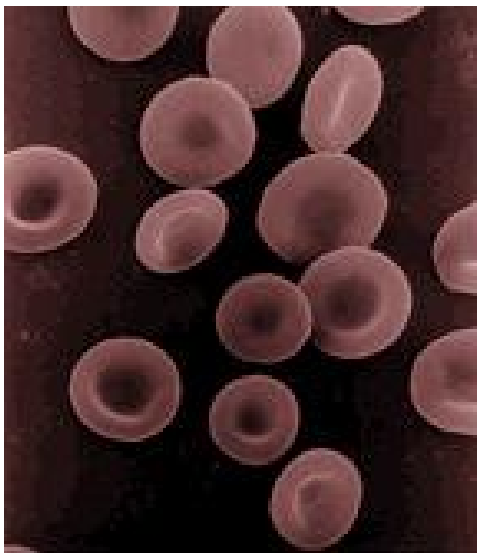


Figure 15.2. Red blood cells have a unique biconcave disc shape.

[http://commons.wikimedia.org/wiki/File:Red\\_bloodcells.jpg](http://commons.wikimedia.org/wiki/File:Red_bloodcells.jpg)



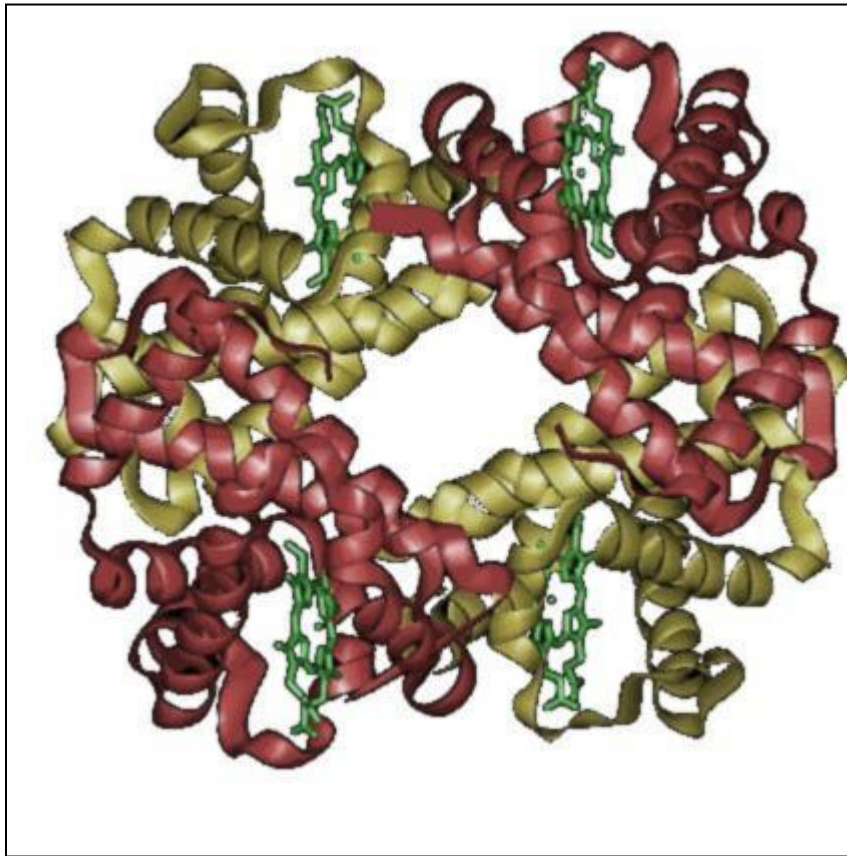


Figure 15.3. Hemoglobin is a special molecule that carries oxygen.

<http://commons.wikimedia.org/wiki/File:Hemoglobin.png>

## The Life Cycle of the Red Blood Cell

Red blood cells develop in the bone marrow. The process of blood cell formation is called hematopoiesis. The process of red blood cell formation is known as erythropoiesis. In erythropoiesis, immature red blood cells called erythroblasts differentiate from hemocytoblasts in the presence of the hormone erythropoietin. Erythropoietin is secreted by the kidneys and liver in response to low oxygen concentration in the blood. Erythroblasts still contain a nucleus and mitochondria and produce the hemoglobin. When they mature into erythrocytes, they shed the nucleus and mitochondria.

The red blood cells then circulate in the bloodstream for approximately 120 days. About 2.5 million red blood cells are produced each second to keep up with the number of cells being recycled. During their lifetime they slowly wear out from passing through small capillary membranes. Each cell can travel through the body as many as 75,000 times. After about 120 days they become worn enough to pass through capillary membranes in the spleen and liver. There they are broken down and phagocytized by macrophages (white blood cells) and the hemoglobin is recycled.

Hemoglobin is broken down in the liver and spleen into four globin molecules and one heme molecule. The heme molecule breaks down into iron and biliverdin. Some of the iron combines with a molecule of transferrin and is recycled in the bone marrow. The rest of the iron is combined with ferritin and stored in the liver. The biliverdin is converted to bilirubin (an orange pigment) and both bilirubin and biliverdin are secreted in the bile and end up in the digestive tract.

An indicator of the amount of red blood cells in the bloodstream is known as the red blood cell count. The red blood cell count is defined as the number of red blood cells in a cubic millimeter of blood.

Red blood cell count = number of RBCs in cubic millimeter of blood

- 4,600,000 – 6,200,000 in males
- 4,200,000 – 5,400,000 in females
- 4,500,000 – 5,100,000 in children

An increase in the red blood cell count is known as erythrocytosis or erythemia. This is caused by lung disease, poisoning, and dehydration. A temporary increase in red blood cell count occurs when people living at sea level visit high altitude environments.

A decrease in the red blood cell count is known as anemia. Anemia can be caused by a number of factors such as vitamin B12 deficiency, blood loss, and iron deficiency.

Certain substances are needed in order to make red blood cells. These include vitamin B12, folic acid and iron. Intrinsic factor is needed in order for vitamin B12 absorption to occur. Intrinsic factor is secreted by the stomach. Damage to the stomach lining can decrease the secretion of intrinsic factor and produce a vitamin B12 deficiency. Vitamin B12 and folic acid are needed in order to allow the hemocytoblast to fully develop into a mature red blood cell. If there is a deficiency of vitamin B12 from either a dietary problem or stomach lining problem a type of anemia called pernicious anemia can develop. The cells in pernicious anemia are usually larger (macrocytic). This is because the larger hemocytoblast has not differentiated fully into a smaller erythrocyte.

Iron is also needed for the production of red blood cells. Iron is needed for the production of hemoglobin. Iron deficiencies can also result in an anemia known as iron deficiency anemia. The cells in iron deficiency anemia are usually smaller and contain less hemoglobin.

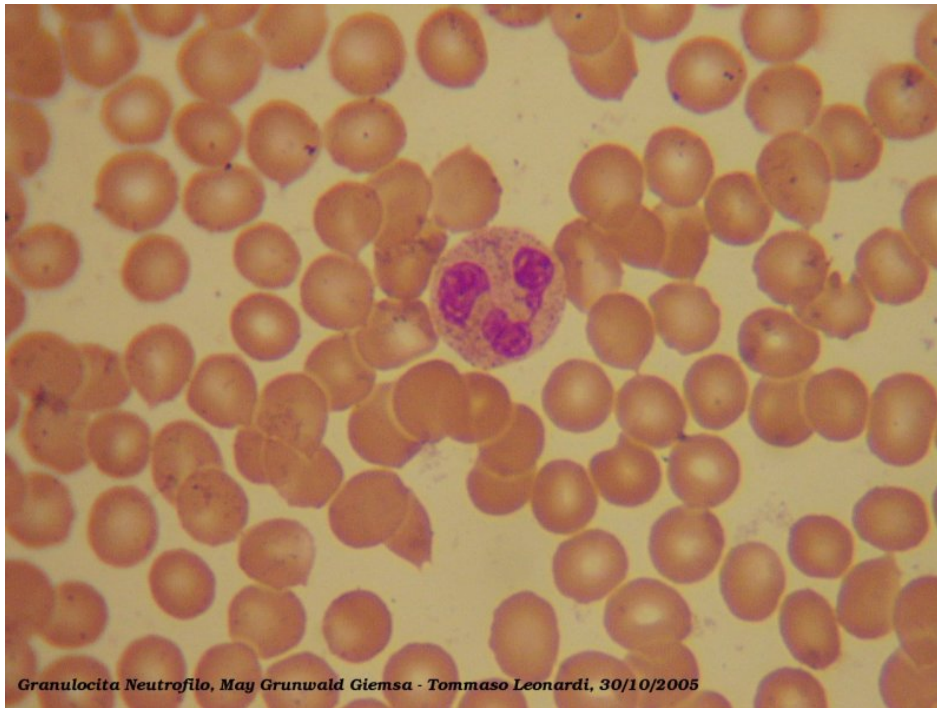
## **White Blood Cells**

White blood cells are called leukocytes. They are found in the blood but many also work outside of the circulatory system in organs and tissue. There are two categories of leukocytes. Granulocytes have a granular cytoplasm while agranulocytes do not.

### **Granulocytes**

Granulocytes tend to be significantly larger than red blood cells. There are three main types of granulocytes. These are the neutrophils, basophils and eosinophils. Granulocytes also have a significantly shorter lifespan (measured in hours) than red blood cells (120 days).

Neutrophils are larger than red blood cells and contain a segmented nucleus (fig. 15.4). They are the majority of leukocytes. Their function is primarily phagocytosis of bacteria and viruses. They are the first cells to arrive at an infection (fig. 15.5).



*Granulocita Neutrofilo, May Grunwald Giemsa - Tommaso Leonardi, 30/10/2005*

Figure 15.4. Neutrophil

<http://commons.wikimedia.org/wiki/File:Neutrophil.jpg>

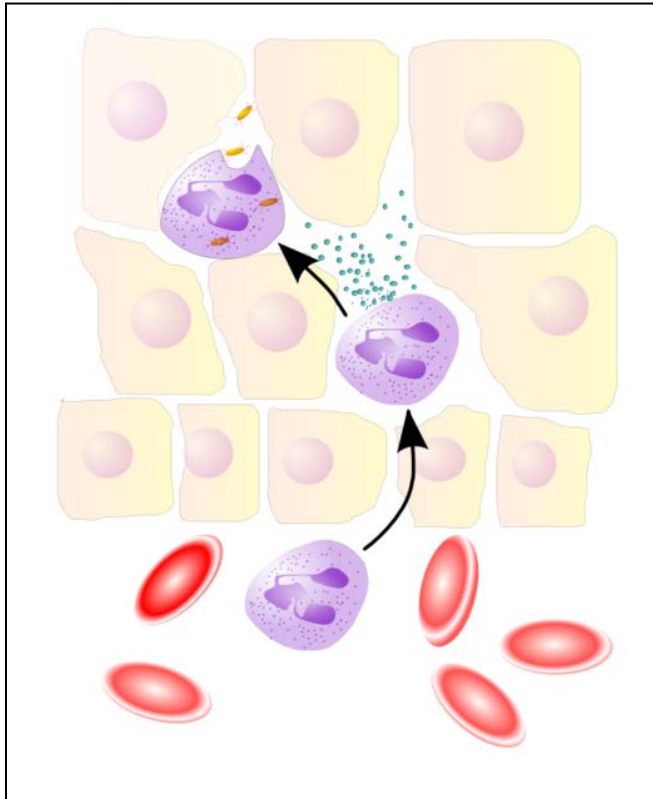


Figure 15.5. Neutrophils move from the blood into tissue and phagocytize bacteria.

<http://commons.wikimedia.org/wiki/File:NeutrophilerAktion.png>

Author: Uwe Thormann

## Eosinophils

Eosinophils have a bilobed nucleus and granular cytoplasm (fig. 15.6). They are relatively rare cells that only make up 1% to 3% of the leukocyte population. Their function is to moderate allergic reactions and defend against parasites.

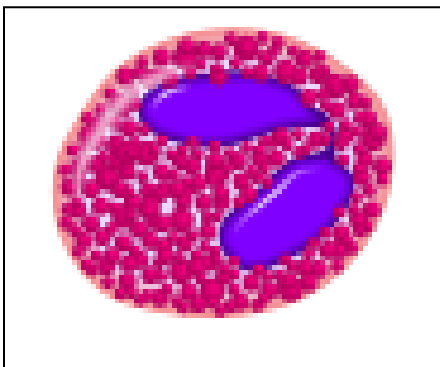


Figure 15.6. Eosinophil

[http://commons.wikimedia.org/wiki/File:Eosinophil\\_1.png](http://commons.wikimedia.org/wiki/File:Eosinophil_1.png)

## Basophils

Basophils have the same size and shape of nuclei as eosinophils (fig. 15.7). They have fewer and much larger granules. The granules release histamine (a vasodilator) and heparin (an anticoagulant). Basophils function in inflammation. Think of the cardinal signs of inflammation; heat, redness, pain and swelling. The basophils release heparin and histamine that function to bring more blood to the area. The additional blood produces the signs of inflammation. Basophils are also relatively rare cells and represent only 1% of the leukocyte population.

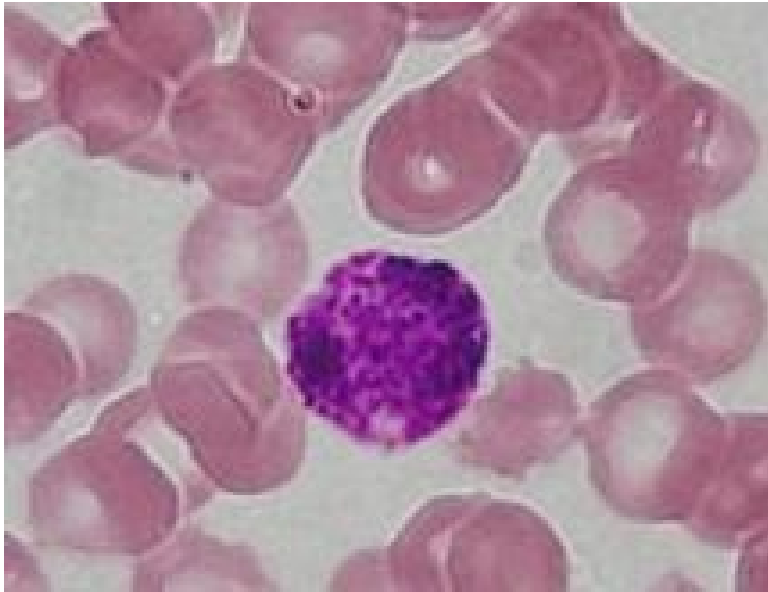


Figure 15.7. Basophil

<http://commons.wikimedia.org/wiki/File:Basophil.jpg>

## Agranular Leukocytes

There are two agranular leukocytes. These include monocytes and lymphocytes.

Monocytes are the largest blood cells (fig. 15.8). Their nuclei can be spherical, kidney-shaped, oval or lobed. Monocytes have a function very similar to neutrophils. Monocytes work to clean up debris and phagocytize bacteria. They constitute 3% to 9% of the leukocyte population.

Lymphocytes are about the same size as red blood cells (fig. 15.9). They constitute 25% to 30% of the leukocyte population. There are two main types of lymphocytes. These include T-lymphocytes and B-lymphocytes. Both function in immunity. T-lymphocytes attack pathogens and help activate B-lymphocytes. B-lymphocytes produce antibodies when activated that attack pathogens.

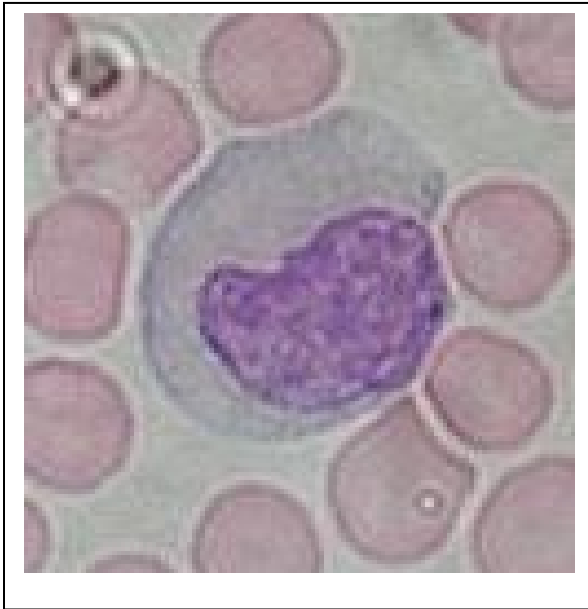


Figure 15.8. Monocyte

<http://commons.wikimedia.org/wiki/File:Monocyte.jpg>

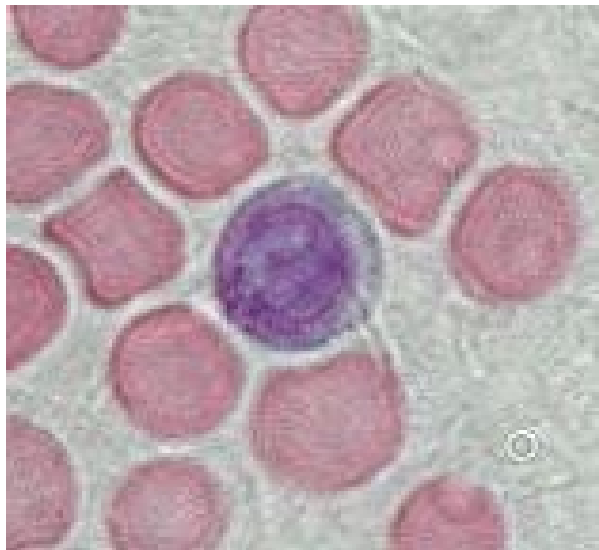

Figure 15.9. Lymphocyte

<http://commons.wikimedia.org/wiki/File:Lymphocyte.jpg>

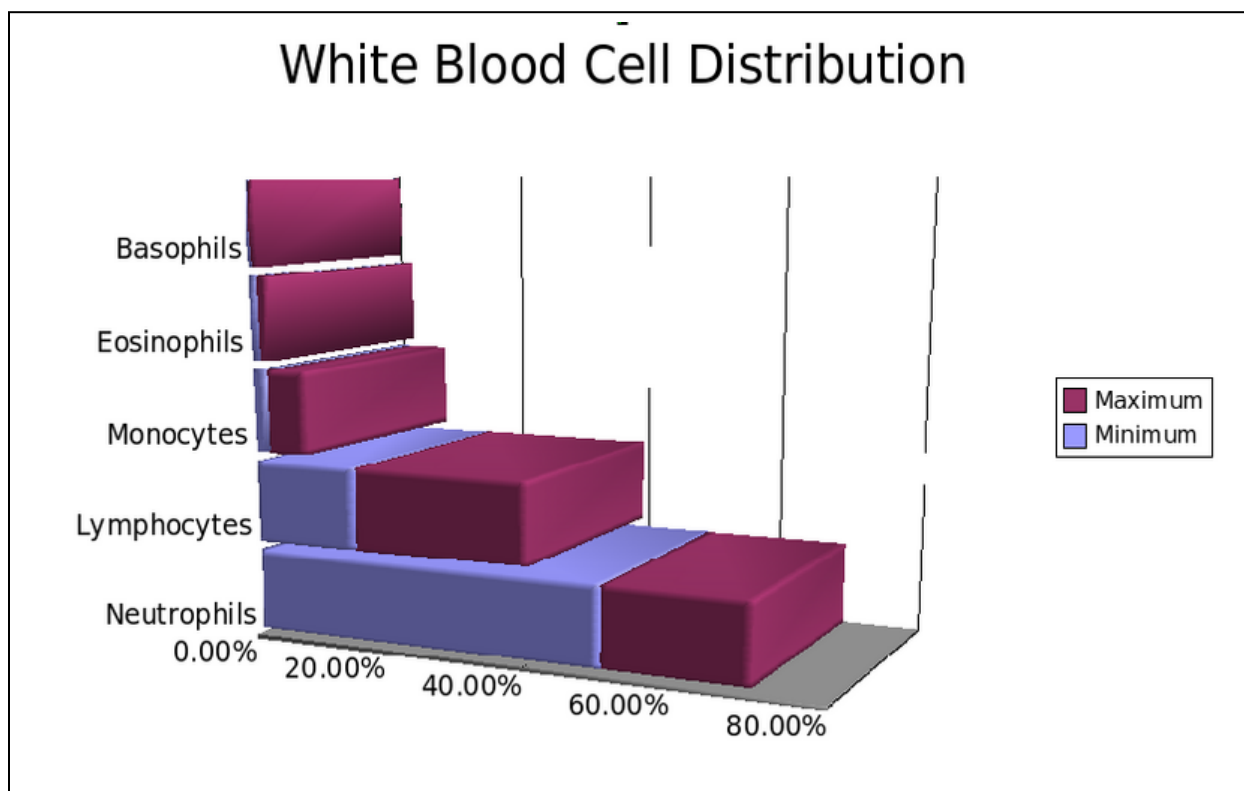


Figure 15.10. Distribution of WBCs

From:

[http://commons.wikimedia.org/wiki/File:White\\_blood\\_cell\\_distribution.png](http://commons.wikimedia.org/wiki/File:White_blood_cell_distribution.png) Author: Jim Thomas



White blood cells can move between capillary walls and enter the tissue. They do so by a process known as diapedesis. In diapedesis an appendage of the cell first moves to an area. This is followed by the remainder of the cell. The cells are self propelled by ameboid motion.

White blood cells are attracted to an infected area by substances secreted by damaged cells. This is known as chemotaxis. The white blood cells then lyse bacteria and form pus.

### **WBC Count**

The typical WBC count is about 5,000 to 10,000 cells per cubic millimeter. A high count is called leukocytosis and can be caused by infection, exercise, loss of body fluids and emotional stress. A low count is called leucopenia and can be caused by viruses such as influenza, measles, mumps, chicken pox and toxins such as lead poisoning.

A test that breaks out the relative percentages of WBCs is called a differential.

### **Platelets**

Platelets are cell fragments called thrombocytes (fig. 15.11). Hemocytoblasts (stem cells) differentiate into megakaryocytes that fragment into platelets. Platelets are about one half the size of red blood cells. There are about 130,000 to 360,000 platelets per cubic millimeter of blood.

Platelets help to stop bleeding by sticking together to form plugs and secreting the hormone serotonin which acts to vasoconstrict the vessels.

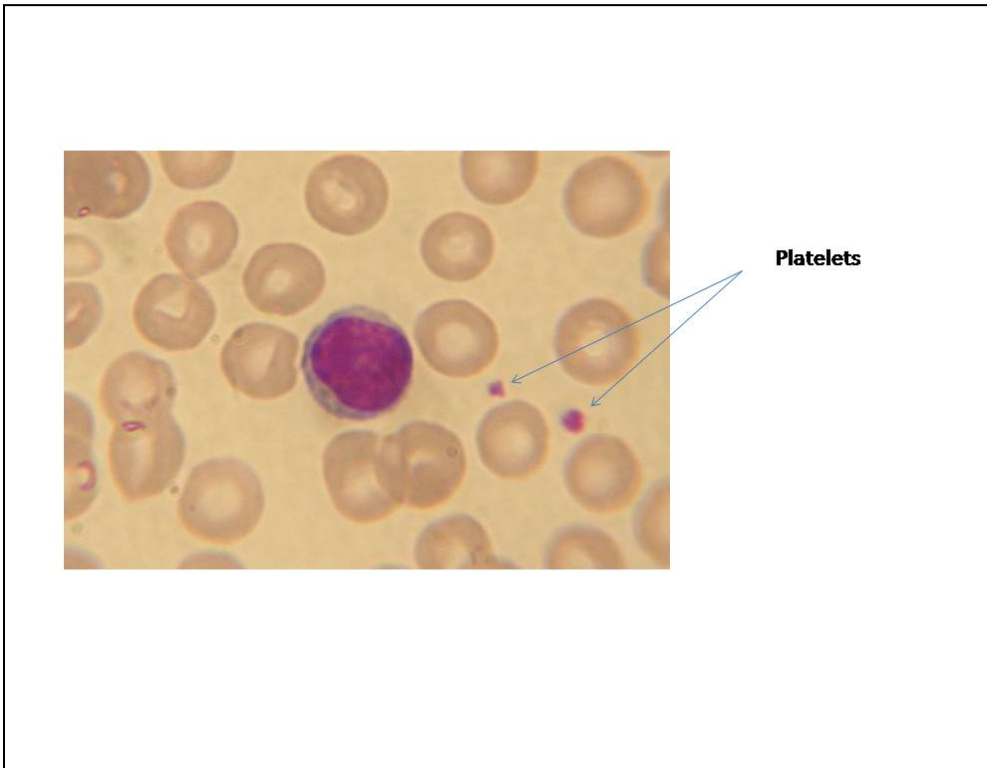


Figure 15.11. Platelets

<http://commons.wikimedia.org/wiki/File:Lymphocyte2.jpg>

Author: May-Gründwald Giemsa

## Blood Plasma

Plasma is the fluid portion of blood that carries the cells and platelets. Plasma is straw-colored and clear and contains water with a variety of substances. Plasma contains various proteins including fibrinogen, globulins and albumin. Plasma also contains dissolved gasses such as carbon dioxide and oxygen and nutrients such as carbohydrates, amino acids and lipids. Lipids are packaged in lipoproteins such as very low density lipoproteins (VLDL), low density lipoproteins (LDL), high density lipoproteins (HDL) and chylomicrons. Other constituents of plasma include electrolytes such as sodium, potassium, calcium, magnesium, chloride, sulfates, phosphates, and bicarbonate ions and nitrogenous substances such as uric acid, urea, creatine, and creatinine.

## Hemostasis

The blood system has some self-protection mechanisms built into it. These come into play during bleeding. The stopping of bleeding is called hemostasis. There are three basic mechanisms of hemostasis. These include blood vessel spasm, platelet plug formation and clotting.

Blood vessel spasm occurs in response to a damaged vessel. Blood vessels have a smooth muscle layer that constricts when the vessel is damaged. Platelets also release serotonin that facilitates constriction of the vessel. This action helps to stop the bleeding.

Platelets become sticky when they contact damaged blood vessels. They can stick together to form a plug. The platelet plugs help to plug small holes in vessels.

Clotting is the third mechanism of hemostasis (fig. 15.12). There are two pathways consisting of a cascade of reactions involving molecules called clotting factors (designated by Roman numerals). The two pathways are called the intrinsic and extrinsic pathways. Both pathways converge at a common point to form a fibrin clot.

The extrinsic pathway is triggered when blood leaves the damaged blood vessel. The clotting factor tissue thromboplastin (Factor III) is triggered to begin the cascade of reactions. Tissue thromboplastin activates factor VII which in turn activates factor X. Factor X combines with factor V and calcium ions to activate prothrombin activator. Prothrombin activator allows for the conversion of prothrombin (factor II) to thrombin. Thrombin in turn allows for the conversion of fibrinogen (factor I) to fibrin. Factor XIII stabilizes the fibrin clot. Fibrinogen is a soluble plasma protein while fibrin is insoluble.

The intrinsic pathway is triggered when blood contacts damaged blood vessel walls but does not leave the vessel. The first clotting factor to become activated in intrinsic clotting is called the Hageman factor (factor XII). This factor activates factor XI which activates factor IX. Factor IX combines with factor VIII to activate factor X. Factor X combines with factor V and calcium to activate prothrombin activator. At this point the pathway is the same as that for extrinsic clotting.

The intrinsic pathway can be triggered by atherosclerosis and stasis. Atherosclerotic plaquing can cause turbulent flow of blood in arteries that can trigger the intrinsic pathway. Also, lack of blood movement in circulation can trigger the intrinsic pathway. This is why it is recommended to walk around when taking long trips or sitting for long periods of time.

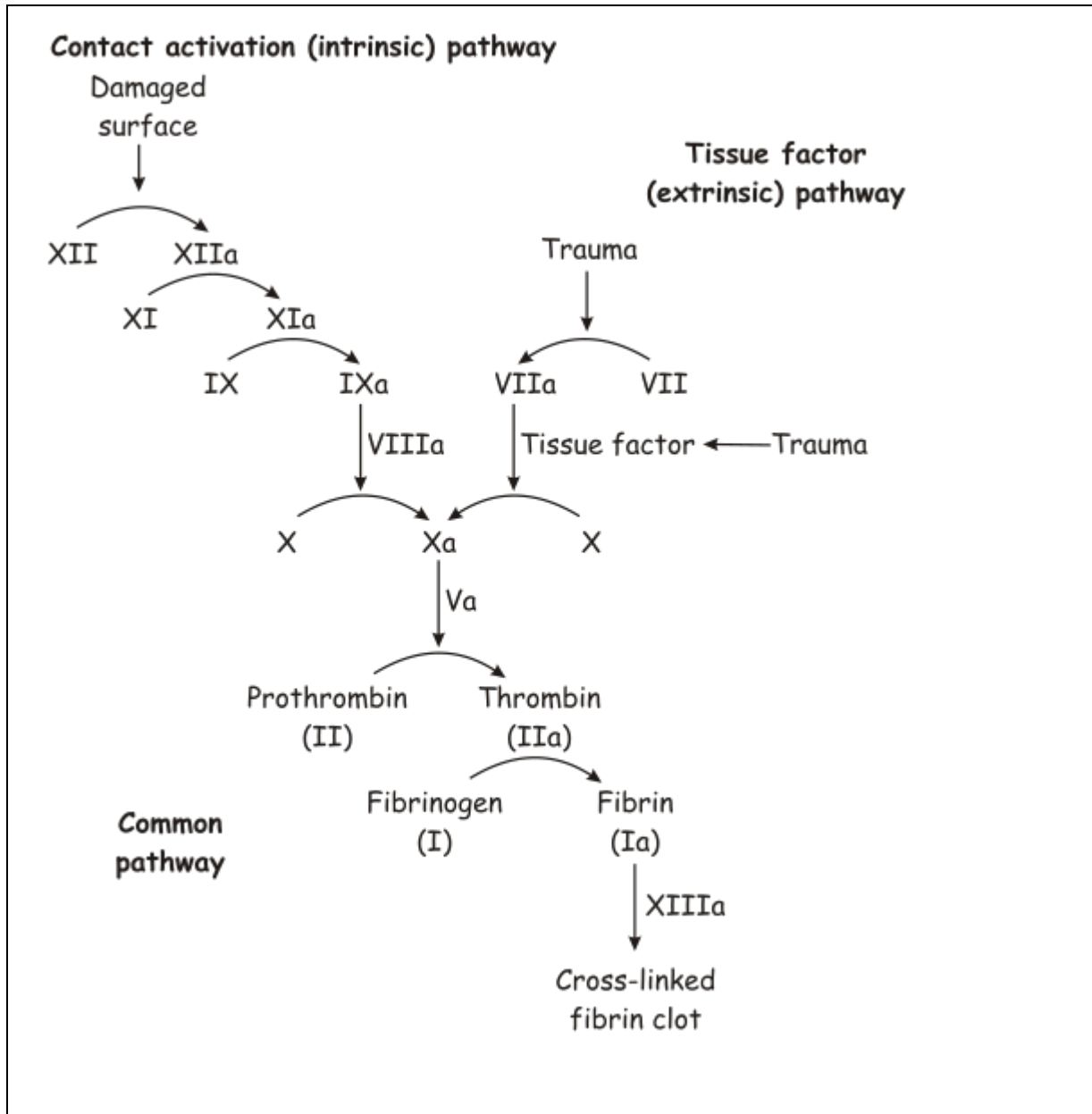


Figure 15.12. Clotting Cascade

[http://commons.wikimedia.org/wiki/File:Coagulation\\_simple.svg](http://commons.wikimedia.org/wiki/File:Coagulation_simple.svg)

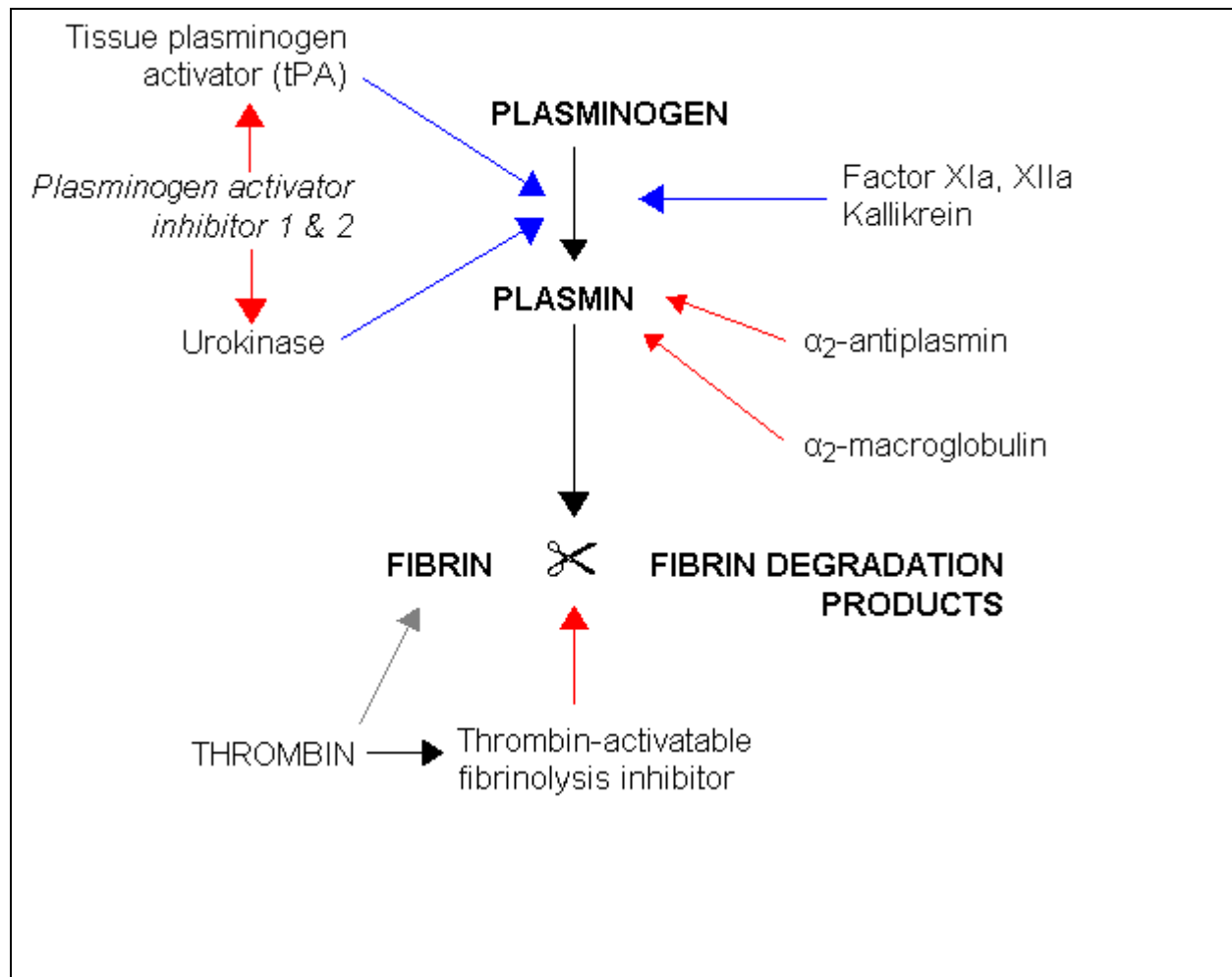


Figure 15.13. Fibrinolysis

<http://commons.wikimedia.org/wiki/File:Fibrinolysis.png>

### Fibrinolysis

Clots formation and dissolution are continuously occurring in the body. Blood contains a plasma protein called plasminogen that is inactive. A number of substances can activate plasminogen to form plasmin. Plasmin dissolves clots (fig. 15.13).

## Clotting terms

- Hematoma—clot resulting from blood leakage
- Thrombus—clot forming in vessel
- Embolus—thrombus broken loose in bloodstream.
- Embolism—clot lodged in blood vessel cutting off circulation.
- Infarction—clot forming in vessel to organ (heart, lung, brain).
- Atherosclerosis—accumulation of fatty deposits in arterial linings. Causes thrombosis.

## Blood Groups

Blood can be categorized or typed according to a set of antigens present on the surface of red blood cells (fig. 15.14). Blood typing can be used to determine compatibility in case a transfusion is needed. There are three antigens that can be used to determine compatibility. These are A, B, and Rh.

Type A blood contains antigen A on the surface of the red blood cells. Type B contains antigen B and type AB contains both antigens A and B. Type O blood contains neither antigen.

Type A blood also contains antibodies that are not compatible with antigen B. These are known as antibody anti-B. Likewise type B contains antibodies that are incompatible with type A. Mixing type A and B produces a reaction known as agglutination in which the blood coagulates.

Type AB blood contains no antibodies that will react with the type A or B antigens. Type O blood contains both antibody anti-A and antibody anti-B.

By just using the ABO system we can determine compatibility. Type A is compatible with itself and type O in case of an emergency. Even though type O contains antibodies that can cause agglutination the risk is less because of the decreased concentration of these. Type B is compatible with itself and type O in case of an emergency. Type AB is compatible with all of the blood types and type O is only compatible with itself.

The third antigen that can be used for typing is the Rh antigen. If the Rh antigen is present on the surface of the red blood cells the blood is Rh positive. If it is not the blood is Rh negative.

Anti-Rh antibodies typically do not appear in the blood. However they can develop in an Rh negative person who has been exposed to Rh positive blood.

Rh positive blood is compatible with either Rh positive or Rh negative blood. However Rh negative blood is only compatible with Rh negative.

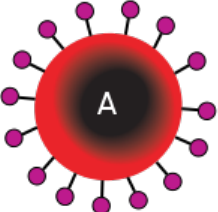
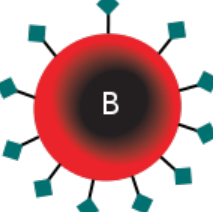
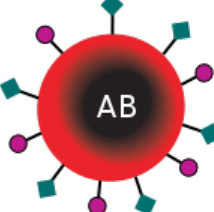

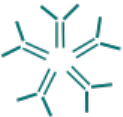

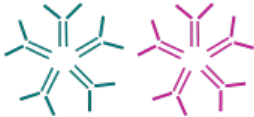




	Group A	Group B	Group AB	Group O
Red blood cell type				
Antibodies present	 Anti-B	 Anti-A	None	 Anti-A and Anti-B
Antigens present	A antigen 	B antigen 	A and B antigens  	None

Figure 15.14. Blood types.

[http://commons.wikimedia.org/wiki/File:ABO\\_blood\\_type.svg](http://commons.wikimedia.org/wiki/File:ABO_blood_type.svg)

## Blood Typing Compatibility

Type	A+	A-	B+	B-	AB+	AB-	O+	O-
A+	+	+	-	-	-	-	+	+
A-	-	+	-	-	-	-	-	+
B+	-	-	+	+	-	-	+	+
B-	-	-	-	+	-	-	-	+
AB+	+	+	+	+	+	+	+	+
AB-	-	+	-	+	-	+	-	+
O+	-	-	-	-	-	-	+	+
O-	-	-	-	-	-	-	-	+



## Chapter 15 Review Questions

1. All blood cells come from one cell called:
  - a. Hemocytoblast
  - b. Erythroblast
  - c. Reticulocyte
  - d. Osteoblast
2. Which blood cell is characterized by the biconcave disc shape:
  - a. Neutrophil
  - b. Red blood cell
  - c. Platelet
  - d. Monocyte
3. Which blood cell contains a segmented nucleus:
  - a. Neutrophil
  - b. Basophil
  - c. Eosinophil
  - d. Lymphocyte
4. Which blood cell would be prevalent in fighting off a parasitic infection:
  - a. Basophil
  - b. Eosinophil
  - c. Neutrophil
  - d. Monocyte
5. Which blood cell helps to moderate inflammation:
  - a. Basophil
  - b. Neutrophil
  - c. Eosinophil
  - d. Monocyte
6. The heme portion of hemoglobin is broken down into:
  - a. Iron and biliverdin
  - b. Iron and plasma proteins
  - c. Potassium and bilirubin
  - d. Biliverdin and bilirubin
7. Red blood cells live for about \_\_\_\_ days:
  - a. 90
  - b. 120
  - c. 180
  - d. 200

8. Red blood cells are recycled in:
- a. Liver and pancreas
  - b. Spleen and adrenal gland
  - c. Liver and spleen
  - d. Ileum and thymus
9. A low RBC count is indicative of:
- a. Erythrocytosis
  - b. Anemia
  - c. Infection
  - d. Parasites
10. Which of the following is not a method of hemostasis:
- a. Clotting
  - b. Platelet plug formation
  - c. Vasodilation
  - d. Vasoconstriction
11. Which of the following blood types is not compatible with A+ blood:
- a. A-
  - b. O+
  - c. B-
  - d. O-
12. Which blood type does not have either anti-A nor anti-B antibodies:
- a. A
  - b. B
  - c. AB
  - d. O

# Chapter 16

## The Lymphatic System

## The Lymphatic System

### The Big Picture

We discussed capillary permeability in the cardiovascular chapter. In essence the capillaries are leaky. In fact there is a net loss of fluid of about 30 L/day from the capillaries to the interstitium. The fluid must be brought back into circulation in order to maintain fluid balance. This is one important job of the lymphatic system. That is to return the interstitial fluid back into circulation.

The lymphatic system is a vascular system that contains capillaries, vessels and lymph nodes (fig. 16.1). The lymph capillaries pick up interstitial fluid lost by the circulatory system. The fluid known as lymph moves through the system and is returned to venous circulation.

The lymphatic system also transports dietary fats from the gastrointestinal system. Small lymphatic structures called lacteals are located in the small intestine in structures called villi. Fats are broken down and packaged as structures known as chylomicrons. The fats then move through the system to the venous circulation.

A good portion of the immune system resides in the lymphatic system as well. Lymph nodes containing white blood cells work to destroy pathogens.

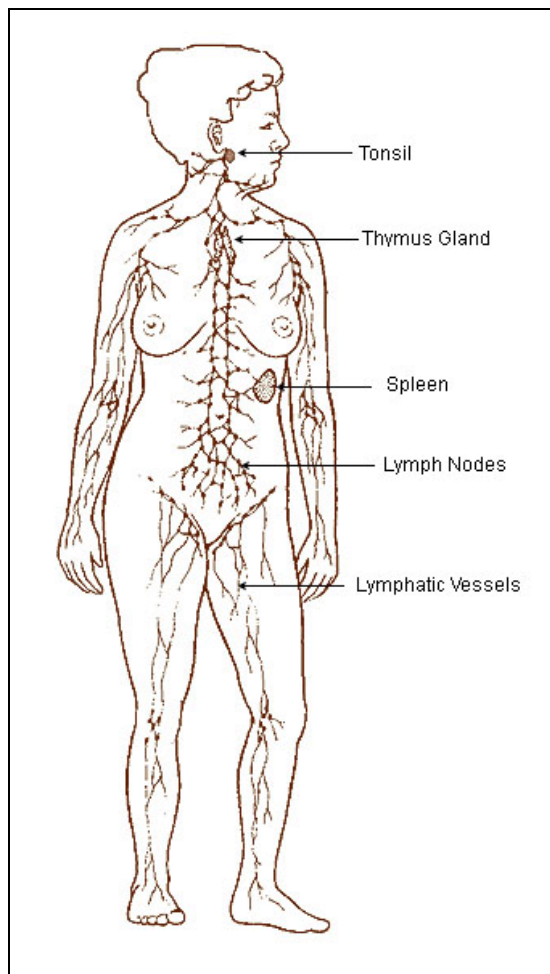


Figure 16.1. Lymphatic system

[http://commons.wikimedia.org/wiki/File:Illu\\_lymphatic\\_system.jpg](http://commons.wikimedia.org/wiki/File:Illu_lymphatic_system.jpg)

## Lymphatic Capillaries

Lymphatic capillaries are distributed throughout the interstitium. Lymphatic capillaries are not found in the central nervous system and bone marrow. They are also not resident in tissues without blood flow such as the epidermis or cartilage. They are designed to allow one way fluid flow into the capillary (fig. 16.2).

Lymphatic capillaries consist of overlapping simple squamous epithelium. They also form one way valves. This arrangement allows for increased permeability and fluid movement toward the venous circulation.

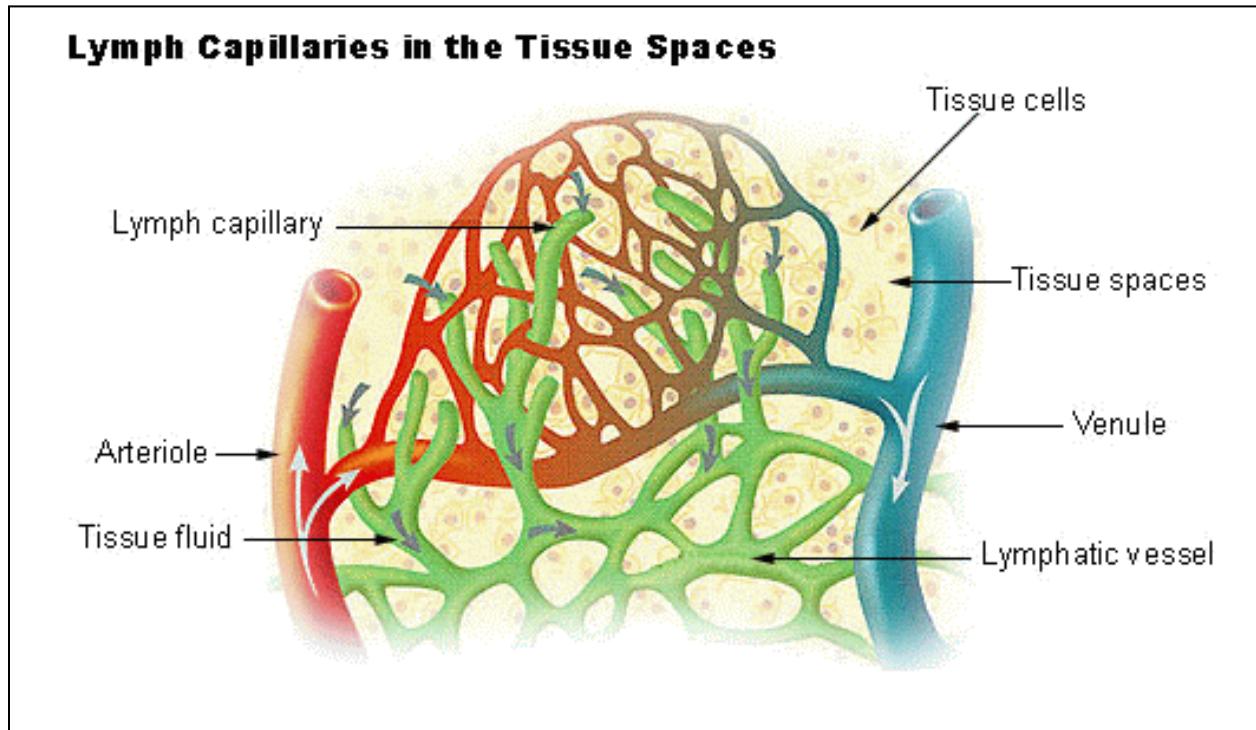


Figure 16.2. Lymphatic capillaries

[http://commons.wikimedia.org/wiki/File:Illu\\_lymph\\_capillary.png](http://commons.wikimedia.org/wiki/File:Illu_lymph_capillary.png)

## Lymphatic Vessels

The lymphatic capillaries form larger structures called lymphatic vessels. The vessels have a similar structure to veins and contain three layers. The three layers consist of an inner endothelium, a middle smooth muscle layer and an outer layer of thin fibrous connective tissue.

Lymphatic vessels also contain valves to allow the one way flow of blood. Smooth muscle contraction moves blood from one area separated by a valve to another. Some cells in the lymph vessel walls are capable of generating action potentials that cause the smooth muscle to contract.

Skeletal muscle contraction also moves lymph fluid by means of generating pressure on the outside of the vessels causing them to constrict. The valves only allow one way flow so lymph is moved toward the venous circulation.

Lymph fluid also moves into vessels in the thoracic cavity as a result of dilation of lymph vessels resulting in decreases in thoracic cavity pressure. The thoracic cavity expands during inspiration causing a decrease in thoracic pressure. The vessels react by dilating and creating an area of lower pressure. Lymph fluid then moves toward the area of lower pressure.

### **Lymph Nodes**

Lymph nodes are located throughout the lymphatic system. The lymphatic vessels connect with the nodes and fluid moves through them. There are numbers of nodes connected to a vessel so that lymph fluid moves from one node to another. Lymph nodes are small oval structures and are generally not felt during examinations unless enlarged or calcified (fig. 16.3).

Lymph nodes act as filters and work to remove pathogens such as bacteria and viruses. Although diffusely located throughout the body, lymph nodes tend to conglomerate in certain areas. These include the cervical, axillary, inguinal, popliteal and mammary glands (fig. 16.4).

Lymph nodes consist of a dense connective tissue covering and a trabeculated internal structure. The nodes contain reticular connective tissue that forms an interconnected web like structure. Vessels entering the nodes are known as afferent vessels. Likewise vessels exiting the nodes are known as efferent vessels.

Lymph nodes consist of an outer cortex and an inner medulla. The cortex contains open areas called sinuses. The medulla contains medullary cords which are branching structures of lymphatic tissue. Open areas called medullary sinuses are also present.

Lymph nodes contain white blood cells called macrophages and lymphocytes. Macrophages are located in the sinuses and phagocytize bacteria and debris. Lymphocytes are located in germinal centers and when activated can move into the bloodstream.

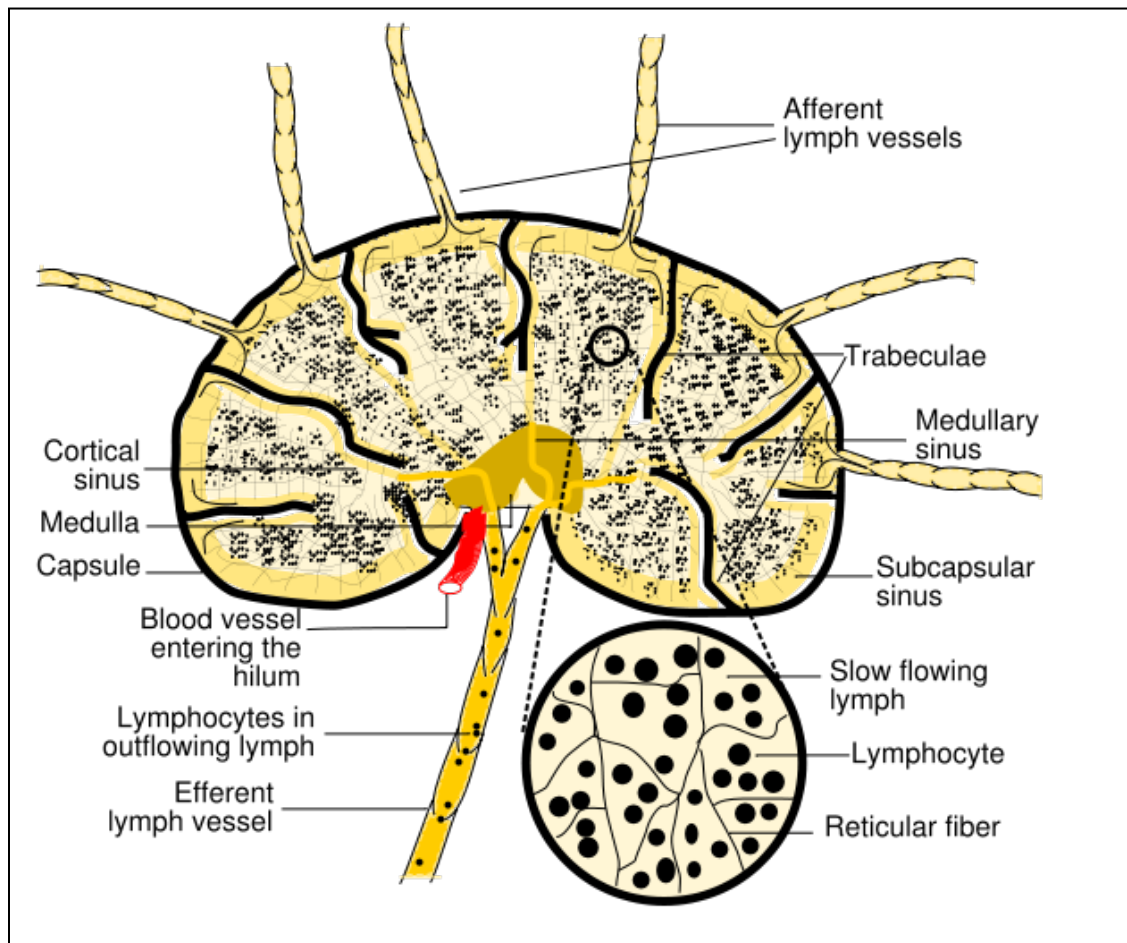


Figure 16.3. Lymph node

[http://commons.wikimedia.org/wiki/File:Schematic\\_of\\_lymph\\_node\\_showing\\_lymph\\_sinuses.svg](http://commons.wikimedia.org/wiki/File:Schematic_of_lymph_node_showing_lymph_sinuses.svg)

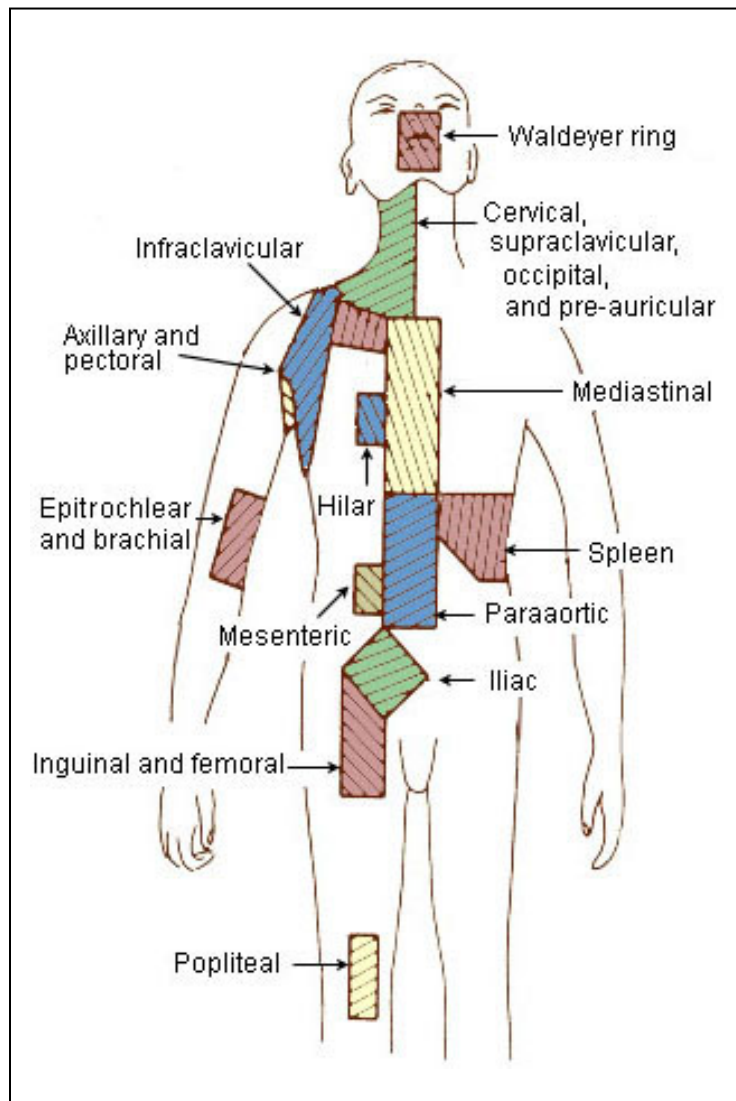


Figure 16.4. Lymph node locations

[http://commons.wikimedia.org/wiki/File:Lymph\\_node\\_regions.jpg](http://commons.wikimedia.org/wiki/File:Lymph_node_regions.jpg)



The lymphatic vessels eventually form larger structures known as lymphatic trunks. The lymphatic trunks drain specific portions of the body. The subclavian trunks drain the upper extremities. The jugular trunks drain the head and neck. The bronchomediastinal trunks drain the thoracic area. The intestinal trunks drain the abdomen. The lumbar trunks drain the lower extremities and pelvic area.

The lymphatic trunks connect with larger structures called lymphatic ducts which connect with the venous system at the subclavian veins. There are two ducts including the thoracic duct and right lymphatic duct. The jugular, subclavian and bronchomediastinal trunks connect to either the right internal jugular, right subclavian, or right brachiocephalic trunk. In some people the three trunks merge to form the right lymphatic duct.

The remaining trunks connect with the thoracic duct. The drainage of lymph fluid is therefore asymmetrical with respect to the arrangement of the right lymphatic and thoracic duct. In other words the right lymphatic duct drains the right side of the head, neck and trunk while the thoracic duct drains the left side of the head, neck and trunk as well as both lower extremities.

In some cases the intestinal and lumbar trunks merge to form a sac like structure called the cisterna chili.

### **Lymphatic Organs**

Two organs are associated with the lymphatic system. These are the spleen and the thymus. The organs contain lymphatic tissue consisting primarily of white blood cells known as macrophages and lymphocytes as well as some other types of cells. There are two general types of lymphocytes. These are the T and B lymphocytes. Both are produced in the bone marrow and carried to the lymphatic system. Activation of the immune system causes these cells to divide and attack pathogens.

Lymphatic tissue also contains reticular cells that produce reticular fibers. White blood cells connect with these fibers so that fluid moving through the tissue is exposed to the cells. The white blood cells can then destroy bacteria and debris.

Lymphatic tissue resides throughout the lymphatic system. When it is not located in a lymph node or organ such as in the mucous membranes of the digestive, urinary, respiratory and reproductive systems it is known as Mucosa associated lymphoid tissue (MALT). The tonsils are another example of MALT.

The spleen is located in the left upper quadrant of the abdominal area generally close to the diaphragm and is about as large as an adult fist (fig. 16.5). It consists of an outer connective tissue capsule. The inner portion has a trabeculated structure containing areas of red and white pulp. The spleen also contains venous sinuses.

White pulp consists of lymphatic tissue associated with arteries within lymphatic organs. Red pulp contains both white and red blood cells and is associated with veins.

The splenic artery and vein enter and exit the spleen at the hilum. Blood flows into the spleen and through the trabeculated network. The cells in the spleen work to destroy pathogens. Lymphocytes in the spleen can react to pathogens and trigger the immune system. The spleen also acts as a blood reservoir.

## Spleen

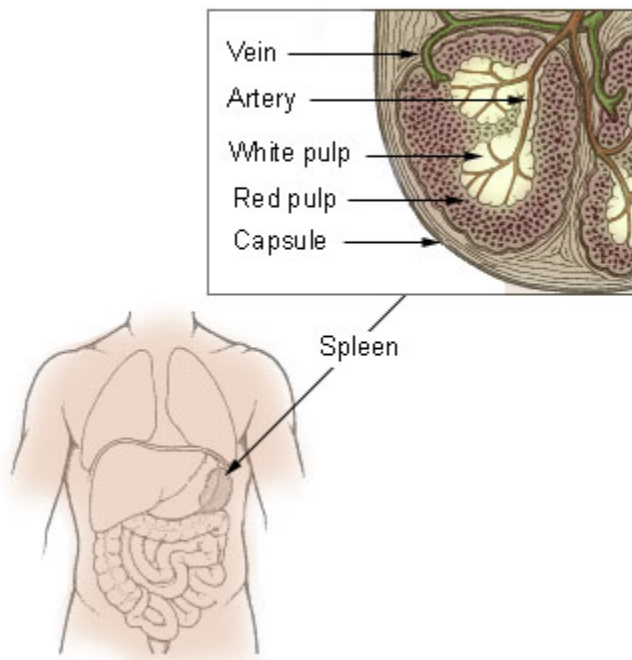


Figure 16.5. Spleen

[http://commons.wikimedia.org/wiki/File:Illu\\_spleen.jpg](http://commons.wikimedia.org/wiki/File:Illu_spleen.jpg)

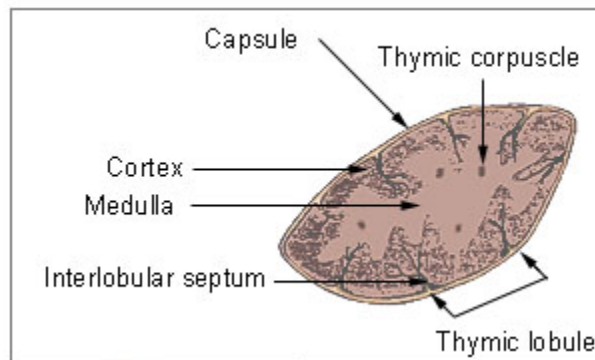


Figure 16.6. Thymus

[http://commons.wikimedia.org/wiki/File:Illu\\_thymus.jpg](http://commons.wikimedia.org/wiki/File:Illu_thymus.jpg)

## Thymus

The thymus is a gland located just deep to the sternum in the superior portion of the mediastinum(fig. 16.6). Early in life the thymus is larger and decreases in size with age although it continues to produce white blood cells.

The thymus has two lobes each surrounded by a connective tissue capsule. It contains an outer cortex and inner medulla. The internal region of the thymus is trabeculated and filled with lymphocytes. The thymus produces large numbers of T-lymphocytes that can travel to the blood.

## Chapter 16 Review Questions

1. Which of the following is not a function of the lymphatic system:
  - a. Transports dietary fats
  - b. Transports interstitial fluid
  - c. Contains white blood cells that function in immunity
  - d. Balances acids and bases
  
2. Lymphatic capillaries contain which type of tissue:
  - a. Cuboidal epithelium
  - b. Reticular connective
  - c. Simple squamous epithelium
  - d. Simple columnar epithelium
  
3. Which of the following is not a common location for lymph nodes:
  - a. Axilla
  - b. Cervical
  - c. Pectoral
  - d. Crural
  
4. Which lymphatic duct drains the right leg:
  - a. Thoracic
  - b. Right lymphatic
  - c. Left lymphatic
  - d. Cervical
  
5. The lymphatic system connects with the circulatory system at:
  - a. Carotid arteries
  - b. Jugular veins
  - c. Subclavian veins
  - d. Femoral arteries
  
6. Which best describes MALT lymphoid tissue:
  - a. Lymphatic tissue residing in mucous membranes of organs
  - b. Lymphatic tissue in lymph nodes
  - c. Located in the axillary region
  - d. Pre-cancerous tissue found throughout the lymphatic system

7. Which 2 organs are associated with the lymphatic system:
- a. Stomach and spleen
  - b. Thymus and spleen
  - c. Liver and spleen
  - d. Pancreas and liver

# Chapter 17

## Immunity

## Immunity

Our immune systems offer us protection against a world full of pathogens. Our immune systems work by providing two types of immunity. In non-specific immunity our bodies present the same kinds of defense systems regardless of the type of pathogens. Non-specific immunity works much like a fence around your property. The fence does not differentiate between friend or foe. It keeps everyone out. The other type of immunity is known as specific immunity (defense). Specific defense produces an attack against a specific pathogen. This is much like having an attendant at the gate of the fence around your house. The attendant can identify potential foes and keep them out.

Before birth the body inventories all of the cells and tissues of the body and classifies them as “self” cells. The presentation of non-self cells can then trigger the immune system.

### Non-Specific Defense

Non-specific defense (innate immunity) consists of mechanisms that either keep pathogens out or destroy them regardless of their type. Non-specific defense includes mechanical barriers, chemical substances, cells and inflammation.

Mechanical barriers include the skin and mucous membranes. Besides presenting a physical barrier that stops pathogens they also work to remove substances from the surface of membranes. Examples include the movement of mucous moving substances toward the digestive tract and tears washing substances from the eyes.

Chemical substances work to destroy pathogens. These include enzymes, cytokines, and the complement system. For example, mucous from the respiratory tract moves toward the pharynx and esophagus where it is swallowed. Upon reaching the digestive tract pathogens are destroyed by powerful digestive enzymes.

Cytokines are a series of protein substances secreted by cells that work to destroy pathogens. Interferons are cytokines that bind to cells causing them to produce substances that inhibit viral replication. One type of interferon can affect many types of viruses. Interferons can also activate other immune cells such as macrophages and natural killer cells.

Some cytokines produce fever. Interleukin 1 (endogenous pyrogen) is a cytokine that acts as a pyrogen (raises body temperature). This cytokine is released in response to toxins or pathogens and causes an increase in body temperature.

The complement system is a series of about 20 plasma proteins (fig. 17.1). They include proteins that are named C1-C9 and factors B, D, P. They act much like the clotting cascade (see blood chapter) in that activation of the first complement protein causes the others to activate. There are two pathways in which to activate the complement system.

The alternative pathway is activated by the presentation of a pathogen to the body. The C3 protein is normally inactivated by the body's cells, however presentation of a non-self cell can cause it to remain active triggering a response.

Complement system responses include inflammation, phagocytosis from white blood cells attracted to the area, and attacking non-self cells.

Inflammation is produced by facilitating the release of histamine from white blood cells called mast cells. Histamine promotes local vasodilation increasing capillary permeability and bringing more blood to the area.

Neutrophils and macrophages are attracted to activated complement proteins for phagocytosis of pathogens. Certain antibodies (we will cover antibodies later) called opsonins work with complement proteins to facilitate phagocytosis. This process is called opsonization.

Some complement proteins (C5-C9) bind to cell membranes to form a membrane attack complex (MAC) that drill holes in cells allowing substances to rush in and burst the cell.

The classical pathway is part of specific defense which will be covered later in this chapter.

Inflammation is characterized by swelling, redness, heat and pain (tumor, rubor, calor, dolor). Inflammation is produced by tissue destruction from trauma, cuts, temperature and chemicals. Inflammation causes an increased blood flow to the damaged area. Blood brings substances for repair and the stasis of blood in the area prevents further spread of pathogens.

Inflammation is primarily caused by the release of histamine and heparin from mast cells (similar to basophils). Histamine promotes local vasodilation and capillary permeability while heparin inhibits clotting. Phagocytes are also attracted to the area and remove debris. Neutrophils release substances that activate fibroblasts to begin to repair the area. Substances released by cells stimulate pain receptors in the tissue causing the sensation of pain.



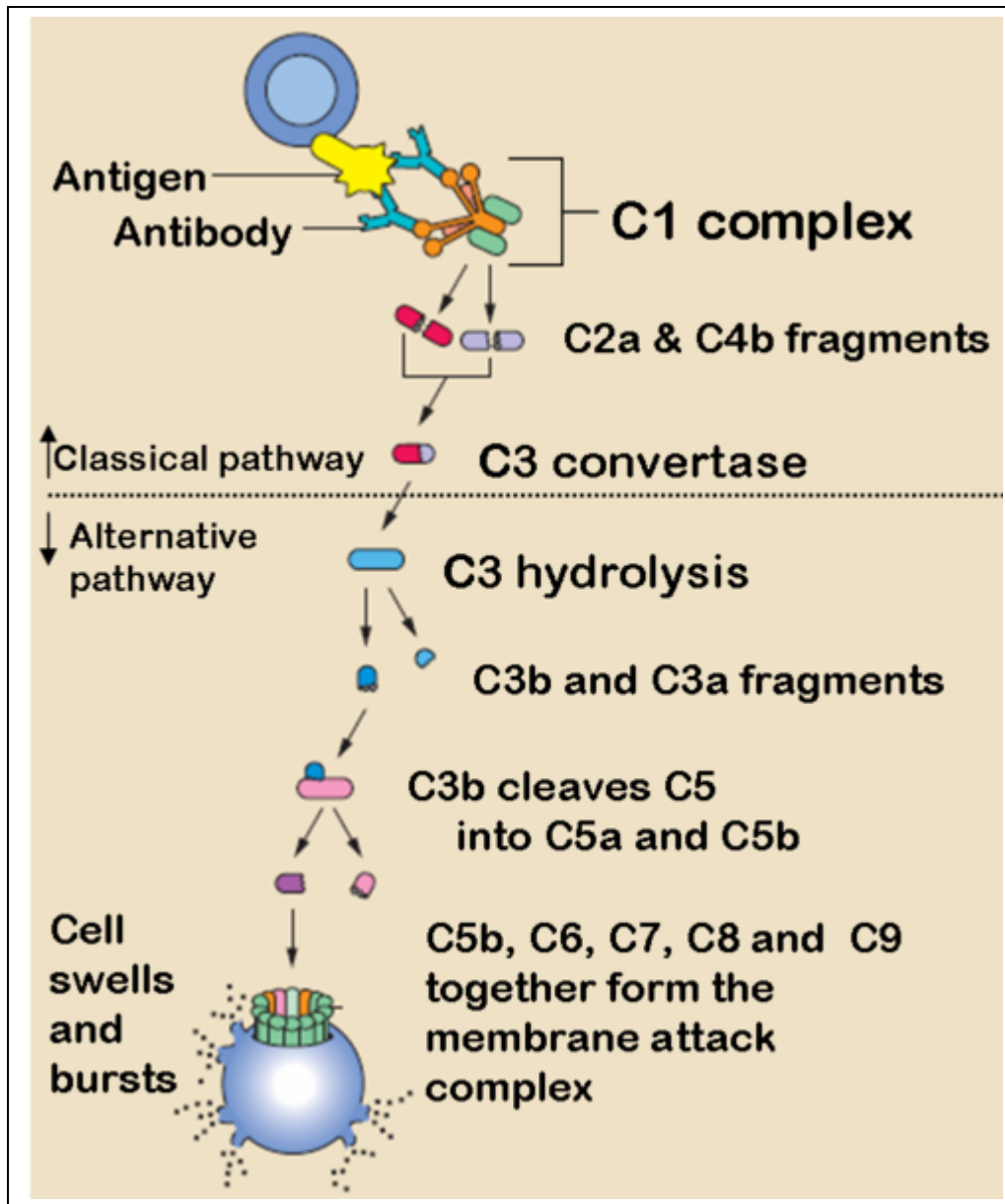


Figure 17.1. Complement System

[http://commons.wikimedia.org/wiki/File:Complement\\_pathway.png](http://commons.wikimedia.org/wiki/File:Complement_pathway.png)

## Specific Defense

Specific defense (sometimes called adaptive immunity) recognizes and coordinates attacks against specific pathogens. The system can also remember pathogens and produce a powerful response the next time a pathogen enters the body.

There are two types of specific defense. These include cell-mediated immunity and antibody-mediated immunity. Cell-mediated immunity occurs when T-lymphocytes (T-cells) become activated by exposure to pathogens. Activated T-cells then attack pathogens directly.

T-cells become activated when exposed to antigens on pathogens. T-cells react with portions of antigens called antigenic determinants (epitopes). T-cells contain antigen receptors on their surface that combine with antigenic determinants on pathogens. The antigen receptors are polypeptide chains that contain variable and constant regions. The variable region binds to the antigenic determinant. This is known as direct activation of T-cells.

## Major Histocompatibility Complexes

Specific glycoproteins can activate T-cells. These glycoproteins are called major histocompatibility complex molecules (MHC molecules). MHC molecules reside on cell membranes and contain a variable region. The variable region is the portion of the molecule that allows for binding to antigens.

MHC class I molecules display antigens on the surface of cells. The antigens are produced inside cells. One example is a cell infected with a virus. The virus replicates inside the cell producing proteins. These proteins combine with MHC class I molecules that move to the outer cell membrane for display. Once displayed on the surface of the cell the immune system can attack and destroy the cell.

MHC class II molecules are found on cells that present antigens. Antigens enter cells via endocytosis and combine with MHC class II molecules in vesicles. The antigen-MHC complex combination is then transported to the cell membrane and displayed on the surface. The response to MHC class II complexes differs from MHC class I in that the MHC class II presenting cells are not directly attacked. The MHC II complex acts more like a signal to other immune system cells to mobilize against the antigen.

## Types of T-cells

Types of T-cells include cytotoxic, helper, and suppressor cells. These cells differ in the presence of certain proteins known as cluster of differentiation (CD) markers. Cytotoxic T-cells contain the CD8 protein in their cell membranes. Cytotoxic T-cells respond to MHC class I molecules. Helper T-cells have CD4 markers and respond to MHC class II molecules.

T-cell activation typically requires costimulation in order to fully activate the cell. Costimulation involves a secondary binding to an antigen. Costimulation helps to ensure that the appropriate cell is attacked (fig. 17.3).

Activated cytotoxic T-cells destroy pathogenic cells by either phagocytosis, release of a substance that drills holes in the infected cell called perforin, secreting a substance that is toxic to the cell called a lymphotoxin, or activating genes in the infected cell that tell it to destroy itself. The latter is known as apoptosis.

Suppressor T-cells also develop from CD8 T-cells. Suppressor T-cells secrete substances known as suppression factors that suppress the action of T-cells and B-cells. These cells require a longer period of time for activation and help to protect against over-activation of the immune system.

Helper T-cells contain the CD4 protein. Helper T-cells facilitate rapid mitosis of other T-cells, cause chemotaxis of macrophages to the infected area, help to activate B-cells, and stimulate natural killer cells.

## **B-cells**

The other major type of lymphocyte is the B-cell (B for bursa of fabricus of the chicken after where they were discovered). There are millions of B-cells in the body and each contains a specific set of antibodies. Some antibodies are present on the surface of the B-cell. Antigen containing pathogens bind to antibodies causing sensitization of the B-cells. Antigens are then displayed on MHC class II proteins on the surface of the B-cells. Helper T-cells complete the activation of B-cells by binding to the MHC class II proteins and secreting cytokines that stimulate the B-cells. Activated B-cells undergo rapid mitosis with some of the cells remaining immature memory cells. Activated B-cells produce and secrete antibodies (fig. 17.4).

Antibodies consist of a pair of polypeptide chains called light chains connected to another pair of polypeptide chains called heavy chains. The chains are connected by disulfide bonds and contain both constant and variable segments. The base of the antibodies is formed by the constant segments of the heavy chains that help to identify the antibody. This region can also activate the complement system. The other end of the antibody contains the variable region. The antigen binding sites are located on this variable region. These sites can connect with antigens on pathogens to form antibody-antigen complexes.

Haptens are incomplete antigens and do not activate B-cells unless they combine with carrier molecules that act as complete antigens.

A number of different effects result from antibody-antigen complexes. Antibodies can bind to cellular receptors and neutralize cells so they cannot enter other cells. Antibodies can cause agglutination or clumping of cells that attract phagocytes (opsonization). Antibodies can produce inflammation by stimulating basophils and activate the complement system.

The activation of the complement system by antibody-antigen complexes is known as the classical pathway.

There are a number of different types of antibodies (fig. 17.2). Antibodies are also known as immunoglobulins and can be organized into five categories. These include IgE (immunoglobulin E), IgG, IgM, IgD, and IgA. IgG is the largest category and accounts for 80% of all antibodies. IgG antibodies attack viruses and bacteria. IgE antibodies function in allergic reactions. They facilitate the release of histamine and heparin from basophils. IgD antibodies bind to antigens on the surface of B-cells and help in activation of B-cells. IgM antibodies work with IgG antibodies to form immune complexes. IgM antibodies are also resident in plasma as anti-A and anti-B antibodies. IgA is found in secretions such as tears, mucous and saliva and attack pathogens.

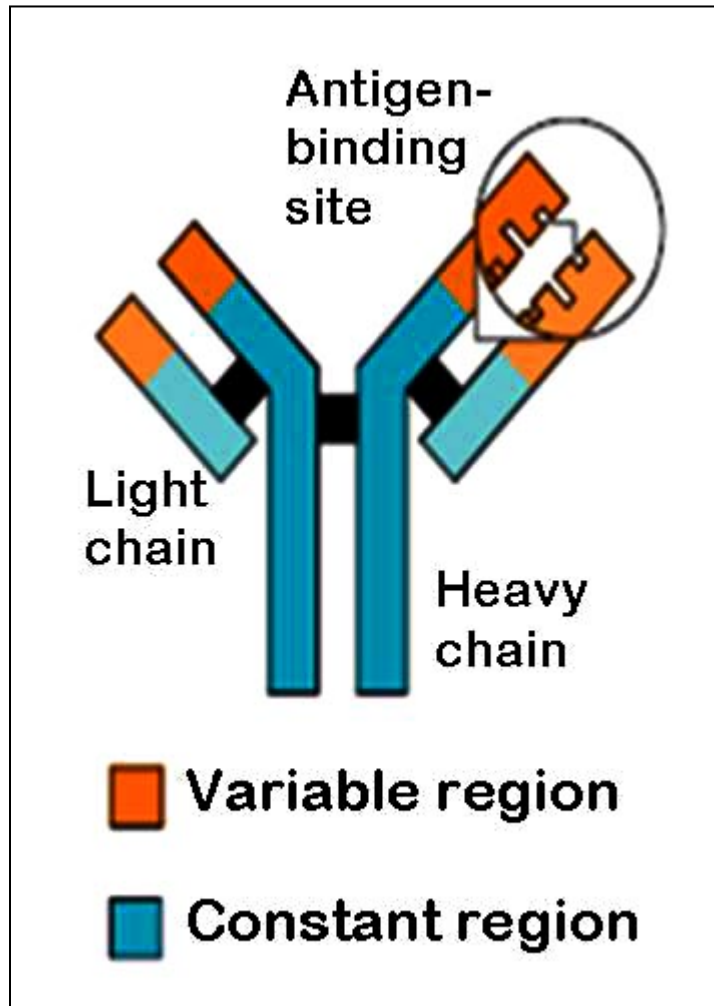


Figure 17.2. Antibody structure

<http://commons.wikimedia.org/wiki/File:Antibody.jpg>

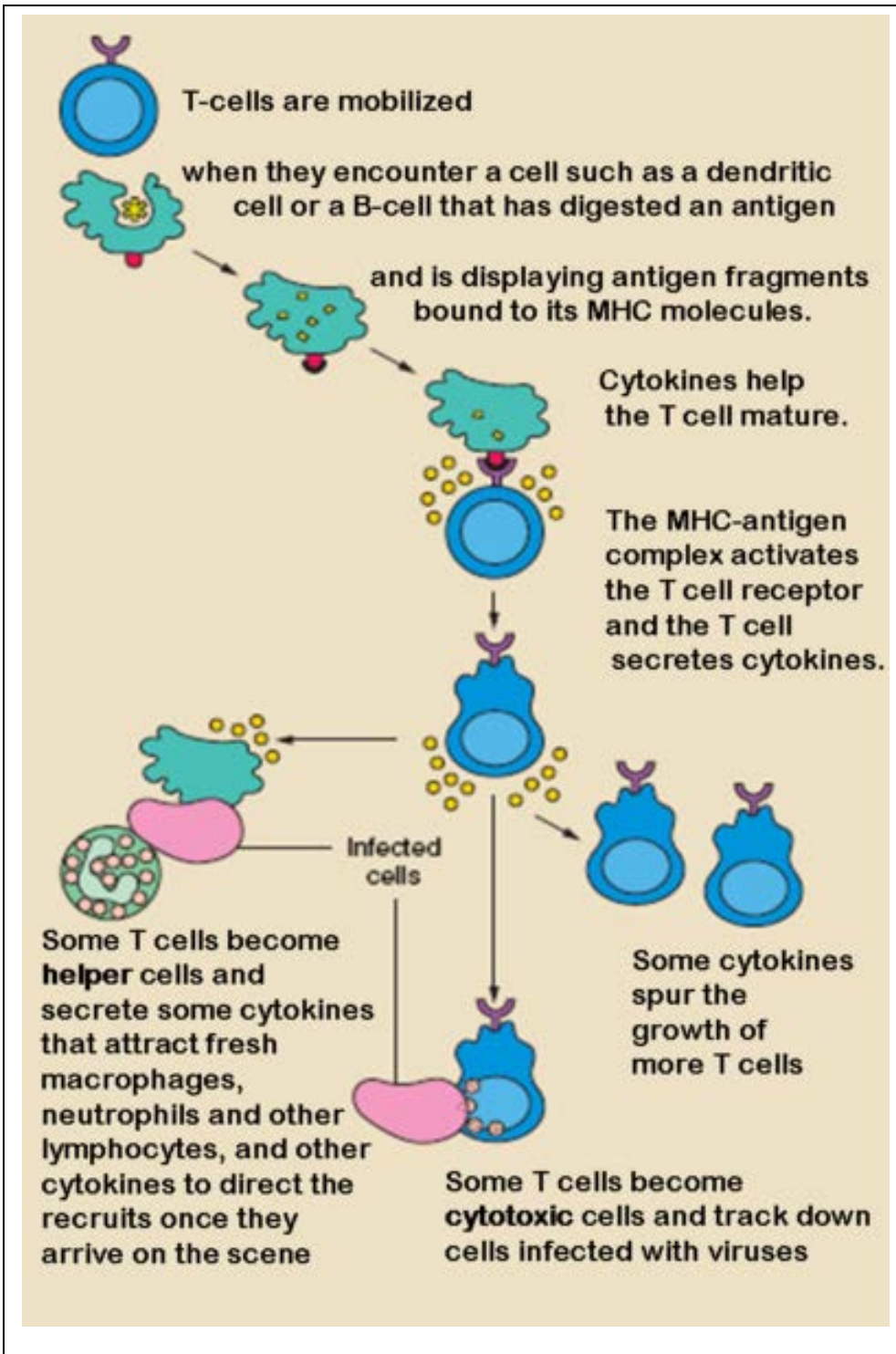


Figure 17.3. T-cell activation

[http://commons.wikimedia.org/wiki/File:T\\_cell\\_activation.png](http://commons.wikimedia.org/wiki/File:T_cell_activation.png)

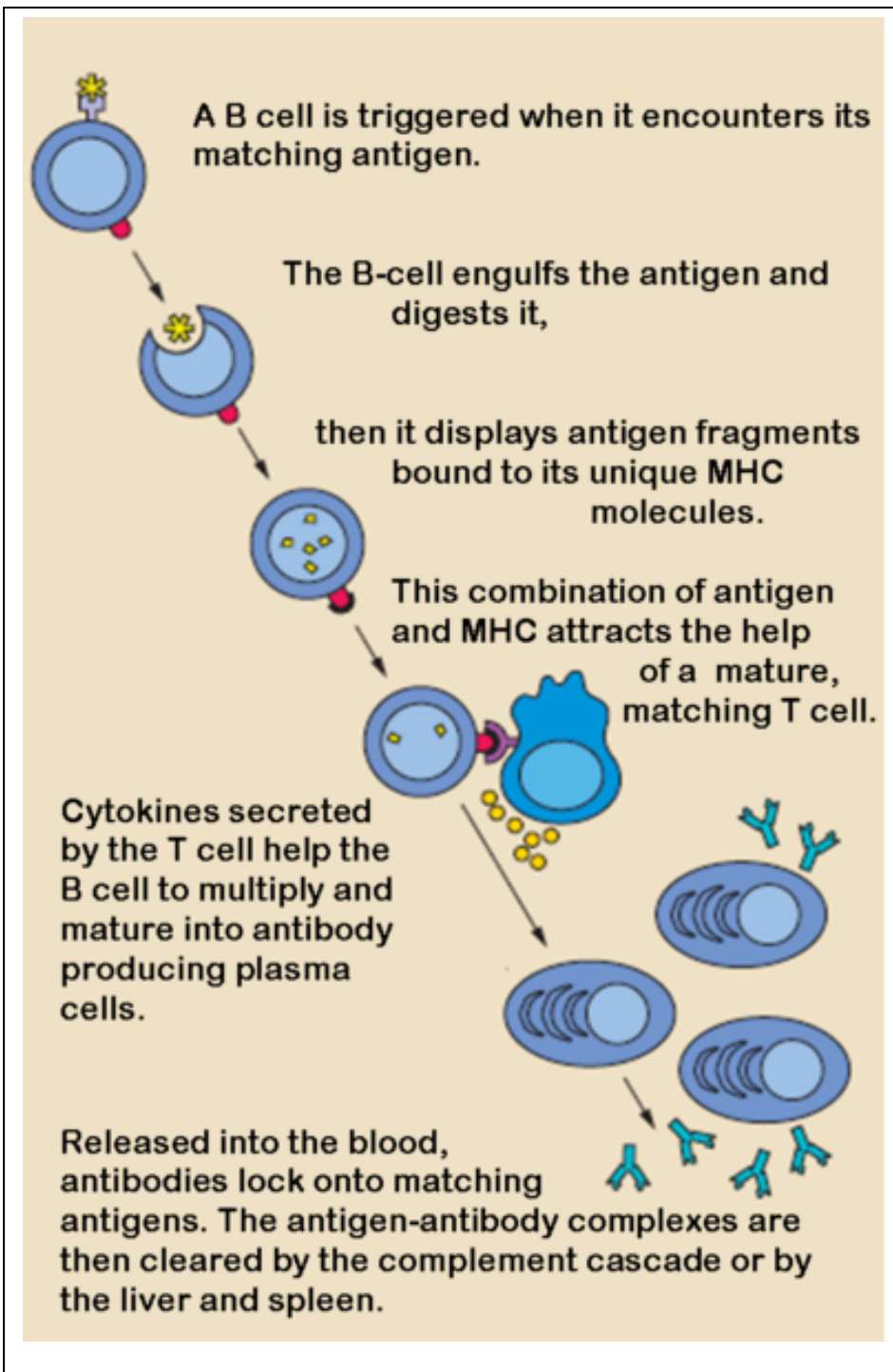


Figure 17.4. B-cell activation

[http://commons.wikimedia.org/wiki/File:B\\_cell\\_activation.png](http://commons.wikimedia.org/wiki/File:B_cell_activation.png)

### **Dendritic Cells**

Dendritic cells are antigen presenting cells found in mucous membranes, lymphatic organs and the epidermis of the skin. These cells have a branched appearance and can engulf pathogens by way of endocytosis. Dendritic cells contain receptors that recognize non-self antigens that trigger endocytosis when activated.

### **Reticular Cells**

Reticular cells (sometimes called fibroblastic reticular cells) are antigen presenting cells located in lymphatic organs. These cells are known to help regulate T-cell function.

### **Macrophages**

Macrophages develop from monocytes that have moved out of the blood. They ingest pathogens by phagocytosis. They also clean up cellular debris including dead neutrophils. Macrophages can display pathogenic antigens on their surface.

### **Primary and Secondary Immune Response**

The first exposure to an antigen with activation of the immune system is known as the primary response. The immune system produces memory cells so that the next time the antigen is presented the system is ready to respond. The second presentation of the same antigen to the immune system is known as the secondary response.

The primary response takes longer to develop (from one to two weeks). During this time B-cells are producing antibodies resulting in a gradual increase in antibodies. The immune system is also producing clones and memory cells that will be ready for the next presentation of the antigen. These memory cells can last for as long as 20 years.

The secondary response is much faster. The second exposure to an antigen results in maturation of the memory cells and production of antibodies. Vaccinations primarily rely on the secondary response (fig. 17.5).



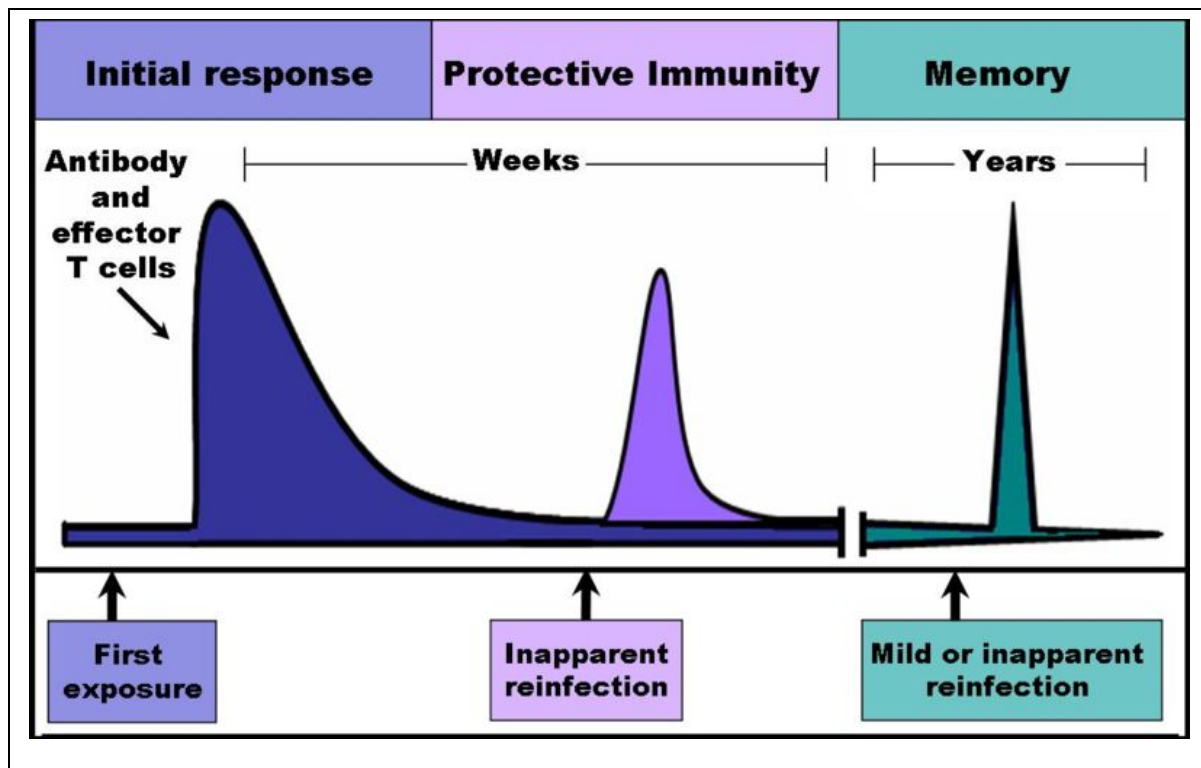


Figure 17.5. Immune response

[http://commons.wikimedia.org/wiki/File:Immune\\_response.jpg](http://commons.wikimedia.org/wiki/File:Immune_response.jpg)

## Allergies

Allergies are immune responses to non-pathological or inert substances. Allergic responses produce a large number of antibodies that can produce a number of adverse effects. Types of allergic responses include Type I anaphylactic, Type II cytotoxic reactions, Type III immune complex disorders, Type IV delayed hypersensitivity (fig. 17.6).

The type I reaction is also known as an immediate hypersensitivity reaction and can be life threatening. It is caused by an inherited tendency to overproduce the IgE antibodies in response to a specific antigen. The first exposure generally does not produce symptoms due to the time it takes for B-cell activation. However the second exposure can be quite severe producing large amounts of inflammation. The most severe reaction is known as anaphylaxis and produces a number of adverse effects within a very brief time period. These include hives, constriction of bronchioles, and peripheral vasodilation that can cause shock.



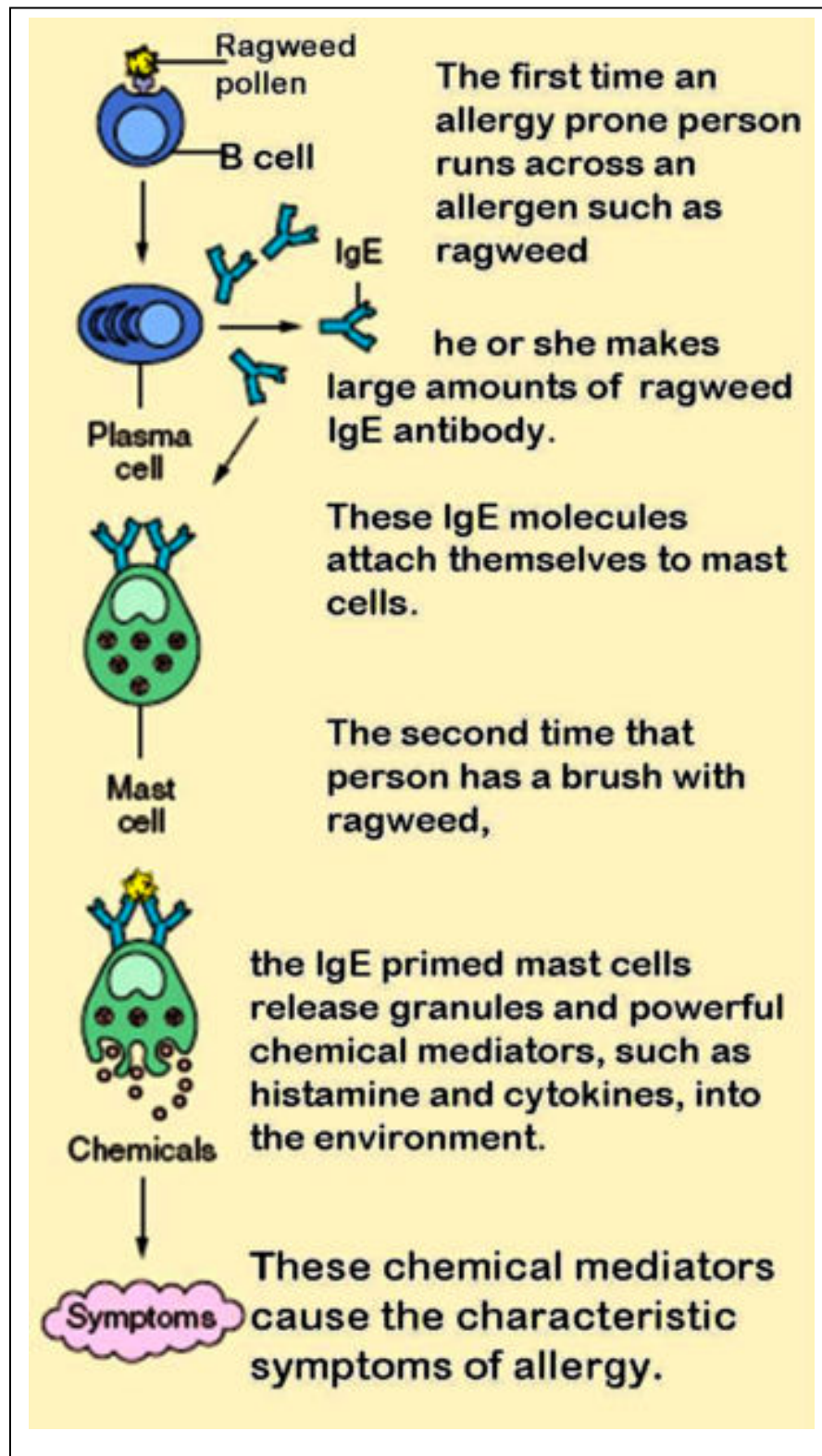


Figure 17.6. Allergic response

[http://commons.wikimedia.org/wiki/File:Mast\\_cells.jpg](http://commons.wikimedia.org/wiki/File:Mast_cells.jpg)

## **Autoimmune Disorders**

In some cases the immune system reacts to self cells and tissues and produces an immune response to them. B-cells produce antibodies known as autoantibodies. Examples of autoimmune disorders include rheumatoid arthritis, systemic Lupus erythematosus, insulin dependent diabetes, and thyroidosis.

## **Types of Immunity**

Immunity is either innate or acquired by exposure to a pathogen. Active immunity is developed after exposure to a pathogen and production of antibodies. Passive immunity results from the presentation of antibodies from other sources.

Naturally acquired active immunity results from exposure to a pathogen. The immune system is activated and produces antibodies and memory cells.

Artificially acquired active immunity results from exposure to pathogens given to the body in the form of vaccines. Vaccines contain inactive or attenuated pathogens that are just strong enough to produce an immune response.

Naturally acquired passive immunity occurs in utero with the passing of antibodies to the fetus from the mother. Antibodies are also passed to the infant through breast milk after birth.

Artificially acquired passive immunity occurs when antibodies are given to a person who has a damaged immune system. Antibodies must be injected periodically because of their short life span.

## Chapter 17 Review Questions

1. Which of the following is not an example of non-specific defense:
  - a. Mucous membrane
  - b. Digestive enzymes
  - c. Antibodies
  - d. Inflammation
  
2. Which of the following best describes a method of activation of T-cells:
  - a. T-cells come into contact with antigen on pathogen
  - b. T-cells activated by basophils
  - c. T-cells activated by helper B-cells
  - d. T-cells activated by enzymes
  
3. If a T-cell contains a CD8 protein it becomes a \_\_\_\_ when activated:
  - a. Helper T
  - b. Autogenic T-cell
  - c. Cytotoxic T-Cell
  - d. Antibody-secreting
  
4. Which of the following occurs with activation of both T and B cells:
  - a. Antibodies are secreted
  - b. Clones are produced
  - c. Inflammation is produced
  - d. Lymph nodes enlarge
  
5. Which of the following is characterized by the secondary immune response:
  - a. Fast response
  - b. Slow response
  - c. Antigens produced
  - d. Antibodies produced slowly
  
6. Which immune cell secretes antibodies when activated:
  - a. Helper T-cells
  - b. Cytotoxic T-cells
  - c. B-cells
  - d. Natural killer cells

7. Which antibody is prevalent in allergic reactions:
- a. IgA
  - b. IgG
  - c. IgD
  - d. IgE
8. Which type of immunity is produced via a vaccine:
- a. Naturally acquired active immunity
  - b. Artificially acquired active immunity
  - c. Naturally acquired passive immunity
  - d. Artificially acquired passive immunity

# Chapter 18

## Cardiovascular System Anatomy

## **Cardiovascular System Anatomy**

The cardiovascular system is a major part of getting oxygenated blood to the tissues. The system consists of the heart and blood vessels. The heart pumps around 1900 gallons of blood each day in an average adult person. The heart is also a vital organ and will endanger life if it ceases to beat for even a few moments.

### **The Big Picture**

The heart essentially has two jobs. It pumps deoxygenated blood from the body to the lungs. It also pumps oxygenated blood from the lungs to the body. The heart then is divided into two regions (right and left sides) with each performing one of the jobs. The right side moves blood from the body to the lungs. The left side moves blood from the lungs to the body.

One of the two jobs is more difficult. In fact because of the close proximity of the lungs to the heart the first job is easier. The second job is more difficult because blood must be pushed out as far as the big toe. Pushing blood farther makes the job more difficult. This is why the left side of the heart is larger than the right.

### **The Heart**

The adult heart is located in the thoracic cavity in an area known as the mediastinum (fig. 18.1). In fact opening the thoracic cavity reveals the right and left lungs and a mass of tissue in the middle called the mediastinum (fig. 18.2). The mediastinum contains the heart, esophagus, trachea, vessels, nerves and membranes surrounding the heart. Dissecting the membrane known as the parietal pericardium reveals the heart.

The heart is shaped like a blunt cone and is the size of a fist. The point of the cone is called the apex and the other end is called the base. The apex points downward (fig. 18.3). The heart is positioned centrally with the apex pointing to the left. More of the heart resides left of the midline of the thoracic cavity than on the right.

### **Membranes of the Heart**

The heart is surrounded by a double layered sac consisting of two membranes. The outer membrane consists of fibrous connective tissue and is known as the fibrous or parietal pericardium. The inner membrane is thinner and consists of simple squamous epithelium. It is known as the visceral or serous pericardium. The visceral pericardium is consistent with the great vessels of the heart and the diaphragm.

Serous fluid known as pericardial fluid exists between the membranes. The fluid helps to reduce friction when the heart beats.

The visceral pericardium can become inflamed and produce extra fluid in a condition known as pericarditis. This can result from infection or diseases of the connective tissues.

Pericarditis can also result from damage caused by radiation therapy. Pericarditis can cause severe sharp pains in the chest and back.

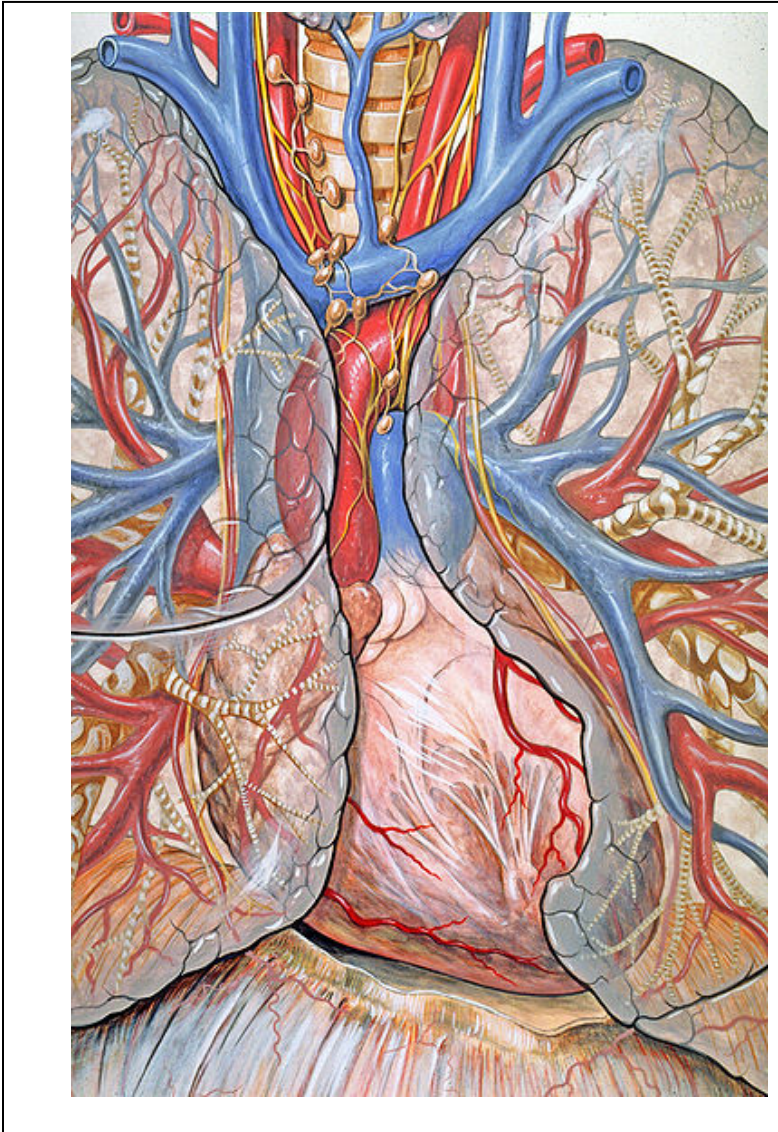

Figure 18.1. The heart is located in the mediastinum.

[http://commons.wikimedia.org/wiki/File:Mediastinum\\_anatomy.jpg](http://commons.wikimedia.org/wiki/File:Mediastinum_anatomy.jpg)

Author: Patrick J. Lynch



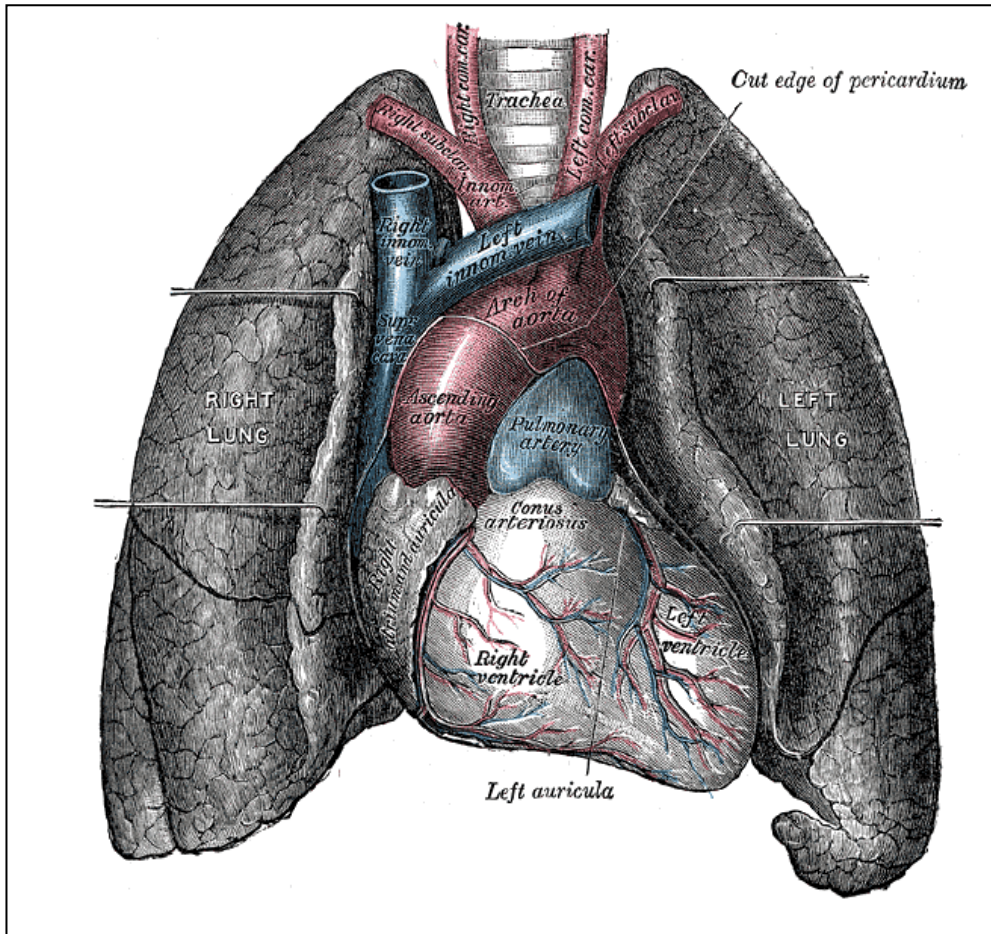


Figure 18.2. The mediastinum.

<http://commons.wikimedia.org/wiki/File:Gray490.png>



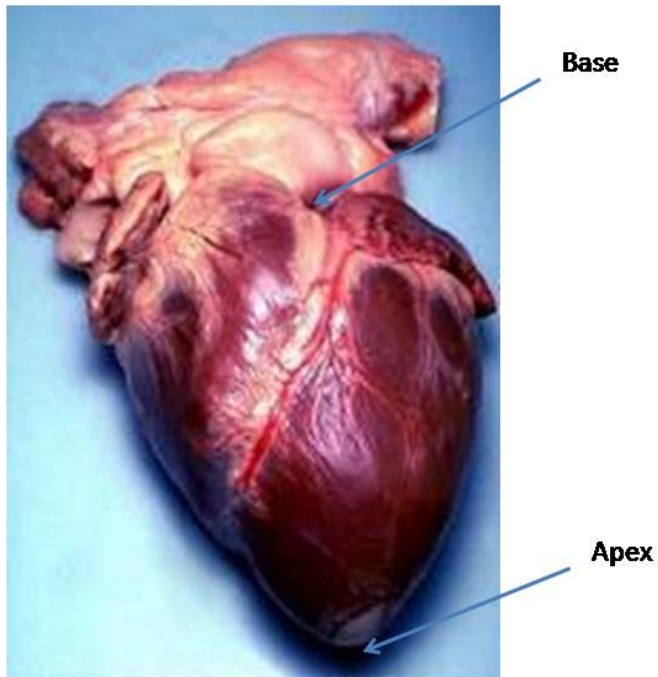


Figure 18.3. Human heart.

Modified by Dr. Bruce Forciea From:

<http://commons.wikimedia.org/wiki/File:Humhrt2.jpg>

## **Layers of the Heart**

The heart consists of three layer of tissue. These include the endocardium, myocardium, and epicardium. The endocardium is the internal layer consisting of simple squamous epithelium and connective tissue. This layer is consistent with the valves of the heart. The middle myocardium is a thick layer of cardiac muscle. The outer epicardium is the visceral pericardium and consists of a thin serous membrane.

## **Heart Structures**

The heart consists of four chambers. Two of these chambers receive blood and are called atria. The other two chambers are larger for pumping blood outside of the heart and are called ventricles. Each side of the heart has an atrium and ventricle. The atria are separated by a mass of tissue called the interatrial septum. The interatrial septum contains a small indentation that is a remnant of fetal circulation known as the fossa ovalis. In utero the fossa ovalis is the foramen ovale that serves as a passageway for blood to bypass the lungs. The foramen ovale closes at birth. On the outer surface of the heart between the atria and ventricles are the auricles which are extensions of the atria.

The ventricles are also separated by a thick mass of muscles known as the interventricular septum.

On the surface of the heart a sulcus known as the coronary sulcus separates the atria and ventricles. The anterior interventricular sulcus divides the right and left ventricles anteriorly. The posterior interventricular sulcus divides right and left ventricles posteriorly.

## **Blood Flow Through the Heart**

One way to learn the heart structures is to follow a drop of blood through the heart (figs. 18.4-18.8). Deoxygenated blood enters the right atrium via two large veins called the superior and inferior vena cava. Blood then flows from the right atrium to the right ventricle past a one way valve known as the tricuspid valve. The tricuspid valve has three cusps with each connected to the internal wall of the right ventricle via connective tissue structures called chordae tendoneae. The chordae tendoneae connect to finger-like projections of muscle called papillary muscles. The tricuspid valve is driven by pressure and only allows blood to flow in one direction (from atrium to ventricle).

Contraction of the right ventricle pushes blood to the pulmonary trunk and past the pulmonary semilunar valve on its way to the lungs. The pulmonary trunk is a thick artery that splits into right and left pulmonary arteries that serve the right and left lungs. The pulmonary semilunar valve contains three cusps that only allow blood to flow in one direction. When pressure builds in the ventricle the cusps open allowing blood to move into the pulmonary trunk. When pressure causes movement of blood back toward the heart the valves close.

Blood moves from the pulmonary arteries to the lungs for oxygenation. Oxygenated blood is carried by four pulmonary veins to the left atrium. Blood then moves from the left atrium to

the left ventricle past the bicuspid valve (aka mitral valve). The bicuspid valve is a one way valve with two cusps that attach to the ventricle wall via chordae tendoneae and papillary muscles. Contraction of the left ventricle causes blood to flow into the aorta past the aortic semilunar valve. The aortic semilunar valve has three cusps and only allows blood to flow away from the heart. Oxygenated blood now flows through the aorta to the body.

### **Coronary Arteries**

The coronary arteries supply the heart muscle with oxygenated blood. The right coronary artery branches off of the aorta and resides in the coronary sulcus. It divides into the right marginal and posterior interventricular arteries. The right marginal supplies the right atrium and ventricle while the posterior interventricular supplies the posterior sides of both ventricles.

The left coronary also branches from the aorta and divides to form the anterior interventricular artery (aka left anterior descending artery), the left marginal artery and circumflex artery. The anterior interventricular artery supplies the anterior side of the ventricles. The left marginal artery supplies the lateral wall of the left ventricle and the circumflex artery supplies the posterior wall of the heart.

The left side of the heart is drained by the great cardiac vein and the right side is drained by the small cardiac vein. Both veins empty into the coronary sinus which empties into the right atrium.

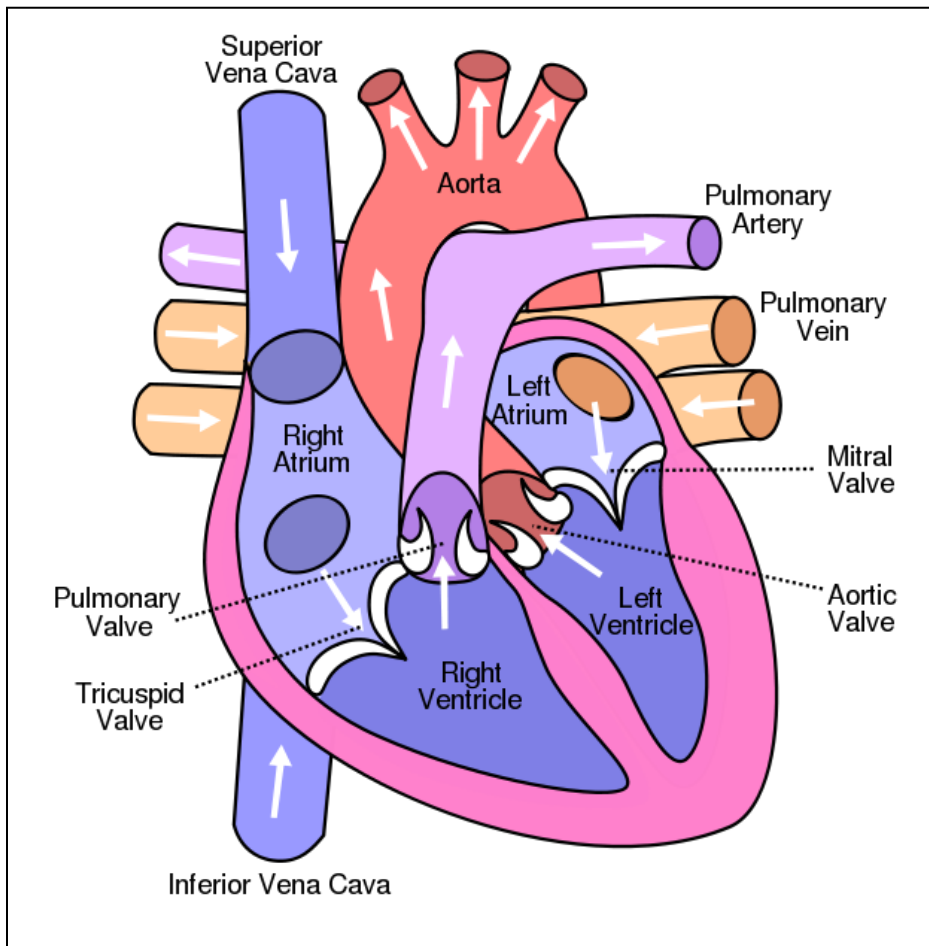


Figure 18.4. Heart

[http://commons.wikimedia.org/wiki/Image:Diagram\\_of\\_the\\_human\\_heart\\_\(cropped\).svg](http://commons.wikimedia.org/wiki/Image:Diagram_of_the_human_heart_(cropped).svg)

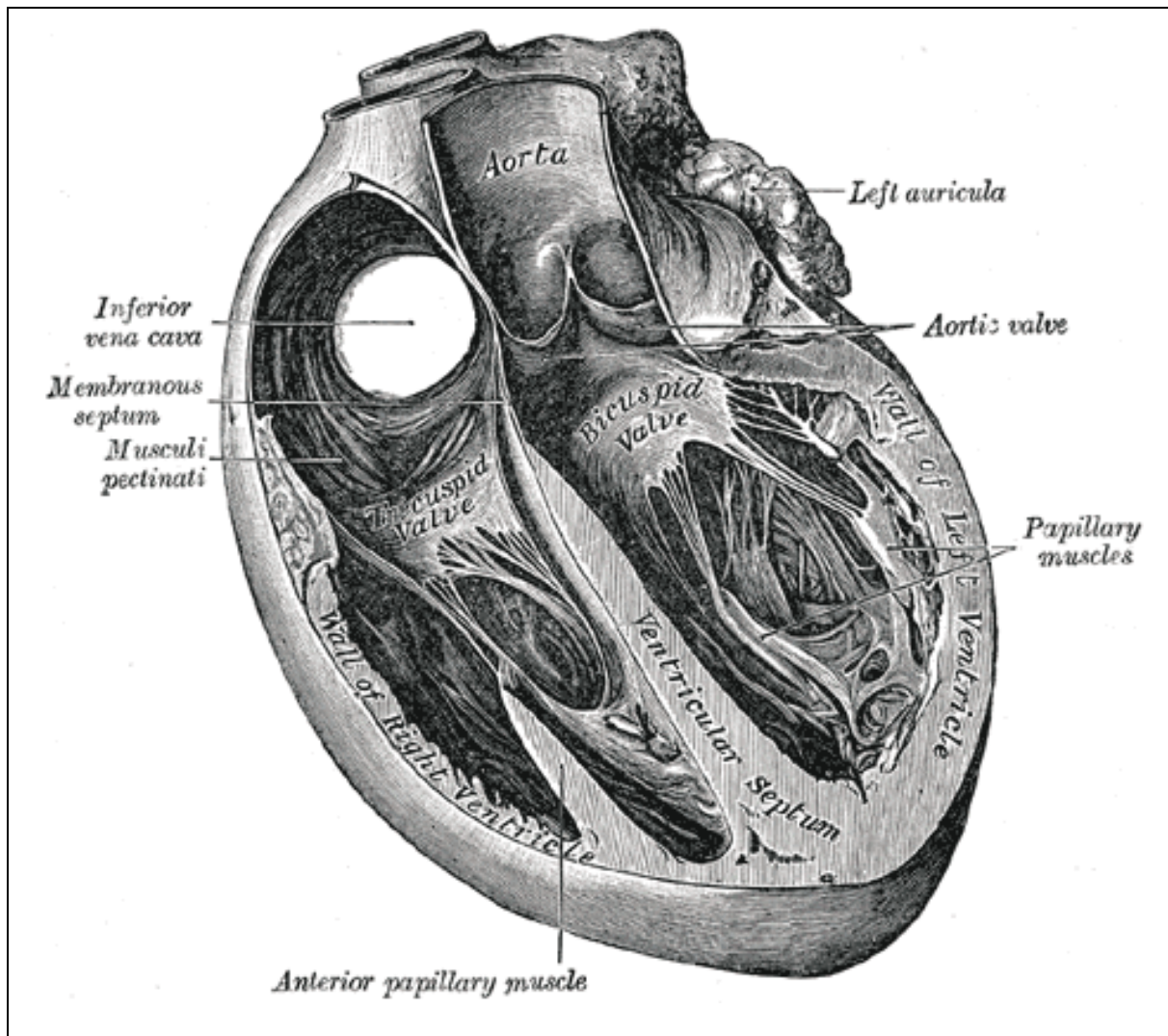


Figure 18.5. Interior of the heart.

<http://commons.wikimedia.org/wiki/File:Gray498.png>

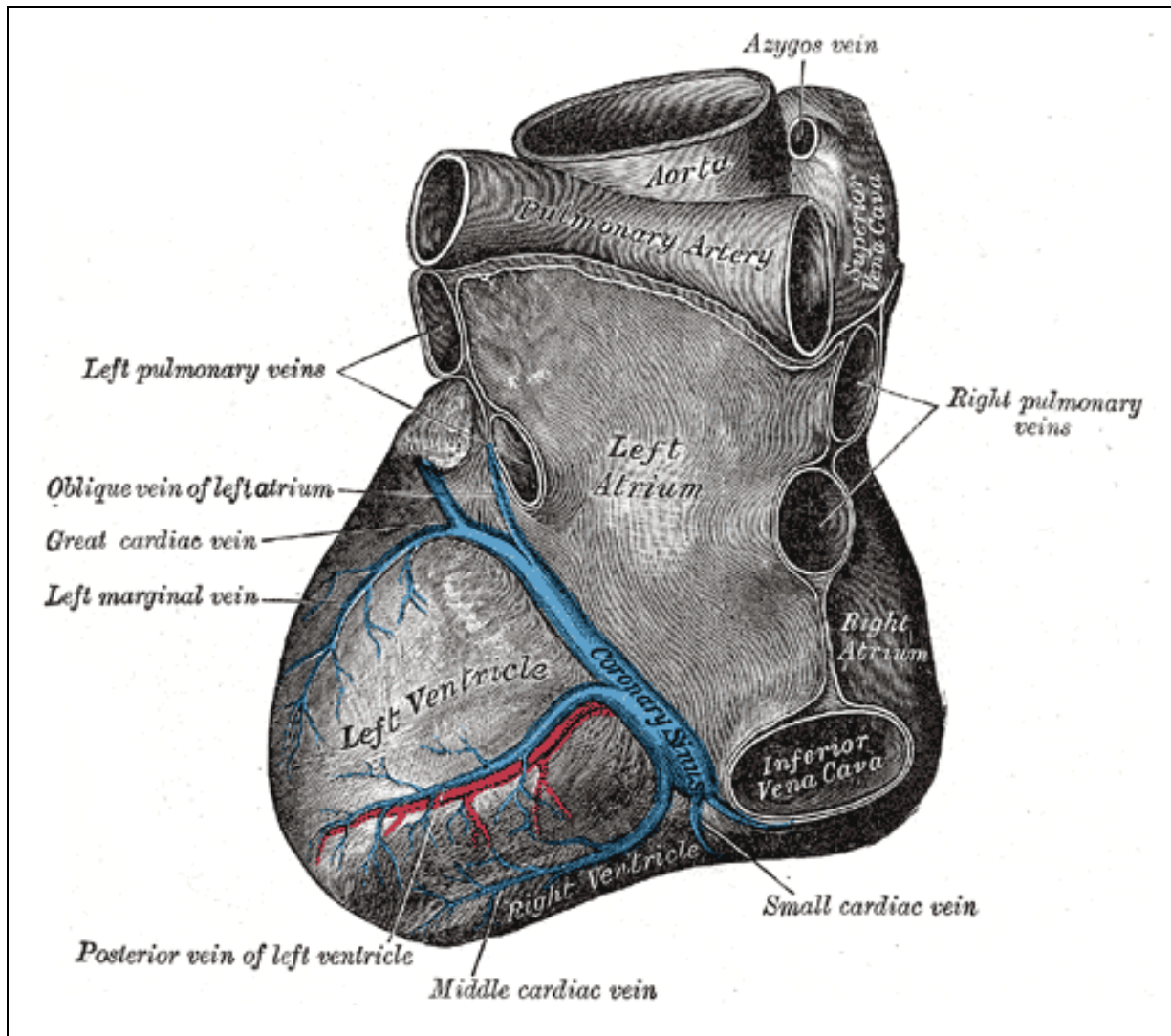


Figure 18.6. Posterior heart structures

<http://commons.wikimedia.org/wiki/File:Gray491.png>



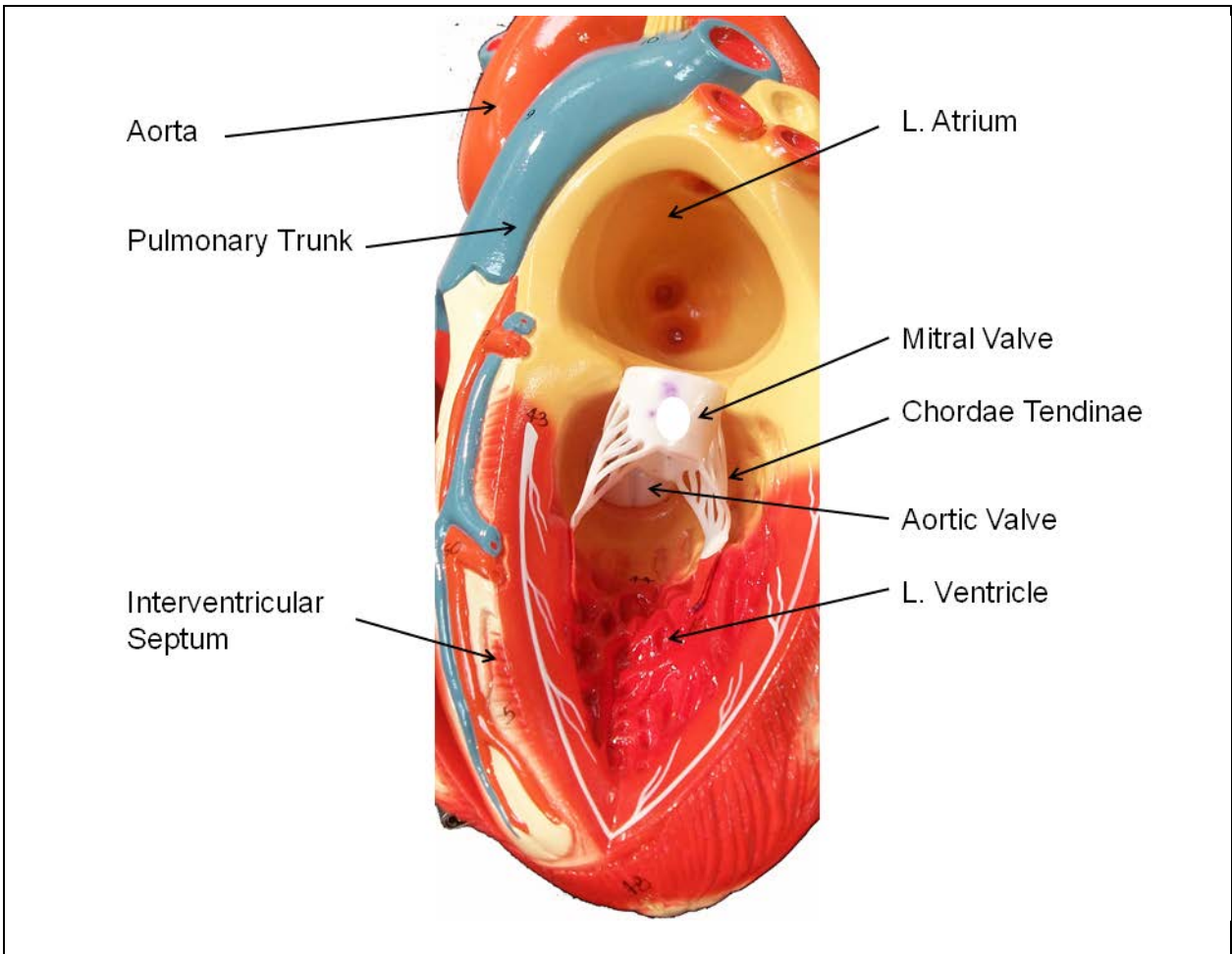


Figure 18.7. Heart Structures

Bruce Forciea

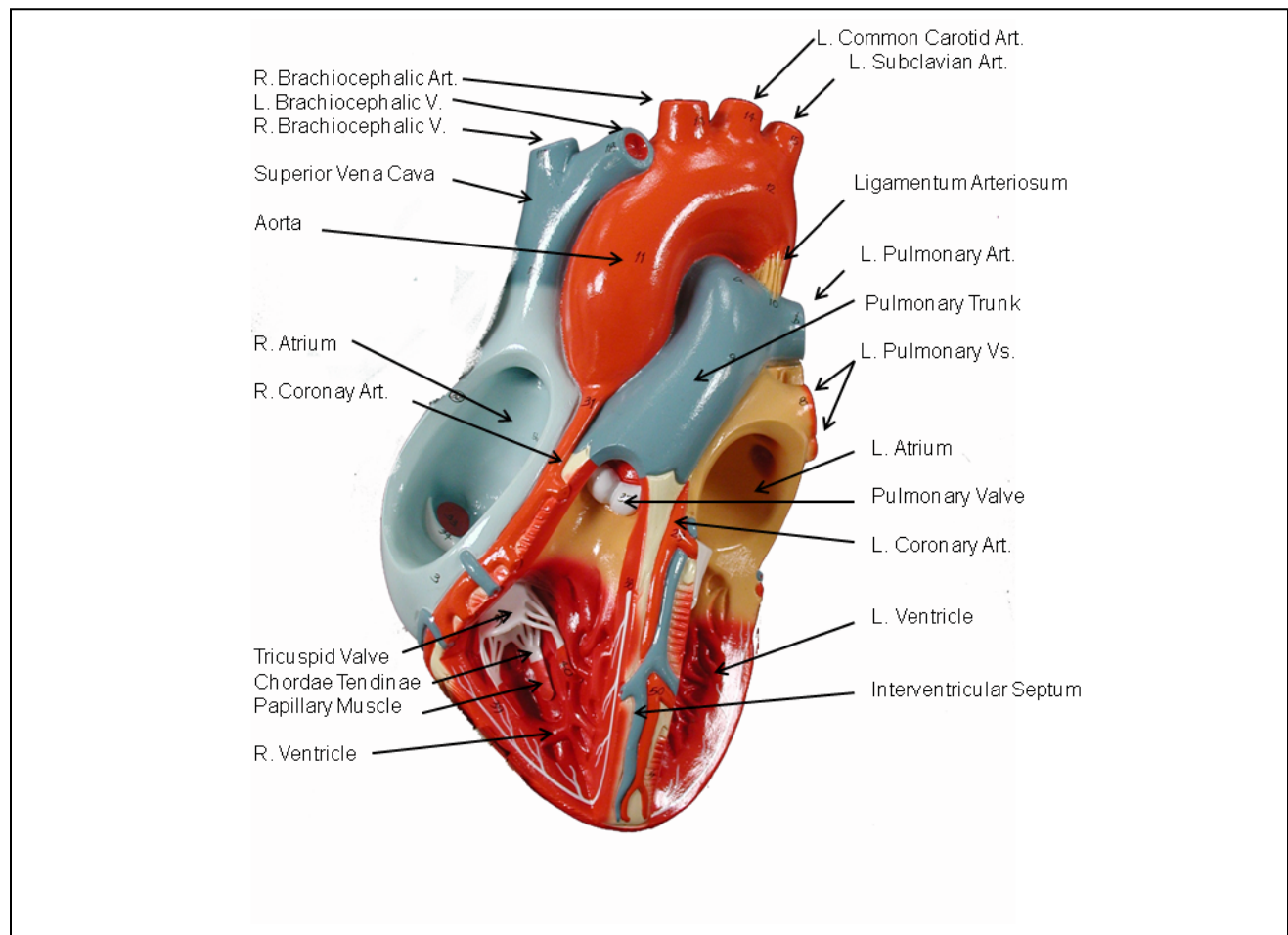


Figure 18.8. Heart Structures.

Bruce Forciea



## **The Cardiac Cycle**

During one heartbeat the heart must receive blood in the atria and then move this blood to the ventricles and out to the lungs or the body. The cardiac cycle is the sequence of events that makes this possible (fig. 18.9-18.10).

There are three phases in the cardiac cycle. In phase one (called the rest phase) the heart is relaxed or in diastole. Blood passively flows into the atria and subsequently into the ventricles. Actually, about 70% of blood flows into the ventricles without any contraction of the atria.

As we stated earlier the valves operate by changes in pressure. During phase one the pressure is greater in the atria than in the ventricles. This causes both atrioventricular valves (bicuspid and tricuspid) to open. The relaxation of the ventricles (ventricular diastole) creates a lower pressure in the ventricles than in the pulmonary trunk and aorta. This causes the semilunar valves (pulmonary and aortic) to close.

The next phase in the cycle is characterized by systole of the atria. The ventricles are still in diastole in this phase. The contraction of the atria pushes the remaining 30% of the blood into the ventricles. The atrioventricular valves remain open and the semilunar valves remain closed.

The final phase is characterized by atrial diastole and ventricular systole. Contraction of the ventricles causes increased pressure in the ventricles. This increase in pressure causes the atrioventricular valves to close and the semilunar valves to open.

The heart again enters the rest phase and the cycle repeats.

We will cover more physiology in the next chapter.

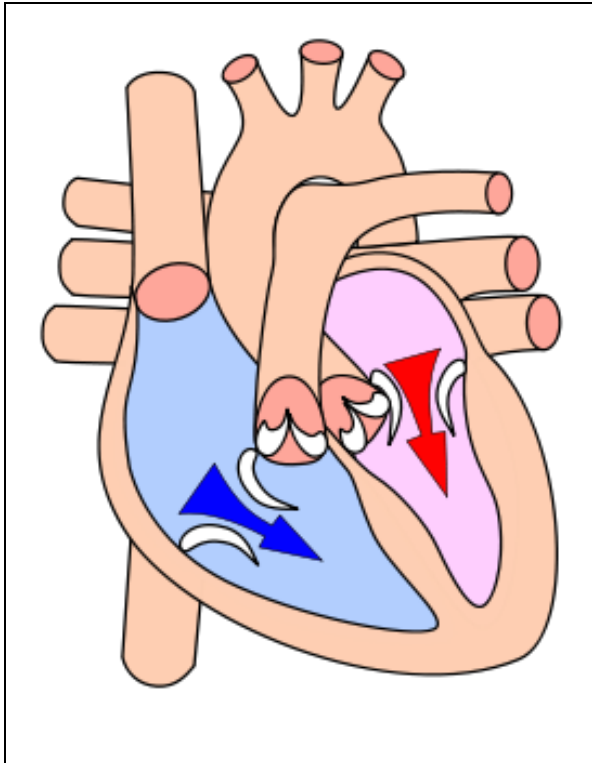


Figure 18.9a. Blood passively flows into the heart during the rest phase. And then is pushed into the ventricles during atrial systole.

[http://commons.wikimedia.org/wiki/File:Heart\\_diastole.png](http://commons.wikimedia.org/wiki/File:Heart_diastole.png)

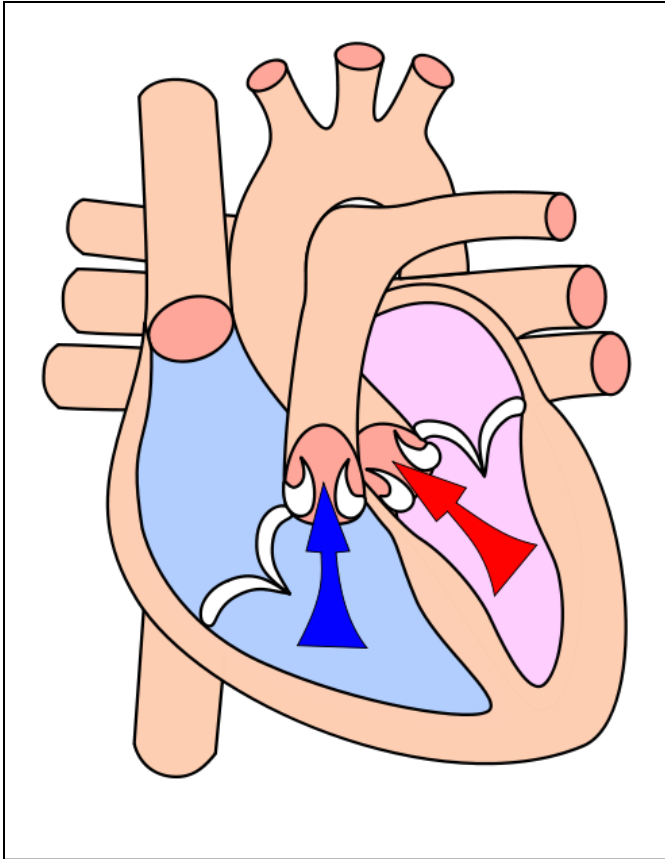


Figure 18.9b. Blood moves from the ventricles to the pulmonary trunk and aorta during ventricular systole.

[http://commons.wikimedia.org/wiki/File:Heart\\_systole.svg](http://commons.wikimedia.org/wiki/File:Heart_systole.svg)

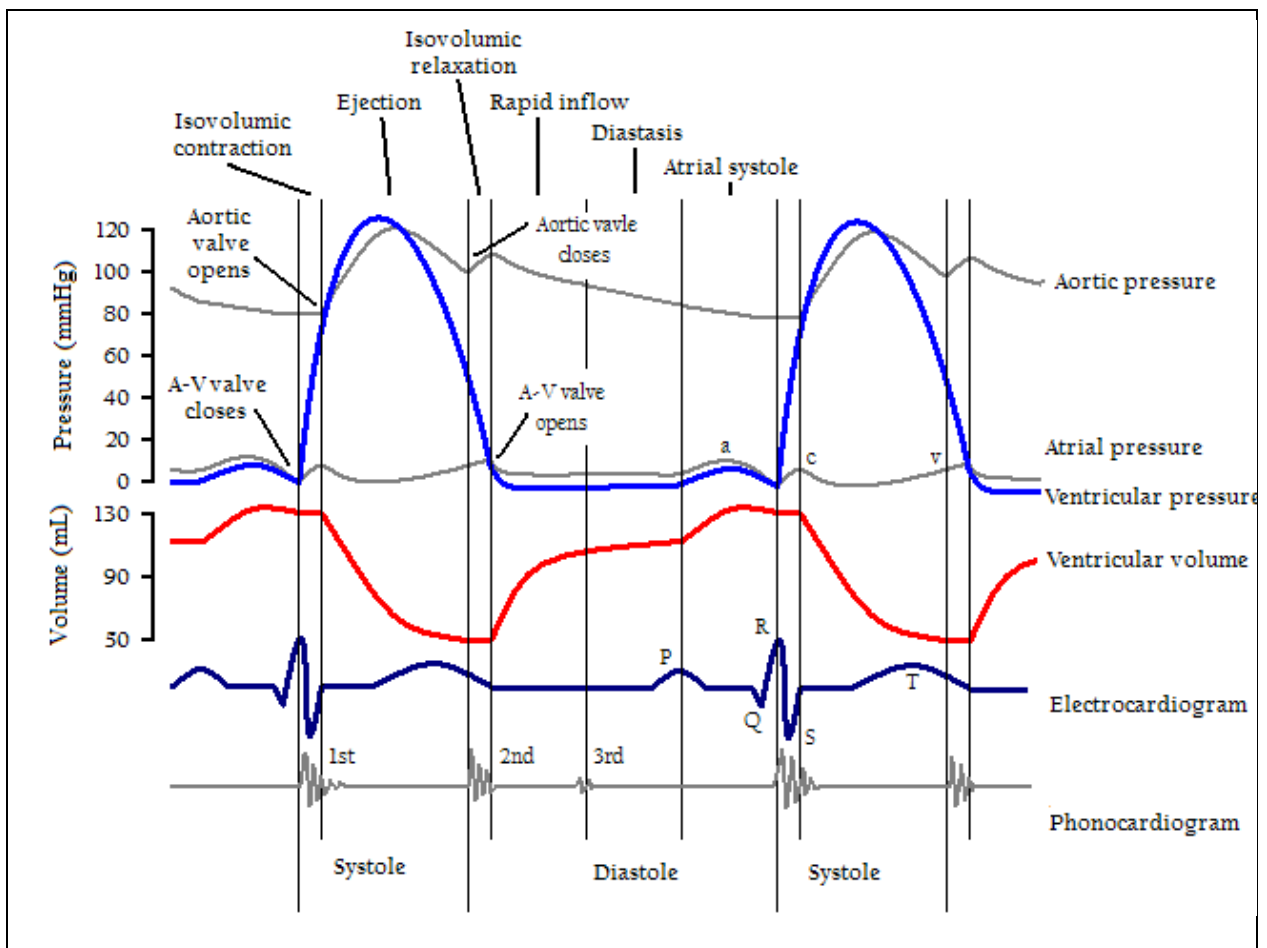


Figure 18.10. Events of the cardiac cycle

[http://commons.wikimedia.org/wiki/File:Cardiac\\_Cycle\\_Left\\_Ventricle.PNG](http://commons.wikimedia.org/wiki/File:Cardiac_Cycle_Left_Ventricle.PNG)

## Heart Sounds

A good deal of information can be obtained from listening to the heart with a stethoscope. This procedure is called auscultation. The heart sounds are produced by changes in blood flow during different parts of the cardiac cycle.

There are four heart sounds that repeat continuously but only two are usually heard in healthy adults. The first sound or S1 (lubb) is produced by turbulent flow of blood resulting from closure of the atrioventricular valves (bicuspid, tricuspid) in ventricular systole. It is louder and longer than the second sound (S2). The S2 sound (dupp) results from closure of the semilunar valves (pulmonary, aortic) during ventricular diastole.

A third sound (S3) can sometimes be heard between S2 and S1. This sound is the result of ventricular filling and can be heard in children and athletes. It also arises in congestive heart failure.

The fourth sound (S4) occurs just before S1 and is not often heard. It is considered abnormal in adults. The sound is produced by forceful contraction of the atria forcefully pushing blood against a failing ventricle.

The period between S1 and S2 represents ventricular systole. Likewise the period between S2 and S1 represents ventricular diastole.

## **Blood Vessels**

Blood vessels carry blood from the heart to the lungs and tissues of the body and back to the heart. The system of blood vessels is called the vascular system and is considered a closed system. Oxygenated blood is carried to tissues where substances are exchanged. Substances need for cell maintenance and growth move out of the blood while waste products and substances needed for regulation of the body move in.

### **The Arterial System**

The arterial system consists of arteries, arterioles and capillaries. The largest arteries consist of three layers (fig. 18.11). The outer tunica externa consists of elastic and collagen fibers. The larger vessels also contain minute blood vessels that carry nutrients to the tissue. Nerve fibers also innervate arteries.

The middle layer or tunica media is thicker in arteries than in veins. It primarily consists of smooth muscle with some elastic fibers. The smooth muscle in the tunica media allows for constriction (vasoconstriction) and dilation (vasodilation) of the arteries. The nervous system has some control over the diameter of arteries in order to control blood pressure. Also blood vessels constrict when damaged to reduce the loss of blood.

The inner layer or tunica interna consists of an inner thin layer of simple squamous epithelium called the endothelium anchored to another layer by a basement membrane. The basement membrane anchors the endothelium to a layer called the internal elastic lamina consisting of elastic fibers.

Arteries branch to form smaller structures called arterioles. Arterioles help to control blood flow to various parts of the body by way of vasoconstriction and vasodilation. The end of the arteriole that connects with the capillaries narrows and becomes a metarteriole that contains a round smooth muscle called a precapillary sphincter. The precapillary sphincters help to control the flow of blood to the capillary beds. One metarteriole may supply up to 100 capillaries forming what is known as a capillary bed.

Capillaries are the smallest blood vessels in the body (fig. 18.12). They carry blood to the venous system and allow for the exchange of substances between the blood and the tissues. Capillaries form complex networks and it is estimated that there are about one billion capillaries in the human body. Blood flow to capillaries is controlled by small smooth muscles called precapillary sphincters.

Capillaries are extensions of the endothelium of arteries. They consist of simple squamous epithelium and a basement membrane that allows a good degree of permeability for substance exchange. Capillaries are more numerous in areas with high metabolic activity such as muscle and nerve tissue. Permeability also varies according to metabolic demand. For example, capillaries in the liver and spleen are more permeable than those in smooth or skeletal muscle.

Most substances are exchanged by diffusion but other transport mechanisms include filtration and osmosis.

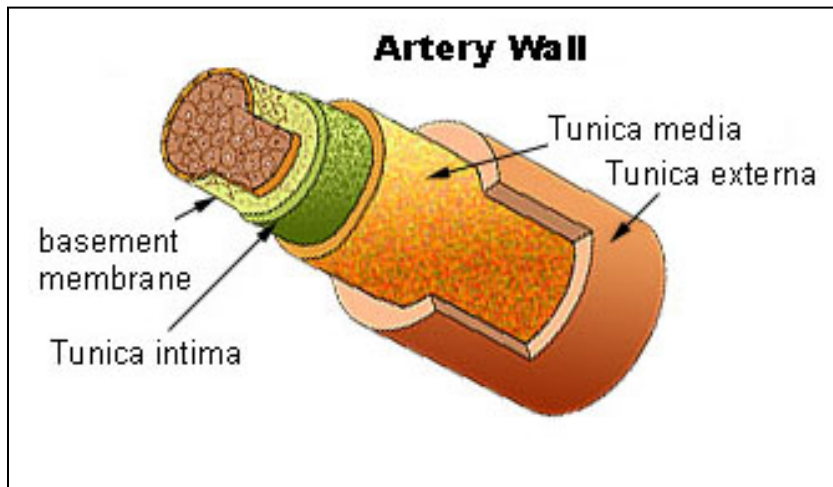


Figure 18.11. Artery

[http://commons.wikimedia.org/wiki/File:Illu\\_artery.jpg](http://commons.wikimedia.org/wiki/File:Illu_artery.jpg)

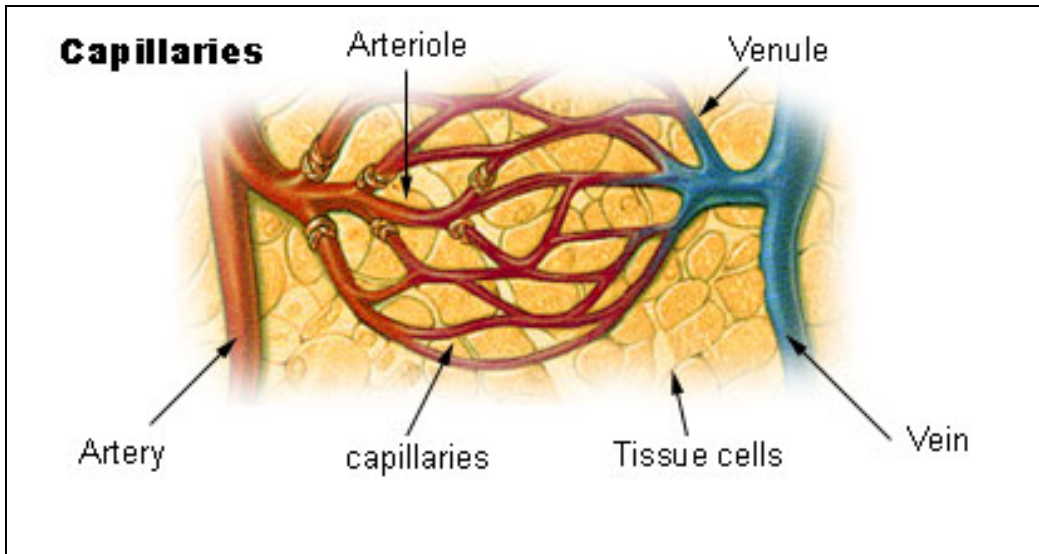


Figure 18.12. Capillary Bed.

[http://commons.wikimedia.org/wiki/File:Illu\\_capillary.jpg](http://commons.wikimedia.org/wiki/File:Illu_capillary.jpg)

## The Venous System

Capillaries contain an arterial and venous end. The venous system begins at the venous end of capillaries (fig. 18.12). Oxygen and carbon dioxide exchange occurs in the capillaries and deoxygenated blood is now carried into the venous vessels.

### Venules

Venules begin at the ends of capillaries and carry blood to the veins. Venules are very small and similar in structure to capillaries. They allow for substance exchange and merge with larger diameter veins.

### Veins

Veins like arteries contain three layers. However the middle layer or tunic media is not as thick as in arteries. Veins have larger lumens than arteries and many veins contain valves that only allow blood to flow to the heart. Veins can vasoconstrict and do so in situations of blood loss in order to conserve blood. When significant blood is lost, the sympathetic nervous system stimulates veins to constrict in an effort to return blood to the heart. This allows for nearly normal blood flow when up to 25% of blood is lost.

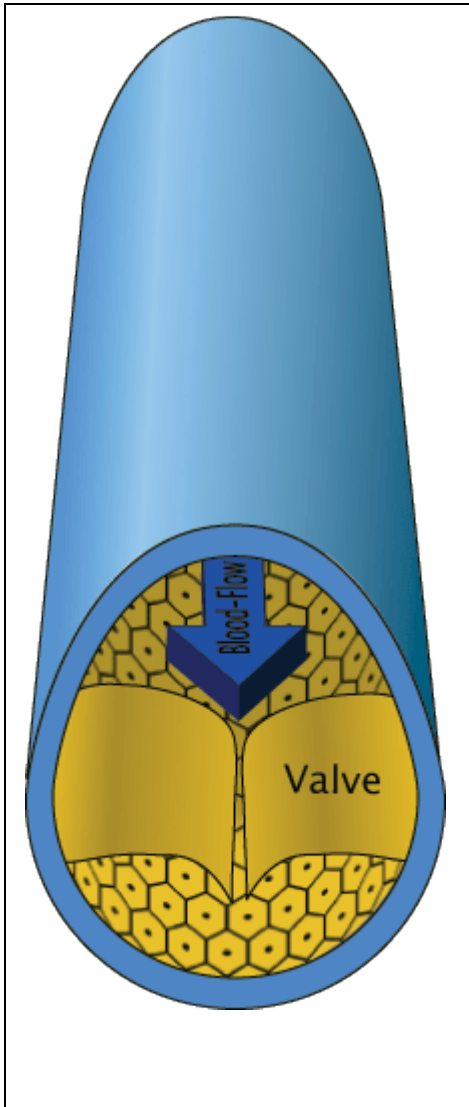


Figure 18.13. Vein

<http://commons.wikimedia.org/wiki/File:Veincrosssection.png>

### Blood Flow in Veins

Pressure in the arterial system is greatest at its source and decreases throughout the system. For example blood pressure is greater in the aorta than in arterioles and even less in capillaries. In fact we would not want a high blood pressure in capillaries as their thin walls would burst (a condition that happens in hypertension). Thus there is minimal blood pressure in capillaries.

The question is then, if blood pressure is so low in capillaries, how does blood get back to the heart?

The answer lies in the structure of veins. Veins contain one-way valves that only allow blood flow to the heart. Many veins lie next to muscles. Muscle contraction produces an external



pumping force on veins that helps to move blood to the heart. The movement of the diaphragm also contributes to venous flow.

### **Major Arteries and Veins (Fig. 18.14)**

This section will cover some of the major arteries and veins. We will present the major arterial and venous routes through the body with some of the secondary branches. Remember the heart has two jobs. It must pump deoxygenated blood to the lungs for oxygenation and then pump the oxygenated blood out to the tissues of the body. In order to complete both jobs there are two pathways or circuits in which the blood flows. The pulmonary circuit begins at the right side of the heart with the pulmonary trunk and ends at the left atrium. The systemic circuit begins at the left side of the heart and ends at the right side.

#### **The Pulmonary Circuit**

Deoxygenated blood enters the right side of the heart at the right atrium. The blood moves to the right ventricle and then exits via the pulmonary trunk. The pulmonary circuit begins at the pulmonary trunk. The pulmonary trunk then divides into right and left pulmonary arteries. The pulmonary arteries enter the lungs and form smaller and smaller branches. The smallest branches consist of the pulmonary arterioles that bring oxygenated blood to the capillaries that feed the alveoli. The alveoli are minute structures in the lung that exchange oxygen and carbon dioxide.

Once the blood becomes oxygenated it exits the alveoli and enters venules that branch to larger vessels called pulmonary veins. There are two pulmonary veins for each lung that carry blood to the left atrium.

It is important to note that in the pulmonary circuit deoxygenated blood is carried by arteries and oxygenated blood is carried by veins. The opposite is true of the systemic circuit.

#### **The Systemic Circuit**

The systemic circuit begins at the left ventricle with the aorta and ends at the right atrium at the superior and inferior vena cava.

#### **Arteries**

One way to think of the circulatory system is to compare it with a freeway system. There are major freeways linking to smaller highways that link to even smaller roads. The circulatory system has a similar structure with main routes linking to smaller ones and so on.

## **Aorta**

As the aorta exits it is known as the ascending aorta. Near the aortic valve is an enlargement known as the aortic sinus. The aortic sinus contains the aortic bodies. The aortic bodies are chemoreceptors that sense changes in chemical concentration and feed this information back to the nervous system. The aorta then curves forming the arch of the aorta and extends inferiorly to become the thoracic aorta. It then passes below the diaphragm to become the abdominal aorta.

### **Branches of the Aorta**

The right and left coronary arteries arise from the aorta shortly after it emerges from the aortic valve. Along the arch of the aorta are three branches. From left to right these include the brachiocephalic trunk, left common carotid and left subclavian arteries. The brachiocephalic trunk then divides into the right common carotid and right subclavian arteries (figs. 18.15).

The thoracic aorta contains both visceral branches to organs and parietal branches to structures of the body wall. The visceral branches include the pericardial, bronchial, esophageal and mediastinal. The parietal branches include the posterior intercostals, subcostal and superior phrenic arteries.

The thoracic aorta then moves through the diaphragm and becomes the abdominal aorta. The abdominal aorta ends with a bifurcation producing the right and left common iliac and middle sacral arteries. The visceral branches of the abdominal aorta include the celiac trunk, right and left suprarenal, renal and gonadal arteries, and the superior and inferior mesenteric arteries. The parietal branches include the inferior phrenic, lumbar and median sacral.

The celiac trunk divides into the splenic, left gastric and common hepatic arteries (fig. 18.17). The splenic artery supplies the spleen and some of the arteries to the stomach. The left gastric artery supplies the stomach and part of the esophagus. The common hepatic artery supplies arteries for the liver, stomach, gallbladder and small intestine.

The right and left common iliac arteries divide and become the internal and external iliac arteries at the level of the lumbosacral junction (fig.18.18). The internal iliac arteries supply the urinary bladder, genitalia, walls of the pelvis and medial thigh. The external iliac arteries continue to the lower extremities.

The external iliacs emerge from under the inguinal ligament as the femoral arteries. The deep femoral artery branches from the femoral artery and gives rise to the femoral circumflex artery. The femoral artery continues distally and gives rise to a branch known as the descending genicular artery that supplies the area around the knee. The femoral artery then pierces the adductor longus muscle and emerges as the popliteal artery which branches to become anterior and posterior tibial arteries. The fibular artery (peroneal artery) branches from the posterior tibial artery.

The anterior tibial artery becomes the dorsalis pedis artery at the ankle which branches and supplies the foot. The posterior tibial divides into the medial and lateral plantar arteries. These arteries supply the plantar area of the foot. The smaller divisions of the plantar arteries connect with the dorsalis pedis artery to form the dorsal and plantar arches of the foot.

### **Arteries of the Head and Upper Extremity**

As stated earlier among the first branches of the aorta is the brachiocephalic trunk, left common carotid artery and left subclavian artery. The brachiocephalic trunk divides to form the right common carotid and right subclavian arteries (figs. 18.22).

The common carotid moves superiorly and divides into the internal and external carotid arteries. The carotid sinus is located at the junction of the internal and common carotid arteries. The external carotid continues on the outer part of the skull and gives rise to arteries that supply the esophagus, neck, pharynx, larynx, mandibular region, and face.

The internal carotid enters the skull through the carotid canal and divides into three branches. These are the ophthalmic, anterior cerebral and middle cerebral arteries.

The vertebral arteries branch from the subclavian arteries and extend upward through the transverse foramen of the cervical vertebra and enter the skull at the foramen magnum. Both vertebral arteries merge to form the basilar artery. Both the vertebral arteries and basilar arteries give rise to branches that supply various parts of the brain before dividing to form the posterior cerebral arteries which then branch to form the posterior communicating arteries.

The anterior portion of the cerebrum is supplied by the internal carotid arteries and the remaining portion of the brain is supplied by the vertebral arteries. The internal carotid arteries connect with the basilar artery via two posterior communicating arteries. Since the resulting vascular structure forms a ring it is called the Circle of Willis (cerebral arterial circle) (fig. 18.27). This structure allows for some redundancy in supply to the brain as it can receive blood from either the vertebral arteries or internal carotid arteries.

The subclavian artery continues under the clavicle and gives rise to the internal thoracic, vertebral and thyrocervical trunk. The subclavian artery emerges from under the clavicle to form the axillary artery which produces the humeral circumflex artery. The axillary artery continues along the arm to become the brachial artery which gives rise to the deep brachial artery and the ulnar collateral arteries. At the elbow the brachial artery divides to form the radial and ulnar arteries. At the wrist the radial and ulnar arteries reconnect to form the superficial and deep palmar arches which in turn supply the digital arteries of the fingers (figs. 18.24-18.26).

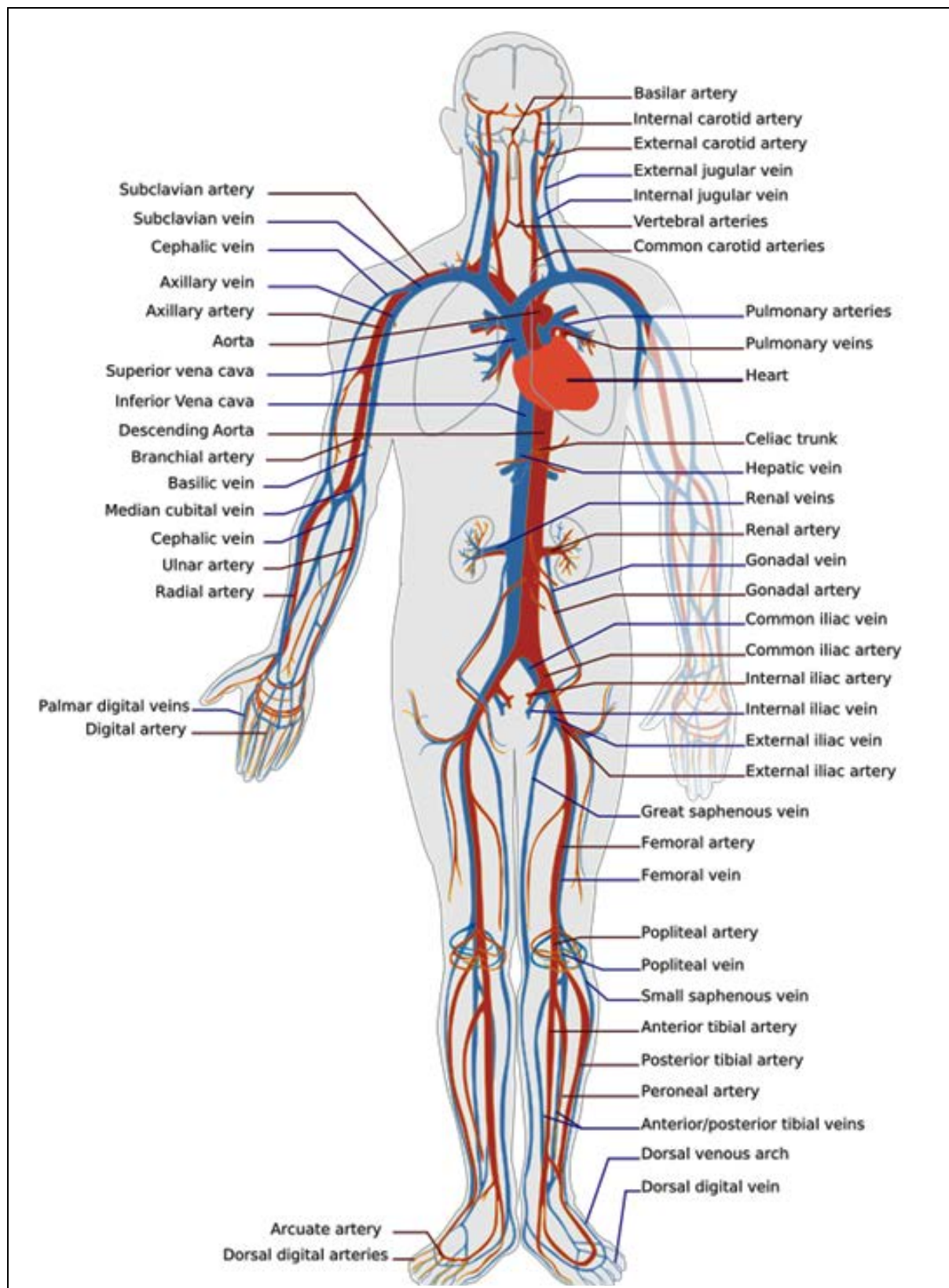


Fig. 18.14. Circulatory System

[http://commons.wikimedia.org/wiki/File:Circulatory\\_System\\_en.svg](http://commons.wikimedia.org/wiki/File:Circulatory_System_en.svg)

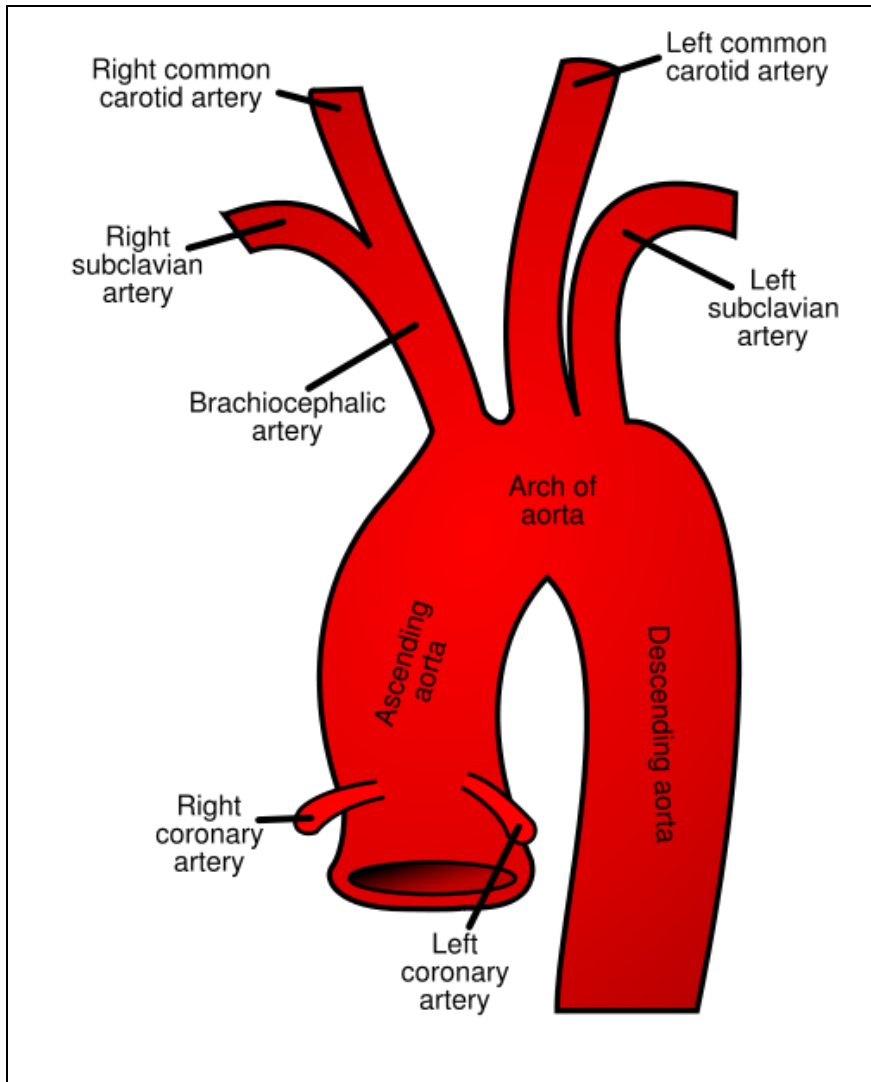


Figure 18.15. Aorta

<http://commons.wikimedia.org/wiki/File:Gray506.svg>

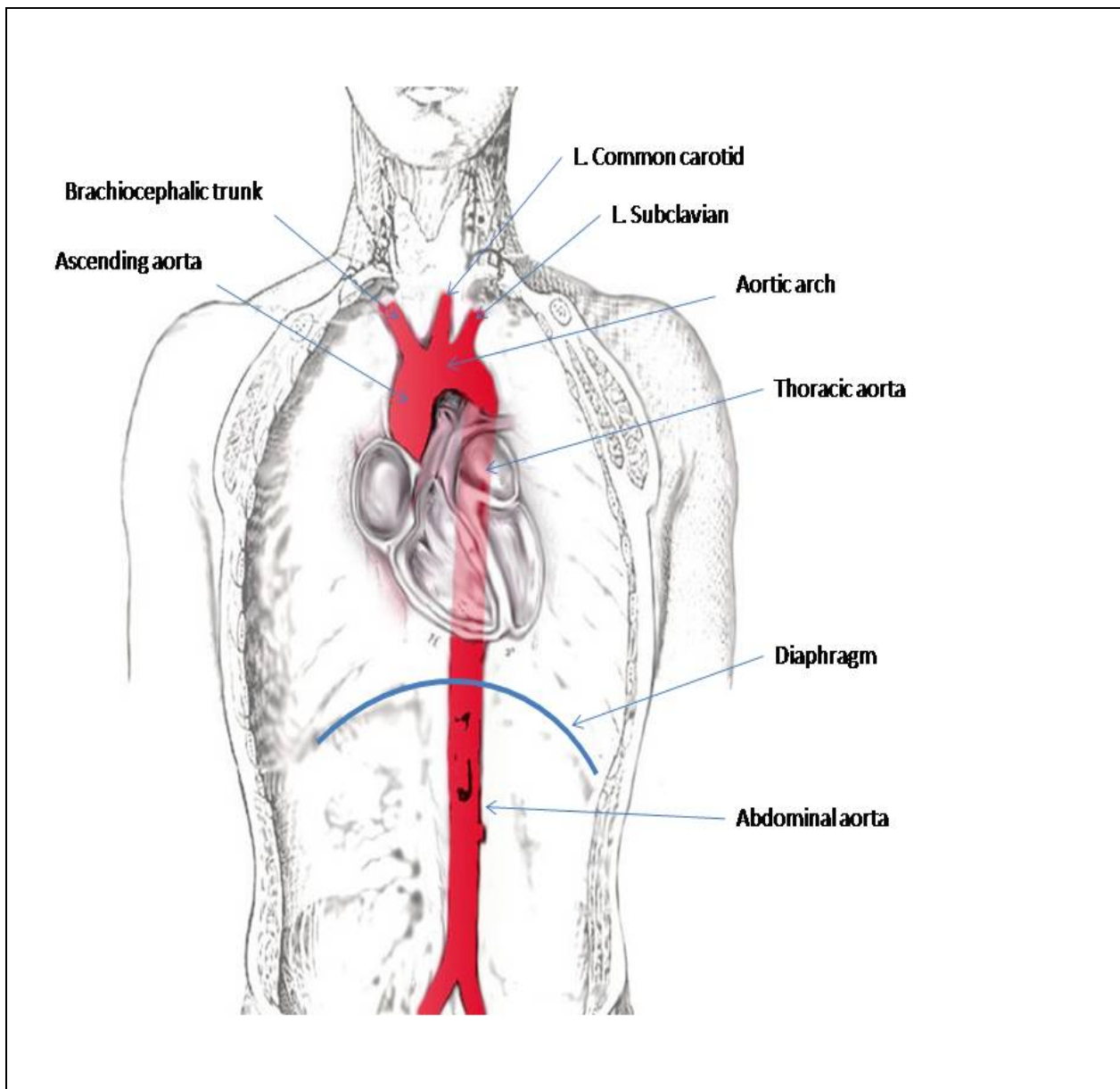


Figure 18.16. Aorta.

Modified by Dr. Bruce Forciea from:

[http://commons.wikimedia.org/wiki/File:Aorta\\_scheme.jpg](http://commons.wikimedia.org/wiki/File:Aorta_scheme.jpg)

Original image Author: J. Heuser



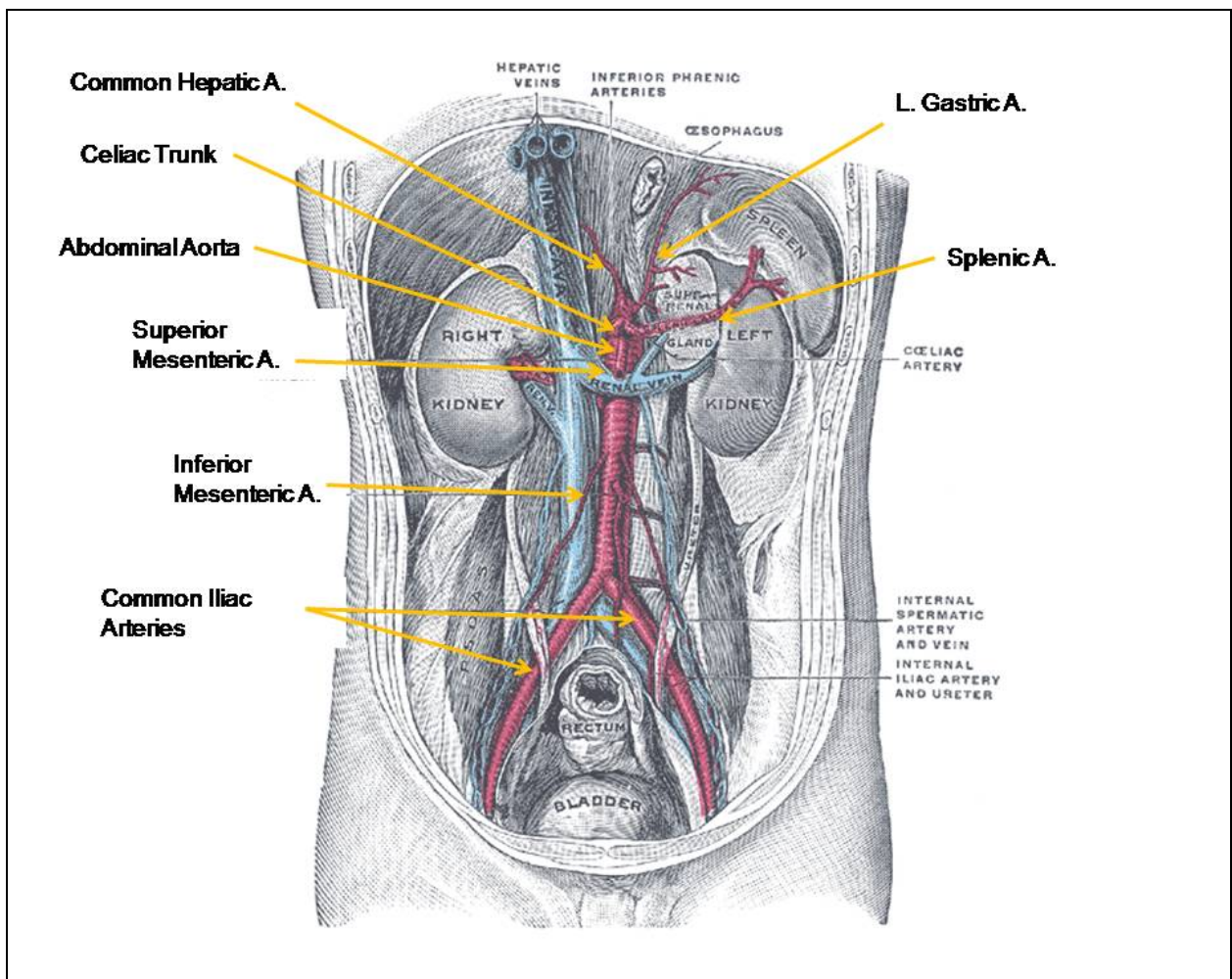


Figure 18.17. Abdominal aorta.

Modified by Dr. Bruce Forciea from:

<http://commons.wikimedia.org/wiki/File:Gray1121.png>

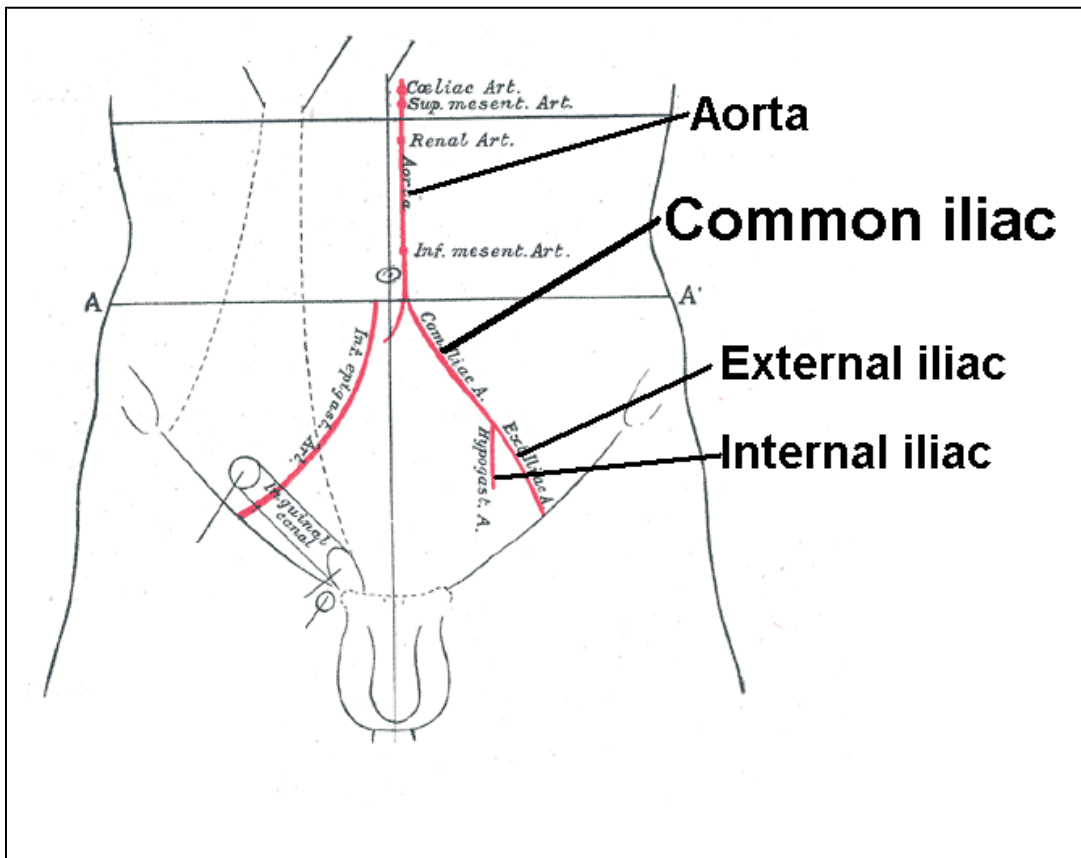


Figure 18.18. Common iliac arteries

[http://commons.wikimedia.org/wiki/File:Iliac\\_artery\\_bifurcation\\_and\\_aorta.PNG](http://commons.wikimedia.org/wiki/File:Iliac_artery_bifurcation_and_aorta.PNG)



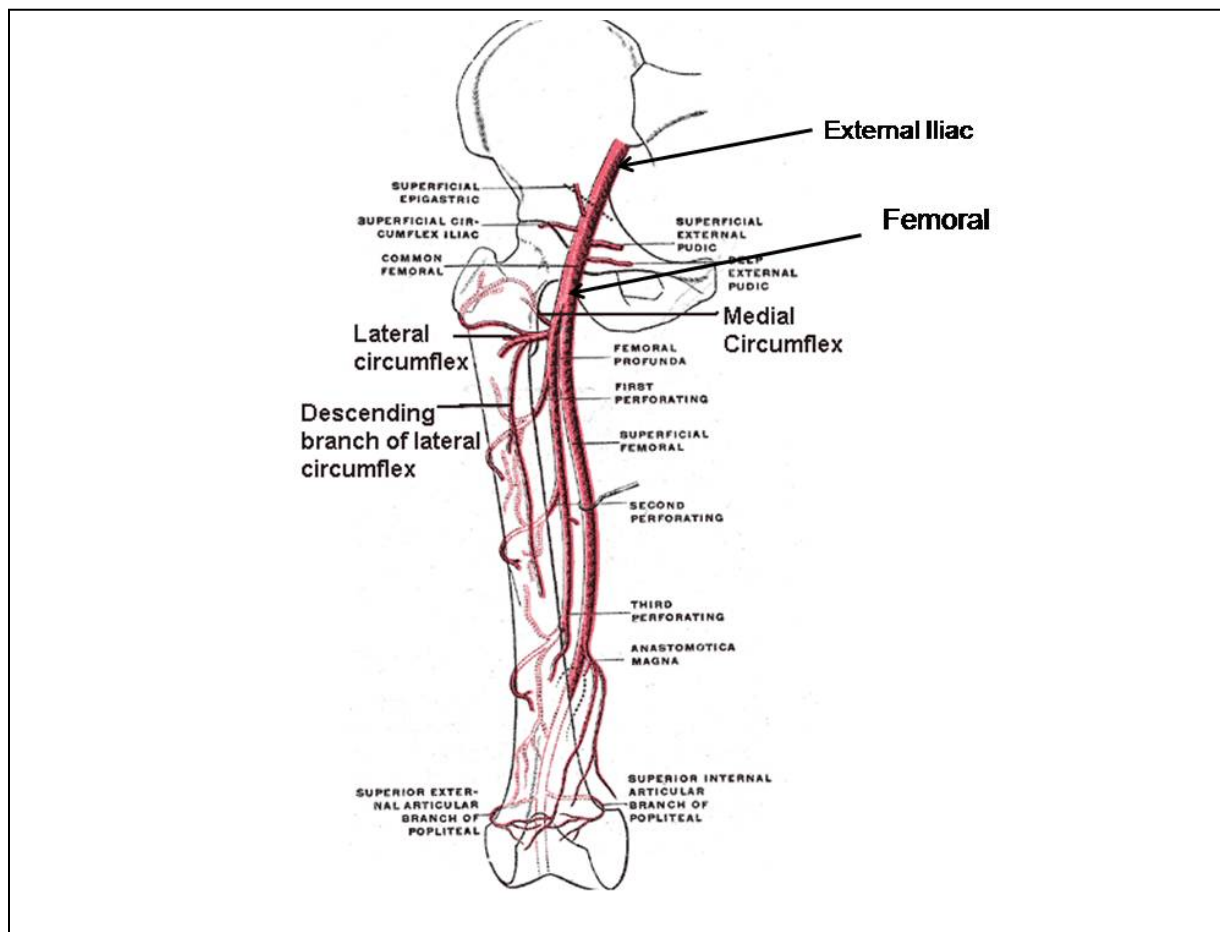


Figure 18.19. Femoral artery

[http://commons.wikimedia.org/wiki/File:Circumflex\\_femoral\\_arteries.png](http://commons.wikimedia.org/wiki/File:Circumflex_femoral_arteries.png)

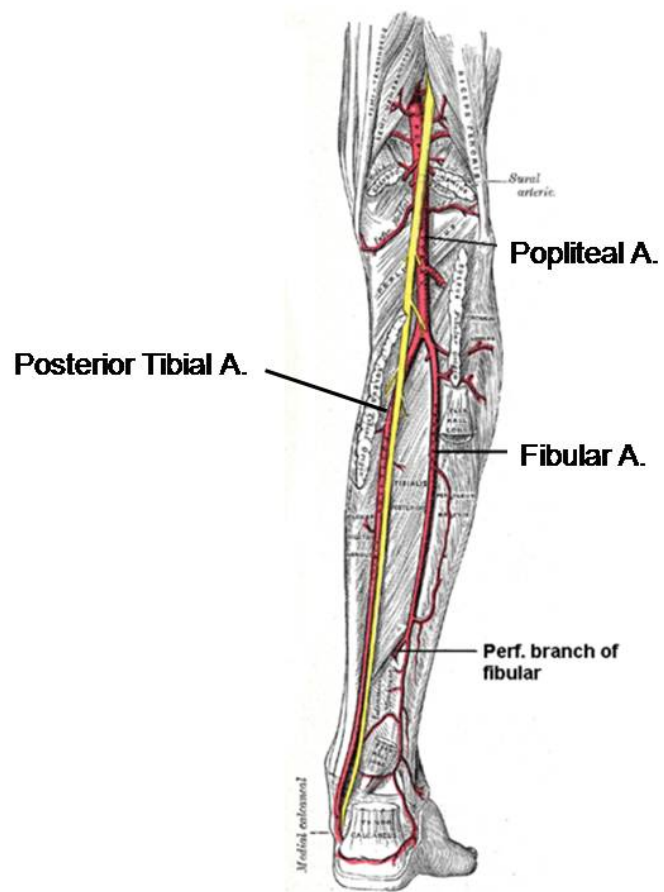


Figure 18.20. Posterior Tibial Artery

[http://commons.wikimedia.org/wiki/File:Fibular\\_artery.png](http://commons.wikimedia.org/wiki/File:Fibular_artery.png)

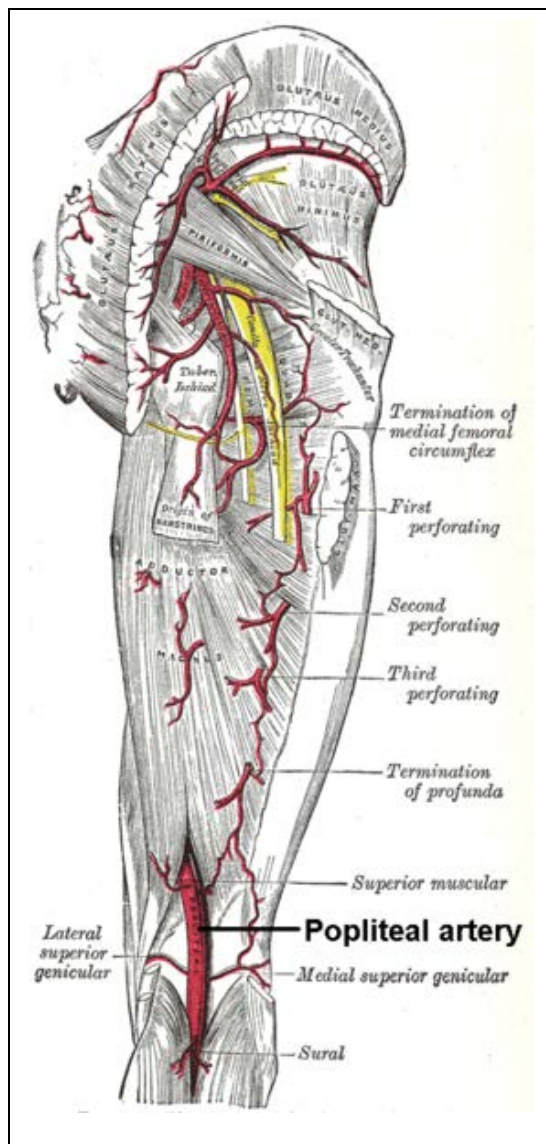


Figure 18.21. Popliteal artery

[http://commons.wikimedia.org/wiki/File:Popliteal\\_artery.png](http://commons.wikimedia.org/wiki/File:Popliteal_artery.png)

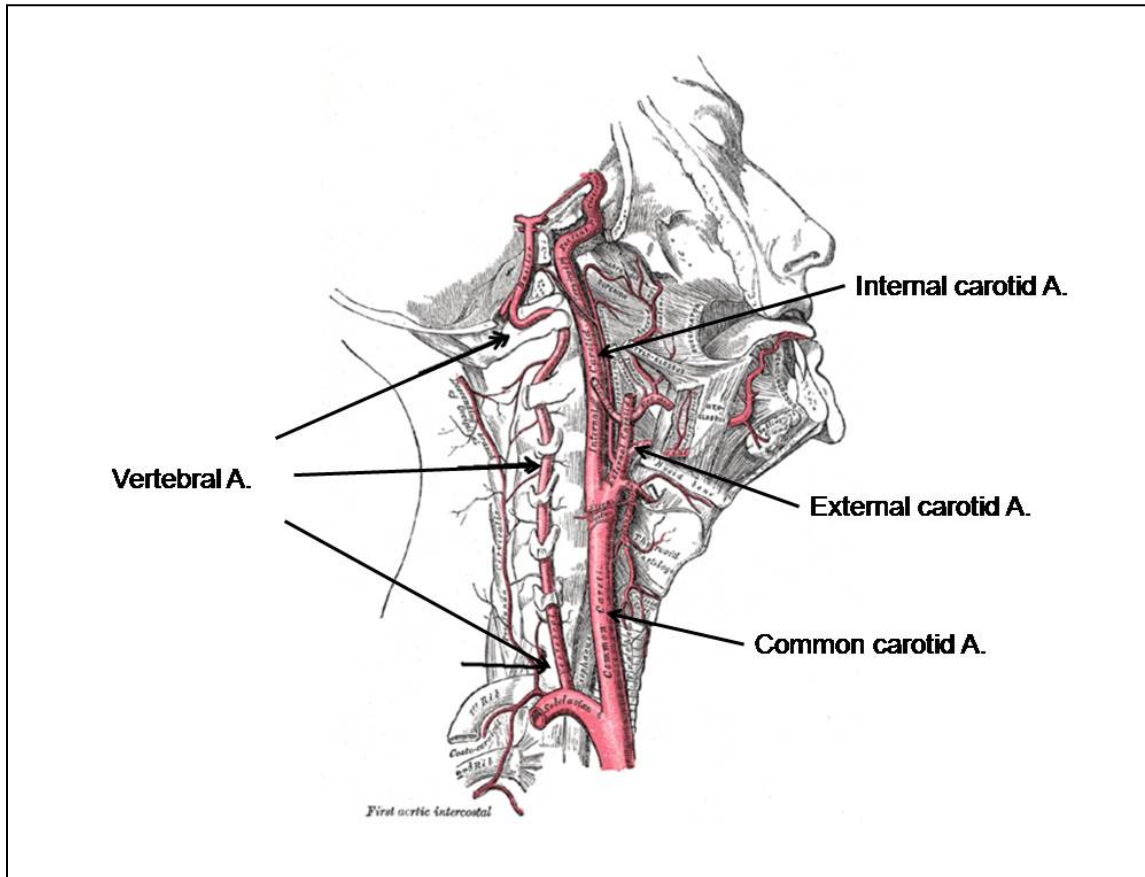


Figure 18.22. Arteries of the Head

[http://commons.wikimedia.org/wiki/File:Vertebral\\_artery.png](http://commons.wikimedia.org/wiki/File:Vertebral_artery.png)

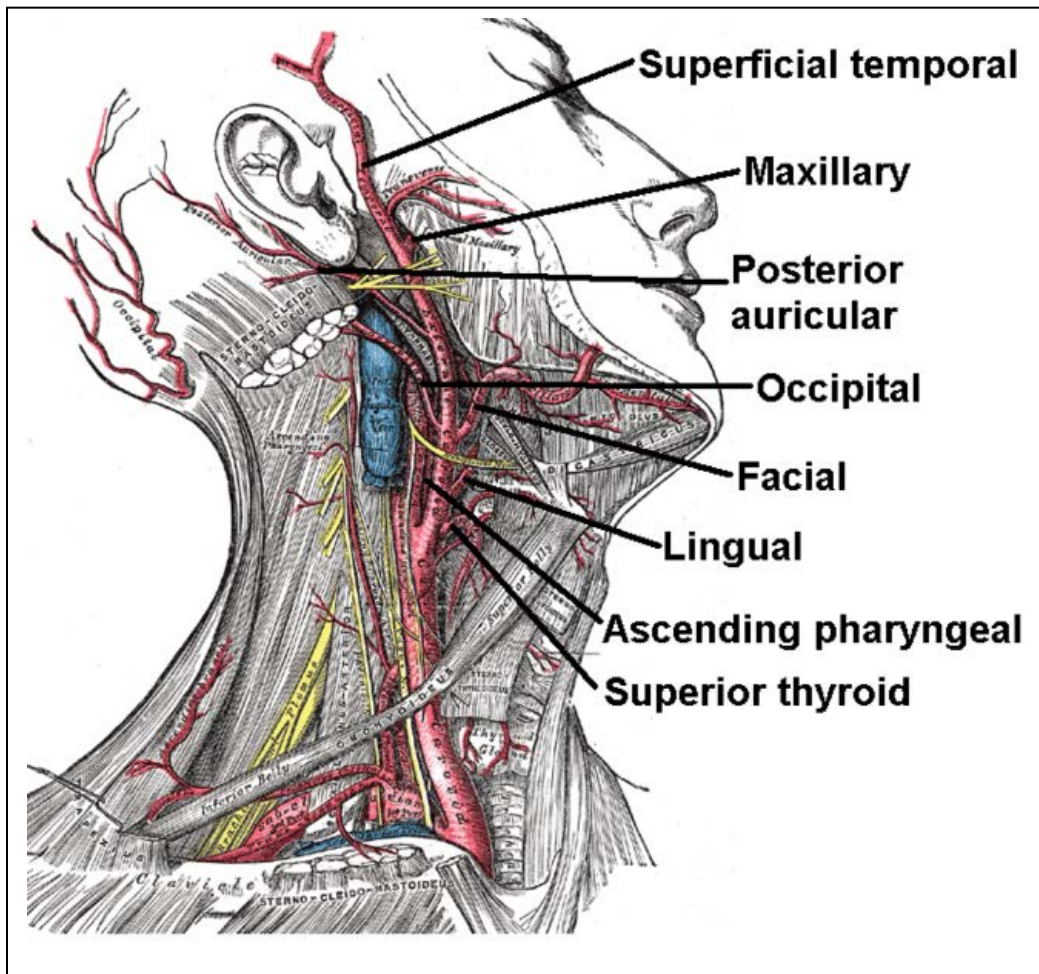


Figure 18.23. Branches of the external carotid artery.

[http://commons.wikimedia.org/wiki/File:External\\_carotid\\_artery.png](http://commons.wikimedia.org/wiki/File:External_carotid_artery.png)

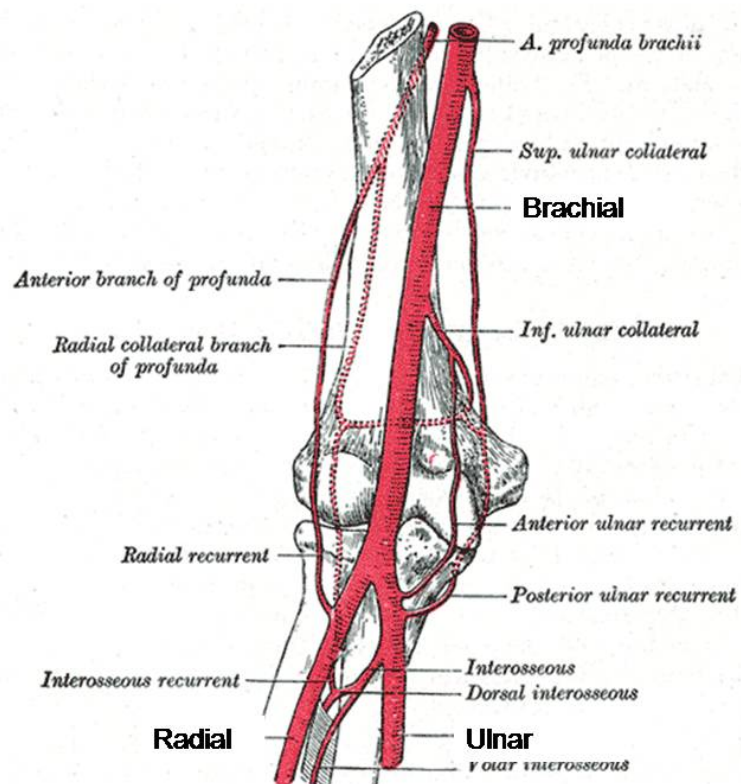


Figure 18.24. Brachial artery.

[http://commons.wikimedia.org/wiki/File:Brachial\\_a.gif](http://commons.wikimedia.org/wiki/File:Brachial_a.gif)

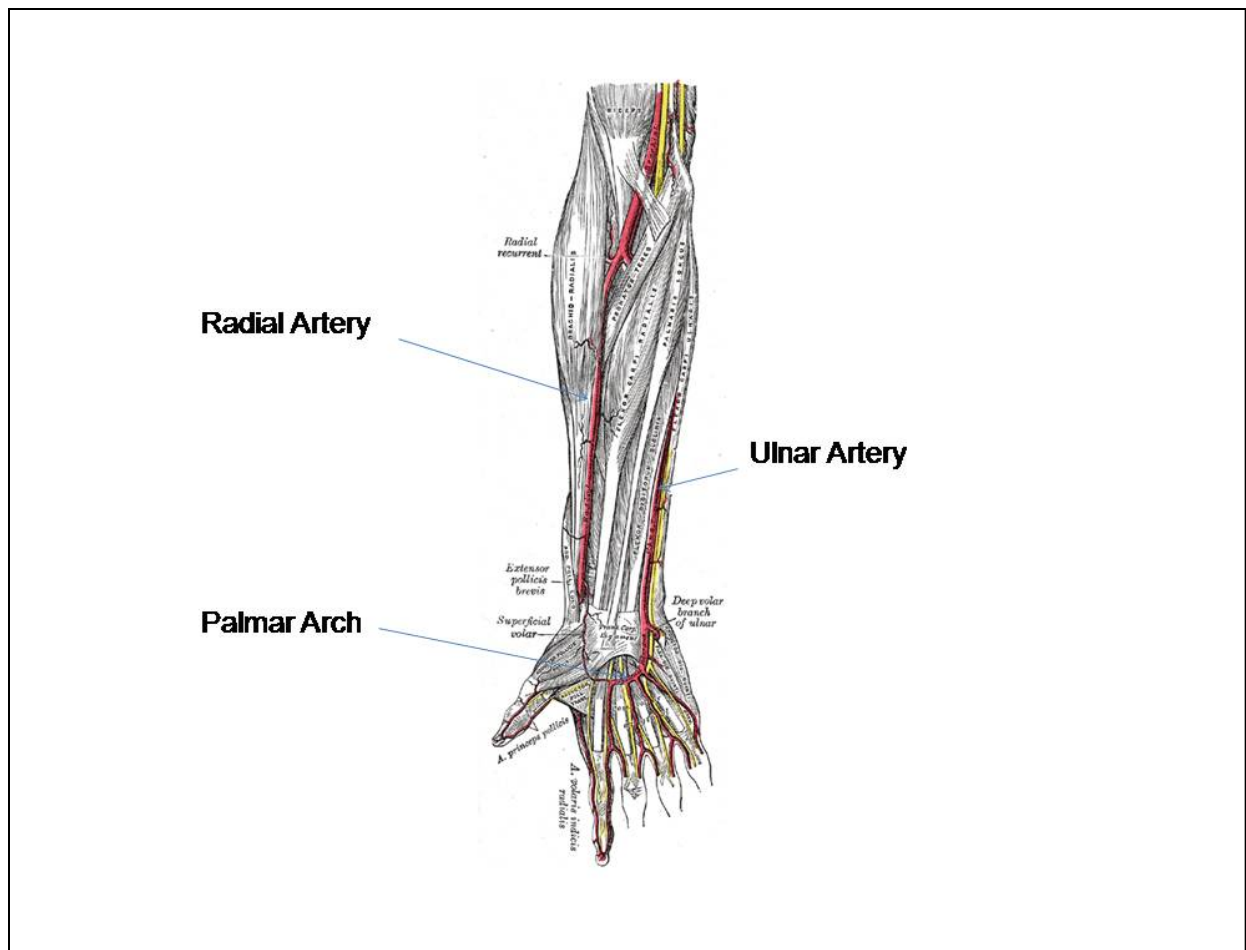


Figure 18.25. Arteries of the forearm.

<http://upload.wikimedia.org/wikipedia/commons/f/f2/Gray527.png>



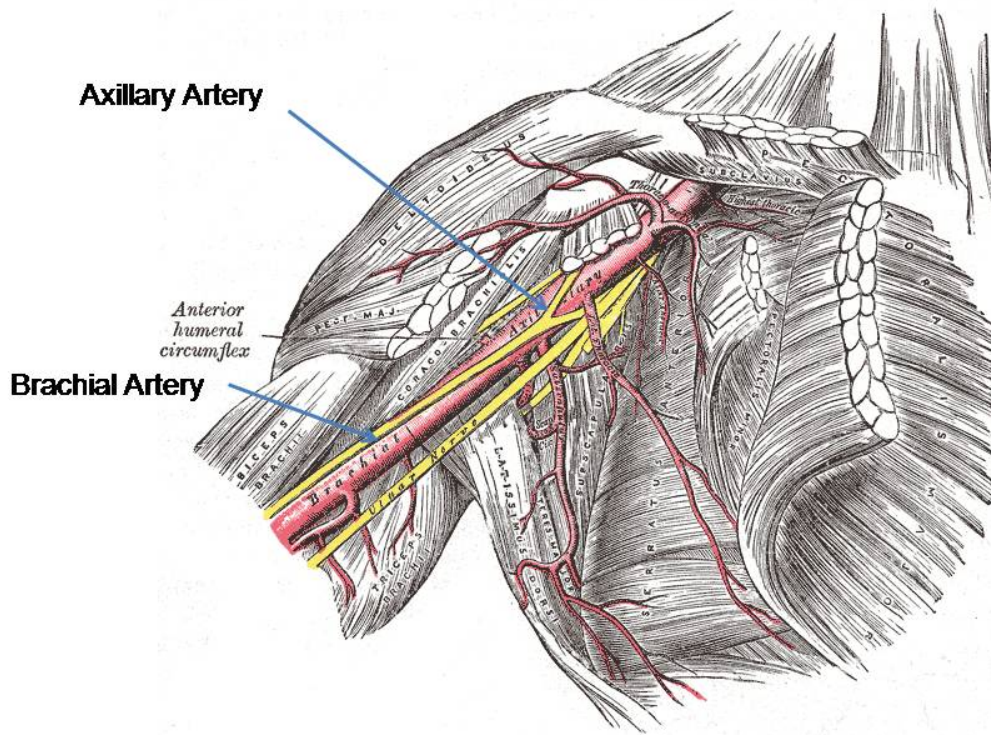


Figure 18.26. Axillary and Brachial Arteries.

<http://commons.wikimedia.org/wiki/File:Gray523.png>





## **Veins of the Systemic Circuit (Fig. 18.14, 18.28)**

The veins of the systemic circuit drain into the superior and inferior vena cavae that connect with the right atrium of the heart. The superior vena cava is formed by the union of the right and left brachiocephalic veins. Each brachiocephalic vein is formed by two branches including the subclavian and jugular veins. The subclavian veins drain the veins of the head and neck. The subclavian drains the shoulder and upper extremity.

## **Veins of the Upper Extremity**

Following the subclavian vein laterally we see that it makes connections with two superficial veins and one deep vein in the upper extremity. The superficial veins are the cephalic vein laterally and the basilic vein medially. Both of these veins extend to the distal upper extremity. The deep vein is the axillary vein which is a continuation of the subclavian vein as it emerges from the inferior aspect of the clavicle. The axillary vein then becomes the brachial vein which divides into radial and ulnar veins. Like the arteries of the upper extremities the radial and ulnar veins also connect at the deep palmar arch. The median cubital vein resides in the anterior portion of the elbow and connects with the cephalic and basilic veins. The cephalic and basilic veins both connect at the superficial palmar arch. The median antebrachial vein is located in the forearm area and connects the radial and ulnar veins.

## **Veins of the Head and Neck**

The head and neck are drained by the internal and external jugular veins, and the vertebral veins. The drainage begins with the dural sinuses. The dural sinuses are located in the dura mater of the brain. The superior and inferior dural sinuses are located in the falx cerebri. The inferior sagittal sinus located deep between the two hemispheres drains into the straight sinus. The superior sagittal and straight sinuses in turn drain into the transverse sinuses. These drain into the sigmoid sinuses which are continuous with the internal jugular vein. The cavernous sinuses drain the ophthalmic veins and also connect with the internal jugular vein.

The internal jugular veins exit the brain at the jugular foramen. As they proceed inferiorly to the subclavian they receive blood from the superficial temporal and facial veins.

The external jugular vein is a superficial vein of the head that drains the superficial structures of the face and head. They drain into the subclavian veins. The vertebral veins drain the area around the cervical vertebrae. This is unlike the vertebral arteries that supply a good deal of the brain with oxygenated blood.

## **Veins of the Thorax**

The Azygos vein originates from the right ascending lumbar vein and right posterior intercostals vein. The Azygos vein is not a paired vein and runs along the right side of the thoracic vertebrae. It empties into the superior vena cava.

The Hemiazygos vein lies on the left side of the vertebral column and originates from the posterior intercostals and left ascending lumbar veins. A continuation of the Hemiazygos vein is the Accessory Hemiazygos vein which extends superiorly.

### **Veins of the Abdomen and Lower Extremity**

The veins of the abdomen and lower extremity drain into the inferior vena cava.

Deoxygenated but nutrient rich blood from the digestive system empties into the hepatic portal system. This blood flows to the liver which extracts the nutrients for use in metabolism. The veins that drain into the hepatic portal vein have the same names as the arteries in the digestive system. These include the superior mesenteric, inferior mesenteric, and splenic veins.

A series of lumbar veins are located in the posterior abdominal wall and drain into the inferior vena cava and the ascending lumbar veins. The gonadal veins drain the testes and ovaries. The right gonadal vein drains into the inferior vena cava while the left gonadal vein empties into the left renal vein. The renal veins drain the kidneys.

The hepatic veins drain blood from the liver to the inferior vena cava. The cystic veins drain the gallbladder and connect with the hepatic veins and the inferior phrenic veins drain the diaphragm.

A number of veins of the lower extremity originate from the medial and lateral plantar veins which drain into the posterior tibial vein. The fibular or peroneal vein drains into the posterior tibial vein. The dorsalis pedis vein at the ankle becomes the anterior tibial vein which becomes the popliteal vein at the posterior knee.

The popliteal vein ascends into the thigh region and becomes the femoral vein. The femoral vein becomes the external iliac vein that combines with the internal iliac vein to become the common iliac vein that unites with the inferior vena cava.

The superficial dorsal venous arch of the foot becomes the great saphenous vein, which is a long superficial vein located on the medial side of the leg that connects with the external iliac vein. The small saphenous vein also originates from the dorsal venous arch and courses more laterally before connecting with the great saphenous vein.

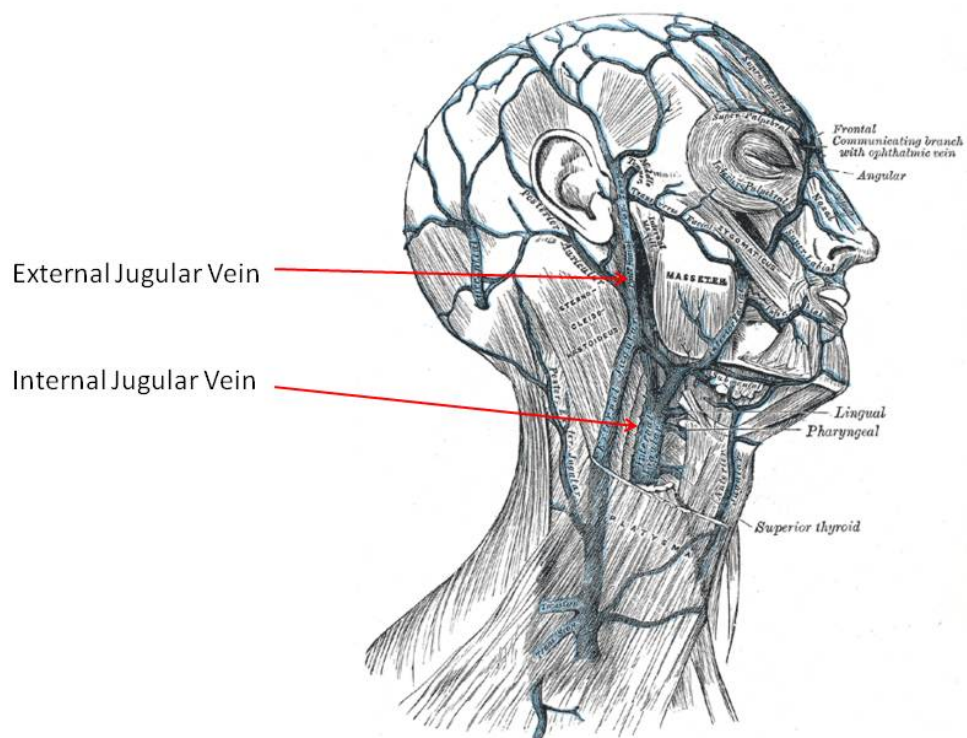


Figure 18.28. Jugular veins.

<http://commons.wikimedia.org/wiki/File:Gray557.png>

## Chapter 18 Review Questions

1. The heart contains \_\_\_\_ valves:
  - a. 2
  - b. 3
  - c. 4
  - d. 6
  
2. Blood flows from \_\_\_\_ to \_\_\_\_ through the heart:
  - a. Right atrium, pulmonary trunk
  - b. Left ventricle, superior vena cava
  - c. Right ventricle, pulmonary trunk
  - d. Left atrium, right atrium
  
3. Which of the following is a branch of the left coronary artery:
  - a. Posterior interventricular
  - b. Circumflex
  - c. Brachiocephalic
  - d. Common carotid
  
4. Which of the following is the thickest layer of the heart:
  - a. Epicardium
  - b. Myocardium
  - c. Endocardium
  - d. Pericardium
  
5. When the atria are in systole and ventricles in diastole the \_\_\_\_ valves are open and the \_\_\_\_ valves closed:
  - a. Bicuspid/tricuspid, aortic/pulmonary
  - b. Aortic/pulmonary, bicuspid/tricuspid
  - c. Bicuspid/ aortic, tricuspid/pulmonary
  - d. Tricuspid/aortic, bicuspid/pulmonary

6. How much blood passively flows into the heart during the rest phase of the cardiac cycle:
- 50%
  - 60%
  - 70%
  - 80%
7. Which of the following contributes to the S2 heart sound:
- Bicuspid valve
  - Aortic valve
  - Tricuspid valve
  - Rapid ventricular filling
8. Which of the following is not a difference between arteries and veins:
- Thick tunica media
  - Valves
  - Blood flow direction
  - 3 layers
9. Which of the following is not a branch off of the aorta:
- Brachiocephalic
  - Jugular
  - Common carotid
  - Subclavian
10. The common carotid artery divides into which arteries:
- Internal and external carotids
  - Medial and lateral carotids
  - Inferior and superior carotids
  - External and internal jugulars
11. As the subclavian artery emerges from beneath the clavicle it becomes:
- Brachial
  - Cephalic
  - Axillary
  - Basilica
12. Which of the following is a lateral superficial vein of the arm:
- Basilic
  - Great saphenous
  - Cephalic
  - Brachial

13. Which branch becomes the femoral artery:

- a. Internal iliac
- b. External iliac
- c. Pudendal
- d. Common iliac

14. Which of the following is a superficial vein of the leg:

- a. Jugular
- b. Basilic
- c. Great saphenous
- d. Femoral

15. When the thoracic aorta descends below the diaphragm it becomes:

- a. Inguinal
- b. Common iliac
- c. Abdominal
- d. Femoral

# Chapter 19

## Cardiovascular System Physiology



## Cardiovascular System Physiology

The cardiovascular system maintains the flow of oxygenated blood to the tissues by adjusting pressure throughout the system. In this section we will investigate how the cardiovascular system produces and maintains blood pressure in a variety of circumstances.

### Cardiac Muscle

We covered some characteristics of cardiac muscle in the tissue chapter. You may recall that cardiac muscle is very similar to skeletal muscle. It consists of long red cells containing densely packed actin and myosin protein filaments which give it a striated appearance. Cardiac muscle cells only contain one nucleus while their muscle counterparts are multinucleated. Cardiac muscle also contains a specialized cell junction called an intercalated disc. Intercalated discs help to transmit action potentials from cell to cell in order to produce a more ordered contraction of large areas of muscle tissue.

Cardiac muscle contraction physiology is also very similar to skeletal muscle. Depolarization of cardiac muscle cells causes the release of calcium. Calcium in turn binds to troponin surrounding actin causing it to move and expose myosin binding sites. Myosin and actin connect and slide past each other powered by ATP.

Cardiac muscle has a resting membrane potential of about  $-90\text{mV}$ . The threshold for a typical ventricular muscle cell is about  $-75\text{mV}$ . An action potential that reaches the threshold causes rapid depolarization and movement of sodium inside the cell. This changes the membrane potential to  $+30\text{mV}$  at which the sodium channels close. The sodium channels are known as fast channels because of their quick reaction to stimuli. Once the membrane reaches  $+30\text{mV}$  slow calcium channels open in order to maintain the transmembrane potential at about  $0\text{mV}$ . The slow calcium channels react slowly to stimuli and remain open for longer periods of time (about 175 milliseconds). At the end of their cycle the calcium channels close and slow potassium channels open allowing the diffusion of potassium ions out of the cell. The cells then repolarizes back to the resting membrane potential (fig. 19.1).

Cardiac muscle cells also exhibit relative and absolute refractory periods much like skeletal muscle cells. During the absolute refractory period the membrane cannot respond to stimuli. This is due to the sodium channels being open. The absolute refractory period in ventricular muscle cells is about 200 milliseconds. This is followed by a relative refractory period in which a strong stimulus can produce an action potential. The relative refractive period is characterized by closed sodium channels that can open. The relative refractive period lasts for about 30 ms.

Cardiac muscle contraction like skeletal muscle relies on the influx of calcium. In cardiac muscle there are two sources of calcium. These include the influx of calcium from slow calcium channels as mentioned above and the calcium stored in the sarcoplasmic reticulum. The long action potential in cardiac muscle also allows it to continue contraction until relaxation occurs. There is no summation in cardiac muscle. This prevents cardiac muscle cells from undergoing tetanic contractions.

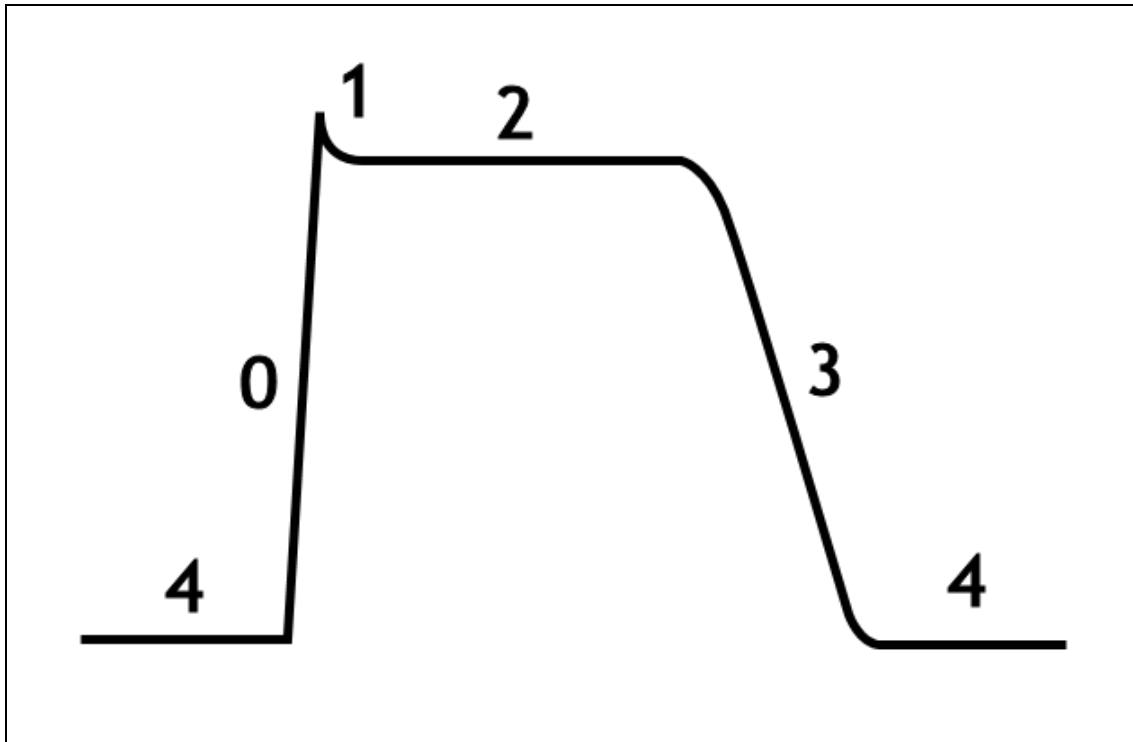


Figure 19.1. Action potential in cardiac muscle. 0. Rapid depolarization produced by opening of fast sodium channels. 1. Maximum depolarization to +30mV. 2. Plateau produced by slow calcium channels. 3. Repolarization produced by slow potassium channels. 4. Resting membrane potential of -90mV.

[http://commons.wikimedia.org/wiki/File:Action\\_potential.png](http://commons.wikimedia.org/wiki/File:Action_potential.png)

## The Cardiac Conducting System

Cardiac muscle tissue is capable of contracting on its own without stimulation from the nervous or endocrine systems. This phenomenon is known as automaticity. Automaticity occurs because of specialized cells that produce action potentials.

In a normal heartbeat conduction begins with an area of special cells called pacemaker cells in the posterior wall of the right atrium. This area is known as the sinoatrial (SA) node. It is sometimes referred to as the pacemaker node. The pacemaker cells cannot maintain a normal resting membrane potential but cycle from depolarization to repolarization. The SA node can generate action potentials automatically at a rate of 60-100 beats per minute.

The impulse from the SA node is transferred by an intermodal pathway consisting of conducting cells to the atrioventricular (AV) node located in the floor of the right atrium. The impulse is delayed about 100 ms as it passes through the AV node. This allows for the completion of atrial contraction before the beginning of ventricular contraction. The AV node is also capable of producing action potential on its

own at a rate of 40-60 bpm. If for some reason the SA node becomes damaged the AV node will cause the heart to contract at 40-60 bpm. The AV node can conduct impulses at a maximum rate of 230 bpm. The heart begins to decrease its pumping efficiency at about 180 bpm. The heart cannot produce rates greater than 230 bpm unless it is damaged. The maximal rate of ventricular contraction is about 300-400 bpm. However contractions at these rates are very inefficient (fig. 19.2).

The impulse from the AV node travels to the atrioventricular (AV) bundle or Bundle of His. These cells are also capable of producing action potentials at a rate of 20-40 bpm. The AV bundle connects the atria and ventricles. The AV bundle sends impulses to the right and left bundle branches. The branches extend to the apex of the heart and distribute impulses to the ventricles via Purkinje fibers and to the papillary muscles via moderator bands. This distribution of impulses allows for contraction of the papillary muscles before the ventricles. This allows for tensioning of the chordae tendoneae of the atrioventricular valves to help prevent backflow of blood to the atria. Purkinje fibers are fast conducting cells and allow for even emptying of the ventricles.

Damage to the heart can manifest in what is known as an ectopic pacemaker. This is an area of tissue that generates abnormal impulses that bypass the normal conducting system. Ectopic pacemakers can disrupt normal ventricular contraction and produce dangerous arrhythmias.

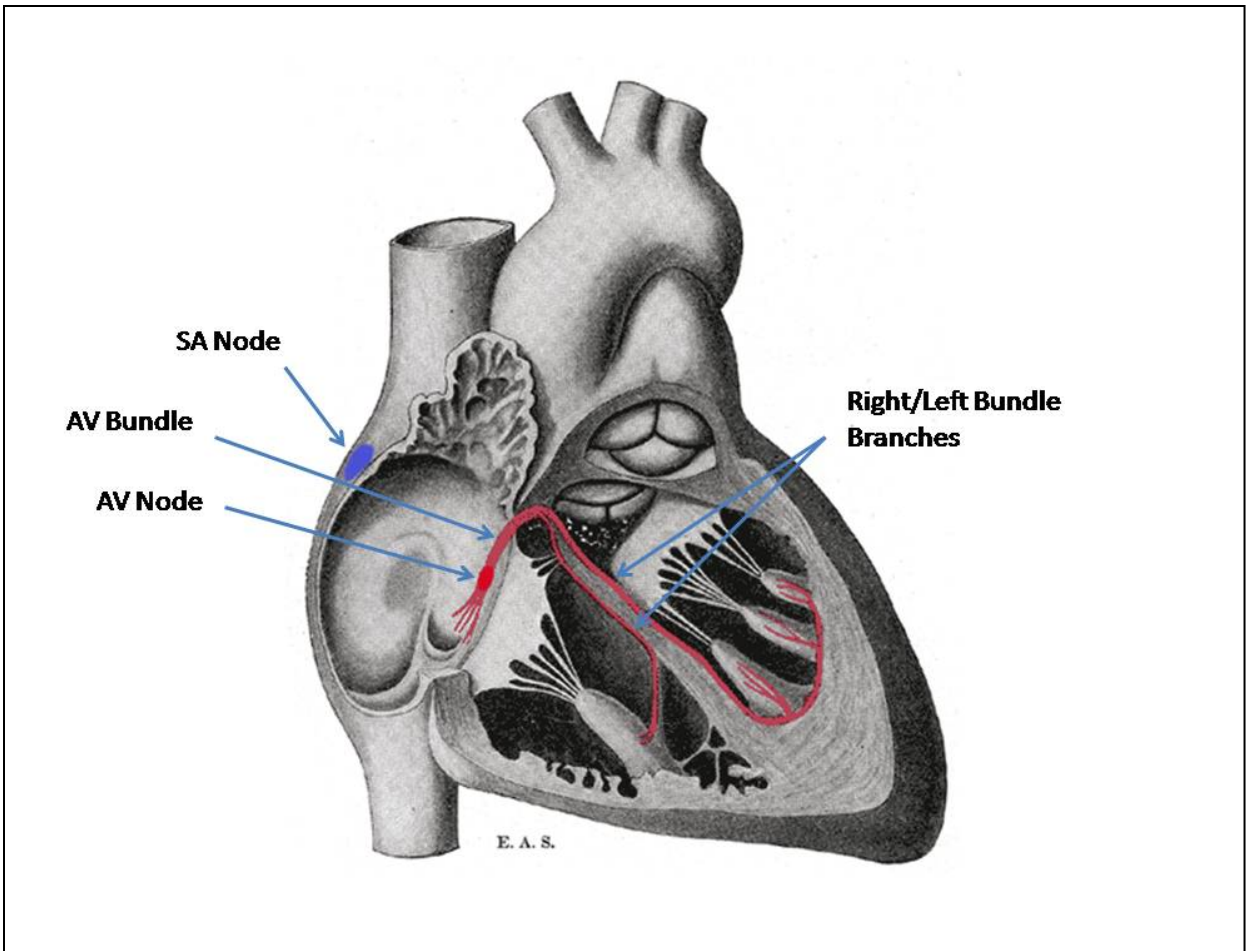


Figure 19.2. Cardiac conduction system.

<http://commons.wikimedia.org/wiki/File:Bundleofhis.png>

Labelled by Bruce Forciea

## The Electrocardiogram

The heart generates significant electrical impulses that can be measured. Devices that measure the heart's electrical impulses produce a recording called an electrocardiogram or ECG (sometimes called an EKG) (fig. 19.3). The information from an ECG can be used to determine problems with conduction, nodes, or contraction of the heart. There are a variety of locations of electrodes that produce different views of the impulses. We will examine a standard ECG view.

The electrical impulses in an ECG produce waves which are a summation of electrical impulses in a given time frame. The P wave is the first wave seen in an ECG and represents atrial depolarization. Atrial depolarization occurs just before atrial contraction (atria contract about 25 ms after the beginning of the P wave).

The P wave is followed by the QRS complex. The QRS complex represents ventricular depolarization. Atrial repolarization is also occurring during this time but is overshadowed by the powerful ventricular signal. The T wave follows the QRS complex and results from ventricular repolarization.

Some common measurements include the P-R interval and the Q-T interval. The P-R interval extends from the beginning of the P wave to the beginning of the QRS complex. A prolonged P-R interval can indicate a conduction problem. The Q-T interval extends from the end of the P-R interval to the end of the T wave. The Q-T interval represents ventricular systole. A prolonged Q-T interval can indicate heart damage or electrolyte problems (figs. 19.4-19.7).

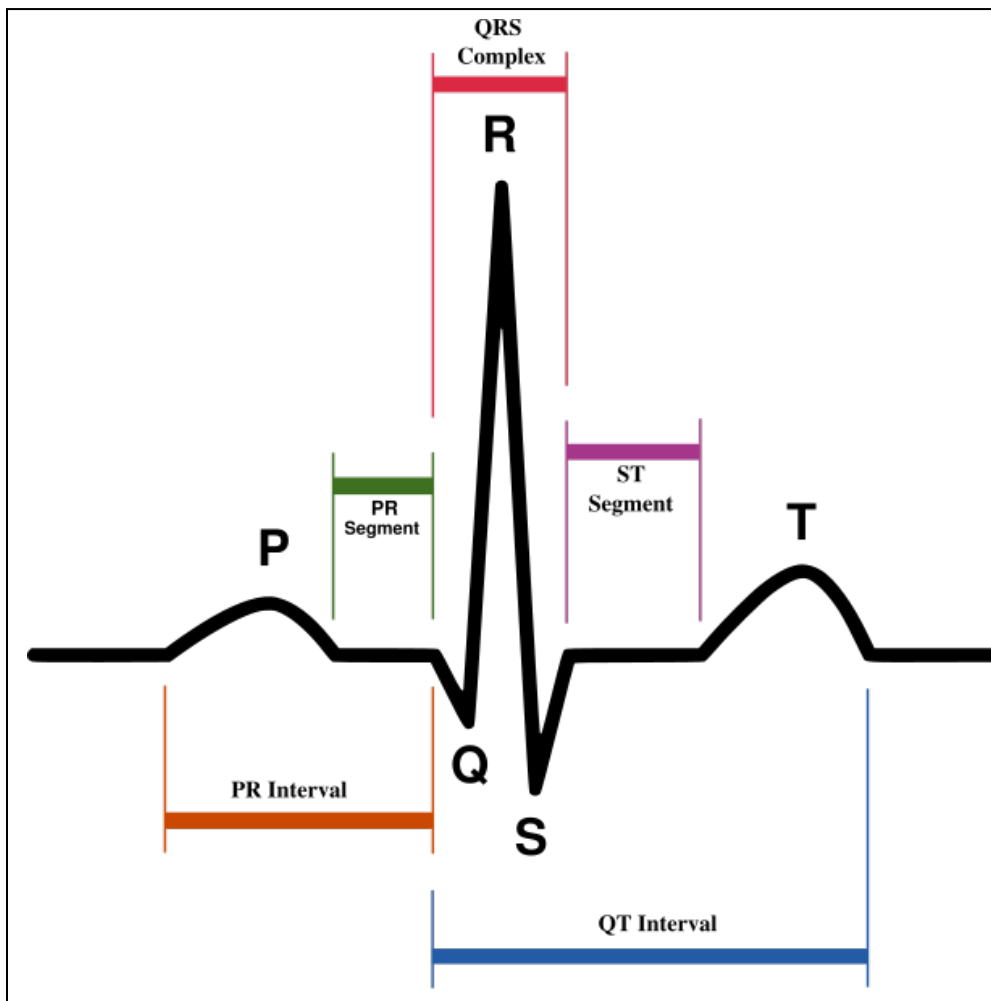


Figure 19.3. ECG

<http://commons.wikimedia.org/wiki/File:SinusRhythmLabels.svg>

Created by [Agateller \(Anthony Atkielski\)](#), converted to svg by [atom](#).

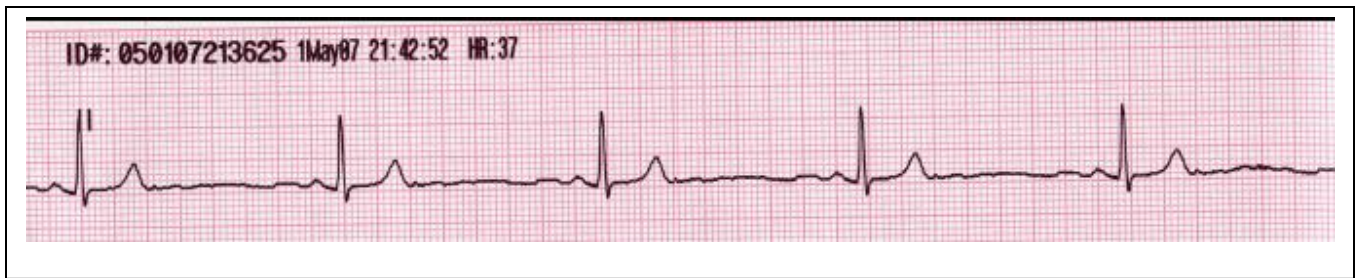

Figure 19.4. Sinus bradycardia. Note the long interval between beats.

[http://commons.wikimedia.org/wiki/File:Lead\\_II\\_rhythm\\_generated\\_sinus\\_bradycardia.JPG](http://commons.wikimedia.org/wiki/File:Lead_II_rhythm_generated_sinus_bradycardia.JPG)

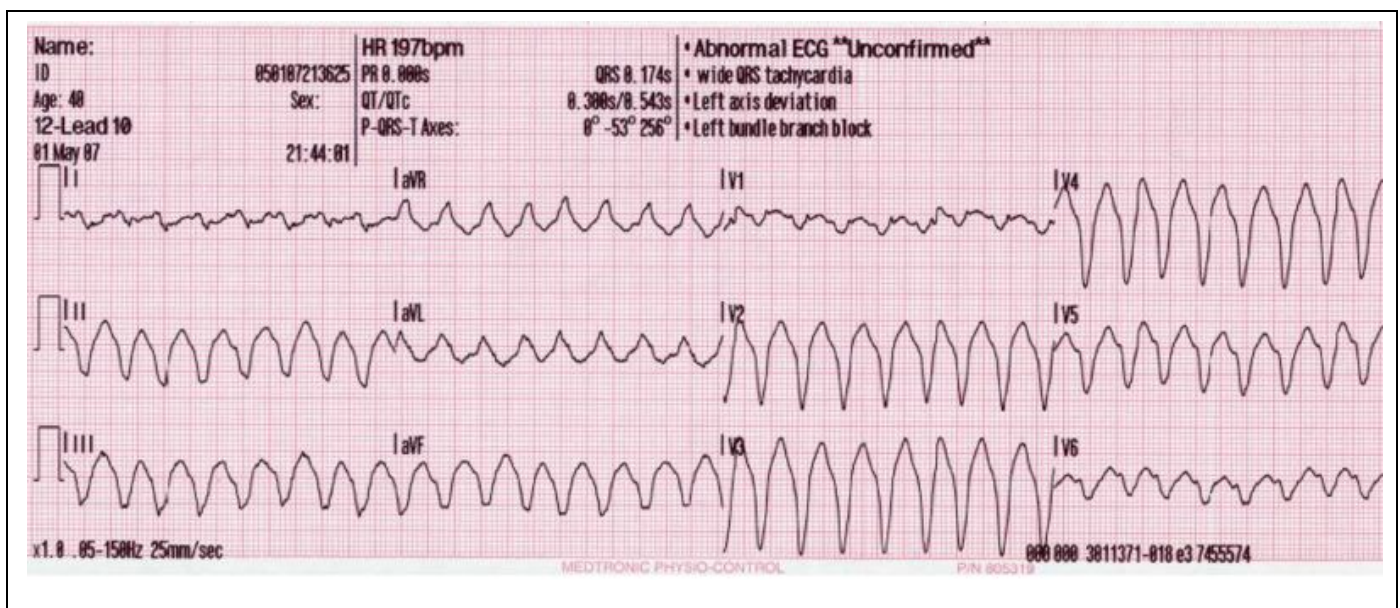


Figure 19.5. Ventricular tachycardia.

[http://commons.wikimedia.org/wiki/File:12\\_lead\\_generated\\_ventricular\\_tachycardia.JPG](http://commons.wikimedia.org/wiki/File:12_lead_generated_ventricular_tachycardia.JPG)



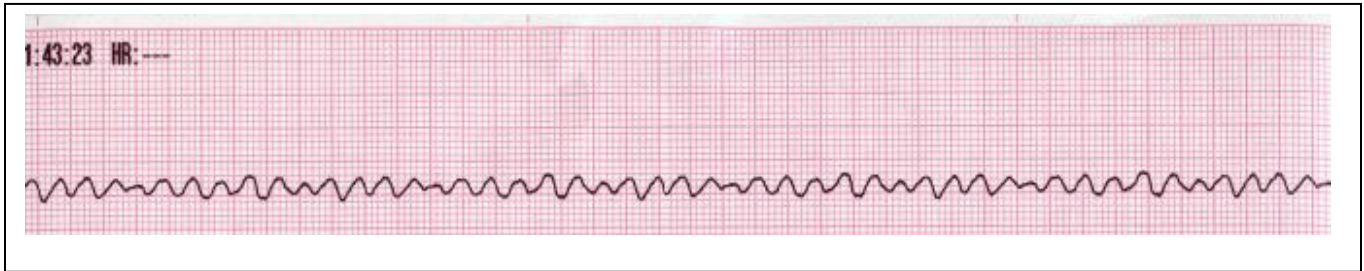

Figure 19.6. Ventricular fibrillation. There is no organized contraction with this arrhythmia.

[http://commons.wikimedia.org/wiki/File:Lead\\_II\\_rhythm\\_generated\\_ventricular\\_fibrillation\\_VF.JPG](http://commons.wikimedia.org/wiki/File:Lead_II_rhythm_generated_ventricular_fibrillation_VF.JPG)

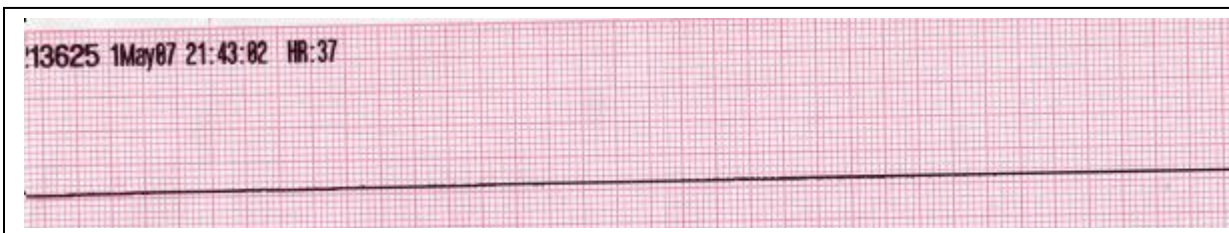

Figure 19.7. Asystole represents no contraction.

[http://commons.wikimedia.org/wiki/File:Lead\\_II\\_rhythm\\_generated\\_asystole.JPG](http://commons.wikimedia.org/wiki/File:Lead_II_rhythm_generated_asystole.JPG)

## Cardiac Output

The primary goal of the cardiovascular system is to maintain the flow of oxygenated blood to the tissues. In order to accomplish this task the heart must maintain what is known as a good cardiac output.

Cardiac output is the amount of blood pumped by each ventricle in one minute. It is a measure of ventricular efficiency. Cardiac output can be described by this equation:

$$CO = SV \times HR$$

CO = Cardiac output

SV = Stroke volume

HR = Heart rate

Stroke volume is the amount of blood ejected by a ventricle in one contraction. Heart rate is in beats per minute. Thus cardiac output is the amount of blood ejected by a ventricle in one minute. Generally SV is about 70-80ml. For example if HR is 70 bpm and SV is 80 ml then cardiac output is 5600 ml per minute or 5.6 L per minute.

Factors that influence SV and HR then will affect cardiac output. SV is affected by end diastolic volume (EDV) or the amount of blood in the ventricle just before contraction as well as end systolic volume (ESV) which is the amount of blood remaining in the ventricle after contraction (systole). SV can be calculated from EDV and ESV by the following:

$$SV = EDV - ESV$$

The following is an example to illustrate how cardiac output works to maintain blood flow. Let's say we have two patients. One is a highly trained endurance athlete; the other suffers from congestive heart failure. The athlete enters our office and you begin your cardiac assessment by taking her pulse. You record the resting pulse as 55 bpm. Your next patient enters the room and you also take his pulse and record it at 100 bpm. How is cardiac output responsible for the difference in the two pulses?

In both circumstances the heart is working to provide adequate amounts of oxygenated blood to the tissues. In other words the heart is working to maintain a good cardiac output. The athlete's stroke volume is high because of her athletic conditioning. Therefore the heart rate will be low in order to maintain good cardiac output. The CHF patient's stroke volume is much lower than the athlete's. Heart rate must then be higher in order to maintain cardiac output.

Starling's law of the heart relates stretch of the ventricular walls to stroke volume. The degree of stretch of the ventricular walls is called preload. An increase in preload results in an increase in stroke volume which, in turn, increases cardiac output. Stroke volume then is affected by venous return which can vary from 2L/min to about 24 L/min.

Other factors that affect cardiac output include neural and hormonal control mechanisms. We will explore these next.



## Nervous System Connections

We have examined how the heart beats on its own accord by generating impulses in the nodes. However heart rate must sometimes vary in order to meet the varying demands of the body. This control of heart rate comes from the nervous and endocrine systems. In fact the autonomic nervous system is constantly adjusting heart rate in order to maintain good blood pressure and flow of blood to the tissues.

The autonomic nervous system connects to the heart by means of the cardiac plexus. The cardiac plexus sends postganglionic sympathetic neurons to the SA and AV nodes and the atrial muscle cells. The postganglionic neurons are referred to as cardiac accelerator nerves and they originate in the cervical and upper thoracic paravertebral ganglia. The parasympathetic nervous system sends postganglionic neurons to the cardiac plexus via the Vagus nerve (CN X).

The autonomic nervous system impulses originate in the cardiac control centers in the medulla oblongata. There is a cardioacceleratory center and a cardioinhibitory center. The cardioacceleratory center controls the sympathetic pathway and increases heart rate while the cardioinhibitory center controls the parasympathetic pathway and decreases heart rate. The centers have input from higher cortical regions of the brain as well as the hypothalamus.

Sensory information about the cardiovascular system originates in baroreceptors and chemoreceptors. These receptors are innervated by the glossopharyngeal nerve (CN IX). The baroreceptors monitor changes in pressure while chemoreceptors monitor changes in blood levels of oxygen, carbon dioxide, and pH. An increase in carbon dioxide or decrease in blood pH will stimulate the sympathetic nervous system which will result in an increase in heart rate and force of contraction. Chemoreceptors in the carotid sinus and aortic body sense changes in oxygen concentration. A drop in oxygen levels causes vasoconstriction and a decrease in heart rate. This allows for movement of blood without an increase in oxygen use of the heart.

For example, when a subject rises from a supine to a sitting position there is a temporary drop in blood pressure in the head. This is sensed by baroreceptors in the carotid sinus. The sensory information travels via the glossopharyngeal nerve to the cardiac control centers to produce a subsequent increase in heart rate via the sympathetic pathway.

The sympathetic neurotransmitter released by the postganglionic neurons is norepinephrine (NE). NE binds to beta adrenergic receptors causing sodium and calcium channels to open. The resulting influx of sodium decreases the period of depolarization causing the threshold to be reached more quickly. This results in an increase in heart rate. Likewise the parasympathetic postganglionic neurons secrete acetylcholine (ACh) that causes potassium gates to open resulting in a longer time period for depolarization. This produces a slower heart rate.

The Bainbridge reflex (atrial reflex) occurs with an increase in stretch of the atrial walls. The reflex results in an increase in sympathetic activity and subsequent increase in heart rate.

NE and ACh have both neurotransmitter and hormonal action. NE and epinephrine are both secreted by the adrenal medulla. These hormones are secreted in response to stress and exercise. Thyroid hormone also has a similar action to NE and increases heart rate.

## Ischemic Response

The ischemic response or central nervous system ischemic response occurs with a decreased in blood flow to the medulla oblongata. The ischemic response occurs when blood pressure decreases to about 50 mm Hg. It produces systemic vasoconstriction in an effort to support blood flow. If ischemia continues then the vasomotor center will cease to function resulting in vasodilation and death.

## Blood Pressure Control

Blood pressure is a measure of the force on blood vessel walls. There are two numbers associated with blood pressure. The systolic pressure is the higher number and results from ventricular contraction. The diastolic pressure represents the pressure in the system during ventricular diastole.

Blood pressure can be measured with a stethoscope and a device called a sphygmomanometer. Typically the pressure in the brachial artery is measured. The examiner listens to (auscultates) the artery at the elbow while the cuff is squeezed above the elbow until the brachial artery collapses. The examiner then slowly releases the cuff and listens for Korotkoff sounds which are produced by turbulent blood flow. The first sound heard represents the systolic pressure. The cuff is loosened until turbulent flow ceases. The pressure at which the sounds disappear represents the diastolic blood pressure. The normal systolic pressure is around 120 mm of mercury. The normal diastolic pressure is around 80 mm Hg.

The difference between the systolic and diastolic pressures is called the pulse pressure. With a normal blood pressure of 120/80 the pulse pressure is 40 mm Hg. Stroke volume and vascular compliance both affect pulse pressure. When stroke volume decreases then so does pulse pressure. Likewise when vascular compliance decreases then pulse pressure increases. This occurs with aging and atherosclerotic plaquing.

Mean arterial pressure is a measure of pressure in the arteries and is somewhere between the average systolic and diastolic pressures. Mean arterial pressure (MAP) can be determined by the following:

$$\text{MAP} = \text{SV} \times \text{HR} \times \text{PR}$$

SV = stroke volume

HR = heart rate

PR = peripheral resistance (resistance in vascular system)

This means that anything affecting stroke volume, peripheral resistance, or heart rate will also affect blood pressure. The mechanisms that control these variables will also work to control blood pressure.

Blood pressure is directly related to cardiac output. Therefore the previously discussed factors that affect cardiac output also affect blood pressure. For example we know that an increase in cardiac output results in an increase in blood pressure. We also know that an increase in heart rate increases cardiac output given no changes in stroke volume. If sympathetic activity increases say, due to periods of stress, then we know that heart rate will increase because of stimulation from the medulla's cardiac control center activating the sympathetic pathway to the SA node. The increase in heart rate increases cardiac

output which in turn increases blood pressure. In essence long periods of stress can cause an increase in blood pressure.

The same process occurs with pain. Pain will activate the sympathetic pathway and increase heart rate and cardiac output. Blood pressure will also increase with pain.

### **Fluid Volume and Blood Pressure**

Overall fluid volume is directly related to blood volume. An increase or decrease in overall fluid volume subsequently increases or decreases blood volume. Likewise blood volume is directly related to blood pressure. Mechanisms that control fluid volume also have an effect on blood pressure. We will examine three mechanisms in this section. They include the renin-angiotensin system, atrial natriuretic hormone and antidiuretic hormone.

#### **Renin-Angiotensin System**

The renin-angiotensin system (renin-angiotensin-aldosterone system) begins with the secretion of renin by the kidneys in response to a decrease in blood pressure (we will explore this system in more detail in the urinary system chapter). Renin activates a plasma protein called angiotensinogen by causing it to cleave a portion known as angiotensin I (one). Angiotensin I travels through the bloodstream to the lungs where it encounters an enzyme known as angiotensin converting enzyme (ACE). The angiotensin converting enzyme again cleaves angiotensin I producing angiotensin II. Angiotensin II causes systemic vasoconstriction as well as stimulates the release of aldosterone, an adrenal cortex hormone. Aldosterone targets the kidneys to conserve sodium and secrete potassium. The conservation of sodium causes an increase in fluid volume by way of osmosis. The increase in fluid volume causes a subsequent increase in blood volume and blood pressure (fig. 19.8).

#### **Atrial Natriuretic Hormone (ANH)**

Atrial natriuretic hormone (sometimes called a peptide) is secreted by the walls of the atria in response to atrial stretch. If blood volume increases so does venous return causing increased atrial stretch. The subsequent release of ANH targets the kidneys to eliminate sodium. Water follows sodium by osmosis causing a decrease in fluid volume, blood volume and blood pressure.

#### **Antidiuretic Hormone (ADH)**

ADH (vasopressin) is a hormone secreted by the posterior portion of the pituitary gland in response to increases in blood solute concentration. The hypothalamus contains neurons that sense changes in blood solute concentration. Like angiotensin II, ADH causes vasoconstriction although it is not as powerful as angiotensin II. ADH targets the kidneys to conserve fluid. Less urine is produced when ADH is secreted as fluid volume is conserved.

## Peripheral Resistance

Fluid moves by virtue of a pressure gradient. In other word fluid moves from areas of higher to lower pressure. The left ventricle must produce a pressure that is greater than the fluid pressure in the arterial side of the vascular system in order to move blood through the system. The pressure that is resident in the vascular system that the heart must overcome in order to move blood is called afterload. The resistance to blood flow in the vascular system is also known as peripheral resistance.

Peripheral resistance is directly proportional to blood pressure.

Pressure in the vascular system is greatest in the aorta and decreases as blood moves from the arteries to arterioles, capillaries and the venous system. The pressure can be as low as 0 mm Hg at the right atrium. The pressure in each part of the arterial system is directly proportional to the resistance to blood flow. The larger structures such as the larger arteries have little resistance while the smaller structures such as the capillaries have a much larger resistance to blood flow. Pressure in the arterioles is about 85 mm Hg and in the capillaries about 30 mm Hg.

Pressure is controlled in part in the vascular system by changing the diameter of the vessels. Arteries and arterioles have a larger smooth muscle layer than veins and are capable of constricting or dilating according to the body's needs for oxygenated blood.

The vessels receive input from the sympathetic nervous system. An increase in sympathetic stimulation will cause vasoconstriction while a decrease causes vasodilation. There is continuous stimulation from the sympathetic nervous system that produces a continuous partial vasoconstriction in order to maintain pressure. This is known as vasomotor tone.

When the arteries are fully stimulated by the sympathetic nervous system they are about one half of their normal diameter. Increases in vasoconstriction produce subsequent increases in peripheral resistance and blood pressure. Likewise a decrease in sympathetic stimulation results in vasodilation that in turn decreases peripheral resistance and blood pressure.

Peripheral resistance also increases with the disease process known as atherosclerosis (fig. 19.9). Atherosclerosis is a thickening of the tunic media of arteries along with damage to the endothelium. This disease has been linked to high levels of small particle low density lipoproteins. These lipids deposit on blood vessel walls and undergo phagocytosis by white blood vessels. The result is the deposition of what is known as plaque. Plaque narrows the lumen of the arteries and increases peripheral resistance and blood pressure.

# Renin-angiotensin-aldosterone system

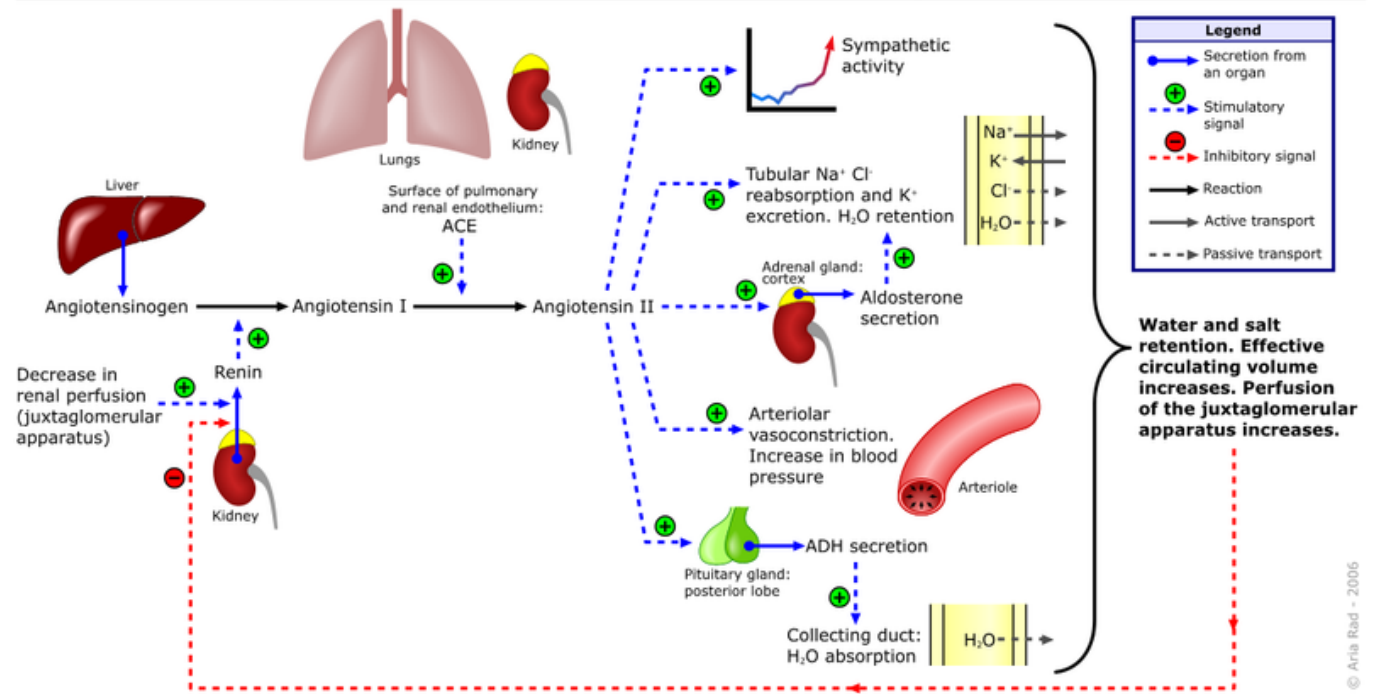


Figure 19.8. The Renin-angiotensin-aldosterone system (RAS).

[http://commons.wikimedia.org/wiki/File:Renin-angiotensin-aldosterone\\_system.png](http://commons.wikimedia.org/wiki/File:Renin-angiotensin-aldosterone_system.png)

Author: A. Rad Date: April 2nd, 2006

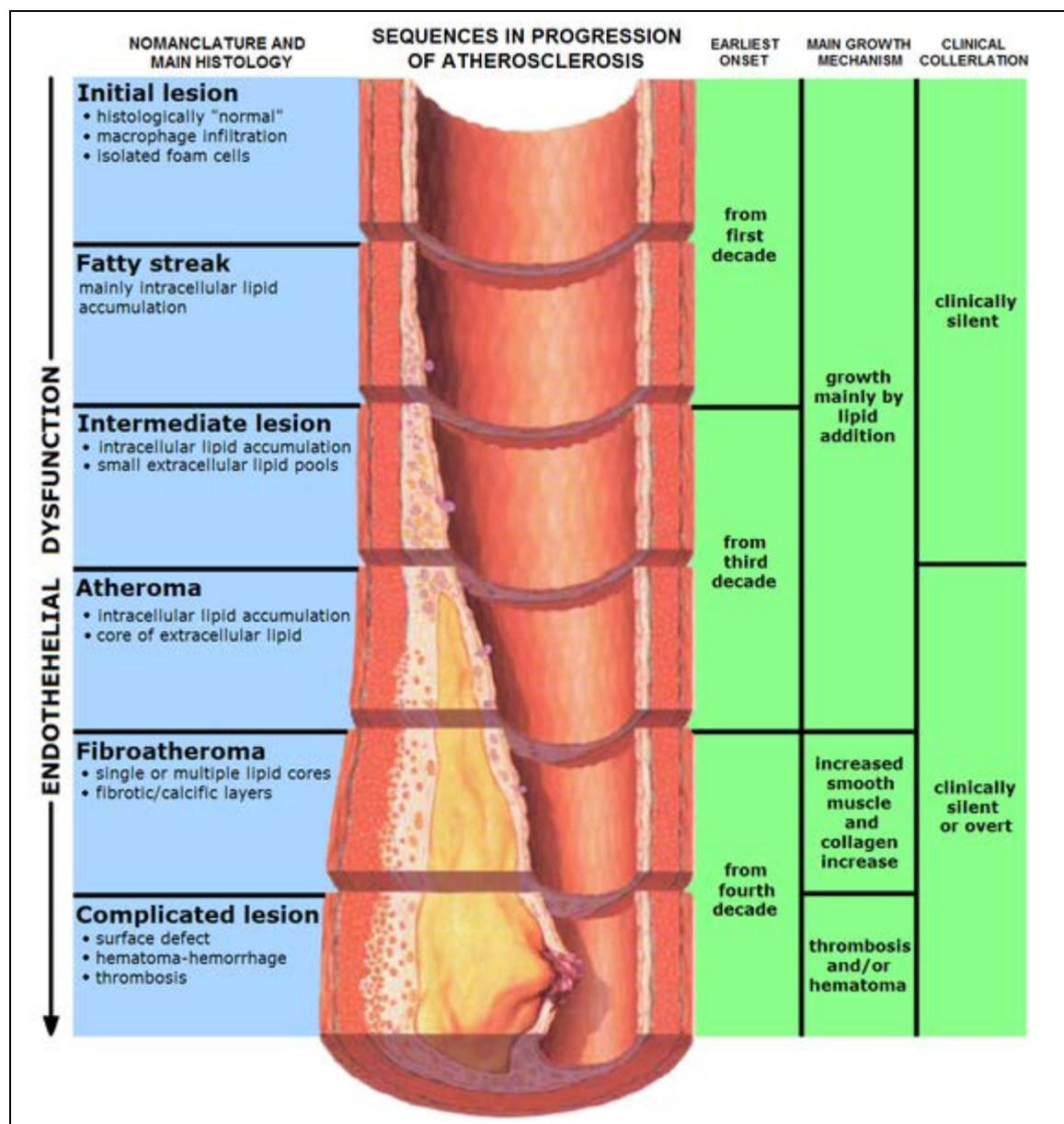


Figure 19.9. Atherosclerosis

[http://commons.wikimedia.org/wiki/File:Endo\\_dysfunction\\_Athero.PNG](http://commons.wikimedia.org/wiki/File:Endo_dysfunction_Athero.PNG)

Original uploader was [Grahams Child](#) at [en.wikipedia](#) Later versions were uploaded by [Jrockley](#) at [en.wikipedia](#)

## **Shock**

Shock results when there is inadequate supply of oxygenated blood to the tissues. Circulatory shock can be described in three stages; compensated, progressive and irreversible.

Compensated shock is characterized by a moderate decrease in blood pressure. Compensated shock stimulates all of the mechanisms for maintaining blood pressure. Blood pressure is gradually restored to normal levels in compensated shock.

If blood pressure control mechanisms are not adequate to restore blood pressure then progressive shock results. Blood flow decreases to levels that produce ischemia in heart tissue resulting in damage if not restored quickly.

Without successful intervention the body progresses into irreversible shock. Irreversible shock is fatal and does not respond to medical treatment.

Types of shock include the following:

Hypovolemic shock results from a loss of fluid volume. This can result from severe dehydration, urination, diarrhea, vomiting, hormonal problems, and diaphoresis (profuse sweating).

Hemorrhagic shock results from loss of blood volume. This can result from severe bleeding either externally or internally.

Neurogenic shock results from damage to vasomotor centers in the central nervous system. This causes profuse vasodilation and decrease in blood pressure.

Emotional shock results from fainting. This is also known as vasovagal syncope. An emotional response can increase parasympathetic input to the heart causing vasodilation in skeletal muscles and a decrease in cardiac output.

Anaphylactic shock results from an allergic reaction that produces an overabundance of certain antibodies that produce vasodilation and capillary permeability.

Septic shock results from toxic substances in the blood. The substances can come from infections and food. The toxic substances produce vasodilation and increased capillary permeability.

Cardiogenic shock results from heart damage. The heart is unable to maintain an adequate cardiac output.

## **Exchange of Substances between Capillaries and the Interstitium**

Cells require a constant supply of substances from capillaries. Thus substances must be delivered at a constant rate. A variety of mechanisms help to move substances between capillaries and the interstitium. Of these mechanisms diffusion is the most prevalent (fig. 19.10).



Substances moving by diffusion move from an area of higher to lower concentration. Substances moving out of capillaries and into the interstium include oxygen and glucose. Likewise substances moving from the interstium to the capillaries also move by diffusion. These include carbon dioxide and various waste products.

Fluid also moves from the capillaries to the interstium at the arterial end and returns back to the capillaries at the venous end. However not all of the fluid is returned to circulation. There is a net loss of fluid from the capillaries. This fluid returns to circulation via the lymphatic system.

Fluid flow between the capillaries and interstitium is controlled by forces. These forces include fluid pressure and osmotic pressure. The pressure moving fluid out of the capillaries is known as net hydrostatic pressure. This pressure must overcome another pressure that works to pull fluid back into capillaries. This pressure is known as net osmotic pressure (figs. 19.11, 19.12) .

We can calculate the total pressure by subtracting net osmotic pressure from net hydrostatic pressure.

Net Filtration Pressure = Net Hydrostatic Pressure – Net Osmotic Pressure

Our calculation gives us Net Filtration Pressure which accounts for all of the pressures moving fluids.

Net hydrostatic pressure actually consists of two pressures. These include capillary hydrostatic pressure (CHP) which is the blood pressure at the arterial end of the capillary and interstitial fluid pressure (IFP). Interstitial fluid pressure is the pressure in the interstitium that opposes movement of fluid from capillary to interstitium. This pressure is a negative pressure because of the action of lymphatic vessels. The lymphatic vessels create a suction effect that pulls fluid from the capillaries.

For example, CHP is usually around 30 mm Hg and IFP is usually around -3 mm Hg. We can calculate net hydrostatic pressure (NHP) as follows:

$$\text{NHP} = \text{CHP} - \text{IFP}$$

$$\text{NHP} = 30 \text{ mm Hg} - (-3 \text{ mm Hg})$$

$$\text{NHP} = 33 \text{ mm Hg}$$

This represents the pressure pushing fluid out of the capillaries.

The pressure pulling fluid back into the capillaries is the net osmotic pressure (NOP). NOP represents the difference in osmotic pressures between the capillaries and the interstitium. There are two pressures that make up NOP. These include blood colloid osmotic pressure and interstitial osmotic pressure.

Blood colloid osmotic pressure (BCOP) represents the pulling force resulting from the presence of plasma proteins in the blood. Fluid moves toward an area of higher concentration of solute due to osmosis. The plasma proteins act like a solute. BCOP then works to move fluid from the interstitium to the capillaries.

Interstitial colloid osmotic pressure (ICOP) results from the presence of proteins in the interstitium. The BCOP is much larger than ICOP because proteins are large molecules that do not pass through capillary walls and thus stay in the blood.

We can calculate the net osmotic pressure by subtracting the ICOP from the BCOP. For example the BCOP is usually around 28 mm Hg and the ICOP is usually around 8 mm Hg.



Net osmotic pressure (NOP) = Blood colloid osmotic pressure (BCOP) – interstitial colloid osmotic pressure (ICOP).

$$\text{NOP} = 28 \text{ mm Hg} - 8 \text{ mm Hg}$$

$$\text{NOP} = 20 \text{ mm Hg}$$

Now we can calculate the net filtration pressure (NFP) by the following.

$$\text{NFP} = \text{NHP} - \text{NOP}$$

$$\text{NFP} = 33 \text{ mm Hg} - 20 \text{ mm Hg}$$

$$\text{NFP} = 13 \text{ mm Hg}$$

This represents the arterial end of the capillary. Thus there is a net loss of fluid from this end of the capillary bed.

The venous end of the capillary is a bit different. Fluid pressure decreases between the arterial and venous ends of capillaries. The capillary hydrostatic pressure at the venous end decreases to about 10 mm Hg.

The net hydrostatic pressure at the venous end is:

$$\text{NHP} = \text{CHP} - \text{IFP}$$

$$\text{NHP} = 10 \text{ mm Hg} - (-3 \text{ mm Hg})$$

$$\text{NHP} = 13 \text{ mm Hg}$$

The colloid osmotic pressures do not change because the movement of proteins from capillary to interstitium does not change.

To calculate net filtration pressure at the venous end:

$$\text{NFP} = \text{NHP} - \text{NOP}$$

$$\text{NFP} = 13 \text{ mm Hg} - 20 \text{ mm Hg}$$

$$\text{NFP} = -7 \text{ mm Hg}$$

The negative pressure at the venous end of capillaries causes fluid to move into the capillaries. The various movements of fluid between the capillaries and interstitium maintain a balance. Disrupting this balance can result in edema.

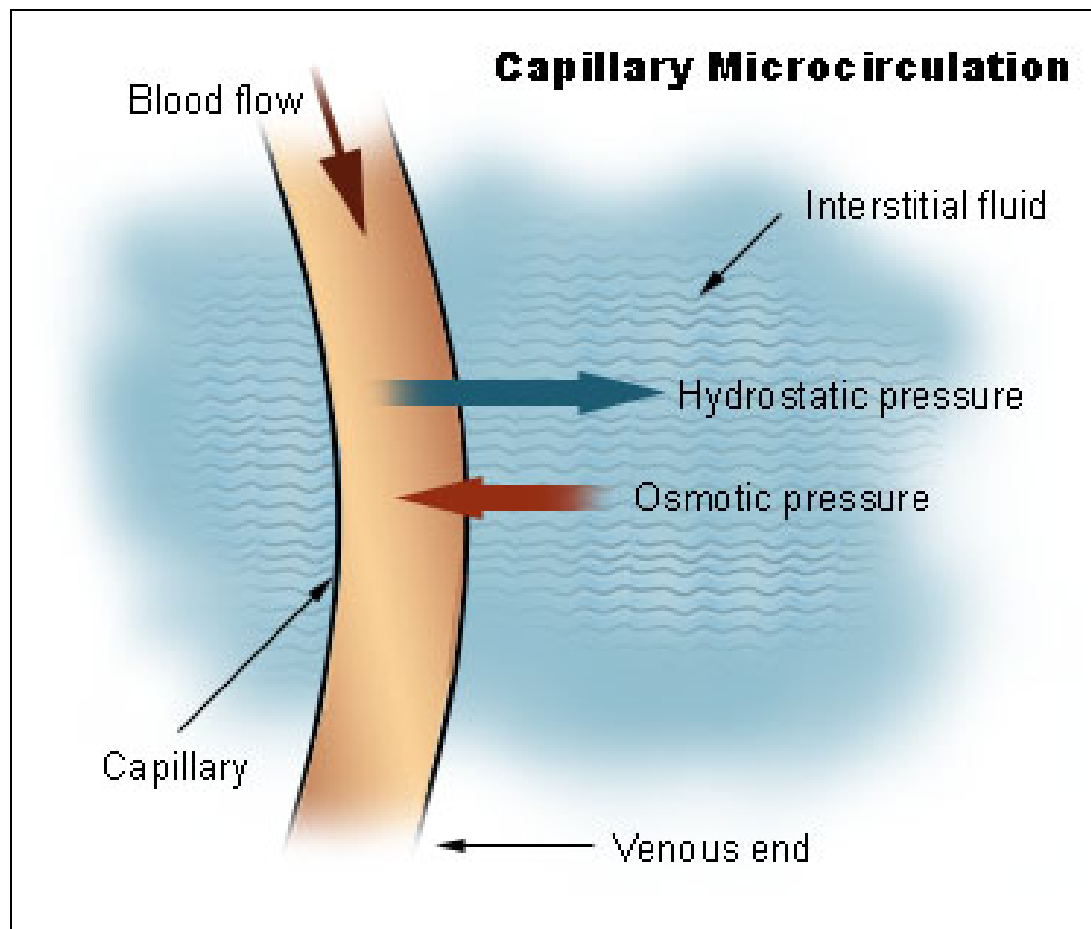


Figure 19.10. Movement of fluid in capillary.

[http://commons.wikimedia.org/wiki/File:llu\\_capillary\\_microcirculation.jpg](http://commons.wikimedia.org/wiki/File:llu_capillary_microcirculation.jpg)

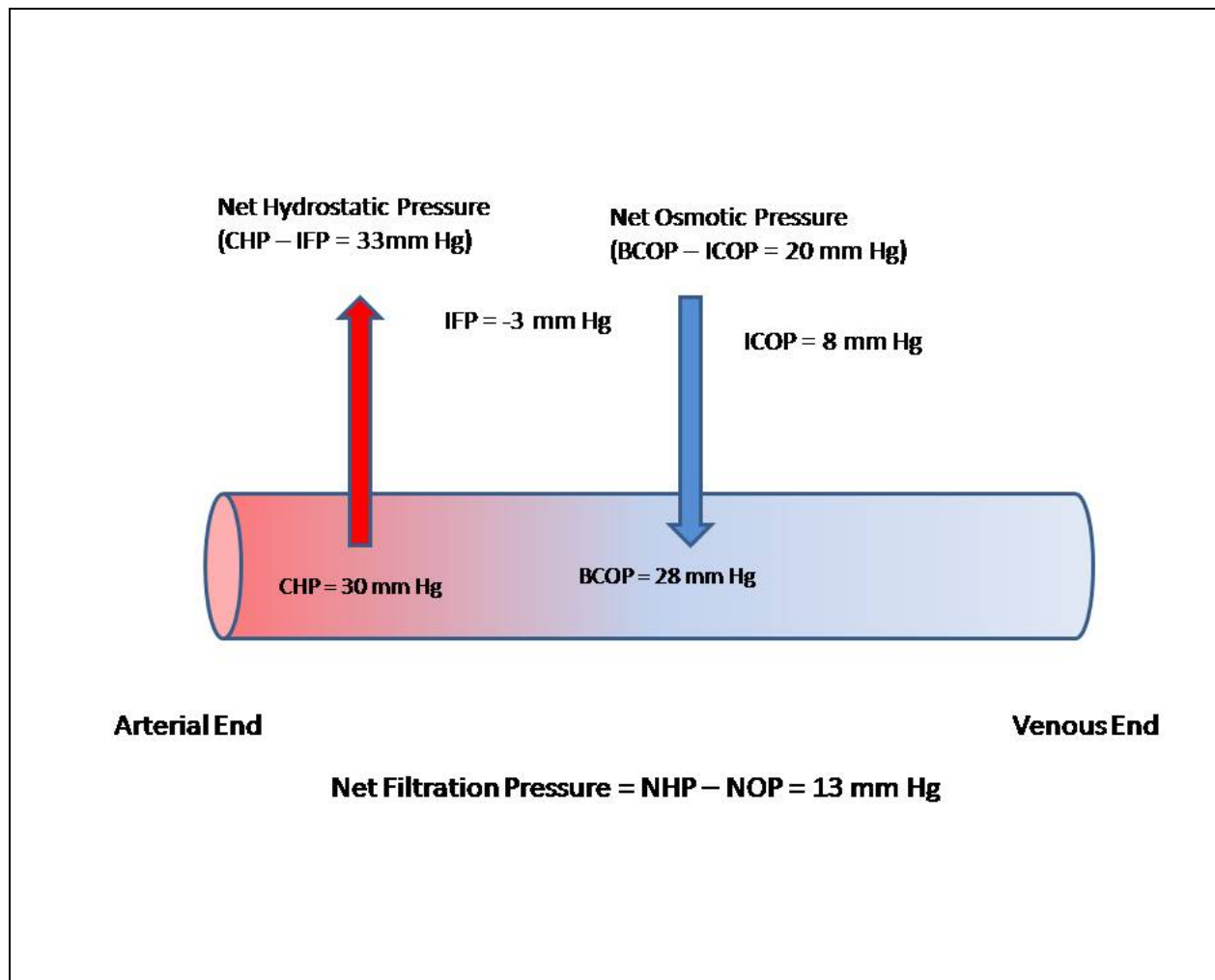


Figure 19.11. There is a loss of fluid from the capillaries at the arterial end. The net filtration pressure is 13 mm Hg.

Bruce Forciea

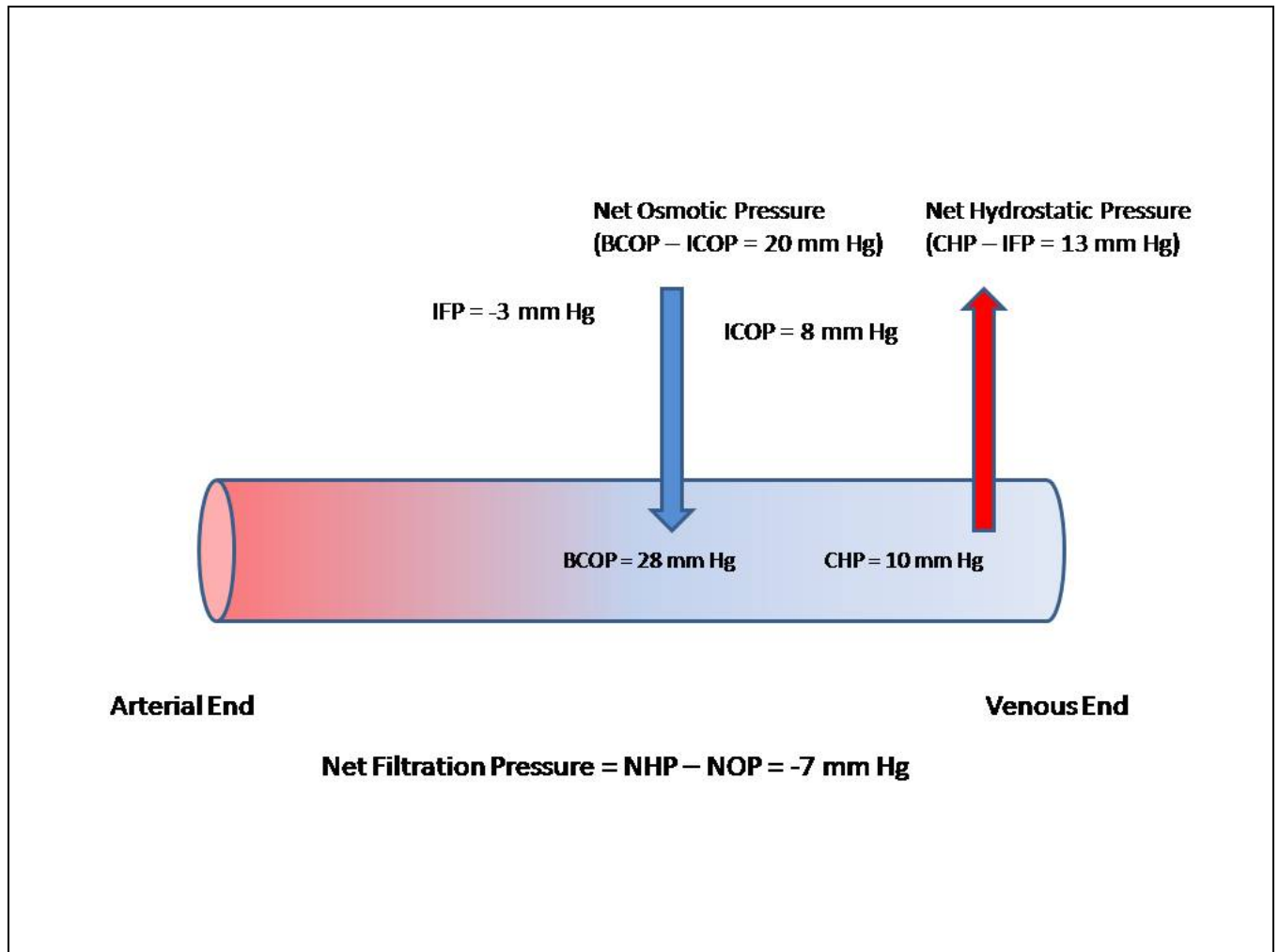


Figure 19.12. Fluid flows back into capillaries at the venous end. The net filtration pressure is -7 mm Hg.

Bruce Forciea

## **Real World A&P**

### **High Blood Pressure**

High blood pressure or hypertension can result from a number of conditions. High blood pressure is classified as follows:

Prehypertension occurs when the systolic pressure is between 120 and 139 or diastolic pressure is between 80-89 mmHg. Stage 1 hypertension occurs when the systolic pressure is between 140 and 159 mm Hg or the diastolic pressure is between 80 and 89 mmHg. Stage 2 occurs when the systolic pressure is greater than 160 or the diastolic pressure is greater than 100 mmHg.

In mild cases hypertension is usually treated with diet and exercise. If you are overweight a little bit of weight loss can go a long way. Your blood pressure goes up when you gain weight because of a phenomenon called peripheral resistance. When you gain weight your body surface area increases. Your body also produces extra blood vessels to bring blood to the area. This increases the resistance in your blood vessels so your heart has to work harder. When the resistance to blood flow increases so does your blood pressure. Also avoiding salt helps in that it reduces the overall fluid and blood volume.

More severe hypertension is treated with a variety of medications. Some work to reduce the amount of fluid in your body. These are called diuretics. Others inhibit hormones that cause constriction of your blood vessels (angiotensin converting enzyme or ACE inhibitors). Another type of medication reduces the effects of adrenaline on the heart so it beats slower (beta blockers).

It is important to work with a physician in using both medication and natural methods to help to lower high blood pressure.

## Chapter 19 Review Questions

1. Cardiac muscle has a resting membrane potential of:
  - a. -55mV
  - b. -70mV
  - c. -90mV
  - d. +30mV
2. Which of the following electrolytes is responsible for maintain depolarization in cardiac muscle:
  - a. Sodium
  - b. Potassium
  - c. Calcium
  - d. Chloride
3. The atrioventricular node is capable of producing an action potential at \_\_\_\_bpm.
  - a. 60-100
  - b. 20-40
  - c. 40-60
  - d. 10-20
4. An area of abnormal tissue that generates its own impulses is known as:
  - a. Myocardial node
  - b. Ectopic pacemaker
  - c. Purkinje fiber
  - d. Endocardial generator
5. In an ECG the T-wave represents:
  - a. Atrial depolarization
  - b. Ventricular depolarization
  - c. Ventricular repolarization
  - d. Atrial repolarization
6. Which of the following best describes cardiac output:
  - a. Amount of blood moving through the atria in one contraction
  - b. Amount of blood moving through the ventricles in one contraction
  - c. Amount of blood moving though the ventricles in one minute
  - d. Amount of blood moving though the atria in one minute

7. The cardiac control center is located here:
- a. Cerebrum
  - b. Medulla oblongata
  - c. Pons
  - d. Midbrain
8. Parasympathetic impulses are carried to the heart by way of:
- a. Vagus nerve
  - b. Cardiac accelerator nerves
  - c. Spinal accessory nerve
  - d. Phrenic nerve
9. The difference between systolic and diastolic blood pressures is known as:
- a. Stroke volume
  - b. Pulse pressure
  - c. Mean arterial pressure
  - d. Peripheral resistance
10. Which of the following occurs with an increase in fluid volume:
- a. ADH secretion
  - b. Activation of the renin-angiotensin system
  - c. ANH secretion
  - d. Retention of sodium
11. Which of the following does not increase peripheral resistance:
- a. Vasodilation
  - b. Atherosclerosis
  - c. Weight gain
  - d. Increased sympathetic nervous system activity
12. Which type of shock results from fainting:
- a. Cardiogenic
  - b. Hypovolemic
  - c. Neurogenic
  - d. Emotional

13. Which 2 pressures contribute to net hydrostatic pressure:
- a. Blood colloid osmotic pressure and capillary hydrostatic pressure
  - b. Interstitial fluid pressure and blood colloid osmotic pressure
  - c. Capillary hydrostatic pressure and interstitial fluid pressure
  - d. Interstitial colloid osmotic pressure and interstitial fluid pressure
14. The net hydrostatic pressure at the arterial end of a capillary is:
- a. 10 mmHg
  - b. 13 mmHg
  - c. 15 mmHg
  - d. 20 mmHg
15. Which of the following is a true statement about the net filtration pressure at the venous end of a capillary:
- a. It is negative
  - b. It is positive
  - c. It allows for stasis of blood
  - d. It works to push blood back into the arterial side



# Chapter 20

## Respiratory System Anatomy

## Respiratory System Anatomy

The respiratory system supplies the body with oxygen and removes carbon dioxide. It consists of a series of structures that allow for the passage of air into the body and the exchanges of gases with the blood (figs. 20.1, 20.2). There are essentially two types of respiration. External respiration is the movement of gases into the body and blood. Cellular respiration is the use of oxygen and production of carbon dioxide by the cells. We will cover external respiration in the next two chapters.

The respiratory system can be divided into the upper and lower respiratory systems. The upper respiratory system consists of the nose and nasal cavity, the sinus, pharynx and the portion of the larynx above the vocal cords. The lower respiratory system consists of the portion of the larynx including the vocal cords and below, trachea, bronchi, bronchioles, lungs and alveoli.

Air moves into the upper respiratory system through the nose at the nostrils or external nares and enters the nasal cavity. The nasal cavity is also known as the nasal vestibule and is lined with epithelium containing hairs. The epithelium contains columnar and mucous secreting goblet cells. Beneath the epithelium is a highly vascular area known as the lamina propria. The vascularization helps to provide heat and humidity to the air of the nasal cavity. The nasal cavity contains bony protuberances called conchae. There are superior, middle and inferior conchae. The purpose of the conchae is to create turbulent flow of air. This works to warm the air and to provide more contact with the nasal mucosa and hairs so that particles can be picked up by the mucosa. The turbulent air can also reach the upper nasal cavity containing sensory receptors for smell.

The nasal cavity is divided into right and left portions by the nasal septum. The nasal septum is formed by two bones. The superior portion consists of the perpendicular plate of the ethmoid bone and the inferior portion consists of the vomer bone. The anterior portion of the nasal septum consists of cartilage.

Located between the conchae are the superior, middle and inferior meatuses which are small grooves that allow air to flow between the nasal cavity, paranasal sinuses and nasolacrimal ducts.

The floor of the nasal cavity consists of the hard palate. The hard palate is formed by the maxilla (anterior) and palatine (posterior) bones. The hard palate separates the nasal and oral cavities. Just posterior to the hard palate is the soft palate and uvula.

Air exits the nasal cavity to the nasopharynx by way of a passage known as the internal nares.

### The Pharynx

Air passing through the internal nares enters the upper portion of the pharynx known as the nasopharynx. The nasopharynx begins posterior to the conchae and extends inferiorly to the soft palate. The soft palate raises to close off the nasopharynx during swallowing to prevent substances from moving into the nasopharynx. The nasopharynx is lined with ciliated pseudostratified columnar epithelium with goblet cells that secrete mucous. The cilia move substances through the nasopharynx so that they can be swallowed. The nasopharynx also contains connections from the Eustachian tubes. The pharyngeal tonsil (adenoid) is also located in the nasopharynx.

Inferior to the nasopharynx is the oropharynx which extends from the soft palate to the epiglottis. The oropharynx is a shared passageway for air and substances on their way to the digestive tract. The

palatine and lingual tonsils are located in the oropharynx. The oropharynx is lined with stratified squamous epithelium.

The most inferior portion of the pharynx is the laryngopharynx which extends from the tip of the epiglottis to the larynx. The laryngopharynx is also a shared pathway with the digestive tract and is lined with stratified squamous epithelium.

## **The Larynx**

The larynx begins at the base of the tongue and extends to the trachea (fig. 20.3). The pharynx consists of nine cartilages that are interconnected with muscles and ligaments. The largest of the cartilages is the thyroid cartilage (Adam's apple). Inferior to the thyroid cartilage is the cricoid cartilage. The epiglottis is an elastic cartilage flap that closes during swallowing to keep substances from moving into the trachea and air passages. Other cartilages include the arytenoids, corniculate and cuneiform cartilages. These cartilages are paired.

The vocal cords reside in the larynx and consist of two pairs of ligaments that extend from the arytenoid to the thyroid cartilages. One set of ligaments (superior set) are called the false vocal cords. The inferior set is called the true vocal cords. When the vocal cords are relaxed they form a triangular space called the glottis. The larynx is lined with pseudostratified columnar epithelium. The vocal cords are covered by a mucous membrane.

Different pitches in the voice are produced by vibrations of the vocal cords. Vibration of smaller areas of the vocal cords results in higher pitches. Males typically have longer vocal cords than females that result in lower pitches.

## **Trachea**

Air travels from the larynx to the trachea (fig. 20.4). The trachea is a tubular structure consisting of dense connective tissue and rings of hyaline cartilage. The trachea is lined with ciliated pseudostratified columnar epithelium with goblet cells. The epithelium moves substances toward the larynx and esophagus for swallowing. The cartilage rings do not completely encircle the trachea but are open posteriorly. The posterior section of the trachea contains a ligament and smooth muscle known as the trachealis muscle. The trachealis muscle can contract and constrict the trachea. The trachea usually ends at about the level of the fifth thoracic segment.

The inferior end of the trachea divides into right and left bronchi at an area known as the carina. The carina is the last tracheal cartilage and forms a cartilage division between the two bronchi.

## **Bronchial Tree**

The trachea ends at the carina and divides into two tubular structures called the right and left primary bronchi. The bronchi then divide into smaller branches called secondary or lobar bronchi and then even smaller branches called tertiary or segmental bronchi. The structure of the bronchi is similar to the trachea with incomplete cartilage rings and smooth muscle. As the bronchi get smaller there is less cartilage and more smooth muscle until reaching the tertiary bronchi that consists entirely of smooth muscle. The smooth muscle can constrict the bronchi and impede air passage.

The bronchi continue to branch and form small bronchioles which divide to form terminal bronchioles. The terminal bronchioles divide to form respiratory bronchioles that connect with alveolar ducts. The alveolar ducts give rise to alveoli. Alveoli are considered the functional unit of the lung and consist of

small hollow areas for gas exchange. The alveolar ducts and alveoli are lined with simple squamous epithelium that allows for gas exchange. The cells of the simple squamous epithelium are called Type I pneumocytes. The alveoli also contain other cells known as type II pneumocytes. These cells secrete a substance known as surfactant that helps to decrease the surface tension in the alveoli. The lungs contain about 300 million alveoli.

## **The Lungs**

The lungs are two cone shaped structures residing in the thoracic cavity. The inferior portion of each lung reaches to the diaphragm. The superior portion extends about one inch above each clavicle. The right lung contains three lobes (superior, middle and inferior) and is larger than the left lung which contains two lobes (superior and inferior). The lobes are separated by fissures. The right lung includes a horizontal and oblique fissure while the left lung only contains an oblique fissure. The medial surface of each lung contains an area known as the hilum where vessels enter and exit. The left lung also contains the cardiac notch which is an indentation for the heart.

The lungs are surrounded by two pleural membranes. The surface of each lung contains a visceral pleural membrane that closely adheres to the lung's surface. Lining the interior of the thoracic wall is the parietal pleural membrane. Both are serous membranes. A fluid known as pleural fluid is secreted by each membrane that reduces friction and helps to hold the membranes together.

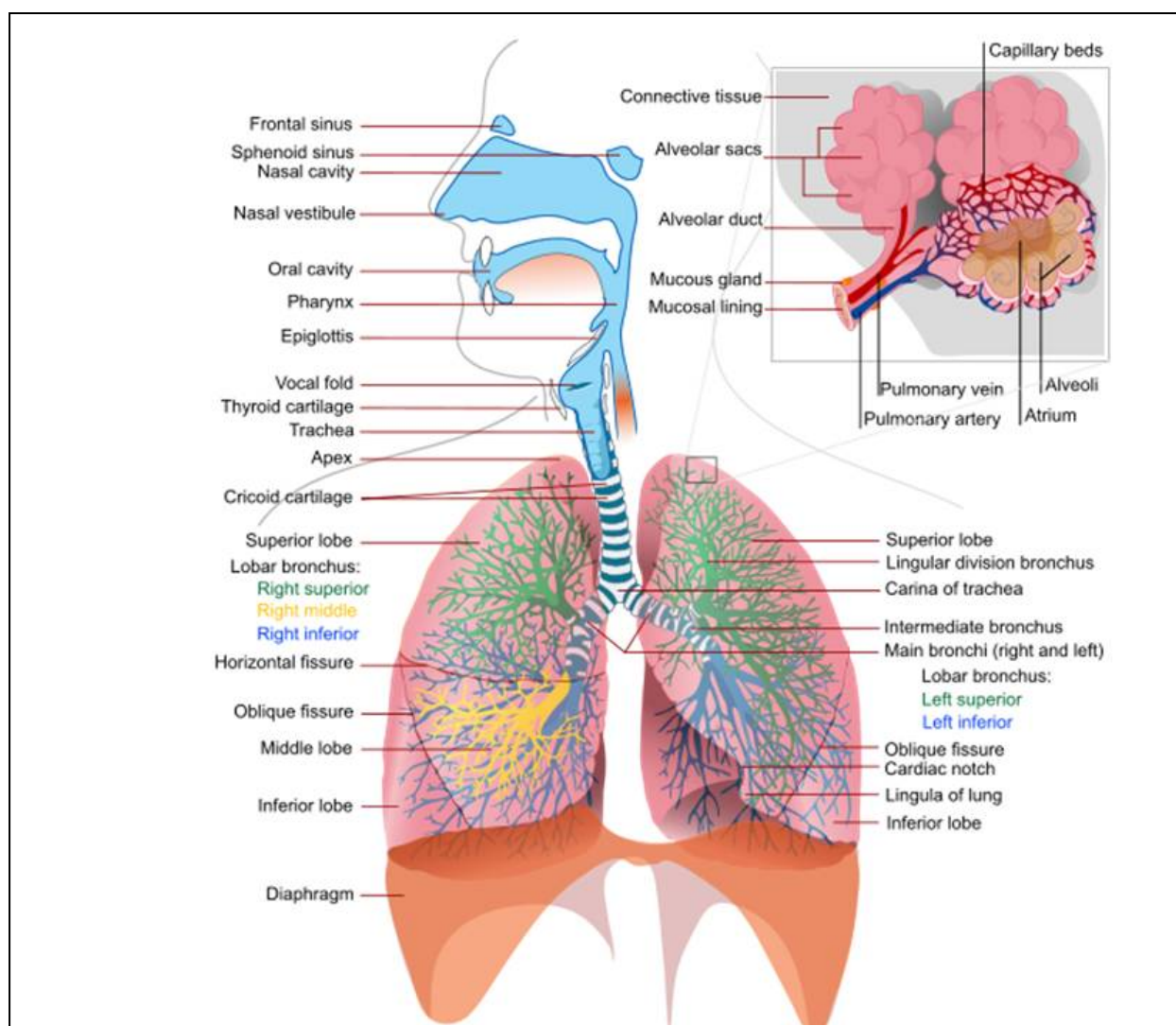


Figure 20.1. Respiratory System

[http://commons.wikimedia.org/wiki/File:Respiratory\\_system\\_complete\\_en.svg](http://commons.wikimedia.org/wiki/File:Respiratory_system_complete_en.svg)

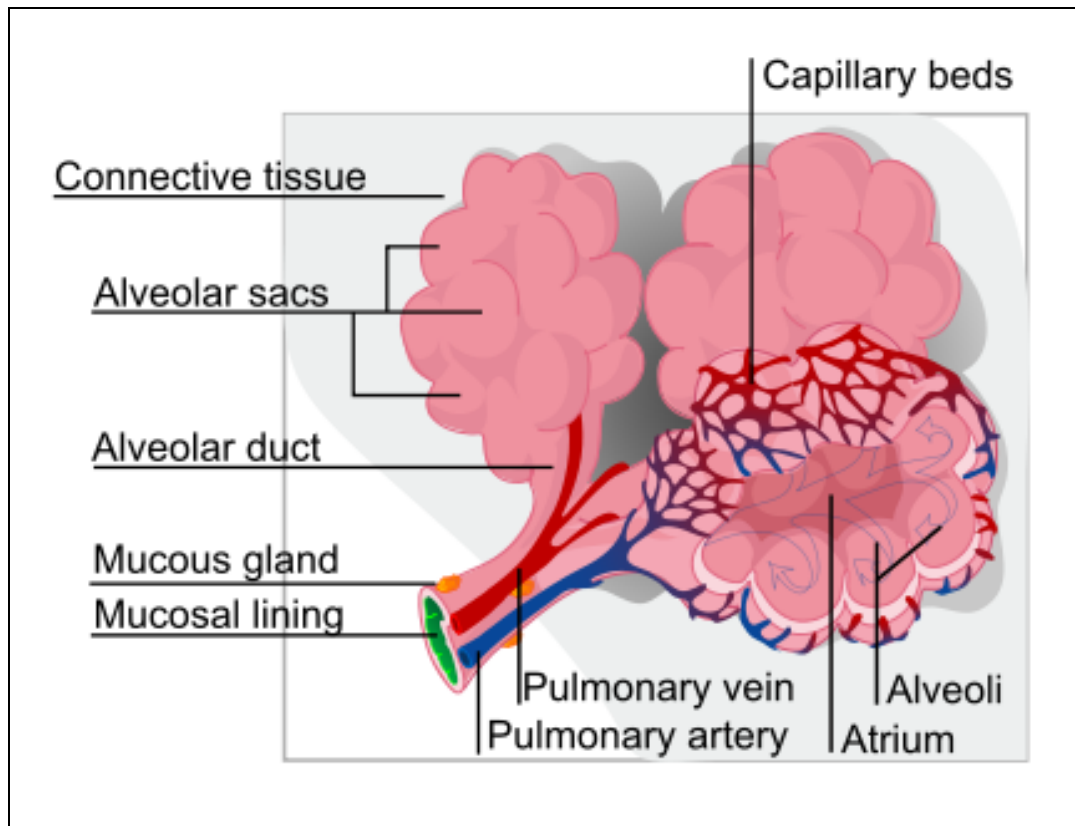


Figure 20.2. Alveolus

[http://commons.wikimedia.org/wiki/File:Alveolus\\_diagram.svg](http://commons.wikimedia.org/wiki/File:Alveolus_diagram.svg)

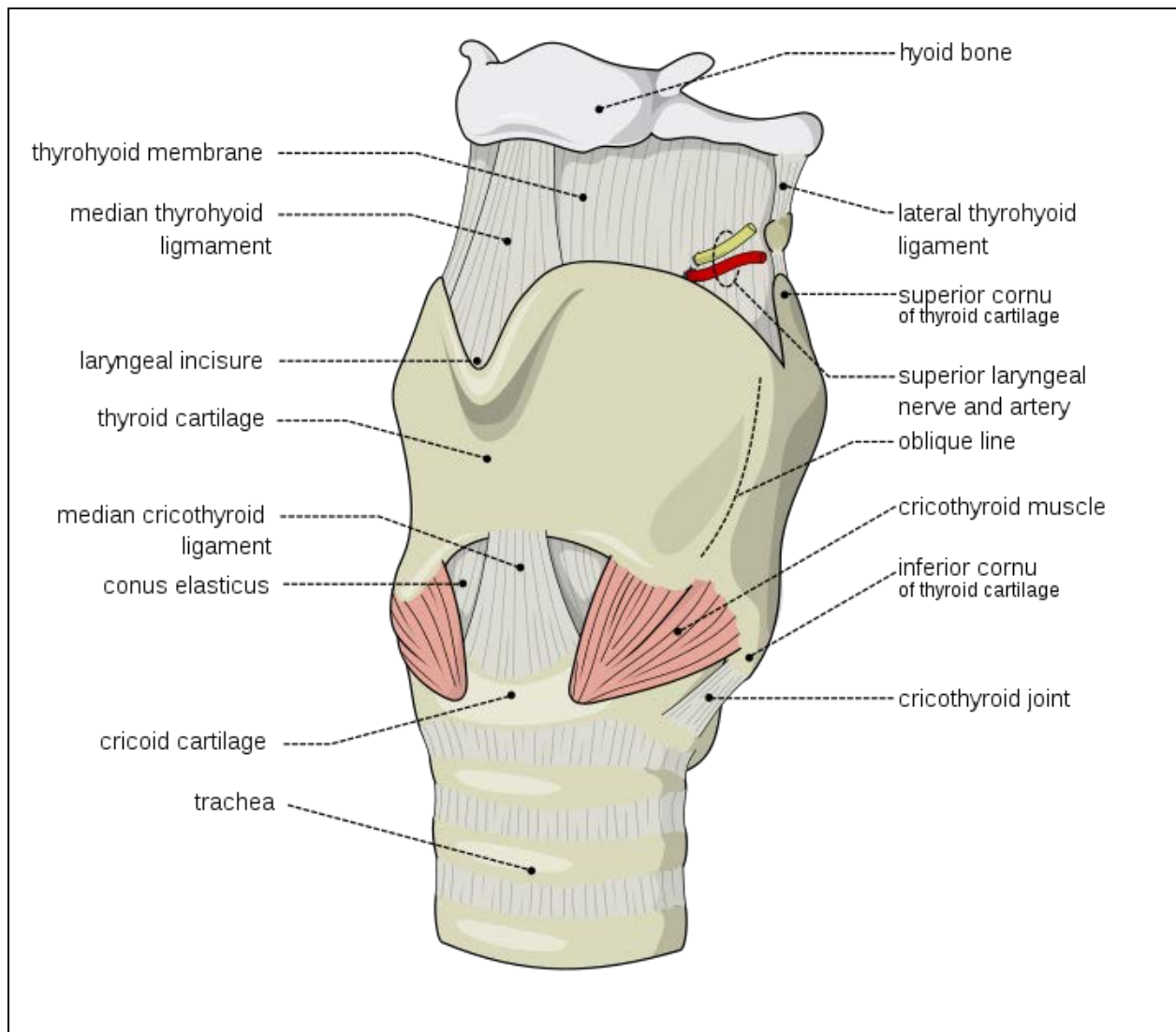


Figure 20.3. Larynx

[http://commons.wikimedia.org/wiki/File:Larynx\\_external\\_en.svg](http://commons.wikimedia.org/wiki/File:Larynx_external_en.svg)

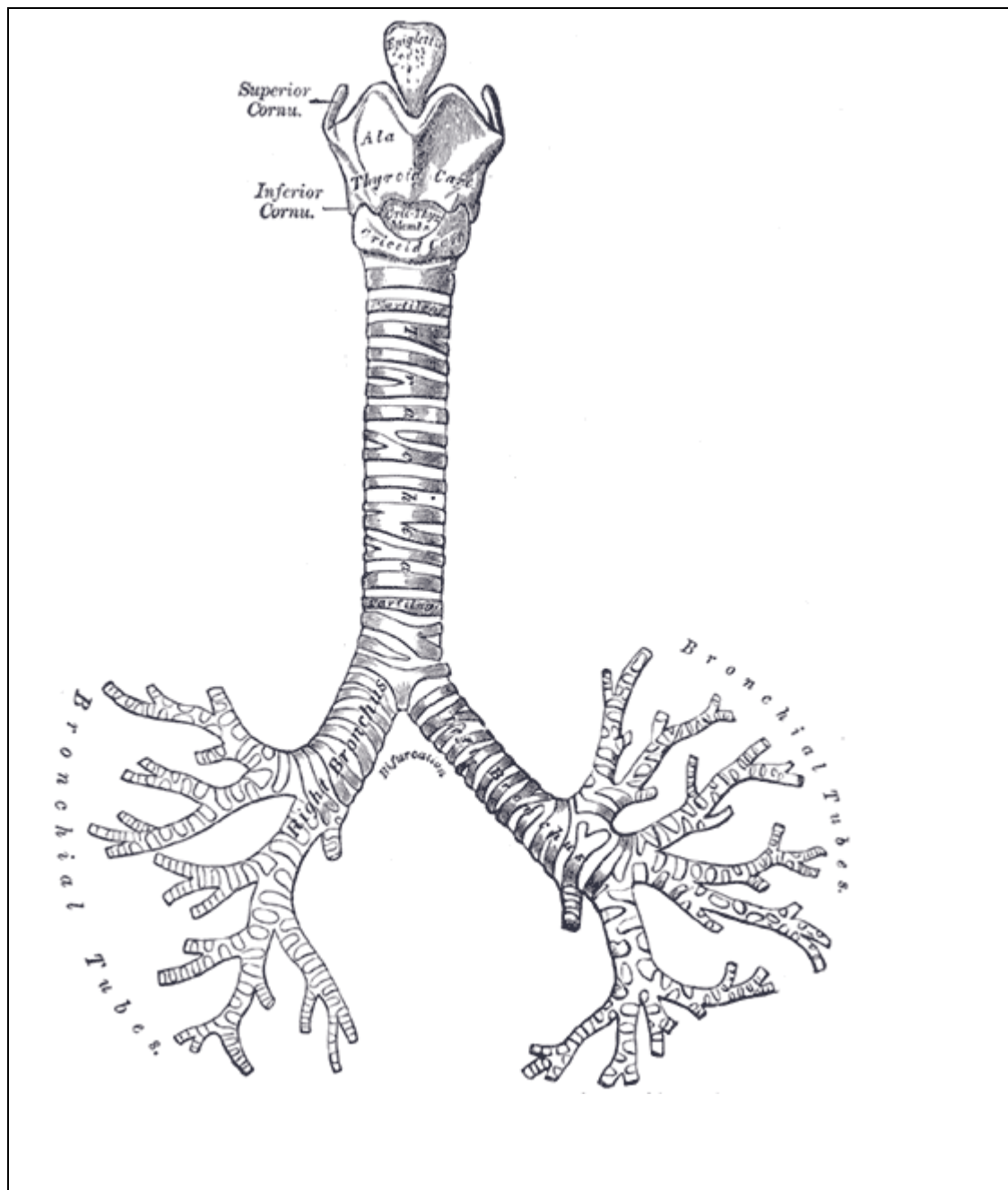


Figure 20.4. Trachea

<http://commons.wikimedia.org/wiki/File:Gray961.png>



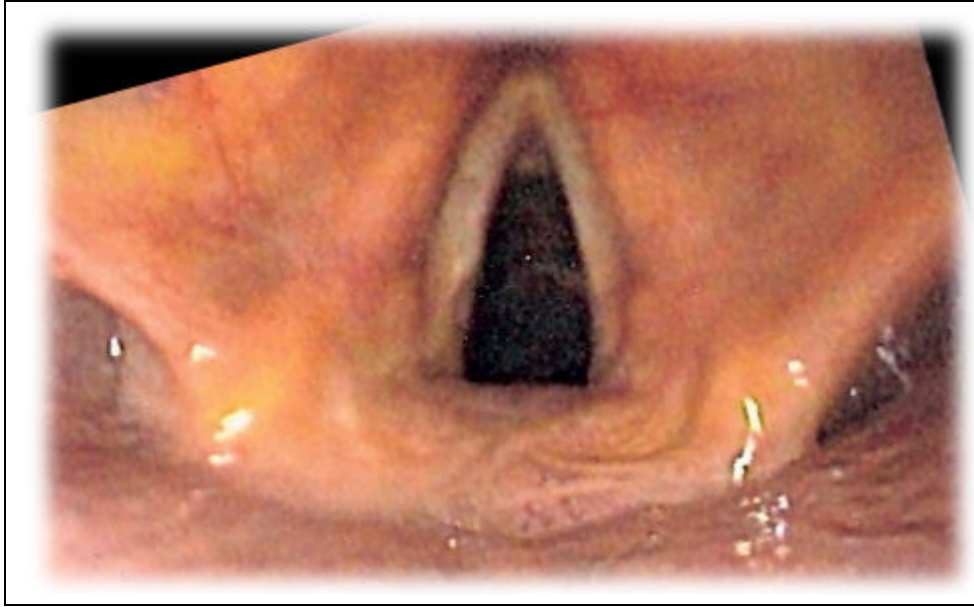


Figure 20.5. Vocal cords

[http://commons.wikimedia.org/wiki/File:Larynx\\_endo\\_2.jpg](http://commons.wikimedia.org/wiki/File:Larynx_endo_2.jpg)

## Inhalation and Exhalation

Inhalation and exhalation depends on changes in lung volume and air pressure. One cycle of inspiration and expiration is called a respiratory cycle. The movement of air in and out of the lungs is known as pulmonary ventilation. Air moves into the lungs and to the alveoli where oxygen and carbon dioxide diffuse between the alveoli and blood. It is important to maintain good airflow to the alveoli (alveolar ventilation) at all times.

Air is a gas and gas moves via pressure gradients. Gas will move from areas of higher pressure to areas of lower pressure. Pressure in the lungs must be lower than atmospheric pressure for air to move into the lungs.

### Boyle's Law

Boyle's law relates pressure and volume. It can be represented by:

$$P = 1/V$$

P = pressure

V = volume

Molecules of a gas will move at random within an enclosed space producing pressure on the walls of the space. The same amount of gas in a smaller space will exert a greater pressure than when in a larger space. So increasing the volume will lower the pressure for a given temperature and vice versa.

This is just what happens during inhalation. The diaphragm contracts and pulls downward increasing the volume of the thoracic cavity. The external intercostals also contract and expand the ribcage. The increased volume decreases the pressure inside of the lungs and air flows from higher pressure outside the lungs to lower pressure inside the lungs (fig. 20.6).

Expansion of the thoracic cavity causes the lungs to expand because of the pleural cavity. The pleural membranes secrete a fluid that forms a bond between the membranes. The force of this bond produces a pressure that is about -4 mm Hg or 4 mm Hg below atmospheric pressure. The lungs also contain elastic fibers. The elastic fibers create a force that opposes the force of the fluid bond between the pleural membranes. If the fluid bond did not exist the lungs would collapse to about 5% of their normal size.

### Compliance

Compliance represents the lung's ability to expand. The more compliant the lung the easier it will expand. As the lungs become less compliant they require more force to expand. The tissue structure of the lungs, flexibility of the thoracic cage and production of surfactant all affect compliance. For example people with emphysema have a decreased compliance.

During exhalation the diaphragm relaxes decreasing the volume of the thoracic cavity (fig. 20.7). The elastic fibers of the lungs work to move the lungs back to their original shape and the pressure increases moving air out of the lungs. Resting exhalation is considered a passive process.

### Accessory Muscles of Respiration

Other muscles besides the diaphragm and external intercostals are involved in respiration when greater amounts of air need to be moved into the lungs. Muscles assisting in inhalation include the sternocleidomastoid, serratus anterior, pectoralis minor and scalenes. Muscles assisting in exhalation include the internal intercostals, transverse thoracic and abdominals.

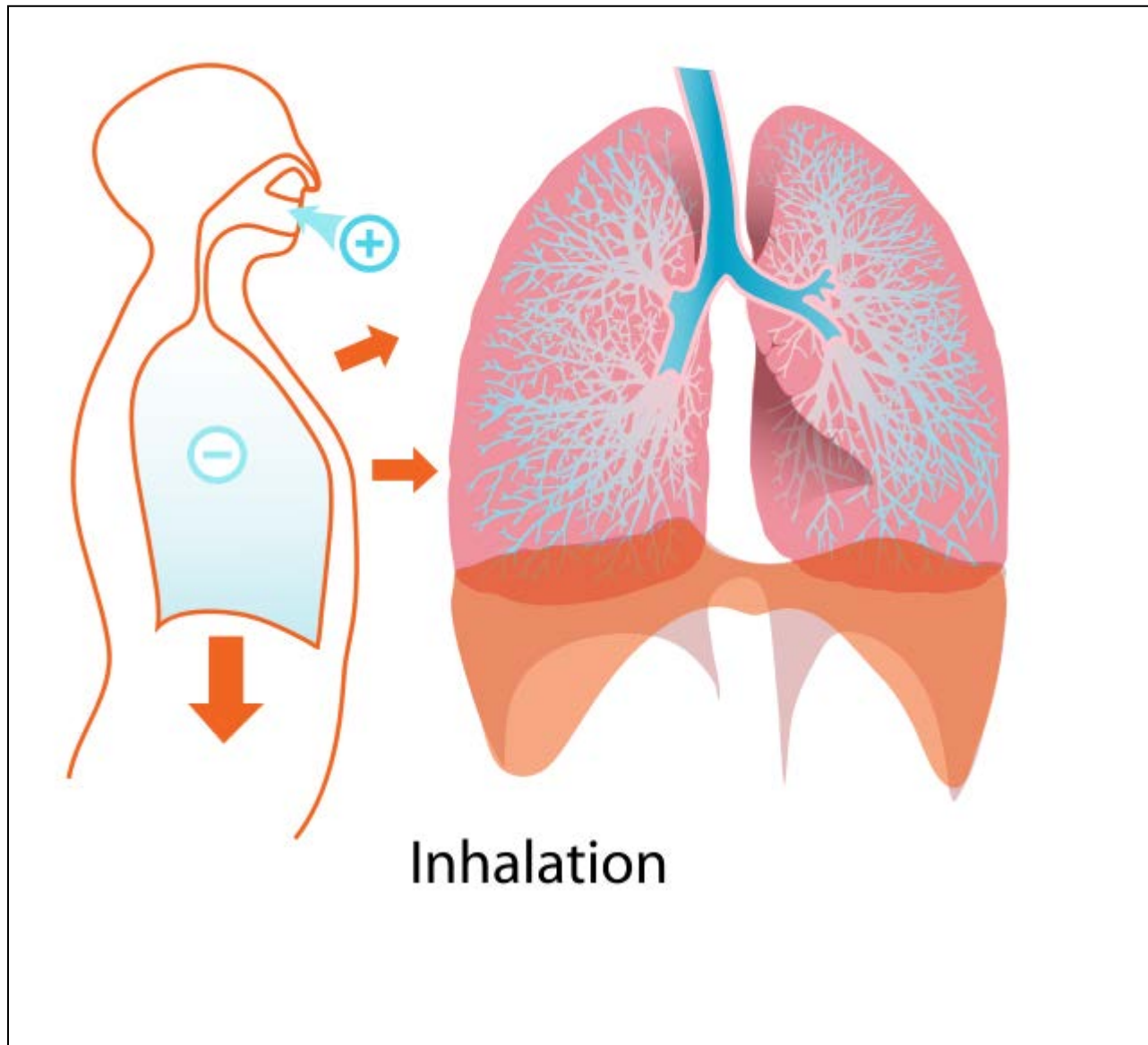


Figure 20.6. Inhalation

[http://commons.wikimedia.org/wiki/File:Inhalation\\_diagram.svg](http://commons.wikimedia.org/wiki/File:Inhalation_diagram.svg)

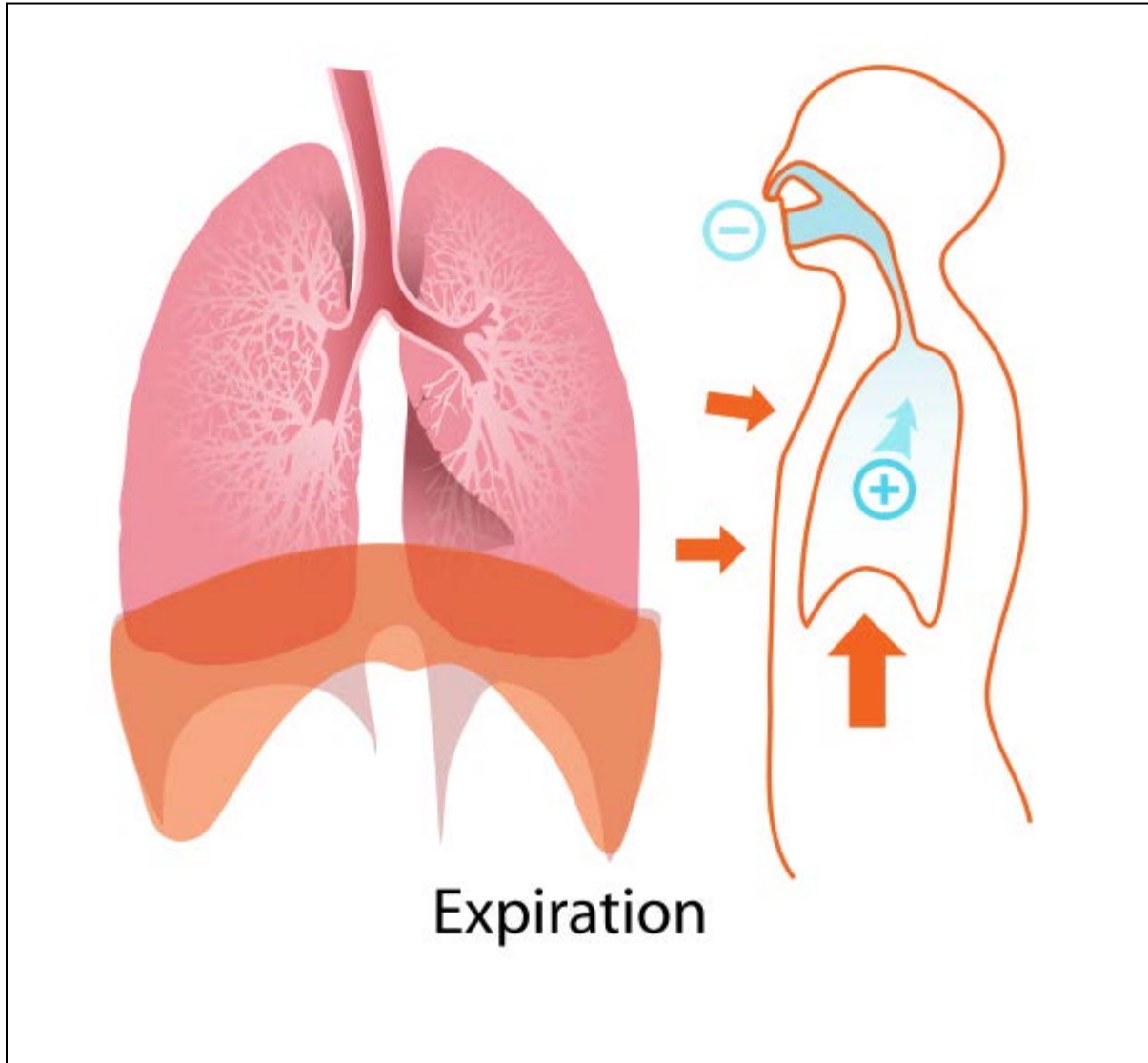


Figure 20.7. Exhalation

[http://commons.wikimedia.org/wiki/File:Expiration\\_diagram.svg](http://commons.wikimedia.org/wiki/File:Expiration_diagram.svg)

## Chapter 20 Review Questions

1. Which of the following structures is not part of the upper respiratory system:
  - a. Nasal cavity
  - b. Larynx
  - c. Pharynx
  - d. Sinuses
  
2. Which 2 bones make up the floor of the nasal cavity:
  - a. Palatine and maxilla
  - b. Ethmoid and maxilla
  - c. Sphenoid and palatine
  - d. Maxilla and sphenoid
  
3. The posterior portion of the soft palate is known as:
  - a. Epiglottis
  - b. Larynx
  - c. Pharynx
  - d. Uvula
  
4. The Adam's apple is known as:
  - a. Cricoid cartilage
  - b. Thyroid cartilage
  - c. Arytenoids cartilage
  - d. Epiglottis
  
5. When the vocal cords relax they form a triangular space called the:
  - a. Glottis
  - b. Epiglottis
  - c. Uvula
  - d. Pharyngeal triangle
  
6. Which type of epithelium lines the trachea:
  - a. Simple squamous
  - b. Stratified squamous
  - c. Pseudostratified columnar
  - d. Simple cuboidal
  
7. Cells lining the alveoli secrete a soapy substance known as:
  - a. Mucous
  - b. Surfactant
  - c. Emulsifier
  - d. Cytosol

8. Which of the following is not a structure of the left lung:
- a. Superior lobe
  - b. Oblique fissure
  - c. Inferior lobe
  - d. Horizontal fissure
9. During resting inhalation:
- a. Volume increases and pressure decreases
  - b. Volume and pressure increase
  - c. Volume and pressure decrease
  - d. Volume decreases and pressure increases
10. Which of the following is not an accessory muscle of inspiration:
- a. External intercostals
  - b. Pectoralis minor
  - c. Sternocleidomastoid
  - d. Pectoralis major
11. At the base of the trachea is a structure known as:
- a. Secondary bronchi
  - b. Thyroid cartilage
  - c. Carina
  - d. Arytenoid cartilage

# Chapter 21

## Respiratory System Physiology

## Respiratory System Physiology

In the last chapter we covered the anatomy of the respiratory system as well as the mechanics of breathing. In this chapter we will look at breathing in more detail and explore how oxygen and carbon dioxide are transported in the blood and exchanged with the tissues.

### Measurement of Respiratory Rates and Volumes

The normal adult respiratory rate is about 12 to 18 breaths per minute. For children the rate is about 18-20 breaths per minute.

The volume of air moved into or out of the lungs in a resting inhalation or exhalation is known as tidal volume and is about 500 ml. If we multiply tidal volume by the number of breaths per minute we have the respiratory minute volume. For example in a resting adult:

$$\text{RMV} = \text{Breaths/min} \times \text{Tidal volume}$$

If breaths/min = 15 and tidal volume = 500 ml

Respiratory minute volume (RMV) = 7500 ml or 7.5 Liters

The respiratory minute volume indicates how much air has entered the respiratory system. However not all of the air inhaled reaches the alveoli. This is because of the air in the respiratory passages known as anatomic dead space. To calculate the amount of air reaching the alveoli:

$$\text{Alveolar ventilation} = \text{breaths per minute} \times (\text{Tidal volume} - \text{Anatomic dead space})$$

Anatomic dead space is usually 350 ml.

Example 1: Normal resting breathing

$$\text{AV} = 12 \times (500 - 350)$$

$$\text{AV} = 1800 \text{ ml or } 1.8\text{L}$$

Example 2: Rapid shallow breathing

$$\text{AV} = 20 \times (400 - 350)$$

$$\text{AV} = 1000 \text{ ml or } 1.0 \text{ L}$$

Can you see that less air reaches the alveoli with rapid shallow breathing than in normal resting breathing?

Respiratory volumes can be measured with a device called a spirometer. Besides tidal volume other volumes can be measured including inspiratory reserve volume and expiratory reserve volume.

Inspiratory reserve volume (IRV) is the maximum amount of air that can be inhaled in addition to tidal volume. IRV is usually about 3300 ml in males and 1900 ml in females.



Expiratory reserve volume (ERV) is the maximum amount of air that can be exhaled in addition to tidal volume. ERV is about 1000 ml.

Residual volume (RV) is the amount of air remaining in the lungs after a maximal exhalation. RV is about 1200 ml in males and 1100 in females.

Combining respiratory volumes gives us respiratory capacities. These include vital capacity, inspiratory capacity, functional residual capacity and total lung capacity.

Vital capacity is the maximal amount of air that can move in and out of the lungs in a single breath. It is the sum of tidal volume, inspiratory reserve volume and expiratory reserve volume. It is about 4800 ml in males and 3400 ml in females.

Inspiratory capacity is the amount of air that can move into the lungs after resting inhalation and exhalation. Inspiratory capacity is the sum of tidal volume and inspiratory reserve volume.

Functional residual capacity is the air remaining in the lungs after a resting inhalation and exhalation. Functional residual capacity is the sum of expiratory reserve volume and residual volume.

Total lung capacity is the total volume of air in the lungs. It is the sum of vital capacity and residual volume. It is about 6000 ml in males and 4500 ml in females.

## **Gas Laws**

Air moves into the lungs by means of changes in volume and pressure. Air is a combination of a number of gases. Air consists of nitrogen (78.6%), oxygen (20.9%), carbon dioxide (.04%) and a trace amount of other gases.

Air produces an atmospheric pressure of 760 mm Hg and this pressure is produced by a combination of gases. Each gas produces a pressure that is proportional to its amount in the whole. This is known as Dalton's Law.

The pressure each gas produces in the mixture of gases is known as the partial pressure of gas. We can represent the partial and total pressure of a gas such as air as follows:

$$P(\text{nitrogen}) + P(\text{oxygen}) + P(\text{water vapor}) + P(\text{carbon dioxide}) = P(\text{air}) = 760 \text{ mm Hg}$$

For example if oxygen produces 20.9% of the total pressure of air then 20.9% of 760 mm Hg is about 159 mm Hg. So the partial pressure of oxygen is 159 mm Hg. We can denote partial pressure as PO<sub>2</sub> or PCO<sub>2</sub>.

Partial pressure can be thought to be analogous to concentration. Henry's Law states that at a given temperature the amount of gas in a solution is directly proportional to the partial pressure of the gas. Gas, like other substances, follows a concentration gradient. We can say that gas follows a partial pressure gradient. For example oxygen will move from a PO<sub>2</sub> of 100 mm Hg to a PO<sub>2</sub> of 80 mm Hg.

## **Respiratory System Gas Exchange**

Air enters the respiratory tract and is warmed and humidified. It eventually reaches the alveoli and mixes with the air resident there. Thus alveolar air differs from atmospheric air. For example alveolar air contains more carbon dioxide than atmospheric air.

After reaching the alveoli gases diffuse across the respiratory membrane and into the surrounding capillaries. The PO<sub>2</sub> of alveolar air is about 104 mm Hg and the PCO<sub>2</sub> is about 40 mm Hg. The PO<sub>2</sub> deoxygenated blood is about 40 mm Hg and the PCO<sub>2</sub> is about 45 mm Hg. Oxygen and carbon dioxide both diffuse in opposite directions across the respiratory membrane. Oxygen diffuses from the alveolus to the blood (PO<sub>2</sub> of 104 mm Hg to PO<sub>2</sub> of 40 mm Hg) and carbon dioxide diffuses from the blood (PCO<sub>2</sub> of 45 mm Hg) to the alveolus (PCO<sub>2</sub> of 40 mm Hg) (figs. 21.1, 21.2).

Other factors affecting the diffusion of gases include the solubility, the size of the concentration gradient, and the surface area and thickness of the respiratory membrane.

The solubility of a gas in liquid is represented by the solubility coefficient. The solubility coefficient for oxygen is .024 and for carbon dioxide is .57. This means that carbon dioxide is much more soluble (or able to dissolve) in water than oxygen. Both oxygen and carbon dioxide are lipid soluble as well and can easily move across the respiratory membrane. Damage to the respiratory membrane tends to affect the diffusion of oxygen before affecting carbon dioxide due to the increased solubility of carbon dioxide. Internal oxygen levels can then decrease to dangerous levels. Giving supplemental oxygen helps to increase the concentration of oxygen and aid diffusion.

The respiratory membrane's total area is about 70 square meters. Some diseases can adversely affect the respiratory membrane. These include emphysema and lung cancer. Emphysema creates large chambers within the lung that decrease the surface area of the respiratory membrane. Lung cancer produces tumors that decrease surface area as well.

Partial pressure and the subsequent pressure gradient can change by increasing or decreasing alveolar ventilation. Breathing slowly and deeply lowers alveolar PCO<sub>2</sub> as more CO<sub>2</sub> exits the lungs with each breath.

Oxygenated blood leaves the pulmonary circulation and enters the systemic circulation for distribution to the tissues. The PO<sub>2</sub> of oxygenated blood is 104 mm Hg and the PCO<sub>2</sub> is 40 mm Hg in the pulmonary circulation. The oxygenated blood mixes with blood from the bronchial veins causing the PO<sub>2</sub> to decrease to 95 mm Hg. Blood leaving the pulmonary circulation and entering the systemic circulation has a PO<sub>2</sub> of 95 mm Hg.

Oxygenated blood eventually reaches the tissues. The intracellular PO<sub>2</sub> is about 40 mm Hg and decreases to about 20 mm Hg in the cells. Oxygen then diffuses down its partial pressure gradient into the interstitium and cells. The blood is now deoxygenated with a PO<sub>2</sub> of 40 mm Hg.

Carbon dioxide is produced in the cells as a byproduct of metabolism. Therefore the highest PCO<sub>2</sub> in the system is at the cells. The PCO<sub>2</sub> is about 46 mm Hg in the cells and about 45 mm Hg in the interstitium. The PCO<sub>2</sub> of oxygenated blood is about 40 mm Hg. Carbon dioxide diffuses from the interstitium to the blood. The resulting PCO<sub>2</sub> of deoxygenated blood leaving the tissues is then 45 mm Hg.

Deoxygenated blood returns to the lungs where the alveolar PCO<sub>2</sub> is about 40 mm Hg. Carbon dioxide then diffuses to the alveoli and is expelled with each exhaled breath.

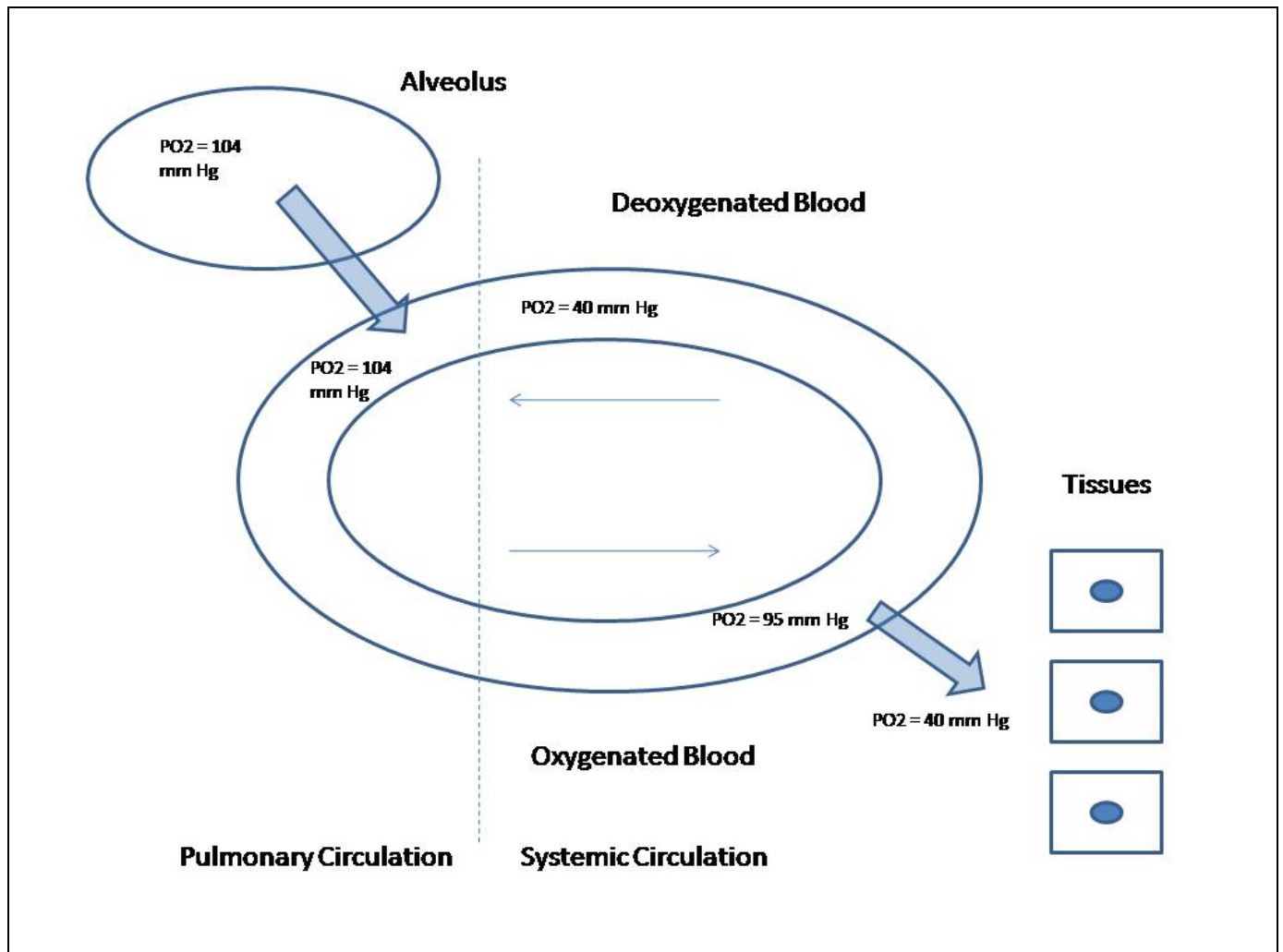


Figure 21.1. Respiratory gas exchange of oxygen. Oxygen diffuses from the alveolus ( $PO_2 = 104$  mm Hg) to deoxygenated blood ( $PO_2 = 40$  mm Hg). The  $PO_2$  of the capillary blood in the respiratory system increases to 104 mm Hg but then mixes with blood in the respiratory system which causes it to decrease to 95 mm Hg in the systemic circulation. Oxygen then travels to the tissues where it diffuses into the interstitium ( $PO_2 = 40$  mm Hg). The cycle then repeats.

Bruce Forciea

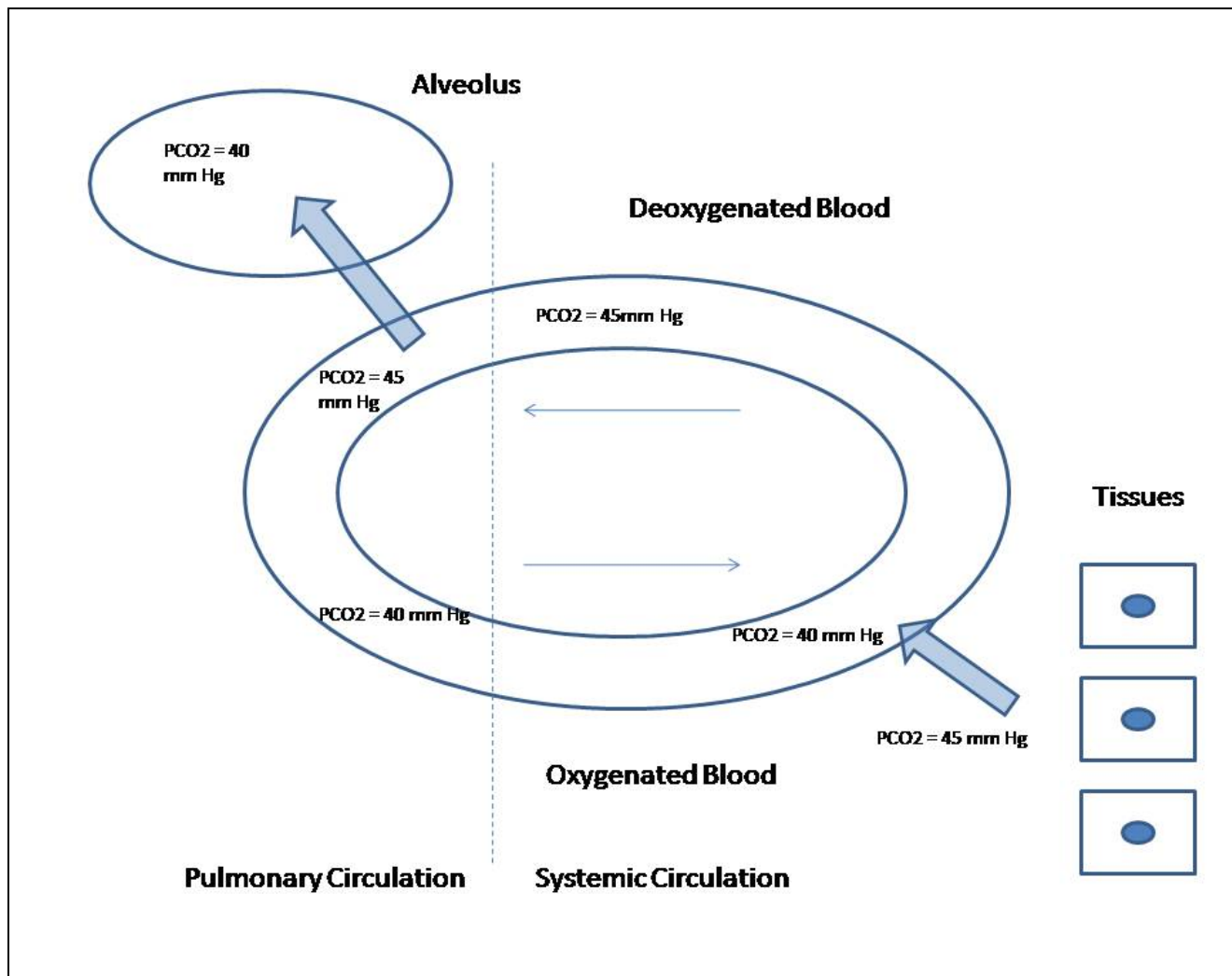



Figure 21.2 Respiratory gas exchange for carbon dioxide. Carbon dioxide is generated in the tissues ( $PCO_2 = 45$  mm Hg). Carbon dioxide diffuses from oxygenated blood ( $PCO_2 = 40$  mm Hg) to the tissues. The resultant deoxygenated blood has a  $PCO_2$  of 45 mm Hg. The blood travels to the lungs where it encounters an alveolar  $PCO_2$  of 40 mm Hg. Carbon dioxide then diffuses into the alveoli and is expelled during exhalation.

Bruce Forciea

## Carbon Dioxide Transport in the Blood

Carbon dioxide is transported in the blood by three mechanisms. These include carbon dioxide dissolved in plasma, carbon dioxide combining with hemoglobin and storage of carbon dioxide in the bicarbonate ion.

About 7% of the total carbon dioxide in blood is dissolved in plasma. Carbon dioxide also combines with hemoglobin to form a compound known as carbaminohemoglobin. About 23% of carbon dioxide is transported as carbaminohemoglobin. The majority of carbon dioxide (about 70%) is transported in the bicarbonate ion.



Carbon dioxide diffuses into red blood cells and encounters the enzyme carbonic anhydrase to form carbonic acid. Carbonic acid is an ionically bonded molecule that dissociates into bicarbonate and hydrogen ions. Bicarbonate ions diffuse out of the red blood cells into the plasma. In order to maintain ionic stability chloride ions move into the red blood cell. The movement of chloride in exchange for bicarbonate is called the chloride shift (fig 21.3).

The reaction is reversible with either the storage or release of carbon dioxide depending on what is needed. For example in areas of low PCO<sub>2</sub> such as in the alveoli the reaction will work in the direction to release CO<sub>2</sub> for removal by the lungs. In areas of high PCO<sub>2</sub> such as in the tissues the reaction will work in the direction to store CO<sub>2</sub> in the bicarbonate ion (fig. 21.4).

The hydrogen ions will bind to hemoglobin. Most of the hydrogen ions bind to hemoglobin which acts as a buffer to help to maintain a narrow range of blood pH.

## Respiratory Acidosis/Alkalosis

Because most of the carbon dioxide is transported by the bicarbonate ion with subsequent release of hydrogen ions, a buildup of carbon dioxide in the blood will produce a lower pH. Carbon dioxide and water combine to form carbonic acid in the blood. Carbonic acid dissociates into bicarbonate and hydrogen ions. If the respiratory system cannot release enough carbon dioxide the subsequent production of hydrogen ions makes the blood acidic. This is known as respiratory acidosis and can result from obstructive diseases such as emphysema or chronic bronchitis. You can generate a mild case of respiratory acidosis by simply holding your breath. The cells continue to produce carbon dioxide but the lungs are not removing it through exhalation. Carbon dioxide builds up in the lungs producing the hydrogen ion byproduct and the blood begins to become acidic.

Likewise you can produce a mild state of respiratory alkalosis by hyperventilating. In this case too much carbon dioxide is removed by the lungs and the hydrogen ion concentration subsequently decreases.

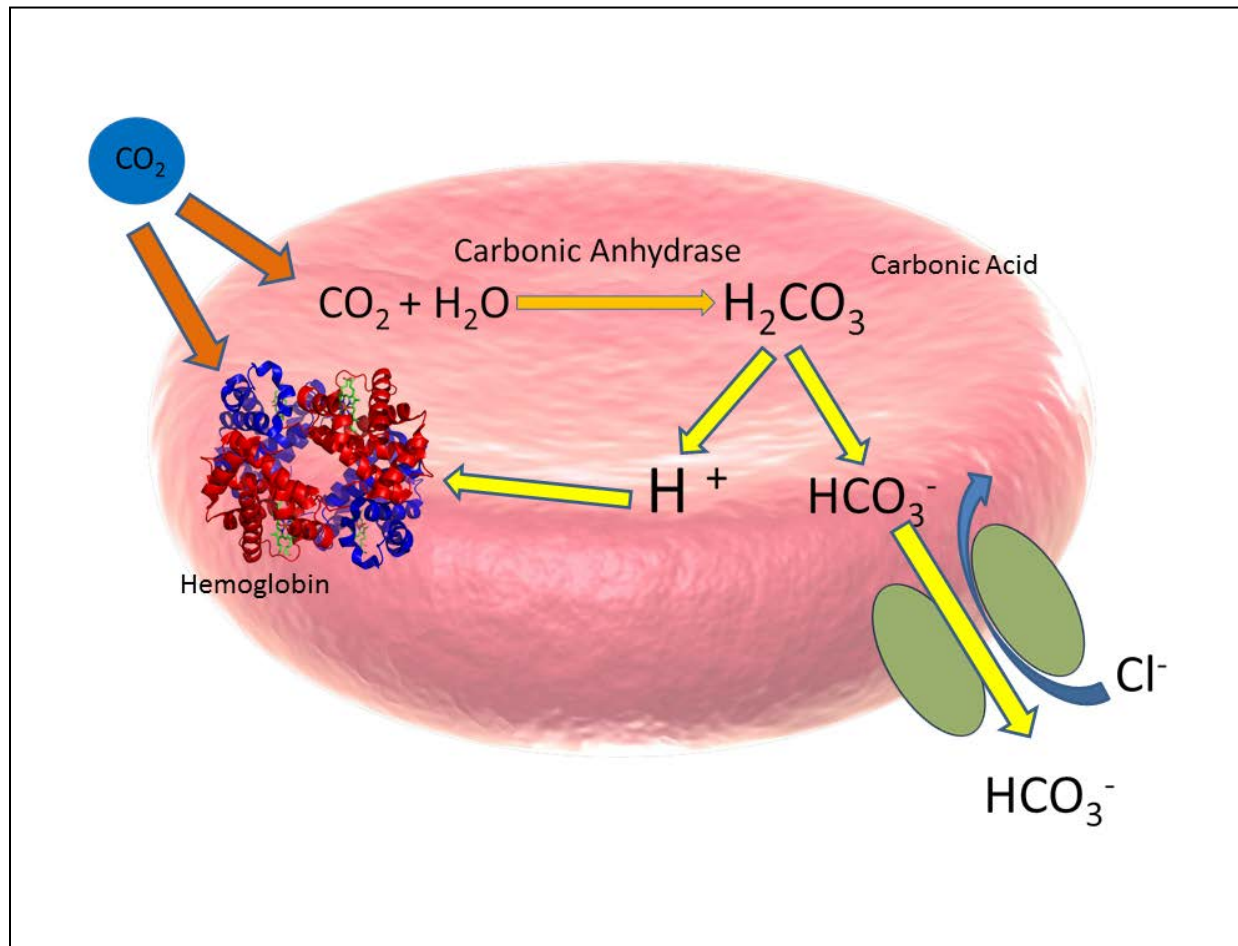


Figure 21.3. Storage of carbon dioxide in bicarbonate ions. Carbon dioxide combines with water and carbonic anhydrase to form carbonic acid that dissociates into bicarbonate and hydrogen ions. Bicarbonate moves out of the red blood cell with chloride ions moving in to maintain ionic stability. Hydrogen ions combine with hemoglobin. Carbon dioxide also enters the red blood cell and combines with hemoglobin. This process occurs in areas of high  $\text{PCO}_2$  where carbon dioxide needs to be transported.

## Oxygen Transport

Most of the oxygen transported in blood is bound to hemoglobin to form oxyhemoglobin. A small amount of oxygen is dissolved in plasma. Each hemoglobin molecule can bind with four oxygen molecules. Hemoglobin can also release oxygen to form deoxyhemoglobin. There are almost 300 million hemoglobin molecules in one red blood cell. The functional characteristics of hemoglobin are also variable and respond to changes in PO<sub>2</sub>, pH, and temperature.

The degree of oxygen binding to hemoglobin can be represented by what is known as an oxygen – hemoglobin saturation curve (fig. 21.25). If all of the hemoglobin is fully bound with oxygen molecules then the saturation is 100%.

By examining the saturation curve we can see that in areas of lower PO<sub>2</sub> hemoglobin tends to release oxygen. In other words we can say that hemoglobin decreases its affinity for oxygen binding. This makes sense because low areas of PO<sub>2</sub> such as in the tissues require free oxygen to diffuse into the interstitium and supply the cells. For example tissue PO<sub>2</sub> is about 40 mm Hg. At this PO<sub>2</sub> hemoglobin is about 75% saturated which means that about 23% of the oxygen bound to hemoglobin was released. The remaining 75% of oxygen acts like a reserve in case PO<sub>2</sub> goes even lower. In the tissues small changes in PO<sub>2</sub> can have a large affect on the release of oxygen. This helps to ensure that the tissues receive enough oxygen so they can function properly.

Likewise in areas of higher PO<sub>2</sub> we see that hemoglobin is almost completely saturated (about 98%). This means that hemoglobin increases its affinity for oxygen binding. Again it makes sense that hemoglobin would bind with oxygen in areas such as the alveolar capillaries so that oxygen can be carried to the tissues. For example alveolar PO<sub>2</sub> is about 104 mm Hg. By examining the curve we can see that hemoglobin is 98% saturated. Even if PO<sub>2</sub> drops to 80 mm Hg we see that hemoglobin is still 95.8% saturated.

The functional characteristics of hemoglobin can change. Hemoglobin saturation is affected by changes in pH, temperature and PCO<sub>2</sub>.

As pH decreases more free hydrogen ions are bound to hemoglobin changing its function and causing it to release oxygen more readily. In other words we can say that in areas of lower pH hemoglobin decreases its affinity for oxygen binding. Likewise in areas of increased pH will increase hemoglobin's affinity for oxygen binding. This change in binding affinity for oxygen is known as the Bohr effect (Christian Bohr).

Hemoglobin also changes with respect to carbon dioxide binding at the same time it changes for oxygen binding. As pH decreases hemoglobin increases its affinity for carbon dioxide binding. Likewise in areas of increased pH hemoglobin will decrease its affinity for carbon dioxide binding. These changes in hemoglobin function for carbon dioxide are known as the Haldane effect.

An increase in PCO<sub>2</sub> has the same effect as a decrease in pH. Hemoglobin again decreases its affinity for oxygen binding. Release of hydrogen ions and bound carbon dioxide work to produce this effect.

Increased temperatures also decrease hemoglobin's affinity for oxygen binding. Again hemoglobin works to release oxygen into the tissues during times of increased metabolism such as with exercise or fever.

The changes in hemoglobin's function with decreases in pH, increases in PCO<sub>2</sub> and temperature can be represented by a right shift in the saturation curve. Likewise in areas of higher pH, lower PCO<sub>2</sub> and decreased temperature hemoglobin resumes its normal function. We can say the saturation curve shifts to the left.

For example exercise will cause an increased metabolic demand in the tissues and subsequent need for oxygen supply and removal of carbon dioxide. PCO<sub>2</sub> increases in skeletal muscle tissue with a subsequent increase in hydrogen ion concentration resulting in a lower pH. Byproducts of anaerobic metabolism such as lactic acid also work to decrease pH.

The decrease in pH causes a right shift in the hemoglobin saturation curve. In other words hemoglobin works to release oxygen in the tissues and pick up carbon dioxide more readily. At the lungs however pH is in the normal range. Hemoglobin then works to release carbon dioxide and bind with oxygen for transport to the tissues. The saturation curve then shifts to the right in skeletal muscle and then back to the left in the lungs.

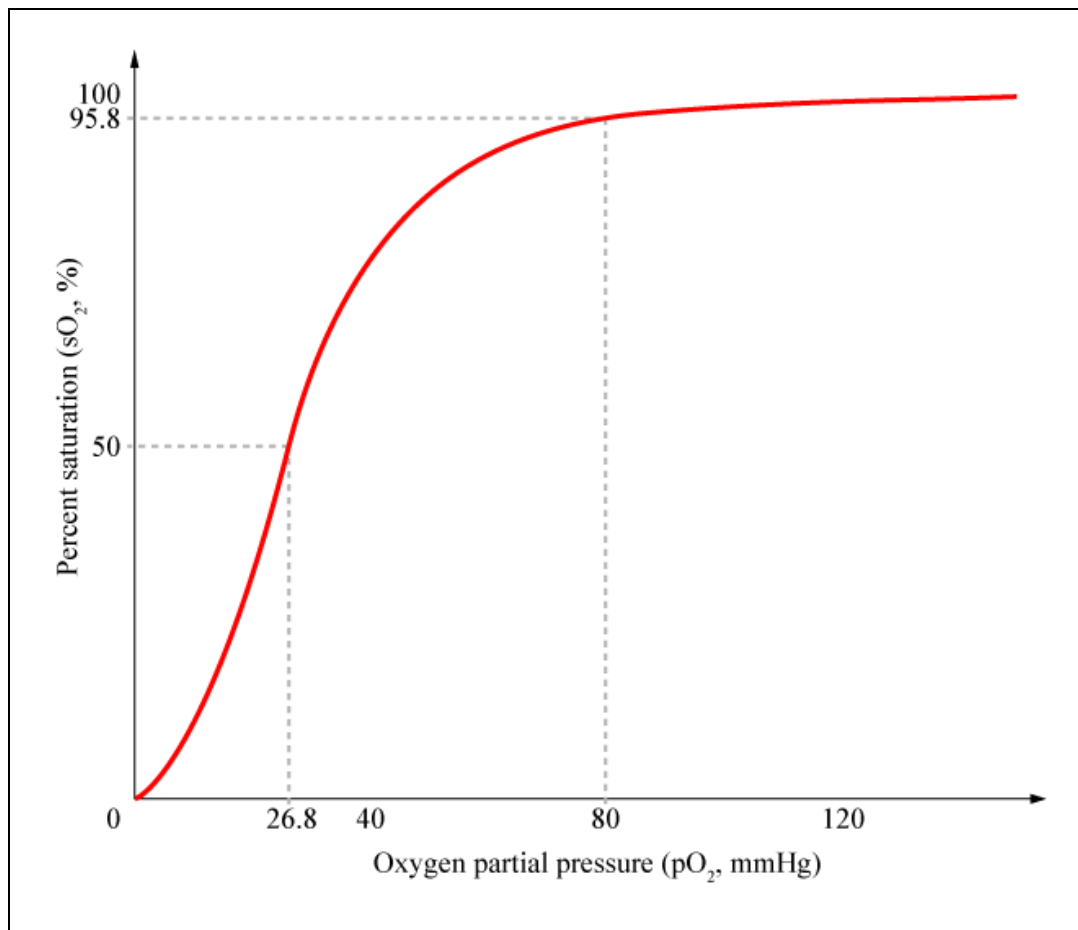


Figure 21.5. Oxygen-hemoglobin saturation curve.

[http://commons.wikimedia.org/wiki/File:Hb\\_saturation\\_curve.png](http://commons.wikimedia.org/wiki/File:Hb_saturation_curve.png)



## Neural Control of Respiration

Neural control of respiration begins in the brainstem at the medulla oblongata and the pons. The medulla contains the medullary respiratory center. The medullary respiratory center consists of two groups of neurons called the dorsal and ventral respiratory groups.

The dorsal respiratory group consists of two groups of neurons located in the posterior area of the medulla oblongata. This group is primarily responsible for contraction of the diaphragm for regulation of breathing rate. The neurons receive input from other parts of the brain and receptors that sense changes in concentrations of gases and pH.

The ventral respiratory group stimulates the external and internal intercostals and abdominal muscles. This group is active in forceful breathing.

The pons contains the pontine respiratory group. This center works with the centers in the medulla and helps to fine tune breathing rate and rhythm. The pneumotaxic center also receives input from other centers in the brain.

The apneustic center also resides in the pons. The pneumotaxic center inhibits the apneustic center to help control exhalation. However if damage to the brainstem occurs the person can exhibit what is known as apneustic breathing. This consists of a very slow respiration rate with a deep inhalation held for ten to twenty seconds followed by shallow and brief exhalations that provide little pulmonary ventilation.

All of the above respiratory centers innervate the phrenic and intercostals nerves.

## Neural Events of Breathing

For normal resting breathing the following neural events occur. The dorsal respiratory group becomes active causing contraction of the diaphragm and external intercostal muscles. Air moves into the lungs. The dorsal respiratory group is now inhibited causing relaxation of the respiratory muscles and passive exhalation.

For forceful breathing both the dorsal and ventral respiratory groups are active causing the respiratory muscles and accessory muscles to contract. Part of the ventral respiratory group that innervates the muscles of expiration is inhibited. Air moves into the lungs. The dorsal respiratory group is now inhibited while the ventral respiratory group is activated. The muscles of inspiration relax while the muscles of expiration contract. Air is expelled from the lungs.

## Other Neural Centers

Breathing is not entirely unconscious. We can decide to take in a deep breath or hold our breath. The cerebral cortex provides connections to the brainstem centers for breathing. The limbic system also affects breathing. For example strong emotions elicited in the limbic system can speed up breathing.

## Sensory Feedback for Breathing

Chemoreceptors that sense changes in concentration of  $PO_2$  and pH are involved in controlling respiration. These receptors are located in the medulla oblongata as well as the carotid and aortic bodies. The carotid bodies connect to the medulla via the glossopharyngeal nerve (CN IX). The aortic body connects to the medulla via the vagus nerve (CN X).

The medulla oblongata senses changes in pH by way of carbon dioxide diffusion. Increased blood levels of carbon dioxide result in an increased rate and depth of breathing. The respiratory centers are very sensitive to changes in PCO<sub>2</sub>. Small increases in PCO<sub>2</sub> can cause large increases in respiratory rate. A greater than normal PCO<sub>2</sub> is called hypercapnia while a lower than normal PCO<sub>2</sub> is called hypocapnia.

Neural respiratory centers are also sensitive to changes in PO<sub>2</sub> but changes in PCO<sub>2</sub> account for the majority of respiratory regulation. If PO<sub>2</sub> levels decrease while PCO<sub>2</sub> levels remain normal there will be a subsequent increase in respiration rate. A lower than normal PO<sub>2</sub> is called hypoxia. Small changes in PO<sub>2</sub> do not cause an appreciable stimulation of the respiratory centers.

#### Hering-Breuer Reflex

Another neural control mechanism is the Hering-Breuer reflex. This reflex is a protective mechanism and prevents overinflation of the lungs. Stretch receptors on the walls of the bronchi and bronchioles send impulses to the vagus nerve to the medulla oblongata. The impulses inhibit the respiratory centers and produce exhalation.

## Chapter 21 Review Questions

1. The typical volume of air moved in and out of the lungs in one minute in an adult is about:
  - a. 10 liters
  - b. 7.5 liters
  - c. 5.5 liters
  - d. 4 liters
2. A person is breathing 15 times per minute with a tidal volume of 400 ml. What is their alveolar ventilation:
  - a. 1 liter
  - b. 800 ml
  - c. 750 ml
  - d. 500 ml
3. Inspiratory capacity is represented by:
  - a. Inspiratory reserve volume and tidal volume
  - b. Vital capacity and tidal volume
  - c. Residual volume and tidal volume
  - d. Vital capacity and inspiratory reserve volume
4. Oxygen produces how much of the total pressure of air:
  - a. 50.2%
  - b. 30.4%
  - c. 20.9%
  - d. 12.7%
5. The PCO<sub>2</sub> of tissues is about:
  - a. 104 mm Hg
  - b. 45 mm Hg
  - c. 40 mm Hg
  - d. 95 mm Hg
6. Oxygen moves out of the alveoli and into the blood by way of:
  - a. Osmosis
  - b. Diffusion
  - c. Active transport
  - d. Filtration
7. Which of the following is not a transport mechanism for CO<sub>2</sub>:
  - a. Carbaminohemoglobin
  - b. Dissolved in plasma
  - c. Bonds with plasma proteins
  - d. Bicarbonate ion

8. Carbon dioxide combines with water and carbonic anhydrase to form:
  - a. Carbonic acid
  - b. Hemoglobin
  - c. Hydrogen ions
  - d. Tricarbonate
  
9. Holding your breath would cause a state of:
  - a. Respiratory alkalosis because of the buildup of hydrogen ions
  - b. Respiratory alkalosis because of the elimination of hydrogen ions
  - c. Respiratory acidosis because of the elimination of hydrogen ions
  - d. Respiratory acidosis because of the buildup of hydrogen ions
  
10. The oxygen-hemoglobin saturation curve represents:
  - a. Hemoglobin's affinity for oxygen binding in various partial pressures of oxygen
  - b. Hemoglobin affinity for oxygen binding over various times
  - c. Partial pressures of oxygen during various times
  - d. Hemoglobin's release of oxygen and carbon dioxide over time
  
11. The change in affinity for carbon dioxide binding in hemoglobin is known as:
  - a. Carbon dioxide release effect
  - b. Bohr effect
  - c. PCO<sub>2</sub> difference effect
  - d. Haldane effect
  
12. Which respiratory center causes slow, deep breathing when stimulated:
  - a. Ventral respiratory group
  - b. Dorsal respiratory group
  - c. Apneustic center
  - d. Pneumotaxic center

# Chapter 22

## Urinary System Anatomy

## Urinary System Anatomy

It would be difficult to deduce the function of the kidneys by performing a gross dissection. Their appearance is deceptively simple and yet they perform some extremely complex physiology. In this chapter we will begin our study of the urinary system. The urinary system consists of the kidneys, ureters, urinary bladder and urethra. The urinary system can be thought of as a kind of purification system for the blood. The system functions to maintain fluid, electrolyte and pH balance and remove toxins from the blood.

### The Big Picture

We can gain a good deal of insight into how the kidneys work by examining the inputs and outputs. Blood flows into the kidney and urine and blood flow out. So the kidneys must somehow make urine from blood. The blood enters via the renal artery and exits via the renal vein. The urine exits by way of the ureters and flows to the bladder, urethra and out of the body.

One of the simplest ways to make urine from blood is to filter the blood. This is actually the first stage of urine formation (filtration). Filters work by the movement of substances from areas of higher to lower pressure across a filtration membrane. The filtration membrane sorts substances based on size. One could think of it as being filled with holes. Smaller substances pass through the holes while larger substances do not. Smaller substances that are filtered include water, electrolytes and glucose.

There would be a problem if filtration were the only mechanism of urine formation. Our bodies need many of the filtered substances and they would be lost in the urine. So there must be some other mechanisms that help to maintain the balance. Fortunately there are and these include tubular reabsorption and secretion.

Tubular reabsorption and secretion work together to reclaim substances like water, glucose and electrolytes after they have been filtered. Tubular reabsorption employs a number of mechanisms in order to move filtered substances back into the blood. Tubular secretion also uses a number of mechanisms to move substances from the blood to the urine. Besides reclaiming filtered substances, both of these processes fine tune electrolyte, water and pH balance. We will cover these in detail in the next chapter on urinary physiology.

### Urinary System Functions

Besides maintaining fluid, electrolyte and pH balance the kidneys also monitor blood oxygen levels. They secrete the hormone erythropoietin in response to low oxygen levels. The hormone travels to the bone marrow to stimulate the production of red blood cells. The kidneys also work to control vitamin D synthesis.

### The Kidneys

The kidneys are paired organs located behind the peritoneal membrane (retroperitoneal) (fig. 22.1). They are bean shaped and about the size of an adult fist. They are located laterally in the flank area about the level of the twelfth thoracic vertebra to the third lumbar vertebra. A layer of adipose tissue called perirenal fat surrounds each kidney. The outer layer of the kidneys consists of a layer of fibrous connective tissue called the renal capsule. The kidneys are partially held in place by connective tissue connections called renal fascia that connect to the outer portion of the peritoneum. Each kidney has an

indentation called a hilum that opens to a renal sinus where the renal artery, vein and ureters enter and exit the kidney.

The inside of the kidney is divided into an outer cortical region (cortex) and an inner medulla (fig. 22.2). The medulla contains conical structures called the renal pyramid. Areas of the cortex called renal columns extend between the pyramids. The distal tip of the pyramid ends at the renal papilla. The renal papillae connect with minor calyces. The minor calyces combine to form larger major calyces that combine to form the renal pelvis that extends to form the ureter.

A renal artery supplies each kidney with blood. The renal artery branches off of the abdominal aorta and extends into the hilum of the kidney. The renal artery forms smaller branches called segmental arteries that form smaller interlobar arteries. The interlobar arteries flow through the renal columns and branch to form arcuate arteries which are located between the cortex and medulla. The arcuate arteries branch to form interlobular arteries that travel in the cortex. The interlobular arteries then branch to form afferent arterioles that supply the functional unity of the kidney known as the nephron.

Exiting the nephron is the efferent arteriole. The efferent arterioles of nephrons feed the interlobular veins that empty into the arcuate veins. The arcuate veins empty into the interlobular veins which empty into the renal vein.

The kidneys also have a nerve supply. The renal nerves which are sympathetic postganglionic neurons from the celiac plexus and inferior splanchnic nerves innervate the kidneys.

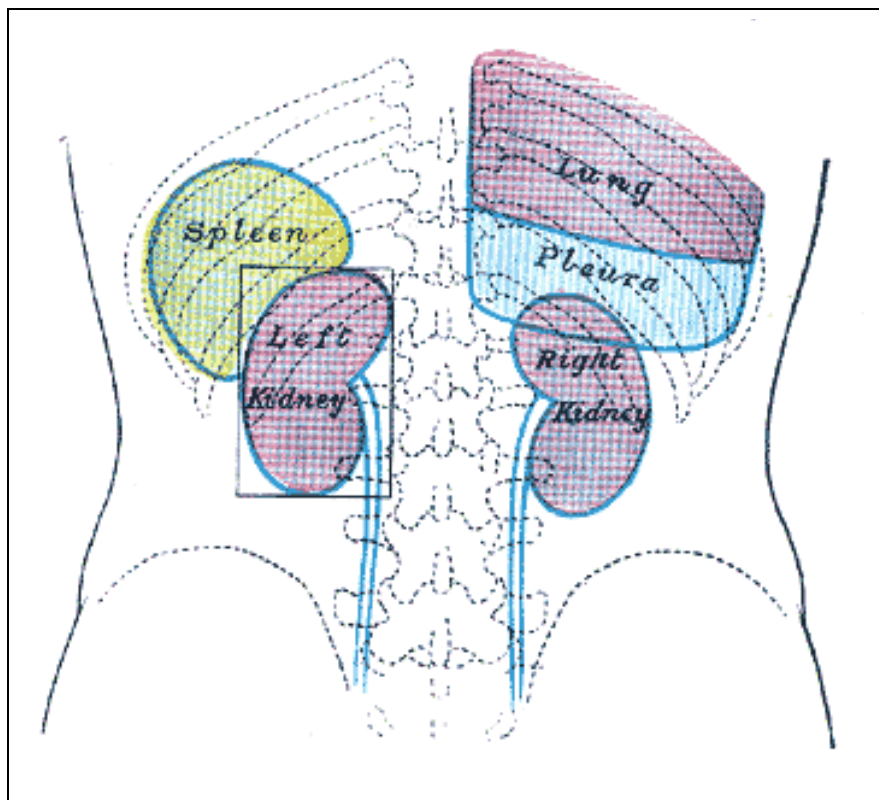


Figure 22.1. Location of the kidneys.

<http://commons.wikimedia.org/wiki/File:Gray1226.png>

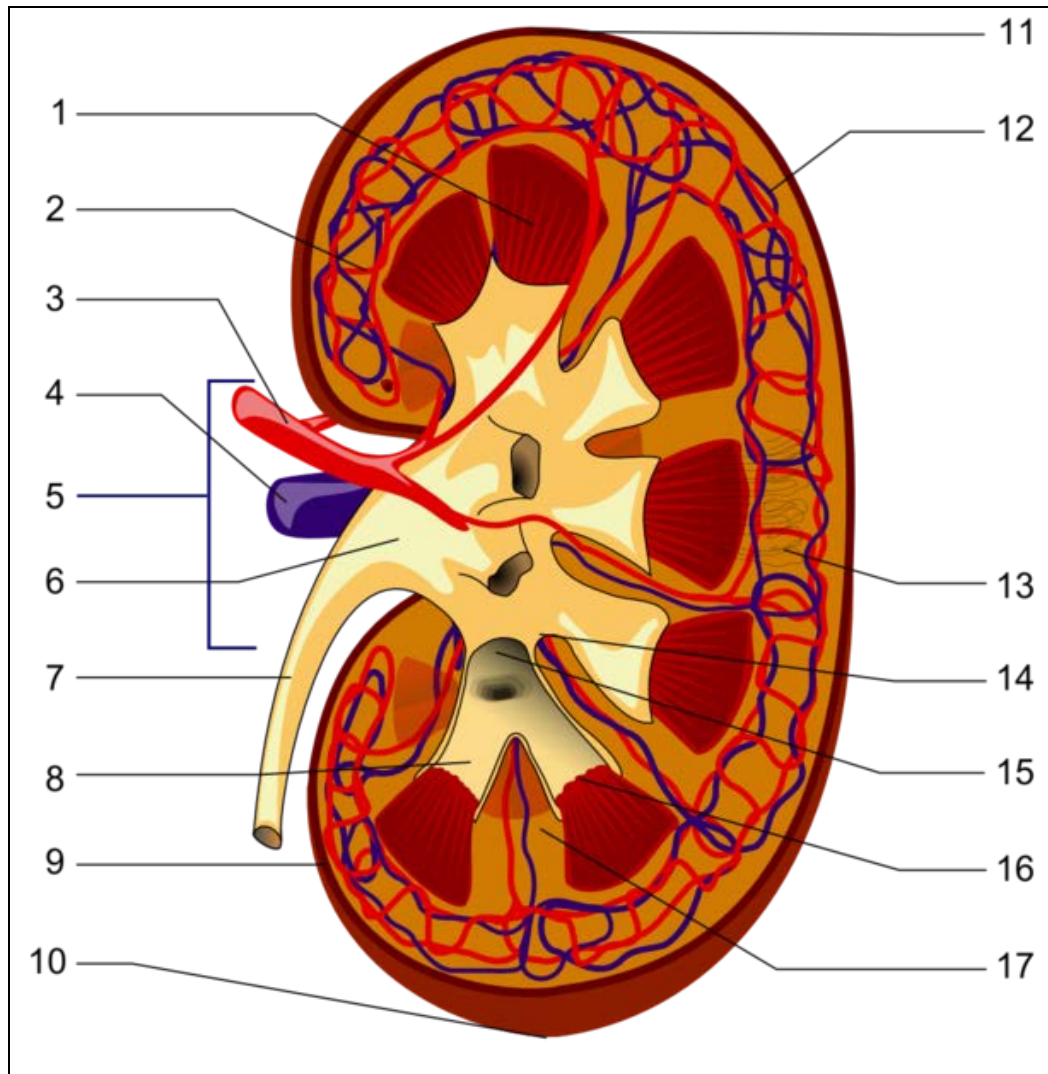


Figure 22.2. Structures of the kidney:

1. Renal pyramid
2. Interlobar artery
3. Renal artery
4. Renal vein
5. Renal hilum
6. Renal pelvis
7. Ureter
8. Minor calyx
9. Renal capsule
10. Inferior renal capsule
11. Superior renal capsule
12. Interlobar vein
13. Nephron
14. Minor calyx
15. Major calyx
16. Renal papilla
17. Renal column

[http://commons.wikimedia.org/wiki/File:Kidney\\_PioM.png](http://commons.wikimedia.org/wiki/File:Kidney_PioM.png)

Author: Piotr Michał Jaworski



## The Nephron

The functional unit of the kidney is a microscopic structure known as the nephron. There are over one million nephrons in one kidney. Some nephrons lie near the medulla and are called juxtamedullary nephrons. These nephrons extend deep into the medulla. Other nephrons reside in the cortex and only minimally extend into the medulla. These are known as cortical nephrons (fig. 22.3).

The nephron consists of a renal tubule and a renal corpuscle. The renal corpuscle is a spherical structure that consists of a capillary network called the glomerulus surrounded by a fibrous capsule called the glomerular capsule (Bowman's capsule). The capillary network is fed by an afferent arteriole. Blood exiting the nephron flows through the efferent arteriole and peritubular capillaries that surround the nephron. The glomerulus and glomerular capsule is where filtration occurs (fig. 22.4).

The glomerular capsule consists of two layers. The outer layer or parietal layer consists of simple squamous epithelium. The inner layer or visceral layer contains special cells called podocytes. Between the podocytes and the capillaries is a thin basement membrane. The podocytes surround the glomerular capillaries. Small openings between the podocytes called filtration slits act as holes in a filter. The glomerular capillaries also contain small openings called fenestrae. The combined action of these structures is to act as a filter.

The filtrate from the glomerular capsule flows through the first part of the renal tubule known as the proximal convoluted tubule. The renal tubule is lined with cuboidal epithelium and a basement membrane with the exception of the ascending limb of the nephron loop. The renal tubule performs reabsorption and secretion of substances. Substances are selectively moved from the tubule to the peritubular capillaries or from the peritubular capillaries to the tubule. Fluid then moves through the nephron loop (loop of Henle). The nephron loop has a descending and ascending limb, each with different tissue characteristics (we will cover this in the next chapter). The ascending limb is lined with simple squamous epithelium in the lower section that again becomes simple cuboidal epithelium in the thick section. Surrounding the nephron loop are capillaries known as vasa recta.

After flowing through the nephron loop the fluid flows through the distal convoluted tubule and past the juxtaglomerular apparatus which consists of a group of cells that reside between the distal convoluted tubule and afferent arteriole. The juxtaglomerular apparatus monitors blood solute concentration as well as the concentration of the urine. It aids in regulating fluid volume and blood pressure.

Fluid (urine) then drains from the distal convoluted tubule into the collecting duct. Urine from many nephrons drains into one collecting duct. The collecting duct merges with other collecting ducts at the renal papilla. Urine flows from the renal papilla to the minor calyces which combine to form major calyces which combine to form the renal pelvis. Urine now flows into the ureter and to the urinary bladder, urethra and out of the body.

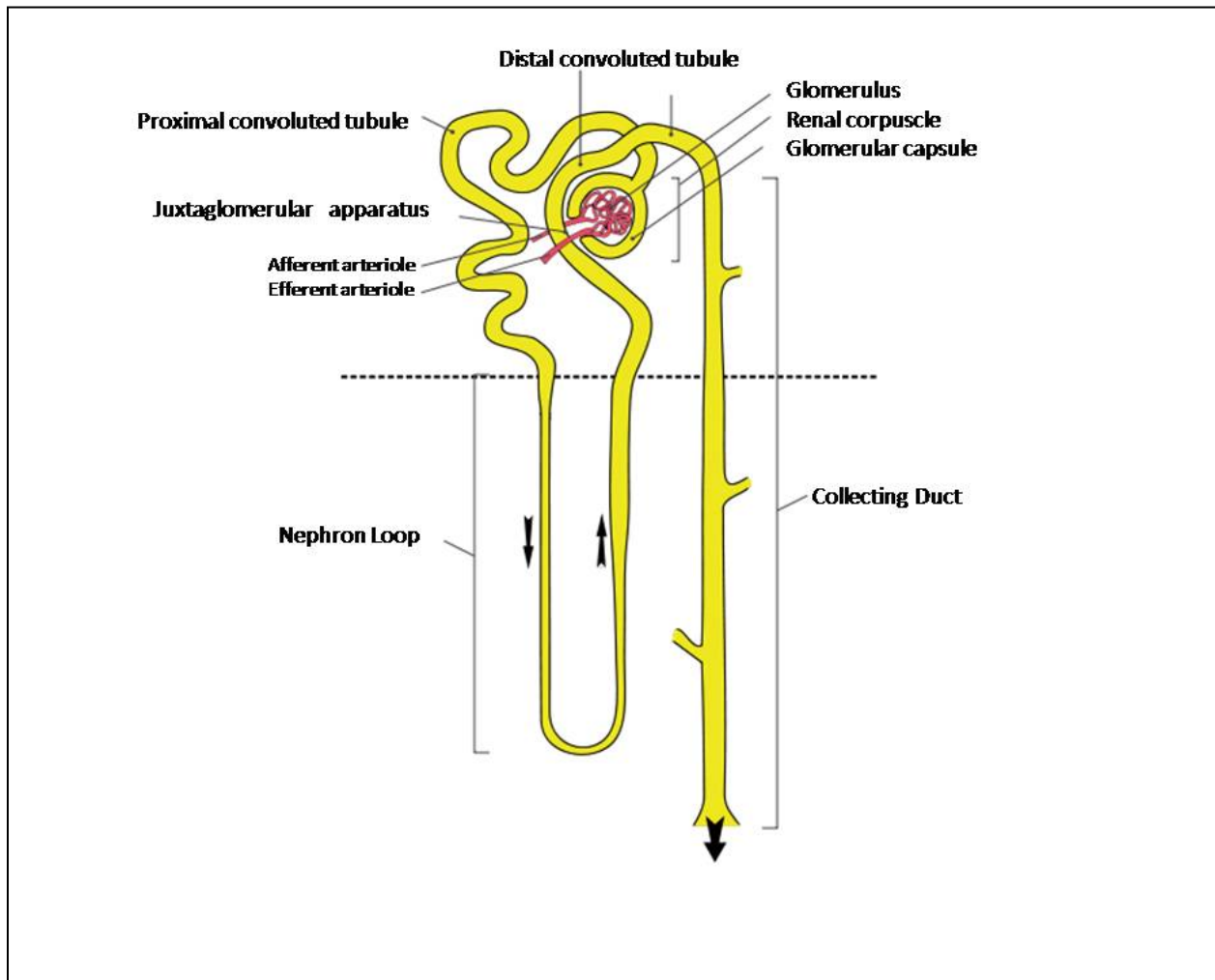


Figure 22.3. Nephron

[http://commons.wikimedia.org/wiki/File:Nephron\\_blank.svg](http://commons.wikimedia.org/wiki/File:Nephron_blank.svg)

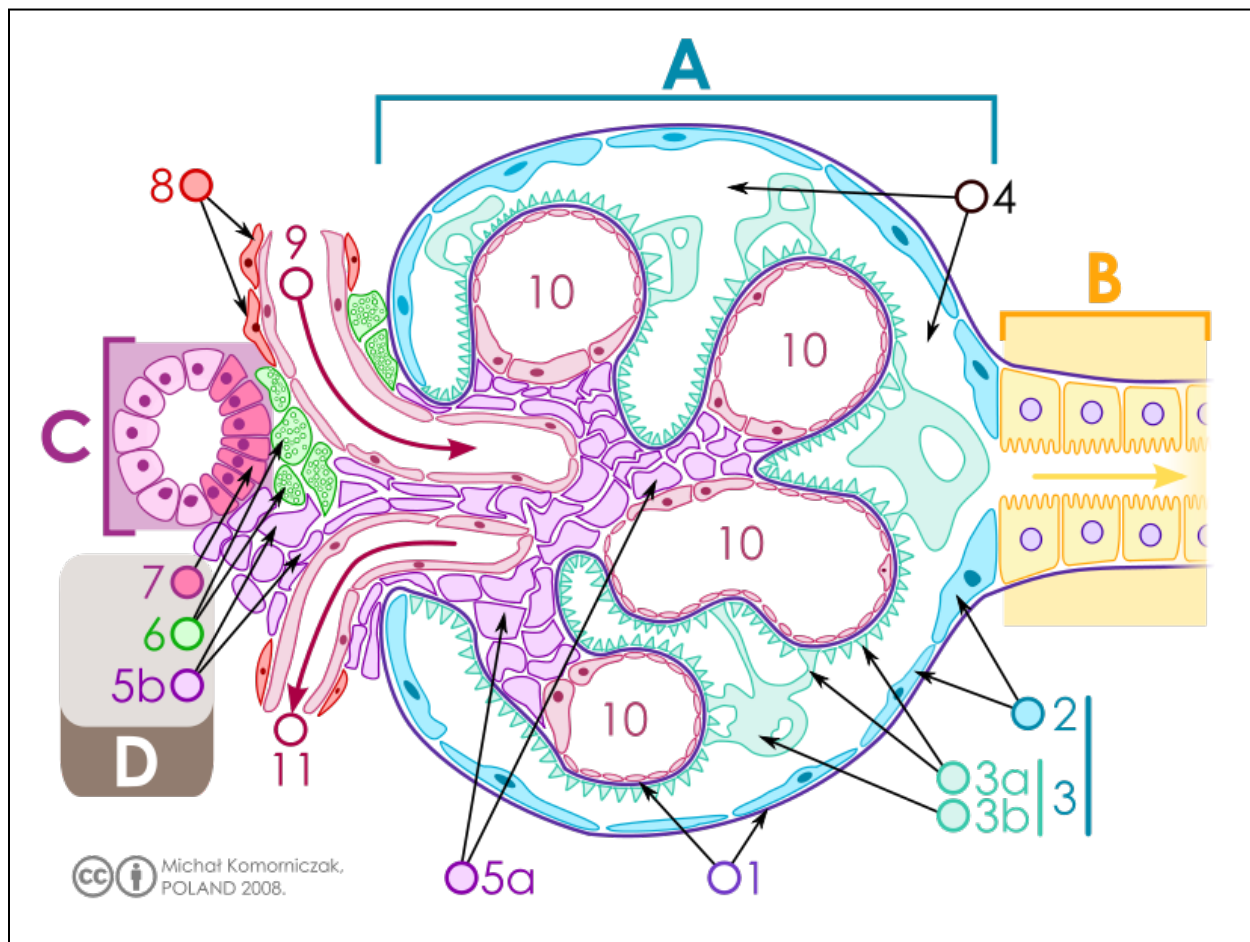


Figure 22.4. Diagram of [renal corpuscle](#) structure:

- |                                       |   |
|---------------------------------------|---|
| A - Renal corpuscle                   | 4. Bowman's space (urinary space)         |
| B - Proximal tubule                   | 5a. Mesangium - Extraglomerular cell      |
| C - Distal convoluted tubule          | 5b. Mesangium - Intraglomerular cell      |
| D - Juxtaglomerular apparatus         | 6. Granular cells (Juxtaglomerular cells) |
| 1. Basement membrane (Basal lamina)   | 7. Macula densa                           |
| 2. Bowman's capsule - parietal layer) | 8. Miocytes (smooth muscle)               |
| 3. Bowman's capsule - visceral layer  | 9. Afferent arteriole                     |
| 3a. Podocyte                          | 10. Glomerulus Capillaries                |
| 3b. Pedicels (podocyte's)             | 11. Efferent arteriole                    |

[http://commons.wikimedia.org/wiki/File:Renal\\_corpuscle.svg](http://commons.wikimedia.org/wiki/File:Renal_corpuscle.svg)

Author: Michał Komorniczak

## **The Ureters, Bladder, Urethra**

The ureters carry the urine from the kidney to the bladder. They exit the kidneys at the hilum and extend inferiorly and medially to the bladder. The ureters have a smooth muscle layer that is capable of producing peristaltic contractions that occur once every two to three minutes. The parasympathetic nervous system increases these contractions and the sympathetic nervous system inhibits them.

The urinary bladder is a hollow organ that resides in the pelvic cavity (fig. 22.5). The ureters connect at the posterolateral surface. The urethra carries the urine from the bladder out of the body. The area on the inside of the bladder between the two ureter connections and the urethra is called the trigone.

The urinary bladder and ureters are internally lined with transitional epithelium. Transitional epithelium is a special kind of epithelium that allows for the cells to slide past each other during distension of the bladder. The bladder also has a thick smooth muscle layer sometimes called the detrusor muscle. Contraction of the detrusor muscle increases the internal pressure of the bladder and causes urine to be expelled.

Male bladders contain an area of smooth muscle and elastic tissue called the internal urinary sphincter. This area is not present in females. The function of this structure is to keep semen from entering the urinary bladder during intercourse. Both males and females have an external urinary sphincter located in the urethra that controls the flow of urine (fig. 22.6).

The male urethra consists of three parts. The prostatic urethra exits the bladder and extends to the inferior prostate gland. It then becomes the membranous urethra until it enters the penis where it becomes the penile urethra (fig. 22.8).

## **Micturation**

Urine continuously flows from the kidney to the bladder. The bladder acts as a storage reservoir for urine and can store up to 1 liter. At about 300 ml the urge to urinate becomes evident. Once the wall is stretched the micturation reflex is stimulated. Stretch of the bladder sends impulses to sensory neurons in the pelvic nerves to the sacral segments of the spinal cord. Micturation is under parasympathetic control and parasympathetic impulses cause the bladder to contract. The motor impulses for micturation originate in a micturation center in the pons. The center also receives input from the cerebral cortex (so one can decide whether to micturate). Contraction of the bladder increases the internal pressure pushing urine into the urethra.

The micturation reflex is an involuntary reflex in infants. Voluntary control of the reflex does not occur until around age 2-3 years.

## Urinary Bladder

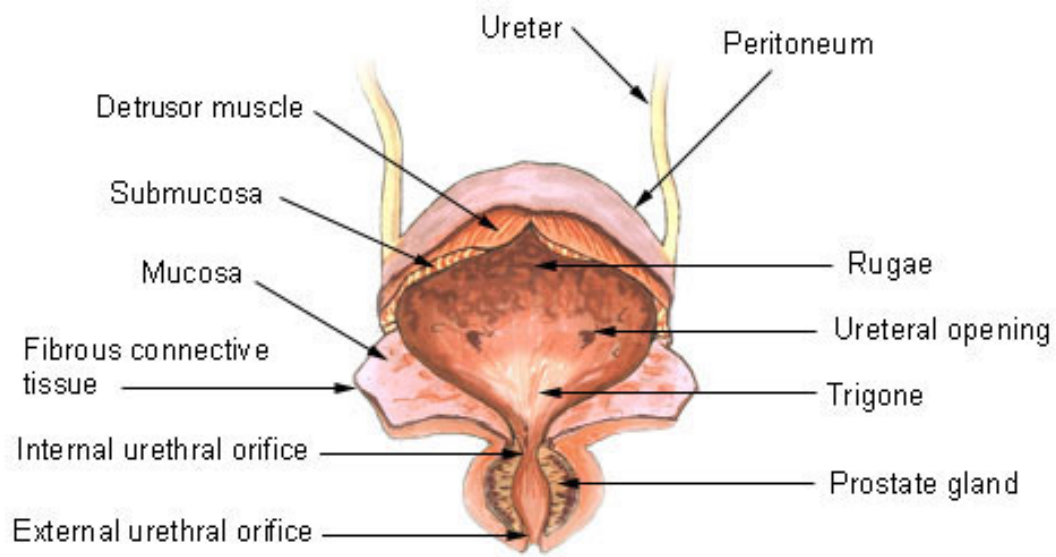


Figure 22.5. Urinary Bladder

[http://commons.wikimedia.org/wiki/File:Illu\\_bladder.jpg](http://commons.wikimedia.org/wiki/File:Illu_bladder.jpg)

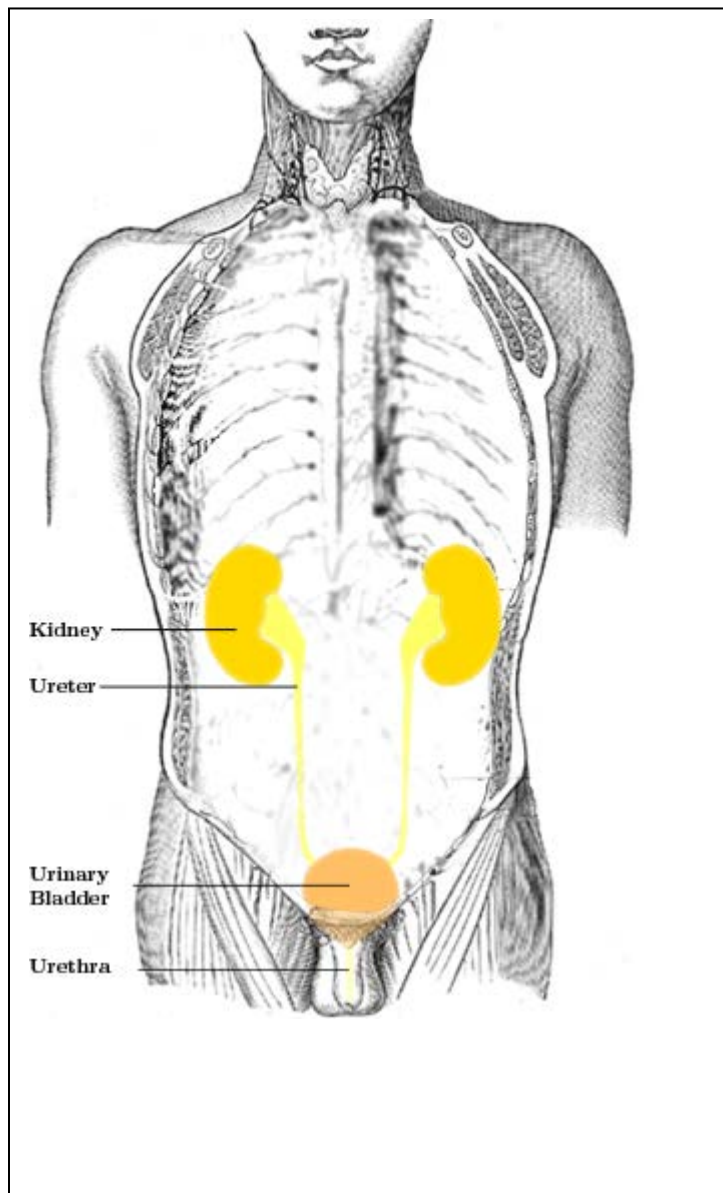


Figure 22.6. Male Urinary System

[http://commons.wikimedia.org/wiki/File:Urinary\\_tract\\_en.png](http://commons.wikimedia.org/wiki/File:Urinary_tract_en.png)

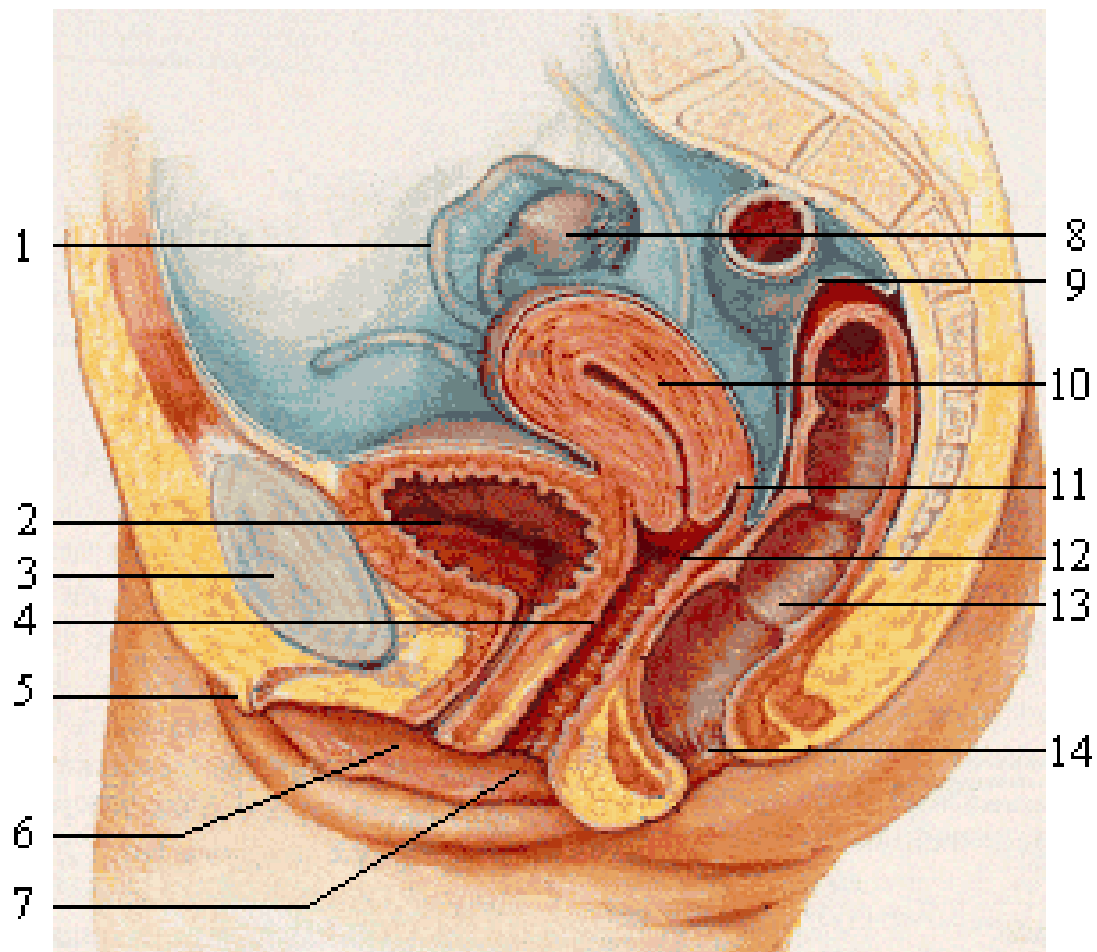


Figure 22.7. Female urinary system.

- 1: fallopian tube
- 2: bladder
- 3: pubic bone (pubic symphysis)
- 4: g-spot
- 5: clitoris
- 6: urethra
- 7: vagina
- 8: ovary
- 9: sigmoid colon
- 10: uterus
- 11: fornix of vagina (including anterior and posterior)
- 12: cervix
- 13: rectum
- 14: anus

[http://commons.wikimedia.org/wiki/File:Female\\_reproductive\\_system\\_lateral\\_nolabel.png](http://commons.wikimedia.org/wiki/File:Female_reproductive_system_lateral_nolabel.png)

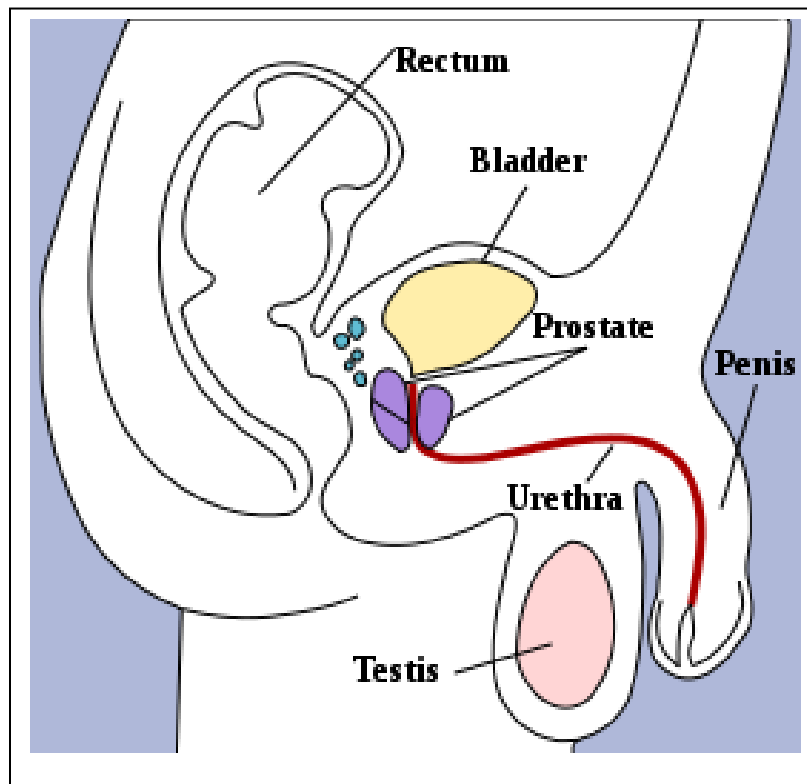


Figure 22.8. Male Urethra

<http://commons.wikimedia.org/wiki/File:Penis.svg>



## Chapter 22 Review Questions

1. Which of the following is not a function of the urinary system:
  - a. Maintain electrolyte balance
  - b. Control blood pressure
  - c. Remove wastes
  - d. Provide nutrition to the body
2. At the tip of each renal pyramid is a structure known as:
  - a. Major calyx
  - b. Renal column
  - c. Renal papilla
  - d. Distal convoluted tubule
3. Urine flows from the proximal convoluted tubule to this structure in the nephron:
  - a. Collecting duct
  - b. Glomerulus
  - c. Afferent arteriole
  - d. Nephron loop
4. Which of the following is not a mechanism of urine formation:
  - a. Enzymatic action
  - b. Filtration
  - c. Tubular reabsorption
  - d. Tubular secretion
5. Which best describes the location of the kidneys:
  - a. Flank area in the peritoneal cavity
  - b. Inguinal area outside of the pelvic cavity
  - c. Retroperitoneal flank area
  - d. Just below 12<sup>th</sup> rib in the midline
6. Which type of tissue lines the inside of the bladder:
  - a. Transitional epithelium
  - b. Stratified squamous epithelium
  - c. Skeletal muscle
  - d. Dense connective tissue
7. Micturation is controlled by:
  - a. Sympathetic nervous system
  - b. Diencephalon
  - c. Parasympathetic nervous system
  - d. Pons

8. Blood leaves the nephron via:
- a. Efferent arteriole
  - b. Renal artery
  - c. Acuate arteries
  - d. Afferent arteriole
9. Which of the following is not a part of the male urethra:
- a. Penile
  - b. Prostatic
  - c. Membraneous
  - d. Corpus
10. The female urethra is about how long:
- a. 1 cm
  - b. 5 cm
  - c. 4 cm
  - d. 3 cm

# Chapter 23

## Urinary System Physiology

## Urinary Physiology

This chapter will focus on the function of the urinary system. We will investigate the process of urine formation as well as how the kidneys help to control fluid and electrolyte volume.

In the last chapter we presented a brief overview of three processes of urine formation. These included filtration, tubular reabsorption and tubular secretion. You may wish to review the “Big Picture” section in the previous chapter before getting into the detail here.

We will begin with filtration (glomerular filtration).

### Glomerular Filtration

Recall that the structures of the glomerulus and glomerular capsule act together as a filter. They filter the blood removing water and small substances small enough to fit through the filtration slits in the glomerular capsule. Larger substances such as blood cells and plasma proteins remain in the blood. We can describe the amount of blood that passes through the kidneys as a percentage of cardiac output. This is known as renal fraction. For example the renal fraction is between 12% and 30% of total cardiac output. It normally averages about 20% which works out to a rate of blood flow of about 1.1 liters per minute. Also if blood consists of about 55% plasma then we can determine the amount of plasma flowing through the kidney in one minute which is about 616 ml. This is known as the renal plasma flow rate (fig. 23.1).

The portion of the plasma that is filtered produces a filtrate known as the filtration fraction. The filtration fraction is about 20% of the plasma flowing into the filter. This works out to  $616\text{ml} \times .2$  or about 123 ml per minute. So the kidneys produce about 123 ml of filtrate per minute. This is called the glomerular filtration rate. That means that in one day the kidneys produce  $(123 \times 60 \times 24)$  177 L per day. We usually round this up to about 180 L per day. That's a lot of filtrate.

We don't urinate 180 L per day so much of that filtrate is reabsorbed via tubular reabsorption. We usually produce about 1L to 2L of urine per day. That means that only about 1% of the filtrate actually becomes urine. The rest is reabsorbed.

The glomerular filter consists of an input (glomerular capillaries), an output (glomerular capsule) and a filtration membrane (podocytes, fenestrae, basement membrane). The filtration membrane is very permeable and allows small substances of less than 7nm through. These include water, glucose, and electrolytes. Larger substances such as plasma proteins and cells do not pass through the membrane.

In order to move substances through the filter there must be a pressure gradient. Substances must move from an area of higher pressure to lower pressure. The pressure gradient is called filtration pressure or net filtration pressure. Net filtration pressure is directly proportional to the glomerular filtration rate. So if for some reason net filtration increases or decreases, so does glomerular filtration rate, and so does the amount of filtrate produced.

Net filtration pressure is the combination of a series of pressures that exist in the renal corpuscle. These include glomerular capillary hydrostatic pressure, glomerular capsular hydrostatic pressure and colloid osmotic pressure.

Glomerular capillary hydrostatic pressure is the blood pressure inside the capillaries. It is usually about 50 mm Hg and must be greater than the pressure inside the glomerular capsule known as glomerular capsular hydrostatic pressure.

The glomerular capillary hydrostatic pressure is controlled in part by the diameter of the afferent and efferent arterioles. The efferent arterioles have a smaller diameter than the afferent arterioles. The smaller diameter works to decrease blood flow through the efferent arterioles increasing the pressure inside the glomerular capillaries. Changing the diameter of the afferent and efferent arterioles changes the glomerular capillary hydrostatic pressure. For example, increasing the diameter of the afferent arteriole or decreasing the diameter of the efferent arteriole increases the capillary pressure.

The pressure inside the glomerular capsule is called the glomerular capsular hydrostatic pressure. This pressure is created by fluid inside the capsule as well as downstream in the tubules. It is usually about 10 mm Hg. The glomerular capsular hydrostatic pressure works against filtration.

Colloid osmotic pressure is produced by the presence of plasma proteins in the urine called colloids. The colloids produce a pulling force causing water to move back into the glomerular capillaries. This pressure is usually about 30 mm Hg.

We can calculate the net filtration pressure by the following:

Net Filtration Pressure = Glomerular capillary hydrostatic pressure – Glomerular capsular hydrostatic pressure – Colloid osmotic pressure

If we plug in the normal values:

$NFP = 50 \text{ mm Hg} - 10 \text{ mm Hg} - 30 \text{ mm Hg}$

$NFP = 10 \text{ mm Hg}$

So the net filtration pressure is about 10 mm Hg.

The kidneys are constantly working to keep the amount of filtrate relatively constant despite changes in mean arterial pressure. For example as systemic blood pressure increases the afferent arterioles vasoconstrict keeping the glomerular capillary hydrostatic pressure constant. Likewise when blood pressure decreases the afferent arteriole dilates.

The sympathetic nervous system affects the afferent arteriole by causing it to vasoconstrict under intense sympathetic activity such as when exercising strenuously or when in shock. Mild to moderate changes in sympathetic activity have little effect on glomerular filtration rate.

The prostaglandin E2 (PGE2) works to counteract the effects of intense sympathetic stimulation by promoting vasodilation.

Colloid osmotic pressure can also be affected by changes in the filtration membrane. If the kidneys become damaged such as with glomerular nephritis, the filtration membrane allows the passage of plasma proteins (a condition known as proteinuria). Loss of plasma proteins causes a decrease in systemic colloid osmotic pressure. Fluid then moves from the plasma into the interstitium causing systemic edema.

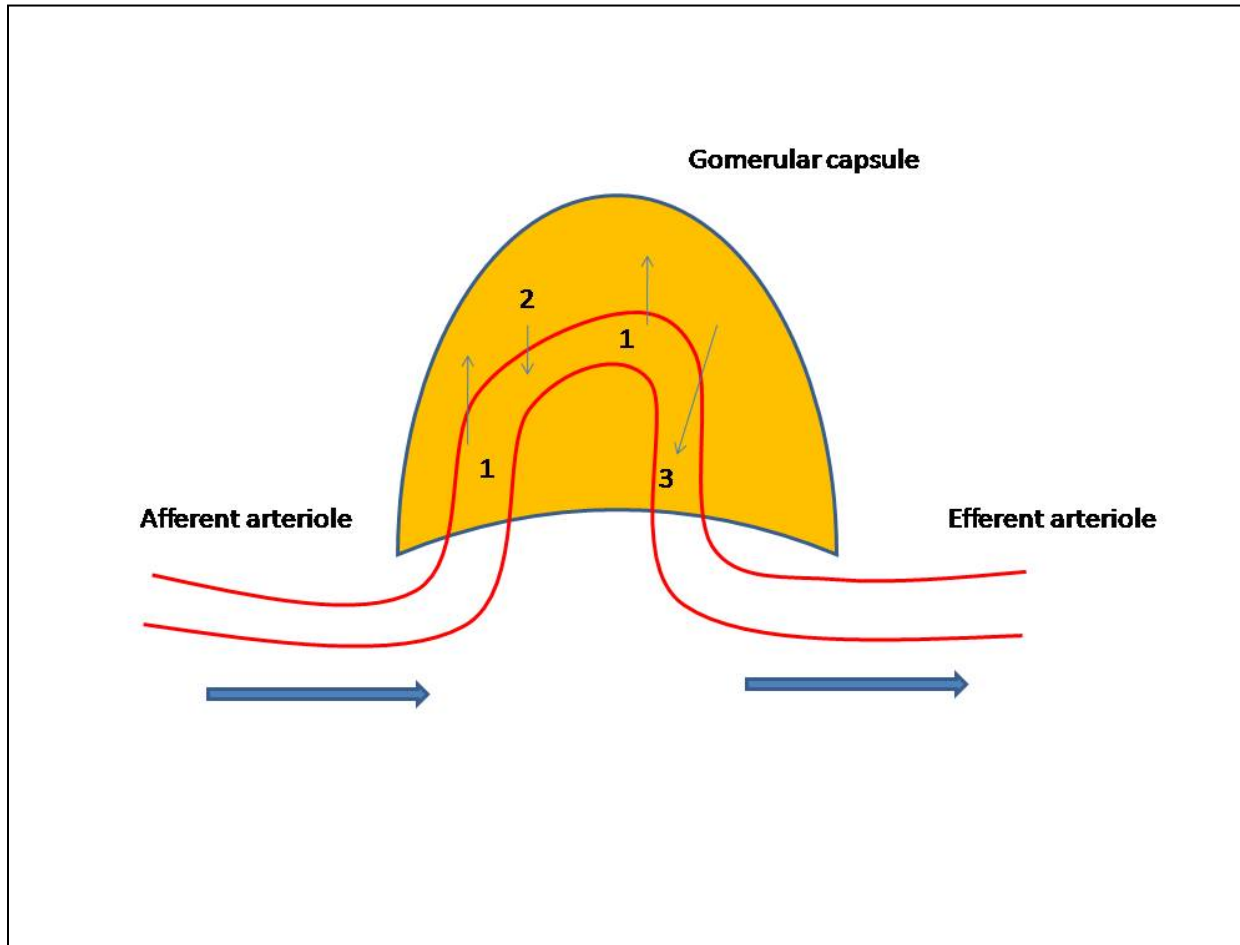


Figure 23.1. Glomerular filtration. 1. Glomerular capillary hydrostatic pressure. 2. Glomerular capsular hydrostatic pressure. 3. Colloid osmotic pressure

Bruce Forciea

## The Juxtaglomerular Apparatus

The juxtaglomerular apparatus is a group of cells residing at the junction of the afferent arteriole and distal ascending limb of the nephron loop. The juxtaglomerular apparatus consists of two different types of cells. Juxtaglomerular cells are located on the afferent arteriole side. These are granulated cells containing renin. These cells secrete renin in response to decreases in blood pressure and decreased urine solute concentration. Macula densa cells are located on the nephron loop side. These cells secrete nitric oxide in response to changes in urine solute concentration.

Renin is secreted by the juxtaglomerular cells in response to a decrease in systemic blood pressure lower than 80 mm Hg. The cells act as a kind of mechanoreceptor that monitors stretch of the afferent arteriole. The cells secrete renin in response to decreased stretch. Renin is also secreted in response to feedback from the macula densa cells when the macula densa cells sense decreases in solute concentration of urine (fig. 23.2).

Renin activates the renin-angiotensin mechanism (see cardiac physiology chapter). Renin acts like an enzyme to allow the conversion of angiotensinogen to angiotensin I. Angiotensin I is converted to angiotensin II by the angiotensin converting enzyme (ACE) located in capillary endothelium (especially in the lungs). Angiotensin II has a number of actions.

Angiotensin II produces systemic vasoconstriction, causes sodium reabsorption in the kidney tubules both directly and through the action of aldosterone, and stimulates the hypothalamus to release antidiuretic hormone (ADH).

The combined actions of angiotensin II work to retain fluid volume and consequently raise blood pressure. Fluid volume increases by way of increased reabsorption of sodium. Water follows sodium from the kidney tubules to the interstitium and blood thereby increasing blood volume and blood pressure.

Angiotensin II also promotes vasoconstriction. Systemic vasoconstriction produces increased peripheral resistance thereby increasing blood pressure. Vasoconstriction of the afferent arteriole also works to decrease glomerular capillary hydrostatic pressure and subsequent net filtration pressure. The resulting glomerular filtration rate then decreases as well and fluid volume is conserved.

The macula densa cells also work to control glomerular filtration by a process known as tubuloglomerular feedback. The macula densa cells secrete varying amounts of nitric oxide synthetase that promotes the secretion of nitric oxide which vasodilates the afferent arteriole. When filtrate concentration decreases as when the filter is producing too much fluid the secretion of nitric oxide synthetase decreases causing vasoconstriction of the afferent arteriole. The resulting vasoconstriction reduced glomerular capillary hydrostatic pressure and subsequent filtration rate.

Macula densa cells also secrete adenosine, a vasoconstrictor in response to an increase in filtrate production. Adenosine also works to reduce the input to the glomerulus thereby regulating the amount of filtrate produced.

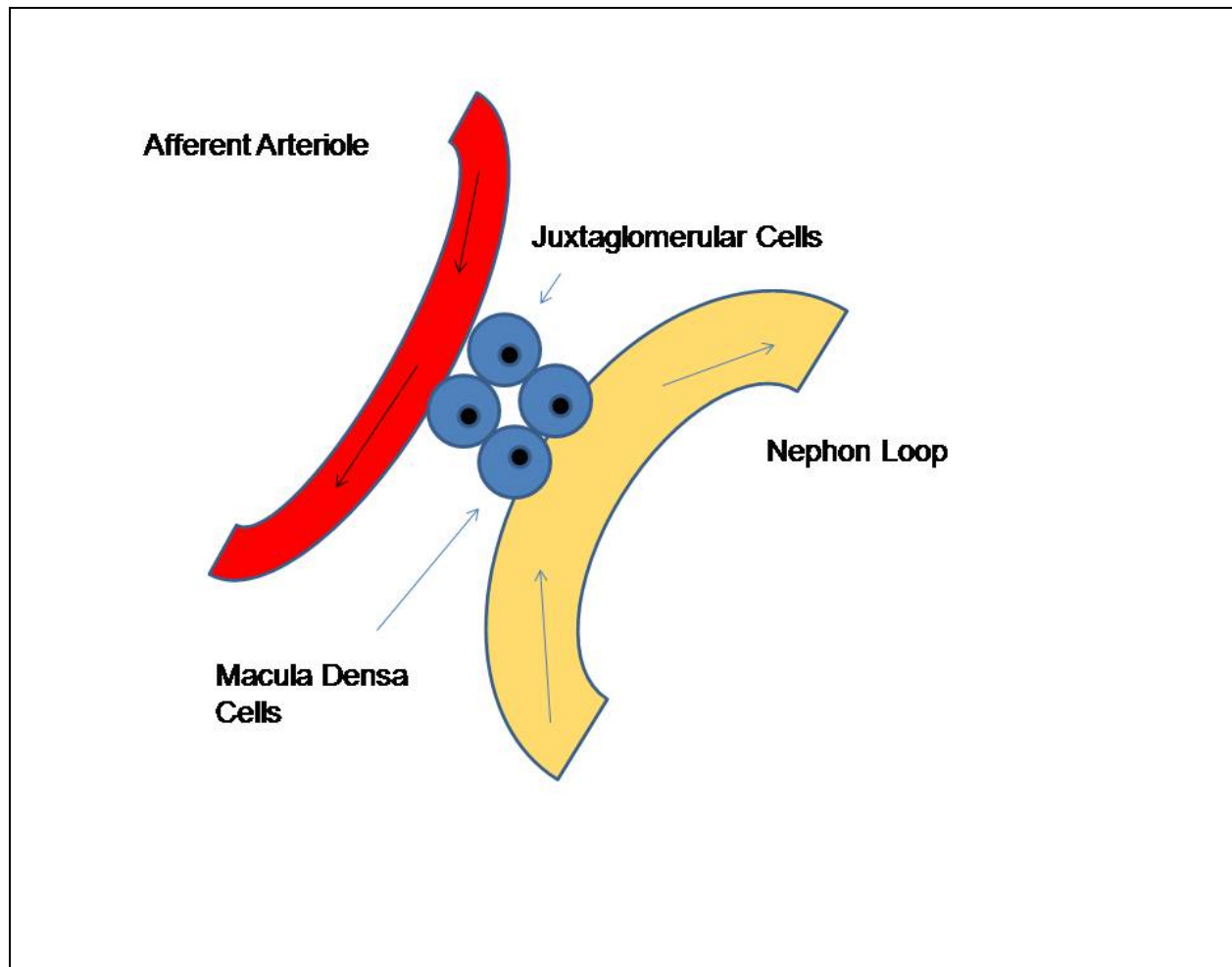


Figure 23.2. Juxtaglomerular apparatus. The juxtaglomerular cells secrete renin while the macula densa cells secrete nitric oxide synthetase and adenosine.

Bruce Forciea



## **Tubular Reabsorption**

Tubular reabsorption occurs in the proximal and distal convoluted tubule. It works in conjunction with tubular secretion and involves moving filtered substances back into the blood. The processes involved in tubular reabsorption include diffusion, active transport, osmosis and facilitated diffusion. The tubules are surrounded by peritubular capillaries. The walls of the tubules also have some special characteristics (fig. 23.3, 23.4)).

The cells of the kidney tubules form two membranes. On the tubule side cells form the basolateral membrane. On the opposite side close to the interstitium cells form the apical (sometimes called luminal) membrane.

In order to move substances from the tubules to the blood they must move through the apical and basolateral membranes of the tubules as well as the peritubular capillary endothelium. Some substances move passively (powered only by concentration gradients) while others move via special transport proteins using ATP. The walls of the tubules are somewhat permeable and allow movement of some substances by way of concentration gradients between the cells of the tubules. The electrolytes calcium, magnesium, potassium and some sodium move this way.

There is a large sodium gradient in the kidney tubules. Sodium concentration is high in the tubules and lower in the surrounding interstitium and blood.

### **Sodium-Glucose Symporter**

Some cells in the apical membrane of the tubules contain special transport proteins called symporters. One such symporter transports sodium and glucose. This symporter is powered by the sodium gradient. Sodium moves through the protein from the tubule to inside the cell. The transport protein also takes glucose along for the ride by transporting it to the inside of the cell as well. Once inside the cells sodium is removed from the cell by traveling through the basolateral membrane by the action of the sodium potassium pump. Sodium travels to the interstitium and blood. Glucose is also removed from the cell by way of a transport protein to the interstitium and blood.

Since so much sodium is reabsorbed water is also reabsorbed by osmosis. The tubules contain special water containing regions called aquaporins that aid in water reabsorption.

Since the reabsorption of many substances relies on the number of transport proteins in cells there is a transport maximum for each of these substances. When the maximum is reached, additional substances flow into the urine. An example of this is with the increased blood glucose levels found in diabetes. Glucose passes through the glomerular filter and is reabsorbed in the tubules. If the amount of glucose exceeds the number of transporters then the excess glucose spills out in the urine in a condition known as glucosuria.

The apical membrane also contains numerous carrier proteins similar to the sodium glucose symporter. For example, symporters use the sodium gradient to transport amino acids. The amino acids are transported into the interstitium at the basolateral membrane by way of a second transport protein. Other such symporters include those for sodium and chloride, and sodium and potassium.

The symporters of the apical membrane work with transport proteins in the basolateral membrane to maintain the concentration gradients for sodium and potassium.

## **Tubular Secretion**

Tubular secretion involves the movement of substances from the blood and interstitium to the kidney tubules (fig. 23.3). Unlike tubular reabsorption that moves substances in order to maintain fluid and electrolyte balance, tubular secretion primarily works to eliminate toxic substances or byproducts of metabolism.

Tubular secretion can involve active or passive transport. An example of passive transport is the sodium hydrogen antiporter. This transport protein uses the sodium gradient to move sodium from the tubule to inside the apical membrane cell while at the same time moving excess hydrogen ions out of the cell and into the lumen of the tubule.

The secreted hydrogen ions result from water and bicarbonate combining in the cell. The bicarbonate and sodium travel into the cell by way of a symporter located in the basolateral membrane and move into the peritubular capillaries. The secretion of hydrogen ions plays an important role in maintaining acid base balance.

Other examples of secreted substances include ammonia, potassium, penicillin, and para-aminohippuric acid. The body does not normally produce these substances.

## **Action of Aldosterone**

The adrenal cortex secretes aldosterone in response to activation of the renin-angiotensin mechanism and adrenocorticotropin hormone (ACTH). Aldosterone targets receptors on cells in the apical membrane that transport sodium. When aldosterone attaches to these receptors the cells respond by increasing sodium transport (increasing tubular reabsorption of sodium). At the same time they also stimulate the tubular secretion of potassium.

## **Atrial Natriuretic Hormone**

Atrial Natriuretic Hormone (ANH) is secreted by the wall of the right atrium in the heart in response to atrial stretch. ANH targets ANH has the opposite action of aldosterone and inhibits sodium and water reabsorption in the kidney tubules.

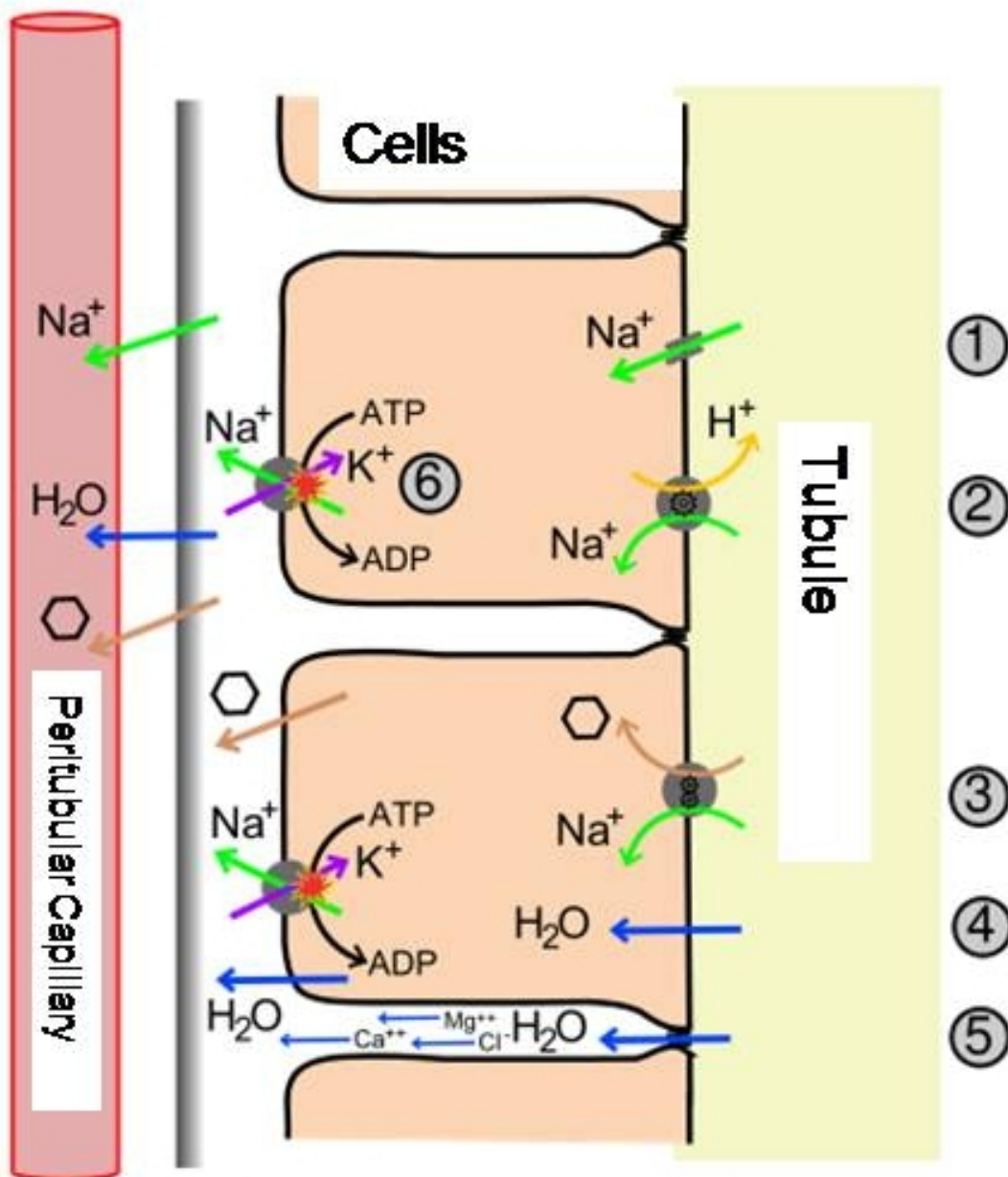


Figure 23.3. Tubular reabsorption and secretion. 1. Sodium passively transported. 2. Sodium-hydrogen antiporter. 3. Sodium-glucose symporter. 4. Water reabsorption by osmosis. 5. Passive diffusion of water, magnesium, chloride, and calcium.

<http://commons.wikimedia.org/wiki/File:Reabsorption.svg>

## **The Nephron Loop**

The nephron loop consists of two segments including a descending and ascending segment each with different characteristics. Juxtamedullary nephrons operate by way of a special process known as the countercurrent multiplier mechanism.

The descending limb contains a thin layer of epithelium that is more permeable to water than the thick portion of the ascending limb. An isotonic fluid (about 300 mOsm) enters the descending limb. As it progresses down the limb, water diffuses into the interstitium causing the concentration to dramatically increase. The fluid concentration can increase to as high as 1200 mOsm (very hypertonic).

The thick segment of the ascending limb inhibits the passage of water by diffusion and contains a series of active transport proteins that selectively move substances. Sodium, chloride, and potassium are moved out of the ascending limb and into the interstitium by way of these active transport proteins. As fluid moves up the ascending limb the concentration decreases. A 100 mOsm hypotonic solution exits the ascending limb and enters the distal convoluted tubule.

The countercurrent consists of the “current” of water moving in one direction and the “current” of electrolytes moving in the opposite direction. The high “salt” gradient is maintained by the active transport of sodium and chloride in the ascending limb. Urea also diffuses into the descending limb adding to the increased concentration (fig. 23.5).

## **Antidiuretic Hormone (ADH)**

ADH is secreted by the posterior pituitary gland in response to an increase in blood solute concentration as sensed by osmoreceptors in the hypothalamus. ADH targets the kidney, particularly the distal convoluted tubule.

ADH affects the distal convoluted tubule by making it more permeable to water. ADH promotes the appearance of aquaporins (water channels) in the distal convoluted tubule. Remember that the fluid exiting the nephron loop is hypotonic. The hypotonic fluid enters the distal convoluted tubule that is surrounded by the interstitium and peritubular capillaries which are isotonic. If the tubule is impermeable to water then dilute urine is produced. Increasing the water permeability of the tubule causes water to move to the more highly concentrated interstitium and blood. ADH plays an important role in maintaining fluid balance.

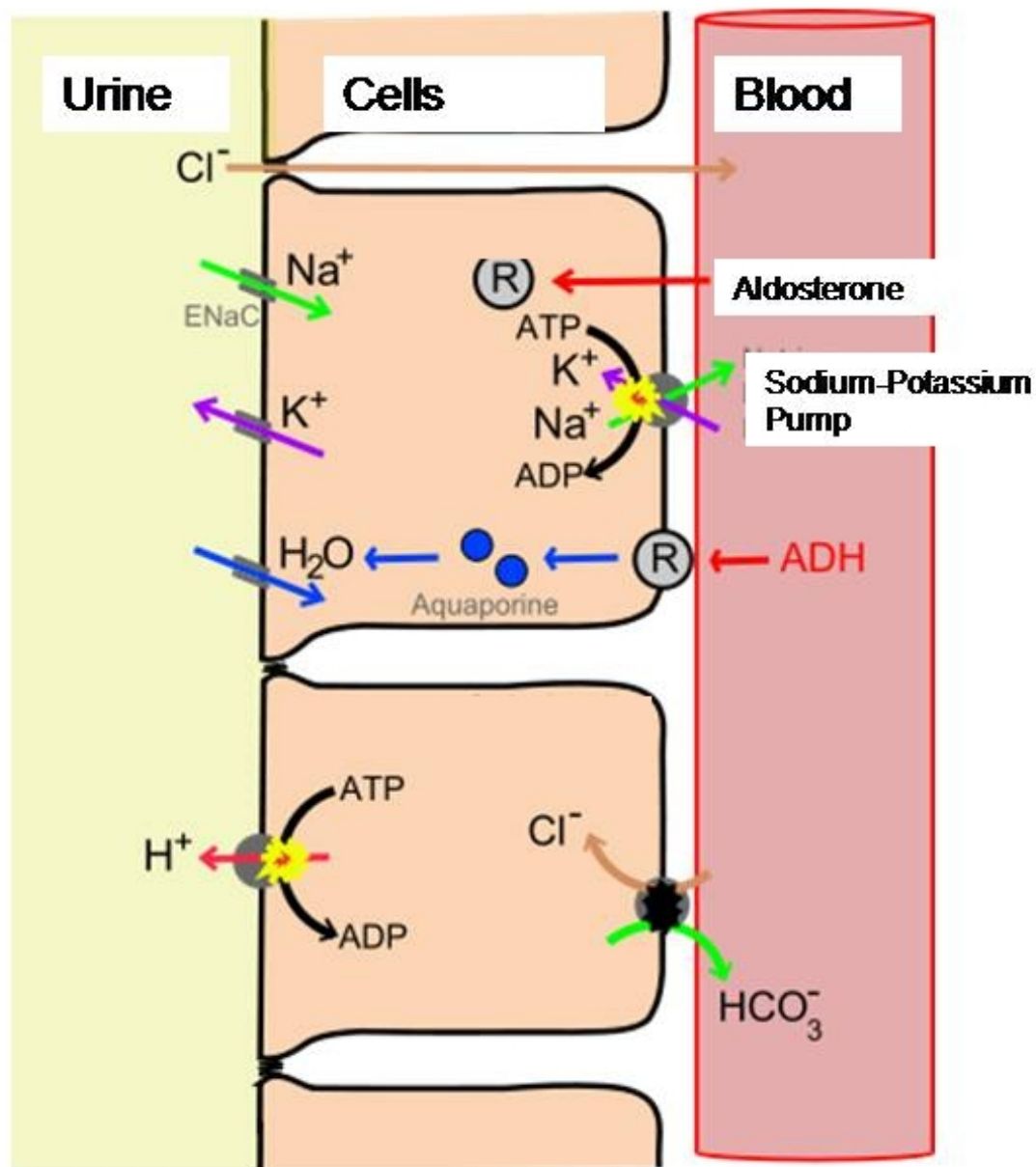


Figure 23.4. Transport proteins in the tubular cells.

<http://commons.wikimedia.org/wiki/File:Sammelrohr.svg>

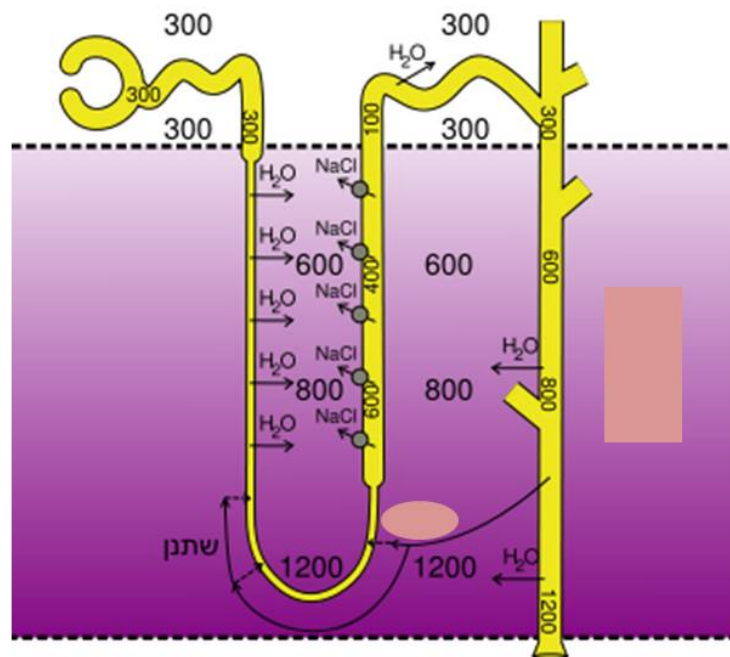


Figure 23.5. Filtrate concentration in the renal tubule.

[http://commons.wikimedia.org/wiki/File:Hypertonic\\_urine1.svg](http://commons.wikimedia.org/wiki/File:Hypertonic_urine1.svg)

Author: [Yosi I](#)

## Renal Clearance

Renal clearance is used to determine kidney function. Renal clearance is the volume of blood plasma from which a substance is completely removed in one minute. Renal clearance reflects the 3 processes of urine formation which include glomerular filtration, tubular reabsorption and tubular secretion. Substances passing through the glomerulus are added to the substances moving from the peritubular capillaries into the tubules by way of secretion. The amount of the substance removed by tubular reabsorption is subtracted. However this method is not practical. We can use an indirect method to determine renal clearance that includes the rate of urine output and the concentration of the substance in blood plasma and urine.

For example let's say we are determining the renal clearance for a substance X. We know the concentration of X in the urine is 5.0 mg/ml and the concentration of X is .3 mg/ml in the plasma. We

also know the rate of urine output equals 2 ml/min. The renal clearance can be determined by the following:

$$\text{Renal Clearance (C)} = UV/P$$

U = concentration of substance in urine

V = rate of urine output

P = concentration of substance in plasma

For our example:

$$C = (5.0)(2)/.3$$

$$C = 33.33 \text{ ml/minute}$$

This can be interpreted as 33.33 ml of blood plasma is cleared of substance X every minute.

### **Glomerular Filtration Rate**

We can use a substance that is not reabsorbed or secreted to determine the glomerular filtration rate. A substance that meets these criteria is inulin, a polysaccharide contained in artichokes and garlic.

Glomerular filtration rate can be determined by injecting inulin and then measuring the urine output as well as the concentrations of inulin in the blood plasma and urine.

Since inulin is not secreted or reabsorbed by the kidney tubules the renal clearance is equal to the glomerular filtration rate. Thus we just need to calculate the renal clearance for inulin:

$$C = UV/P$$

$$U = 25 \text{ mg/ml}$$

$$V = 2 \text{ ml/min}$$

$$P = .4 \text{ mg/ml}$$

$$C = (25)(2)/.4$$

$$C = 125 \text{ ml/min}$$

$$\text{Glomerular filtration rate (GFR)} = C$$

$$\text{GFR} = 125 \text{ ml/min}$$

## **Urine Composition**

Adults produce about 1 to 2 liters of urine daily. Pathologies such as diabetes or some medications can produce a larger urine output known as polyuria. A urine output of less than 500 ml/day is known as oliguria and an output less than 100 ml is known as anuria.

Urine is the final product of the kidney. It is mostly water (95%) with a few other solutes including nitrogenous wastes, electrolytes, pigments, and toxins. It can also contain abnormal substances including glucose, albumin, bile and acetone.

Urine is usually clear or straw colored. An abnormal color may indicate presence of blood, bile, bacteria, drugs, food pigments, or high-solute concentration. Urine will become cloudy after standing due to a buildup of bacteria. Pus from problems such as kidney infections will also make urine cloudy.

Urine has a slight odor. It will develop an ammonia odor after standing due the breakdown of urea. An acetone odor may indicate diabetes. The pH of urine varies between 4.6 and 8.0. The specific gravity is between 1.001 and 1.035.



## Chapter 23 Review Questions

1. The renal fraction averages about what percentage of cardiac output:
  - a. 10%
  - b. 15%
  - c. 20%
  - d. 30%
2. How much filtrate is produced by the kidneys each day:
  - a. 2 liters
  - b. 50 liters
  - c. 120 liters
  - d. 180 liters
3. Glomerular capillary hydrostatic pressure is normally about:
  - a. 10 mm Hg
  - b. 20 mm Hg
  - c. 50 mm Hg
  - d. 60 mm Hg
4. A typical net filtration pressure is about:
  - a. 10 mm Hg
  - b. 20 mm Hg
  - c. 50 mm Hg
  - d. 60 mm Hg
5. An increase in colloid osmotic pressure would have which effect on urine production:
  - a. It would increase
  - b. It would decrease
  - c. No effect
  - d. It would decrease glomerular capillary hydrostatic pressure
6. During exercise urine production \_\_\_\_\_ because \_\_\_\_\_:
  - a. Increases, sympathetic effects
  - b. Decreases, sympathetic effects
  - c. Increases, parasympathetic effects
  - d. Decreases, parasympathetic effects
7. Renin is secreted by the juxtaglomerular apparatus when this occurs:
  - a. Systemic blood pressure drops below 80 mm Hg
  - b. Systemic blood pressure increases beyond 100 mm Hg
  - c. Increase in solute concentration of filtrate
  - d. Decrease in solute concentration of filtrate

8. Macula densa cells secrete \_\_\_\_\_ which promotes \_\_\_\_\_:
- Norepinephrine, vasoconstriction
  - Nitrous oxide, vasoconstriction
  - Nitric oxide, vasodilation
  - Acetylcholine, vasodilation
9. Which of the following substances is secreted:
- Glucose
  - Sodium
  - Water
  - Potassium
10. Which of the following best describes the action of aldosterone:
- Increases reabsorption of hydrogen ions
  - Increases reabsorption of sodium
  - Decreases reabsorption of potassium
  - Decreases reabsorption of hydrogen ions
11. The ascending limb of the nephron loop is:
- Permeable to water but not solute
  - Permeable to water and solute
  - Permeable to solute but not water
  - Impermeable to water and solute
12. What type of fluid exits the nephron loop:
- Isotonic
  - Hypertonic
  - Hyperosmotic
  - Hypotonic
13. Which best describes the action of ADH:
- Decreases membrane permeability to water in the distal convoluted tubule
  - Creates hypotonic solution in distal convoluted tubule
  - Increases membrane permeability to water in the distal convoluted tubule
  - Creates isotonic solution in the distal convoluted tubule
14. What is the renal clearance for a substance A given the following:  
Concentration of substance A = 4.0 mg/ml in urine  
Concentration of substance A = .2 mg/ml in plasma  
Rate of urine output = 2 ml/min
- 20 ml/min
  - 40 ml/min
  - 50 ml/min
  - 60 ml/min

# Chapter 24

## Fluids, Electrolytes and Acid-Base Balance

## Fluids, Electrolytes and Acid-Base Balance

The human body is more than 70% water. Fluids are an important constituent of tissues, membranes and many other structures of the body as well as play an important role in the body's chemistry. Fluid levels must be maintained in order for the body to function properly. The same can be said for the millions of charged atoms called electrolytes. Our bodies run on the concentration gradients of electrolytes. Since electrolytes are carried by fluids the balance of both fluids and electrolytes is of extreme importance in keeping our bodies alive.

### The Big Picture

Fluids and electrolytes go together. This is because of concentration. When we describe a solution in terms of concentration we are defining the amount of solute in the solution. In many cases the electrolytes represent the solute. Fluids also move across membranes by way of osmosis. For example if we were losing water on one side of a membrane we would say that this area is becoming hypotonic. Water would then move across the membrane by osmosis. Also, if we lost electrolytes from the same area water would also be drawn across the membrane by osmosis.

There are many electrolytes in the body. The most important of these however are sodium, potassium and calcium so you really want to know about these and how they are regulated. Acid base balance is also important as the blood is kept at a narrow range of pH. If it becomes too acidic a condition called acidosis develops. Likewise if the blood becomes too basic a condition called alkalosis develops. Both acidosis and alkalosis can cause severe problems.

### Fluids

The normal adult human can have as much as 75% water by weight. The amount of water depends on the proportion of body tissues contributing to the overall composition. The body loses water content with aging and can drop to about 45% water in the elderly.

In physiology fluid is explained in terms of two compartments. These include the compartment inside the cells or intracellular compartment (ICF) and the compartment outside the cells or extracellular compartment (ECF). If we were to generalize fluid and electrolyte problems we could say that substances lost from the ECF are compensated for to a point. If the gain or loss exceeds the body's ability to compensate then the gain or loss affects the cells causing a larger problem.

The total fluid in a normal adult is about 40 liters. If we were to measure the fluid in the ICF and ECF we would see that the ECF contains about 37% of the total fluid by volume. The ICF contains about 63%. The ICF consists of the cytoplasm of the cells. The ECF consists of a number of areas including interstitial fluid, plasma, lymphatic fluid, and transcellular fluids. These include the cerebral spinal fluid, aqueous and vitreous humors, synovial fluid and glandular secretions.

The mechanisms allowing fluid movements include filtration and osmosis. The amount of fluid intake must equal the amount of fluid lost in order to maintain what is known as fluid balance. Normally about 1.5 liters of fluid is gained and lost per day. Fluid is gained by ingesting moist food (750 ml) and beverages (1500 ml) as well as through cellular metabolism (250 ml). Water is a byproduct of many metabolic processes of the body including aerobic metabolism.

Fluid is lost through the urine (1500 ml), sweating (150 ml), feces (150 ml) and through respiration (700 ml).

### **Fluid Regulation**

The first method of fluid regulation is the thirst mechanism. Osmoreceptors in the hypothalamus sense an increase in solute concentration and stimulate the thirst center. A loss of as little as 1-2% of body fluid can stimulate thirst. Upon drinking the resultant stretch of the stomach inhibits the thirst center. Water is then absorbed in the stomach and intestines. Solute concentration subsequently decreases.

#### **Hormonal Regulation**

Certain hormones have a powerful influence on regulating fluid volume. These include antidiuretic hormone, aldosterone and atrial natriuretic peptide.

Antidiuretic hormone (ADH) was covered in the urinary chapter. It is secreted by the posterior pituitary gland in response to increased solute concentration as sensed by osmoreceptors in the hypothalamus. ADH then travels through the blood to the kidneys where it causes an increase in tubular permeability particularly in the distal convoluted tubule of the nephron. When this occurs water moves from the tubule to the interstitium and eventually into the blood. The primary effect is to conserve fluid volume. ADH also stimulates the thirst center in the hypothalamus.

Aldosterone is a hormone secreted by the adrenal cortex in response to activation of the renin-angiotensin system (RA system). The RA system is triggered by the secretion of renin from the juxtaglomerular cells of the juxtaglomerular apparatus in the nephron of the kidney. Aldosterone targets cells in the kidney tubules causing them to increase their permeability to sodium. When this occurs sodium is reabsorbed and water follows by osmosis. Water moves into the interstitium and blood and is conserved.

Atrial natriuretic peptide (ANP) is secreted by the right atrium of the heart in response to an increase in atrial stretch. Atrial stretch results from an increase in blood volume. The increase in plasma volume relates to an increase in fluid volume. ANP also inhibits the thirst mechanism.

### **Fluid Regulation Problems**

#### **Dehydration**

When more water is lost than when gained the result is dehydration. Water is first lost from the ECF causing the osmotic pressure to rise due to a rise in solute concentration. If compensatory mechanisms cannot restore water balance then the increase in osmotic pressure in the ECF causes a subsequent movement of water out of the ICF.

If water loss continues the person will experience thirst, dizziness, weakness, mental confusion, delirium and coma. Water loss results from a decrease in fluid intake, vomiting, diarrhea, severe sweating known as profuse diaphoresis, or profuse urination from diseases such as diabetes.

Dehydration can cause general hypovolemia which can result in low cardiac output, electrolyte imbalances and acid-base abnormalities.

Treatment for dehydration includes restoring intake of fluids and electrolytes either orally or through an intravenous route.

## Water Intoxication

Water intoxication or hyperhydration occurs when fluid intake exceeds water loss. It is a rare occurrence in adults and is more likely to occur in newborns given dilute formula or water. Newborns do not have a fully developed system for decreasing fluid volume. Water is gained first in the ECF which causes the compartment to become hypotonic. This causes subsequent loss of fluid from the ICF. Water intoxication can be severe and result in muscle cramping, convulsions, confusion, coma, and brain edema.

## Electrolytes

### Sodium Balance

Like fluids sodium balance depends on the intake versus excretion of sodium. A normal adult human has a sodium intake of about 1.1 to 3.4 g of sodium per day. Sodium enters the body through the digestive system epithelium. Sodium is excreted through the kidneys and skin via sweating. The kidneys are the main regulators of sodium in the body (figs. 24.1, 24.2).

Sodium is regulated by aldosterone. As discussed in the urinary system physiology chapter, aldosterone increases the reabsorption of sodium in the kidney tubules. As stated earlier, sodium and water are often transported together as water moves by osmosis. This helps to keep the sodium concentration constant. For example ingesting a large amount of sodium causes a subsequent increase in water absorption via osmosis. The additional water ends up in plasma and increases blood volume. The increase in blood volume results in an increase in blood pressure. This is why people with hypertension are told to limit their sodium intake.

### Hyponatremia

When sodium concentration is reduced to below 130 mEq/L, a state of hyponatremia exists. Hyponatremia can result from prolonged and severe sweating, vomiting, diarrhea, renal disease, and a condition of the adrenal gland called Addison's disease. In hyponatremia the ECF becomes hypotonic causing swelling of the ICF. Symptoms include muscle spasms, postural blood pressure changes, nausea, vomiting, convulsions, confusion, and coma (fig. 24.3).

Treatment for hyponatremia ranges from water restriction in mild cases to the administration of sodium orally or intravenously in more severe cases.

## **Real World A&P: Hyponatremia in Athletes**

During the Summer months many of us turn to the outdoors for our exercise fix. We also know that it is important to drink enough water to replace the fluid lost by sweating during vigorous workouts in order to avoid becoming dehydrated. With sales of bottled water and sports drinks on the rise it is easy to find fluids just about anywhere there are food products. Many of us were brought up on the idea that drinking large amounts of water is safe and the more the better especially when exercising in hot, humid conditions.

This thinking is generally correct. Many of us do need to hydrate ourselves sufficiently during intense, long-term exercise. However a new problem is on the rise and it results from drinking too much water during exercise. The problem is a condition known as hyponatremia which is a condition that occurs from having a too low concentration of sodium in our blood.

Hyponatremia occurs when the concentration of sodium in the blood is too low (less than 135 milliequivalents per liter). Symptoms of hyponatremia include nervous system problems such as tiredness, lethargy, confusion, irritability, seizures and coma.

According to a study in the Archives of Pathology and Laboratory Medicine (1) that examined causes of collapse in marathon runners in the 2003 Boston marathon it was found that a significant number of runners suffered from hyponatremia.

Hyponatremia appears to be more prevalent in the slower marathon runners completing races in greater than 4 hours and those who use hyperhydration techniques before events.

Hyponatremia is difficult to diagnose without measuring blood sodium levels because the symptoms are similar to dehydration. It is very dangerous to give fluids to someone with hyponatremia and it could cause swelling of the brain and even death. Other signs of too much water intake included weight gain of greater than 1 kilogram that was correlated with water intake of greater than 3 liters.

The researchers' recommended limiting water intake during a marathon to between 400-800 ml per hour. These recommendations could also be applied to other forms of vigorous exercise such as bicycling, hiking or dancing.

Another recommendation from the American College of Sports Medicine is to drink fluids at regular intervals rather than at one time and consume salty snacks to replace lost sodium.

Hyponatremia can be a very dangerous problem and is counterintuitive to our belief about drinking lots of fluids during extreme exercise. In the coming summer months it is important for athletes, trainers and coaches to be aware of this problem in order to avoid serious consequences.

### **References:**

1. Kratz, A., et. al. Sodium status of collapsed marathon runners.

Arch Pathol Lab Med. 2005 Feb; 129(2):227-30

## Hypernatremia

When sodium concentration exceeds 145 mEq/L a state of hypernatremia exists. Hypernatremia results from severe uncorrected diabetes insipidus/mellitus, severely high sodium intake, lack of fluid intake, diarrhea, heart disease or renal failure (fig. 24.4).

The signs and symptoms of hypernatremia include thirst, disorientation, lethargy, and central nervous system problems. Hypernatremia is treated with a hypotonic solution which lowers sodium concentration.

## Potassium Balance

Most of the potassium in the body is located in the ICF (98%). Potassium enters the body through the digestive system and is primarily excreted by the kidney. Potassium is mainly regulated by aldosterone. Aldosterone causes secretion of potassium as well as reabsorption of sodium. High concentration of potassium in blood plasma stimulates the release of aldosterone.

If potassium levels drop below 3.5 mEq/L a state of hypokalemia exists. The causes of hypokalemia include Cushing's disease (affects the adrenal cortex causing increased aldosterone levels resulting potassium loss), potassium wasting diuretics, increased urine output, gastric suctioning (without potassium replacement) and vomiting.

Signs and symptoms of hypokalemia include muscle weakness, paralysis, atrial or ventricular arrhythmias, and respiratory problems. Potassium disorders can be very dangerous and result in a life-threatening condition.

Hypokalemia can result in Peaked T-waves on ECG, ventricular dysrhythmias, cardiac arrest, muscle weakness, failure of respiratory muscles, intermittent diarrhea, and intestinal colic,

If potassium levels exceed 5.5 mEq/L a state of hyperkalemia exists. This condition is very dangerous and life threatening. Causes of hyperkalemia include kidney disease, vomiting-diarrhea, potassium sparing diuretics, extensive tissue damage, severe infections, and Cushing's syndrome.

The treatment for hyperkalemia ranges from dietary restriction of potassium in mild cases to intravenous administration of calcium gluconate to correct cardiac problems along with dialysis to remove excess potassium. The underlying problem must also be corrected.



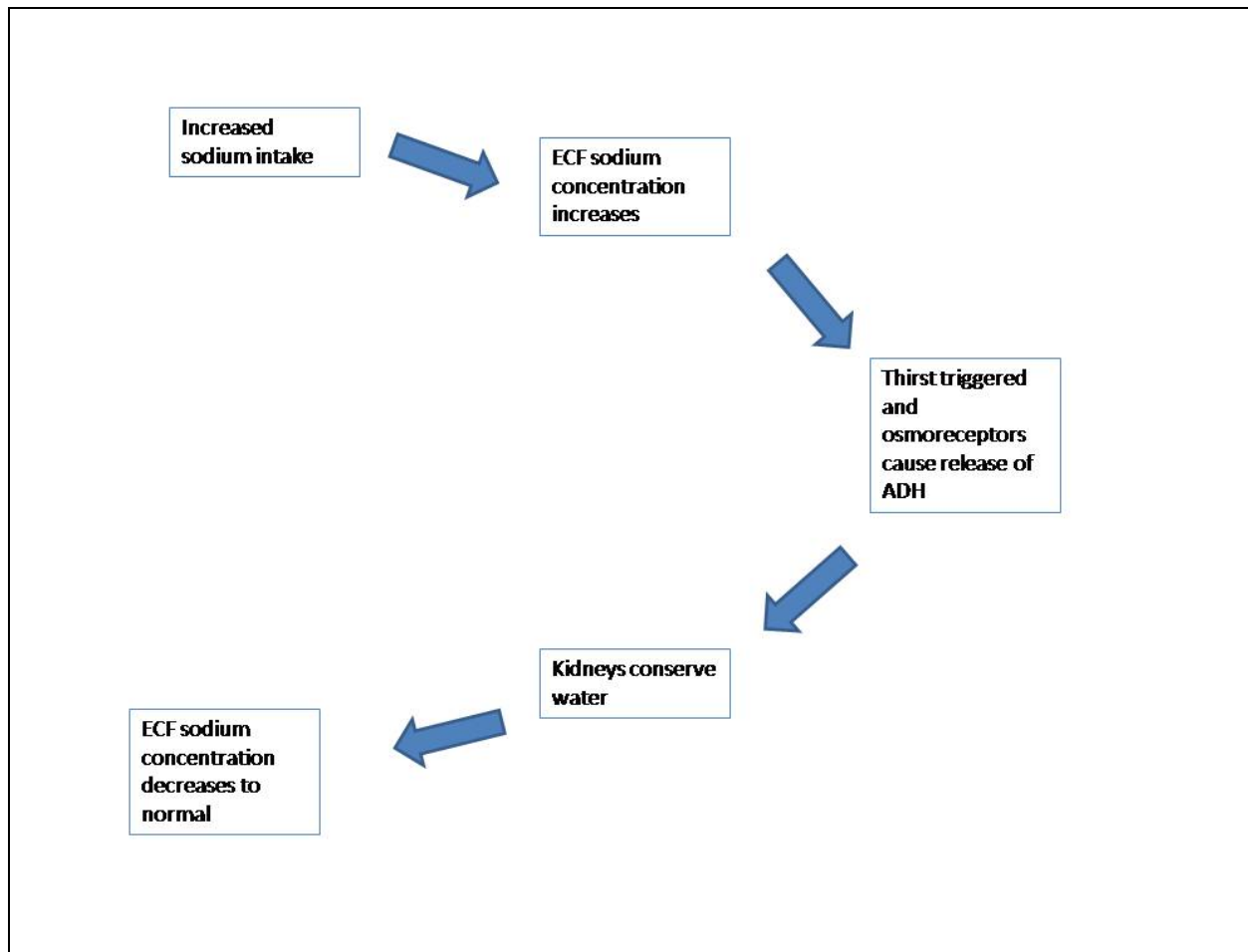


Figure 24.1. Mechanism of maintaining sodium balance after large intake of sodium.

Bruce Forciea

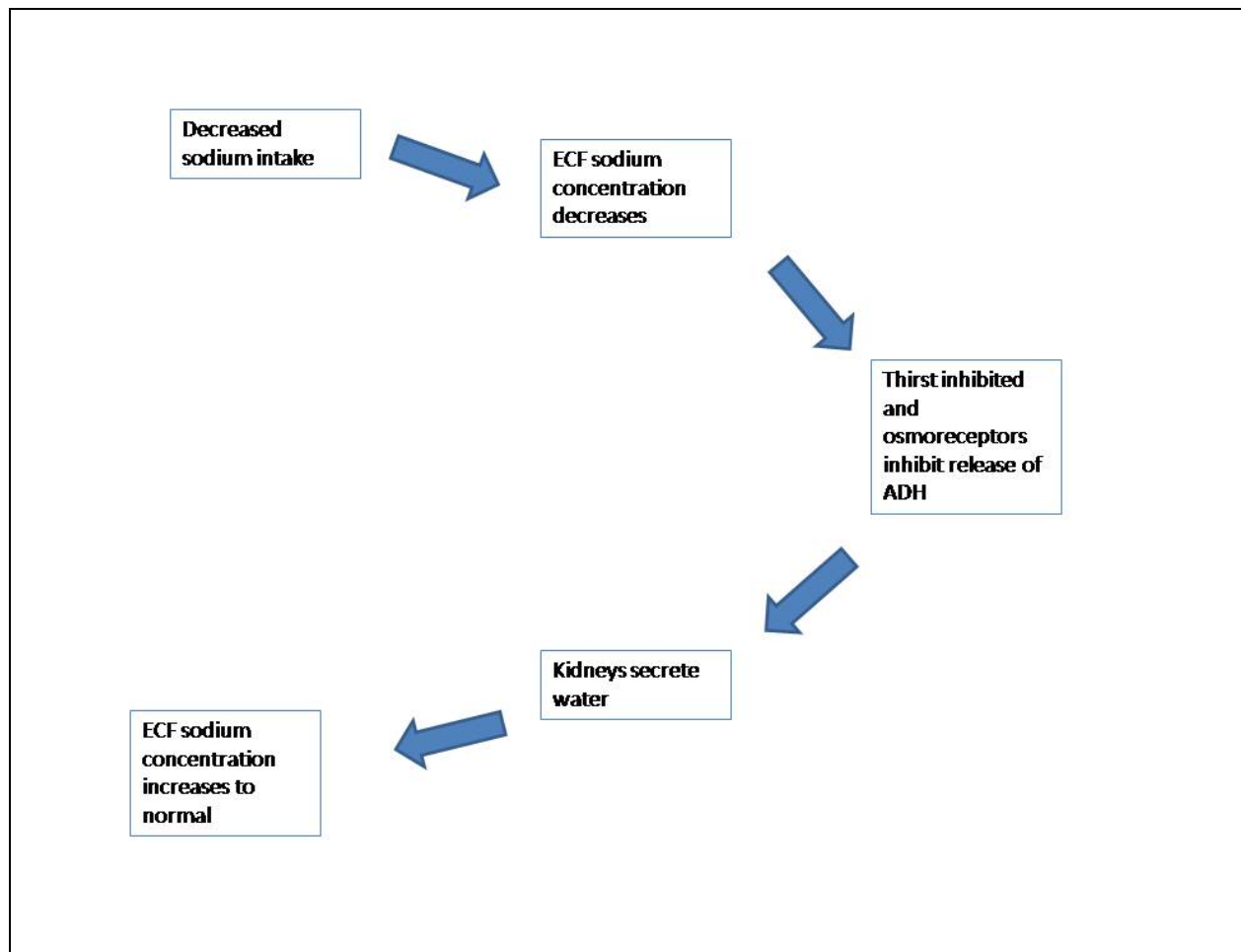


Figure 24.2. Mechanism of maintaining sodium balance with decrease in sodium intake.

Bruce Forciea

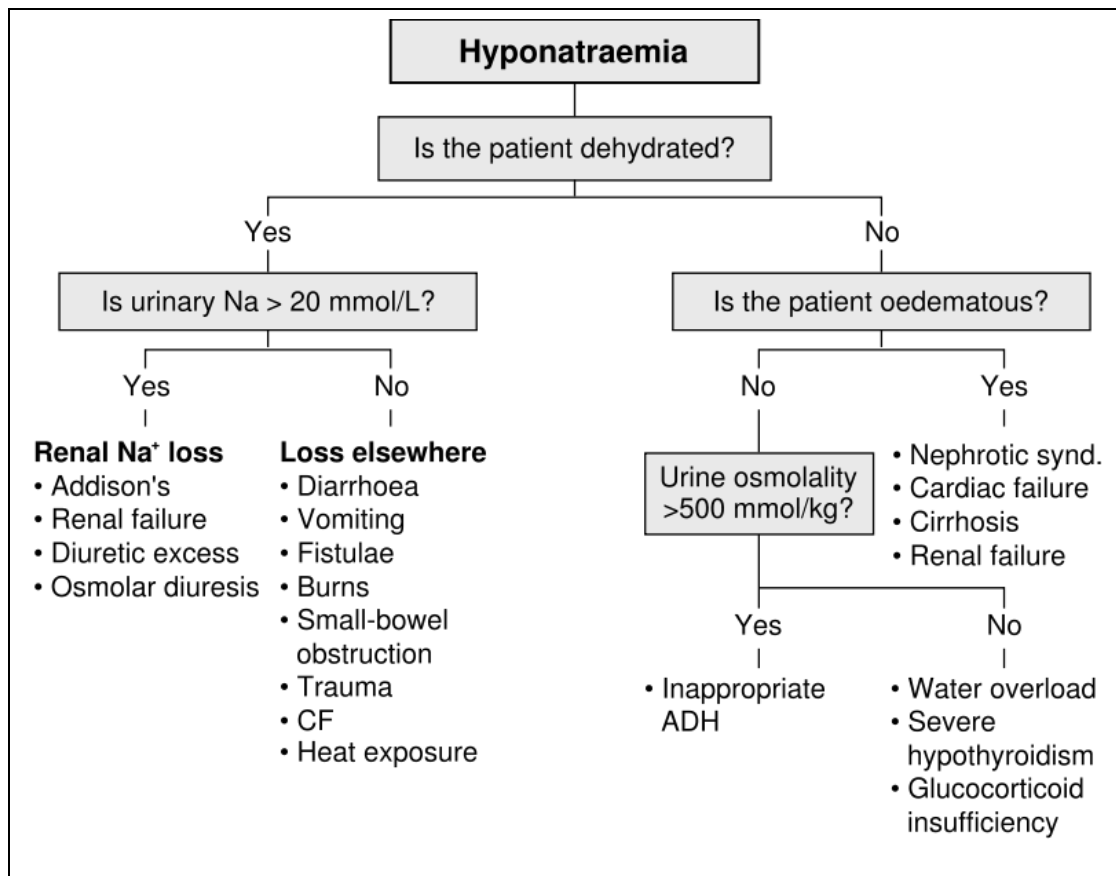


Figure 24.3. Hyponatremia

[http://commons.wikimedia.org/wiki/File:Hyponatraemia\\_Causes.svg](http://commons.wikimedia.org/wiki/File:Hyponatraemia_Causes.svg)

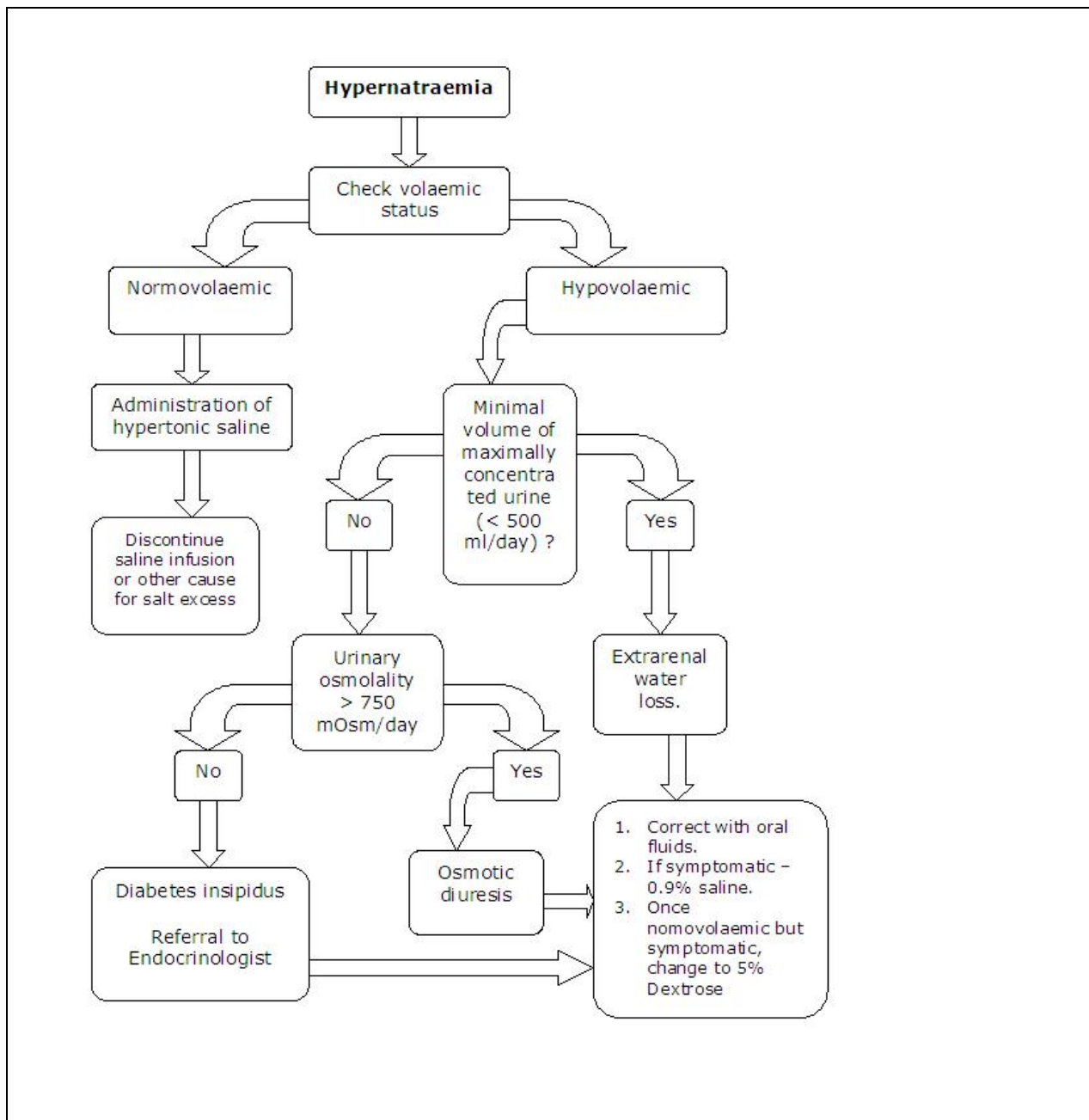


Figure 24.4. Hypernatremia

[http://upload.wikimedia.org/wikipedia/commons/7/7b/Management\\_of\\_Hypernatremia.jpg](http://upload.wikimedia.org/wikipedia/commons/7/7b/Management_of_Hypernatremia.jpg)

## **Calcium Balance**

A typical adult human has about 1-2kg of calcium. We have seen calcium play an important role in skeletal and cardiac muscle contraction as well as in the transmission of nervous system impulses. There is a dynamic interplay between calcium in blood and bone. Calcium can be deposited or removed from bone when necessary.

Calcium enters the body through the digestive tract and is excreted in the kidneys with a small portion excreted in bile. A typical adult needs about .8 to 1.2 gm.day of calcium.

Calcium is regulated by the hormones calcitonin and parathyroid hormone. Calcitonin stimulates osteoblasts that remove calcium from blood and deposit it into bone. Calcitonin also inhibits osteoclastic activity. Osteoclasts remove calcium from bone so that it is available in the blood.

Parathyroid hormone (PTH) has the opposite effect of calcitonin. PTH increases osteoclastic activity and decreases osteoblastic activity. Both calcitonin and PTH work together to maintain calcium balance.

When calcium levels decrease to lower than 4 mEq/L a state of hypocalcemia exists. Hypocalcemia results from hypoparathyroidism which produces a low level of parathyroid hormone, vitamin D deficiency, and renal failure. Signs and symptoms include muscle spasms, convulsions, and cardiac arrhythmias.

When calcium levels exceed 11 mEq/L a state of hypercalcemia exists. This can result from hyperparathyroidism and some cancers. Signs and symptoms include confusion, fatigue, arrhythmias and calcification of the soft tissues of the body.

## **Magnesium Balance**

Magnesium is needed for a number of metabolic reactions including phosphorylation of glucose and in muscle contraction. Magnesium is reabsorbed in the proximal convoluted tubule. Excess magnesium is excreted in the urine. The typical adult needs about .3-.4 g/day of magnesium.

## **Phosphate Balance**

Phosphates are stored in the skeleton and used for phosphorylation of ADP. Phosphates are reabsorbed in kidney tubules and excreted in the urine. The typical adult needs about .8-1.2 g/d of phosphate.

## **Chloride Balance**

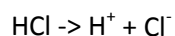
Chlorides are the most numerous negative electrolytes in the body. Chloride ions are absorbed in the digestive tract and cotransported with sodium ions. Chloride ions are reabsorbed in the kidney tubules. The typical adult requires about 1.7-5.1 g/day of chloride.

## Acid Base Balance


The body maintains a narrow range of pH of the blood that is between 7.35 and 7.45. It must maintain this pH despite the constant release of acidic substances from metabolic processes and minute changes in pH associated with the respiratory system.

Acids are substances that release hydrogen ions. Bases are substances that combine with hydrogen ions in order to neutralize them. Many bases release hydroxide ions that combine with hydrogen ions to form water. Remember that the pH scale ranges from 0 to 14. It is a logarithmic scale that measures tenfold increases in hydrogen ion concentration. A pH of 7 is neutral while a pH below 7 is considered acidic and a pH above 7 is considered basic or alkaline.

There are strong acids that completely dissociate in solution. For example hydrochloric acid is considered a strong acid:



Weak acids do not completely dissociate in solution. For example carbonic acid is considered a weak acid:



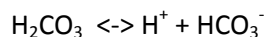
Notice the double arrow that indicates that the reaction reaches equilibrium in solution. This means that only a portion of the carbonic acid molecules will dissociate.

Acid-base balance is maintained by the respiratory and urinary systems as well as buffer systems in the blood. We have seen that the kidneys secrete hydrogen ions and reabsorb bicarbonate ions. These actions help to regulate pH. We have also seen that the respiratory system works to adjust pH by carbon dioxide storage (see respiratory physiology chapter). Although the kidneys have a large effect on pH, they tend to work slowly over a period of hours or days. Buffer systems work instantly to adjust pH.

Most metabolic reactions in the body tend to release more hydrogen ions than combine with them. Hydrogen ions are released in the aerobic and anaerobic respiration of glucose, the incomplete oxidation of fatty acids, oxidation of amino acids containing sulfur and the hydrolysis of phosphoproteins and nucleic acids.

Buffer systems are bidirectional chemical reactions that either release or combine with hydrogen ions in order to control pH. There are several important buffer systems in the body. These include the carbonic acid system, proteins, phosphates and ammonium compounds.

Let's take a look at the carbonic acid system.



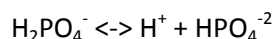
When there is an excess of hydrogen ions the reaction moves to the left. In other words the hydrogen ions combine with bicarbonate ions to form carbonic acid. This helps to raise pH. Likewise when pH increases the reaction moves to the right. Carbonic acid tends to dissociate into hydrogen ions and bicarbonate.

The carbonic acid buffer system reacts quickly to the addition of substances such as lactic acid and carbon dioxide during periods of intense activity.

Proteins also play a role in acting as a buffer system. These include cellular proteins such as histones and plasma proteins such as hemoglobin. The ability of proteins to act as buffers has to do with the presence of the carboxyl and amine groups. The carboxyl group acts as a weak acid while the amine group acts as a weak base.

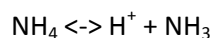
When conditions become acidic hydrogen ions bind to the amine group. Likewise when conditions become basic hydrogen ions are released from the carboxyl group.

Phosphates also act as buffers. Dihydrogen phosphate acts like a weak acid that dissociates according to the following reaction:



When conditions become acidic monohydrogen phosphate ( $\text{HPO}_4^{2-}$ ) combines with hydrogen ions to form dihydrogen phosphate ( $\text{H}_2\text{PO}_4^-$ ). Phosphates are located in ATP, DNA and RNA.

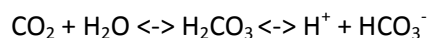Ammonium also acts as a weak acid.



When conditions are acidic hydrogen ions combine with ammonia to form ammonium. When conditions are basic ammonium tends to dissociate into hydrogen ions and ammonia.

### **Respiratory System Regulation of Acid-Base Balance**

We saw that carbon dioxide was stored in bicarbonate by the following reaction:



In areas of higher concentrations of carbon dioxide the reaction moves to the right. Carbon dioxide combines with water to form the intermediate carbonic acid which dissociates into hydrogen ions and bicarbonate. Likewise when the concentration of carbon dioxide decreases the reaction moves to the left. Typically the reaction moves to the right in the tissues as they produce higher levels of carbon dioxide. The reaction moves to the left in the alveoli where carbon dioxide levels are lower causing the release of carbon dioxide so that it can be removed by the lungs.

As the blood becomes more acidic respiratory centers in the brainstem respond by increasing the rate and depth of breathing. This causes the reaction to move more readily to the left. Hydrogen ions are removed by recombining with bicarbonate to form carbonic acid and subsequent carbon dioxide.

As blood becomes more basic respiratory centers are inhibited causing an increased concentration of carbon dioxide. This causes the reaction to move to the right allowing the release of hydrogen ions. Thus respiratory rate and depth of breathing act to maintain pH.

## Urinary System Regulation of Acid-Base Balance

As conditions become acidic hydrogen ions combine with bicarbonate to eventually form carbon dioxide and water. If this situation continues then total body bicarbonate will decrease. Thus bicarbonate needs to be replaced by the kidneys.

The opposite also applies. If pH gets too high (basic) bicarbonate is produced through the dissociation of carbonic acid. Thus excess bicarbonate needs to be removed by the kidneys.

Bicarbonate is a small molecule that passes through the filter in the kidney. If bicarbonate were merely filtered the total body bicarbonate would decrease to dangerous levels. Bicarbonate must be reabsorbed in the kidney tubules.

The reabsorption of bicarbonate occurs in several steps. Carbon dioxide in the filtrate diffuses into kidney tubule cells. Inside the tubule cells carbon dioxide and water combine to form carbonic acid which dissociates into hydrogen ions and bicarbonate. Hydrogen ions are then secreted into the tubule by way of a sodium/hydrogen antiporter protein. Once in the tubule, hydrogen ions combine with filtered bicarbonate to form carbonic acid which dissociates into carbon dioxide and water. The carbon dioxide can diffuse into the tubule cell to complete the circle. Bicarbonate ions inside the tubule cells are transported to the interstitium and blood by way of a sodium/bicarbonate symporter. So for each hydrogen ion secreted, one bicarbonate has been added to the blood.

Generally as the filtrate moves through the tubules most of the bicarbonate is reabsorbed. If there is an excess amount of hydrogen ions secreted, hydrogen ions can combine with non-bicarbonate molecules (such as phosphates). The carbon dioxide used to produce bicarbonate inside of the tubule cell then originates from the blood and enters the tubule cell by diffusion. Bicarbonate is still produced in the tubule cell and ends up being reabsorbed. However this system produces a new bicarbonate for every hydrogen ion secreted.

Besides phosphates the amino acid glutamate can be a source of new bicarbonate for the body. Glutamate is broken down into bicarbonate and ammonium. The bicarbonate is reabsorbed into the blood. Glutamate produces about 50% of the new bicarbonate in the body each day.

## Acid-Base Imbalances

### Respiratory Acidosis

We discussed respiratory acidosis in the respiratory physiology chapter so we will present an overview here. Respiratory acidosis generally occurs from an inability of the lungs to get rid of carbon dioxide. Carbon dioxide then builds up in the blood and is converted to bicarbonate and hydrogen ions. The increased concentration of hydrogen ions causes the acidosis.

Respiratory acidosis is caused by injuries to the respiratory centers in the brainstem, obstructions in air passages, and decreases in gas exchange such as with emphysema and pneumonia. The symptoms of respiratory acidosis include drowsiness, disorientation, stupor, coma and even death in severe cases.

Respiratory acidosis is treated with an intravenous infusion of sodium lactate. The lactate ions are converted to bicarbonate ions in the liver and the bicarbonate ions help to buffer the hydrogen ions.



## Respiratory Alkalosis

Respiratory alkalosis can develop from fever, hyperventilation and salicylate (aspirin) poisoning. An increased amount of carbon dioxide is removed from the lungs decreasing the hydrogen ion concentration in the blood.

Respiratory alkalosis results from aspirin poisoning because aspirin stimulates the respiratory centers in the medulla causing an increased respiratory rate. This causes a subsequent increase in removal of carbon dioxide from the lungs.

Symptoms of respiratory alkalosis include lightheadedness, dizziness, tingling sensations in the hands and feet and tetany of muscles in severe cases.

## Metabolic Acidosis

Not all acidosis is from the respiratory system. Metabolic acidosis can occur from an accumulation of acids or loss of bases from the body. Examples of conditions that can cause metabolic acidosis include kidney disease (kidneys fail to secrete acids), prolonged vomiting (lose alkaline substances from GI tract), prolonged diarrhea and diabetes mellitus (production of ketone bodies that lower pH). The symptoms are the same as respiratory acidosis and so is the treatment. The underlying cause of the problem must be treated as well as the symptoms.

## Metabolic Alkalosis

Metabolic alkalosis occurs from a loss of hydrogen ions or gain of bases in the body. Examples of conditions that can cause alkalosis include gastric lavage, prolonged vomiting, diuretics, and taking too much antacid. The symptoms are the same as respiratory alkalosis and so is the treatment.

Acid-base balance can be determined by a blood test called an arterial blood gas (ABG) (fig. 24.5). The normal values are:

pH between 7.35 and 7.45

PCO<sub>2</sub> between 35-45 mm Hg

[H<sup>+</sup>] between 35-45 nanomoles per liter

[HCO<sub>3</sub><sup>-</sup>] between 22-26 nanomoles per liter

The source of acidosis or alkalosis can be determined by using this test. See the chart below.

# Arterial Blood Gas

	pH	PCO <sub>2</sub>	HCO <sub>3</sub>
<b>Metabolic Acidosis</b>	<b>Low</b>	<b>Normal</b>	<b>Low</b>
<b>Metabolic Alkalosis</b>	<b>High</b>	<b>Normal</b>	<b>High</b>
<b>Respiratory Acidosis</b>	<b>Low</b>	<b>High</b>	<b>Normal</b>
<b>Respiratory Alkalosis</b>	<b>High</b>	<b>Low</b>	<b>Normal</b>

Figure 24.5. Arterial blood gas.

Bruce Forciea

In order to determine an acid-base abnormality the pH is examined first. If pH is low we know acidosis exists. Likewise if pH is high a state of alkalosis exists.

Next we look at PCO<sub>2</sub>. For example a low pH indicates acidosis. If we combine this information with a high PCO<sub>2</sub> then we know that the respiratory system is responsible for the acidosis. If the PCO<sub>2</sub> is low then we can look at bicarbonate ion concentration. If bicarbonate is high then we know a state of metabolic acidosis exists. In acidosis bicarbonate ions buffer the excess hydrogen ions.

We can use the same rationale for determining alkalosis. For example if pH is high and PCO<sub>2</sub> is low we know a state of respiratory alkalosis exists. However if PCO<sub>2</sub> is normal and bicarbonate is high we know a state of metabolic alkalosis exists.

## Chapter 24 Review Questions

1. Which of the following is not part of the extracellular compartment:
  - a. Interstitium
  - b. Lymph
  - c. Plasma
  - d. Cytosol
2. The typical adult body contains about \_\_\_\_ liters of fluid:
  - a. 20
  - b. 30
  - c. 40
  - d. 50
3. The thirst mechanism resides here:
  - a. Pons
  - b. Medulla oblongata
  - c. Parietal lobe
  - d. Hypothalamus
4. Which best describes the mechanism by which aldosterone affects fluid volume:
  - a. Causes sodium retention and water is retained by osmosis
  - b. Causes potassium secretion and water is removed by osmosis
  - c. Causes active transport of water to kidney capillaries
  - d. Increases filtration of water in kidney tubules
5. Which of the following is not a result of dehydration:
  - a. Dizziness
  - b. Mental confusion
  - c. Hypovolemia
  - d. Vasodilation
6. A person with a sodium level of 160 mg/dl has:
  - a. Nothing, this is normal
  - b. Hyponatremia
  - c. Hypernatremia
  - d. Hypokalemia
7. Which is the most severe problem:
  - a. Hyponatremia
  - b. Hypernatremia
  - c. Hypokalemia
  - d. Hyperkalemia

8. Which of the following is treated with calcium gluconate:
- Hyponatremia
  - Hypernatremia
  - Hypokalemia
  - Hyperkalemia
9. A decrease in blood calcium levels will facilitate the secretion of which substance:
- Parathyroid hormone
  - Calcitonin
  - Aldosterone
  - Atrial natriuretic hormone
10. A decrease in hydrogen ion concentration can produce:
- Hyperkalemia
  - Acidosis
  - Hyponatremia
  - Alkalosis
11. Prolonged vomiting producing an increase of hydrogen ions is most likely:
- Respiratory acidosis
  - Metabolic acidosis
  - Respiratory alkalosis
  - Metabolic alkalosis
12. A low PCO<sub>2</sub> is typically associated with:
- Respiratory acidosis
  - Metabolic acidosis
  - Respiratory alkalosis
  - Metabolic alkalosis

# Chapter 25

## Digestive System Anatomy

## **Digestive System Anatomy**

The gastrointestinal system or digestive system is vital to processing the substances our bodies need for growth and maintenance. Most of the substances we take in are too big to be used by the body. The digestive system breaks these substances down and absorbs them for use by tissues and cells. Before we get into the anatomy we should learn a few terms.

### **The Big Picture**

Digestion begins with the breakdown of food. This can be mechanical or chemical. For example when we eat an apple we first chew it up. This is mechanical digestion. Enzymes in saliva begin to break down the carbohydrate in the apple. This is known as chemical digestion. The chewed up and partially digested apple travels through the esophagus to the stomach and small intestines where chemical digestion is completed. The carbohydrate which consisted of complex sugars has now been broken down into simple sugars such as glucose. These are absorbed in the small intestine. The small intestine is built for absorption with a large surface area and slow peristaltic action that slowly moves substances through. Once absorbed the simple sugars travel through the blood stream and end up in cells that use them for energy. What's left over in the intestine is waste. The waste moves through the large intestine and is excreted as feces.

### **The Alimentary Canal**

The digestive system consists of a long tube extending from the mouth to the anus with some accessory organs attached. The total length of the tube is about 15-23 feet long. Fully extended it can be as large as 30 feet. The alimentary canal consists of the mouth, esophagus, stomach, duodenum, jejunum, ileum, cecum, colon, rectum and anus. The accessory organs include the tongue, teeth, salivary glands, pancreas, liver and gallbladder (fig. 25.1).

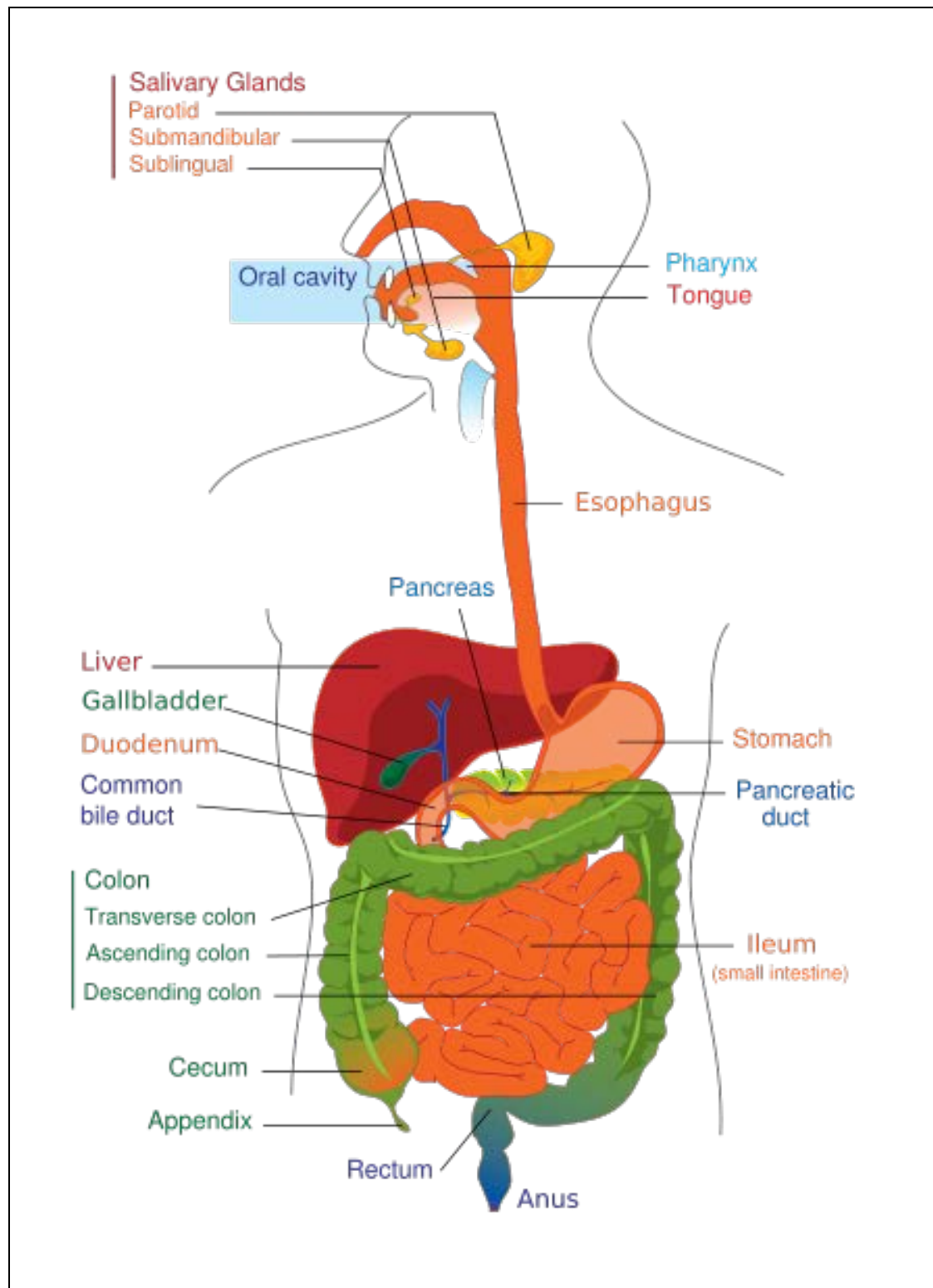


Figure 25.1. The gastrointestinal system.

[http://commons.wikimedia.org/wiki/File:Digestive\\_system\\_diagram\\_edit.svg](http://commons.wikimedia.org/wiki/File:Digestive_system_diagram_edit.svg)

Mariana Ruiz LadyofHats, edited by Joaquim Alves Gaspar

There are some important tissue similarities that are consistent throughout the alimentary canal. The canal contains four layers of tissue. The outer portion consists of a serous membrane called the serosa. This layer secretes a slimy serous fluid that helps reduce friction so the organs can slide over one another. Deep to this layer is a muscle layer called the muscularis layer. This consists of two layers of smooth muscle including longitudinal muscle and bands of circular muscle. There is also skeletal muscle under voluntary control in the mouth, pharynx and portions of the upper esophagus. The next layer is known as the submucosa. The submucosa consists of connective tissue that helps to hold the mucosa and muscularis layers together. It also contains blood and lymphatic vessels and nerves.

Deep to the muscularis layer is a mucous membrane called the mucosa. The mucosa consists of three layers including an epithelial layer, a layer of connective tissue called the lamina propria and a smooth muscle layer. The epithelial layer of the mucosa consists of stratified squamous in the mouth, pharynx, esophagus and anal canal and columnar epithelium in the stomach and intestines. The thin smooth muscle layer of the mucosa helps to produce folds in the membrane to increase the surface area.

Two membranes surround the digestive system. We already mentioned the serosal layer and this layer in the abdominal cavity is known as the visceral peritoneum. There is also a membrane lining the inside of the abdominal cavity known as the parietal peritoneum. The peritoneum consists of simple squamous epithelium and connective tissue.

The peritoneum also creates folds of tissue that extend between some of the organs. The greater omentum is one such fold that lies over the transverse colon and small intestines. The greater omentum also attaches to the greater curvature of the stomach. It contains blood vessels, lymphatic vessels, nerves and adipose tissue. The lesser omentum is much smaller and connects to the lesser curvature of the stomach. It has the same structure as the greater omentum. The falciform ligament extends from the liver to the anterior abdominal wall. The mesentery connects the small intestine to the posterior abdominal wall. The mesocolon connects the large intestine to the posterior abdominal wall as well.

## **Mouth**

The mouth or oral cavity is bordered by the lips anteriorly, cheeks laterally, tongue inferiorly and the hard and soft palate superiorly. The mouth is lined with a mucous membrane. The lips have an outer membrane consisting of skin and an inner mucous membrane. The upper lip contains a groove at the midline known as the philtrum (figs. 25.2, 25.3).

The cheeks also contain an outer skin and inner mucous membrane. The buccinator muscle lies between the membranes. The hard palate consists of the two palatine bones and the palatine processes of the maxilla. The soft palate is a muscular structure that forms two arches with the uvula in the midline. The arches form openings to the oropharynx called the fauces.

The tongue consists of skeletal muscles covered by a mucous membrane. The tongue is connected externally by a series of muscles including the genioglossus and hyoglossus. Parts of the tongue include a root, tip and body. The superior surface of the tongue contains papillae. There are several types of papillae including vallate, fungiform, circumvallate and filiform. The fungiform papillae contain taste buds. A section of mucous membrane connecting the tongue to the floor of the mouth is known as the lingual frenulum (fig. 25.4).



## **The Enteric Nervous System**

The digestive system contains a complex system of nerves called the enteric nervous system. The nerves form plexi that reside in the digestive tract walls and connect with higher nervous system centers in the central and autonomic nervous systems.

Many of the actions of the enteric nervous system occur within the system. However, both sympathetic and parasympathetic divisions of the autonomic nervous system also have an effect on digestion. The neurons in the enteric nervous system include sensory neurons that sense changes in chemical concentration and mechanical deformation of the tract. There are also motor neurons that help to control smooth muscle contraction and glandular secretions. Lastly, interneurons located in the enteric nervous system interconnect other neurons.

The enteric nervous system provides a good deal of control over the GI tract without influence from other parts of the nervous system. It produces reflex actions, controls secretions and smooth muscle contraction as well as blood flow.

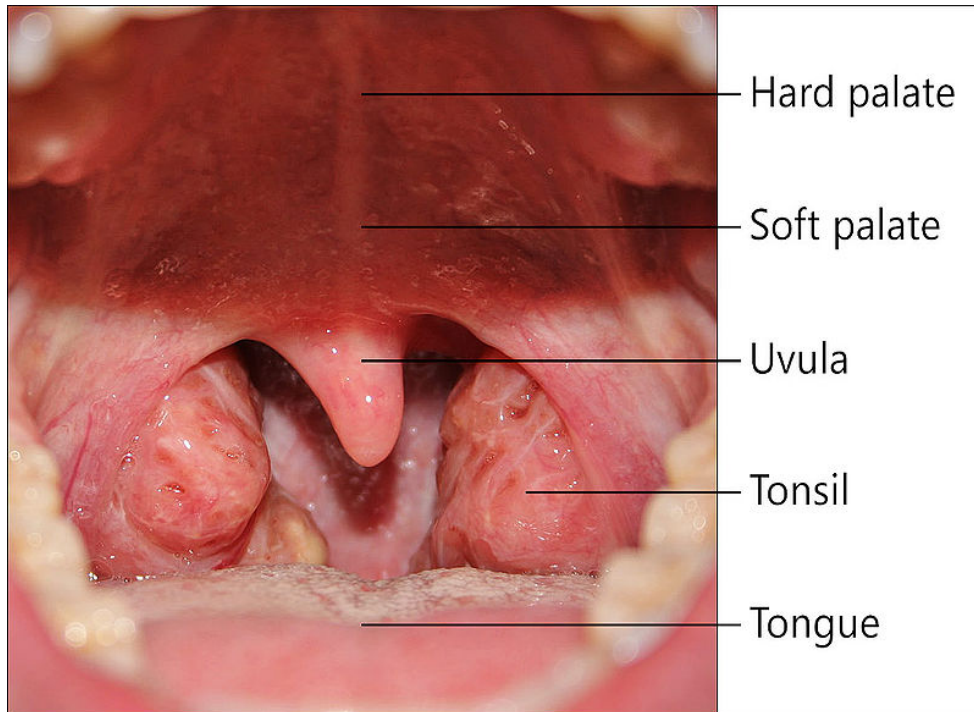


Figure 25.2. Mouth

[http://commons.wikimedia.org/wiki/File:Throat\\_with\\_Tonsils\\_0011J.jpeg](http://commons.wikimedia.org/wiki/File:Throat_with_Tonsils_0011J.jpeg)

Author: [Klem](#)

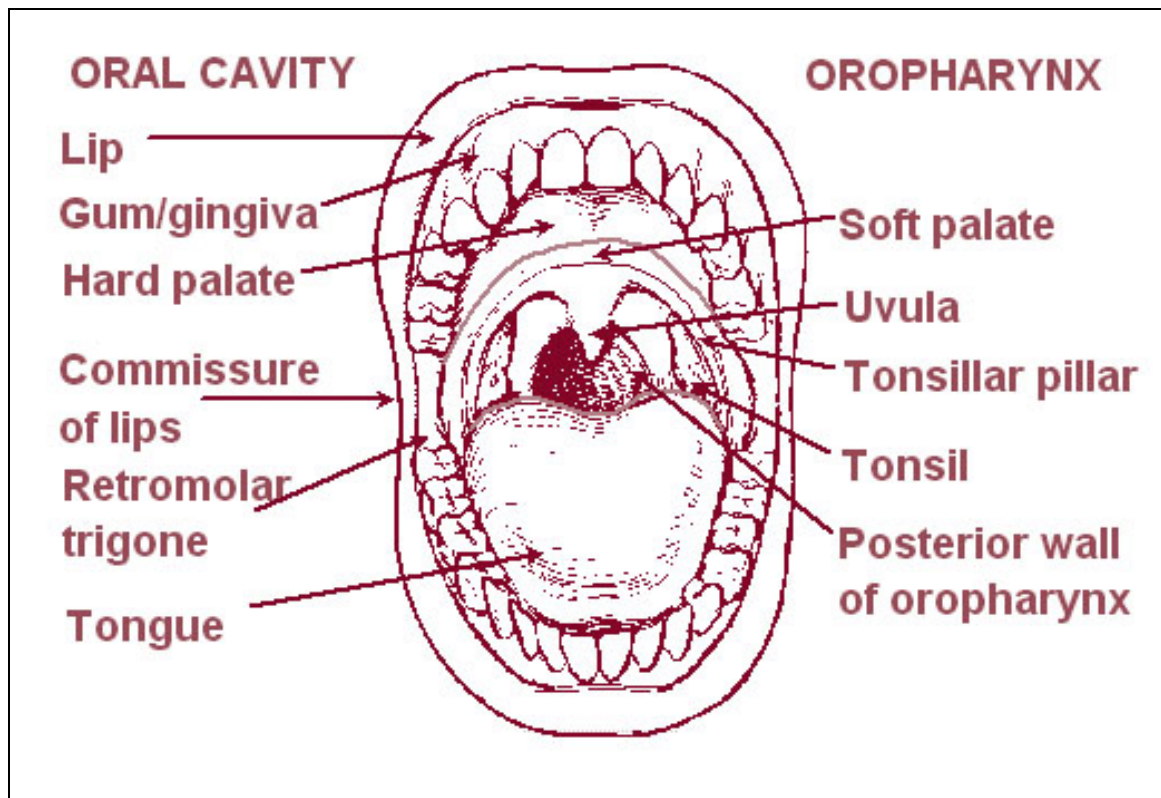


Figure 25.3. Mouth Structures

[http://commons.wikimedia.org/wiki/File:Illu03\\_mouth.jpg](http://commons.wikimedia.org/wiki/File:Illu03_mouth.jpg)

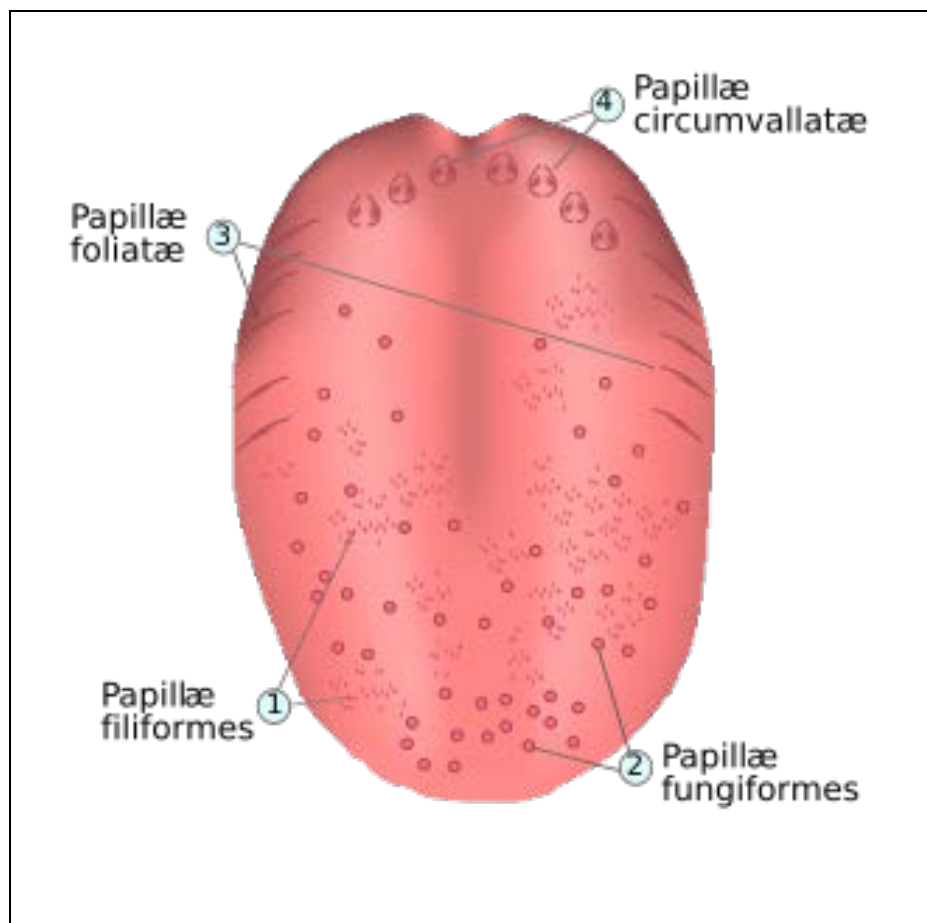


Figure 25.4. Tongue papillae

[http://commons.wikimedia.org/wiki/File:Papillae\\_on\\_tounge.svg](http://commons.wikimedia.org/wiki/File:Papillae_on_tounge.svg)

Derivative work: [Kjell ANDRÉ \(talk\)](#) [Kieli.svg](#): [Antimoni](#)

## Salivary Glands

There are three pairs of salivary glands. These are the parotid, submandibular and sublingual glands (fig. 25.5). The salivary glands produce about 1L of saliva per day. In addition to the large glands, small glands on the insides of the cheeks called buccal glands also secrete saliva (about 5% of the total volume per day) which helps to keep the mouth moist. The salivary glands are considered exocrine glands which secrete their substances into tubes.

The parotid glands are the largest salivary glands. They are also somewhat superficial and lie between the skin and masseter muscles just anterior and inferior to the ear. These glands secrete a serous fluid containing enzymes. The secretions travel by way of ducts (parotid or Stensen ducts) that pierce the buccinator muscles and empty into the oral cavity.

The submandibular glands are located just inferior to the angle of the mandible. They generate both serous and mucous secretions and are known as compound glands. The ducts of these glands (known as Wharton ducts) open into the floor of the mouth near the frenulum.

The sublingual glands are located just under the mucous membrane of the floor of the mouth. The sublingual glands are the smallest salivary glands. They contain a series of up to 20 ducts (Rivinus ducts) that drain into floor of the mouth. These glands only secrete mucous.

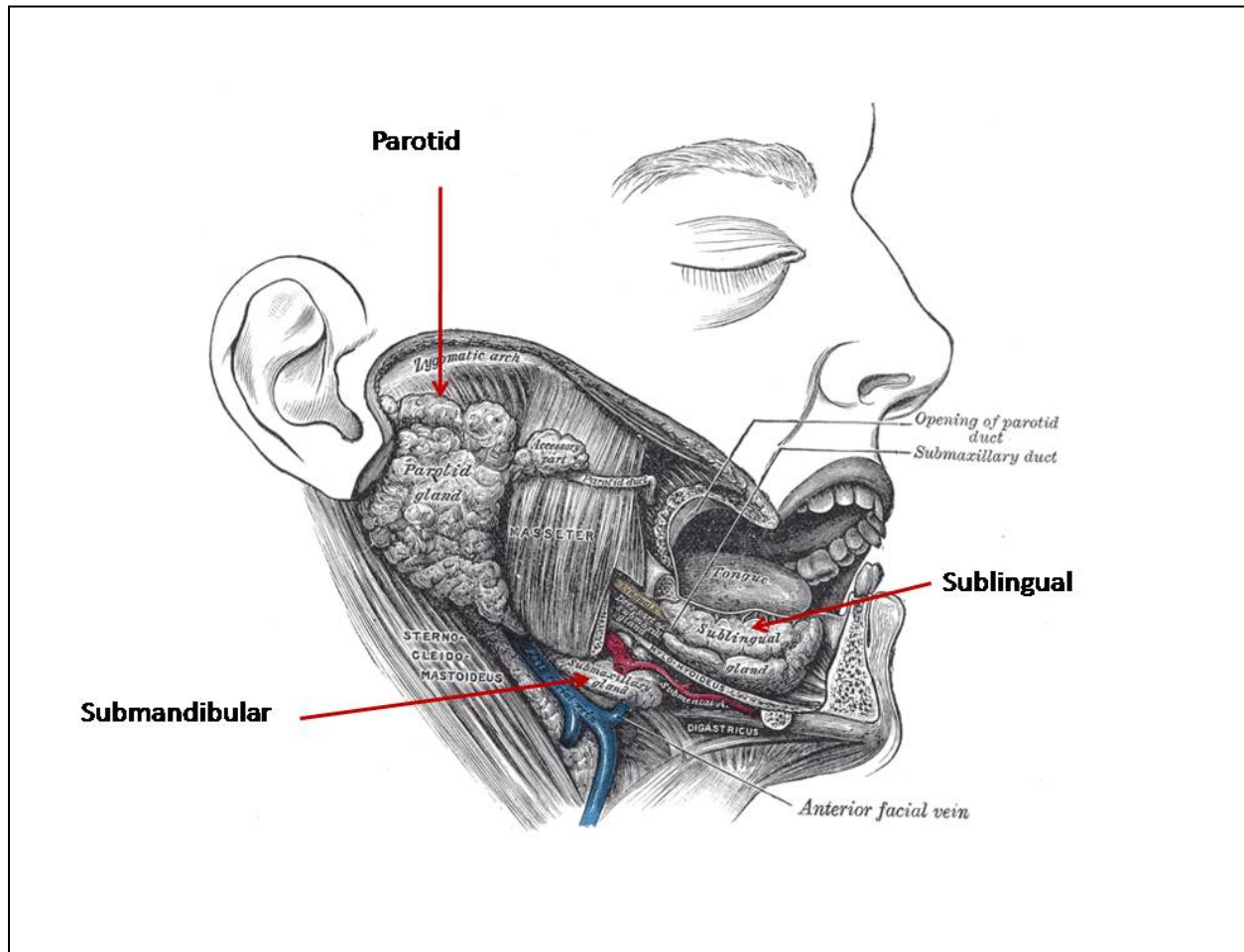


Figure 25.5. Salivary glands

<http://commons.wikimedia.org/wiki/File:Gray1024.png>

## The Teeth

A typical tooth consists of a crown, neck and a root. The crown is the visible portion. The root is a cone shaped process that lies below the gum line and forms a joint with the alveolar process of the mandible or maxilla. The neck is the portion surrounded by the gums. The crown is covered by enamel which is a hard substance that protects the teeth. Deep to the enamel is the dentin. In the crown dentin is covered by enamel. In the root the dentin is covered by cementum. The deepest portion of the tooth consists of a pulp cavity and root canal that contain blood vessels and nerves (figs. 25.6, 25.7).

The baby teeth are also known as deciduous teeth. There are 20 of these which are gradually replaced by the permanent teeth which number 32.

The deciduous teeth include:

4 central incisors

4 lateral incisors

4 canines

4 first molars

4 second molars

The secondary teeth include:

4 central incisors

4 lateral incisors

4 canines

4 first premolars (bicuspid)

4 second premolars (bicuspid)

4 first molars

4 second molars

4 wisdom teeth

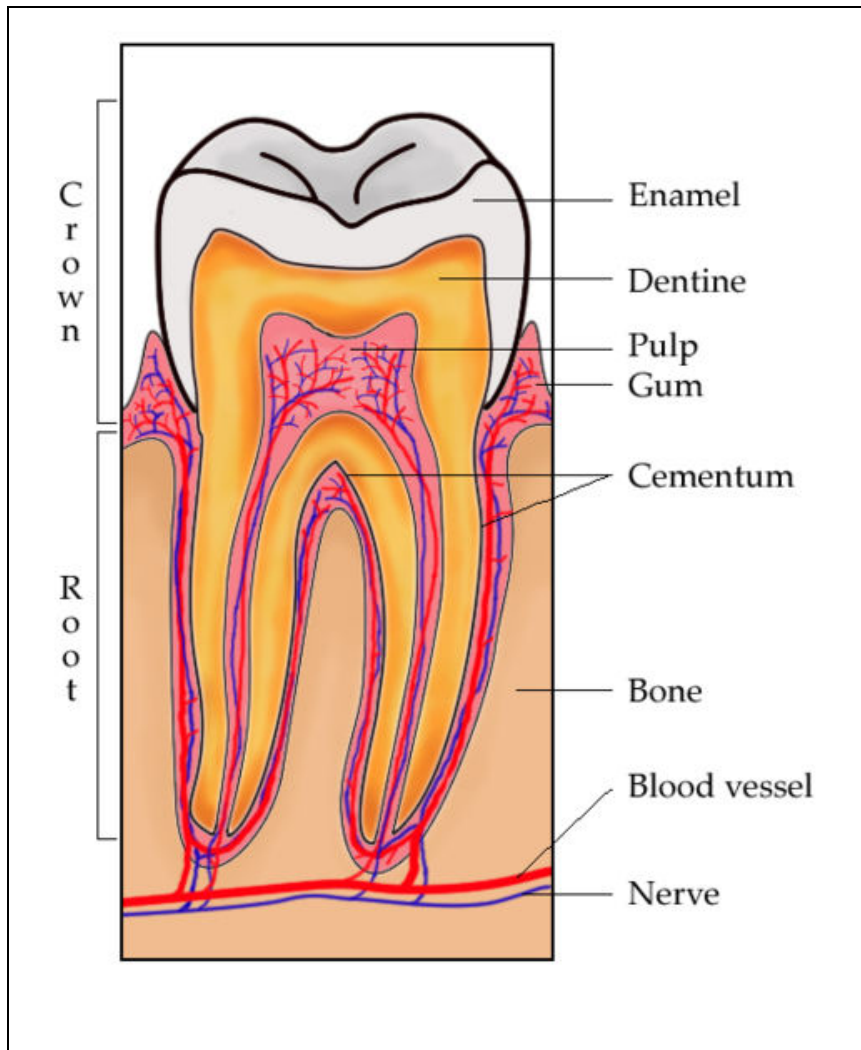


Figure 25.6. Tooth

<http://commons.wikimedia.org/wiki/File:ToothSection.jpg>

Author: Sam Fentress



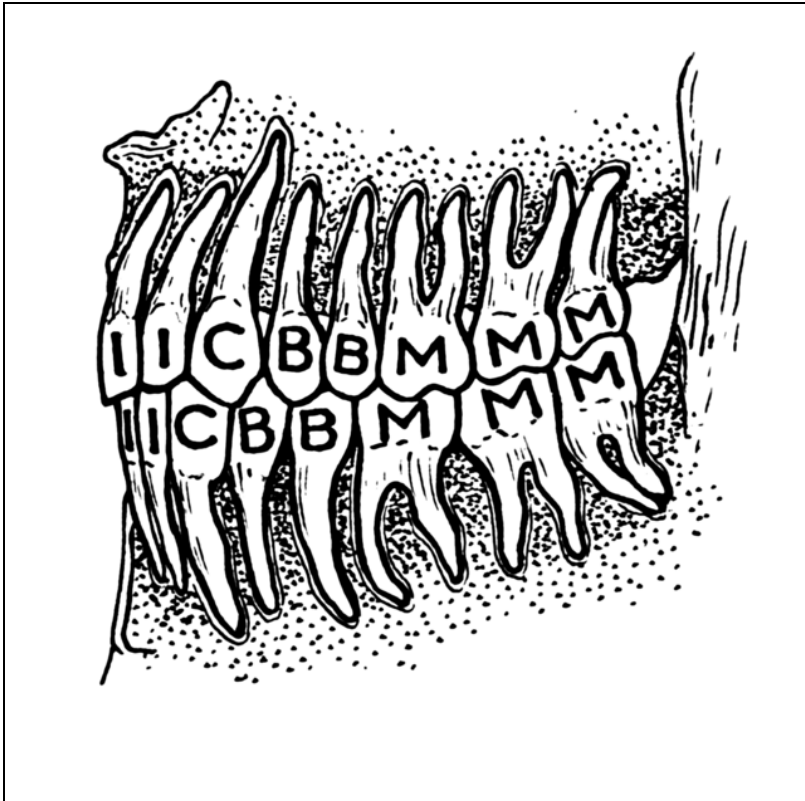


Figure 25.7. Teeth

I = incisor

C = canine

B = bicuspid

M = molar

[http://commons.wikimedia.org/wiki/File:Teeth\\_\(PSF\).png](http://commons.wikimedia.org/wiki/File:Teeth_(PSF).png)

## The Pharynx

The pharynx is a shared passageway for the respiratory and digestive systems. Food is chewed up and rolled in what is known as a bolus and pushed to the back of the mouth where it enters the pharynx for swallowing (fig. 25.8). You may wish to review the anatomy of the pharynx in the respiratory anatomy chapter.

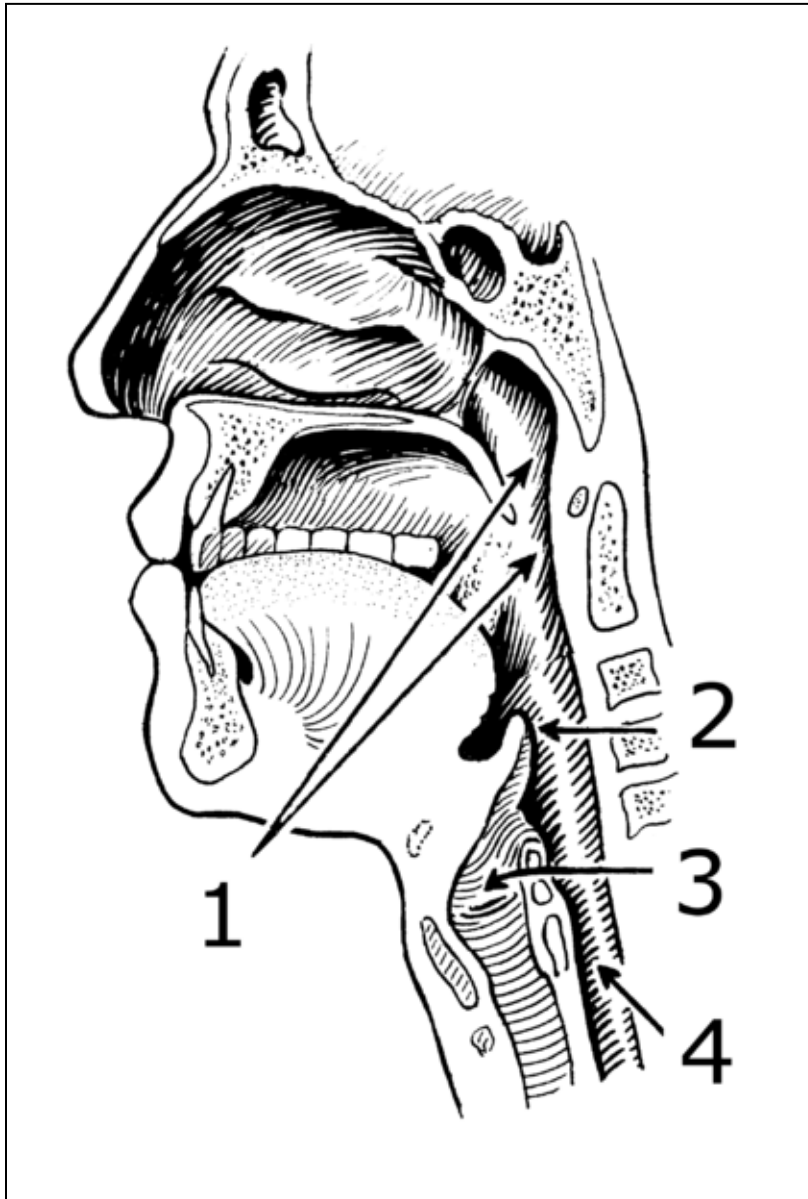


Figure 25.8. Pharynx

1. Pharynx
2. Epiglottis
3. Larynx
4. Esophagus

[http://commons.wikimedia.org/wiki/File:Pharynx\\_\(PSF\).png](http://commons.wikimedia.org/wiki/File:Pharynx_(PSF).png)

## The Esophagus

The esophagus is a muscular tube extending from the pharynx to the stomach (fig. 25.9). It lies posterior to the trachea. The upper portion of the esophagus contains voluntary skeletal muscle. The middle and lower sections contain involuntary smooth muscle.

The esophagus has two circular sphincter muscles. The upper esophageal sphincter keeps the esophagus closed during breathing to keep air from moving into the digestive tract. The lower esophageal sphincter (cardiac sphincter) is located at the inferior end of the esophagus where it pierces the diaphragm at the esophageal hiatus. The lower esophageal sphincter remains closed until swallowing occurs. In some cases the diaphragm is weakened near the hiatus and the sphincter enlarges. This is known as a hiatal hernia and can allow contents of the stomach to enter the esophagus and cause gastric reflux.

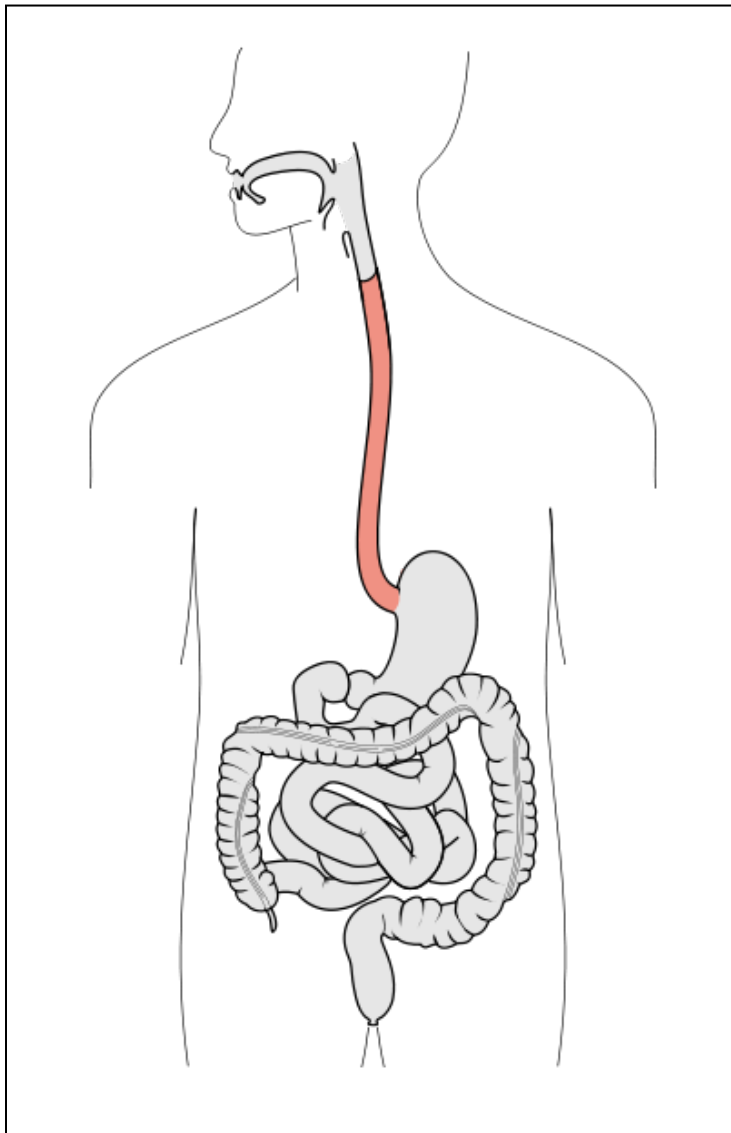


Figure 25.9. Esophagus

[http://commons.wikimedia.org/wiki/File:Tractus\\_intestinalis\\_esophagus.svg](http://commons.wikimedia.org/wiki/File:Tractus_intestinalis_esophagus.svg)

## **The Stomach**

The esophagus empties into the stomach which is a curved pouchlike organ. There are four major divisions of the stomach. These include the cardiac region, body, fundus and pylorus. The cardiac region is the superior portion just after the esophagus. The fundus is an upward bulge that is located on the left side. The body is the central portion and the pylorus the inferior portion (figs. 25.10, 25.11).

The outer portion of the stomach contains a concave and convex curve. The concave curve is called the lesser curvature while the convex curve is the greater curvature.

The stomach contains two sphincters at each opening. The lower esophageal (cardiac) sphincter allows substances to enter while the pyloric sphincter allows substances to exit.

The stomach has three smooth muscle layers. The outer layer runs longitudinally across the stomach. The middle layer is a circular layer that produces constriction of the stomach. The internal layer is an oblique muscle layer.

The inside of the stomach is lined with simple columnar epithelium. The epithelium contains tube-like openings called gastric pits. Secretions from gastric glands flow through the pits to the inside of the stomach. There are also a good deal of mucous secreting cells that secrete and alkaline mucous to help to protect the lining. The inner membrane creates folds called rugae. The rugae increase the surface area and help in mixing the contents of the stomach.

The gastric glands consist of mucous secreting cells, parietal cells and chief cells. Parietal cells secrete hydrochloric acid and intrinsic factor. Chief cells secrete a precursor enzyme called pepsinogen. Pepsinogen combines with hydrochloric acid to become an active form known as pepsin. Pepsin digests proteins. There are also endocrine cells that secrete hormones that help to control digestion. An example is intrinsic factor that combines with vitamin B12 to help in absorption.

Parietal cells contain a proton pump that helps to produce hydrochloric acid. Carbon dioxide and water enter the parietal cell and combine with the enzyme carbonic anhydrase to form carbonic acid. The carbonic acid dissociates into bicarbonate and hydrogen ions. The hydrogen ions are actively transported out of the cell and into the stomach by a transport protein (proton pump). Bicarbonate ions flow down their concentration gradient and are exchanged for chloride ions.

The parietal cells are capable of creating a very acidic pH of 2.0 within the stomach.

The combination of all of the stomach secretions is known as gastric juice. Food enters the stomach and combines with gastric juice to form a pasty substance called chyme. Chyme then leaves the stomach by way of the pyloric sphincter and enters the duodenum.

## **Stomach Movements**

The stomach can mix substances and move them through. Both of these movements result from smooth muscle contractions. Weaker peristaltic waves help to mix the stomach contents while stronger waves move the contents toward the pylorus. Emptying of the stomach is controlled so that it occurs at a rate that allows for adequate digestion of substances.

Vomiting is a reverse peristaltic action of the stomach. The vomiting center in the medulla oblongata is sensitive to stimuli such as toxins and rapid body movements. The vomiting center also receives cortical input so certain thoughts can cause vomiting.

## Stomach

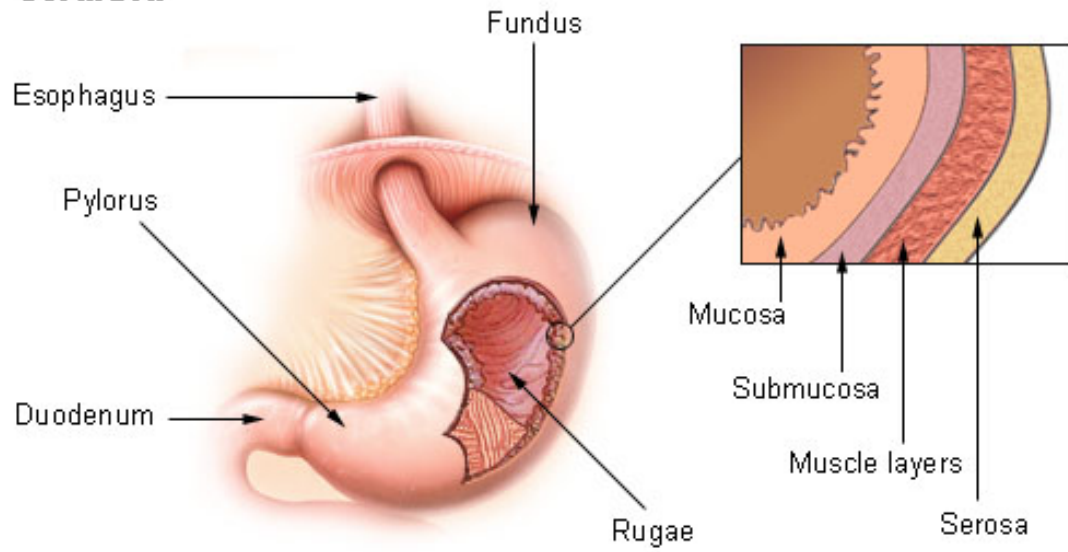


Figure 25.10. Stomach

[http://commons.wikimedia.org/wiki/File:Illu\\_stomach2.jpg](http://commons.wikimedia.org/wiki/File:Illu_stomach2.jpg)

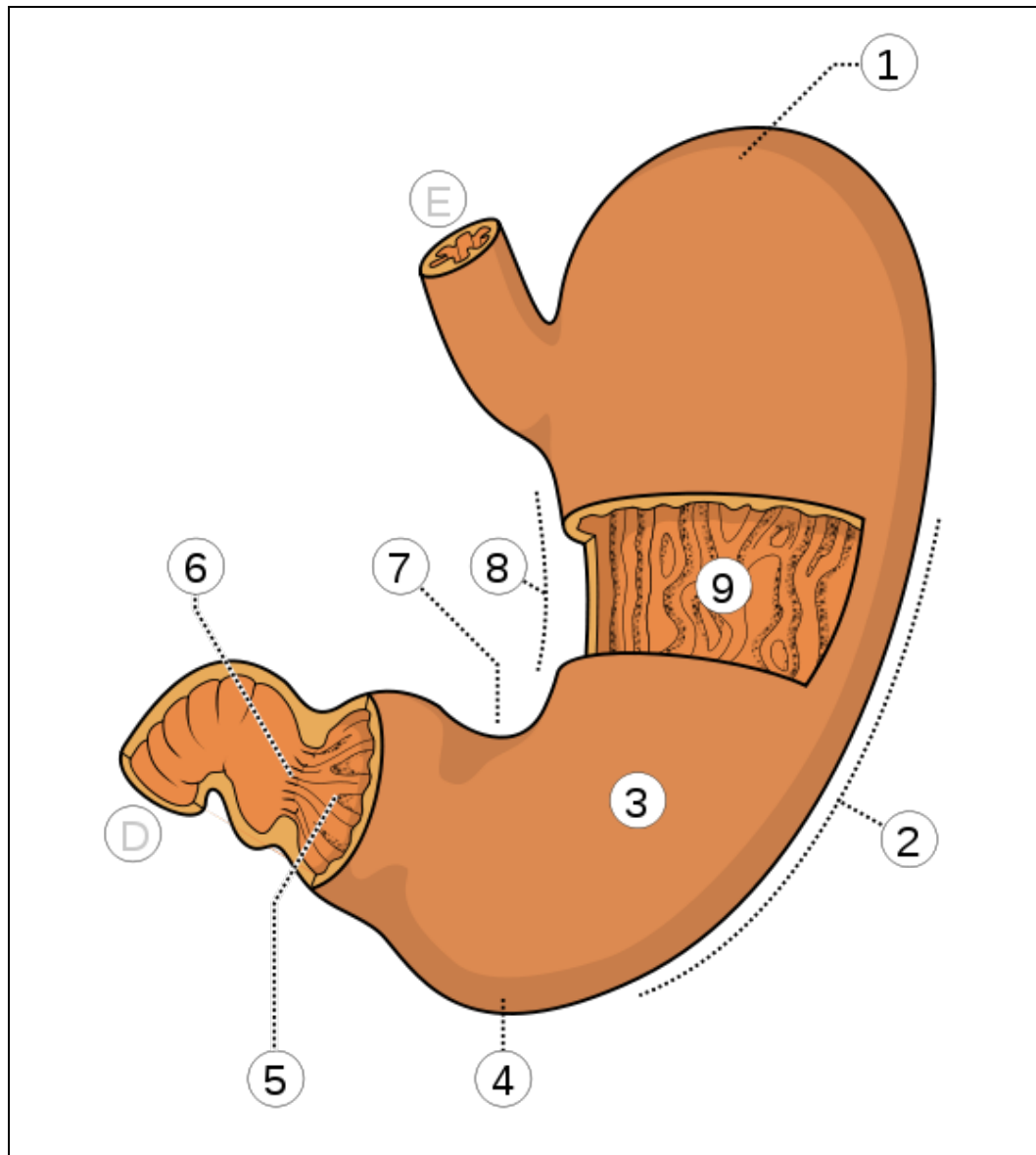


Figure 25.11. Stomach

- 1. fundus
- 2. greater curvature
- 3. body
- 4. Inferior aspect
- 5. pyloric antrum
- 6. pyloric canal
- 7. angular notch
- 8. lesser curvature
- 9. rugal folds
- E. esophagus
- D. duodenum (bulbus and part of descending part)

<http://commons.wikimedia.org/wiki/File:Ventriculus.svg> Author: Olek Remesz

## **The Small Intestine**

The small intestine consists of three parts. The proximal section is the duodenum which is followed by the jejunum and ileum. The duodenum begins at the pylorus and extends about 10 inches. It becomes the jejunum at its distal curve. The jejunum extends for about 8 feet before gradually becoming the ileum. There is no anatomical separation between jejunum and ileum (figs. 25.12, 25.13).

The small intestine is built for absorption with a large surface area. The inside of the small intestine consists of circular folds called plica circulares. The plicae also contain numerous finger-like projections known as villi. The villi contain blood vessels and a lymphatic system tubule called a lacteal (figs. 25.14, 25.15). The intestine is lined with cilia containing epithelium. The epithelial membrane resembles a brush and is sometimes referred to as a brush border. The cells lining the intestine secrete enzymes and mucus. The membrane also contains intestinal crypts (crypts of Lieberkuhn) that are areas of rapid mitosis. The crypts help the intestinal membrane to renew itself as old cells are pushed out of the villi as they are replaced by new cells.

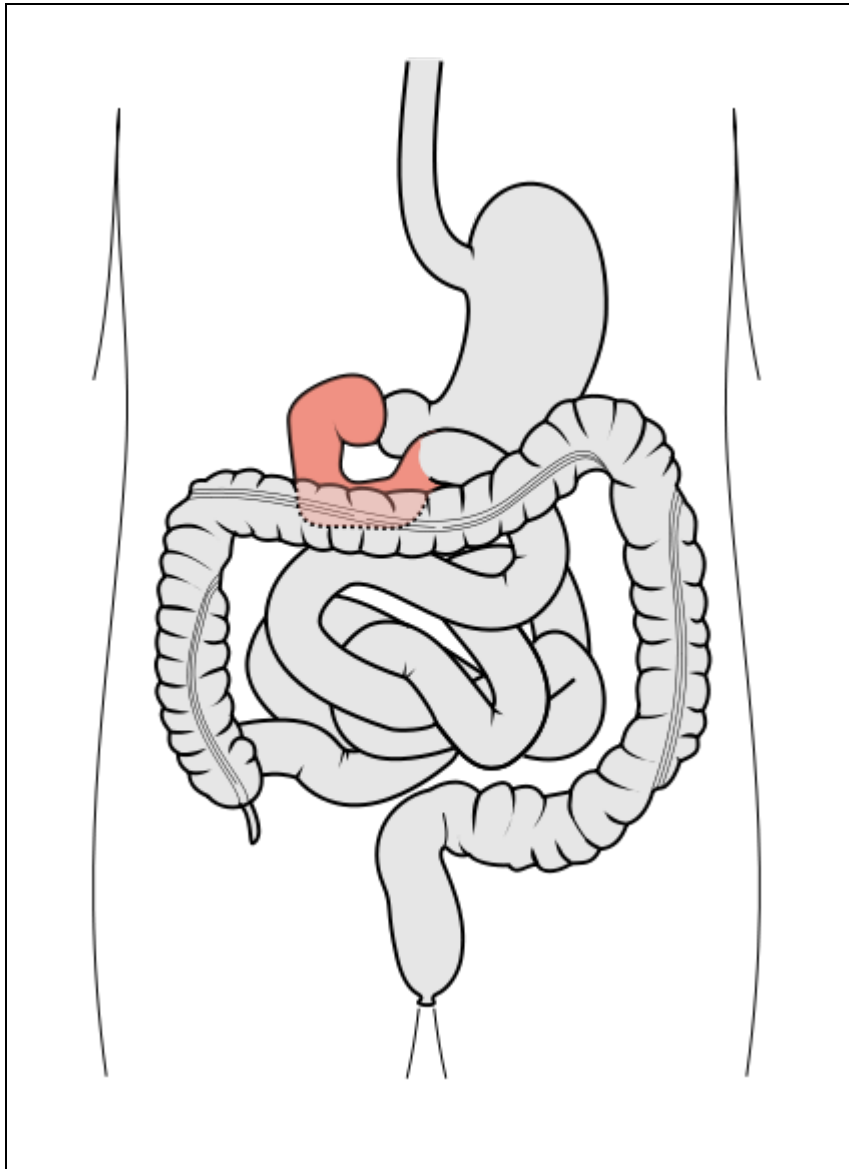


Figure 25.12. Duodenum

[http://commons.wikimedia.org/wiki/File:Tractus\\_intestinalis\\_duodenum.svg](http://commons.wikimedia.org/wiki/File:Tractus_intestinalis_duodenum.svg)

Author: Olek Remesz



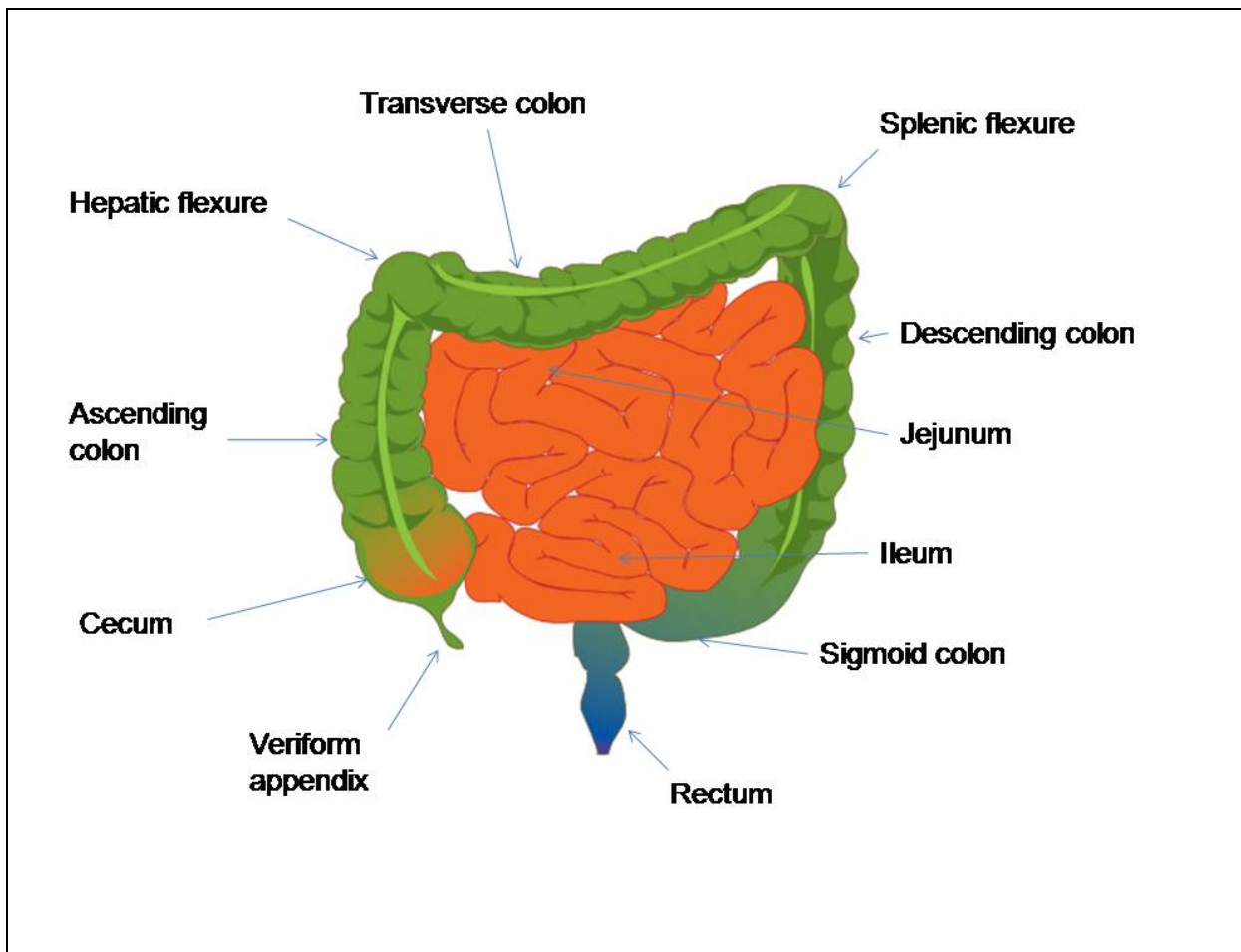
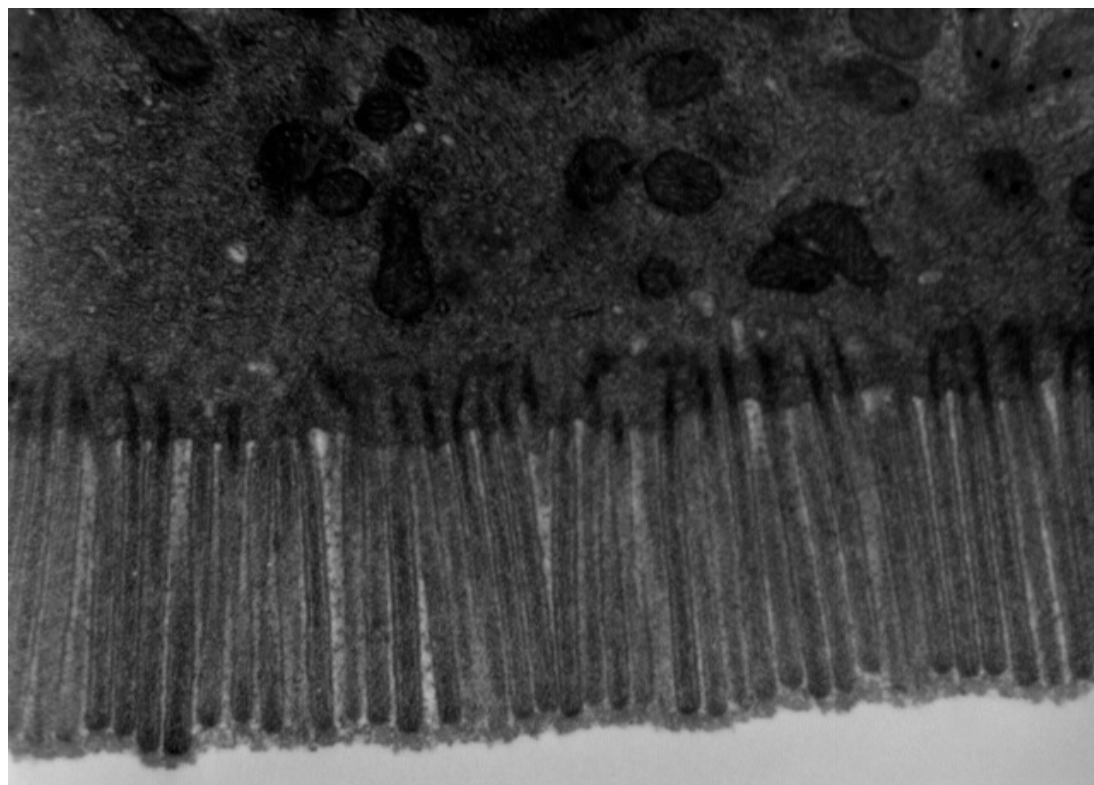


Figure 25.13. Intestines and colon

[http://commons.wikimedia.org/wiki/File:Intestine\\_-\\_sized.png](http://commons.wikimedia.org/wiki/File:Intestine_-_sized.png)

Labelled by Bruce Forciea



100 nm

1Microvilli

1/7/0 REMF

Figure 25.14. Intestinal villi

[http://commons.wikimedia.org/wiki/File:Human\\_jejunum\\_microvilli\\_1\\_-\\_TEM.jpg](http://commons.wikimedia.org/wiki/File:Human_jejunum_microvilli_1_-_TEM.jpg)

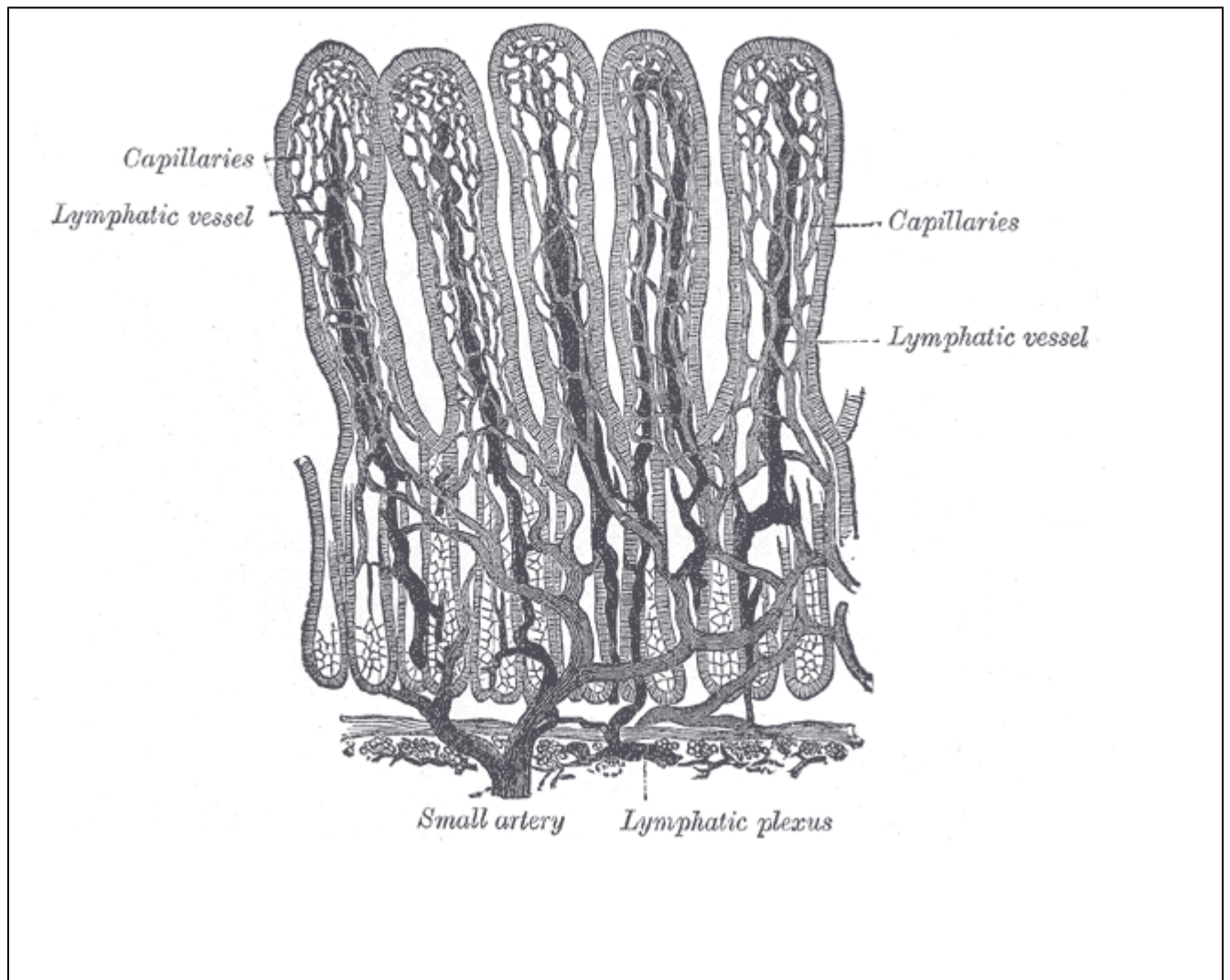


Figure 25.15. Intestinal villi.

<http://commons.wikimedia.org/wiki/File:Gray1061.png>

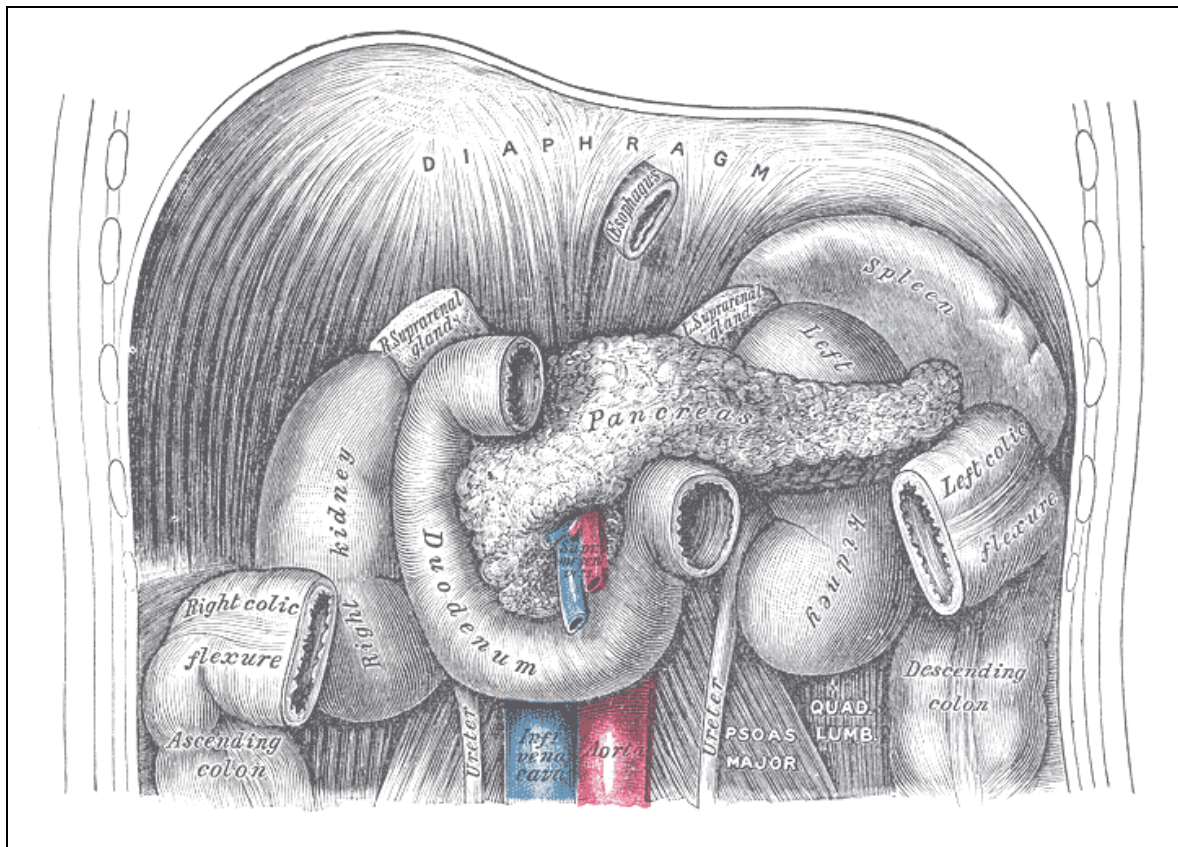


Figure 25.16. Pancreas and duodenum

<http://commons.wikimedia.org/wiki/File:Gray1056.png>

## **The Large Intestine**

The large intestine begins at a pouch called the cecum. The junction between the ileum and cecum occurs at a smooth muscle sphincter in the cecum known as the ileocecal valve or sphincter. The diameter of the large intestine (2.5 inches) is much larger than the small intestine (1 inch).

The cecum contains a fingerlike projection (8-10cm) called the vermiform appendix. The function of the appendix is not known but it may be an area for breeding intestinal bacteria (intestinal flora).

Extending vertically from the cecum is the first segment of the colon known as the ascending colon. The ascending colon takes a left turn at the liver (hepatic flexure) and continues horizontally as the transverse colon. The transverse colon takes a downward turn at the spleen (splenic flexure) and continues as the descending colon. As the descending colon extends beyond the iliac crest it becomes the sigmoid colon which is S-shaped.

The sigmoid colon becomes the rectum which runs about 7-8 inches long. The last inch or so of the rectum is known as the anal canal. The anal canal contains vertical folds called anal columns. The anal columns contain blood vessels. The rectum contains two sphincter muscles including an internal and external sphincter. The internal sphincter consists of smooth muscle while the external sphincter is striated muscle. The opening of the anal canal is called the anus (figs. 25.20, 25.21).

The large intestine contains numerous mucous secreting glands. Along the outside of the colon are bands of smooth muscles called taeniae coli that run longitudinally. There are also rings of smooth muscle that divide the colon into pouchlike structures called haustra.

## **The Liver**

The liver is located in the right upper quadrant of the abdominal cavity close to the diaphragm. The liver consists of four lobes including right, left, quadrate, and caudate. The falciform ligament (figs. 25.17, 25.19) separates the right and left lobes.

The lobes are further divided into lobules by blood vessels and connective tissue. Tributaries of the hepatic vein extend into each lobule. Hepatic plates radiate outward from the central region of the lobules. Bile ducts and interlobular arteries are located on the outer regions of the plates. Smaller bile vessels called canaliculi permeate the plates and collect bile from the hepatic cells. Sinusoids containing white blood cells called Kupffer cells are located between the plates. These cells help phagocytize bacteria and debris.

The small bile ducts merge into one large duct known as the hepatic duct. The hepatic duct merges with the cystic duct emerging from the gallbladder to form the common bile duct. The common bile duct carries bile to the duodenum. The common bile duct merges with the pancreatic duct just before entering the duodenum.

The liver performs many functions and is considered a vital organ. Its functions include detoxifying the blood, producing bile, metabolism of carbohydrates, fats and proteins, storing iron, blood and vitamins, recycling red blood cells and producing plasma proteins.

The liver secretes bile which is stored in the gallbladder. Bile contains bile salts that are formed from cholesterol. Bile works to break down fat by emulsification and eliminates products from the breakdown of red blood cells. The gallbladder contains an outer serous membrane as well as a smooth muscle layer and inner mucous membrane. The inside of the gallbladder contains rugae much like the stomach. The



gallbladder is about 3-4 inches long. In some cases bile can precipitate and form gallstones. The gallbladder can become inflamed in a condition known as cholecystitis.

### **The Pancreas**

The pancreas has a dual endocrine and exocrine role (figS. 25.16, 25.18). We investigated the endocrine role in the endocrine system chapter. The exocrine portion consists of compound acinar glands. These are branching duct structures containing clusters of cells that secrete substances into the ducts. The smaller ducts merge with the larger pancreatic duct. The pancreatic duct merges with the common bile duct at an area in the duodenum known as the hepatopancreatic ampulla. The hepatopancreatic ampulla is encircled by smooth muscle forming the hepatopancreatic sphincter.

The exocrine glands secrete digestive enzymes. The endocrine cells are called alpha and beta cells. The alpha cells secrete glucagon and the beta cells secrete insulin.

The pancreas consists of a body, head and a tail. It is located in the curve of the duodenum.

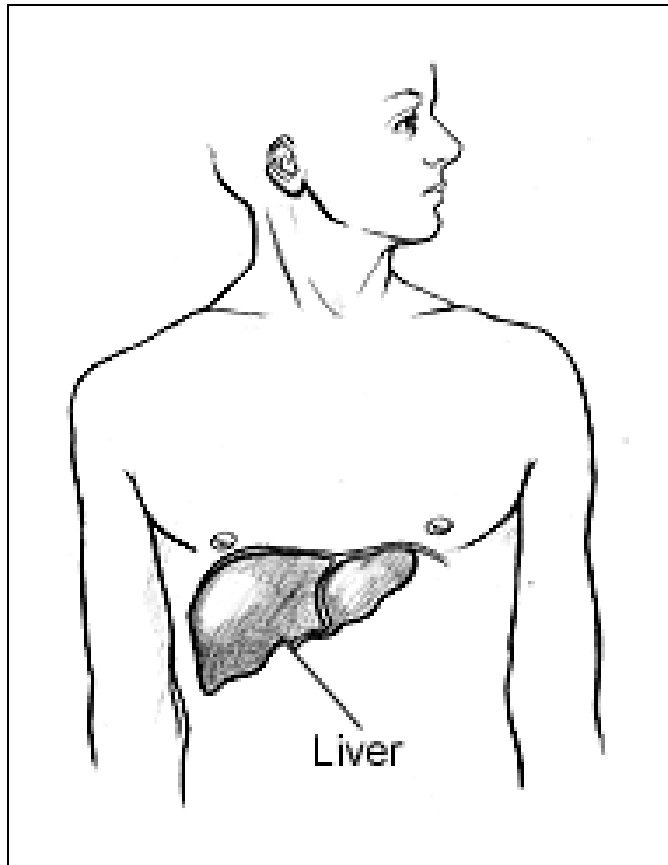


Figure 25.17. The liver is located in the right upper quadrant.

<http://commons.wikimedia.org/wiki/File:Liver2.png>

## Pancreas

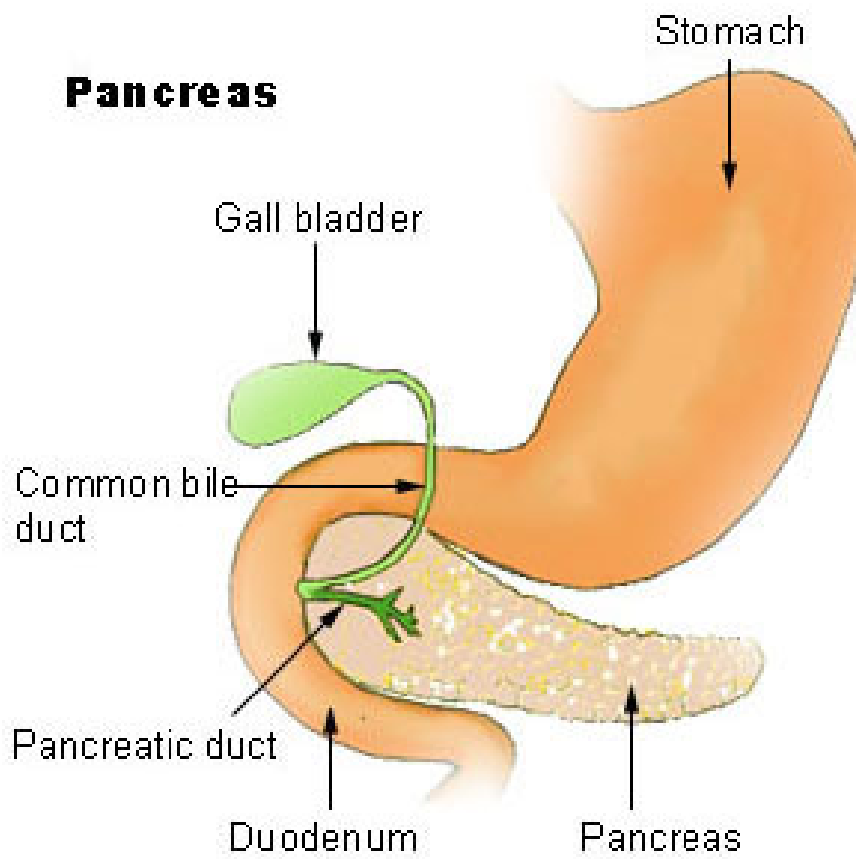


Figure 25.18. Pancreas

[http://commons.wikimedia.org/wiki/File:Illu\\_pancrease.jpg](http://commons.wikimedia.org/wiki/File:Illu_pancrease.jpg)



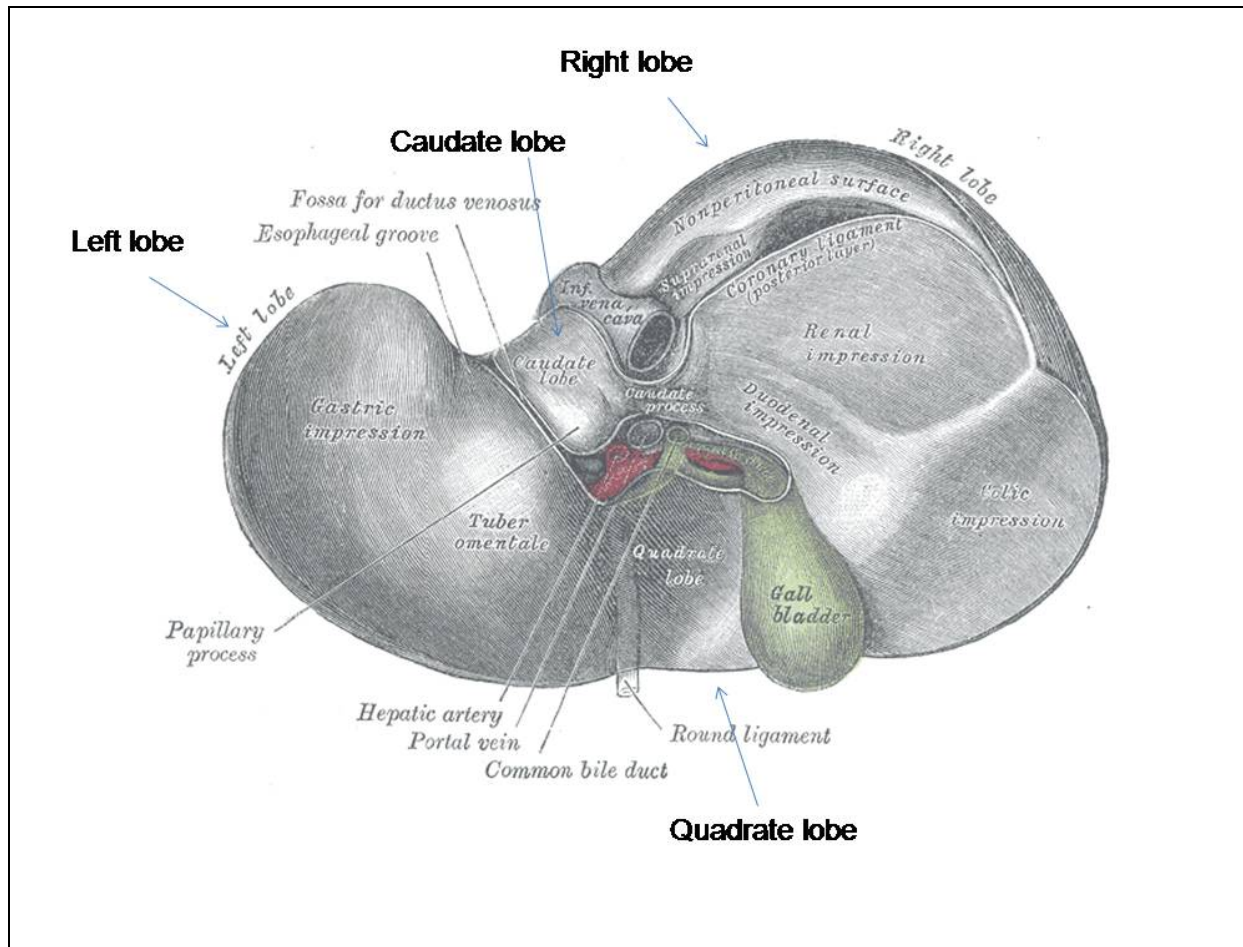


Figure 25.19. Liver

<http://upload.wikimedia.org/wikipedia/commons/1/1a/Gray1086-liver.PNG>

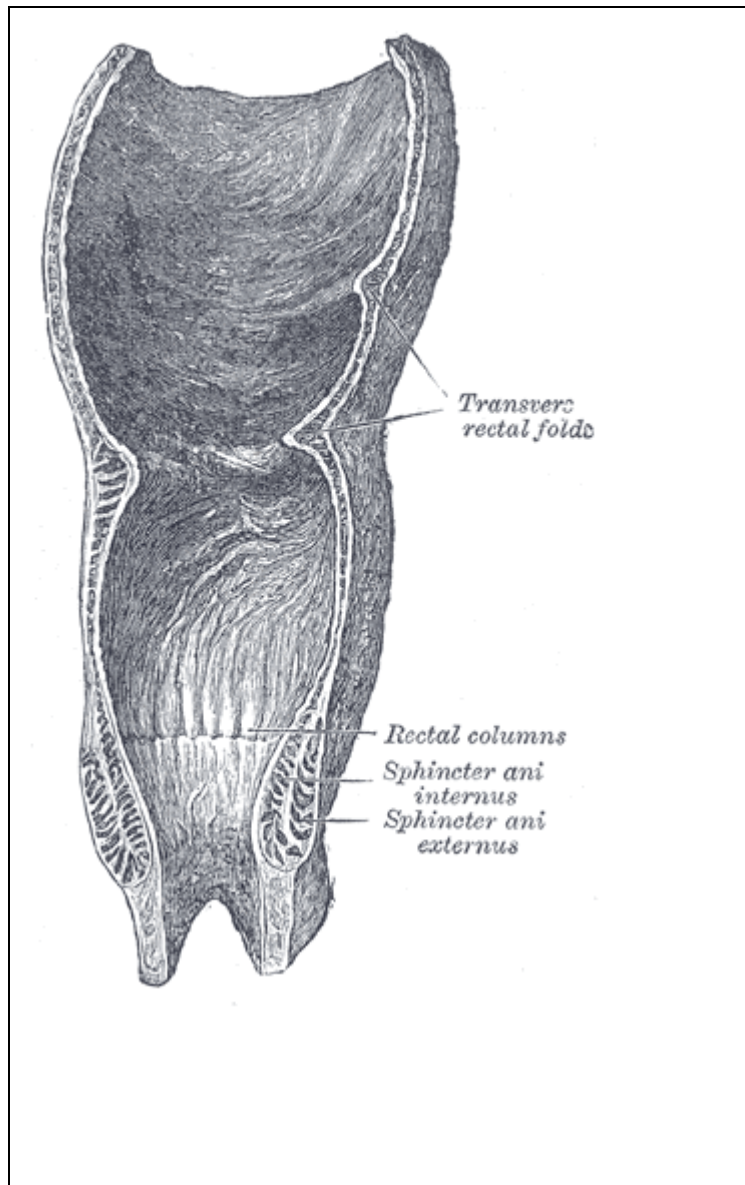


Figure 25.20. Rectum

[http://commons.wikimedia.org/wiki/File:Gray\\_1078.png](http://commons.wikimedia.org/wiki/File:Gray_1078.png)

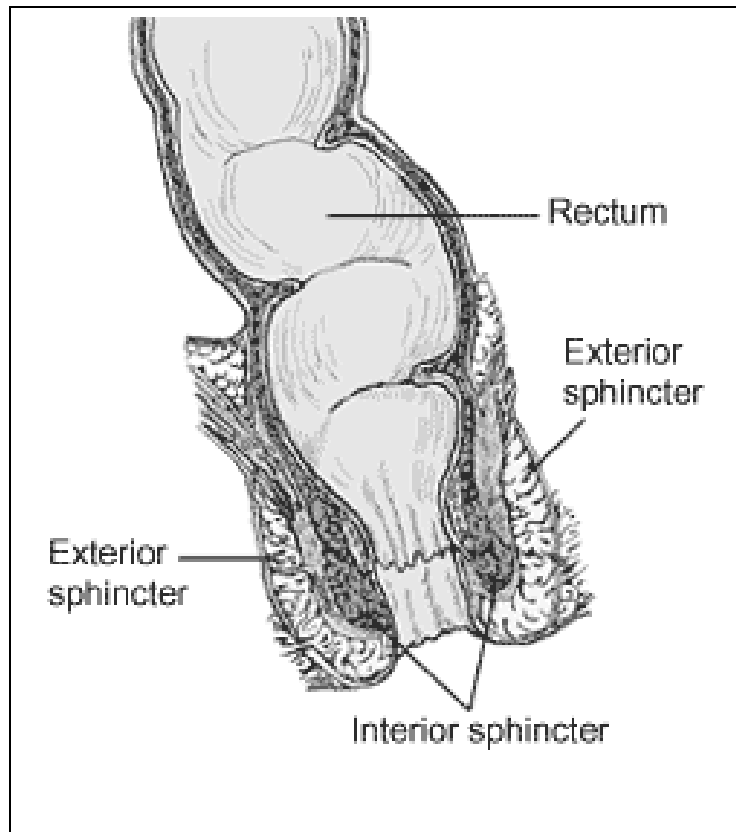


Figure 25.21. Rectum

<http://commons.wikimedia.org/wiki/File:Anorectum.gif>

## Chapter 25 Review Questions

1. Which of the following is not part of the alimentary canal:
  - a. Stomach
  - b. Ileum
  - c. Liver
  - d. Duodenum
2. The alimentary canal contains \_\_\_\_ smooth muscle layers:
  - a. 1
  - b. 2
  - c. 3
  - d. 4
3. Which of the following papillae contain taste buds:
  - a. Vallate
  - b. Circumvallate
  - c. Fungiform
  - d. Filiform
4. Which of the following salivary glands secrete salivary amylase:
  - a. Parotid
  - b. Submandibular
  - c. Sublingual
  - d. All of the above
5. How many secondary teeth are there in the adult human:
  - a. 24
  - b. 26
  - c. 30
  - d. 32
6. Which of the following is not a stomach structure:
  - a. Rugae
  - b. Fundus
  - c. Pylorus
  - d. Omentum
7. Pepsinogen is secreted by which stomach cells:
  - a. Chief
  - b. Parietal
  - c. Columnar
  - d. Serous

8. Which of the following is not a stomach secretion:
- a. Pepsinogen
  - b. Hydrochloric acid
  - c. Vit B12
  - d. Intrinsic factor
9. Where is the vomiting center located:
- a. Cerebrum
  - b. Medulla oblongata
  - c. Sympathetic nervous system
  - d. Pons
10. Where are the crypts of Lieberkuhn located:
- a. Stomach
  - b. Small intestine
  - c. Esophagus
  - d. Pancreas
11. Which best describes the structures known as haustra:
- a. Pouches in the small intestine
  - b. Long smooth muscle segment in the large intestine
  - c. Pouches in the large intestine
  - d. Circular structures on the inner portion of the small intestine
12. Bile is formed in which of the following:
- a. Pancreas
  - b. Duodenum
  - c. Gallbladder
  - d. Liver

# Chapter 26

## Digestive System Physiology

## **Digestive System Physiology**

In order to supply the body with the substances it needs the digestive system must perform a number of processes. These include breaking the substances down by mechanical and chemical digestion, absorption, assimilation and eliminating waste products. This chapter will focus on the physiology of digestion.

### **Digestion in the Mouth**

Mechanical digestion begins in the mouth with chewing or mastication. The teeth physically break down food and the mandible moves to provide the necessary force. The muscles of mastication include the masseter and temporalis muscles. The front teeth known as the incisors work to tear the food while the molars work to grind it into smaller pieces. The final goal of mastication is to increase the surface area of the food so that the digestive enzymes can continue to break it down. Before swallowing food the mouth forms it into an oval bolus. The bolus is pushed to the pharynx by the tongue.

Chemical digestion also begins in the mouth. The parotid and submandibular salivary glands contain an enzyme called salivary amylase. This enzyme begins carbohydrate digestion. Salivary amylase essentially breaks complex sugars (polysaccharides) into disaccharides such as maltose and isomaltose.

The structure of the mouth does not allow for much absorption however some chemicals can be absorbed. These include nitroglycerin and some vitamins.

### **Swallowing**

There are essentially three phases to swallowing (deglutition). These include a voluntary phase followed by pharyngeal and esophageal phases. The first phase consists of pushing the bolus of food toward the back of the mouth to the pharynx.

During the second phase or pharyngeal phase the uvula of the soft palate raises to block the nasopharynx and a series of pharyngeal muscles known as the superior pharyngeal constrictor muscles contract. The action of the constrictor muscles pushes the bolus toward the esophagus. The epiglottis closes to block the passageway to the larynx and the larynx is elevated. One can view the elevation of the larynx during swallowing by observing the thyroid cartilage elevate during swallowing.

During the last phase or esophageal phase the smooth muscles of the esophagus create a peristaltic wave that pushes the food to the stomach. The lower esophageal sphincter relaxes to allow food to pass into the stomach.

### **Digestion in the Stomach**

Once food reaches the stomach it mixes with the secretions of the stomach. The stomach contains cells that produce secretions that continue the chemical digestion of food. The parietal cells secrete hydrochloric acid and intrinsic factor and chief cells secrete pepsinogen. Mucous secreting cells that secrete an alkaline mucous help protect the stomach lining. G-cells secrete gastrin and enterochromaffin cells secrete histamine.

Pepsinogen combines with hydrochloric acid to produce pepsin. Pepsin is an enzyme that digests proteins by breaking peptide bonds. Intrinsic factor combines with vitamin B12 so that it can be absorbed. Gastrin and histamine help to regulate secretions.

The combination of all of the gastric secretions is known as gastric juice. Gastric juice combines with food to produce a pasty substance called chyme.

There are three phases of gastric secretions. These include the cephalic, gastric and gastrointestinal phases. The cephalic phase is a preparatory phase for the arrival of food (fig. 26.1). Thoughts and smells can initiate the cephalic phase. During this phase the parasympathetic nervous system sends impulses to the stomach by way of the vagus nerve. The postganglionic parasympathetic neurons secrete acetylcholine that stimulates the production of stomach secretions.

Gastrin is secreted in response to parasympathetic stimulation and promotes the release of more hydrochloric acid. Gastrin also causes the release of histamine which also promotes the release of hydrochloric acid. The action of the parasympathetics causing secretion of hydrochloric acid and gastrin which in turn causes more release of hydrochloric acid constitutes a positive feedback mechanism. This is one of the few positive feedback mechanisms in the body.

The hormone somatostatin also plays a role in the regulation of digestion. We have seen somatostatin in the endocrine system as it played a role in the regulation of growth hormone. There are 2 types of somatostatin secreted in the body. The type SS-14 is produced by the hypothalamus and pancreas while type SS-28 is produced by the intestines. This type of somatostatin has an inhibitory effect on gastrointestinal secretions including the hormones gastrin and secretin. The parasympathetic nervous system can facilitate digestion by inhibiting the release of somatostatin type SS-28.

The gastric phase is characterized by food entering the stomach (fig. 26.2). Stimuli such as distention of the stomach and the presence of proteins promote additional secretions of gastric juice. The stimuli activate the parasympathetic nervous system to send impulses to the stomach causing a series of events similar to those in the cephalic phase.

The regulation of gastric secretions is also affected by the pH of the stomach. If the pH gets lower than 2.0 stomach secretions are inhibited.

During the gastrointestinal phase stomach secretions are inhibited when chyme exits the stomach and reaches the duodenum (fig. 26.3). This occurs most when chyme is acidic. Digestive enzymes work better with alkaline conditions. Acid chyme entering the duodenum causes the release of the hormone secretin which has an inhibitory effect on gastric secretions. This is known as the enterogastric reflex. Fatty chyme causes the release of another hormone called cholecystokinin which has an inhibiting effect on gastric secretions.

### **Absorption in the Stomach**

Since digestion is usually not completed in the stomach there is little absorption there. Water, alcohol and lipid soluble drugs are absorbed in the stomach.



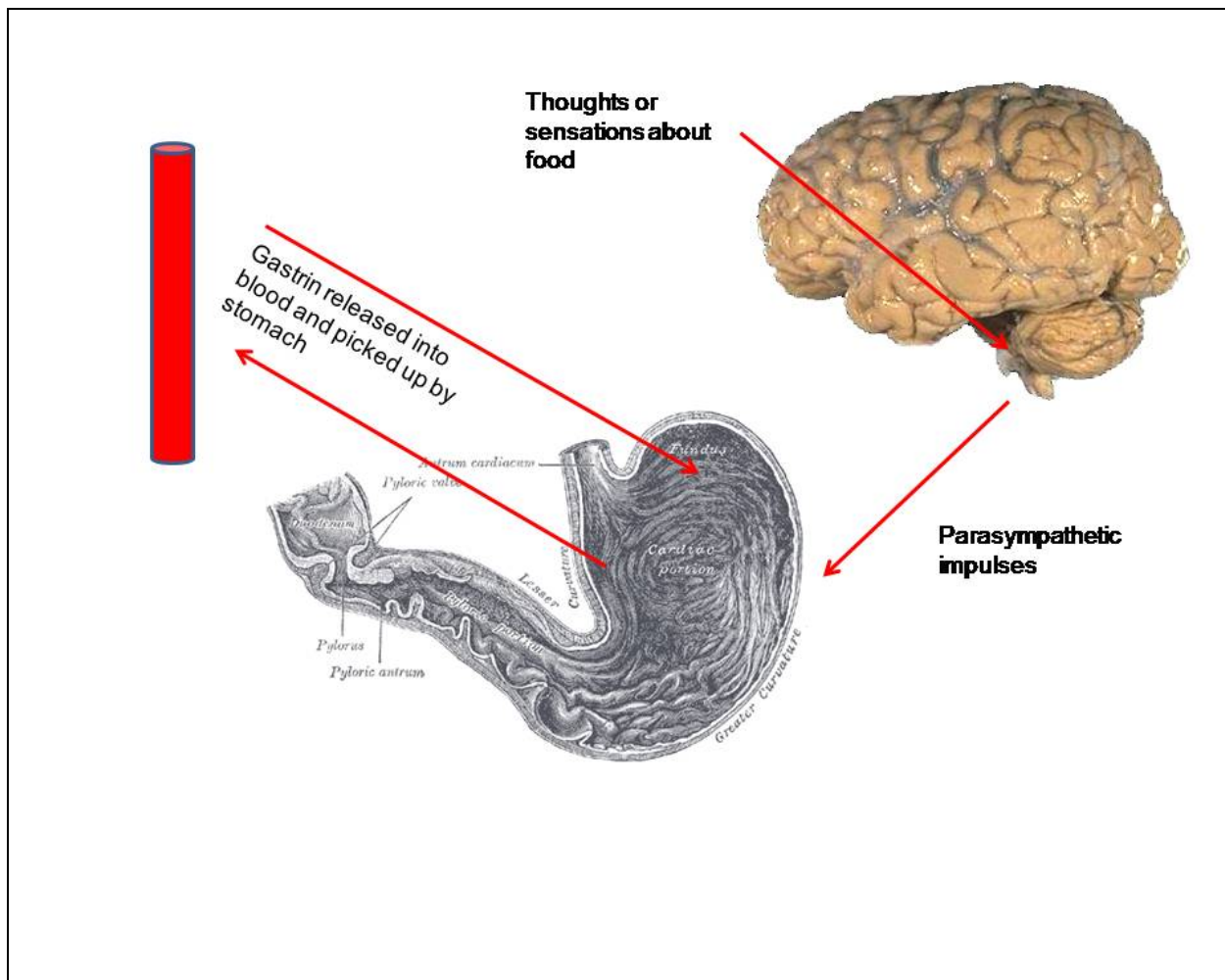


Figure 26.1. The cephalic phase of gastric secretion. Thoughts and smells cause the parasympathetic nervous system to send impulses by way of the vagus nerve to the stomach causing the release of the hormone gastrin. Gastrin is picked up by the stomach and stimulates gastric secretions.

Bruce Forciea

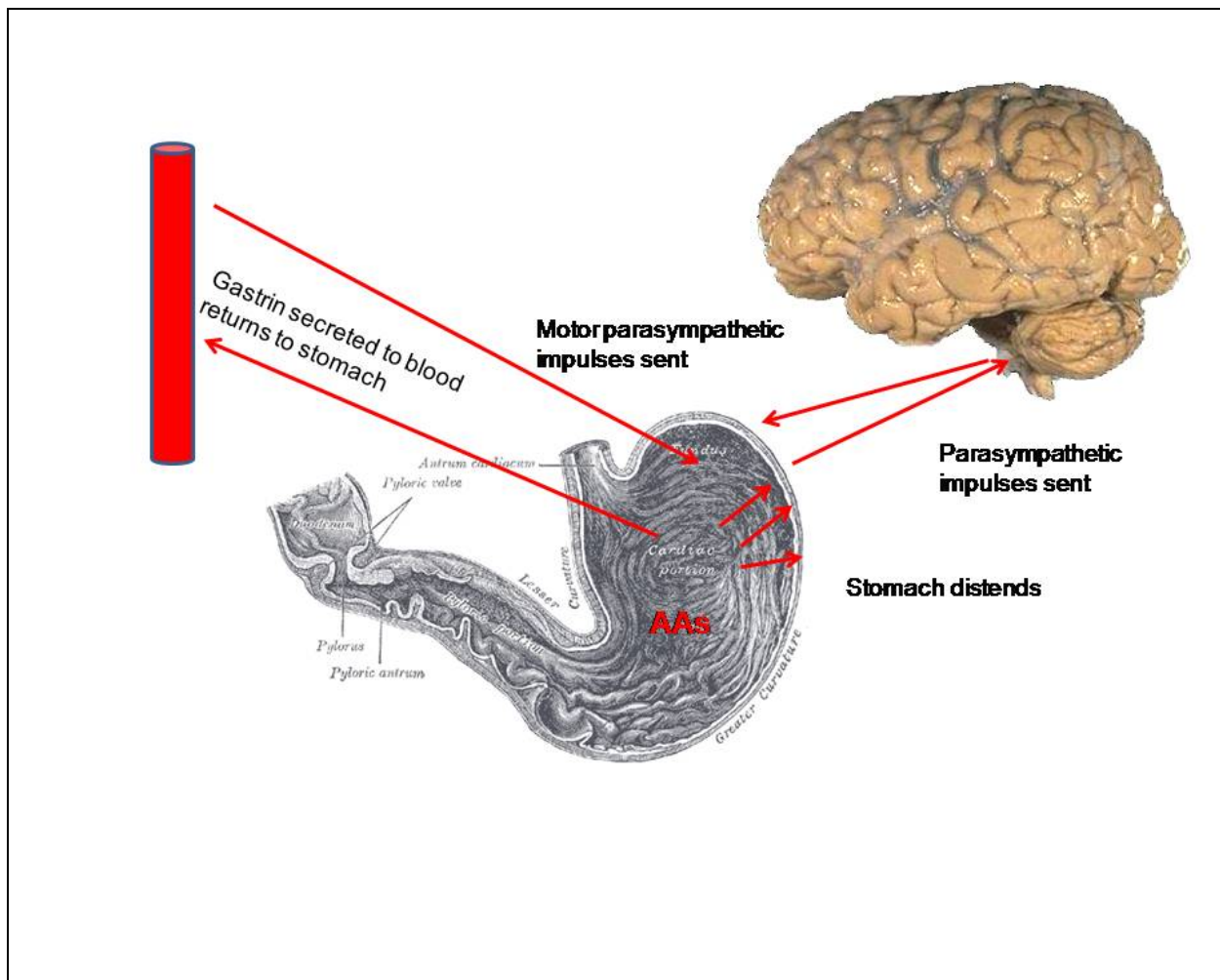


Figure 26.2. The gastric phase of gastric secretion. Distention of the stomach and the presence of amino acids causes the parasympathetic nervous system to stimulate gastric secretions.

Bruce Forciea

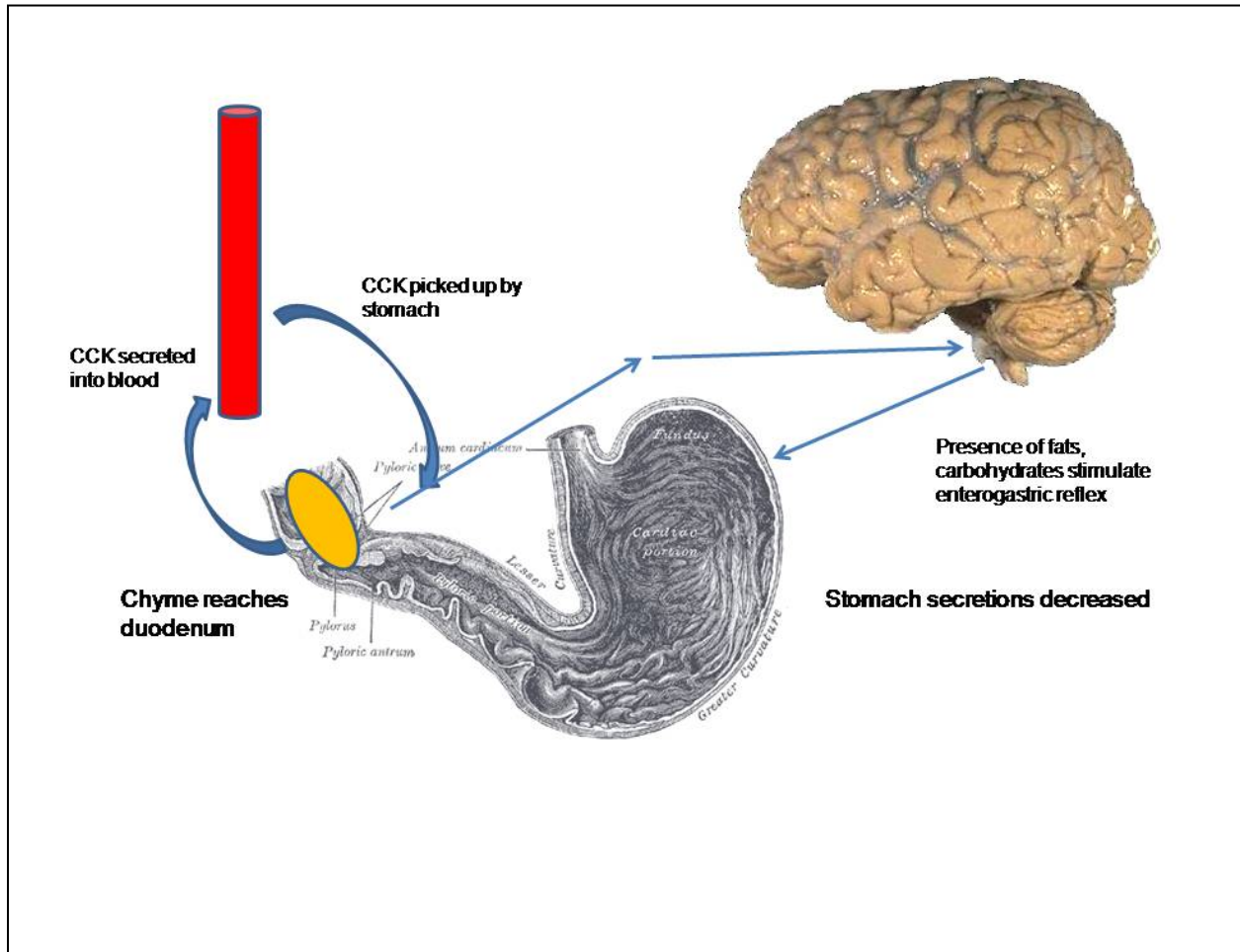


Figure 26.3. Intestinal phase of gastric secretion. Chyme moves into the duodenum causing the release of CCK and secretin that inhibit gastric secretions.

Bruce Forciea

## **Digestion in the Duodenum**

Chyme entering the duodenum combines with a number of secretions. Many of these secretions come from the pancreas and gallbladder. The inner membrane of the duodenum contains many mucous secreting cells that help to protect the membrane from acidic chyme. The pancreas secretes its exocrine secretions into the pancreatic duct. The pancreatic duct combines with the common bile duct at an area in the duodenum known as the hepatopancreatic ampulla.

Fatty chyme entering the duodenum stimulates the secretion of cholecystokinin (CCK). CCK is a hormone that travels to the gallbladder to stimulate the release of bile. Bile works to break down fats through emulsification.

Fatty chyme also stimulates the release of secretin. Besides inhibiting gastric secretions, secretin targets the pancreas to facilitate the release of bicarbonate ions that help to neutralize acidic chyme.

Bicarbonate ions are produced by the columnar epithelium lining pancreatic ducts. CCK released by the duodenum stimulates the pancreas to secrete a variety of enzymes from pancreatic acinar cells. These include trypsin, chymotrypsin and carboxypeptidase for digesting proteins. The enzymes are secreted in an inactive form and activated by the presence of certain peptides. CCK also stimulates the release of pancreatic lipase for fat digestion, pancreatic amylase for carbohydrate digestion, and nucleases for breaking down DNA into nucleotides.

Pancreatic secretions are also stimulated by the parasympathetic nervous system but to a lesser degree than by secretin and CCK (fig. 26.4).

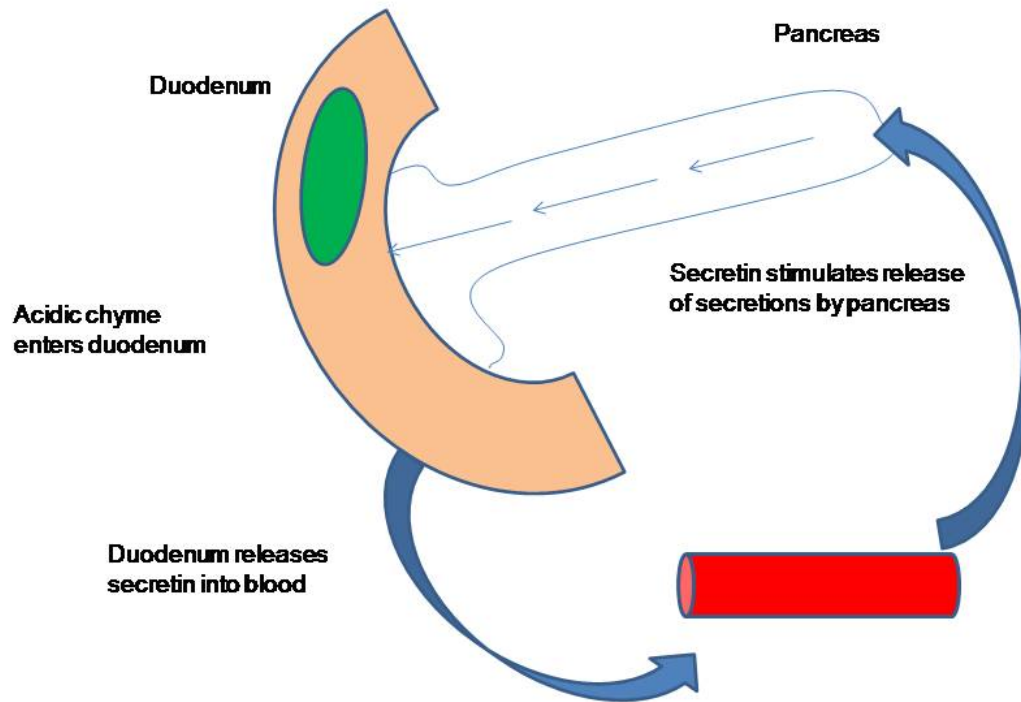


Figure 26.4. Pancreatic secretions are regulated by the release of secretin by the duodenum. Secretin causes the release of bicarbonate ions that help to neutralize acidic chyme.

Bruce Forciea

Major Digestive Enzymes			
Enzyme	Produced In	Site of Release	pH Level
<b>Carbohydrate Digestion:</b>			
Salivary amylase	Salivary Glands	Mouth	Neutral
Pancreatic amylase	Pancreas	Small Intestine	Basic
Maltase	Small intestine	Small intestine	Basic
<b>Protein Digestion:</b>			
Pepsin	Gastric glands	Stomach	Acidic
Trypsin	Pancreas	Small intestine	Basic
Peptidases	Small Intestine	Small intestine	Basic
<b>Nucleic Acid Digestion:</b>			
Nuclease	Pancreas	Small intestine	Basic
Nucleosidases	Pancreas	Small intestine	Basic
<b>Fat Digestion:</b>			
Lipase	Pancreas	Small intestine	Basic

Figure 26.5. Enzymes in the digestive system

[http://commons.wikimedia.org/wiki/File:Major\\_digestive\\_enzymes.png](http://commons.wikimedia.org/wiki/File:Major_digestive_enzymes.png)

## **Digestion in the Jejunum and Ileum**

The walls of the jejunum and ileum contain cells with additional enzymes for performing the final stages of digestion. These enzymes include peptidases for breaking peptide bonds, disaccharidases for breaking carbohydrates into monosaccharides and lipases for breaking down lipids. The ileum also contains lymphatic nodules called Peyer's patches that help to fight infection.

## **Absorption in the Small Intestine**

Most digestion is completed by the time substances reach the jejunum and the majority of substances are absorbed by the time they reach the end of the ileum. The inner membrane of the small intestine is built for absorption with a very large surface area produced by the plicae circulares and intestinal villi.

Digested carbohydrates (monosaccharides) are absorbed in the small intestine by way of active and passive transport proteins. For example glucose and galactose move into intestinal villi cells by way of symporters powered by the sodium gradient. Other monosaccharides are transported by facilitated diffusion. The monosaccharides then move out of the villi and into capillaries for transport to other areas of the body (fig. 26.6).

Digested proteins (amino acids and dipeptides) also enter villi cells by way of a sodium symporter or facilitated diffusion. Once inside the cells additional enzymes break down dipeptides and tripeptides into amino acids. The amino acids then exit the cell and are carried to the liver by the hepatic portal system. The amino acids are then either reconfigured or released into the bloodstream for use by other body tissues (fig. 26.7).

Digested lipids (glycerol and fatty acids) enter the villi cells by simple diffusion. Once inside they are reassembled to form triglycerides by the smooth endoplasmic reticulum and packaged by the Golgi apparatus into packages called chylomicrons. The chylomicrons then leave the cell and enter the lacteals of the villi. The lacteals are extensions of the lymphatic system. Chylomicrons then travel through the lymph back to the venous blood. Lymph fluid containing large amounts of fat is called chyle. Chylomicrons end up in the liver where they are used for energy, converted to other molecules or stored. Excess lipids are also stored in adipose tissue for later use (fig. 26.8).

The liver converts lipids by combining them with proteins to form lipoproteins. Lipoproteins are named for the amount of protein and lipid within them. Very low density lipoproteins (VLDL) contain about 92% lipid and 8% protein. Low density lipoproteins (LDL) contain about 75% lipid and 25% protein. High density lipoproteins (HDL) contain about 55% lipid and 45% protein.

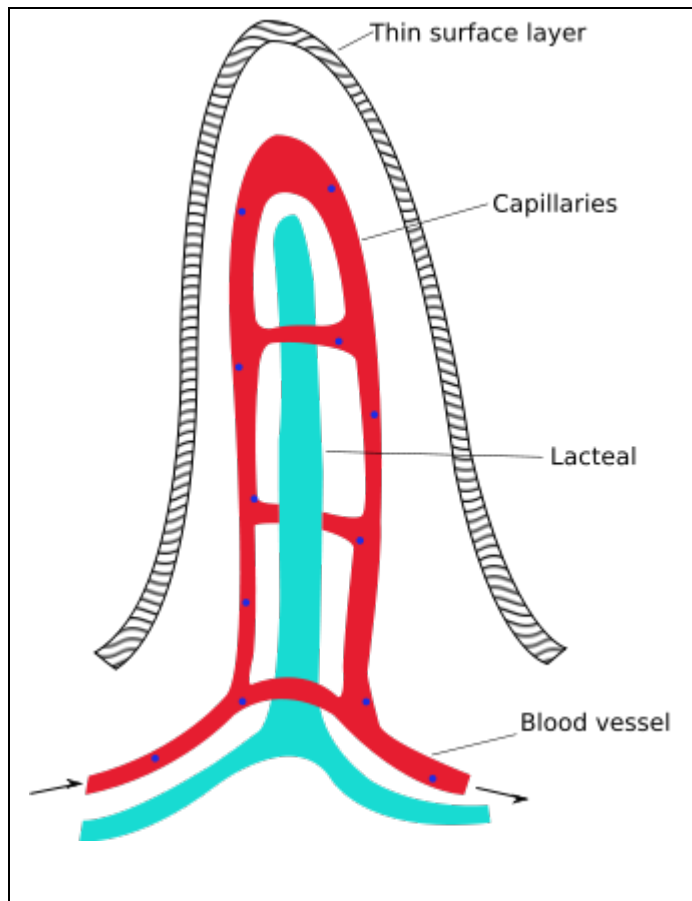


Figure 26.6. Intestinal villus

[http://commons.wikimedia.org/wiki/File:Intestinal\\_villi\\_simplified.svg](http://commons.wikimedia.org/wiki/File:Intestinal_villi_simplified.svg)



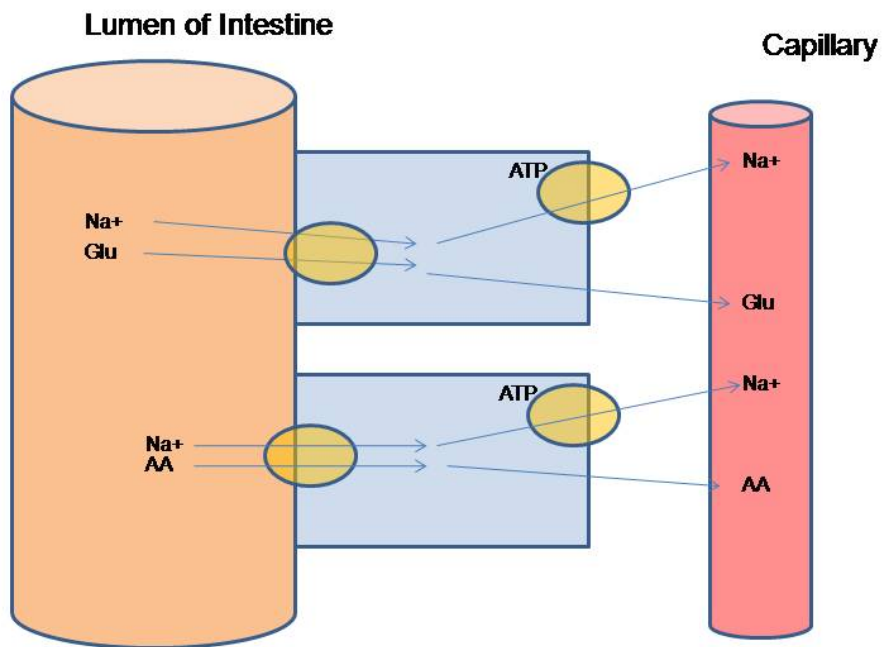


Figure 26.7. Absorption of glucose (Glu), sodium and amino acids (AA) in the intestinal wall. Transport proteins use the sodium gradient to symport glucose and amino acids into the cells. Sodium is removed by active transport while glucose and amino acids are transported passively into the blood capillaries.

Bruce Forciea

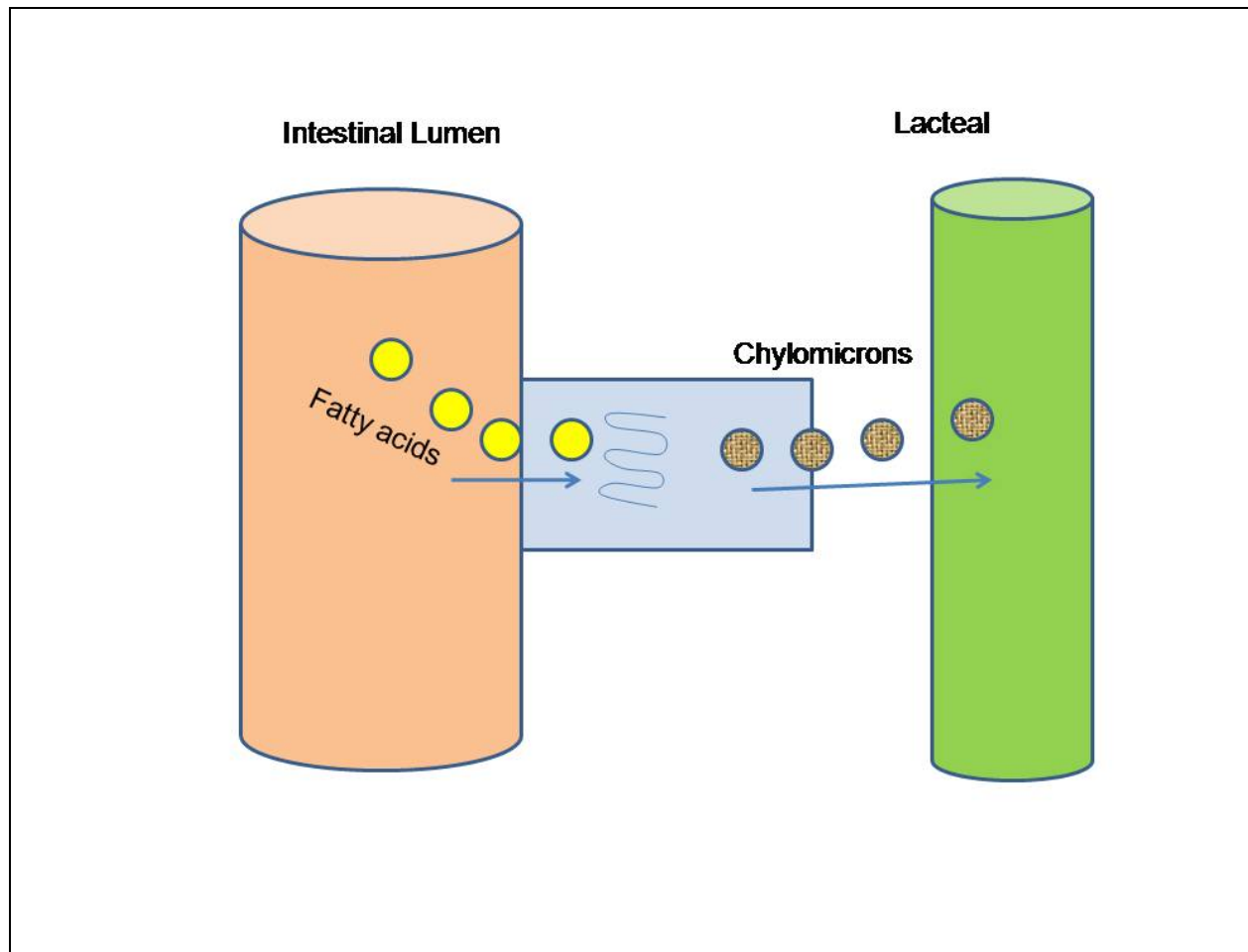


Figure 26.8. Lipid molecules diffuse into epithelial cells lining the lumen of the small intestine. Once inside lipids are repackaged by smooth endoplasmic reticulum into chylomicrons. The chylomicrons diffuse out the cells and into the lacteals which are part of the lymphatic system.

Bruce Forciea

## **Digestion and Absorption in the Large Intestine**

By the time material has reached the large intestine digestion and absorption are primarily complete. The colon secretes mucous that holds feces together. There are also resident bacteria known as intestinal flora. The bacteria help to break down undigested substances.

Substances move through the small intestine by slow peristaltic movements. In the large intestine substances move in what are called mass movements. Mass movements are stimulated by parasympathetic impulses, stretch of the colon walls and impulses from the enteric nervous system. The mass movements move large sections of the colon (up to 20 cm) resulting in the movement of feces toward the rectum.

Water and electrolytes are absorbed in the large intestine with the resulting material called feces. When feces enter the rectum it triggers the defecation reflex. Distention of the rectum sends sensory impulses to the conus medullaris of the spinal cord. The resultant motor impulses produce peristaltic contractions in the colon and cause the internal anal sphincter muscle to relax. Impulses also travel to the cerebrum where the urge to defecate is sensed. This allows for voluntary control of the external anal sphincter. Relaxation of the external anal sphincter results in defecation.

Defecation can be produced voluntarily by holding the breath and bearing down. This increases the intrabdominal pressure and moves feces toward the rectum triggering the defecation reflex.

## Chapter 26 Review Questions

1. During which phase of swallowing do the uvula and epiglottis move to close off the pharynx and larynx:
  - a. First
  - b. Second
  - c. Third
  - d. Fourth
2. Which of the following best describes the action of pepsin:
  - a. Helps to digest carbohydrates
  - b. Inhibits the release of gastrin
  - c. Helps to digest fats
  - d. Helps to digest proteins
3. Which best describes a mechanism for the release of gastrin:
  - a. Release is stimulated by sympathetic nervous system
  - b. Salivary amylase stimulates release of gastrin
  - c. Acetylcholine secreted by parasympathetic nervous system stimulates release of gastrin
  - d. Fatty chyme leaving the duodenum stimulates release of gastrin
4. Which of the following best describes the function of secretin:
  - a. Inhibits the release of gastric secretions
  - b. Stimulates the release of salivary amylase
  - c. Stimulates release of gastric secretions
  - d. Causes the release of bile
5. Which best describes the reason bicarbonate ions are secreted by the pancreas:
  - a. To help breakdown of carbohydrates
  - b. To help stimulate the release of bile
  - c. To control stomach secretions
  - d. To make the chyme more alkaline
6. Which best describes the function of bile:
  - a. Breaks down carbohydrates
  - b. Inhibits stomach secretions
  - c. Emulsifies fats
  - d. Stimulates release of pancreatic secretions
7. Fats are repackaged in the small intestine into structures called:
  - a. Chyme
  - b. Chylomicrons
  - c. Low density lipoproteins
  - d. Vesicles

8. Which of the following structures absorbs the most nutrients:
  - a. Stomach
  - b. Pancreas
  - c. Small intestine
  - d. Large intestine
  
9. Which of the following best describes the sodium/amino acid symporter in the small intestines:
  - a. Moves sodium and amino acids in the same direction powered by the sodium gradient
  - b. Moves sodium and amino acids in opposite directions powered by the sodium gradient
  - c. Moves sodium and amino acids in the same direction powered by the amino acid gradient
  - d. Moves sodium and amino acids in the opposite direction powered by the amino acid gradient
  
10. Which of the following substances is not absorbed in the large intestine:
  - a. Water
  - b. Electrolytes
  - c. Fats
  - d. All are absorbed

# Chapter 27

## Reproductive System Anatomy

## **The Reproductive System**

One of the primary directives of life is to reproduce and pass on genetic information to future generations. This is the purpose of the human reproductive system. We often think of the differences between males and females but there are striking similarities in reproductive systems of both. Both carry half of the genetic information required to produce a human, both contain a number of the same hormones and both have similar stages of reproductive development. As you get through this chapter you may wish to discover the similarities of both systems.

### **The Big Picture**

The overall function of both male and female reproductive systems is to pass on genetic information to offspring. The male produces half of the genetic information and packages it in sperm cells. These cells develop and travel through the male to the female. Likewise the female also produces half of the genetic information and packages it in an egg cell called an oocyte. The oocyte is cyclically produced and is either fertilized to complete its development or is not and is subsequently discarded. Hormones work to control and support these processes.

### **The Male Reproductive System**

The male reproductive system can be thought of as having two divisions. The primary organs are the testes and the rest of the organs are considered secondary. The function of the male system is to produce and develop sperm cells, transport the sperm to the female and produce and secrete sex hormones (fig. 27.1).

#### **Testes**

The testes are considered the primary sex organs of the male. The testes develop in utero in a retroperitoneal location. They descend and pass through the inguinal canal to finally reside in the scrotum. A tissue structure called the gubernaculum connects the developing testes with the scrotum. As the gubernaculum shortens the testes descend to the scrotum. This occurs at between 7-9 months of fetal development. The secretion of testosterone facilitates this process.

The scrotum is a sac located outside of the pelvic cavity. The scrotum consists of skin and is divided into two chambers. It also contains a smooth muscle known as the dartos muscles that can contract and draw the testes closer to the body. The abdominal muscles also connect to the testes by way of the cremaster muscles. These muscles also work to draw the testes closer to the body when they contract. By adjusting the position of the testes the internal temperature of the testes can be adjusted.

The testes are considered both endocrine and exocrine glands. They produce hormones that travel through the blood and secrete sperm cells that travel through ducts. The adult male has two testes.

A connective tissue membrane called the tunica albuginea covers the testes. The inside of the testes is arranged in a series of lobules with tubular structures called seminiferous tubules within. The seminiferous tubules are surrounded by cell known as interstitial cells of Leydig. The Leydig cells secrete testosterone. The seminiferous tubules are coiled structures and empty into straight tubules called tubuli recti which in turn empty into the rete testes which constitutes a tubular network. The rete testes empty into the efferent ductules which in turn move through the tunica albuginea to the epididymis.

The testes also contain the sperm cells called spermatogonia as well as sustentacular cells (Sertoli cells). The Sertoli cells are columnar in shape and form a barrier between the testes and the blood. This barrier helps to isolate sperm cells so that the immune system does not attack them. Sertoli cells secrete the hormone called inhibin as well as substances to help sperm mature. Sperm cells have different antigens on their surface than body cells that could trigger an immune response.

### Epididymis

The epididymis is a tubular structure that resides on the superior-posterior surface of the testes. These paired structures each have three portions consisting of a head, body and tail. The head connects with the efferent ductules of the testes. The epididymis works to help sperm cells mature as they spend up to 3 weeks in the tubule system within the epididymis. Sperm move through the epididymis to the vas deferens.

### Vas Deferens

The vas deferens or ductus deferens is a tubular structure that is consistent with the tail of the epididymis. The vas deferens has three muscular layers including inner and outer longitudinal layers and a middle circular layer. The muscular layers help to propel sperm cells through the tube. Each vas deferens moves superiorly through the inguinal canal and travels through the abdominal cavity and over the top of the bladder to the seminal vesicle. The vas deferens travels in the spermatic cord which is a connective tissue sheath that also contains blood vessels and lymphatics. As the vas deferens nears the seminal vesicle the tube widens into an ampulla.

### Seminal Vesicles

The seminal vesicles are located posterior to the bladder and anterior to the rectum (fig. 27.3). They contain epithelium that secretes an alkaline substance, fructose and prostaglandins.

### Prostate Gland

The prostate is a walnut shaped gland just inferior to the bladder (fig. 27.2). The prostate gland secretes an acidic milky fluid that helps to nourish and mobilize sperm. The fluid also contains enzymes (hyaluronidase) and prostate specific antigen (PSA).

The urethra (prostatic urethra) passes through the prostate gland. The prostate also contains another set of paired ducts that connect the seminal vesicles to the urethra called the ejaculatory ducts.

### Bulbourethral Glands

The paired bulbourethral glands (Cowper's glands) are pea-shaped glands that secrete an alkaline substance and mucous to help protect and transport the sperm.

### Urethra

The urethra begins at the base of the urinary bladder and passes through the prostate gland and through the penis ending at the urinary meatus of the penis. The urethra is lined with a mucous membrane. There are three parts to the male urethra. These include the portion traveling through the urethra (prostatic urethra), the portion extending from the base of the prostate gland to the penis (membranous urethra) and the portion running through the center of the penis (penile urethra).



## Penis

The penis consists of three columns of tissue called erectile columns surrounded by fibrous coverings surrounded by skin (fig. 27.4). The two superior columns are called the corpus cavernosum and the lower column is called the corpus spongiosum. Each corpus cavernosum contains a deep artery and is surrounded by a fibrous covering called a tunica albuginea. The corpus spongiosum contains the urethra. The distal portion of the penis contains a slightly larger structure called the glans penis. The glans penis is covered by loose skin called the prepuce which is sometimes removed by circumcision.

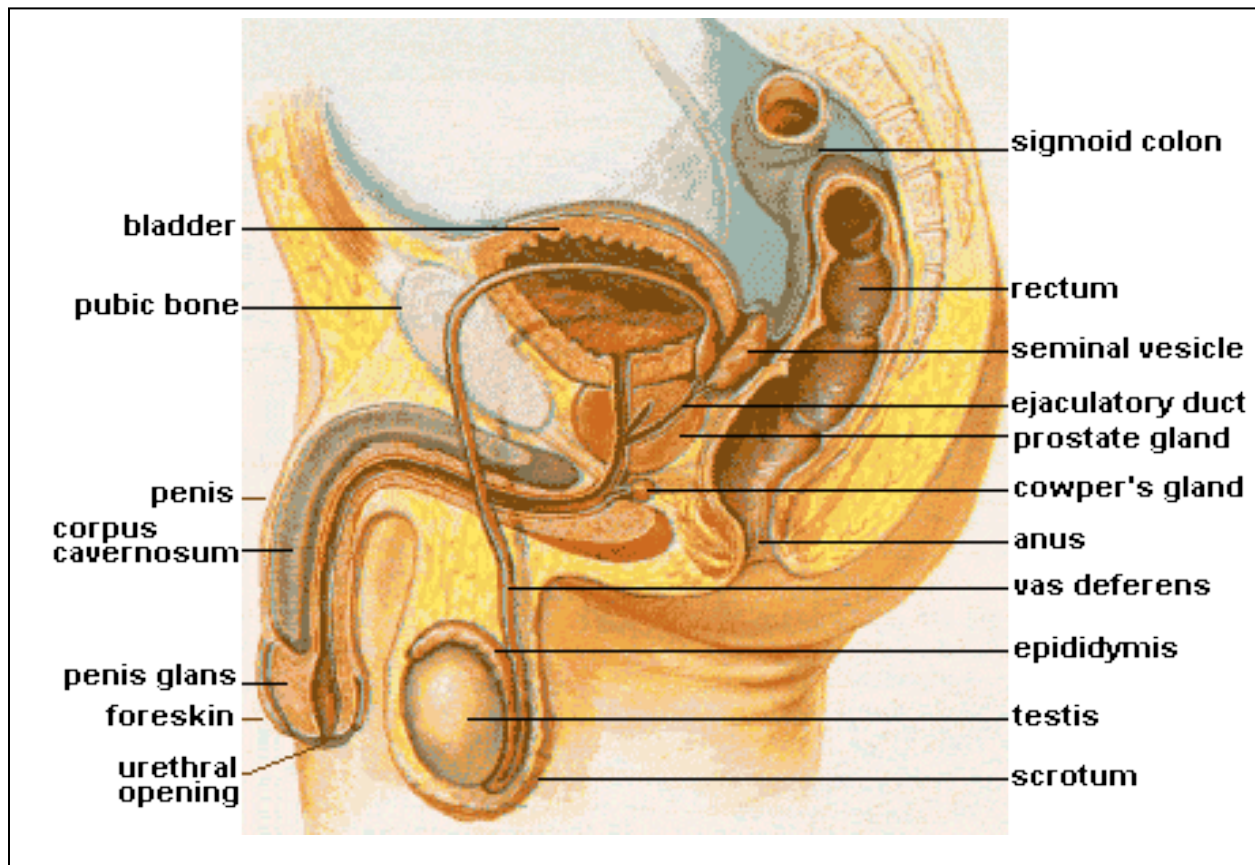


Figure 27.1. Male reproductive system

[http://commons.wikimedia.org/wiki/File:Male\\_anatomy.png](http://commons.wikimedia.org/wiki/File:Male_anatomy.png)

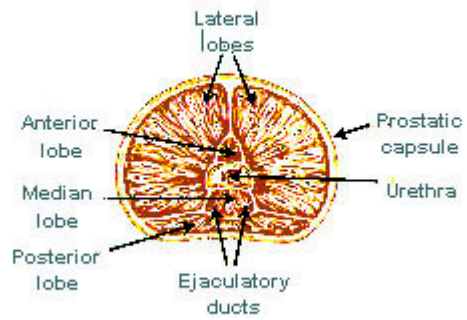
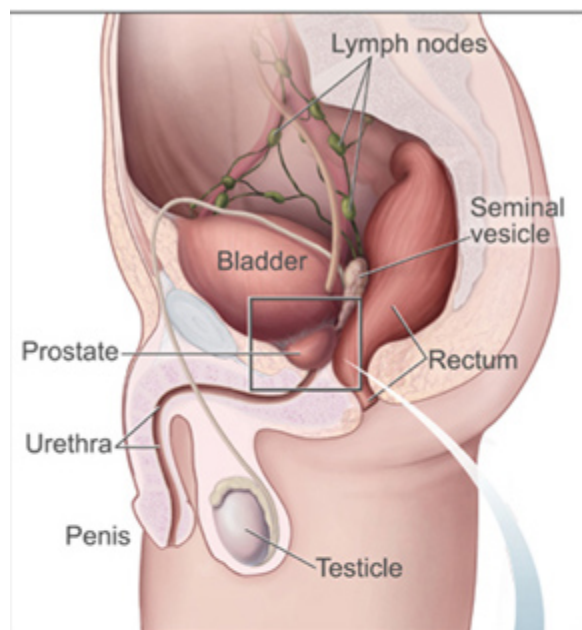
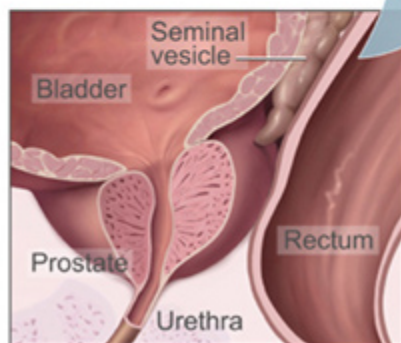


Figure 27.2. Prostate gland

[http://commons.wikimedia.org/wiki/File:Illu\\_prostate\\_lobes.jpg](http://commons.wikimedia.org/wiki/File:Illu_prostate_lobes.jpg)



This shows the prostate and nearby organs.



This shows the inside of the prostate, urethra, rectum, and bladder.

Figure 27.3. Prostate and seminal vesicle

<http://commons.wikimedia.org/wiki/File:Prostatelead.jpg>

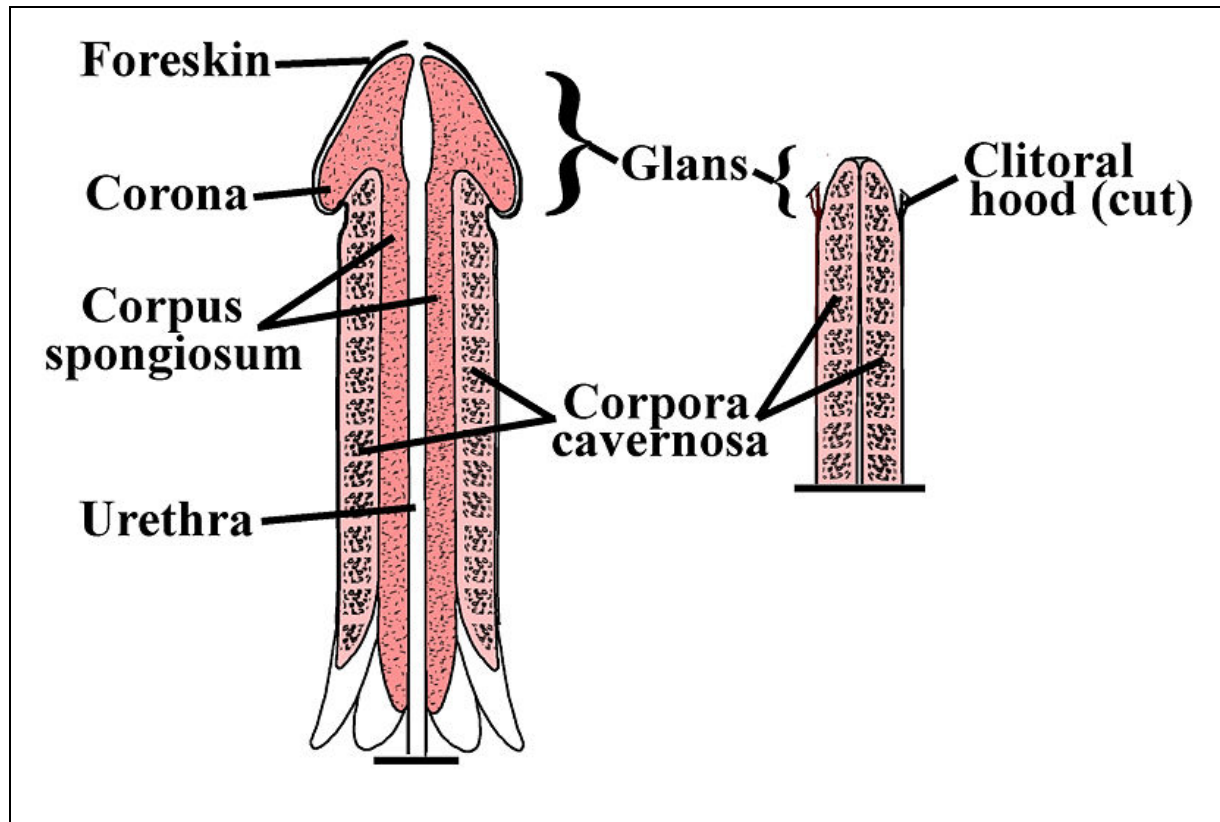


Figure 27.4. Penis

[http://commons.wikimedia.org/wiki/File:Penile-Clitoral\\_Structure.JPG](http://commons.wikimedia.org/wiki/File:Penile-Clitoral_Structure.JPG)

## Female Reproductive System

The female reproductive system not only carries the genetic information for offspring but is also capable of providing an environment for the early stages of growth and development of the human (fig. 27.5).

### Ovaries

The primary sex organs of the female reproductive system are the ovaries. All of the other structures are considered secondary organs. The ovaries are similar in structure to the testes. The ovaries begin in utero as masses of tissue located posterior to the abdominal cavity (retroperitoneal). They descend slightly and reside in the pelvic cavity on either side of the uterus. They are ovoid structures located inferior to the uterine tubes (Fallopian tubes). A thin layer of epithelium called germinal epithelium covers the ovaries. The inner region of the ovaries contains structures known as ovarian follicles surrounded by a connective tissue matrix. The ovarian follicle contains the egg cells known as oocytes. The oocytes are released at about half way through the menstrual cycle in what is known as ovulation.

### Fallopian Tubes

The Fallopian tubes or uterine tubes extend from the lateral areas of the uterus and continue to near the ovaries but do not contact it. The tubes contain three layers including an inner mucous membrane, a middle muscular layer and an outer serous layer. The inner mucous membrane is continuous with the peritoneal membrane surrounding the pelvic cavity. This membrane is also continuous with the walls of the vagina and can be susceptible to infection by microorganisms.

The Fallopian tubes have three sections. These include the first third that extends from the isthmus of the uterus, the second third which ends in a widened area called the infundibulum and the final third which ends in finger-like projections called fimbriae.

The Fallopian tubes work to transport the oocyte to the uterus after fertilization and are the sites for fertilization by sperm cells. Most fertilized oocytes move to the uterus but occasionally they will deposit somewhere in the pelvic cavity causing what is known as an ectopic pregnancy.

### Uterus

The uterus is a pear shaped structure about three inches long and two inches in width. The uterus has two divisions including the body and cervix. The body ends anteriorly as a narrow region called the cervix and posteriorly as a rounded structure called the fundus (figs. 27.6, 27.7).

The uterus has three layers. The inner layer is called the endometrium. The endometrium varies in thickness and is thinner just after menstruation and thicker at the end of the cycle. The endometrium has an extensive blood supply and contains mucous secreting cells. The mucous changes its consistency during various times of the menstrual cycle. It is normally thicker during most of the cycle and more water near the time of ovulation to help move sperm cells through.

The middle layer or myometrium is a thick smooth muscle layer. The smooth muscle is capable of producing very strong contractions during childbirth. The outer layer or perimetrium consists of a serous membrane.

The body of the uterus lies on top of the bladder in what is called an anteflexed position. The cervix of the uterus connects with the vagina at an upward right angle. This connection allows for pockets around the cervix called the anterior and posterior fornix that allow for pooling of semen to increase the chances of fertilization.

The uterus can lie in retroflexion in which the uterus tilts backward. Retroflexion can sometimes cause prolapsed of the uterus. The uterus is held in place by a series of ligaments. These include two broad ligaments, two uterosacral ligaments, a posterior, anterior and two round ligaments.

The posterior ligament forms a pouch called the posterior cul de sac or rectouterine pouch (of Douglas). Likewise the anterior ligament also forms a pouch called the anterior cul de sac or vesicouterine pouch.

## Vagina

The vagina is located between the rectum and urethra. It is a tubular structure about 3 inches long that opens to the outside and extends superior and posterior to the cervix of the uterus. The vagina is primarily smooth muscle lined with an epithelial mucous membrane. The mucous membrane can form around the opening of the vagina. This structure is called a hymen. In some cases the opening to the vagina can be completely covered by the hymen (imperforate hymen). An imperforate hymen needs to be medically punctured to allow discharge of the menstrual flow.

## Vulva

The vulva consists of several externally located structures of the female reproductive system. These include the labia majora and minora, mons pubis, clitoris, vestibule, urinary meatus, greater and lesser vestibular glands.

The labia majora are skin covered structures consisting of primarily adipose and connective tissue. The outer surface of the labia majora contain hair while the inner surface does not. They also contain a mucous lining. They are analogous to the scrotum of the male. The labia minora are hairless structures located medially to the labia majora. The space between both labia minor is known as the vestibule.

The clitoris is an organ consisting of erectile tissue. It is located just superior and behind the labial junction. The clitoris contains two corpus cavernosum but no corpus spongiosum so it is similar in structure to the penis. The superior aspect of the clitoris contains a covering of tissue known as the prepuce.

Between the clitoris and opening to the vagina (vaginal orifice) is the urinary meatus which is the external opening of the urethra.

On the sides of the vagina are the greater vestibular glands or Bartholin's glands that open into the area between the labia minor and hymen. The lesser vestibular glands or Skene's glands are located near the urinary meatus.

## Perineum

The perineum is the area between the vagina and anus. The perineum helps to form the muscular floor of the pelvis and can be torn during vaginal childbirth. The perineum contains the urogenital triangle which is formed by drawing a line between the ischial tuberosities with the anterior point of the triangle just superior to the prepuce.

## Mammary Glands

The mammary glands or breasts are superficial to the pectoral muscles. Internally they consist of a series of lobes separated by connective tissue. The lobes subdivide into lobules containing secretory cells. The cells are arranged in clusters around a central duct. The smaller ducts combine to form larger ducts called lactiferous ducts for each lobe. The lactiferous ducts open to the outside at the nipple. The breasts also contain suspensory ligaments (of Cooper) that help to support it. Each breast contains a circular pigmented area called an areola. The areola contains sebaceous (oil secreting) glands to help protect the nipple.

The breast also contains adipose tissue and lymphatics that drain into the axillary region.

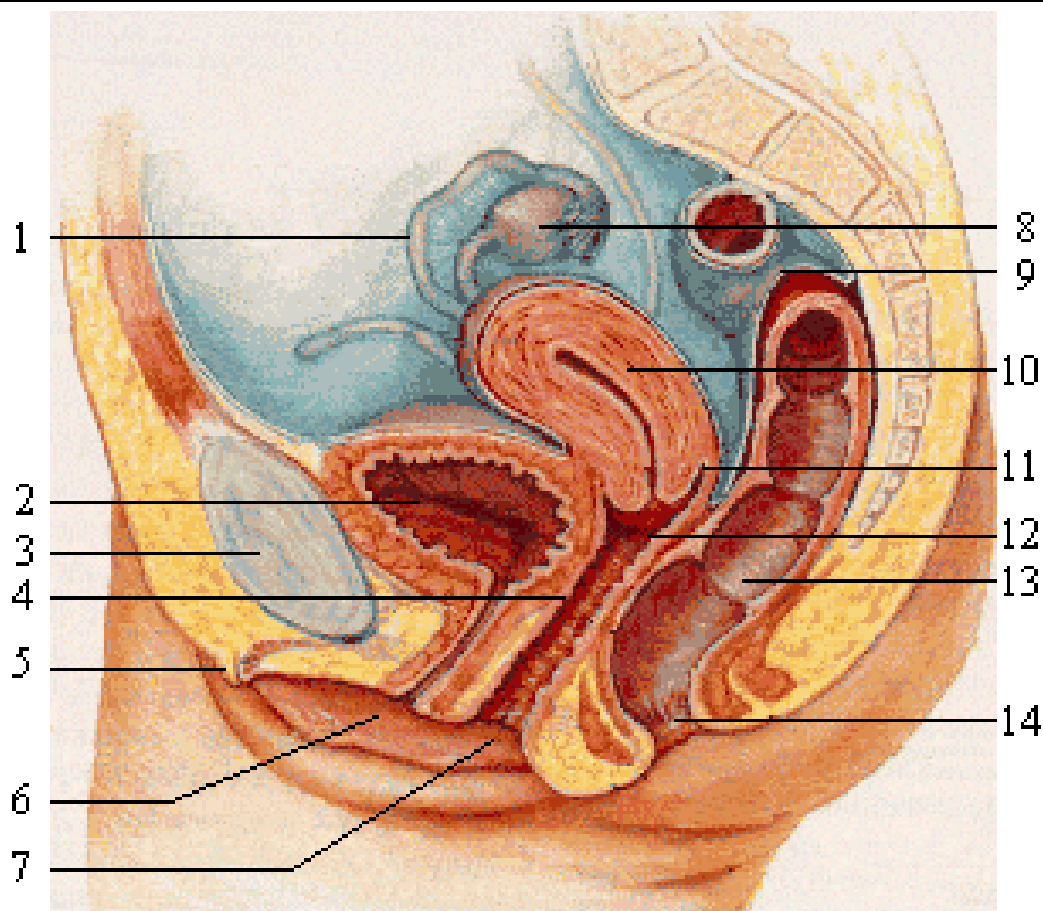


Figure 27.5. Female reproductive system

[http://commons.wikimedia.org/wiki/File:Female\\_reproductive\\_system\\_lateral\\_nolabel.png](http://commons.wikimedia.org/wiki/File:Female_reproductive_system_lateral_nolabel.png)

1: fallopian tube

- 2: bladder
- 3: pubic bone (pubic symphysis)
- 4: g-spot
- 5: clitoris
- 6: urethra
- 7: vagina
- 8: ovary
- 9: sigmoid colonti
- 10: uterus
- 11: fornix of vagina (including anterior and posterior)
- 12: cervix
- 13: rectum
- 14: anus

Rohen, Yokochi, and Lutjen-Drecoll. *Color Atlas of Anatomy*. Lippincott Williams & Wilkins. 2002. "Regional relations of female internal genital organs". "Midsagittal section through the female trunk".



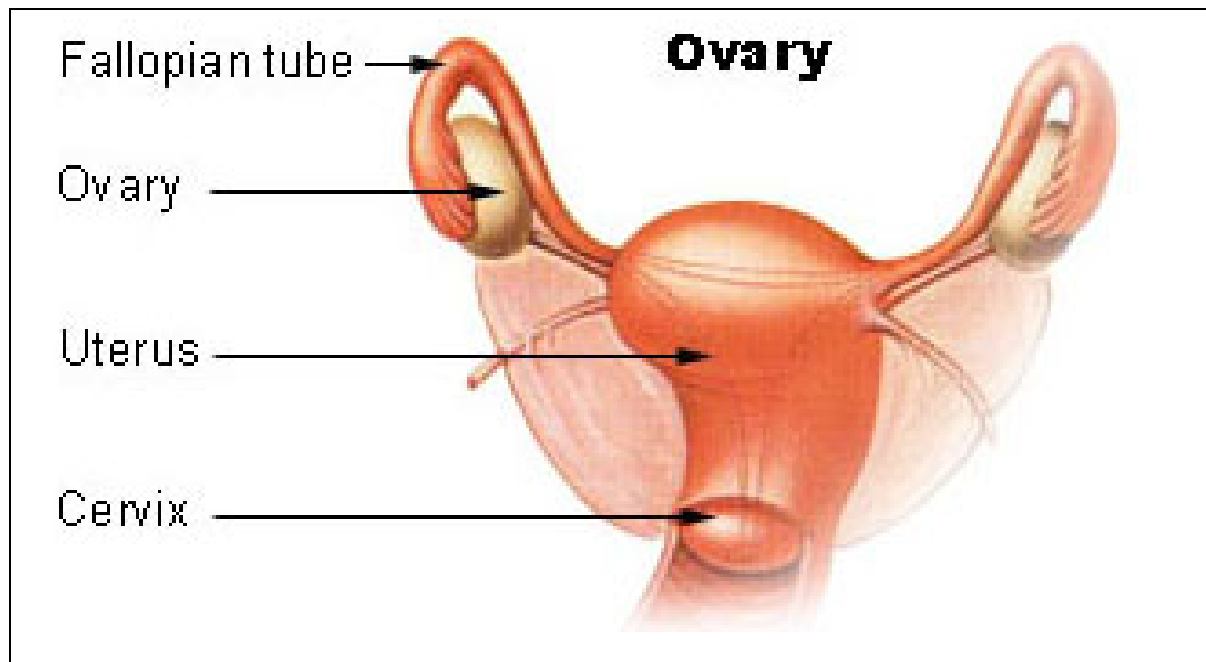


Figure 27.6. Uterus and Ovaries

[http://commons.wikimedia.org/wiki/File:Illu\\_ovaryb.jpg](http://commons.wikimedia.org/wiki/File:Illu_ovaryb.jpg)

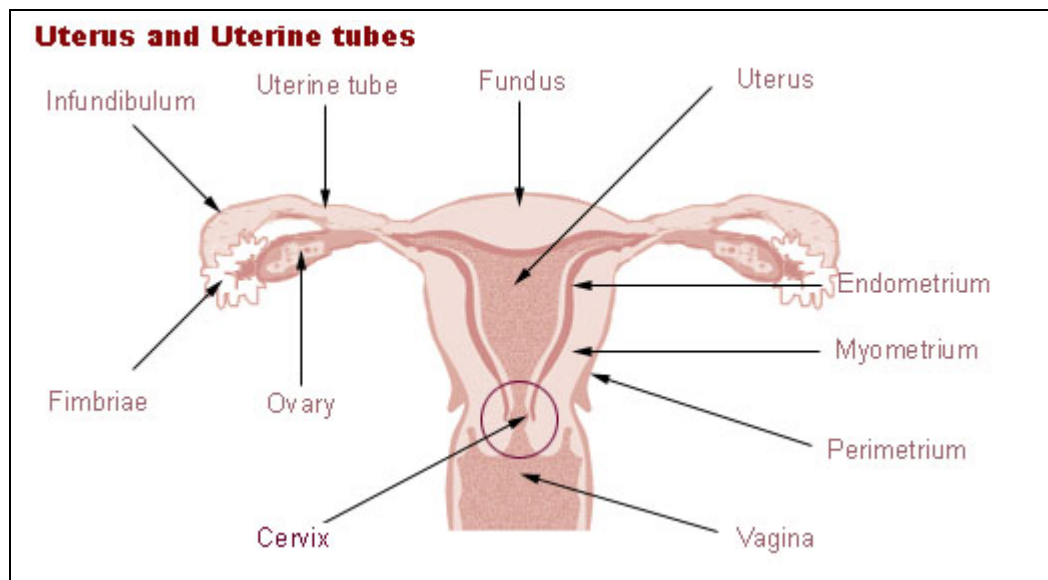


Figure 27.7. Uterus

[http://commons.wikimedia.org/wiki/File:Illu\\_cervix.jpg](http://commons.wikimedia.org/wiki/File:Illu_cervix.jpg)

## Chapter 27 Review Questions

1. Which of the following cells secrete testosterone:
  - a. Sustentacular
  - b. Leydig
  - c. Seminiferous
  - d. Tubular
2. Which of the following is a correct statement:
  - a. Sperm move from the vas deferens to the epididymis
  - b. Sperm move from the seminal vesicle to the ejaculatory duct
  - c. Sperm move from the epididymis to the vas deferens
  - d. Sperm move from the prostate to the seminal vesicle
3. Which of the following structures secretes fructose:
  - a. Epididymis
  - b. Testes
  - c. Seminal vesicle
  - d. Prostate gland
4. Which of the following is correct regarding the erectile columns:
  - a. 1 corpora cavernosum and 2 corpora spongiosum
  - b. 1 corpora cavernosum and 1 copora spongiosum
  - c. 2 corpora cavernosum and 2 corpora spongiosum
  - d. 2 copora cavernosum and 1 corpora spongiosum
5. This mucous secreting gland is located at the base of the penis:
  - a. Prostate
  - b. Bulbourethral
  - c. Seminal vesicle
  - d. Epididymis
6. Which are considered primary sex organs in the female:
  - a. Vagina
  - b. Ovaries
  - c. Uterus
  - d. Fallopian tubes
7. Which of the following is the thickest layer of the uterus:
  - a. Myometrium
  - b. Endometrium
  - c. Ectometrium
  - d. Perimetrium

8. The space between the labia in the female is known as:
- a. Labial space
  - b. Majoral space
  - c. Vestibule
  - d. Perineum
9. The widened area of the Fallopian tube is called:
- a. Infundibulum
  - b. Fimbriae
  - c. Ampulla
  - d. Endometrium
10. The normal uterus is in this position:
- a. Retroflexed
  - b. Anteverted
  - c. Retroextended
  - d. Anteextended

# Chapter 28

## Reproductive System Physiology

## **Reproductive System Physiology**

This chapter will focus on the growth and development of gametes (sex cells), hormonal control of the reproductive system, and the female menstrual cycle.

### **Male Reproductive Physiology**

#### **Spermatogenesis**

Spermatogenesis encompasses the development of sperm cells in the male reproductive system. Spermatogenesis begins with the undeveloped sex cells called spermatogonia. Spermatogonia reside in the testes and will begin to mature around the age of puberty. They continue to do so throughout an adult male's life.

The process begins with the secretion of gonadotropins from the anterior pituitary gland. These include follicle stimulating hormone and luteinizing hormone. Both are secreted in response to the releasing factor gonadotropin releasing hormone secreted by the hypothalamus. Luteinizing hormone (LH) is sometimes referred to as interstitial cell stimulating hormone (ICSH). This hormone targets the interstitial cells (Leydig cells) of the testes and promotes the secretion of testosterone. Follicle stimulating hormone (FSH) targets the sustentacular cells (Sertoli cells) of the testes and promotes their maturation and response to testosterone. Both FSH and testosterone work to facilitate the maturation of spermatogonia.

Spermatogonia begin to mature in utero but their maturation is halted until puberty. They will undergo mitosis and develop into primary spermatocytes. Maturation is halted at this stage until puberty and the secretion of the sex hormones as described above.

Once reaching puberty the primary spermatocytes undergo another type of cell division called meiosis (fig 28.1). There are two stages to meiosis including meiosis I and meiosis II. During meiosis I the genetic material is divided in half. The normal adult human has 46 chromosomes (diploid number of chromosomes). Chromosomes form pairs that have the same but not necessarily identical genes. These are called homologous chromosomes. The pairs essentially split into two sections of homologous chromosomes with each new cell having 23 chromosomes (haploid number of chromosomes). The chromosomes may contain different variants of genes. For example one cell may contain a different variant for the gene for eye color than the other cell.

#### **Steps of Meiosis**

##### **Meiosis I**

###### **Prophase I**

Chromatin condenses to form chromosomes. The nuclear membrane and nucleoli disappear and the spindle fibers begin to form much like in mitosis. Homologous chromosomes form pairs. During this process genetic material may be exchanged through what is known as crossing over. In crossing over chromatids cross over to the other chromosome and vice versa. This allows for a large amount of genetic variability in offspring. Each human has 8 million possible combinations of chromosomes that can combine with millions of combinations from their mate. This works out to more than 70 trillion possible unique human beings.

### Metaphase I

Chromosome pairs line up in the midline of the cell and are attached to the spindle.

### Anaphase I

The chromosome pairs separate and move to each end of the spindle. The chromosome number for each new cell is now reduced by half.

### Telophase I

The cell cleaves and produces two new cells. The nuclear membrane and nucleolus reappear and the spindle dissipates. The new cells are now ready for meiosis II.

## **Meiosis II**

Meiosis II is very similar to mitosis.

### Prophase II

Chromosomes reappear, the nuclear membrane and nucleolus disappear and the spindle begins to form again.

### Metaphase II

Chromosomes line up in the middle of the cell and attach to spindle fibers.

### Anaphase II

Chromatids of chromosomes separate and are pulled to opposite ends of the cell.

### Telophase II

Cell division finishes. The cell cleaves, nuclear membrane and nucleolus reappear, and the chromatids unravel. There are now two cells each having 23 chromosomes.

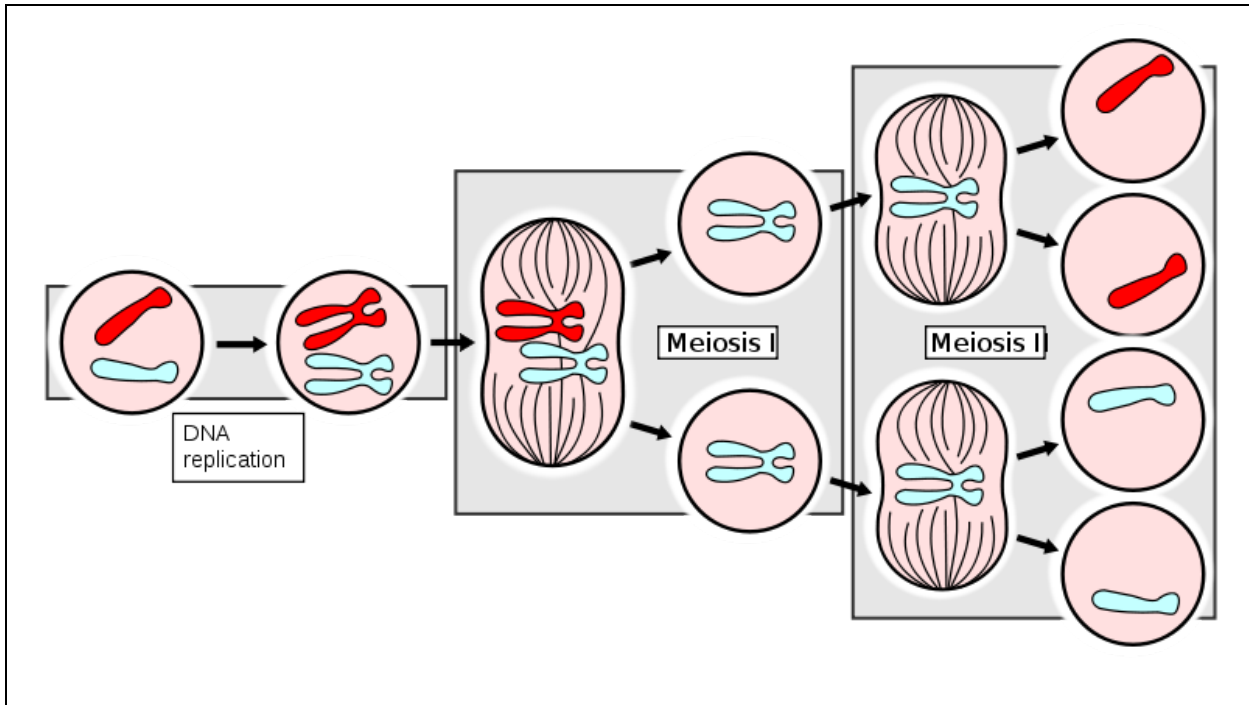


Figure 28.1. Meiosis

[http://commons.wikimedia.org/wiki/File:MajorEventsInMeiosis\\_variant.svg](http://commons.wikimedia.org/wiki/File:MajorEventsInMeiosis_variant.svg)

## Sperm Cells

Mature sperm cells contain three parts including a head, midpiece and tail (fig. 28.2). The head contains the genetic material and has an enzyme containing structure called an acrosome on its outer surface. The acrosome contains enzymes such as hyaluronidase that help the sperm cell penetrate the egg cell of the female. The midpiece contains many mitochondria that produce a good deal of energy in the form of ATP to power the long tail or flagellum. The tail contains the flagellum which is constructed of protein microtubules.

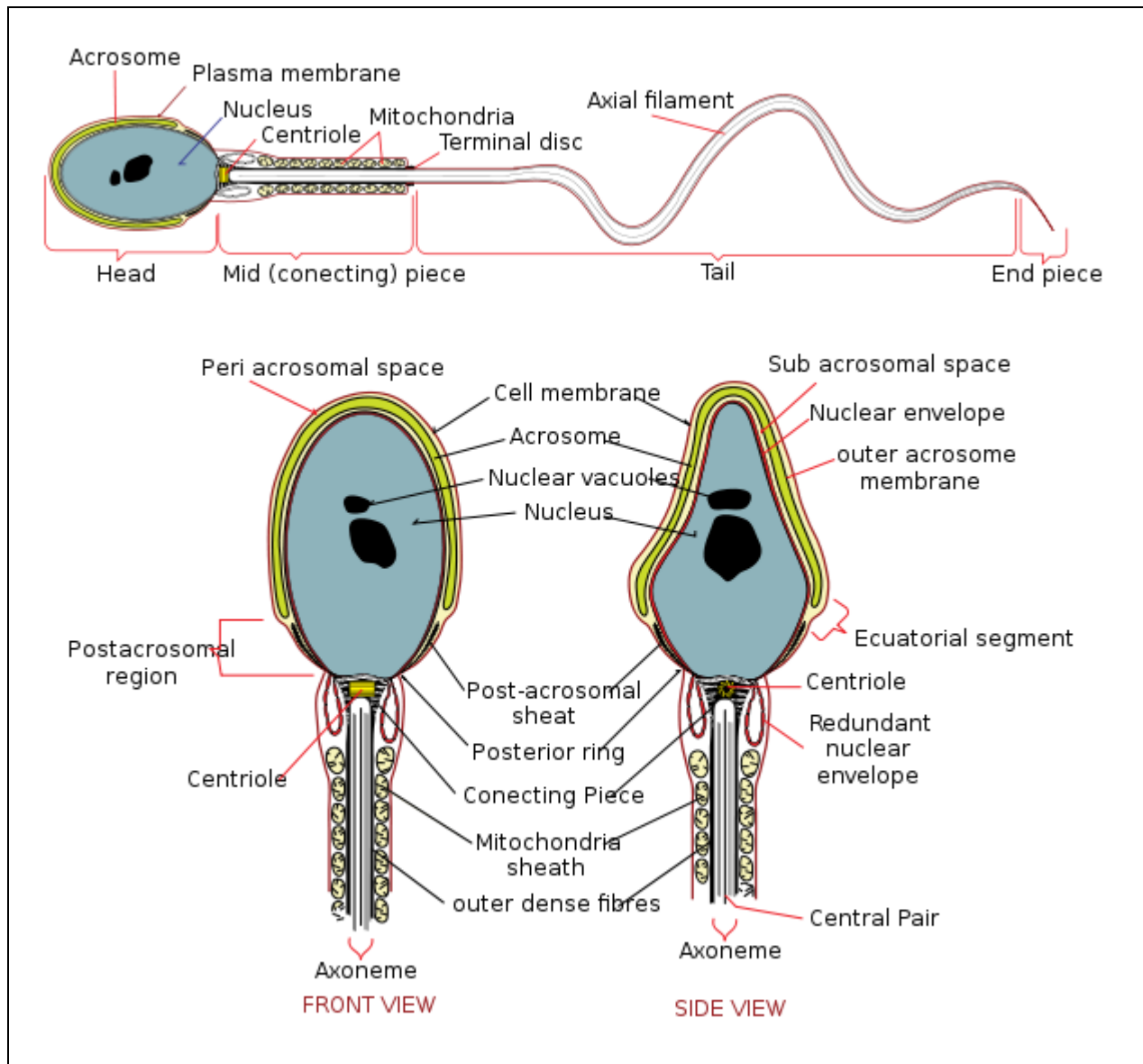


Figure 28.2. Sperm cell

[http://commons.wikimedia.org/wiki/File:Complete\\_diagram\\_of\\_a\\_human\\_spermatozoa.svg](http://commons.wikimedia.org/wiki/File:Complete_diagram_of_a_human_spermatozoa.svg)



## **Erection and Ejaculation**

The sacral spinal cord sends parasympathetic impulses to the penis during sexual stimulation. The impulses result in the secretion of nitric oxide which causes vasodilation of the deep arteries in the erectile columns of the penis. Blood then fills the erectile columns which in turn close off the return pathway for blood by compression the dorsal vein of the penis. The penis then becomes erect.

Sexual stimulation then results in orgasm, emission and ejaculation. Emission is the movement of sperm and secretions from the seminal vesicle, prostate and bulbourethral gland into the urethra. Emission is under sympathetic control from the sacral spinal cord which results in smooth muscle contractions throughout the reproductive tract. Skeletal muscles at the base of the penis contract to cause ejaculation which is the forceful expelling of semen from the urethra. Following ejaculation sympathetic impulses cause vasoconstriction of the arteries of the penis and the penis again becomes flaccid.

## **Testosterone**

Besides facilitating spermatogenesis, testosterone has other important functions in the male reproductive system. Testosterone is one of a group of hormones called androgens (male hormones). Testosterone is a steroid hormone and is converted to another form called dihydrotestosterone in certain cells in the male system such as in the prostate and seminal vesicles.

Testosterone levels are higher during fetal development to help initial development of the male reproductive system and descent of the testes. Testosterone levels then fall during childhood until puberty where they again rise to essentially finish the job of maturation of the male reproductive system.

The actions of testosterone during puberty include the following:

Enlargement of the vocal cords and deepening of the voice.

Increased muscular growth.

Increased body hair on face, axilla and pubic areas.

Strengthening of bones.

Increased metabolism.

Maturation of the sex organs.

Testosterone is regulated by a feedback mechanism involving hormones from the hypothalamus and anterior pituitary gland. We saw that testosterone is secreted in response to LH secreted by the anterior pituitary gland. LH is secreted in response to gonadotropin releasing hormone from the hypothalamus. Blood concentration of testosterone is monitored by the hypothalamus which responds through negative feedback to control the secretion of gonadotropin releasing hormone. The testes also secrete a hormone called inhibin which feeds back to the hypothalamus exhibiting the same effect as testosterone.

## **Female Reproductive Physiology**

It is interesting to note that a number of the regulatory hormones are the same for both males and females. These include gonadotropin releasing hormone, FSH and LH.

### **Oogenesis**

Each ovary contains millions of sex cells called oocytes. The oocytes are encased in structures called follicles. At the premature stage the follicles are known as primordial follicles and each contains a primary oocyte. The primary oocytes begin meiosis but do not complete it until puberty. The development of oocytes is known as oogenesis.

As oogenesis continues at puberty the primary oocytes finish meiosis I which results in two cells each containing the haploid number of chromosomes (23). When the oocytes finish meiosis I they are called secondary oocytes. Unlike spermatogenesis in the male the resultant cells consist of one secondary oocyte and a polar body. The polar body is not a viable cell but helps the secondary oocyte conserve resources to help make it as viable as possible. Development stops at this point unless fertilization occurs. Once the secondary oocyte is fertilized it completes meiosis and produces a second polar body. The fertilized cell is now called a zygote and has the diploid number of chromosomes (46).

The follicle plays an important role in oogenesis as well. The follicle matures under the influence of FSH. It first becomes a primary follicle and contains a region known as the zona pellucida. The zona pellucida contains glycoprotein that gradually separates the oocyte from the inner walls of the follicle. The follicle continues to mature into a secondary follicle which is characterized by the presence of a cavity called the antrum. The oocyte is pushed against the inner wall of the follicle at this stage. Finally the follicle reaches the end of maturation as it becomes a mature or Graffian follicle. The antrum is filled with fluid and the follicle moves to the surface of the ovary. Maturation of the follicle occurs in half of the menstrual cycle.

At about midway through the menstrual cycle the follicle pushes the oocyte out in what is called ovulation. This occurs in response to a surge of LH from the anterior pituitary gland. The oocyte moves toward the Fallopian tube. If it becomes fertilized it will eventually move to the uterus for implantation. If it is not fertilized it will degenerate.

### **Female Sex Hormones**

During fetal development the hormones gonadotropin releasing hormone (GnRH), FSH and LH cause the initial development of the reproductive system as well as descent of the ovaries to their normal position in the pelvic cavity. Secretion of GnRH then decreases until puberty which occurs at about age 10. During puberty the levels of these hormones increases causing the secretion of estrogens and progesterone.

Estrogens are a group of molecules with estradiol as the most abundant. Estrogens are secreted by the ovaries as well as the adrenal glands, adipose tissue and the placenta (during pregnancy). Estrogens promote development of the secondary sex organs of the female. Actions of estrogen include:

Development of the breasts.

An increase in adipose tissue under the skin in specific areas of the body (thighs, buttocks, breasts).

There are also changes associated with the secretion of androgens during puberty including increased hair in the genital and axillary regions.

Estrogens also provide negative feedback to the hypothalamus and anterior pituitary gland. For example a rise in estrogen levels works to inhibit the secretion of GnRH which in turn inhibits the secretion of FSH and LH.

### **Menstrual Cycle**

The female menstrual cycle begins during puberty (between the ages of 10-13 years). It is characterized by changes in the endometrium of the uterus. The first menstrual cycle is called menarche. GnRH is secreted by the hypothalamus causing the secretion of FSH and LH. FSH causes maturation of the ovarian follicle and secretion of estrogens by the granulosa cells. LH also helps the follicle to mature and stimulates the production of estrogens. Estrogens cause an increase in the thickening of the endometrium during the first phase of the menstrual cycle (proliferative phase) (fig. 28.3).

During the proliferative phase the follicle secretes estrogen that works to inhibit the release of LH. Instead of being released by the anterior pituitary, LH is stored. At about the 14<sup>th</sup> day LH is released (LH surge) causing the follicle to release the oocyte in what is called ovulation. The follicle then moves toward the Fallopian tube and is either fertilized or not (fig. 28.4).

Following ovulation, the follicle becomes what is known as a corpus luteum. The corpus luteum secretes large amounts of progesterone and estrogens during this second half of the cycle. The estrogens and progesterone inhibit the release of LH and FSH from the anterior pituitary which in turn keeps other follicles from maturing. Progesterone also facilitates increased vascularization and thickening of the endometrium. If the oocyte is not fertilized the corpus luteum begins to degenerate near the end of the cycle at around the 24<sup>th</sup> day. What is left of the degenerated corpus luteum is called a corpus albicans. When the follicle goes from the corpus luteum stage to the corpus albicans stage the secretions of estrogen and progesterone diminish. This causes the thickened endometrium to slough off. The endometrium and accompanying blood constitute the menstrual flow which continues for about 3-5 days.

Menstruation continues throughout the female lifespan until the late 40s or early 50 where it begins to become irregular and eventually stops completely. This process marks the period of menopause. During this time the few remaining follicles no longer respond to FSH and LH. Since the follicles do not mature there is a subsequent drop in estrogens and progesterone. The consequences of low levels of these hormones include thinning of the vaginal, urethral and uterine linings, osteoporosis, and thinning of the skin.

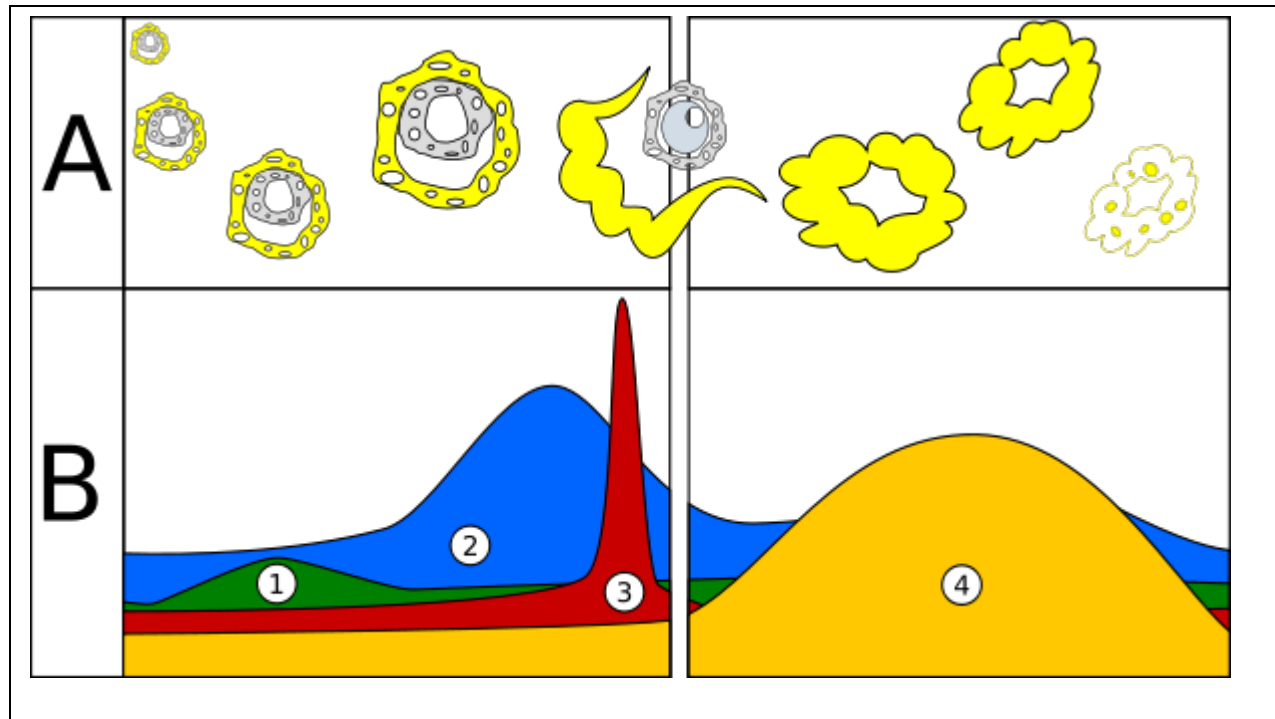


Figure 28.3. Menstrual Cycle

- 1 Follicle-Stimulating Hormone
- 2 Estrogens
- 3 Luteinizing Hormone
- 4 Progesterone
- A Maturing follicle & corpus luteum
- B Hormones level

[http://commons.wikimedia.org/wiki/File:Hormons\\_level\\_-\\_follicle\\_%26\\_corpus\\_luteum.svg](http://commons.wikimedia.org/wiki/File:Hormons_level_-_follicle_%26_corpus_luteum.svg)

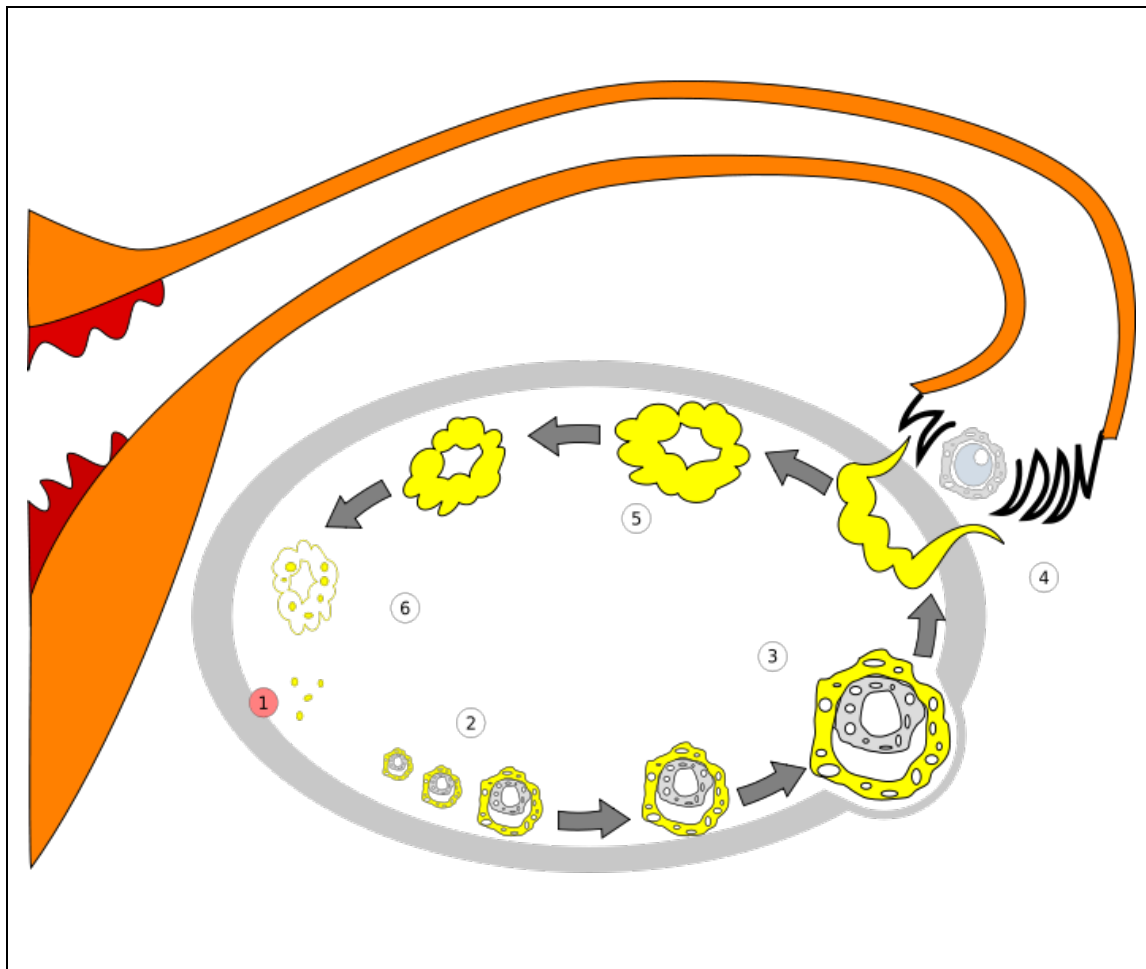


Figure 28.4. Follicle development

- 1 - Menstruation
- 2 - Maturing follicle
- 3 - Mature follicle
- 4 - Ovulation
- 5 - Corpus luteum
- 6 - Deterioration of corpus luteum

[http://commons.wikimedia.org/wiki/File:Order\\_of\\_changes\\_in\\_ovary.svg](http://commons.wikimedia.org/wiki/File:Order_of_changes_in_ovary.svg)

Sperm cells that reach the oocyte attempt to penetrate it with the help of the enzymes located in the acrosome. Once a sperm cell penetrates the oocyte it sheds its tail and the oocyte becomes unresponsive to other sperm. The nucleus of the sperm cell enters the oocyte and the oocyte undergoes meiosis II creating a second polar body. The genetic material from sperm and oocyte combine and the resultant cell is called a zygote. The zygote continues mitotic division to form a group of cells that migrates to the uterus. The Fallopian tube helps the migration along with its ciliated epithelial lining and smooth muscle contractions. The cells eventually implant in the wall of the uterus.

The layer surrounding the embryo secretes a hormone called human chorionic gonadotropin which helps to maintain the corpus luteum throughout the pregnancy. This results in high levels of estrogens and progesterone. After the first trimester the placenta takes over the job of secreting these hormones.

### **Breast Milk Production**

The hormone prolactin works to stimulate milk production after birth. The first milk to appear is called colostrum which contains some nutrients including proteins and antibodies. When the infant suckles the breast the sensory impulses travel to the hypothalamus which in turn causes the release of oxytocin from the posterior pituitary. Oxytocin causes milk ejection by stimulating contraction of the myoepithelial cells of the breasts.

## Chapter 28 Review Questions

1. Which of the following is the main difference between meiosis and mitosis:
  - a. The number of chromosomes are doubled in meiosis
  - b. Meiosis is much slower than mitosis
  - c. Mitosis produces better cells
  - d. The number of chromosomes are halved in meiosis
2. Which best describes the function of the acrosome:
  - a. Helps to propel the sperm
  - b. Helps to nourish the sperm
  - c. Helps the sperm gain access to the oocyte
  - d. Helps to develop the sperm
3. Which of the following is not a function of testosterone:
  - a. Thickens vocal cords
  - b. Increases muscular growth
  - c. Causes testes to descend
  - d. Decreases metabolism
4. Which of the following best describes the function of inhibin:
  - a. Inhibits the secretion of gonatotropin releasing hormone
  - b. Stops growth and metabolism
  - c. Inhibits secretion of estrogen
  - d. Inhibits parasympathetic impulses
5. A mature ovarian follicle is known as:
  - a. Corpus albicans
  - b. Oocyte
  - c. Graffian follicle
  - d. Leuteal follicle
6. Which hormone causes ovulation:
  - a. Follicle stimulating hormone
  - b. Luteinizing hormone
  - c. Estrogen
  - d. Progesterone
7. How long is the proliferative phase of the ovarian cycle:
  - a. 10 days
  - b. 12 days
  - c. 14 days
  - d. 16 days

8. What happens when the corpus leuteum degenerates:
  - a. It secretes estrogen
  - b. It secretes progesterone
  - c. It secretes luteinizing hormone
  - d. It ceases to secrete estrogen and progesterone
  
9. The first breast milk to appear is called:
  - a. Prenatal milk
  - b. Colostrum
  - c. Estrostum
  - d. Prolactin
  
10. This hormone works to maintain the corpus leuteum:
  - a. Estrogen
  - b. Human chorionic gonadotropin
  - c. Gonadotropin releasing hormone
  - d. Progesterone



# Chapter 29

## Overview of Genetics

## Overview of Genetics

### Genes

An area on DNA that contains the information for producing a specific trait is called a gene. All of the genes in DNA are known as the genome. The human genome contains 35,000 to 45,000 genes.

Chromosomes are called homologous if they have the same gene at the same location or “locus.” Different forms of the same gene are called alleles. One example of an allele is the gene for eye color. The variations in eye color among individuals results from different alleles in the same gene.

Alleles can also be dominant or recessive. Dominant alleles will cause a particular variation of a trait to be expressed. Recessive alleles need to be present on both homologous chromosomes in order to be expressed. Dominant alleles will also mask recessive alleles. Dominant alleles are referred to with a capital letter while recessive alleles are referred to with a small letter. There are also wild type alleles that are neither dominant nor recessive but are considered the normal form of the gene.

Homozygous individuals have identical alleles on their homologous chromosomes. For example they may have 2 dominant or 2 recessive alleles. Heterozygous individuals have different alleles on their homologous chromosomes. The alleles for a specific trait produce the genotype while the expression of the trait is known as the phenotype.

Genes can also be X-linked, Y-linked or autosomal. X-linked genes are carried on the X-chromosome while Y-linked genes are carried on the Y chromosome. Autosomal traits are carried on non-sex chromosomes.

Autosomal conditions are equally likely to affect either males or females. Recessive traits can sometime skip a generation if both parents are heterozygotes. Dominant traits do not skip generations.

One tool used to calculate the probabilities of inheriting a trait is called the Punnett square. The mother’s alleles are listed across the top while the father’s alleles are listed on the left side. The inside boxes hold the combinations of the mother’s and father’s alleles (figs. 29.1, 29.2).

# Punnett Square

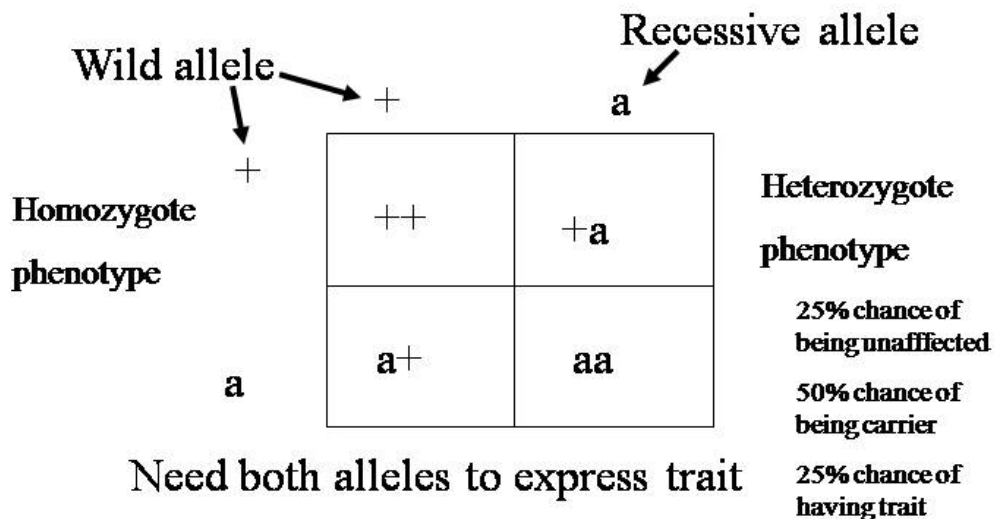


Figure 29.1. Punnett square for recessive trait.

Dr. Bruce Forciea

A disease causing allele is considered penetrant if it is expressed in every individual who inherits it. Incompletely penetrant alleles are only expressed in some individuals. These are usually expressed in percentages. For example an incompletely penetrant trait may show up in 60% of the individuals with that particular allele.

Sometimes one genetic problem can cause a variety of symptoms. This is known as pleiotropy. An example of pleiotropy is the symptoms associated with Sickle Cell anemia. Sickle cell anemia causes the production of misshapen red blood cells. These misshapen cells affect oxygen concentration in the blood and tissues and can have a variety of effects on various organs.

# Punnett Square

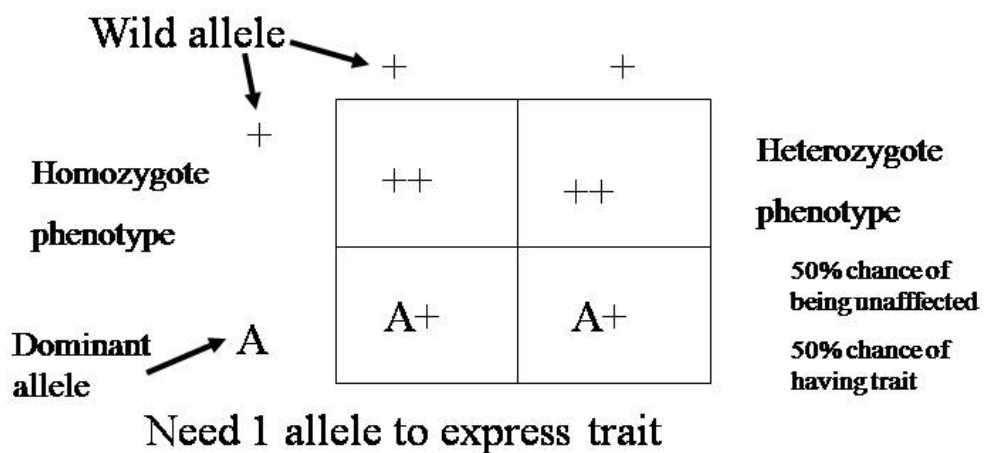


Figure 29.2. Punnett square for dominant trait.

Dr. Bruce Forciea

Cells with the normal number of chromosomes are called euploids while cells with extra or missing chromosomes are called aneuploids. Cells with autosomal aneuploidy cause more severe problems such as mental retardation than those with sex-linked chromosomal aneuploidy.

Aneuploidy is caused by an error in meiosis. Normally, homologous chromosomes separate during meiosis but in aneuploidy they fail to separate. This meiotic error is also known as nondisjunction.

Genes can exist in more than one allelic form. For example blood types are determined by 3 alleles consisting of 2 dominant and 1 recessive. We can represent the dominant allele with a capital I and the recessive allele with a small i.

Blood Type Allele	Blood Type
I <sup>A</sup>	A
I <sup>B</sup>	B
i	O

Parent 1 Allele	Parent 2 Allele	Child's Genotype	Blood Type
I <sup>A</sup>	I <sup>A</sup>	I <sup>A</sup> I <sup>A</sup>	A
I <sup>A</sup>	I <sup>B</sup>	I <sup>A</sup> I <sup>B</sup>	AB
I <sup>A</sup>	i	I <sup>A</sup> i	A
I <sup>B</sup>	I <sup>A</sup>	I <sup>B</sup> I <sup>A</sup>	AB
I <sup>B</sup>	I <sup>B</sup>	I <sup>B</sup> I <sup>B</sup>	B
I <sup>B</sup>	i	I <sup>B</sup> i	B
i	i	ii	O

### Sex-Linked Traits

Traits carried on the X or Y chromosomes are known as sex-linked traits. These traits are inherited differently than autosomal traits because of the different distribution of X and Y chromosomes in males and females. Males contain an XY combination while females contain and XX combination.

Y-linked traits are transmitted from males to their male children. The Y chromosome is inherited from a male's father while the X chromosome is inherited from his mother. Females inherit one X chromosome from each parent. Genes on the X chromosomes of males are expressed because there is no other X chromosome containing a second allele. An example of a recessive X-linked trait is the inheritance of hemophilia. Alleles on the X chromosomes in females may or may not be expressed. The expression depends on the presence of dominant or recessive alleles on the other X chromosome.

An example of an X-linked trait is the disease hemophilia. Hemophilia A is a disorder resulting from a mutation on the gene that encodes for one of the clotting factors (Factor VIII). The gene is located on the X chromosome. Since males only have one X chromosome, those who inherit the mutated gene will express the disease since there is no other X chromosome containing an allele to counteract it. In heterozygous females however a normal gene on one X chromosome will still be able to code for the clotting factor. The incidence of hemophilia then is much greater in males than in females.

## Chapter 29 Review Questions

1. How many genes are in the human:
  - a. 10,000-15,000
  - b. 15,000-20,000
  - c. 25,000-35,000
  - d. 35,000-45,000
2. Different forms of the same genes are called:
  - a. Alleles
  - b. Chromosomes
  - c. Genomes
  - d. Chromatids
3. If both mother and father contain the allele for a specific trait then their offspring has a \_\_\_\_ chance of expressing the trait:
  - a. 50%
  - b. 10%
  - c. 25%
  - d. 100%
4. Which of the following terms is used when one genetic problem causes a variety of symptoms:
  - a. Homozygous
  - b. Pleitropy
  - c. Heterozygous
  - d. Primary inheritance
5. A trait carried on the X or Y chromosome is called:
  - a. Male trait
  - b. Pleitropy
  - c. Sex-linked
  - d. Chromosomal

# Chapter 30

## Fetal Circulation

## Fetal Circulation

One of the most amazing things that occur at birth is the changes in the circulatory system to allow functioning of the newborn's lungs. Within minutes the newborn takes his first breath and no longer relies on his mother for a supply of oxygenated blood. In this section we will outline the changes that occur in fetal circulation in order to allow the lungs to function.

The developing fetus primarily derives its nutrition from the placenta. The placenta is located within the uterus and contains the umbilical cord consisting of 2 umbilical arteries and an umbilical vein (figs. 30.1, 30.2). Nutrients diffuse from the mother's circulation to the placenta. These nutrients diffuse from the mother's circulation into structures known as chorionic villi. The chorionic villi are imbedded in the endometrium of the uterus. They are arranged in a way that they are filled with fetal blood while surrounded by maternal blood.

The fetal heart pumps blood through the arterial system including the umbilical arteries where they reach the placenta and return by way of the umbilical vein. Many substances move across the membrane separating the fetus and mother by diffusion. Since substances move from areas of higher concentration to lower concentration substances such as oxygen move from mother to fetus while waste products such as carbon dioxide move from fetus to mother.

The oxygenated blood moves to the fetus by way of the umbilical vein. The umbilical vein travels along the abdominal wall to the liver where it joins the ductus venosus. About half of the freshly oxygenated blood enters the liver directly from the umbilical vein while the other half bypasses the liver by way of the ductus venosus. The ductus venosus then carries blood to the inferior vena cava where the oxygenated blood mixes with deoxygenated blood from the lower portion of the fetus.

The inferior vena cava transports blood to the right atrium of the heart. The fetal heart contains 2 bypass routes that bypass the lungs since the lungs are not functional. Typically blood flows from the right atrium to the right ventricle then exits via the pulmonary trunk. However in the fetal heart blood is shunted from the right ventricle to the left ventricle through a passageway known as the foramen ovale. A small flap-like valve called the septum primum allows a one-way passage of blood from the right to the left atrium.

Not all of the blood passes from the right to the left atrium through the foramen ovale. The remaining blood enters the right ventricle and exits via the pulmonary trunk. A small amount of blood enters the lungs and provides oxygen to the lung tissues. The remaining blood flowing in the pulmonary trunk bypasses the lungs by traveling through a vessel known as the ductus arteriosus. The ductus arteriosus connects the pulmonary trunk with the descending portion of the aorta.

Oxygenated blood moving from the right to left atrium is pumped into the left ventricle. This blood mixes with some deoxygenated blood from the pulmonary veins. The resulting mixture is pumped into the aorta and out to the body. This partially oxygenated blood then moves to the inferior portions of the aorta and its associated branches. Some of this blood passes to the umbilical arteries that branch off of the internal iliac arteries. The umbilical arteries return this blood to the placenta for oxygenation.



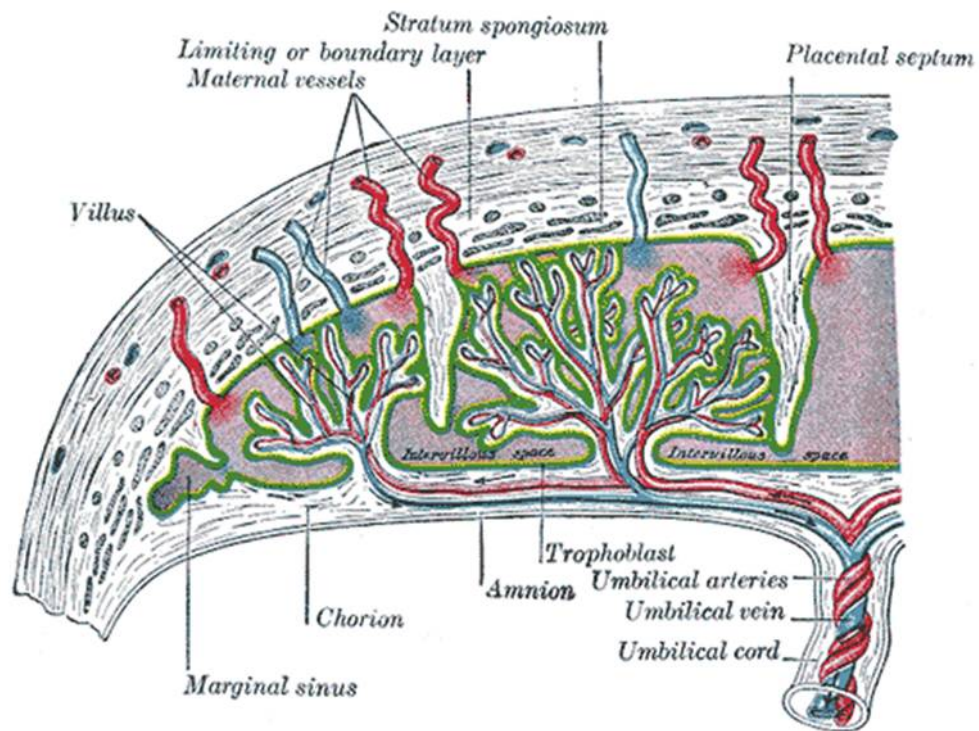


Figure 30.1. The placenta.

<http://commons.wikimedia.org/wiki/File:Gray39.png>

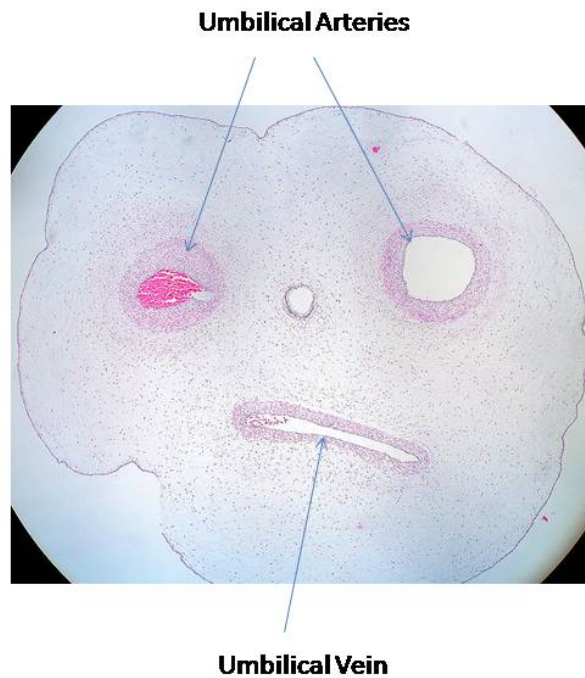

Figure 30.2. The umbilical cord contains 2 umbilical arteries and an umbilical vein.

[http://commons.wikimedia.org/wiki/File:The\\_Umbilical\\_Cord.jpg](http://commons.wikimedia.org/wiki/File:The_Umbilical_Cord.jpg)

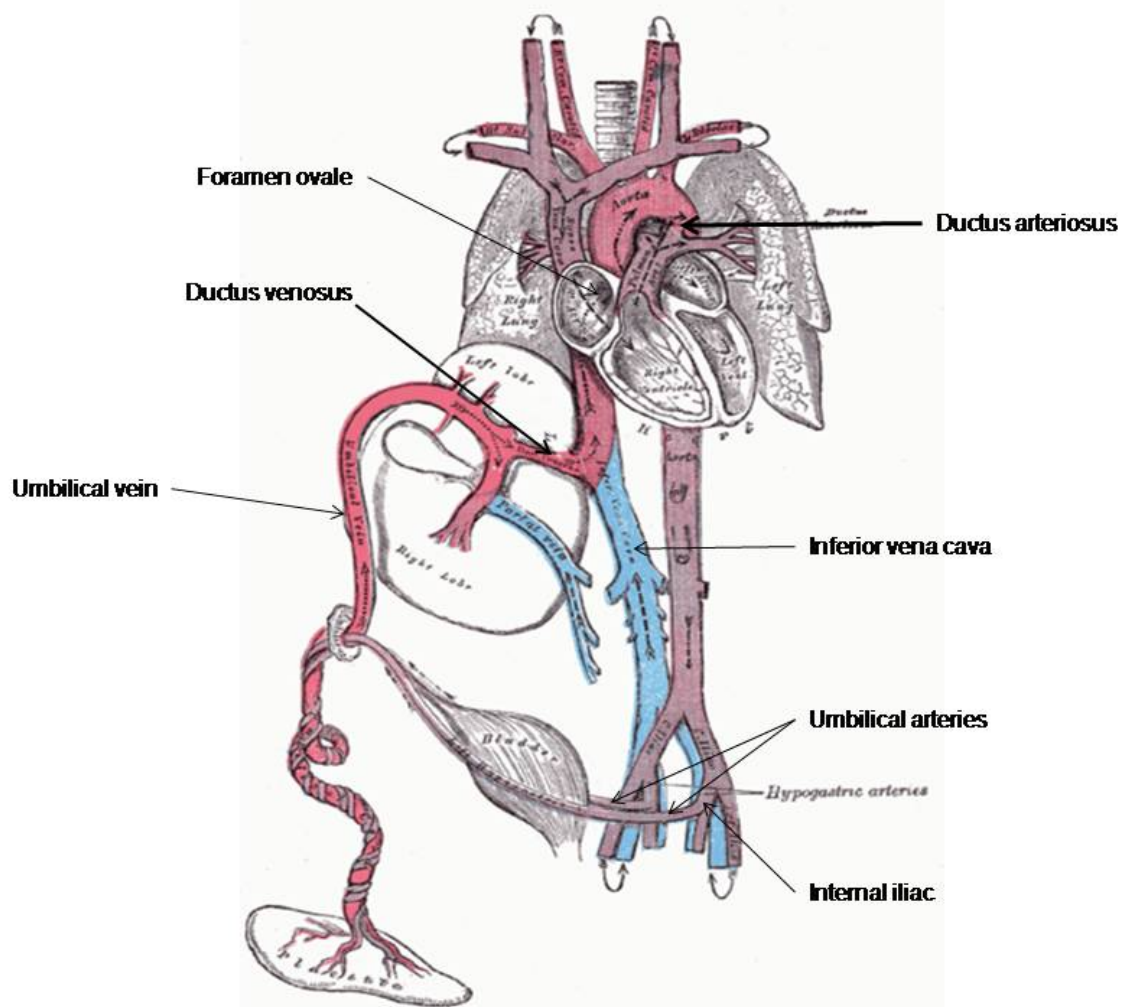


Figure 30.3. Fetal Circulation.

[http://commons.wikimedia.org/wiki/File:Fetal\\_circulation.png](http://commons.wikimedia.org/wiki/File:Fetal_circulation.png)

## Chapter 30 Review Questions

1. The umbilical cord contains:
  - a. 1 umbilical artery and vein
  - b. 2 umbilical arteries and veins
  - c. 2 umbilical arteries and 1 vein
  - d. 1 umbilical artery and 2 veins

### Matching

- |  |                       |
|--|-----------------------|
| 2. _____ passageway between atria          | a. umbilical arteries |
| 3. _____ located in liver                  | b. ductus arteriosum  |
| 4. _____ between pulmonary trunk and aorta | c. umbilical vein     |
| 5. _____ return path                       | d. foramen ovale      |
| 6. _____ carries oxygenated blood to fetus | e. ductus venosum     |
- 
7. Which of the following does not occur at or shortly after birth:
    - a. Ductus venosum become teres ligament
    - b. Ductus arteriosum become ligament arteriosum
    - c. Foramen ovale closes
    - d. Umbilical vein becomes inferior vena cava

## Answers to Review Questions

### C1 Introduction to the Human Body

1. B
2. B
3. A
4. A
5. D
6. D
7. D
8. A
9. B
10. C
11. B
12. C
13. C
14. A
15. B
16. B
17. B
18. D

### C2 Basic Chemistry Review

1. D
2. B
3. D
4. B
5. B
6. B
7. C
8. C
9. B
10. C
11. D
12. C
13. C
14. B

### C3 Cells

1. B
2. A
3. C
4. C
5. A
6. C
7. A
8. D
9. C
10. C
11. C
12. C
13. B
14. A
15. B
16. D
17. A
18. B

### C4 Overview of Cellular Metabolism

1. D
2. A
3. A
4. B
5. C
6. C
7. D
8. C
9. B
10. C

### C5 Tissues

1. C
2. B
3. D
4. B
5. B
6. A
7. A
8. C
9. C
10. B
11. D
12. D

#### C6 The Integument

1. B
2. D
3. B
4. B
5. A
6. D
7. A
8. D
9. B
10. A
11. C
12. C

#### C7 The Skeletal System

1. D
2. D
3. D
4. A
5. B
6. B
7. A
8. C
9. B
10. A
11. D
12. B
13. B
14. C
15. C
16. D
17. B
18. A
19. D
20. B

#### C8 Joints

1. D
2. B
3. B
4. C
5. D
6. D
7. D
8. D
9. B
10. D

### C9 The Muscular System

1. B
2. A
3. B
4. C
5. C
6. C
7. A
8. B
9. A
10. B

### C10 Muscular System Physiology

1. B
2. B
3. D
4. B
5. B
6. C
7. A
8. A
9. C
10. A
11. A
12. D
13. C

### C11 Nervous system Anatomy

1. C
2. C
3. B
4. C
5. C
6. C
7. B
8. C
9. B
10. A
11. D
12. C
13. B
14. C
15. B
16. D
17. A



18. C
19. B
20. B
21. C
22. B
23. C
24. B
25. D

#### C12 Nervous System Physiology

1. C
2. B
3. A
4. B
5. B
6. B
7. A
8. D
9. D
10. D
11. B
12. B

#### C13 The Senses

1. D
2. C
3. A
4. C
5. B
6. D
7. B
8. C
9. A
10. A
11. B
12. B
13. A
14. C
15. B
16. C

#### C14 The Endocrine System

1. D
2. B
3. B
4. C
5. D
6. B
7. C
8. A
9. C
10. B

#### C15 The Blood

1. A
2. B
3. A
4. B
5. A
6. A
7. B
8. C
9. B
10. C
11. C
12. C

#### C16 The Lymphatic System

1. D
2. C
3. D
4. A
5. C
6. A
7. B

#### C17 Immunity

1. C
2. A
3. C
4. B
5. A
6. C
7. D
8. B

#### C18 Cardiovascular System Anatomy

1. C
2. C
3. B
4. B
5. A
6. C
7. B
8. D
9. B
10. A
11. C
12. C
13. B
14. C
15. C

#### C19 Cardiovascular System Physiology

1. C
2. C
3. C
4. B
5. C
6. C
7. B
8. A
9. B
10. C
11. A
12. D
13. C
14. B
15. A

#### C20 Respiratory System Anatomy

1. B
2. A
3. D
4. B
5. A
6. C
7. B
8. D
9. A
10. D
11. C

### C21 Respiratory System Physiology

1. B
2. C
3. A
4. C
5. B
6. B
7. C
8. A
9. D
10. A
11. D
12. C

### C22 Urinary System Anatomy

1. D
2. C
3. D
4. A
5. C
6. A
7. C
8. A
9. D
10. D

### C23 Urinary System Physiology

1. C
2. D
3. C
4. A
5. B
6. B
7. A
8. C
9. D
10. B
11. C
12. D
13. C
14. B

#### C24 Fluids, Electrolytes, Acid-Base Balance

1. D
2. C
3. D
4. A
5. D
6. C
7. D
8. D
9. A
10. D
11. B
12. C

#### C25 Digestive System Anatomy

1. C
2. B
3. C
4. A
5. D
6. D
7. A
8. C
9. B
10. B
11. C
12. D

#### C26 Digestive System Physiology

1. B
2. D
3. C
4. A
5. D
6. C
7. B
8. C
9. A
10. C

#### C27 Reproductive System Anatomy

1. B
2. C
3. C
4. D
5. B
6. B
7. A
8. C
9. A
10. B

#### C28 Reproductive System Physiology

1. D
2. C
3. D
4. A
5. C
6. B
7. C
8. D
9. B
10. B

#### C29 Overview of Genetics

1. D
2. A
3. C
4. B
5. C

#### C30 Fetal Circulation

1. C
2. D
3. E
4. B
5. A
6. C
7. D

### **Image Credits**

Many images are public domain images from Wikimedia Commons. Boxes below the image contain the link to that image that provides the specific copyright for the image. Authors of images are listed when found. For detailed image information including author information click on the link in the box below the image.

Visit my website at:

[www.drbruceforciea.com](http://www.drbruceforciea.com)

For course information, podcasts, videos and other anatomy and physiology information.